

Case Reports

Monika Prochorec-Sobieszek¹, Jerzy Windyga², Renata K. Maryniak¹, Andrzej Misiak³,
Andrzej Szczepanik³

Angiodysplasia as a Cause of Recurrent Bleeding from the Small Bowel in Patients with von Willebrand Disease. Report of 4 Patients

¹Department of Pathomorphology, Institute of Hematology and Blood Transfusion, Warszawa,

²Blood Coagulation Laboratory, Institute of Hematology and Blood Transfusion, Warszawa,

³Department of Surgery, Institute of Hematology and Blood Transfusion, Warszawa

Angiodysplasia, characterized by the presence of malformed vessels in the submucosa of the gastrointestinal tract, may be a cause of recurrent bleeding. Bleeding angiodysplasia can be associated with von Willebrand disease (vWD) and this coincidence is probably the consequence of the lack of high molecular weight molecules of von Willebrand factor in the plasma. We report four patients with unexplained repeated massive intestinal bleeding, recurrent melena and iron deficiency anemia, which required numerous blood transfusions. All patients were adults (average age 68 years). Three patients have congenital von Willebrand disease (type 1, 2A and 3) and one idiopathic acquired von Willebrand syndrome. Correct diagnosis was made 2–5 years after the onset of the symptoms and was confirmed by histopathological examination of surgically resected small bowel, where vascular lesions were located. Elderly patients with recurrent gastrointestinal bleeding and unexplained iron deficiency anemia should be diagnosed for angiodysplasia and vWD.

Introduction

Angiodysplasia is probably an acquired degenerative lesion associated with the aging process, in which malformed vessels are found in submucosa and mucosa of the gastrointestinal (GI) tract [3]. They appear due to abnormalities of the arteriolar-capillary sphincter and subsequent large increase in the blood outflow, which results in dilatation of veins, venules and capillaries [8]. These lesions may be located anywhere in the GI tract

(stomach, jejunum, duodenum, tongue), but most of them are found in the caecum and the ascending colon [2]. Angiodysplasia is being recognized with increased frequency as a major cause of recurrent spontaneous gastrointestinal bleeding especially in patients over 60 years, although it may be asymptomatic. Factors causing bleeding in angiodysplasia have not been clearly identified. It has been known that angiodysplasia can accompany various diseases, such as aortic stenosis, chronic renal failure and von Willebrand disease (vWD) [12]. Von Willebrand disease is the commonest inherited bleeding disorder (1% of population) caused by quantitative or qualitative defects of von Willebrand factor (vWF). The factor is an adhesive glycoprotein (one of two components of FVIII) synthesized in megakaryocytes, endothelial cells and also present in the plasma, subendothelial space and blood platelets. vWF exists as series of multimers of molecular weight 800–20,000kDa and participates in both primary and secondary hemostasis. It mediates adhesion of platelets to the injured subendothelium and participates in platelets aggregation, especially when high rate of blood flow through vascular malformation produces locally a very high shear condition [5, 7]. vWF also serves as a protective carrier for plasma factor VIII (FVIII). Defects in vWF may cause, therefore, bleeding by impairing either platelet adhesion or fibrin clot formation. The bleeding tendency in von Willebrand disease may be mild, moderate or severe, proportionally to the degree of the vWF defect. Typical bleeding symptoms are characterized by prolonged oozing after minor and major surgery and by mucosal tract hemorrhages such as epistaxis and metrorrhagia. Only some of the more severely affected patients have soft-tissue bleeding, such

as muscle hematomas and hemarthroses [5]. Patients with a negative family history and with a recent personal history of bleeding may have an acquired diathesis similar to congenital vWD. It is usually associated with other clinical conditions and is called acquired von Willebrand syndrome (AvWS) [11].

Patients with vWD and associated GI angiodysplasia, who often require numerous hospital admissions for GI bleeding needing massive transfusions with packed red cells, FVIII-vWF concentrates and plasma, are a serious problem. Recent evidence suggests that bleeding GI angiodysplasia associated with vWD is probably not a mere coincidence but a consequence of the absence of the HMW multimers of vWF in the plasma [4, 12]. Although the first report on the association between bleeding angiodysplasia and vWD appeared in 1976 [9] and then other investigators reported this coincidence [2, 4], the correct diagnosis of this disease is frequently established many months or years after the onset of symptoms. It is probably due to difficulties in clinical and histopathological evaluation.

Description of Cases

Data of all patients are given in the Table 1. Patient No. 3 will be presented in more detail for demonstration of the usual clinical course.

A 68 years old woman was admitted for evaluation of severe, intermittent GI bleeding, recurrent melena and anemia that has been present for 5 years. At the age of 13 she had recurrent metrorrhagia and then on the basis of

laboratory tests and family history the congenital von Willebrand disease type 3 was recognized. Episodes of melena began after the age of 60. They were followed by decrease of hematocrit to 20%. Subsequently she had numerous (>30) hospital admissions for GI bleeding requiring transfusions with packed red cells, cryoprecipitate and factor VIII/vWF concentrates. Repeated radiological and endoscopic studies did not reveal any source of bleeding. Because of a life-threatening GI bleeding the only treatment option was surgical intervention. During the operation a fragment of the jejunum (120cm), filled with fresh blood was resected and end-to-end anastomosis of the intestine was performed.

In all cases during gross examination of the resected small intestine fragments no mucosal vascular lesion, mucosal ulceration or hemorrhage were found. Therefore

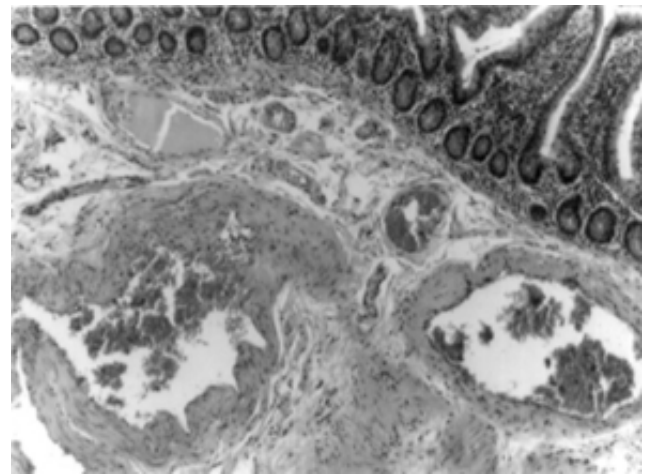


Fig. 1. Dilated and distorted dysplastic vessels with irregularly thickened walls in the submucosa of the small bowel. HE. Magn. 100x.

TABLE 1

Clinical features of the patients

Variable	Patient 1 J.J.	Patient 2 K.W.	Patient 3 A.B.	Patient 4 M.B.
Age(y)/Sex	73/female	58/male	68/female	73/female
Type of vWD	Familial type 1	Familial type 2A	Familial type 3	Acquired idiopathic
Presentation	recurrent melena hematemesis anemia	recurrent melena anemia	upper GI bleeding recurrent melena anemia	recurrent melena anemia
Affected site	jejunum	jejunum	jejunum	jejunum
Method of detection	during surgery	during surgery	during surgery	during surgery
Duration between initial symptoms and diagnosis (years)	4	2	5	1
Treatment	partial resection of the small intestine	partial resection of the small intestine	partial resection of the small intestine	partial resection of the small intestine
Outcome	3 years stable and next 3 years recurrent melena	6 months without bleeding episodes	1 year after surgery 1 bleeding episode	4 years with no bleeding episodes

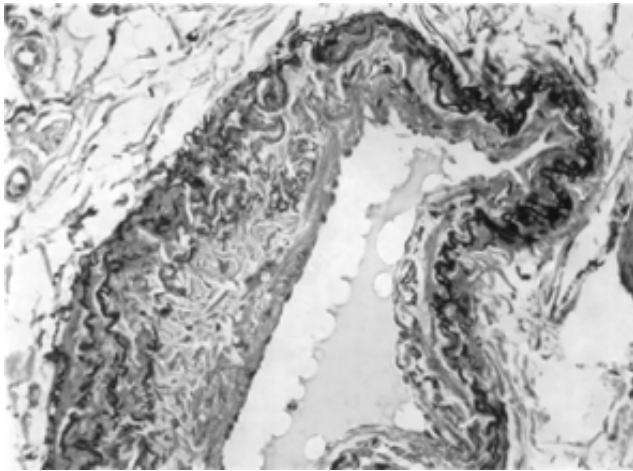


Fig. 2. Fragmentation and multiplication of elastic fibers in the wall of dysplastic submucosal vessel. Orcein. Magn. 200x.

many sections were needed for microscopic analysis and some revealed collections of abnormal, dilated, tortuous veins, venules and capillaries in the submucosa. Some of the blood vessels had irregularly thickened walls and significantly dilated lumens (Fig. 1). In the case 4 dilated capillaries were also seen in the mucosa with adjacent mucosal hemorrhages. Orcein stain showed fragmentation and multiplication of elastic fibers in dysplastic vessels (Fig. 2). In comparison with normal vascular endothelium the factor VIII labeling was significantly decreased or even absent in the endothelium of malformed and ectatic vessels.

Discussion

Cases of angiodysplasia account for 6% of digestive tract bleeding [10]. A deficiency of von Willebrand factor might increase the risk of bleeding in patients with coexisting angiodysplasia [12]. Three patients in this study had congenital vWD, and one suffered from acquired vWS. Median age at the diagnosis of angiodysplasia was 63. In the earlier study of Fressinaud et al. [4] the prevalence of angiodysplasia in acquired vWS was 11.7% and the median age was 69, and in congenital vWD angiodysplasia has been found exclusively in type 2 (2%) and in type 3 (4.5%) at a median age of 55. The age of patients with congenital vWD and angiodysplasia at the time of occurrence of bleeding episodes, would support the theory that angiodysplasia is a degenerative aging process, which is present mostly in the population over 50–60 years. The most interesting finding in the cited survey was that bleeding GI angiodysplasia affected only patients lacking high molecular multimers (HMW) of vWF. Contrary to the re-

sults of the study carried out by Fressinaud et al. [4], and in accordance to our observations, Castaman et al. [1] found angiodysplasia also in patients with the full range of multimers (vWD type 1).

Our cases indicate that GI angiodysplasia in patients with von Willebrand disease remains the challenge for both clinicians and pathologists. The cause of hospitalization in all cases presented was severe upper GI bleeding, with very low values of hemoglobin and hematocrit. Despite of the massive transfusions of FVIII/vWF concentrates, cryoprecipitate, fresh frozen plasma and administration of desmopressin, good hemostasis was unattainable. Other treatment modalities, such as estrogens and octreotide were ineffective. Since extensive diagnostic procedures, including endoscopic studies, isotope scanning and capsule did not reveal a site of blood loss, treatment options like electrocoagulation, laser photocoagulation or sclerotherapy could not be used. Taking into account the dramatic history of bleeding with very frequent long-period hospitalizations requiring months of treatment and the poor quality of life, the decision to perform surgical resection has been made in all 4 cases.

Angiodysplasia appeared on endoscopy as cherry red flat or slightly raised vascular lesion of 2–10mm in diameter forming a cluster of submucosal vessels with prominent central vessel [6]. After surgical resection most angiodysplasias are not macroscopically visible, like in our cases, due to blood pressure decrease in venules. For identification of these vascular lesions a mixture of radiopaque material and India ink may be injected and then angiodysplasia appears as a conglomeration of multiple vessels [3]. Since this method had not been used in our patients numerous sections from small intestine were evaluated. The histological diagnosis of angiodysplasia is a problem in GI pathology, because submucosa of the intestinal tract is rich in vessels. The typical lesion contains distorted vessels with dilated lumens: veins, venules, capillaries and sometimes arteries [3]. In our material they appeared mainly in submucosa, in one case also in mucosa. The presence of abnormal ectatic vessels in mucosa indicates progression of the disease. In one of our cases there was evidence of an old as well as recent hemorrhage. The vessels were dysplastic with irregularly thickened walls and fragmentation or multiplication of elastic fibers. The presence of dysplastic vessels distinguishes angiodysplasia from hemangioma. Similarly as Duray [2] we observed a decreased labeling of endothelium by FVIII in the dysplastic vessels. This finding may be related to the cause of bleeding from these vessels (e.g. lost of capacity to synthesize this factor by endothelium).

The management of patients with bleeding angiodysplasia and vWD is difficult, because no single treatment modality has been successful in all cases [13].

Conclusion

Elderly patients with recurrent GI bleeding, melena or unexplained iron deficiency anemia should be diagnosed for angiodysplasia and vWF deficiency.

References

1. *Castaman G, Di Bona E, Rodeghiero F*: Angiodysplasia and von Willebrand Disease. *Thromb Haemost* 1994, 71(4), 527-528.
2. *Duray PH, Marcal JM, LiVolsi VA, Fisher R, Scholhamer Ch, Brand MH*: Gastrointestinal angiodysplasia: a possible component of von Willebrand's disease. *Hum Pathol* 1984, 15(6), 539-544.
3. *Fenoglio-Preiser CM, Pascal RR, Perzin KH*: Tumour of the Intestines. Hartman WH, Sobin LH, eds. Armed Forces Institute of Pathology, Washington DC 1990, 483-486.
4. *Fressinaud E, Meyer D*: International survey of patients with von Willebrand's disease and angiodysplasia. *Thromb Haemost* 1993, 70(3), 546.
5. *Ginsburg D*: Von Willebrand Disease in Williams Hematology. Beutler E et al, eds. Mc Graw-Hill Medical Publishing Division, New York 2001, 1813-1828.
6. *Howard OM, Buchanan JD, Hunt RH*: Angiodysplasia of the colon. Experience of 26 cases. *Lancet* 1982, 3, 16-19.
7. *Moake JL, Turner NA, Stathopoulos NA, Nolasco LH, Hellums JD*: Involvement of large plasma von Willebrand factor (vWF) multimers and unusually large forms derived from endothelial cells in shear stress-induced platelet aggregation. *J Clin Invest* 1986, 78, 1456-1461.
8. *O'Brien JR*: Angiodysplasia, haemostasis and capillaries. A hypothesis. *Thrombosis Research* 1996, 84(5), 385-387.
9. *Ramsay DM, Buist TAS, Macleod DAD, Heading RC*: Persistent gastrointestinal bleeding due to angiodysplasia of the gut in von Willebrand's disease. *Lancet* 1976, 2, 275-278.
10. *Veyradier A, Balian A, Wolf M, Giraud V, Montembault S, Obert B, Dagher I, Chaput JC, Meyer D, Naveau S*: Abnormal von Willebrand factor in bleeding angiodysplasias of the digestive tract. *Gastroenterology* 2001, 120(2), 346-353.
11. *Veyradier A, Jenkins CSP, Fressinaud E, Meyer D*: Acquired von Willebrand syndrome: from pathophysiology to management. *Thromb Haemost* 2000, 84, 175-182.
12. *Warkentin TE, Moore JC, Anand SS, Lonn EM, Morgan DG*: Gastrointestinal bleeding, angiodysplasia, cardiovascular disease, and acquired von Willebrand syndrome. *Transfus Med Rev* 2003, 17(4), 272-286.
13. *Zanon E, Vianello F, Casonato A, Girolami A*: Early transfusion of factor VIII/von Willebrand factor concentrates seems to be effective in the treatment of gastrointestinal bleeding in patients with von Willebrand type III disease. *Haemophilia* 2001, 7(5), 500-503.

Address for correspondence and reprint requests to:

Monika Prochorec-Sobieszek M.D., Ph.D.
 Department of Pathomorphology
 Institute of Hematology and Blood Transfusion
 Chocimska 5, 00-957 Warszawa
 Tel/fax: 4822 8488638