

Scoliosis as cause of pulmonary atelectasis

P.M. ter Wee*, W.J. Luth**, A.C. van der Schee***, J. Stam***

Scoliosis as a cause of pulmonary atelectasis. P.M. ter Wee, W.J. Luth, A.C. van der Schee, J. Stam.

ABSTRACT: We present a patients with persistent position-dependent productive cough and intermittent fever. He was first examined at 38 yrs of age. Chest X-ray showed a severe thoracic lordoscoliosis and an atelectasis of the right lower lobe. Bronchography revealed a total stenosis of the right lower lobe bronchus. Five years later he had increased symptoms. Spirometry showed total lung capacity (TLC) 3.8 l (predicted value 6.7 l), forced vital capacity (FVC) 2.6 l (4.8 l) and forced expiratory volume in one second (FEV₁) 1.7 l (3.9 l). Bronchoscopy demonstrated a smooth stenosis of the right lower lobe bronchus but the stenosis could be passed through with a brush. Computed tomographic scanning demonstrated compression of the right lower lobe bronchus and the atelectasis. After surgical removal of the right lower lobe, all symptoms disappeared. Histological examination of the right lower lobe revealed fibrosis and chronic inflammation.

Eur Respir J., 1991, 4, 371-373.

Depts of Internal Medicine*, Radiology** and Pulmonology***, Free University Hospital, Amsterdam, The Netherlands.

Keywords: Lordoscoliosis; pulmonary atelectasis.

Correspondence: Dr P.M. ter Wee, Dept of Internal Medicine, Free University Hospital, P.O. box 7057, 1007 MB Amsterdam, The Netherlands.

Accepted: January 16, 1990.

Deformities of the chest, and especially thoracic lordoscoliosis, can cause disturbances of pulmonary function. Whether structural damage to the lung can occur is less well known.

We present a patients with a lordoscoliosis of the thoracic spine with persistent position-dependent productive cough and intermittent fever as a result of chronic atelectasis of the right lower lobe.

Case report

The patient, a 38 yr old male, visited our hospital first in 1983 because of persistent cough and intermittent fever. He had no medical history and had never consulted an orthopaedic surgeon. He did not smoke. The patient had always been able to do his work and could play soccer in his free-time without signs of pulmonary

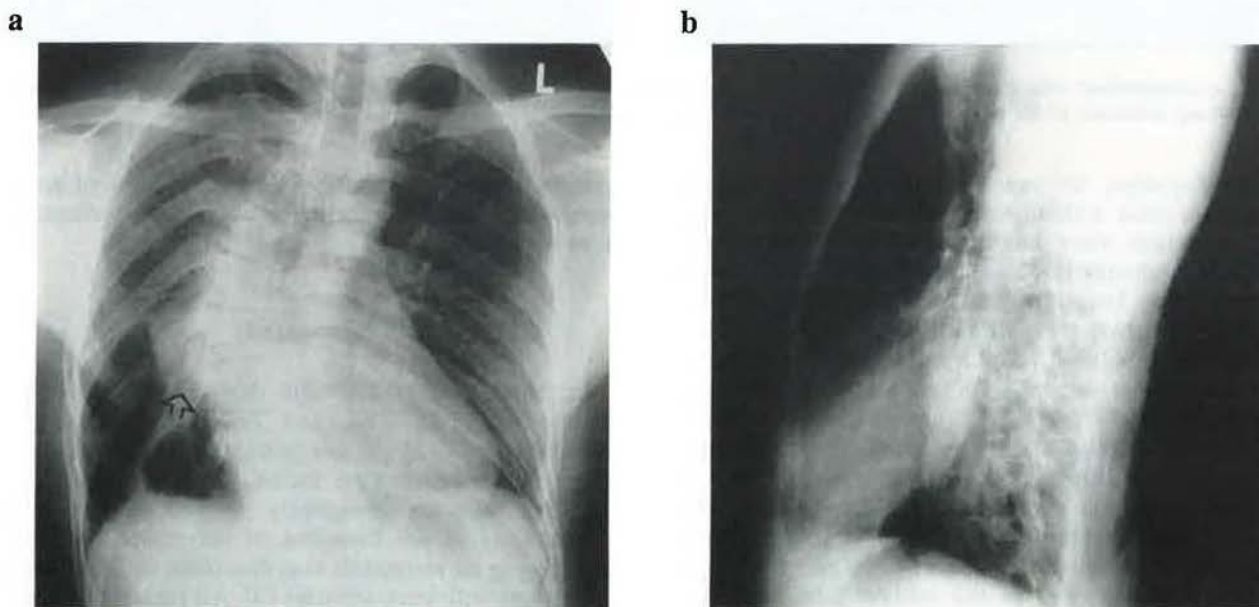


Fig. 1. — Postero-anterior (a) and left lateral (b) chest radiographs. Note the spine deformity (lordoscoliosis) which causes atypical appearance of the right lower lobe atelectasis (arrow).

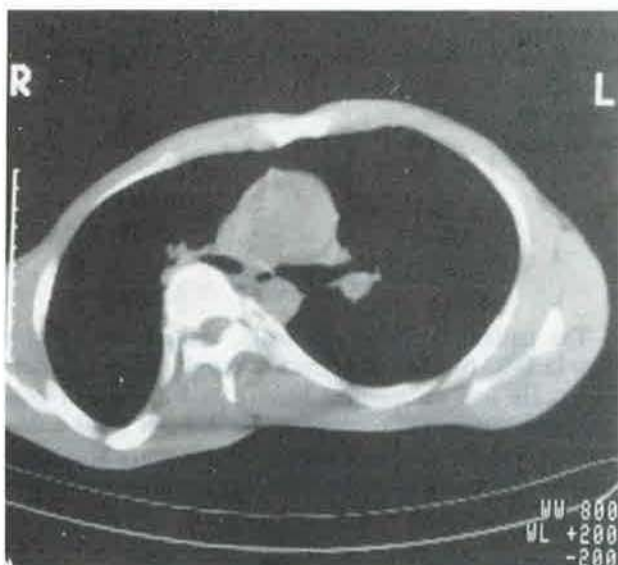
function disturbances. At physical examination a right-sided lordoscoliosis was found but no signs of pulmonary infection or atelectasis. The X-ray of the chest demonstrated the existence of severe lordoscoliosis and an atelectasis of the right lower lobe (fig. 1). Broncho- graphy revealed a total stenosis of the right lower lobe bronchus. By means of arteriography a sequester of the right lung could be excluded. At that time the patient refused further investigation and therapy. Therefore, he was dismissed from the hospital and returned to his pulmonologist for follow-up.

Five years later he returned to out hospital. He had been without symptoms for four years. Afterwards a persistent cough had returned with a position-dependent production of purulent sputum. There had been several episodes with general discomfort and fever which were treated by antibiotics.

with a brush, resulting in the discharge of purulent sputum. No further abnormalities were seen. Computed tomographic scanning of the thorax clearly demonstrated the severity of the lordoscoliosis and of the right lower lobe atelectasis which most likely was due to compression of the bronchus by the spine (fig. 2). Bronchogenic cysts were excluded by means of nuclear magnetic resonance scanning.

Since there had been several bursts of fever and the atelectasis persisted for these years, it was assumed that the right lower lobe was destroyed. A right-sided thoracotomy confirmed the compression of the lower lobe bronchus by the spine, and the corresponding lobectomy was performed. The middle and upper lobe were sound. Histological examination of the right lower lobe revealed fibrosis and signs of chronic inflammation. The patient recovered soon and could be dismissed

a



b

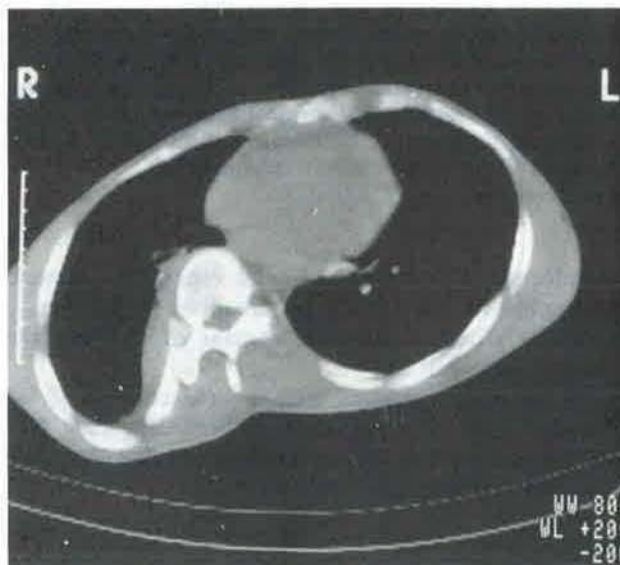


Fig. 2. - Computerized axial tomograph. The close relationship between compressed right lower lobe bronchus and vertebral body (a) and the resulting atelectasis of the right lower lobe (b) are clearly depicted (arrows).

On admission, we saw a healthy looking, slightly dyspnoeic male without fever. Over the lungs, normal breath sounds were heard without rales or ronchi. Besides the already lordoscoliosis no abnormalities were found. Lung function tests showed a restrictively disturbed function with a total lung capacity (TLC) of 3.8 l (normal value 6.7 l), forced vital capacity (FVC) of 2.6 l (normal value 4.8 l), forced expiratory volume in one second (FEV₁) of 1.7 l (normal value 3.9 l). The chest X-ray showed a slightly increased consolidation of the known atelectasis of the right lower lobe but, apart from this, was not changes significantly since 1983. Bronchography showed a cessation in the lower lobe bronchus and an impaired passage of contrast through the bronchus of the middle lobe. At bronchoscopy, a smooth stenosis of the right lower lobe bronchus due to extrapulmonary compression was seen. The stenosis was not fixed and could be passed through

symptom-free. So far, no symptoms or signs of either recurrent pulmonary infection or pulmonary dysfunction have appeared.

Discussion

In patients with idiopathic thoracic lordoscoliosis, decreased TLC, FVC and FEV₁ are commonly encountered [1, 2]. In our patient similar changes in pulmonary function were found. Structural changes of the lung were less frequently pointed out. In 1978, compression of the bronchus of the right lower lobe resulting in an atelectasis was described in four female youngsters with lordoscoliosis [3]. All patients had been treated with a thoracic corset. More recently, an atelectasis of the right middle and lower lobes occurred after orthopaedic surgery using a Harrington

compression rod at the convexity [5]. In our male adult patient, there was atelectasis of the right lower lobe. The compression of the bronchus most likely provokes sputum retention with superimposed infection, resulting in the development of atelectasis [3].

References

1. Winter RB, Lovell WW, Moe JH. - Excessive thoracic lordosis and loss of pulmonary function in patients with idiopathic scoliosis. *J Bone Joint Surg*, 1975, 57-A, 7, 972-977.
2. Holden WE, Carr WA, Beals RK. - Position dependence of pulmonary function in a patients with lordoscoliosis. *Eur J Respir Dis*, 1986, 68, 146-150.
3. Hofner W, Denk G, Kummer F, et al. - Lungenatektasen auf der konvexseite thorakaler Skoliosen. *Z Orthop*, 1987, 116, 640-645.
4. Scuderi G, Sanders DP, Brustowicz RM, et al. - Postoperative lordoscoliosis causing extrinsic compression of the right main stem bronchus and respiratory insufficiency. *Spine*, 1989, 14, 110-114.

Scoliose facteur étiologique d'atélectasie pulmonaire. P.M. ter Wee, W.J. Luth, A.C. van der Schee, J. Stam.

RÉSUMÉ: Les déformations thoraciques, et en particulier la lordoscoliose, peuvent provoquer des anomalies de la fonction pulmonaire. L'on connaît moins les perturbations structurelles du poumon qu'elles peuvent provoquer. Nous présentons un cas de lordoscoliose thoracique se plaignant d'une toux productrice positionnelle persistante et de poussées fébriles en rapport avec une atélectasie chronique du lobe inférieur droit. Tous les symptômes ont disparu après résection de ce lobe.

Eur Respir J., 1991, 4, 371-373.