



ISSN: 0976-3031

Available Online at <http://www.recentscientific.com>

International Journal of Recent Scientific Research  
Vol. 8, Issue, 2, pp. 15631-15633, February, 2017

**International Journal of  
Recent Scientific  
Research**

## Research Article

### CATAMENIAL PNEUMOTHORAX DUE TO PULMONARY ENDOMETRIOSIS

Sajeethkumar K G<sup>\*1.</sup>, Santhosh Narayanan<sup>1</sup> and Gomathy Subramaniam<sup>2</sup>

<sup>1</sup>Department of Medicine, Govt. Medical College, Kozhikode, Kerala, India

<sup>2</sup>Department of Radiodiagnosis, Govt. Medical College, Kozhikode, Kerala, India

#### ARTICLE INFO

##### Article History:

Received 17<sup>th</sup> November, 2016

Received in revised form 21<sup>st</sup>

December, 2016

Accepted 05<sup>th</sup> January, 2017

Published online 28<sup>th</sup> February, 2017

##### Key Words:

Endometriosis, Catamenial pneumothorax,  
VATS

#### ABSTRACT

We report a case of 37 year old multiparous woman who presented to us with right sided chest pain aggravated on inspiration and coughing, associated with breathlessness on exertion. Symptoms started 2 days after the onset of menstruation. Examination revealed features of right sided pneumothorax. Investigations revealed evidence of endometriosis with elevated serum CA 125 levels. Video assisted thoracoscopy showed pleural nodules, histopathology of the same confirming the presence of pulmonary endometriosis. She was started on hormonal suppressive therapy and is asymptomatic on follow up.

**Copyright © Sajeethkumar K G et al, 2017**, this is an open-access article distributed under the terms of the Creative Commons Attribution License, which permits unrestricted use, distribution and reproduction in any medium, provided the original work is properly cited.

#### INTRODUCTION

Thoracic endometriosis syndrome is a rare disorder characterised by the presence of functioning endometrial tissue in pleura, lung parenchyma and airways. Spontaneous recurrent pneumothorax within 72 hours of menstruation is known as catamenial pneumothorax. It is encountered in 3-6% of spontaneous pneumothorax cases among menstruating women. In 90 % of the cases it involves the right side. Etiology of catamenial pneumothorax is unknown, but is most often associated with thoracic endometriosis or diaphragmatic fenestrations.

#### CASE REPORT

A 37 year old woman, with no comorbidities, presented to our emergency department with history of acute onset of right sided chest pain for 6 hours duration. Pain increased on coughing and inspiration. It was associated with breathlessness on exertion. There was no history of orthopnoea, palpitations, syncope, fever. Her symptoms occurred two days after the onset of menstruation. She had history of spontaneous right sided pneumothorax 6 months back at the time of menstruation, and was treated by intercostals tube drainage, but was not investigated further. She had no history of pelvic or abdominal pain in the past. Her menstrual cycles were regular. Obstetric history was uneventful. She was moderately built and nourished with a BMI of 22 kg/m<sup>2</sup>. On clinical examination, her pulse was 88/min, regular in rhythm, normal volume, BP-

120/80 mm Hg, respiratory rate 24 /min with Spo2 94 percent in room air.

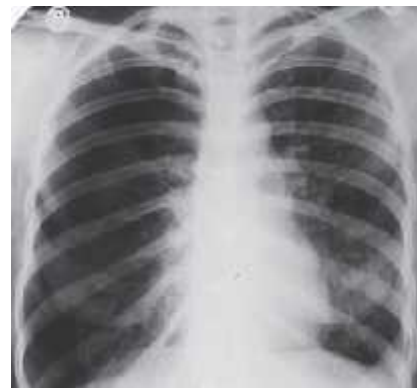

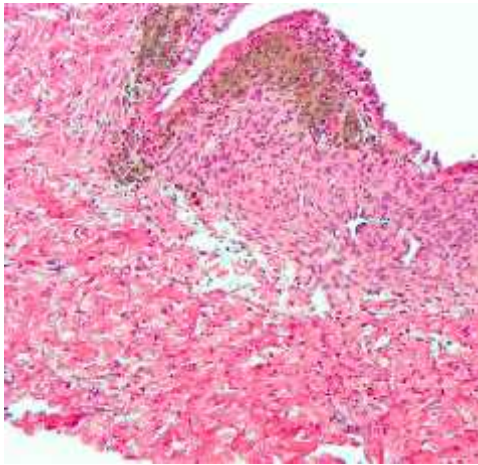
Figure 1 Chest Xray showing right sided pneumothorax

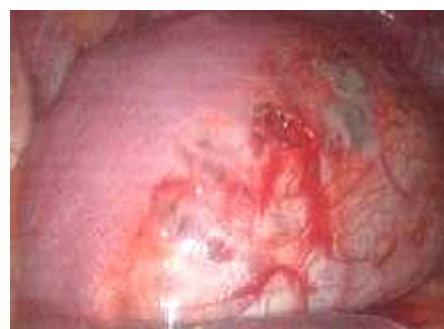

Figure 2 showing diaphragmatic fenestrations

\*Corresponding author: **Sajeethkumar K G**

Department of Medicine, Govt. Medical College, Kozhikode, Kerala, India



**Figure 3** histopathological specimen showing endometriosis

She had no pallor, icterus, clubbing, lymphadenopathy or edema. Examination of respiratory system revealed signs of right sided pneumothorax without evidence of tracheal or mediastinal shift. Other systems were within normal limits. Chest xray (Figure 1) showed right pneumothorax with right lung collapse. Intercostal tube drainage was done and her symptoms subsided. Computed tomography of thorax did not reveal any pleural or parenchymal lesions. Video assisted thoracoscopy (Figure 2) done after 2 weeks, displayed pleural nodules and diaphragmatic blebs. Resection of the nodules, correction of diaphragmatic defects and pleurodesis was done. Histopathological examination of the pleural nodule confirmed the presence of thoracic endometriosis (Figure 3). Ultrasound abdomen did not reveal any pelvic foci of endometriosis. She was started on danazol 400 mg twice a day. She was asymptomatic on follow up and did not report any respiratory symptoms during menstruation.

## DISCUSSION

Endometriosis is the growth of uterine endometrium outside the uterus and was first described by Rokitansky in 1956. Pulmonary endometriosis manifests in the form of catamenial hemoptysis or as catamenial pneumothorax<sup>1</sup>. 3% to 6% of spontaneous pneumothorax occurring in females are due to pulmonary endometriosis. The mean age of onset is 32-35 years. The condition may also occur as late as at 39 years of age. Catamenial pneumothorax is mostly unilateral. In 85-95 percent of cases, it occurs on the right side of the chest. The clockwise peritoneal circulation from the pelvis to the right subphrenic space sweeps endometrial implants to the right diaphragm. The 'piston effect' of the liver then transmits intraperitoneal pressure spikes through pre-existing diaphragmatic defects, forcing air into the pleural space<sup>2</sup>. The pathogenesis of catamenial pneumothorax is explained by the following: physiological theory, coelomic metaplasia, microembolic-metastatic theory, and the diaphragmatic theory of air "passage". In the physiological theory, researchers believe that prostaglandin F<sub>2</sub>, which is elevated during ovulation, causes constriction of the bronchioles. Bronchiolar narrowing may cause the alveolar sacs to rupture resulting in pneumothorax. The theory of coelomic metaplasia maintains that uterine endometrium and pleural mesothelium share the same embryological origin, and undefined pathogenic stimuli may result in the differentiation of pleural-based precursor cells

into endometrial cells. But this does not explain the occurrence of intrapulmonary endometriosis<sup>3</sup>. In the metastatic model, catamenial pneumothorax is caused by the abnormal migration of endometrial tissue from the lining of the uterus to the diaphragm or the pleura. Many studies say that catamenial pneumothorax is associated with single or multiple fenestrations in the tendinous part of the diaphragm. Nodules located on the diaphragmatic or visceral pleura undergo cyclical changes similar to uterine endometrium. These nodules may rupture and result in pneumothorax. Histopathological analysis of these nodules reveal, endometrial stroma, and macrophages filled with hemosiderin<sup>4,5</sup>. Computed tomography can reveal endometrial nodules on the surface of the diaphragm. Although magnetic resonance may facilitate the visualization of endometriotic foci, the routine performance of this examination in the case of pneumothorax is not feasible in many centers.

Video-assisted thoracoscopic surgery (VATS) is the treatment of choice in catamenial pneumothorax<sup>6</sup>. Thoracotomy is indicated if there is recurrence after a previous procedure. Joseph et compared surgical and medical modality of treatment and found that during a follow-up of 1 year, recurrence occurred in 30% of the patients treated with surgery and in 60% of the patients receiving pharmacological treatment. Marshall *et al.* suggested that, in the case of catamenial pneumothorax accompanied by radiologically visualized lesions, extensive surgery is recommended, consisting of diaphragmatic resection, bullectomy, pleurodesis, or pleurectomy<sup>7,8</sup>. In another study Bagan *et al* performed surgical procedures during menstruation in order to avoid overlooking small and hidden lesions in the pleurae and the diaphragm<sup>9</sup>. The aim of performing the procedure during this period is to provide precise visualization of the endometrial lesions and to cover the diaphragm with a polyglactin mesh instead of performing a resection. Postoperatively patients should be put on hormonal therapy with GnRH agonist or danazol for atleast six months<sup>10,11</sup>. There are no recommendations regarding duration of therapy.

## CONCLUSION

Catamenial pneumothorax is a rare entity of spontaneous, recurrent pneumothorax occurring in synchrony with the menstrual cycle. It should be suspected in ovulating women with spontaneous pneumothorax, even in the absence of symptoms associated with pelvic endometriosis. The incidence appears to be far greater than initially thought. Video assisted thoracoscopic surgery which allows visualization and correction of diaphragmatic pathology is the treatment of choice. Hormonal therapy alone is ineffective.

## References

1. Alifano M, Roth T, Broet SC, Schussler O, Magdeleinat P, Regnard JF. Catamenial pneumothorax a prospective study, *Chest*, 2003, vol. 124 (pg. 1004-1008)
2. Alifano M, Trisolini R, Cancellieri A, Regnard JF. Thoracic endometriosis: current knowledge. *Ann Thorac Surg* 2006; 81: 761-769
3. Haga T, Kurihara M, Kataoka H, Ebana H. Clinical-pathological findings of catamenial pneumothorax: comparison between recurrent cases and nonrecurrent cases. *Ann Thorac Cardiovasc Surg* 2014; 20: 202-206.

4. Korom S, Canyurt H, Missbach A. Catamenial pneumothorax revisited: clinical approach and systematic review of the literature. *J Thorac Cardiovasc Surg.* 2004; 128:502–8.
5. Joseph J, Sahn SA. Thoracic endometriosis syndrome: new observations from an analysis of 110 cases, *Am J Med* , 1996, vol. 100 (pg. 164-170)
6. Cowl CT, Dunn WF, Deschamps C. Visualisations of diaphragmatic fenestration associated with catamenial pneumothorax. *Ann Thorac Surg* 1999; 68: 1413-1414.
7. Marshall MB, Ahmed Z, Kucharczuk JC. Catamenial pneumothorax: optimal hormonal and surgical management. *Eur J Cardiothorac Surg.* 2005;27:662–6.
8. Ceccaroni M, Roviglione G, Giampaolino P, Clarizia R, Bruni F, Ruffo G, Patrelli TS, De Placido G, Minelli L. Laparoscopic surgical treatment of diaphragmatic endometriosis: a 7-year single-institution retrospective review. *Surg Endosc* 2013; 27: 625-632
9. Bagan P, Le Pimpec Barthes F, Assouad J, Souilamas R, Riquet M. Catamenial pneumothorax: retrospective study of surgical treatment. *Ann Thorac Surg* 2003; 75: 378-381
10. Maurer ER, Schaal JA, Mendez Jr FL. Chronic recurring spontaneous pneumothorax due to endometriosis of the diaphragm, *J Am Med Assoc* , 1958, vol. 168 (pg. 2013-2014)
11. Cieslik L, Haider SS, Fisal L, Rahman J, Sachithanandan A. Minimally invasive thoracoscopic mesh repair of diaphragmatic fenestrations for catamenial pneumothorax due to likely endometriosis: a case report. *Med J Malaysia* 2013; 68: 366-367.

\*\*\*\*\*

**How to cite this article:**

Sajeethkumar K G *et al.*207, Catamenial Pneumothorax Due To Pulmonary Endometriosis. *Int J Recent Sci Res.* 8(2), pp. 15631-15633.