



Rhinology World 2009

PROGRAM

APRIL 15-19, 2009

Sheraton Philadelphia City Center Hotel
Four Seasons Hotel
Philadelphia, Pennsylvania USA

- XIII International Rhinologic Society
- XXVIII International Symposium on Infection and Allergy of the Nose
- 2009 Spring Meeting of the American Rhinologic Society
- Basic Course of the American Academy of Otolaryngic Allergy

Co-Hosted By:



Department of Otorhinolaryngology: Head and Neck Surgery



The meeting organizers are proud
to present these Platinum Sponsors:



Acclarent, Inc.

Acclarent is dedicated to the development of innovative devices providing new technologies to further meet the needs of ENT surgeons and their patients.

Acclarent started in 2005 with an initial focus on achieving the goals of sinus surgery with novel, endoscopic, catheter-based tools—*Balloon Sinuplasty*™ devices. This portfolio has evolved to include Relieva Solo Pro™, a 4th generation sinus balloon catheter, Relieva Luma™, a sinus illumination system and Relieva Sidekick™, a sinus guide catheter handle. Together these devices create the Relieva® Direct Visualization System. Acclarent's most recent innovation is the Relieva Stratus™ MicroFlow Spacer which has been cleared for ethmoid and frontal sinus placement.



Phytoneering—Research of Plant-based Medicines

Bionorica and its "Phytoneering" approach stand for deciphering the active principle in botanicals (PHYTO) using innovative technologies (engiNEERING) to produce highly effective plant-based medicines for the benefit of human health. The process begins with the cultivation and selection of the appropriate plants and includes defined and thoroughly controlled steps throughout the whole manufacturing process up to the final pharmaceutical product. That includes harvesting and drying of the plants, an optimized extraction process, galenics up to appropriate packing of the pharmaceuticals. Moreover, it also comprises comprehensive preclinical and clinical research and development.



About the ENT Business at Medtronic

Located in Jacksonville, Florida, the ENT business at Medtronic develops and manufactures products designed to treat ear, nose and throat (ENT) diseases. As the market leader in ENT, Medtronic is changing the way ENT surgery is performed with innovative, minimally invasive products and techniques that benefit both patients and surgeons. Main products include powered tissue-removal systems and other microendoscopy instruments, nerve monitoring systems, disposable fluid control products, image-guided surgery systems and a Ménière's disease therapy device. Learn more about the ENT business on the web at www.MedtronicENT.com

The meeting organizers graciously
acknowledge these Gold Sponsors:

- ArthroCare ENT
- GE Healthcare
- Gyrus ACMI
- Karl Storz Endoscopy-America
- Xoran Technologies

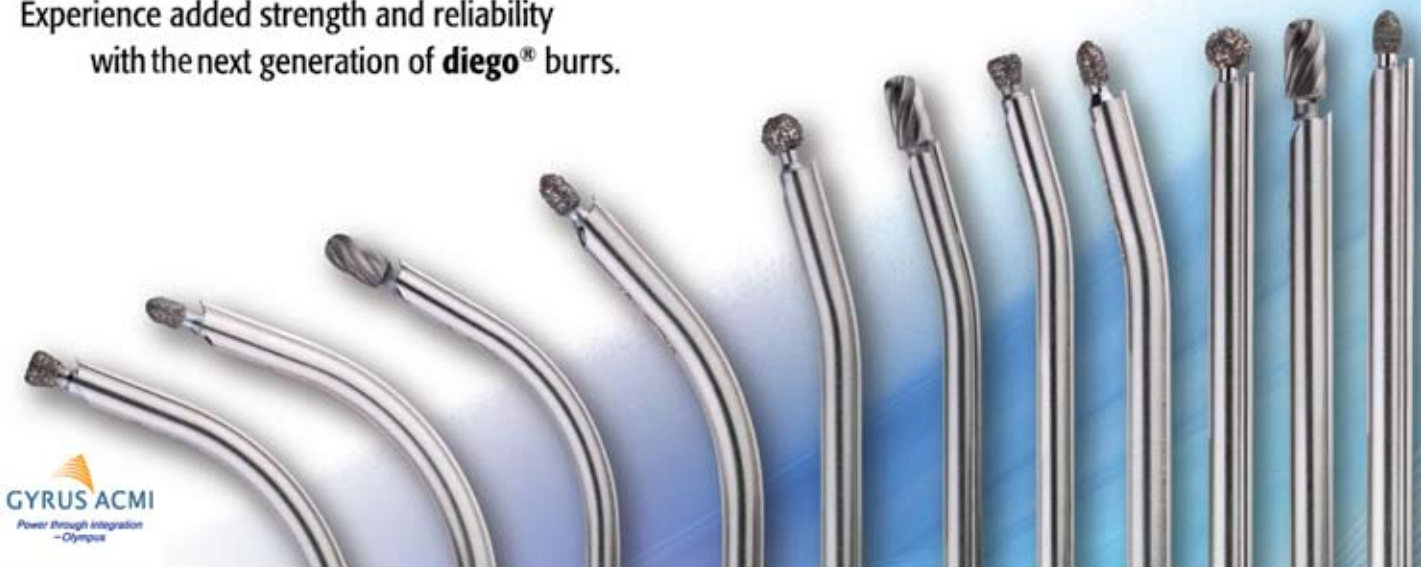OLYMPUS

Your Vision, Our Future

Advanced Design. Enhanced Durability.

Experience added strength and reliability
with the next generation of **diego**[®] burrs.

diego[®]
SYSTEM



GYRUS ACMI
Power through integration
-Olympus

PLEASE VISIT US AT OUR RHINOLOGY WORLD BOOTH # 101-103

The meeting organizers salute these Silver Sponsors:

- BrainLab
- Entellus Medical
- Entrigue Surgical
- Meda Pharmaceuticals
- Stryker Instruments

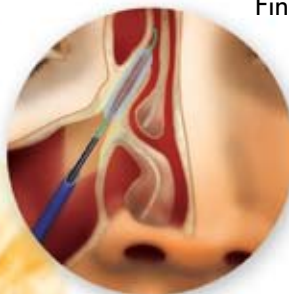Instant Relief That Lasts

FinESS™
Sinus Treatment

Break the CRS cycle. Give your patients immediate and lasting relief with FinESS™ Sinus Treatment.

FinESS™ Sinus Treatment breaks the cycle of chronic sinusitis (CRS) that affects so many patients. A less invasive procedure, FinESS™ maximizes tissue and bone preservation while optimizing patient outcomes. The relief is immediate. The results are long lasting.

Call 1-866-620-7615 or visit entellusmedical.com



Indications For Use: To access and treat the maxillary sinus ostium and the ethmoid infundibulum in adults with a trans-antral approach. The bony sinus outflow tract is remodeled by balloon displacement of adjacent bone and paranasal sinus structures. Please see Instructions for Use for a complete listing on contraindications, warnings and precautions.

 **entellus**
MEDICAL®

Booth 611/613

Welcome Messages	5
Faculty Delegates	8
Program “At-A-Glance”	10
Program	13
Thursday	13
Friday	18
Saturday	23
Sunday	28
ACCME	28
Hotel Floor Plan	29
Society Board and Committee Meetings	30
Rhinology Bowl	30
Social Program	31
The Best of Philadelphia	31
Oral Abstracts	32
Poster Abstracts	86
Video Abstracts	114
Exhibitors	119
Exhibit Hall Floor Plan	120



David W. Kennedy, M.D., FACS, FRCSI
President, International Rhinologic Society
President, American Academy of
Otolaryngology-Head and Neck Surgery



Welcome

It gives me great pleasure to welcome you to the XIII meeting of the International Rhinologic Society; it promises to be one of the most exciting meetings within the field of rhinology. Because we combined this meeting with ISIAN, ARS and AAOA, you will have an outstanding opportunity to get an exceptionally broad exposure to all aspects of contemporary rhinology and rhinologic research. We have assembled a program that provides significant depth, as well as a broad understanding of the more recent advances within the specialty. However, an important aspect of a meeting of this type is to allow debate, face to face discussion, and interactions with the leading international faculty both in the meeting rooms and also in less formal settings. This is a significant advantage of a meeting such as this. It provides the opportunity to talk to people, probe issues and develop relationships which may last for years. Please take this opportunity to avail yourself of the privilege of open interaction and informal discussion with the faculty during the meeting, if you do not do this you will not be truly making the most of what a meeting such as this provides; a benefit unavailable with internet conferences. The resident Rhinology Bowl competition, held in the Horizons Ballroom at the top of the hotel, will allow

you an opportunity to test your own knowledge of the field with the residents, and promises to be a lot of fun. Please take some time to sit in on some of these sessions. We are also very lucky to be able to provide a limited number of places with hands on dissection with image guidance, fresh specimens and outstanding instructors.

However, I hope that you will also find time to enjoy both the social events that we provide within the meeting and the historic City of Philadelphia. The Welcome Reception and the Gala Dinner will provide the opportunity for exposure to the city and to some of the history of this nation. The Gala Dinner will be emceed by TV personality and otolaryngologist Nancy Snyderman and will feature Patti LaBelle's Philadelphia Choir and other entertainment, in the outstanding setting of the Constitution Center. In addition, I hope that you will take the time to visit Independence Hall, see the Liberty Bell, tour the Art Museum, Rodin Museum and the Barnes Collection, as well as visit some of the superb restaurants which this city has attracted.

Welcome to Philadelphia, Rhinology World and the XIII meeting of the International Rhinologic Society.

David W. Kennedy
President, IRS



James N. Palmer, M.D.
President-Elect, ISIAN



Welcome

As President-Elect of the International Symposium on Infection and Allergy of the Nose, I am excited to welcome you to Rhinology World 2009. The ISIAN is a yearly meeting that historically has rotated between Europe in conjunction with the European Rhinologic Society, and other continents, biennially. The ISIAN emphasizes the very best of basic science and clinical findings in Rhinology, and is pleased to participate in this gathering. Special program highlights include great debates, mini-seminars,

and over 200 oral presentations of cutting edge research in Rhinology. Our ISIAN members wish you a fruitful meeting and hope to see you in Geneva, Switzerland for the next joint ERS-ISIAN meeting in 2010.

James N. Palmer
President-Elect, ISIAN



James A. Stankiewicz, M.D.,
President, ARS

Welcome

On behalf of the American Rhinologic Society, I am very happy to invite all those interested in Rhinologic disease to the largest gathering of Rhinologists in the world- Rhinology World 2009. Not since 2000 when the Mayo Clinic sponsored Nose 2000 have 4 senior rhinology societies come together to promote and educate all attending this great meeting in the many facets of Rhinology. The ARS, AAOA, ISIAN, and IRS program directors have worked very closely to organize the many facets of this meeting and we hope it nicely serves all of your interests. Special thanks are due to Drs. David Kennedy and James Palmer who are hosting Rhinology World 2009. The Ameri-

can Rhinologic Society has been committed to diagnosing and treating nasal and sinus disorders for over 50 years. The society goals include teaching, research and socioeconomic support for its membership. Our meetings include participation from the world of Rhinology and the ARS has been honored to have many of you participate in our Fall and Spring meeting programs. We in the ARS wish all of you a very successful meeting and an enjoyable visit to Philadelphia.




Richard C. Haydon, III, MD
President, AAOA

Welcome

On behalf of the American Academy of Otolaryngic Allergy, it is exciting to welcome all attendees to this comprehensive gathering of Rhinologists. The AAOA is pleased to present the Basic Course of the American Academy of Otolaryngic Allergy as a part of Rhinology World 2009. This Basic Course will count towards the CME credits needed for those applying for the AAOA Fellow membership status, and will serve to refresh and improve the allergy practitioner towards new concepts in rhinologic allergy treatment. There are also

several allergy sessions as part of the global program, and we are excited to also offer a significant Resident education component to Rhinology World 2009. Thank you for attending this wonderful meeting, and we look forward to seeing you at future AAOA events!





Alexander G. Chiu, M.D.
General Secretariat–Clinical Sciences

Welcome

The Clinical paper sessions and debates in Rhinology World 2009 have been designed to allow all participants to improve their clinical skill set from basic to advanced techniques, ranging from cosmetic rhinoplasty all the way to skull base surgery. I invite you to peruse the schedule and improve any and all areas of your personal surgical techniques. We have also put together an extensive surgical skills laboratory, highlighted by the very latest in modern surgical equipment, donated by our very generous sponsors. I hope you enjoy Rhinology World 2009!

General Secretariat–Clinical Sciences



Noam A. Cohen, M.D., Ph.D.
General Secretariat–Basic Science

Welcome,

I am excited to welcome you to the world’s largest congress of rhinologic knowledge - the Basic Science in Rhinology portion of the program highlights all aspects of scientific Rhinology. Large portions of the submitted abstracts present new findings in microbiology, cell and molecular biology, physiology, genetics and proteomics with respect to rhinologic disease. A special plenary session entitled “Contemporary Overview and Pathogenesis of CRS” will serve to kick off discussion of new advances and put them in an historical context. I wish all of you the best in this opportunity to distill new findings in rhinology into patient care advances!

General Secretariat–Basic Science



Faculty Delegates



AUSTRALIA

Christopher Brown
Simon Carney
Richard Gallagher
Richard Harvey
Larry Kalish
Alkis Psaltis
Ray Sacks



AUSTRIA

Heinz Stammberger



BELGIUM

Claus Bachert
Peter Hellings



BRAZIL

Wilma Anselmo-Lima
Alexandre Felippu
Monica Menon-Miyake
Tania Sih
Aldo Stamm
Fabiana Valera



CANADA

Martin Desrosiers
Amin Javier
John Lee
Brad Mechor



CHINA

De-Min Han
Yuan Li
Geng Xu
Luo Zhang



COLUMBIA

Roxana Cobo
Alfredo Herrera
Fernando Pedroza



CROATIA

Ranko Mladina



DENMARK

Christian Buchwald
Niels Hoiby



EGYPT

Ossama Hamid
Reda Kamel



FINLAND

Markus Rautiainen
Risto Renkonen
Sanna Toppila-Salmi
Elina Toskala



FRANCE

Jean-Michel Klossek
Elie Serrano



GERMANY

Jan Gosepath
Werner Hosemann



GREAT BRITIAN

David Gatland
Nick Jones
Valerie Lund
Ian Mackay
Salil Nair



GREECE

Anthony Papavassiliou
Kazanas Savvas



INDIA

Ramesh Deka



IRAN

Alireza Mesbahi
Mohsen Naraghi



ISRAEL

Itzhak Braverman
Ephraim Eviatar



ITALY

Luisa Bellussi
Mario Bussi
Paolo Castelnovo
Piero Nicolai
Ernesto Pasquini
Desiderio Passali
Ignazio Tasca
Matteo Trimarchi



JAPAN

Shinichi Haruna
Shoji Matsune
Hiroshi Moriyama
Nobuyoshi Otori
Ruby Pawankar



KOREA

Joong Saeng Cho
Andy Dhong
Tae-Young Jang
Yong Ju Jang
Yang-Gi Min



MALAYSIA

Balwant Gendeh
N. Prepageran



MEXICO

Carlos Yañez



NETHERLANDS

Fenna Ebbens
Wytske Fokkens
Gilbert Trenite
Cornelis van Drunen



NEW ZEALAND

Richard Douglas



PHILIPPINES

Gil Vicente



POLAND

Eiliza Brozek-Madry
Norbert Gorski
Iwona Gromek
Antoni Krzeski



PORTUGAL

Antonio Sousa Vieira



RUSSIA

Vladimir Kozlov
Andrei Lopatin
Marina Nersesyanyan



SINGAPORE

De Yun Wang



SPAIN

Josep Fabra



SWEDEN

Anders Cervin
Anders Ehnhage
Mats Holmstrom
Pontus Stiern



SWITZERLAND

Jean-Silvain Lacroix
Daniel Simmen



TURKEY

Fazil Apaydin
Cemal Cingi
Kemal Değer
Nesil Keleş
Metin Önerci
Levent Soyulu
Semih Sutay
Halis Unlu



VENEZUELA

Aderito DeSousa
Enrique Iturriaga



UNITED STATES

Soo Kim Abboud
 Vijay Anand
 Fuad Baroody
 Devraj Basu
 Pete Batra
 Daniel Becker
 Samuel Becker
 Neil Bhattacharyya
 Douglas Bigelow
 Jurij Bilyk
 Benjamin Bleier
 Seth Brown
 Anne Marie Cahill
 Ricardo Carrau
 Roy Casiano
 Peter Catalano
 Ara Chalian
 Michael Chandler
 Rakesh Chandra
 Alexander Chiu
 Martin Citardi
 Noam Cohen
 David Conley
 Minas Constantinides
 Jacqueline Corey
 Beverly Cowart
 Jeffrey Cutler
 Subinoy Das
 John DelGaudio
 Jennifer Derebery
 Jason Diaz
 H. Peter Doble
 Richard Doty
 Brian Dunham
 Jay Dutton
 Samer Fakhri
 Berrylin J. Ferguson
 Karen Fong
 Jack Fornadley
 Marvin Fried
 Oren Friedman
 Roberta Gausas
 Andrew Goldberg
 Stephen Goldstein
 Suman Golla
 Satish Govindaraj
 Parul Goyal
 Scott Graham
 Stacey Gray
 Joseph Han
 Richard Haydon
 Edward Hepworth
 Eric Holbrook
 Steven Houser
 Peter Hwang
 Masaru Ishii
 Alexis Jackman
 Joseph Jacobs
 Ivo Janecka



Stephanie Joe
 Leland Johnson
 Jordan Josephson
 Ashutosh Kacker
 Ken Kazahaya
 James Kearney
 David Kennedy
 Eugene Kern
 Robert Kern
 Todd Kingdom
 Still Kountakis
 Jack Krouse
 Fred Kuhn
 Mary Lally
 Andrew Lane
 Donald Lanza
 Kevin Leahy
 Richard Lebowitz
 Jeff Leid
 Donald Leopold
 Howard Levine
 Daqing Li
 Sandra Lin
 Scott Litin
 Todd Loehrl
 Laurie Loevner
 Amber Luong
 Rodney Lusk
 Patricia Maeso
 Kelly Malloy
 Jeffrey Mandel
 Bradley Marple
 Kevin McMains
 Ralph Metson
 Robert Meyers
 Philip Miller
 J. Whitman Mims
 Natasha Mirza
 Andrew Murr
 Robert Naclerio
 Jayakar Nayak
 Jason Newman
 Gurston Nyquist
 Bert O'Malley
 Richard Orlandi
 J. David Osguthorpe
 John Pallanch
 James Palmer
 Ira Papel
 Sanjay Parikh
 Michael Parker
 Alpen Patel
 Steven Pletcher
 Kim Pollock
 Jens Ponikau
 Edmond Pribitkin
 Hassan Ramadan
 Vijay Rao
 William Reisacher
 Marc Rosen



Douglas Ross
 Matthew Ryan
 Steven Schaefer
 Robert Schleimer
 Rodney Schlosser
 Theodore Schwartz
 Brent Senior
 Reuben Setliff
 Gavin Setzen
 Michael Setzen
 Michael Siegel
 Michael Sillers
 Ameet Singh
 Timothy Smith
 James Stankiewicz
 Jacob Steiger
 Abtin Tabae
 Mas Takashima
 Thomas Tami
 M. Eugene Tardy
 Erica Thaler
 Paul Toffel
 Lawrence Tom
 Winston Vaughan
 Eugenia Vining
 Gregory Weinstein
 Erik Weitzel
 Kevin Welch
 Ralph Wetmore
 Sarah Wise
 Bradford Woodworth
 Bozena Wrobel
 Kathleen Yaremchuk
 Mark Zacharek
 Adam Zanation
 S. James Zinreich

Thursday April 16, 2009

7:00-8:00	CONTINENTAL BREAKFAST & EXHIBITS Freedom/Independence Ballroom										
8:00-8:45	PLENARY SESSION: Contemporary Overview of CRS Liberty Ballroom AB										
8:50-10:00	ROUND TABLE: Pathogenesis of CRS Liberty Ballroom AB										
10:00-10:30	BREAK	GREAT DEBATE: Sinuplasty vs. MIST vs. FESS vs. Nasalization Liberty Ballroom AB									
10:30-11:25	MINI SEMINAR Benign Tumors Liberty Ballroom D									ARS MEETING PAPERS Liberty Ballroom C	AAOA BASIC COURSE Philadelphia Ballroom N & S
11:35-12:30										MINI SEMINAR: Experience is the Best Teacher: The Rhinoplasty Student Never Graduates Liberty Ballroom AB	
12:30-1:30	LUNCH SYMPOSIUM: Treatment of Respiratory Diseases with Phytopharmaceuticals Liberty Ballroom AB (Boxed Lunches Available)					Exhibits Freedom/Independence Ballroom (Boxed Lunches Available)					
1:30-2:25	DEMO-DISSECTION Liberty Ballroom AB Complete Sphenothmoidectomy SPA Ligation	MINI SEMINAR Frontiers in Computer Aided Surgery Liberty Ballroom C	IRS/ISIAN FREE PAPERS Salon 1 Salon 3/4 Salon 5/6 Salon 9 Salon 10	MINI SEMINAR Evidence Based Medicine in Rhinology Liberty Ballroom D	INSTRUCTIONAL COURSE Endoscopic Orbital Surgery Logans 2	MINI SEMINAR Relevance of Allergy for Rhinologists Logans 1	AAOA BASIC COURSE Philadelphia Ballroom N & S	RHINOLOGY BOWL Horizons Ballroom 1:30-5:00	INSTRUCTIONAL COURSE Hands-on Lab Dissection UPENN School of Medicine, Stemmler Hall Rm 212 1:30-5:00		
2:35-3:30	Extended Frontal	MINI SEMINAR (ARS) Frontal Sinus- State of the Art (Southern States Rhinology Course) Liberty Ballroom C		MINI SEMINAR The Marriage of Function & Aesthetics in Rhinoplasty Liberty Ballroom D	MINI SEMINAR Evidence Based Medicine for Immunotherapy Logans 1	MINI SEMINAR Mucosal Innate Immunity & CRS Logans 2					
3:30-4:00	BREAK										
4:00-5:00	MINI SEMINARS Reflux Disease in the Upper Airway Logans 2 Computer Modeling in Rhinology Logans 1 Management Strategies for Chronic Rhinitis Salon 1 Management of Failed Frontal Sinus Obliteration Seminar C Objective Evaluation of Nasal Function Seminar B Management of Advanced Sinonasal Malignancy Salon 3/4			INSTRUCTIONAL COURSES Advanced Imaging Techniques Salon 10 Tips for Minimizing Complications in FESS Salon 5/6 Management of Rhinosinusitis in Pediatric Population Salon 9 The Nasal Dorsum Liberty Ballroom D Management & Effects of Cocaine Abuse Seminar A Ethnic Rhinoplasty Liberty Ballroom C							
6:30-8:30	WELCOME RECEPTION Liberty Ballroom AB										

All Posters will be on display throughout the meeting in Liberty Foyer.

Friday April 17, 2009

7:00-8:00	CONTINENTAL BREAKFAST & EXHIBITS Freedom/Independence Ballroom										
8:00-8:45	PLENARY SESSION: Evolution of Endoscopic Sinus Surgery Liberty Ballroom AB										
8:50-10:00	ROUND TABLE: Surgical Techniques Liberty Ballroom AB										
10:00-10:30	BREAK										
10:30-11:25	MINI SEMINAR: Endoscopic Sinus Surgery Liberty Ballroom C		GREAT DEBATE: Open vs. Endoscopic Approaches for Malignancy Liberty Ballroom D			ARS MEETING PAPERS Liberty Ballroom AB		AAOA BASIC COURSE Philadelphia Ballroom N & S			
11:35-12:30	MINI SEMINAR: Nasal Valve/Functional Rhinoplasty Liberty Ballroom C		GREAT DEBATE: Genetics vs. Environment Liberty Ballroom D								
12:30-1:30	LUNCH SYMPOSIUM: Evidence-based Medicine: the Foundation Behind Balloon Sinuplasty™ Technologies Liberty Ballroom AB (Boxed Lunches Available)							Exhibits Freedom/Independence Ballroom (Boxed Lunches Available)			
1:30-2:25	DEMO-DISSECTION: Plastics Liberty Ballroom AB	MINI SEMINAR Comprehensive Management of Non-Invasive Fungal Rhinosinusitis Logans 2	AAOA PAPERS Salon 1	IRS/ISIAN PAPERS Salon 3/4 Salon 5/6 Salon 9 Salon 10	MINI SEMINAR Mucosal Biofilms Liberty Ballroom D	INSTRUCTIONAL COURSE Granulomatous Diseases of Rhinology (USC Rhinology Course) Logans 1	MINI SEMINAR Mucociliary Clearance Cilia Function Liberty Ballroom C	AAOA BASIC COURSE Philadelphia Ballroom N & S	RHINOLOGY BOWL Horizons Ballroom 1:30–5:30	INSTRUCTIONAL COURSE Hands-on Lab Dissection UPENN School of Medicine, Stemmler Hall Rm 212 1:30–5:30	Patient Safety Horizons Ballroom 2:00–3:00
2:35-3:30	Skull Base Surgery–The Assisted, Bimanual “4-Hand” Technique	MINI SEMINAR Chronic Sinusitis-A Complex Disease: Coalescence of Surgical, Medical and Laboratory Information (Einstein/NYU Rhinology Course) Logans 2			MINI SEMINAR Pediatric Chronic Rhinosinusitis Logans 1	INSTRUCTIONAL COURSE CT and MRI Interpretation Liberty Ballroom D					
3:30-4:00	BREAK										
4:00-5:30	MINI SEMINARS Sinuplasty Indications Salon 3/4 Alternative and Complimentary Therapies Seminar A Rhinoplasty–Personal Philosophy Liberty Ballroom C Implants in Rhinology: Stents and Packing Liberty Ballroom D Towards System Level Analysis of Allergic Nasal Epithelium Salon 5/6 Combined Approaches to the Orbit Salon 1 Obstructive Sleep Apnea Salon 9					INSTRUCTIONAL COURSES Evolving Indications for FESS Seminar D Endoscopic Sinus Surgery: Problems and Solutions (Turkish Rhinologic Society) Salon 10 Topical Therapies Logans 2 Advances in the Management of Facial Pain and Empty Nose Syndrome Seminar B (4:00–5:00) Anesthetic Considerations in Endoscopic Sinus Surgery Seminar B (5:00 – 5:30) Aspirin-Exacerbated Respiratory Disease Seminar C Pediatric JNA Logans 1					
6:45-10:45	GALA BANQUET National Constitution Center										

All Posters will be on display throughout the meeting in Liberty Foyer.

Saturday April 18, 2009

7:00-8:00	CONTINENTAL BREAKFAST & EXHIBITS Freedom/Independence Ballroom										
8:00-8:45	PLENARY SESSION: <i>Beyond the Paranasal Sinuses</i> Liberty Ballroom AB										
8:50-10:00	ROUND TABLE: <i>Surgical Techniques</i> Liberty Ballroom AB										
10:00-10:30	BREAK										
10:30-11:25	MINI SEMINAR Unified Airway Liberty Ballroom C	GREAT DEBATE: Fungus vs. Bacteria Liberty Ballroom D	ARS MEETING PAPERS Liberty Ballroom AB			VIDEO PAPER PRESENTATIONS Salon 5/6			AAOA BASIC COURSE Philadelphia Ballroom N & S		
11:35-12:30	MINI SEMINAR Skull Base Reconstruction Liberty Ballroom C	GREAT DEBATE: SCIT vs. SLIT Liberty Ballroom D									
12:30-1:30	LUNCHTIME SYMPOSIUM: The Role of Coblation® Technology in Sinus Surgery Liberty Ballroom AB (Boxed Lunches Available)						Exhibits Freedom/Independence Ballroom (Boxed Lunches Available)				
1:30-2:25	DEMO-DISSECTION Liberty Ballroom AB Transpterygoid/Infratemporal Fossa	MINI SEMINAR Sinus Surgery: Management of Complications Liberty Ballroom D	MINI SEMINAR Nasal Polyposis Logans 2	MINI SEMINAR Point of Service Imaging Salon 10	MINI SEMINAR (ARS) Endoscopic Skull Base Surgery Liberty Ballroom C 1:30-3:00	MINI SEMINAR Frontal Sinus Fx Logans 1	IRS/ISIAN PAPERS Salon 3/4 Salon 5/6 Salon 9	INSTRUCTIONAL COURSE Pediatric Rhinoplasty Salon 1	AAOA BASIC COURSE Philadelphia Ballroom N & S	RHINOLOGY BOWL Horizons Ballroom 1:30-5:30 Presentation Skills for Physicians: Making Your Next Talk Go Better Than Your Last Horizons Ballroom 2:30-3:15	INSTRUCTIONAL COURSE Hands-on Lab Dissection UPENN School of Medicine, Stemmler Hall Rm 212 1:30-5:00
2:35-3:30	Narrow Band Imaging in the Head and Neck Region Clival Resection and Posterior Fossa Anatomy	MINI SEMINAR Microbes in CRS Liberty Ballroom D	MINI SEMINAR Lasers in Rhinology Logans 1	INSTRUCTIONAL COURSE Predictable Tip Techniques Liberty Ballroom C 3:00-4:00	MINI SEMINAR HHT/Epistaxis Salon 1	INSTRUCTIONAL COURSE Revision Rhinoplasty Salon 10					
3:30-4:00	BREAK										
4:00-5:30	MINI SEMINARS Management of Turbinates and Septum Salon 3/4 DCR/Orbit Salon 1 Olfaction Salon 5/6 Guidelines in Rhinosinusitis: The Questions They Answer and Do Not Answer Seminar A Endoscopic Surgery of Skull Base (Cornell Rhinology Course) Salon 10 Wound Healing and FESS Salon 9 Management of Eustachian Tube Dysfunction Seminar B			INSTRUCTIONAL COURSES Robotic Skull Base Surgery Liberty Ballroom D Perioperative Medical Management Seminar D Correct Coding For Better Reimbursement in Rhinology Logans 2 Rhinoplasty-Technique I Cannot Live Without Liberty Ballroom C SLIT Seminar C GERD Logans 1							

Sunday April 19, 2009

7:00-8:00	CONTINENTAL BREAKFAST & EXHIBITS Freedom/Independence Ballroom										
8:00-8:45	PLENARY SESSION: <i>Allergy</i> Liberty Ballroom AB										
8:50-10:00	ROUND TABLE: <i>Techniques for an Allergy Practice</i> Liberty Ballroom AB										
10:00-10:30	BREAK										
10:30-12:00	MINI SEMINAR: Complications/Reducing Complications/Strategies in Revision Rhinoplasty Liberty Ballroom D			"MY MOST FASCINATING CASE" Liberty Ballroom AB				ARS MEETING PAPERS Expert's "How I Do It" Liberty Ballroom C 10:30-12:20			
	RHINOLOGY BOWL CHAMPIONSHIP Liberty AB										
	CLOSING CEREMONY Liberty AB										

All Posters will be on display throughout the meeting in Liberty Foyer.

Program • Thursday, April 16, 2009

- 7:00–8:00am **Continental Breakfast & Exhibits**
Freedom/Independence Ballroom
- 8:00–8:45am **PLENARY SESSION: Contemporary Overview of CRS**
Liberty Ballroom AB
Chair: David Kennedy, Keynote Speaker: Valerie Lund
- 8:50–10:00am **ROUND TABLE: Pathogenesis of CRS**
Liberty Ballroom AB
Chair: David Kennedy, Moderator: Valerie Lund
The Superantigen Story: Claus Bachert
Ciliary Dysfunction: Noam Cohen
The Role of Biofilms: James Palmer
The Role of Osteitis: David Kennedy
Allergic Fungal Sinusitis—Misnomer or Reality?: Heinz Stammberger
- 10:00–10:30am **BREAK: Refreshments in Exhibit Hall**
Freedom/Independence Ballroom
- 10:00–11:25am **GREAT DEBATE:**
Sinuplasty vs. MIST vs. FESS vs. Nasalization
Liberty Ballroom AB
Chair: Wytke Fokkens, Moderator: Alexander Chiu
Nasalization: Jean-Michel Klossek
FESS: Bradley Marple
MIST: Reuben Setliff
Hybrid: FESS/Balloon: Michael Setzen
Balloon Dilatation: Frederick Kuhn
- 10:30–12:30pm **MINI SEMINAR: Benign Tumors**
Liberty Ballroom D
Chair: Hiroshi Moriyami, Moderator: David Kennedy
Transnasal Endoscopic Medial Maxillectomy in Inverted Papilloma: Reda Kamel
Endonasal Approach for the Inverted Papilloma in the Maxillary Sinus Via Fontanelle and Inferior Meatus: Hiroshi Moriyami
Endoscopic Resection of JNA: Metin Önerci
Endoscopic Resection of JNA: De-Min Han
Endoscopic Resection of Meningiomas: Ricardo Carrau
Endoscopic TSA for the Management of Pituitary Adenoma: Hun-Jung Dhong
- 10:30–12:30pm **ARS MEETING PAPERS**
Liberty Ballroom C
Moderators: Neil Bhattacharyya, Andrew Lane
- 10:30am **Abstract #1640—Decreased Expression Of Connexin (Cx)26 and 43 In Allergic Nasal Epithelium:** Huabin Li
- 10:36am **Abstract #1628—Alterations In Complement Pathway Gene and Protein Expression In Chronic Rhinosinusitis:** Rodney Schlosser
- 10:42am **Abstract #1685—SPLUNC1 Expression of Nasal Polyp Epithelial Cells in Air-Liquid Interface Culture Treated with IL-13:** Te-Huei Yeh
- 10:48am **Discussion**
Moderators: Joseph Jacobs, Brent Senior
- 11:00am **Abstract #1647—The Effect of Topical Intranasal Budesonide Saline Irrigations on Serum and Urinary Cortisol Levels in Patients with Recurrent Polyposis Following Endoscopic Sinus Surgery:** Kevin Welch
- 11:06am **Abstract #1782—Development of a Chinchilla Model to Allow Direct, Continuous Imaging of Fluorescent Nontypeable Haemophilus Influenzae during Experimental Chronic Rhinosinusitis:** Subinoy Das
- 11:12am **Abstract #1569—The Comparative Disease Burden of Rhinosinusitis:** Neil Bhattacharyya
- 11:18am **Discussion**
Moderator: Stilianos Kountakis
- 11:30am **Expert's How I Do It: Endoscopic Trans-Sphenoidal Hypophysectomy:** Marvin Fried
- 11:40am **Discussion**
Moderators: Bradley Marple, Marvin Fried
- 11:45am **Abstract #1556—Chronic Fungal Sinusitis: Fungal Colonization of Paranasal Sinuses, Evaluation of ICAM-1 and IL-8 and Studying of Immunological Effect of Long-Term Low-Dose Macrolide Therapy:** Shawky Elmorsy
- 11:51am **Abstract #1642—Cigarette Smoke Extract Stimulates Interleukin-8 Production In Human Sinus Epithelium Via Reactive Oxygen Species:** Rodney Schlosser
- 11:57am **Abstract #1761—Secondhand Tobacco Smoke Exposure and Chronic Rhinosinusitis—A Case-Control Study:** Douglas Reh
- 12:03pm **Discussion**
Moderator: Rodney Schlosser
- 12:15pm **Expert's How I Do It: Endoscopic DCR:** Todd Kingdom
- 12:25pm **Discussion**
- 12:30–12:40pm **ARS BUSINESS MEETING**
Liberty Ballroom C
- 11:35–12:30pm **MINI SEMINAR: Experience is the Best Teacher: The Rhinoplasty Student Never Graduates**
Liberty Ballroom AB
Chair: Roxana Cobo, Moderator: M. Eugene Tardy, Jr.
Confusion, Then Clarity, at the Internal Nasal Valve: Minas Constantinides
The Lipsitt Technique Deprojects But Does Not Necessarily Counter-Rotate the Nasal Tip: Daniel Becker
Medial Osteotomies: When to Use or Abuse in Rhinoplasty: Ira Papel
Managing the Acute Nasolabial Angle: A Technique That Survives Gravity and Gives Additional Support: Roxana Cobo
Profile Planning: An Advance or a Waste of Time: Ian Mackay
Discussion
- 12:30–1:30pm **LUNCH: Boxed Lunches available in Lunchtime Symposium (Liberty Ballroom AB) and Exhibit Hall (Freedom/Independence Ballroom)**
- 12:30–1:30pm **LUNCHTIME SYMPOSIUM: Treatment of Respiratory Diseases with Phytopharmaceuticals**
Liberty Ballroom AB
Phytoneering—Research of Plant-based Medicines: From the Seed, to Cultivation, to clinical Efficacy: Michael A. Popp
Preclinical Development and Animal Trials in Herbal Treatment: Pontus Stierna
Clinical Experience of Treating Upper and Lower Airway Diseases with Phytopharmaceuticals: Narinder Duggal

- 1:30–5:00pm **RHINOLOGY BOWL**
Horizons Ballroom
- 1:30–5:00pm **INSTRUCTIONAL COURSE: Hands-on Lab Dissection**
UPENN School of Medicine, Stemmler Hall Rm 212
(Pre-registration required; buses leave the Sheraton at 1:00pm)
Soo Kim Abboud, Samuel Becker, Andrew Goldberg,
Alexis Jackman, James Kearney, David Kennedy,
Steven Pletcher, Michael Siegel, Heinz Stammberger,
Jacob Steiger, Erica Thaler, Sarah Wise, Bradford Woodworth
- 1:30–2:25pm **DEMONSTRATION DISSECTION:**
Complete Spenoethmoidectomy SPA Ligation
Liberty Ballroom AB
Heinz Stammberger
Discussants: Donald Lanza, Metin Onerci
- 1:30–2:25pm **MINI SEMINAR: Frontiers in Computer Aided Surgery**
Liberty Ballroom C
Chair: Stilianos Kountakis, Moderator: Marvin Fried
CAS: Which System for Me?: Thomas Tami
Intraoperative Imaging in Rhinologic Surgery: Martin Citardi
CAS and Simulation: Marvin Fried
- 1:30–2:25pm **MINI SEMINAR: Evidence Based Medicine in Rhinology**
Liberty Ballroom D
Chair: Yang-Gi Min, Moderator: Timothy Smith
Introduction to Evidence Based Medicine and Evidence
Based Sinus Surgery: Timothy Smith
Evidence Based Medical Therapy for Rhinosinusitis:
Wytske Fokkens
Fungal Rhinosinusitis? What is the Evidence?: Fenna Ebbens
The Evidence for Image Guidance in Rhinology:
Richard Orlandi
Questions to Panel
- 1:30–2:25pm **INSTRUCTIONAL COURSE: Endoscopic Orbital Surgery**
Logans 2
Chair: Reda Kamel, Moderator: Ranko Mladina
Endoscopic Endonasal Orbital Decompression: Valerie Lund
Novel Technical Aspects of the Endonasal
Endoscopic Orbital Decompression: Ranko Mladina
Endonasal Endoscopic Orbital Compression: N. Prepageran
Transnasal Endoscopic Surgery of the Sino-Orbital Lesions:
Reda Kamel
- 1:30–2:25pm **MINI SEMINAR: Relevance of Allergy for Rhinologists**
Logans 1
Chair: Richard Haydon, Moderator: Joseph Han
Prevalence of Allergy in Rhinology Practice: Joseph Han
Impact of Allergic Rhinitis on Sinusitis: Pete Batra
Asthma in Rhinology Practice?: Mark Zacharek
Management of Allergic Rhinitis: Alpen Patel
- 1:30–3:30pm **IRS/ISIAN PAPER SESSIONS**
Salon 1
Moderators: Rakesh Chandra, Kasper Aanaes
- 1:30pm **Abstract #1563—Prophylactic IV Antibiotics in FESS:
Trends and Attitudes of the ARS Membership:** Rakesh Chandra
- 1:38pm **Abstract #1583—Hemodynamic Effects of Topical Adrenaline
in Nasal Surgery:** Suja Sreedharan
- 1:46pm **Abstract #1611—Comparison of Laryngeal Mask With
Endotracheal Tube:** Ahmed Atef
- 2:00pm **Abstract #1653—Sinus Irrigation Bottles:
A Potential Source of Infection?:** Eun Hae Estelle Chang
- 2:08pm **Abstract #1727—Antibiotic Prophylaxis in Sinus Surgery: A
Review of Current Practices:** Anita Sethna
- 2:16pm **Abstract #1893—Coblation Assisted Endoscopic Sinus Surgery:**
Maurice Roth
- 2:30pm **Abstract #1894—New Focus-Old Disease: The Paranasal
Sinuses a Focus for Bacterial Lung Infections in Patients
with Cystic Fibrosis (CF):** Kasper Aanaes
- 2:38pm **Abstract #1745—Polysomnographic Evaluation of the Effect
of Propofol on Sleep for Both Healthy and OSAHS Patients:
Preliminary Results:** Fabiana Valera
- 2:46pm **Abstract #1892—Comparison of Prick, Intradermal Testing,
and Invitro Testing in Predicting Response to Nasal
Provocation with Ragweed Antigen:** Camysha Wright
- 3:00pm **Abstract #1898—Safety and Efficacy of Citric Acid/
Zwitterionic Surfactant (Novus) Cleansing Solution in a
Rabbit Model of Sinusitis:** Noam Cohen
- 1:30–3:30pm **IRS/ISIAN PAPER SESSIONS**
Salon 3/4
Moderators: Joao Nogueira, Vijay Ramakrishnan
- 1:30pm **Abstract #1601—Manuka Honey: The New Treatment for
Recalcitrant Chronic Sinus Disease:** Andrew Thamboo
- 1:38pm **Abstract #1612—Biofilms and Mucosal Healing in Postsurgical
Patients with Chronic Rhinosinusitis:** Zi Zhang
- 1:46pm **Abstract #1880—Biofilm-Forming Capability in Pseudomonas
Aeruginosa Increases Upregulation of the Pro-Inflammatory
Cytokine CXCL1/KC in Murine Nasal Epithelium:** Nicholas Smith
- 2:00pm **Abstract #1565—Guide-wire Augmented Endoscopic Frontal
Sinusotomy:** Hamed Sajjadi
- 2:08pm **Abstract #1619—Mucocoele & Osteoma of Frontal Sinus: The
Clinic & Histopathologic Analysis of Coexistence:** Mustafa Gerek
- 2:16pm **Abstract #1585—Construction and Effectiveness of
Endoscopic Sino-Nasal Surgery Model:** Joao Nogueira
- 2:38pm **Abstract #1623—Can CT Score Predict Success in Pediatric
Endoscopic Sinus Surgery?:** Hassan Arshad
- 2:46pm **Abstract #1665—Different endoscopic Surgergical Strategies
in the Treatment of Juvenile Nasopharygeal Angiofibroma—
Shanghai EENT 'Hospital' Experience:** DeHui Wang
- 3:00pm **Abstract #1732—A Role for Observation in the Treatment of
Isolated Diseases of the Pediatric Sphenoid Sinus and Clivus:**
Vijay Ramakrishnan
- 3:08pm **Abstract #1824—Septoplasty in Children by Endonasal
Approach: Results at Long-Term Follow-Up:** Ignazio Tasca
- 1:30–3:30pm **IRS/ISIAN PAPER SESSIONS**
Salon 5/6
Moderators: Marc Rosen, Mohsen Naraghi
- 1:30pm **Abstract #1788—Airway Management and Perioperative
Concerns Surrounding Endoscopic Surgery for Pituitary
Tumors in Acromegaly Patients:** Douglas Johnston
- 1:38pm **Abstract #1792—Technical Modifications of the Pedicled
Nasoseptal Flap for Endonasal Skull Base Reconstruction:**
Amol Bhatki
- 1:46pm **Abstract #1794—Lumbar Drain Utilization in Endoscopic
Skull Base Surgery:** Ameet Singh

- 2:00pm Abstract #1800—Endoscopic Repair of Expanded Endonasal Skull Base Defects Using a Stable Bilayer “Button” Closure: Marc Rosen
- 2:08pm Abstract #1805—Endoscopic Transsphenoidal Approach to Craniopharyngiomas: Adam Luginbuhl
- 2:16pm Abstract #1808—Limitations of the Pedicled Nasoseptal Flap for Endoscopic Reconstruction of Transsellar Skull Base Defects in Pediatric Patients: Rupali Shah
- 2:30pm Abstract #1673—Bone Removal during Transphenoidal Hypophysectomy Using an Ultrasonic Aspirator: Justin Antisdell
- 2:38pm Abstract #1720—Orbital Mass Lesions: Implications & Limitations of Endonasal Endoscopic Approach: Mohsen Naraghi
- 2:46pm Abstract #1760—Endoscopic Transmaxillary Approach to the Pterygopalatine Space: Hwa Jung Son
- 3:00pm Abstract #1819—Comparison of External Rhinoplasty Versus Endoscopic Approach to Transsphenoidal Sellar Mass Resection: Naveen Bhandarkar
- 3:08pm Abstract #1828—Endoscopic Modified Endonasal Denker Operation for Management of Tumor in Pterygopalatine and Infratemporal Fossae: DeHui Wang
- 3:16pm Abstract #1829—Endoscopic Removal of a Silent Middle Turbinate Angiofibroma: Ping-Hung Shen
- 1:30–3:30pm **IRS/ISIAN PAPER SESSIONS**
Salon 9
Moderators: Richard Harvey, Chester Griffiths
- 1:30pm Abstract #1728—Orbital Infection Associated with Sinusitis in the Adult Population: Mohannad Al-Qudah
- 1:38pm Abstract #1827—Endoscopic Dacryocystorhinostomy With Mucosal Flap vs Silicone Stent Necessary?: DeHui Wang
- 1:46pm Abstract #1840—Transnasal Endoscopic Image-Guided Orbital Apex Surgery: Chester Griffiths
- 2:00pm Abstract #1849—Sinonasal Orbital Lesions and Their Management: Hossam Elbasraty
- 2:08pm Abstract #1870—Orbital Complications of Rhinosinusitis: Ibrahim Sayin
- 2:16pm Abstract #1700—Sphenopalatine Artery Pseudoaneurysm After FESS: A Literature Review and Case Report: Raewyn Campbell
- 2:30pm Abstract #1777—Radiologic Evaluation of Anterior Ethmoid Artery Anatomy in the Non-Diseased Frontal Recess: Gamwell Rogers
- 2:38pm Abstract #1630—A Prospective Study Identifying Variations in Paranasal Sinus Anatomy and Complication Rates in Endoscopic Sinus Surgery: Kevin Welch
- 2:46pm Abstract #1709—Weighted Magnetic Resonance Imaging of Para-nasal Diseases: Adam French
- 3:00pm Abstract #1607—Computed Tomography Findings in Sinonasal Wegener’s Granulomatosis: Pete Batra
- 3:08pm Abstract #1866—Incidence of Middle Turbinate Pneumatization, Concha Bullosa, in Twisted Nose: Shahriar Nazari
- 3:16pm Abstract #1888—Endoscopic Removal of a Silent Middle Turbinate Angiofibroma: Erica Ortiz
- 1:30–3:30pm **IRS/ISIAN PAPER SESSIONS**
Salon 10
Moderators: Samer Fakhri, Ignazio Tasca
- 1:30pm Abstract #1572—Mastoid Bone as a New Graft Material in Rhinoplasty: Mahmoud Sadoughi
- 1:38pm Abstract #1683—Pulp Necrosis and Septorhinoplasty: Mehdi Bakhshaei
- 1:46pm Abstract #1697—Mastoid Bone as a New Graft Material in Rhinoplasty: Mahmoud Sadoughi
- 2:00pm Abstract #1822—Lateral Crus Pull-Up for the Collapse of External Nasal Valve: Rhinomanometric and Rhinometric Study: Ignazio Tasca
- 2:08pm Abstract #1823—Nasal Dorsum Cosmetic Contour by Cartilaginous Sandwich Graft Technique: Ignazio Tasca
- 2:16pm Abstract #1835—The Effect Of Postauricular Fascial Flap In Otoplasty: Yaser Khalil
- 2:30pm Abstract #1571—Changed Nasal Cavity and Paranasal Sinus Airflow Velocity and Distribution After Total Sinusotomy: A Computational Fluid Dynamics Study: Xu Geng
- 2:38pm Abstract #1580—Paranasal Sinus Disease and Airway Inflammation in Prednisone-Dependent Asthma: Bosco Lui
- 2:46pm Abstract #1678—Morphological Variation of Nasal Cavity Effect on Nasal Patency—CFD Simulation with a Turbulent Model: Wang De Yun
- 3:00pm Abstract #1682—The Validity of Peak Nasal Inspiratory Flow: Kornkiat Snidvongs
- 3:08pm Abstract #1696—Relationship Between Olfactory Acuity and Peak Expiratory Flow During Postoperative Follow-Up In Chronic Rhinosinusitis Associated With Asthma: Katsuhisa Ikeda
- 3:16pm Abstract #1878—Sensation of Nasal Patency Through Mucosal Heat Loss Rather Than Air Temperature: Kai Zhao
- 2:35–3:30pm **DEMONSTRATION DISSECTION: Extended Frontal**
Liberty Ballroom AB
David Kennedy
Discussants: Donald Lanza, Metin Onceri
- 2:35–4:00pm **MINI SEMINAR (ARS): Frontal Sinus—State of the Art (Southern States Rhinology Course)**
Liberty Ballroom C
Moderator: Stilianos Kountakis
Introduction and Basic Anatomy: Stilianos Kountakis
Endoscopic Frontal Sinusotomy Draft I-III: Michael Sillers
Above and Below: External Techniques: John DelGaudio
CSF Leaks: Rodney Schlosser
Tumors: Brent Senior
- 2:35–3:30pm **MINI SEMINAR:**
The Marriage of Function & Aesthetics in Rhinoplasty
Liberty Ballroom D
Chair: Ian Mackay, Moderator: Ira Papel
Introduction of Topic: Ian Mackay
Alar Strut Graft Applications: Minas Constantinides
Osteotomies in the Crooked Nose: Stephen Goldstein
I-Beam Intercrural Strut Grafts: Daniel Simmen
Anatomic Guidelines for Spreader Graft Applications: M. Eugene Tardy
The Alar/Rim Graft Combo Graft for Form/Function: Ira Papel
Questions/Discussion

Program • Thursday, April 16, 2009

- 2:35–3:30pm **MINI SEMINAR:**
Evidence Based Medicine for Immunotherapy
Logans 1
Chair: Richard Haydon, Moderator: Bradley Marple
How Does Immunotherapy Work?: Luisa Bellussi
Immunotherapy Indication and Duration?: Steven Houser
Immunotherapy Outcome?: Matthew Ryan
Novel Immunomodulation for Allergy: Jack Krouse
- 2:35–3:30pm **MINI SEMINAR: Mucosal Innate Immunity and CRS**
Logans 2
Chair: Claus Bachert, Moderator: Andrew Lane
Introductory Remarks: Claus Bachert
Overview of Sinonasal Innate Immunity: David Conley
Innate Immune Dysregulation in CRS with Nasal Polyps: Andrew Lane
Innate Immunity and Barrier Dysfunction in CRS Pathogenesis: Robert Schleimer
Questions
Closing Remarks: Therapeutic Implications: Claus Bachert
- 3:30–4:00pm **BREAK: Refreshments & Exhibits**
Freedom/Independence Ballroom
- 4:00–5:00pm **MINI SEMINAR: Reflux Disease in the Upper Airway**
Live Nasoendoscopy (Olympus)
Logans 2
Chair: Michael Setzen, Moderator: John DelGaudio
Introduction: Michael Setzen
Support of a Connection: John DelGaudio
Lack of Support for a Connection: Bradley Marple
Closing Remarks: Michael Setzen
- 4:00–5:00pm **MINI SEMINAR: Computer Modeling in Rhinology**
Logans 1
Chair: Marvin Fried, Moderator: Martin Citardi
Quantitative Endoscopy in Sinus and Endoscopic Skull Base Surgery: Masaru Ishii
The Pattern and Physical Characteristics of Airflow in Healthy and Pathological Conditions—A Computational Fluid Dynamics Model: De Yun Wang
- 4:00–5:00pm **MINI SEMINAR: Management Strategies for Chronic Rhinitis**
Salon 1
Chair: Vladimir Kozlov Moderator: Jordon Josephson
Chronic Rhinitis: Evaluation and Initial Management: Eugenia Vining
Topical Therapy for Chronic Rhinitis: Fabiana Valera
When Might FESS Be Recommended in CRS?: Christian Buchwald
- 4:00–5:00pm **MINI SEMINAR:**
Management of Failed Frontal Sinus Obliteration
Seminar C
Chair: Peter Hwang, Moderator: Winston Vaughn
Introduction of Speakers: Peter Hwang
Reasons for Frontal Sinus Surgery Failure/Anatomy: Brad Mechor
Endoscopic Options: Winston Vaughn
External and Combined Options: Amin Javier
Audience Questions and Closing Remarks: Peter Hwang
- 4:00–5:00pm **MINI SEMINAR: Objective Evaluation of Nasal Function**
Seminar B
Chair: Richard Doty, Moderator: John Pallanch
Introduction Remarks
Role of the Nasal Airway in Sleep Disorders as Assessed by Acoustic Rhinometry: Jacqueline Corey
Questions
Common Methods of Measuring Olfactory Function: Richard Doty
Questions
Evaluation of Ciliary Function: Stacey Gray
Questions
Objective Evaluation of Nasal Breathing Function with Rhinomanometry: John Pallanch
Questions
Wrap-up
- 4:00–5:00pm **MINI SEMINAR:**
Management of Advanced Sinonasal Malignancy
Salon 3/4
Chair: Gregory Weinstein, Moderator: Jason Newman
Introduction: Gregory Weinstein
Management of Non-SCCa Malignancies: Devraj Basu
Multimodality Therapy for Advanced Cranial Base Tumors: Jason Newman
Robotic Cranial Base Surgery: Gregory Weinstein
Peri-Operative and Post-Operative Conditions in Advanced Sinonasal Tumors: Kelly Malloy
Questions/Comments
Closing Comments: Gregory Weinstein
- 4:00–5:00pm **INSTRUCTIONAL COURSE:**
Advanced Imaging Techniques
Salon 10
Moderator: Vijay Rao
Planning Surgery: Understanding Imaging of the Paranasal Sinuses: Salil Nair
Imaging Pearls in Special Cases: S. James Zinreich
Advanced Imaging in Revision FESS: S. James Zinreich
Panel Discussion
- 4:00–5:00pm **INSTRUCTIONAL COURSE:**
Tips for Minimizing Complications in FESS
Salon 5/6
Moderator: Wilma Anselmo-Lima
FESS: There Are Rules About How to Avoid Complications: Ranko Mladina
How to Reduce Bleeding in Ethmoidectomy for Nasal Polyposis: Elie Serrano

FESS: Changes in Air Flow of the Nasal Cavity & Sinuses
after FESS: Geng Xu
Frontal Sinus Surgery: Which Procedure to Choose?:
James Palmer

4:00–5:00pm **INSTRUCTIONAL COURSE: Management of Rhinosinusitis in Pediatric Population**
Salon 9
Moderator: Lawrence Tom
Changes and Trends in Management: Ken Kazahaya
My Approach: Ralph Wetmore
Case Presentations*: Ken Kazahaya, Ralph Wetmore, Lawrence Tom
**The Audience is Encouraged to Bring Case Presentations for Discussion.*

4:00–5:00pm **INSTRUCTIONAL COURSE: The Nasal Dorsum**
Liberty Ballroom D
Moderator: Oren Friedman
Correction of Saddle Nose Deformities: Edmund Pribitkin
Final Touch of Excellence: Daniel Simmen
Managing Complications Related to the Augmented Dorsum:
Philip Miller
The Radix Area as Part of a Balanced Rhinoplasty:
David Gatland
The Management of the Broad Dorsum: Nick Jones

4:00–5:00pm **INSTRUCTIONAL COURSE: Management & Effects of Cocaine Abuse**
Seminar A
Moderator: Matteo Trimarchi
Introduction: Mario Bussi
Diagnosis: Matteo Trimarchi and Mario Bussi
Apoptosis: Matteo Trimarchi
Nasal Septal Repair: Fernando Pedroza
Conclusions: Mario Bussi
Discussion with Participants

4:00–5:00pm **INSTRUCTIONAL COURSE: Ethnic Rhinoplasty**
Liberty Ballroom C
Moderator: Ira Papel
Introduction to Ethnic Rhinoplasty Considerations: Ira Papel
Mestizo/South American Rhinoplasty: Roxana Cobo
Middle Eastern Rhinoplasty: Alireza Mesbahi
Alar Base in Ethnic Rhinoplasty: Minas Constantinides
Asian Rhinoplasty: Yong Ju Jang
Summary/Questions: Ira Papel

6:30–8:30pm **WELCOME RECEPTION**
Liberty Ballroom AB



Program • Friday, April 17, 2009

- 7:00–8:00am **CONTINENTAL BREAKFAST & EXHIBITS**
Freedom/Independence Ballroom
- 8:00–8:45am **PLENARY SESSION: Evolution of Endoscopic Sinus Surgery**
Liberty Ballroom AB
Chair: James Palmer
Keynote Speaker: Heinz Stammberger
- 8:50–10:00am **ROUND TABLE: Surgical Techniques**
Liberty Ballroom AB
Chair: James Palmer, Moderator: Heinz Stammberger
Balloon Sinuplasty: Howard Levine
Aggressive Approaches to Sinus Disease: Wytske Fokkens
Extended Frontal Approaches: Alexander Chiu
Changes in Surgical Concepts: David Kennedy
Powered Instrumentation: James Palmer
Changes in Our Approach to the Frontal: Heinz Stammberger
- 10:00–10:30am **BREAK: Refreshments in Exhibit Hall**
Freedom/Independence Ballroom
- 10:30–11:25am **MINI SEMINAR: Endoscopic Sinus Surgery**
Liberty Ballroom C
Chair: James Palmer, Moderator: Hiroshi Moriyama
Frontal Sinus Surgery—Key Points and Pitfalls: Nobuyoshi Otori
ESS for Blowout Fracture: Shoji Matsune
Revision Sinus Surgery and Postoperative Treatment: Shinichi Haruna
- 10:30–11:25am **GREAT DEBATE:**
Open vs. Endoscopic Approaches for Malignancy
Liberty Ballroom D
Moderator: Bert O'Malley
Contextuality in Skull Base Surgery: Ivo P. Janecka
Endoscopic Options for Management of Sinonasal Malignancies: Piero Nicolai
- 10:30–11:25am **ARS MEETING PAPERS**
Liberty Ballroom AB
Moderators: Peter Hwang, Chris McMains
- 10:30am Abstract #1785—Treatment-Recalcitrant Chronic Rhinosinusitis With Polyps Is Associated With Altered Epithelial Cell Expression Of Interleukin-33: Andrew Lane
- 10:36am Abstract #1731—Controlled Steroid Delivery via Bioabsorbable Stent: Safety and Performance in a Rabbit Model: Peter Li
- 10:42am Abstract #1639—The Use of Bioresorbable Staples for Mucoperichondrial Flap Coaptation in Septoplasty: Thomas Tami
- 10:48am Discussion
Moderators: Todd Kingdom, Martin Citardi
- 11:00am Abstract #1558—Treatment Of Recalcitrant Chronic Rhinosinusitis With Long-Term, Low-Dose Macrolide Antibiotics: Anders Cervin
- 11:06am Abstract #1815—Title: Current Practice in the Use of Systemic Steroids in CRS: Amy Anstead
- 11:12am Abstract #1816—Title: Antimicrobial Lipid Composition of Sinus Secretions In Patients With And Without Chronic Rhinosinusitis: Jivianne Lee
- 11:18am Discussion
Moderator: Michael Setzen
- 11:30am Expert's How I Do It: Inverted Papilloma Removal: David Kennedy
- 11:40am Discussion
Moderators: Timothy Smith, Kathleen Yaremchuk
- 11:45am Abstract #1693—Traumatic Optic Neuropathy: Role of Bone Marrow Mononuclear Stem Cell Implant?: Ashok Gupta
- 11:51am Abstract #1554—Allergic Fungal Sinusitis (AFS): Detection of Fungal DNA in Sinus Aspirate Using PCR: Shawky Elmorsy
- 11:57am Abstract #1652—Wound Healing Model of Nasal Mucosa in a Rat: Roza Khalmuratova
- 12:03pm Discussion
Moderator: Richard Orlandi
- 12:15pm Expert's How I Do It: Anterior Skull Base Defects: Stilianos Kountakis
- 12:25pm Discussion
- 11:35–12:30am **MINI SEMINAR: Nasal Valve/Functional Rhinoplasty**
Liberty Ballroom C
Chair: Minas Constantinides, Moderator: Paul Toffel
Introductions: Minas Constantinides, Paul Toffel
Preferred Techniques for Nasal Valve Collapse: Oren Friedman
Managing the Caudal Septum: Jacob Steiger
The Butterfly Graft for Nasal Valve Collapse: Philip Miller
Spreader Grafts to Correct Nasal Valve Dysfunction: Roxana Cobo
Structural Grafting of the Nasal Valves, Form with Function: Stephen Goldstein
Open Discussion with Audience
- 11:35–12:30pm **GREAT DEBATE: Genetics vs. Environment**
Liberty Ballroom D
Moderator: Donald Lanza
Introduction: Donald Lanza
Genetics: Martin Desrosiers
Environment: Wytske Fokkens
Rebuttal: Martin Desrosiers
Rebuttal: Wytske Fokkens
Conclusions: Donald Lanza
Tally Vote by a Show of Hands
- 12:30–1:30pm **LUNCH: Boxed Lunches available in Lunchtime Symposium (Liberty Ballroom AB) and Exhibit Hall (Freedom/Independence Ballroom)**
- 12:30–1:30pm **LUNCHTIME SYMPOSIUM: Evidence-based Medicine: The Foundation Behind Balloon Sinuplasty™ Technologies**
How do new technologies, clinical data and applied science stimulate a new era in ESS?
Liberty Ballroom AB
Panelists: Ford Albritton, Peter Catalano, David Conley, Spence Payne, James Stankiewicz
- 1:30–5:00pm **RHINOLOGY BOWL**
Horizons Ballroom
- 1:30–5:00pm **INSTRUCTIONAL COURSE: Hands-on Lab Dissection**
UPENN School of Medicine, Stemmler Hall Rm 212
(Pre-registration required; buses leave the Sheraton at 1:00pm)
Devraj Basu, Samuel Becker, Seth Brown, David Conley, Samer Fakhri, Nick Jones, Jason Newman, Rodney Schlosser, Daniel Simmen, Abtin Tabae, Lawrence Tom, Erik Weitzel, Kathleen Yaremchuk

1:30–2:25pm **MINI SEMINAR: Comprehensive Management of Non-Invasive Fungal Rhinosinusitis**
 Logans 2
 Chair: Ossama Hamid, Moderator: Simon Carney
 Introduction: Ossama Hamid
 Diagnosis and Classification: Jean-Michel Klossek
 Clinical Management: Ramesh Deka
 Adjuvant Therapies & Experimental Techniques: Simon Carney

1:30–2:25pm **DEMONSTRATION DISSECTION: Plastics**
 Liberty Ballroom AB
 M. Eugene Tardy
 Discussants: Daniel Becker, Ian Mackay

1:30–2:25pm **MINI SEMINAR: Mucosal Biofilms**
 Liberty Ballroom D
 Chair: Martin Desrosiers, Moderator: James Palmer
 What are Biofilms and Why are they Important?: Niels Hoiby
 Sinonasal Biofilms and Pseudomonas: Christian Buchwald
 Microbiology and Immunology of Biofilms: Jeff Leid
 Biofilm Communities in the Sinuses: Kevin (Chris) McMains
 The Electronic Nose and Biofilms: Erica Thaler
 Biofilms and the Sinuses—the Adelaide Experience:
 Alkis Psaltis
 Questions: Martin Desrosiers

1:30–2:25pm **INSTRUCTIONAL COURSE: Granulomatous Diseases of Rhinology (USC Rhinology Course)**
 Logans 1
 Chair: Jean-Silvain Lacroix, Moderator: Bozena Wrobel
 Granulomatous Disease & Sinus Disease: General
 Introduction, Classification, Opening Remarks:
 Bozena Wrobel
 Sarcoidosis and Sinus Disease/Lethal Midline
 Cholesterol Granulomas: Valerie Lund
 Wegener’s Granulomatosis and Sinus Disease: Pete Batra
 Cocaine Abuse and Granulomatous Disease:
 Matteo Trimarchi
 Churg-Strauss Syndrome, Eosinophilic Granuloma,
 Cholesterol Granulomas, Rhinoscleroma: Alexis Jackman
 Closing Thoughts: Jean-Silvain Lacroix

1:30–3:30pm **MINI SEMINAR: Mucociliary Clearance & Cilia Function**
 Liberty Ballroom C
 Chair: Markus Rautiainen, Moderator: Noam Cohen
 Welcome and Overview: Markus Rautiainen
 Introduction: Noam Cohen
 Physiology
 Mucociliary Clearance Physiology, 2009 Update:
 Bradford Woodworth
 Role of Calcium in the Regulation of Airway CBF: Luo Zhang
 Pathophysiology of Cilia in CRS
 CBF in Normal, CRS & Polyp Nasal Tissue: Itzhak Braverman
 Cilia Dynamic Dysfunction in CRS: Noam Cohen
 Quantification
 In Vivo Ciliary Beat Frequency-Capture & Analysis:
 H. Peter Doble
 Surgery
 Effects of Sinus Surgery on Antral Mucociliary Clearance:
 Markus Rautiainen

Pharmacology
 Effects of Common Intranasal
 Medications on Cilia Function: Yang-Gi Min
 Discussion: Consensus on Techniques, Temperature,
 Solutions, Experimental Paradigms: Noam Cohen

1:30-2:30pm **AAOA PAPER SESSIONS**
 Salon 1
 Moderators: Suman Golla

1:30pm Abstract #1895—The Long-Term Efficacy Of Mucosal Cpg Oligodeoxynucleotides In The Treatment Of Eustachian Tube Dysfunction In Rats: Deidra Blanks

1:40pm Abstract #1896—Validation of Optical Rhinometry Using Nasal Provocation Testing in Allergic and Nonallergic Subjects: Amber Luong

1:50pm Abstract #1897—Histopathology of Nasal Polyps for CRS; Preliminary Results: Joseph Han

2:00pm Abstract #1729—Genome-Wide Analysis of Gene Expression Changes in the Chronic Rhinosinusitis: Alla Solyar

2:10pm Abstract #1850—Development Of A Mouse Model of Chronic Maxillary Sinusitis: Xiaoyang Hua

2:20pm Questions

1:30–3:30pm **IRS/ISIAN PAPER SESSIONS**
 Salon 3/4
 Moderators: Adam Zanation, Theodore Truitt

1:30pm Abstract #1598—The Effects of Bipolar Radiofrequency Ablation on Sinonasal Mucosa in a Sheep Model: Laura Swibel Rosenthal

1:38pm Abstract #1609—Radiofrequency Coblation Decreases Blood Loss During Endoscopic Sinonasal and Skull Base Tumor Removal: John Kostrzewa

1:46pm Abstract #1814—An Initial Clinical Evaluation of a Three Dimensional Endoscope System for Endoscopic Sinus and Skull Base Surgery: Adam Zanation

2:00pm Abstract #1643—Clinical Experience Using Canine Fossa Access During Trans-Antral, Endoscopically Guided Balloon Dilation of the Ostiomeatal Complex (OMC): Theodore Truitt

2:08pm Abstract #1644—Early Results for Trans-Antral Balloon Antrostomy under Local Anesthesia in the Office: Theodore Truitt

2:16pm Abstract #1754—Case Study: Mechanisms of Action for Balloon Dilation of the Ostiomeatal Unit (OMU) in Patients with Chronic Rhinosinusitis: James Atkins

2:30pm Abstract #1758—Is Loose Nasal Packing Efficient and Safe After Inferior Turbinectomy: Tung-Tsun Huang

2:38pm Abstract #1797—Sinus Spacer: A Preliminary Analysis Of Efficacy and Safety: Mark Thong

2:46pm Abstract #1861—Packingless Rhinologic Surgery: A 20 Year Experience: Chester Griffiths

3:00pm Abstract #1775—Incidence of Fontanel Defects and the Two Holes Syndrome: Katarina Vukovic

3:08 PM Abstract #1769—A 24-Year Experience in Endoscopic Surgical Management of Sino-Nasal Mucocoeles: Devyani Lal

3:16pm Abstract #1807—Local Mucosal Flaps in the Management of Post-Sphenoidotomy Stenosis: John Lee

1:30-3:30pm

IRS/ISIAN PAPER SESSIONS

Salon 5/6

Moderators: Jay Dutton, Abtin Tabae

- 1:30pm Abstract #1545—Prevalence and Severity of Anosmia in Workers Exposed to the World Trade Center Site: Shaun Desai
- 1:38pm Abstract #1734—The Effect of Middle Turbinate Suture Medialization on Olfaction: Jay Dutton
- 1:46pm Abstract #1765—Olfactory Bulb Volume in Idiopathic Olfactory Loss: Philippe Rombau
- 2:00pm Abstract #1631—Sinus Culture Directed Management of Sinusitis in a Tertiary Rhinology Centre: Carl Philpott
- 2:08pm Abstract #1670—Epstein-Barr Virus—Mild Acquired Immune Deficiency Syndrome in Sinusitis, Implications for Treatment of Biologic Chronic Fatigue Syndrome: Paul Toffel
- 2:16pm Abstract #1604—Allergic Fungal Sinusitis—A New Staging System: Carl Philpott
- 2:30pm Abstract #1663—Cerebrospinal Fluid Rhinorrhoea: New Classification & Guidelines for Endoscopic Management: Reda Kamel
- 2:38pm Abstract #1702—Repair of Frontal Sinus Cerebrospinal Fluid Leak: Selecting a Surgical Approach: Jian-bo Shi
- 2:46pm Abstract #1722—Endoscopic Repair of Basal Sinonasal Cephaloceles: Mohammed Hassab
- 3:00pm Abstract #1802—Endoscopic Management of Cerebrospinal Fluid Leaks of the Sphenoid Sinus: Annie Lee
- 3:08pm Abstract #1806—“Gasket-Seal” Reconstruction of the Sellar Floor Using Non-Autologous Material in Revision Endoscopic Pituitary Surgery: Abtin Tabae
- 3:16pm Abstract #1885—Endoscopic Repair of CSF Leak Rhinorrhea in 165 Patients: The Outcomes: Marina Nersesyan

1:30-3:30pm

IRS/ISIAN PAPER SESSIONS

Salon 9

Moderators: Zara Patel, Shahriar Nazari

- 1:30pm Abstract #1677—Exploring Legal Risks Related to Endoscopic Sinus Surgery: David Keschner
- 1:38pm Abstract #1706—Correlation Between Subjective Assessment and Objective Measurement of Nasal Obstruction: Gehua Zhang
- 1:46pm Abstract #1715—Outcomes Testing for Endoscopic Skullbase Surgery including Nasal Tissue Resection: Zara Patel
- 2:00pm Abstract #1669—Complications and Sequelae of Fractures Involving the Sphenoid Sinus: Joseph Sciarrino
- 2:08pm Abstract #1674—Ventral Skull Base Erosions as Risk Factors for the Recurrence of Allergic Fungal Rhinosinusitis After Endonasal Endoscopic Surgery: Omar El-banhawy
- 2:16pm Abstract #1675—Molecular Characterization of the Polymicrobial Flora in Chronic Rhinosinusitis (CRS): Marie-France Stephenson
- 2:30pm Abstract #1790—Revision Rhinoplasty For Correction of Deviated Nose: Yong Ju Jang
- 2:38pm Abstract #1791—Classification And Treatment Outcome of Convex Nasal Dorsum Deformity In Orientals: Ji Heui Kim
- 2:46pm Abstract #1818—An Adjustable Implant for Nasal Valve Dysfunction: A 3 Year Experience: Charles Hurbis
- 3:00pm Abstract #1855—The Role of Titanium Plates In Septorhinoplasty: Jose Godoy
- 3:08pm Abstract #1864—Is Lateral Osteotomy an Obligation In Rhinoplasty For Crooked and Non-Crooked Nose or Not: Shahriar Nazari
- 3:16pm Abstract #1865—Multilayer Spreader Grafts: Shahriar Nazari

1:30-3:30pm

IRS/ISIAN PAPER SESSIONS

Salon 10

Moderators: Shawky Elmorsey, Stephanie Joe

- 1:30pm Abstract #1578—Correlation Between Outcomes of Endoscopic Management of Sinogenic Facial Pain or Headache and Preoperative Computed Tomography in Rhinosinusitis: Mohamed Askar
- 1:38pm Abstract #1616—Long Term Results of Septal-Turbinate-Suture in Endoscopic Sinus Surgery: Mona Ashoor
- 1:46pm Abstract #1655—Epidemiological Findings of Chronic Rhinosinusitis in our Population: Rafael Hijano
- 2:00pm Abstract #1736—Upregulation of Bcl-2 in Nasal Polyps of Patients with Cystic Fibrosis: Victor Scapa
- 2:08pm Abstract #1708—Prevalence of Metabolic Bone Disease in Chronic Rhinosinusitis: Karthik Rajasekaran
- 2:16pm Abstract #1726—Extranodal Rosai-Dorfman Disease involving Pterygopalatine fossa, Orbit and Middle Cranial Fossa—Case Report: Tsan-Jen Chiu
- 2:30pm Abstract #1853—PGE2 Suppresses Staphylococcal Enterotoxin-Induced Eosinophilia-Associated Cellular Responses Dominantly Via An EP2-Mediated Pathway In Nasal Polyps: Mitsuhiro Okano
- 2:38pm Abstract #1733—Nasopharyngeal Swab Cytology for Nasopharyngeal Carcinoma by Non-Otorhinolaryngologists: S Tiong
- 2:46pm Abstract #1671—Application of Genetic Association Studies to the Study of Chronic Rhinosinusitis: A New Era Dawns: Martin Desrosiers
- 3:00pm Abstract #1549—Rubber Tube Versus Silicone Tube at the Osteotomy Site in Dacryocystorhinostomy: Shawky Elmorsey
- 3:08pm Abstract #1564—Powered Endoscopic Dacryocystorhinostomy with Mucosal Flaps Without Stenting: Harvinder Singh
- 3:16pm Abstract #1711—Anastomosis of Nasal Mucosal & Lacrimal Sac Flaps: Key Role In Endoscopic Dacryocystorhinostomy: Chiara Bellini

2:00-3:00pm

Patient Safety

Horizons Ballroom

Ara Chalian

2:30-3:30pm

IRS/ISIAN PAPER SESSIONS

Salon 1

Moderators: Alan Shikani, Richard Harvey

- 2:30pm Abstract #1658—Rhinotopic Therapy for Refractory Chronic Rhinosinusitis Using the Vibrating Mesh Nebulizer: Alan Shikani
- 2:38pm Abstract #1714—Fluticasone Propionate Delivered With the Optinose Delivery Device Effectively Treats Chronic Rhinosinusitis: Per Djupesland
- 2:46pm Abstract #1724—Nasal Congestive and Inflammatory Response to Inhalation Challenge with Hexamethylene Diisocyanate (HDI): A Pilot Study: Roberto Castano
- 3:00pm Abstract #1742—The Effectiveness of Pulmicort Delivery With the Mucosal Atomisation Device in Treating Allergic Fungal Sinusitis: Bedy Lau
- 3:08pm Abstract #1750—Fluid Residuals and Drug Exposure in Nasal Irrigation: Richard Harvey
- 3:16pm Abstract #1871—The Effect Of Montelukast on Quality of Life in Patients with Nasal Polyposis Accompanying Asthma Bronchiale—Preliminary Results: Ibrahim Sayin

- 2:35–3:30pm **MINI SEMINAR: Chronic Sinusitis—A Complex Disease Coalescence of Surgical, Medical and Laboratory Information** (Einstein/NYU Rhinology Course)
Logans 2
Moderator: Joseph Jacobs
Michael Chandler, Alexis Jackman, Richard Lebowitz, Amber Luong, Steven Schaefer, Michael Setzen
- 2:35–3:30pm **DEMONSTRATION DISSECTION: Skull Base Surgery—The Assisted, Bimanual “4-Hand” Technique**
Liberty Ballroom AB
Nick Jones, Daniel Simmen
Discussants: Vijay Anand, Aldo Stamm
- 2:35–3:30pm **MINI SEMINAR: Pediatric Chronic Rhinosinusitis**
Logans 1
Chair: Rodney Lusk, Moderator: Sanjay Parikh
Definition and Evaluation of Pediatric CRS: Fuad Baroody
Judicious Medical Management of Pediatric CRS: Tania Sih
Current Understanding of the Adenoids and Pediatric CRS: Hassan Ramadan
Current Indications, Technology and Techniques for Pediatric FESS: Rodney Lusk
Case Presentations: Sanjay Parikh
- 2:35–3:30pm **INSTRUCTIONAL COURSE: CT and MRI Interpretation**
Liberty Ballroom D
Laurie Loevner
- 3:30–4:00pm **BREAK: Refreshments in Exhibit Hall**
Freedom/Independence Ballroom
- 4:00–5:30pm **MINI SEMINAR: Balloon Sinuplasty Indications**
Salon 3/4
Moderator: Peter Catalano
Anthony Papavassiliou, Jeffrey Cutler, Howard Levine
- 4:00–5:30pm **MINI SEMINAR: Alternative and Complimentary Therapies**
Seminar A
Chair: Pontus Stierna, Moderator: Claus Bachert
Homeopathic Therapy for Sinusitis: My 10 Year Experience: Marina Nersesyan
Complementary Medicine in Rhinology: Myths, Truth & Risks: Monica Menon-Miyake
Acute Rhinosinusitis: Phytotherapy vs. Glucocorticosteroids: Claus Bachert
Host Defense: The Role of Phytotherapy: Pontus Stierna
- 4:00–5:30pm **MINI SEMINAR: Personal Philosophy in Rhinoplasty**
Liberty Ballroom C
Chair: Ian Mackay, Moderator: Stephen Goldstein
Introductions: Ian Mackay, Stephen Goldstein
From Basic to Advanced, My Approach: David Gatland
Structural Grafts and the Test of Time: Roxana Cobo
Repairing the Traumatized Nose: Stephen Goldstein
Graft Selection in the Asian Rhinoplasty: Balwant Gendeh
Asian Tipplasty: Tae-Young Jang
Questions and Answers
- 4:00–5:30pm **MINI SEMINAR: Implants in Rhinology: Stents & Packing**
Liberty Ballroom D
Chair: Heinz Stammberger
Moderator: David Kennedy
Overview of Biomaterials in Rhinology: Richard Orlandi
Pharmacodynamics & Tissue Mechanics in the Sinus Ostia: Edward Hepworth
Biomaterial Composition and Mucosal Healing: Rakesh Chandra
Nasal Packing after FESS: Is it Necessary?: Peter Hwang
Change in Packing Techniques after FESS and Skull Base Surgery Over the Last Ten Years—The Graz Experience: Heinz Stammberger
- 4:00–5:30pm **MINI SEMINAR: Towards System Level Analysis of Allergic Nasal Epithelium**
Salon 5/6
Chair: Robert Naclerio, Moderator: Wytse Fokkens
System Level Analysis from Cell to Human System: Wytse Fokkens
Allergens Meet the Epithelium—A Systems Biology Approach: Risto Renkonen, Sanna Toppila-Salmi
How Epithelial Cells Detect Danger: Cornelis van Druenen
The Sinus Inflammatory Response—A Neural Reflex or a Systemic Allergic Inflammation: Robert Naclerio
United Airways—The Role of Systemic Circulation: Peter Hellings
Patient Selection and the Consequences for Study Designs: Fenna Ebbens
- 4:00–5:30pm **MINI SEMINAR: Obstructive Sleep Apnea**
Salon 9
Chair: Gil Vicente, Moderator: Metin Onerci
Gil Vicente, Metin Onerci, Antonio Sousa Vieira, Andrew Goldberg
- 4:00–5:30pm **MINI SEMINAR: Combined Approaches to the Orbit “Challenging Cases and Favorite Techniques”**
Salon 1
Moderator: Edmund Pribitkin
Panelists: Jurij Bilyk, Roberta Gausas, Ralph Metson, Edmund Pribitkin, Marc Rosen, Raymond Sacks
Optic Nerve Decompression for Traumatic and Non-Traumatic Causes
Primary and Revision Orbital Decompression for Thyrotoxic Exophthalmos
Techniques to Approach the Orbital Apex
Managing Mucocelles Eroding the Orbital Roof
Technique Refinement in Orbital Trauma
Sinonasal Tumors Invading the Orbit & Orbital Tumors Invading the Nose
- 4:00–5:30pm **INSTRUCTIONAL COURSE: Evolving Indications for FESS**
Seminar D
Moderator: Martin Desrosiers
Selecting the Optimal Patient for Primary ESS: Wilma Anselmo-Lima
When is Revision Surgery of Benefit?: Satish Govindaraj
Thinking Outside the Box: Indication for ESS Beyond the Sinus: Donald Lanza
Evolution of Endoscopic Frontal Sinus Surgery: Carlos Yanez

Program • Friday, April 17, 2009

4:00–5:30pm **INSTRUCTIONAL COURSE: Endoscopic Sinus Surgery: Problems and Solutions** (Turkish Rhinologic Society)
Salon 10
Moderator: Kemal Deger
Panelists: Nesil Keles, Halis Unlu, Levent Soylu, Semih Sutay

4:00–5:30pm **INSTRUCTIONAL COURSE: Topical Therapies**
Logans 2
Moderator: Richard Harvey
Delivery Devices (Neti Pot, Squeeze Bottle),
Low Volume Devices and Positioning: Richard Harvey
Scientific (+/- Clinical) Effects of Saline: Christopher Brown
Steroids and Anti-Inflammatory Treatments: Alexander Chiu
Anti-Microbial Treatments—Including Anti-Fungals and
Anti-Bacterial Therapies: Larry Kalish
Surfactants, Mucolytics and Other Novel Topical:
Noam Cohen
Vladimir Kozlov

4:00–5:00pm **INSTRUCTIONAL COURSE: Advances in the Management of Facial Pain and Empty Nose Syndrome**
Seminar B
Moderator: Nick Jones
Nerve Blocks for Facial Pain: Jay Dutton
An Update on Midfacial Segment Pain: Nick Jones
Empty Nose Syndrome: Steven Houser

4:00–5:30pm **INSTRUCTIONAL COURSE: Aspirin-Exacerbated Respiratory Disease**
Seminar C
Moderator: Antoni Krzeski
Introduction: Antoni Krzeski
Aspirin-Exacerbated Respiratory Disease—
Pathomechanism and Clinical Presentation: Iwona Gromek
Testing for Aspirin Hypersensitivity: Anders Ehnhage
Management of Aspirin-Sensitive Chronic Rhinosinusitis
with Nasal Polyps: Antoni Krzeski
Impact of Chronic Rhinosinusitis Management on the Course
of Bronchial Asthma in Aspirin-Exacerbated Respiratory
Disease: Iwona Gromek

4:00–5:30pm **INSTRUCTIONAL COURSE: Pediatric JNA**
Logans 1
Moderator: Sanjay R. Parikh
Introduction: Sanjay R. Parikh
Diagnosis and Staging with Current Classification Systems:
Ken Kazahaya
Current Indications & Techniques for Embolization:
Anne Marie Cahill
Contemporary Adjunct Navigation Technologies: Sanjay R. Parikh
Current Endoscopic and Open Techniques for Pediatric JNA:
Piero Nicolai
Case Presentations and Discussion: Ken Kazahaya
Audience Questions

5:00–5:30pm **MINI SEMINAR: Anesthetic Considerations in Endoscopic Sinus Surgery**
Seminar B
Jeffrey Mandel, Ashutosh Kacker

6:45–10:45am **GALA BANQUET**
National Constitution Center
(Tickets required; bus transportation provided)



- 7:00–8:00am **CONTINENTAL BREAKFAST & EXHIBITS**
Freedom/Independence Ballroom
- 8:00–8:45am **PLENARY SESSION: Beyond the Paranasal Sinuses**
Liberty Ballroom AB
Chair: James Stankiewicz
Keynote Speaker: Aldo Stamm
- 8:50–10:00am **ROUND TABLE: Surgical Techniques**
Liberty Ballroom AB
Chair: James Stankiewicz
Moderator: Aldo Stamm
- How to Approach Sellar and Parasellar Tumors:**
Heinz Stammberger
- Infratemporal Space Surgery—Case Selection:**
Alexandre Felippu
- Case to Explain the Transplanum Approach:** Vijay Anand
- How to Approach Esthesioneuroblastoma with Intradural Invasion:** Roy Casiano
- How to Reconstruct the Skull Base Defect After Extended Transnasal Craniectomy:** Rodney Schlosser
- When to Choose a Combined Approach (External X Endonasal):** Piero Nicolai
- 10:00–10:30am **BREAK: Refreshments in Exhibit Hall**
Freedom/Independence Ballroom
- 10:30–11:25am **MINI SEMINAR: Unified Airway**
Liberty Ballroom C
Chair: Ruby Pawankar
Moderator: Stephanie Joe
- Overview:** Ruby Pawankar
- Clinical Picture- Incidence, Clinical Presentation, and Histopathology:** Stephanie Joe
- The Arguments For and Against the Concept/the Research:**
- Viewpoint by Robert Schleimer
 - Viewpoint by Elina Toskala
 - Viewpoint by Claus Bachert
- Treatment Strategies:**
Open Discussion by the Panel with Cases Provided by Stephanie Joe and Ruby Pawankar
- Final Comments:** Ruby Pawankar
- 10:30–12:30pm **ARS Meeting Papers**
Liberty Ballroom AB
Moderators: Peter Catalano, John DelGaudio
- 10:30am **Abstract #1650—Regulation of Proton (H⁺) Secretion of Freshly Excised Nasal Tissues:** Do-Yeon Cho
- 10:36am **Abstract #1600—Title: A New Model for Analyzing the Flow Effects on Electrical Barrier of Nasal Epithelium:** Masato Miwa
- 10:42am **Abstract #1627—Nasopharyngeal Endoscopic Resection (Ner) in the Management of Selected Malignancies: Surgical Technique and Preliminary Results:** Andrea Bolzoni Villaret
- 10:48am **Discussion**
Moderators: Hassan Ramadan, Roy Casiano
- 11:00am **Abstract #1625—Endoscopic Surgery for Juvenile Angiofibroma (Ja): Indications and Limits:** Sylvie Nadeau
- 11:06am **Abstract #1701—Detection of Staphylococcus Aureus in Nasal Tissue with Peptide Nucleic Acid—Fluorescence in Situ Hybridization:** Marie-Noëlle Corriveau
- 11:12am **Abstract #1561—Tryptase Does Not Alter Paracellular Permeability in Human Airway Epithelial Cells:** Eugene Chang
- 11:18am **Discussion**
Moderator: Jay Dutton
- 11:30am **Expert's How I Do It: Choanal Atresia:** Heinz Stammberger
- 11:40am **Discussion**
Moderators: Robert Kern, Sanjay Parikh
- 11:45am **Abstract #1633—Mucosal Expression of Nerve Growth Factor and Brain-Derived Neurotrophic Factor in Chronic Rhinosinusitis:** Charles Coffey
- 11:51am **Abstract #1676—Polymorphisms in the NOS1 and NOS1AP Genes Are Associated With Severe Chronic Rhinosinusitis:** Yuan Zhang
- 11:57am **Abstract #1606—The Expression of the Immunoregulatory Enzyme Indoleamine 2,3-Dioxygenase in Patients With Nasal Polyps:** Sanna Toppila-Salmi
- 12:03pm **Discussion**
Moderator: Karen Fong
- 12:15pm **Expert's How I Do It: Surgery of the Pterygopalatine Fossa:** Peter Hwang
- 12:25pm **Discussion**
- 10:30–11:25am **GREAT DEBATE: Fungus vs. Bacteria**
Liberty Ballroom D
Moderator: Eugene Kern
Robert Kern, Jens Ponikau
- 10:30–12:00pm **IRS/ISIAN VIDEO SESSION**
Salon 5/6
Moderators: Robert Meyers, Adam Zanation
- 10:30am **Abstract #1576—Endoscopic Maxillary Failures:** Robert Meyers
- 10:36am **Abstract #1577—An Alternative To Revision Endoscopic Procedures in Frontal Sinus Failures:** Robert Meyers
- 10:42am **Abstract #1579—Endoscopic Management of Chronic Isolated Frontal Sinusitis: The Uncinectomy Approach:** Mohamed Askar
- 10:48am **Abstract #1883—Endoscopic Endonasal Repair of Orbital Blow-out Fracture:** Shoji Matsne
- 10:54am **Abstract #1548—Nasolacrimal duct probing: Failure and treatment:** Shawky Elmorsy
- 11:00am **Abstract #1781—The Endoscopic Pericranial Flap for Endoscopic Anterior Skull Base Reconstruction: A Technical Report:** Adam Zanation
- 11:06am **Abstract #1590—Frontal Sinus Approach: The Concept of the “Vertical Bar”:** Joao Nogueira
- 11:12am **Abstract #1592—Nasal outcomes after novel binostril approach for endoscopic pituitary surgery with septal preservation:** Joao Nogueira
- 11:35–12:30pm **MINI SEMINAR: Skull Base Reconstruction**
Liberty Ballroom C
Chair: Balwant Gendeh
Moderator: Rodney Schlosser
- Anterior Cranial Fistula Repair:** Balwant Gendeh
- Vascularized Flaps for Skull Base Repair:** Ricardo Carrau
- Impact of Etiology on Graft Repair of Skull Base Defects:** Roy Casiano
- Repair of Cribriform Plate Defects:** Enrique Iturriaga
- Laser Tissue Welding for Skull Base Repair:** James Palmer

- 11:35–12:30pm **GREAT DEBATE: SCIT vs. SLIT**
 Liberty Ballroom D
 Moderator: Richard Haydon
 SCIT: Berrylin J. Ferguson
 SLIT: Elina Toskala
 Discussion and Questions
- 12:30–1:30pm **LUNCH: Boxed Lunches available in Lunchtime Symposium (Liberty Ballroom AB) and Exhibit Hall (Freedom/Independence Ballroom)**
- 12:30–1:30pm **LUNCHTIME SYMPOSIUM:**
The Role of Coblation® Technology in Sinus Surgery
 Liberty Ballroom AB
 Overview of Coblation Technology: Simon Carney
 Endoscopic Coblation of Sinonasal Mucosa in the Sheep and Rabbit Model: Mark Zacharek
 Use of Coblation for Endoscopic Skull Base & Sinus Tumors: Panelists: Bradford Woodworth, James Hicks, Gregory James
 Use of Coblation for Polypectomy and JNA: Jose Ruiz
- 1:30–5:00pm **RHINOLOGY BOWL**
 Horizons Ballroom
- 1:30–5:00pm **INSTRUCTIONAL COURSE: Hands-on Lab Dissection**
 UPENN School of Medicine, Stemmler Hall Rm 212
 (Pre-registration required; buses leave the Sheraton at 1:00pm)
 Soo Kim Abboud, Samuel Becker, Edward Hepworth, James Kearney, Kelly Malloy, James Palmer, Aldo Stamm, Erica Thaler, Winston Vaughan, Eugenia Vining, Sarah Wise
- 1:30–2:25pm **DEMONSTRATION DISSECTION**
 Liberty Ballroom AB
 Transpterygoid/Infratemporal Fossa: James Palmer
 Narrow Band Imaging in the Head & Neck Region: Bert O'Malley
 Discussants: Alexander Chiu, Rodney Schlosser
- 1:30–2:25pm **MINI SEMINAR**
Sinus Surgery: Management of Complications
 Liberty Ballroom D
 Chair: Ian Mackay
 Moderator: Scott Graham
 Complications of Sinus Surgery—Role of Technology: Scott Graham
 Orbital Injury: Alfredo Herrera
 Intra-Cranial Complications: Ephraim Eviatar
 Carotid Injury: Richard Gallagher
- 1:30–3:30pm **MINI SEMINAR: Nasal Polyposis**
 Logans 2
 Chair: Desiderio Passali
 Moderator: Peter Hwang
 Introductory Comments: Desiderio Passali
 Abnormalities of Disease-Related Gene Expression Profiles in Nasal Polyposis: De Yun Wang
 The Role of Superantigens in Nasal Polyposis: Claus Bachert
 Medical Therapy for Nasal Polyposis: Anders Cervin
 Samter's Triad: Special Considerations: Jan Gosepath
 Surgical Management of Nasal Polyposis: Andrei Lopatin
 Management of Recurrent Nasal Polyposis: Joong Saeng Cho
 Case Discussions with Panelists: Peter Hwang
 Closing Remarks: Desiderio Passali
- 1:30–2:25pm **MINI SEMINAR: Point of Service Imaging**
 Salon 10
 Chair: David Kennedy
 Moderator: David Conley
 Introduction: David Kennedy
 Choice of Device: Flat Panel vs. Conventional CT: David Conley
 Indications for POS CT and Pre-authorization: Michael Sillers
 Accreditation: Mary Lally
 Making It Work in Your Practice: Gavin Setzen
 Summary and Question: David Kennedy
- 1:30–2:25pm **INSTRUCTIONAL COURSE: Pediatric Rhinoplasty**
 Salon 1
 Gilbert Trenite
- 1:30–2:25pm **MINI SEMINAR: Frontal Sinus Fx**
 Logans 1
 Chair: Geng Xu
 Moderator: De-Min Han
 Overview of Frontal Sinus Fractures:
 Obliteration and Cranialization Concepts, Open Reduction Internal Fixation and Approaches: Andrew Murr
 Endoscopic Approaches to Frontal Sinus Fractures in Detail: Jacob Steiger
 Management of Long-Term Complications of Frontal Sinus Fractures—Including Endoscopic and External Approaches: Steven Pletcher
 Questions from Audience
- 1:30–3:30pm **IRS/ISIAN PAPER SESSIONS**
 Salon 3/4
 Moderators: Ahmed Atef, Jamie Litvack
- 1:30pm Abstract #1608—The Calcium Sensing Receptor in Sinonasal Epithelium: A Modulator of Ciliary Beat Frequency?: Dawn Sharp
- 1:38pm Abstract #1610—Ultrastructural Ciliary Changes of Maxillary Sinus Mucosa Following Functional Endoscopic Sinus Surgery: An Image Analysis Quantitative Study: Ahmed Atef
- 1:46pm Abstract #1546—Rheologic Properties of Sinonasal Mucus in Patients with Chronic Rhinosinusitis: David Saito
- 2:00pm Abstract #1832—A Pilot Study of a Chinese Version of the University of Pennsylvania Smell Identification Test for Application in Taiwan: Rong-San Jiang
- 2:08pm Abstract #1879—Objective Assessment of the Impact of Chronic Rhinosinusitis (CRS) On Olfactory Function: Kai Zhao
- 2:16pm Abstract #1887—Computational Modeling of Nasal Airflow and Odorant Transport In Patients With Chronic Rhinosinusitis: Kai Zhao
- 2:30pm Abstract #1804—Comparison of Disease-Specific Quality of Life Instruments In The Assessment of Chronic Rhinosinusitis: Jamie Litvack
- 2:38pm Abstract #1834—Quality of Life is Improved by Endoscopic Sinus Surgery in Nasal Polyposis with Asthma: Anders Ehnbage
- 2:46pm Abstract #1842—Quality of Life in Patients with Chronic Rhinosinusitis, Nasal Septal Deviation, Obstructive Sleep Apnea, Headaches, and GERD: Helen Perakis
- 3:00pm Abstract #1852—Impact of Nasal Polyps On Quality of Life of Chronic Sinusitis Patients: Lakshmi Vaid
- 3:08pm Abstract #1859—Functional Voice Outcomes Following External Medialization Thyroplasty Using Autologous Nasal Septal Cartilage Under Local Anesthesia: Tamer Mesallam
- 3:16pm Abstract #1884—Differentiation of Chronic Rhinosinusitis (CRS) and its Coupling to Lower Airways: Kåre Håkansson

1:30–3:00pm MINI SEMINAR (ARS): Endoscopic Skull Base Surgery
 Liberty Ballroom C
 Chair: Todd Loeuhl
 Moderator: Ricardo Carrau

Endoscopic Endonasal Resection of Anterior Skull Base Meningiomas: Heinz Stammberger
 Endoscopic Resection of Malignant Tumors of the Sinonasal Tract: Piero Nicolai
 Endoscopic Control of the ICA: Adam Zanation
 Endoscopic Approaches to the Cavernous Sinus: Ernesto Pasquini
 Duraplasty after Endoscopic Skull Base Surgery: Paolo Castelnuovo

1:30–3:30pm IRS/ISIAN PAPER SESSIONS

Salon 5/6
 Moderators: Amin Javer, Vittorio Sciarretta

- 1:30pm Abstract #1550—Transnasal Endoscopic Resection of Benign Tumors Extending to Pterygopalatine & Infratemporal Fossa: Shawky Elmorsy
- 1:38pm Abstract #1551—Management of CSF Rhinorrhea; Septal Graft and Middle Turbinate Rotational Flap Technique: Shawky Elmorsy
- 1:46pm Abstract #1575—Endoscopic Transnasal Resection of Malignant Tumor in the Pterygopalatine Fossa: Satoru Kodama
- 2:00pm Abstract #1605—Endoscopic Management of Sino-Nasal Tumors: Long-Term Results—The St Paul’s Experience: Carl Philpott
- 2:08pm Abstract #1620—Endoscopic Versus Open Approaches in Treating Huge Locally Advanced Angiofibromas: Hossam El Bosraty
- 2:16pm Abstract #1641—Endoscopic Treatment of Inverted Papilloma: A Report of 109 Cases: Vittorio Sciarretta
- 2:30pm Abstract #1764—Minimally Invasive Treatment Modality for Sinonasal Malignancy With Anterior Skull Base Invasion—A Preliminary Report: Yu-Fu Chou
- 2:38pm Abstract #1766—The Influence of Septal Flap Reconstruction On Sinonasal Function and Quality of Life: Harshita Pant
- 2:46pm Abstract Number: 1768—Endoscopic Transphenoidal Approach to Petrous Apex Lesions: Leela Lavasani
- 3:00pm Abstract #1784—Endoscopic Management of Sphenoclivar Neoplasms: Anatomic Correlates and Patient Outcomes: Clementino Solares
- 3:08pm Abstract #1787—Large B-cell Lymphoma of the Frontal sinus: A Case Report: Gopi Shah
- 3:16pm Abstract #1786—Concurrent Resection of Pituitary Adenoma and Planum Sphenoidale Meningioma in a Patient with Cushing’s Disease: A Case Report: Gopi Shah

1:30–3:30pm IRS/ISIAN PAPER SESSIONS

Salon 9
 Moderators: Brad Mechor, Matteo Trimarchi

- 1:30pm Abstract #1589—Novel “Cross-Over Flap” Technique for Nasal Septal Perforations: Joao Nogueira
- 1:38pm Abstract #1599—Endoscopic Septoplasty with Powered Instruments: Aderito De Sousa
- 1:46pm Abstract #1710—Endoscopic Back and Forth Septoplasty Technique: Trimarchi Matteo

- 2:00pm Abstract #1833—Flap Reconstruction of Nasal Septal Perforation: Yaser Khalil
- 2:08pm Abstract #1844—Validity of “Hydrodissection” for Subperichondral Septoplasty—an Experimental Anatomical Study: Patrick Dubach
- 2:16pm Abstract #1664—Eustachian Tube Endoscopy: Validity and Limits: Stefano Millarelli
- 2:30pm Abstract #1739—Snoring In Adult Patients With Nasopharyngeal Tuberculosis: S Tiong
- 2:38pm Abstract #1841—Comparison of Retropalatal and Retroglossal Airway Obstruction in Obstructive Sleep Apnea Syndrome: Baharudin Abdullah
- 2:46pm Abstract #1767—Clinical Evaluation of a New Approach In Acute Rhinosinusitis: Anders Clemens
- 3:00pm Abstract #1747—Coblation Assisted Endoscopic Resection of a Juvenile Nasopharyngeal Angiofibroma with Pre-Operative Transnasal Embolization: Jose Ruiz
- 3:16pm Abstract #1874—Treatment of Nasal Polyposis with Oral Methylprednisolone and Doxycycline: A Double-Blind, Randomized, Placebo-Controlled Trial With Evaluation of Clinical and Biological Activity: Van Zele Thibaut

2:30–3:15pm Presentation Skills for Physicians: Making Your Next Talk Go Better Than Your Last
 Horizons Ballroom
 Scott Litin

2:35–3:30pm DEMONSTRATION DISSECTION
 Liberty Ballroom AB
 Clival Resection and Posterior Fossa Anatomy: Aldo Stamm
 Discussants: Alexander Chiu, Rodney Schlosser

2:35–3:30pm MINI SEMINAR: Microbes in CRS
 Liberty Ballroom D
 Chair: Jean-Silvain Lacroix
 Moderator: Robert Kern
 CRS and Infection: A View from the Tree Tops: Neil Bhattacharrya
 Characterizing the Microbial Communities Associated with CRS: Jeff Leid
 Endonasal Mupirocine Treatment for Staph Aureus Carriage: Does it Work?: Jean-Silvain Lacroix
 CRS: A Dysfunctional Host Reaction to Microbial Stimulation?: Robert Kern
 Questions

2:35–3:30pm MINI SEMINAR: Lasers in Rhinology
 Logans 1
 Chair: Anthony Papavassiliou
 Moderator: Howard Levine
 Introduction: Anthony Papavassiliou
 History of Lasers in Rhinology and Use of Laser for Turbinate Dysfunction: Itzhak Braverman
 Role of Argon Laser in Rhinology: Kazanas Savvas
 Transcanalicular DCR using Diode Laser: Antonio Sousa Vieira
 Laser Septochondroplasty: Anthony Papavassiliou
 Tissue Welding in Anterior Skull Base Repair: Benjamin Bleier

- 2:35–3:30pm **MINI SEMINAR: HHT/Epistaxis**
Salon 1
Chair: Elie Serrano
Moderator: Douglas Ross
Elie Serrano, Douglas Ross, Valerie Lund
- 2:35–3:30pm **INSTRUCTIONAL COURSE**
Salon 10
Revision Rhinoplasty: Gilbert Trenite
- 3:00–4:00pm **INSTRUCTIONAL COURSE: Predictable Tip Techniques**
Liberty Ballroom C
Moderator: Edmund Pribitkin
Tips in Tip Work: Nick Jones
Case Presentation: Daniel Becker, Cemal Cingi, Nick Jones, Ira Papel, Edmund Pribitkin
Topics to include:
 - Managing the Medial Crura: Widened Crural Feet, Medial Crural Fixation Suture, Septocolumellar Suture, Columellar Strut
 - Refining the Tip: Interdomal Suture, Transdomal Suture, Weakening the Dome, Vertical Dome Division
 - Tip, Shield and Cap Grafts
 - Special Considerations: Thick Skinned Tip
 - Special Considerations: Thin Skinned Tip
- 3:30–4:00pm **BREAK: Refreshments in Exhibit Hall**
Freedom/Independence Ballroom
- 4:00–5:30pm **MINI SEMINAR: Management of Turbinates and Septum**
Salon 3/4
Chair: Fuad Baroody
Moderator: Raymond Sacks
Review of Evidence Looking at Surgery of the Septum or Turbinates for Headache: Fuad Baroody
Medical Management of Rhinitis: Jay Dutton
Endoscopic Inferior Turbinoplasty Versus Alternative Techniques—The Pros and Cons: Raymond Sacks
Role of Coblation in the Management of the Hypertrophied Inferior Turbinate: Simon Carney
An Algorithm for the Management of the Turbinates: Gil Vicente
- 4:00–5:30pm **MINI SEMINAR: DCR/Orbit**
Salon 1
Chair: Balwant Gendeh
Moderator: Aderito DeSousa
Anatomy of the Lacrimal Bone at the Lateral Wall of the Nose—Its Significance to the Rhinoendoscopist: Enrique Iturriaga
Surgical Techniques and its Variations: Reda Kamel
Long-term Results and Reasons for Failure: Mohsen Naraghi
- 4:00–5:30pm **MINI SEMINAR: Olfaction**
Salon 5/6
Chair: Donald Leopold
Moderator: Edmund Pribitkin
Donald Leopold, Edmund Pribitkin, Luisa Bellussi, Beverly Cowart, Richard Doty, Karen Fong, Eric Holbrook
- 4:00–5:30pm **MINI SEMINAR: Guidelines in Rhinosinusitis: The Questions They Answer and Do Not Answer**
Seminar A
Chair: Peter Hellings
Moderator: Wytse Fokkens
Definitions and Agreements—
The Basis for Advancement in the Field: Wytse Fokkens
What I Could Not Find in the Recent Guidelines on Rhinosinusitis and Would Have Loved to Know: Richard Douglas
Management Schemes—A Way to Educate and to Improve Patients QOL: Fenna Ebbens
American Versus European CRS Guidelines, Similarities & Differences: To A World Guideline on CRS: Peter Hellings
- 4:00–5:30 **MINI SEMINAR: Endoscopic Surgery of Skull Base (Cornell Rhinology Course)**
Salon 10
Chair: Theodore Schwartz
Moderator: Vijay Anand
Advanced Endoscopic Anatomy: Ameet Singh
Endoscopic Approaches: Classification: Seth Brown
Endoscopic Suprasellar Approaches for Skull Base Lesions: Theodore Schwartz
Surgical Decisions in Endoscopic Skull Base Resections: Abtin Tabaei
Endoscopic Approaches to Infratemporal Fossa and Beyond: Vijay Anand
Discussion
- 4:00–5:30pm **MINI SEMINAR: Wound Healing and FESS**
Salon 9
Chair: Hiroshi Moriyama
Moderator: Peter Hwang
Opening Remarks: Hiroshi Moriyama
Mucosal Histologic and Function in CRS: Parul Goyal
Histologic and Functional Recovery After FESS: Werner Hosemann
Intraoperative and Postoperative Considerations in Optimizing Wound Healing: Richard Orlandi
Enhancement of Wound Healing Through Biotechnology: Rakesh Chandra
Discussion: Peter Hwang
Closing Remarks: Hiroshi Moriyama
- 4:00–5:30pm **MINI SEMINAR: Management of Eustachian Tube Dysfunction**
Seminar B
Chair: Brian Dunham
Moderator: Douglas Bigelow
Brian Dunham, Douglas Bigelow, Daqing Li, Carlos Yanez
- 4:00–5:30pm **INSTRUCTIONAL COURSE: Robotic Skull Base Surgery**
Liberty Ballroom D
Bert O'Malley, Gregory Weinstein

4:00–5:30pm

INSTRUCTIONAL COURSE:

Perioperative Medical Management

Seminar D

Moderator: Norbert P. Gorski

Perioperative Medical Management in Endoscopic Sinus Surgery—Novel Idea or Traditional Approach: Norbert P. Gorski
 Preoperative Approach to ESS Patient: Norbert P. Gorski
 Topical Nasal Irrigations and Sprays, Mechanical Penetration and Coverage: Erik Weitzel
 Target Ostial Sizes with Sinus Surgery and Influence on Sinus Irrigation: Erik Weitzel
 Pitfalls in Postoperative Management: Eliza Brozek-Madry
 Impact of Perioperative Medical Management on the Long-Term Results of Endoscopic Sinus Surgery: Norbert P. Gorski

4:00–5:30pm

INSTRUCTIONAL COURSE:

Rhinoplasty—Technique I Cannot Live Without

Liberty Ballroom C

Moderator: Ian Mackay

Cottle's Technique—Functional Approach: Ignazio Tasca
 Septum and Tip Support: Cemal Cingi
 Reassuring Tip Position in Rhinoplasty: Fazil Apaydin
 Seagull Wing Graft: A Technique for the Replacement of Lower Lateral Cartilages: Fernando Pedroza
 Tipplasty in Thick Skin Patients: I Love Triamcinolone!: Alizera Mesbahi

4:00–5:30pm

INSTRUCTIONAL COURSE: Correct Coding For Better Reimbursement in Rhinology

Seminar A

Moderator: Michael Setzen

Common Coding Dilemmas in Rhinology and What to Do: Michael Setzen
 Top 5 Practice Management Tips Including E&M and Modifiers: Kim Pollock
 Top 5 Practice Management Tips You Cannot Afford to Miss: Kim Pollock

4:00–5:30pm

INSTRUCTIONAL COURSE: SLIT

Seminar C

Moderator: Rodney Schlosser

History of SLIT and AAOA Recommendations: Sandra Lin
 Clinical Outcomes in Allergic Rhinitis and Escalation Protocols: Sarah Wise
 Impact of SLIT on Asthma: William Reisacher
 How Does SLIT Work and Future Directions: Rodney Schlosser

4:00–5:30pm

INSTRUCTIONAL COURSE: GERD

Live Nasoesophagoscopy (Olympus)

Logans 1

Moderator: Natasha Mirza

Extra-Esophageal Reflux (EER): Todd Loehrl
 Reflux and Refractory Chronic Sinusitis: Todd Loehrl
 Overview of EER/GERD: Todd Loehrl
 Evidence Based Reflux and Sinusitis: Todd Loehrl
 Overview of Laryngo-Pharyngeal Reflux: Kevin Leahy
 Diagnosing LPR: RSI, RFS, Laryngoscopies, Manometry, pH Probes: Kevin Leahy
 Reflux and Sinusitis: Distinguishing Between the Two: Natasha Mirza
 Managing “Mucus in the Throat”: Natasha Mirza
 Cough: Reflux or Sinusitis: Natasha Mirza

8:00–8:45am **PLENARY SESSION: Allergy**
Liberty Ballroom AB
Chair: Richard Haydon
Keynote Speaker: Jennifer Derebery

8:50–10:00am **ROUND TABLE: Techniques for an Allergy Practice**
Liberty Ballroom AB
Chair: Richard Haydon
Moderator: Jennifer Derebery
Richard Haydon, Jennifer Derebery, Jack Krouse, Michael Parker, Ruby Pawanker, Elina Toskala

10:30–12:00pm **MINI SEMINAR: Complications/Reducing Complications/Strategies in Revision**
Liberty Ballroom D
Chair: Cemal Cingi
Moderator: Daniel Becker
Introduction: Cemal Cingi
Complications in Rhinoplasty: Eugene Kern
Reducing Complications in Rhinoplasty: Daniel Becker
Case Presentation- Tip and Middle Vault: Cemal Cingi
Questions

10:30–12:00pm **“MY MOST FASCINATING CASE”**
Liberty Ballroom AB
Chair: Alexandre Felippu
Moderator: James Palmer
Alexandre Felippu, James Palmer, Roy Casiano, Paolo Castelnuovo, Piero Nicolai, Ernesto Pasquini, Aldo Stamm

10:30–12:20pm **ARS MEETING PAPERS**
Liberty Ballroom C
Moderators: Subinoy Das, Patricia Maeso

10:30am Abstract #1798—Clinical Protocol For Endonasal Skull Base Reconstruction—The Pittsburgh Algorithm: Annie Lee

10:36am Abstract #1778—A Comprehensive Algorithm and Systematic Review for Endoscopic Skull Base Reconstruction: Mihir Patel

10:42am Abstract #1588—Surgical Staging of Esthesioneuroblastoma for Endoscopic-Assisted Transnasal-Craniectomy: Joao Nogueira

10:48am Discussion
Moderator: Pete Batra

11:00am Expert’s How I Do It: Management of Epistaxis: Martin Citardi

11:10am Discussion
Moderators: Pete Batra, James Stankiewicz

11:15am Abstract #1626—Endoscopic Transnasal Craniectomy (Etc) In The Management of Selected Sino-Nasal Malignancies: Surgical Technique and Morbidity: Andrea Bolzoni Villaret

11:21am Abstract #1810—Outcome Results Of Endoscopic Versus Craniofacial Resection of Sinonasal Malignancies: A Pooled-Data Analysis: Thomas Higgins

11:26am Abstract #1801—Prospective Evaluation of 70 Nasoseptal Flaps for Endoscopic Reconstruction of High Flow Intraoperative CSF Leaks During Endoscopic Skull Base Surgery: Adam Zanation

11:32am Discussion
Moderator: Stephanie Joe

11:45am Expert’s How I Do It: Coding for the Rhinologist: Michael Setzen

11:55am Discussion
Moderator: Stilianos Kountakis

12:00pm Expert’s How I Do It: Frontal Sinus Surgery: James Stankiewicz

12:10pm Discussion & Farewell: James Stankiewicz, President, ARS

12:00–1:00pm **RHINOLOGY BOWL CHAMPIONSHIP**
Liberty AB

1:00pm **CLOSING CEREMONY**
Liberty AB

The American Rhinologic Society (ARS) is accredited by the Accreditation Council for Continuing Medical Education to provide continuing medical education for physicians.

AMA PRA Statement

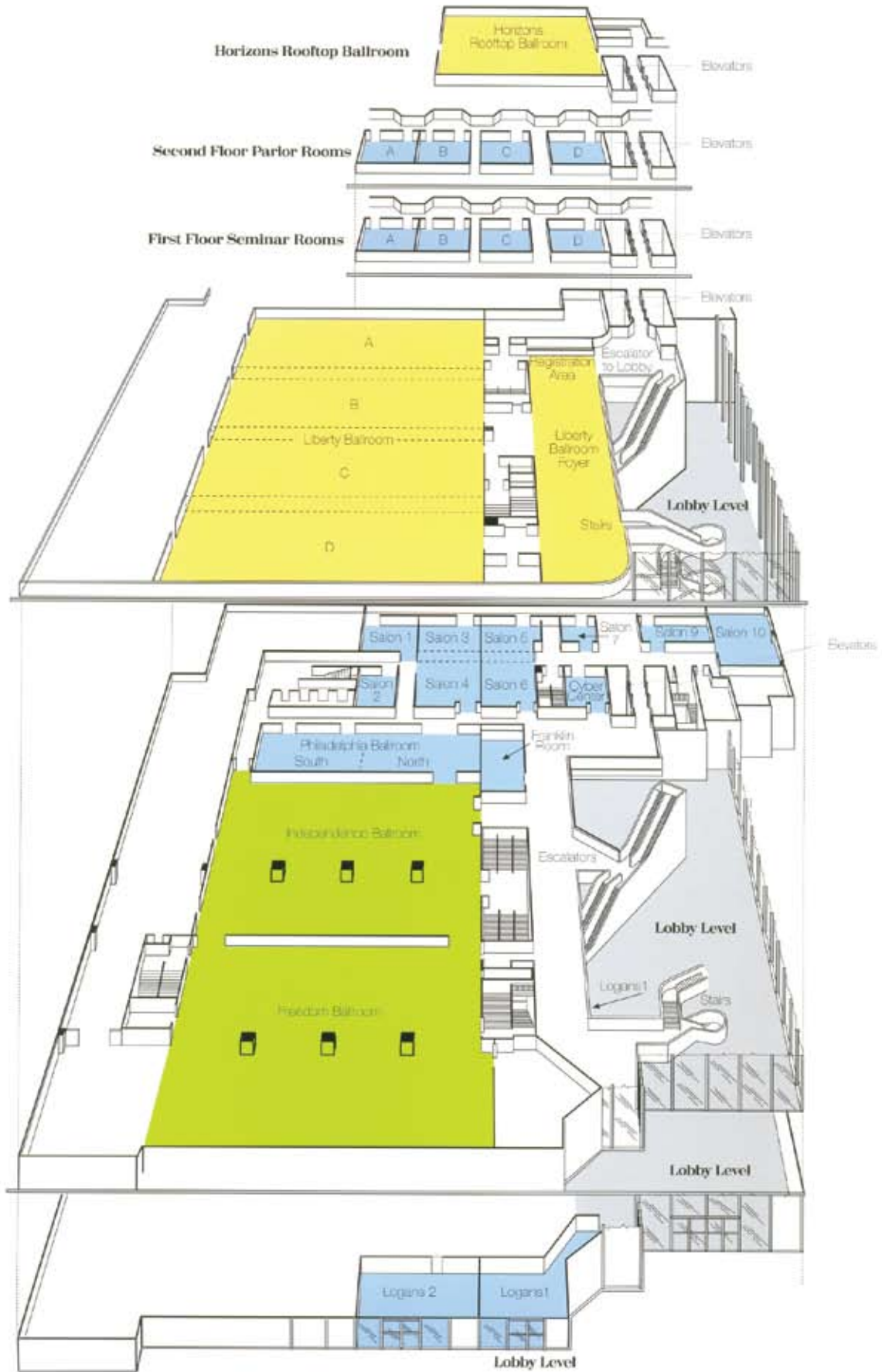
ARS designates this educational activity for a maximum of 11.75 *AMA PRA Category 1 Credit(s)*[™]. Physicians should only claim credit commensurate with the extent of their participation in the activity.

ARS sessions include:

- ARS Meeting Papers
Thursday, Friday & Saturday, 10:30–12:30
- ARS Meeting Papers Sunday, 10:30–12:20
- Mini Seminar Thursday, 2:35–4:00
- Mini Seminar Saturday, 1:30–3:00



Hotel Floor Plan



Society Board & Committee Meetings

WEDNESDAY, APRIL 15

- 4:00–6:00pm **ARS Executive Committee Meeting**
Horizons Ballroom
- 5:30–6:30pm **ARS PAC Meeting**
Salon 3/4
- 6:30–9:30pm **ARS Board of Directors Meeting**
Horizons Ballroom

THURSDAY, APRIL 16

- 12:30–12:40pm **ARS Business Meeting**
Liberty Ballroom C

FRIDAY, APRIL 17

- 9:00–10:00am **ARS Education Committee Meeting**
Logans 1
Chair: Todd Kingdom
- 12:00–1:30pm **ISIAN Board Meeting**
Phillip's–Private Dining Room

SATURDAY, APRIL 18

- 7:00–8:00am **ARS Resident/Fellows Committee Meeting**
Logans 1
- 9:00–10:00am **ARS Fellowship Committee Meeting**
Logans 1
Chair: Todd Kingdom
- 12:00–1:30pm **IRS Board Meeting**
Phillip's–Private Dining Room

Rhinology Bowl

Rhinology World 2009 is proud to present the resident “Rhinology Bowl” as part the four day meeting. This interactive knowledge-bowl, “Jeopardy” style competition will feature resident teams from around the U.S. and the world, entered by some of the best Otorhinolaryngology Residency Programs.

Teams will consist of two (2) residents, with one alternate permitted. Only two residents per team will complete in any one match–no substitution will be allowed during a match round. Any post graduate year resident is allowed. An individual who has graduated from the residency program is not permitted to register. A residency program may enter more than one team.

The competition format consists of NCAA-March Madness-style brackets divided into regions. Questions will be multiple choice, covering “Medical and surgical management of all rhinology—from the tip of the nose through the skull base.”

Competition schedules will be posted onsite. Be sure to stop up to Horizons “Rooftop” Ballroom Thursday through Saturday to cheer on your favorite team! Dr. Kevin Welch (Rhinology World’s answer to Alex Trebek!) will be hosting, with some of our most distinguished faculty reading the questions. The Rhinology Bowl Championship will be held on Sunday at 12:00 Noon in Liberty Ballroom AB.

Cash prizes will be awarded to the winning teams:

- 1st Place: \$5000
- 2nd Place: \$3000
- 3rd Place: \$2000
- 4th Place: \$1000

Social Program

Welcome Reception

Thursday, April 16th • 6:30–8:30pm
Sheraton Philadelphia City Center Hotel (Conference Site)
Liberty Ballroom AB

All registered participants are invited to join together on Thursday for an evening of cocktails, hors d'oeuvres, and entertainment celebrating "historic Philadelphia." Spend time catching up with old colleagues and meet new friends while enjoying the sights and sounds of Philadelphia, the "birthplace of a nation." Ben Franklin will be on hand, as well as some other special guests. *(Included in Registration Fee.)*



Gala Banquet

Friday, April 17th • 6:45–10:45pm
National Constitution Center
525 Arch Street, Philadelphia, PA

This is sure to be the crowning social event of the meeting! Come enjoy a night of fine dining in a most unique setting—the Grand Hall Overlook at the National Constitution Center. The 60 foot high ceilings and breathtaking views will provide the perfect backdrop to highlight some of the important history of our nation. The gala, emceed by Nancy L. Snyderman, MD, will feature stirring musical performances by the Patti La Belle Choir and multi-media presentations. Guests will have the opportunity to visit Signer's Hall, a room featuring life-sized, bronze sculptures of the 39 signers of the United States Constitution—including Benjamin Franklin and George Washington. Museum exhibits will be open for viewing. Cocktail hour begins at 6:45 PM. Bus transportation will be provided from the Sheraton to the Constitution Center, departing at 6:15 PM from the 17th Street hotel exit. *(Tickets may be purchased at the meeting registration desk until Thursday, April 16, 5:00pm, subject to availability.)*



Best of Philadelphia

RESTAURANTS

Our local meeting organizers offer these suggestions:

- **David Kennedy:**
White Dog Café
3420 Sansom Street
215-386-9224
Eclectic, Organic
- **Jim Palmer:**
La Croix
The Rittenhouse Hotel
210 W. Rittenhouse Square
215-546-9000
Continental
- **Alex Chiu:**
Buddakan
325 Chestnut Street
215-574-9440
Asian Fusion
- **Noam Cohen:**
Capital Grille
1338 Chestnut Street
215-454-9588
Steakhouse

PHILLY CHEESESTEAKS

- **Jim's Steaks**
400 South Street
- **Pat's Steaks**
1237 E. Passyunk Avenue
- **Geno's Steaks**
1219 S. 9th Street

BEST BRUNCH

- **Sabrina's Cafe**
910 Christian Street
215-574-1599

SOUTH PHILLY ITALIAN

- **Ralph's Restaurant**
760 S. 9th Street
215-627-6011

SOUTH PHILLY STEAKHOUSE

- **Saloon Restaurant**
750 S. 7th Street
215-627-1811

BEST COOL MARKET/ GRAB A SANDWICH

- **Reading Terminal Market**
12th and Arch Streets

SIGHT-SEEING

- **Phila Trolley Tours**
215-389-TOUR
Big Bus Tours depart daily from
5th & Market Streets
- **Ride The Ducks**
877-887-8225

SPECIAL MUSEUMS

- **Barnes Museum**
French Impressionism
300 N Latch's Lane
Merion, PA 19066
610-667-0290
Reservations are required in advance
- **Mütter Museum**
Medical Specialties
The College of Physicians
19 S. 22nd Street
215-563-3737
- **Philadelphia Museum of Art**
26th St. & Ben Franklin Parkway
215-235-7469
- **Rodin Museum**
Sculpture
22nd St. & Ben Franklin Parkway
215-568-6026

FOR THE KIDS

- **Academy of Natural Sciences**
Ages 6–12
19th St. & Ben Franklin Parkway
215-299-1000
- **Franklin Institute**
Ages 6–15
222 N. 20th Street
215-448-1200
- **Independence Hall/Liberty Bell**
Ages 6+
Market St. between 5th & 6th Streets
- **Adventure Aquarium**
All ages,
Across the river, but worth the trip!
1 Aquarium Drive
Camden, New Jersey
856-365-3300
- **Please Touch Museum**
Ages 3–6+
Memorial Hall, Fairmount Park
4231 Avenue of the Republic
215-581-3181
- **Philadelphia Zoo**
All ages, America's First Zoo
Celebrating 150 years
3400 Girard Avenue, Philadelphia
215-243-1100

SHOPPING

- **Liberty Place**
1625 Chestnut Street
- **King of Prussia Mall**
160 North Gulf Road
King of Prussia, PA
More than 400 Stores
- **Macy's Department Store**
1300 Market Street
- **Walnut Street Shopping**
between 16th–20th Streets

ABSTRACT NUMBER: 1545

PREVALENCE AND SEVERITY OF ANOSMIA IN WORKERS EXPOSED TO THE WORLD TRADE CENTER SITE

Shaun Desai, BA, Richard Doty, PhD, Robin Herbert, MD, Kenneth Altman, MD, PhD

BACKGROUND: Following the terrorist attacks at the World Trade Center (WTC) on September 11, 2001, greater than 40,000 people were exposed to a mix of toxic and hazardous chemicals in the massive recovery effort. While a large portion of subjects developed chronic upper and lower respiratory symptoms, it is not known whether olfactory function was compromised, particularly since such compromise can be eclipsed by more prominent respiratory symptoms.

OBJECTIVE: To assess the prevalence and severity of anosmia in WTC-exposed subjects, and to compare these findings with severity of upper respiratory symptoms.

METHODS: The University of Pennsylvania Smell Identification Test (UPSIT) and the Sino-Nasal Outcomes Test (SNOT-20) were prospectively administered to patients presenting to the WTC Medical Monitoring and Treatment Program from April to July 2008.

RESULTS: One-hundred research subjects were recruited, of which 99 completed both UPSIT and SNOT-20 [72 men & 27 women; mean (SD) age = 48.0 (0.7)]. Mean UPSIT scores were 30.05 in the WTC-exposed group, compared to 35.94 in the control group (out of maximum score of 40; $p = 0.01$). As expected from other studies, age was inversely related to the UPSIT scores ($p = 0.003$). No meaningful association existed between UPSIT and SNOT-20 scores ($r = 0.20$; $p = 0.11$).

CONCLUSION: Subjects exposed to noxious chemicals and airborne particulates at Ground Zero exhibited a statistically-significant decrement of olfactory function. Such smell loss may have significant consequences for the first-responder group of police and firefighters who frequently rely on a sense of smell to identify public safety hazards.

ABSTRACT NUMBER: 1546

RHEOLOGIC PROPERTIES OF SINONASAL MUCUS IN PATIENTS WITH CHRONIC RHINOSINUSITIS

David Saito, MD, Steven Pletcher, MD, Anh Innes, MD, John Fahy, MD

BACKGROUND & OBJECTIVE: Mucociliary clearance is a critical aspect of sinonasal physiology. While ciliary function has been evaluated in patients with chronic rhinosinusitis, little is known about the rheologic properties of sinonasal mucus. The goal of the current study is to describe the rheologic properties of sinonasal mucus in patients with chronic rhinosinusitis and correlate these properties with disease severity.

STUDY DESIGN: Cross-sectional study.

METHODS: Twenty-three adult subjects with chronic rhinosinusitis underwent collection of sinonasal secretions. Samples were analyzed using the AR2000 cone and plate rheometer to determine the dynamic viscosity and elasticity across a range of oscillatory frequencies. The mucus clearance index (MCI) and cough clearance index (CCI) was calculated from these values and compared to measures of disease severity.

RESULTS: Mean dynamic elasticity and viscosity was calculated at both 1 Hz (78.24 ± 103.4 Pa and 22.09 ± 29.62 Pa respectively) and 10Hz (118.9 ± 155.5 Pa and 32.36 ± 45.58 Pa respectively). A greater Lund-McKay score correlated with higher values for all measures of viscoelasticity and predicted a worse MCI ($p = .02$) and CCI ($p = .04$). Higher SNOT-20 scores predicted a statistically significant increase in mucus elasticity and

viscosity. Mucus from patients with sinonasal polyps demonstrated a worse MCI (1.00 vs. 1.18, $p = .02$) and CCI (1.54 vs. 2.12, $p = .03$).

CONCLUSIONS: This study establishes the range of rheological properties of sinonasal mucus in patients with chronic rhinosinusitis and demonstrates an association between severity of sinus disease and rheologic properties of sinonasal secretions.

ABSTRACT NUMBER: 1549

RUBBER TUBE VERSUS SILICONE TUBE AT THE OSTEOTOMY SITE IN DACRYOCYSTORRHINOSTOMY

Shawky Elmorsy, MD, Hytham Fayk, MD

PURPOSE: To compare the efficacy of using rubber versus silicone tubes at the osteotomy of Dacryocystorhinostomy.

METHOD: 46 patients diagnosed with primary acquired nasolacrimal duct obstruction were assigned randomly to rubber, silicone or control group. The surgical procedures in the three groups were the same except that in patients of rubber and silicone groups, rubber or silicone tubes were placed at osteotomy opening and removed after 3 months. Transnasal Endoscopic findings were recorded at the completion of surgery and at 3 months, 6 months and 9 months after surgery for the 3 groups. A computer aided digitizer was used to calculate the surface area of the osteotomy site.

RESULTS: After removal of their tubes 3 patients in the rubber group had recurrent epiphora (78.0% success), one patient in silicone group (92.86% success) and 4 patients in control group (77.8% success). The average final surface area of the osteotomy opening of patients with rubber group at the end of follow up was (9.85 mm²) in the silicone group was (17.47mm²) whereas in the control group was (8.56mm²). Conclusion: Silicone tube more better than rubber one in maintaining effective larger osteotomy after Dacryocystorhinostomy. This can improve the long term success of the operation.

ABSTRACT NUMBER: 1550

TRANSNASAL ENDOSCOPIC RESECTION OF BENIGN TUMOURS EXTENDING TO PTERYGOPALATINE AND INFRATEMPORAL FOSSA

Shawky Elmorsy, MD, Yasser Khafagy, MD

INTRODUCTION: Endoscopic resection of nasal and sinus tumours extending beyond the limits of the nose and sinuses is one of the new frontiers of endoscopic sinus surgery. Tumour vascularity, inability of the surgeon to manipulate the tumour and uncertainty about the endoscopic anatomy are the major limitations for endoscopic resection. These limitations have been largely overcome by improvement in interventional radiology and the development of the endoscopic two surgeons technique.

PATIENTS AND METHODS: We present our surgical technique for resection of angiofibroma extending to pterygopalatine and infratemporal fossa in 5 cases by using two surgeons technique (Wormald and Robinson approach) with slight modifications.

RESULTS: Better control with no recurrence for 2 years follow up. MRI were performed 6 monthly postoperative.

CONCLUSION: the endoscopic two surgeons technique is not a conservative or less radical approach, but the principles of complete tumour resection should be applied. This technique also requires a high level of endoscopic skills, careful surgical planning and detailed knowledge of the anatomy.

ABSTRACT NUMBER: 1551

MANAGEMENT OF CSF RHINORRHEA; SEPTAL GRAFT AND MIDDLE TURBINATE ROTATIONAL FLAP TECHNIQUE.

Shawky Elmorsy, MD, Yasser Khafagy, MD

INTRODUCTION: Endoscopic management of CSF rhinorrhea has been reported as highly successful by several authors. Various techniques are used for site preparation, graft selection and graft stabilization. Endoscopic approach is highly effective and safe with minimal invasiveness.

PATIENTS AND METHODS: We presented our experience on using trans-nasal endoscopy for the repair of CSF rhinorrhea. Between 2000 and 2007 we observed 20 patients with spontaneous CSF rhinorrhea. Endoscopy allowed the localization and repair of the defect. Septal graft was inserted with the underlay technique (cartilage or bone) and supported with middle turbinate rotational flap. Surgical and gelfoam packing are then applied. Anterior nasal packing for 5 days.

RESULTS: Endoscopy was successful in 90% of patients at the first attempt and in 95% at the second approach. No major complications were encountered.

CONCLUSIONS: Septal graft and middle turbinate flap are easy to harvest and easy to be applied to the site of the leak. The endoscopic approach is effective and safe with minimal morbidity.

ABSTRACT NUMBER: 1554

ALLERGIC FUNGAL SINUSITIS (AFS): DETECTION OF FUNGAL DNA IN SINUS ASPIRATE USING PCR

Shawky Elmorsy, MD, Yasser Khafagy, MD, Mohamed Elnagar

OBJECTIVE: Aimed to compare the detection of fungi in sinus aspirate by culture and PCR assay and relate the presence of fungi in nasal sinus and type of fungal allergen causing the disease.

METHODS: In our study, 68 cases of allergic fungal sinusitis (AFS) were selected, fungal culture and PCR assay for universal fungal, *Aspergillus* and *Bipolaris* DNA. Measurement of *Aspergillus* specific IgE in sinus aspirate and serum total IgE were done. A control group (10 cases) was included.

RESULTS: Among the total number of AFS (68), only 42 cases give positive fungal growth with a percentage of 61.7% while among 10 control cases, only 3 cases give positive growth with a percentage of 30%. Dematiaceae family was the most common as it was isolated from 30 cases (71.4%). *Bipolaris* was the most common isolated species (18 cases) followed by *Curvularia* (11 cases) and *Alternaria* (1 case). The results of PCR assay assured the detection of fungal DNA in all cases of AFS group (68 cases) and in 4 cases of control group (40%). Ten patients were positive for *Aspergillus fumigatus* specific IgE (14.7%) out of 68 patients and the mean value was 11.32 ± 4.12 IU/ml which was significantly higher than the mean value of this specific IgE in our control group which was 0 IU/ml.

CONCLUSION: Detection of fungal DNA by PCR in nasal aspirate was superior to culture method. The presence of fungus is not essentially accompanied with allergic process.

ABSTRACT NUMBER: 1556

CHRONIC FUNGAL SINUSITIS: FUNGAL COLONIZATION OF PARANASAL SINUSES, EVALUATION OF ICAM-1 AND IL-8 AND STUDYING OF IMMUNOLOGICAL EFFECT OF LONG-TERM LOW-DOSE MACROLIDE THERAPY

Shawky Elmorsy, MD, Mohamed Elnagar

INTRODUCTION: Elevated concentrations of sICAM-1 in patients with chronic non allergic sinusitis pointed to its key role in the recruitment of neutrophils into the inflamed tissue. IL-8 transcripts were detected in 45% of chronic sinusitis RNAs by RT-PCR suggesting that IL-8 may contribute to neutrophil involvement in chronic sinusitis. Long-term low-dose macrolide therapy was first introduced for the treatment of diffuse panbronchiolitis in the 1980's. In the 1990's it was also shown to be an effective treatment for chronic sinusitis.

PATIENTS AND METHODS: In our study, one hundred and eight patients with chronic sinusitis who underwent sinus surgery were selected. Sinus aspirates were collected in sterile containers. A part of the aspirate was used for immunologic assay, the other part was cultured for mycologic growth. All patients were examined for the presence of characteristic fungal mucin of chronic allergic fungal sinusitis and this was confirmed later by measurement of total serum IgE. After culture, we have classified our cases into 3 groups: group I chronic non allergic fungal sinusitis (48), group II chronic allergic fungal sinusitis (14) and group III chronic sinusitis without fungal growth (46). A control group (11) was included.

RESULTS: The collection and culturing method results in culture positive for fungus in 62 (57.4%) of 108 patients. Chronic non allergic fungal sinusitis represented 48 cases (44.4%) with *Aspergillus fumigatus* (17) most prevalent followed by *Bipolaris* spp. (9), and *Aspergillus niger* (8). Chronic allergic fungal sinusitis was diagnosed in 14 cases (12.9%). The most prevalent was *Aspergillus fumigatus* (7) followed by *Aspergillus niger* (2), *Bipolaris* (2), and *Curvularia* (2). In our study, we have found a statistically increased IgE levels in group II compared to group I, group III and control group IV and there were non statistically significant difference among the later 3 groups compared to each other. There were statistically increased ICAM-1 and IL-8 in groups I, II and III compared to control group IV. There were non statistically significant differences among the first 3 groups compared to each other.

CONCLUSION: These results assured the role of these molecules in all types of sinusitis. We selected Erythromycin from macrolides to study its effect in chronic fungal sinusitis and after finishing treatment, the mean value of IL-8 and ICAM-1 decreased with a statistically significant value indicating the efficacy of this drug to affect the immunologic part of this disease.

ABSTRACT NUMBER: 1558

TREATMENT OF RECALCITRANT CHRONIC RHINOSINUSITIS WITH LONG-TERM, LOW-DOSE MACROLIDE ANTIBIOTICS

Anders Cervin, MD, Ben Wallwork, MD, Prof. Alan Mackay-Sim, Prof. William Coman

A hands on approach to select and treat the right chronic rhinosinusitis patients with low-dose, long-term macrolide antibiotics will be presented. Treatment strategy is based on the randomised controlled trial presented below and on personal experience over a decade. A double-blind, randomized, placebo-controlled clinical trial on 64 patients with chronic rhinosinusitis was conducted. Subjects received either 150 mg roxithromycin daily for 3 months or placebo. Outcome measures included the Sinonasal Outcome Test-20 (SNOT-20), measurements of peak nasal inspiratory flow, saccharine transit time, olfactory function, nasal endoscopic scoring, and nasal lavage assays for ninterleukin-8, fucose, and alpha2-macroglobulin. There were statistically significant improvements in SNOT-20 score, nasal endoscopy, saccharine transit time, and IL-8 levels in lavage fluid ($P < .05$) in the macrolide group. A correlation was noted between improved outcome measures and low IgE levels.

ABSTRACT NUMBER: 1561

TRYPTASE DOES NOT ALTER PARACELLULAR PERMEABILITY IN HUMAN AIRWAY EPITHELIAL CELLS

Eugene Chang, MD, John Lee, MD, Joseph Zabner, MD

INTRODUCTION: The epithelial membrane functions as a barrier against bacteria, viruses, and antigens. The paracellular pathway involves the movement from apical to basolateral between cells by disruption of the cell-cell adhesion complex. In allergic and inflammatory diseases such as allergic rhinitis and asthma mast cell levels are increased. Degranulation of mast cells releases tryptase, a protease whose effects in airway epithelia can induce bronchospasm, mucus secretion, vasodilation, and edema.

HYPOTHESIS: We hypothesize that tryptase increases paracellular permeability in human airway epithelia (HAE).

METHODS: We applied recombinant human tryptase (rhtryptase) on the apical and basolateral surface to primary HAE and measured changes in paracellular permeability during short (every minute) and longer (over hours) time courses. We then immunostained the cell membranes for occludins and claudins to observe for changes in the structure of the tight junctions after tryptase application.

RESULTS: Rhtryptase does not alter airway conductance over hours. We tested a range of concentrations that replicated reported tryptase levels found in physiologic concentrations in the nose and as high as levels reached in systemic mastocytosis. HAE conductance was measured every fifteen minutes over 24 hours. Even under high concentrations, rhtryptase did not alter transepithelial conductance. Rhtryptase does not affect paracellular permeability transiently over minutes. In order to investigate if tryptase application had a transient effect we used cystic fibrosis (CF) HAE studied under short circuit conditions. Resistance was measured every 50 seconds for 60 minutes. The application of rhtryptase (6mu/ml) did not alter transepithelial conductance and thereby paracellular permeability. Rhtryptase does not affect the structure of the tight junction. HAE were stained for two proteins, occludin and claudin, that are specific

to the tight junction of airway epithelial cells. After the application of rhtryptase (6mu/ml), HAE cells retained their normal architecture.

CONCLUSION: Our in vitro studies have conclusively shown that tryptase alone does not affect human airway epithelial permeability. One explanation could be that tryptase may not be the critical mediator in mast cell degranulation that alters the tight junction structure. Future tests of mast cell lysates in vitro and in vivo may answer this question.

ABSTRACT NUMBER: 1563

PROPHYLACTIC IV ANTIBIOTICS IN FESS: TRENDS AND ATTITUDES OF THE ARS MEMBERSHIP

Rakesh Chandra, MD, David Conley, MD, Robert Kern, MD

BACKGROUND: Use of antibiotic prophylaxis in otolaryngology-head and neck surgery is a practice that exhibits significant variation among practitioners, and trends vary by subspecialties within the field. The objective of the present study was to assess these habits among otolaryngologists with special interest or experience in FESS.

METHODS: Attendees of the 2008 Annual Meeting of the ARS were surveyed regarding practice patterns and attitudes concerning the use of prophylactic IV antibiotics in FESS.

RESULTS: Surveys were returned from 49 attendees, and within this sample, IV antibiotic prophylaxis was employed by 28 (57%) and was not in 21 (43%). Among those who utilized prophylaxis, only 2/28 (7%) did so because they felt there was strong evidence to support such a practice, while 26/28 (93%) used prophylactic antibiotics despite the opinion that there is no solid evidence in support of this. The most common antibiotic chosen empirically was a cephalosporin (25/28; 89%). There was no significant difference between those who did and did not employ prophylactic IV antibiotics with regard to number of years in practice or practice situation (full time academic, academic affiliated private, solo private, group private).

CONCLUSIONS: Opinion of the respondents suggests there is no solid evidence supporting the use of prophylactic IV antibiotics in FESS. Nonetheless, this practice is more common than not. Possible explanations for these observations are explored in the context of medicolegal factors and the present fiscal climate.

ABSTRACT NUMBER: 1564

POWERED ENDOSCOPIC DACRYOCYSTORHINOSTOMY WITH MUCOSAL FLAPS WITHOUT STENTING

Dr. Harvinder Singh, Dr. Rosalind Simon

OBJECTIVES: Dacryocystorhinostomy (DCR) is a procedure performed to drain the lacrimal sac in cases of nasolacrimal duct obstruction or in chronic dacryocystitis. It can be performed externally or endoscopically. The aim of this study is to describe powered endoscopic dacryocystorhinostomy with full sac exposure and primary mucosal anastomosis without stenting the lacrimal ostium and to report perioperative and follow-up results achieved with this procedure since April 2005.

STUDY DESIGN: Prospective, nonrandomized study.

METHODS: Thirty-four consecutive patients (27 Females and 7 Males; mean age 48.29y; range 18-74y) who presented to the DCR clinic with epiphora secondary to nasolacrimal duct obstruction and

recurrent infection were included in this study. All these patients underwent primary powered endoscopic DCR. A total of 39 procedures were performed using a standardized surgical technique. Post-operatively, symptom evaluation and endoscopic assessment of the newly created lacrimal ostium were done.

RESULTS: Thirty-three of the 39 DCR's were patent after a mean follow-up of 21.5 months, yielding a success rate of 84.6%. Patency was assessed by symptomatic evaluation and endoscopic visualization at each post-operative visit. Two patients had complications, one orbital fat exposure and the other secondary haemorrhage. All 6 failures were due to inadequate bone removal at the lacrimal ostium site with subsequent synechiae formation and stenosis.

CONCLUSION: Powered endoscopic DCR with mucosal flaps without stenting has a success rate comparable to that achieved with stents and external DCR.

ABSTRACT NUMBER: 1565

GUIDE-WIRE AUGMENTED ENDOSCOPIC FRONTAL SINUSOTOMY

Hamed Sajjadi, MD

Endoscopic Frontal sinus surgery remains the most difficult of all sinus operations. Mastering the endoscopic approach to the frontal recess remains a challenge and the margin of error is unforgiving. A new adjunctive method utilizing fiberoptic guide wire to safely find the nasofrontal recess and then performing the standard endoscopic nasofrontal sinusotomy has been used in 20 patients with excellent results. This method seems to augment the well know standard endoscopic frontal sinus surgery and provide an increased level of safety and efficiency while allowing the traditional approach to be completed with the guide wire in place.

ABSTRACT NUMBER: 1569

THE COMPARATIVE DISEASE BURDEN OF RHINOSINUSITIS

Neil Bhattacharyya, MD

OBJECTIVES: Determine the disease burden of sinusitis relative to other medical conditions.

METHODS: The National Health Interview Survey for the calendar years 1997-2006 adult sample was analyzed, extracting one-year prevalence data for the disease conditions: sinusitis, hayfever, peptic ulcer, acute asthma and chronic bronchitis. Disease burden data for emergency room visits, general and specialist visits, health-care spending and workdays lost were also extracted. The influence of each disease condition on disease burden variables was statistically determined. Comparisons among outcomes variables were conducted across disease conditions to determine their relative economic and healthcare impacts.

RESULTS: 313,982 adult patients were studied (mean age, 45.2 years). The one-year disease prevalences were: sinusitis (15.2%), hayfever (8.9%), ulcer (2.4%), acute asthma (3.8%) and chronic bronchitis (4.8%). Patients with sinusitis were significantly more likely to: visit the emergency room (33.3% versus 17.7%, $p<0.001$), spend greater than \$500/year on healthcare (50.0% versus 39.0%, $p<0.001$) and see a medical specialist (33.6% versus 22.1%, $p<0.001$), than those without sinusitis. Patients with sinusitis missed an average of 5.93 workdays

per 12 months versus 3.82 workdays for those without ($p<0.001$). The number of workdays lost with sinusitis was similar to that of acute asthma (6.10 workdays, $p>0.05$) and health-care spending with sinusitis was significantly greater than that of ulcer disease, acute asthma and hayfever ($p<0.004$).

CONCLUSIONS: Sinusitis imparts a significant disease burden both within and outside of the healthcare system that is comparable to or exceeds that of other conditions commonly thought to be more serious.

ABSTRACT NUMBER: 1571

CHANGED NASAL CAVITY AND PARANASAL SINUS AIRFLOW VELOCITY AND DISTRIBUTION AFTER TOTAL SINUSOTOMY: A COMPUTATIONAL FLUID DYNAMICS STUDY

Xu Geng, MD, Xong Xia, MD

BACKGROUND: This study aimed to investigate the difference of airflow velocity, trace, distribution, and air pressure, as well as the airflow exchange between the nasal cavity and paranasal sinus in a numerical simulation of nasal cavity pre and post of total sinus open according to the method of FESS.

METHODS: Computational Fluid Dynamics (CFD) techniques were applied to construct an anatomically and proportionally accurate three-dimensional nasal model based on a normal nasal CT scans. A virtual FESS intervention was performed numerically on the normal nasal model using Fluent software. Navier-Stokes and continuity equations were used to calculate and compare airflow, velocity, distribution and pressure in both the pre and post FESS models.

RESULTS: In the post-FESS model, there was an increase in airflow distribution in the area connecting the middle meatus and the surgically opened ethmoid, 19% increase during stable inhalation and 9% increase during stable Exhalation; flow velocity in the ostiomeatal complex was increased. The flow trace in the nasal vestibule, nasopharynx, common and inferior meatus were similar with the pre-FESS, the flow trace in the middle meatus were obviously changed, there were wide-ranging vortex in the maxillary, ethmoid and sphenoid sinuses following FESS. There was a gradual decrease in nasal resistance in the posterior ethmoid sinus region, the airflow exchange between the nasal cavity and paranasal were markedly increased following FESS, the maxillary sinus was at most.

CONCLUSION: The airflow velocity, trace, distribution, and air pressure were changed in the ostiomeatal complex following FESS, the airflow exchange between the nasal cavity and paranasal sinus were markedly increased, the maxillary sinus was at most.

ABSTRACT NUMBER: 1572

MASTOID BONE AS A NEW GRAFT MATERIAL IN RHINOPLASTY

Mahmoud Sadoughi, MD, Ali Kouhi, MD, Mehdi Bakhshaei, MD

INTRODUCTION: Management of some nasal deformity including saddle noses, low radix especially in the secondary rhinoplasty challenges the surgeon to provide both cosmetic and functional improvement. We describe a new technique for creation of a split mastoid bone to provide dorsal support while increasing tip projection in patients with substantial saddle nose deformities due to trauma or excessive surgical resection.

MATERIALS AND METHODS: In a Case series since 2004, sculptured lateral cortex of mastoid bone was used in 56 patients for dorsal nasal augmentation, smoothing dorsal nasal irregularities or augmentation of radix. Eighteen patients had been suffered overresection of osteocartilaginous nose structures during previous aesthetic nose surgeries while 38 cases were candidate of primary rhinoplasties (18 low radix and 20 saddle nose) due to structural deformity or trauma.

RESULTS: Fifty six consecutive patients (mean age: 25±6 year, female/male: 45/11) with postoperative follow-up from 6 to 49 months (mean: 23 months) met the study criteria. All cases resulted in an augmented, straightened nasal dorsum, increased tip projection and adjusted radix. The final results were satisfied throughout follow-up with no evidence of graft infection. Only in two cases the graft was displaced needing revision. The amount of graft absorption even 2 years after operation was acceptable.

CONCLUSIONS: This graft provides adequate autologous bone for large group of patients. Furthermore the donor site is in the field of an otolaryngologist task with low morbidity and camouflaged scar. We recommend overcorrection of the defect using additional bone graft considering some predictable future bone resorption.

ABSTRACT NUMBER: 1575

ENDOSCOPIC TRANSNASAL RESECTION OF MALIGNANT TUMOR IN THE PTERYGOPALATINE FOSSA

Dr. Satoru Kodama, Toshiaki Kawano, Masashi Suzuki

INTRODUCTION: Pterygopalatine fossa (PPF) is a difficult-to-access anatomic area and PPF tumors are uncommon entities. Structures contained within the PPF include the internal maxillary artery (IMA) and its branches, the maxillary division of the trigeminal nerve (V2), and the vidian nerve. Standard approaches to the PPF require open transmaxillary techniques that violate the anterior and posterior walls of the maxillary sinus. Here, we describe endoscopic transnasal resection of malignant tumor, ectopic esthesioneuroblastoma (ENB), in the PPF.

TECHNIQUES: Endoscopic medial maxillectomy was performed, and this allowed the transnasal approach to be performed up to the posterior wall of the maxillary sinus and the PPF with a wide working space under the 0o endoscope. The posterior wall of the maxillary sinus was drilled out with a diamond bur, and the tumor was identified in the PPF. The IMA supplying the tumor was clipped with a hemoclip and cut with the Harmonic Scarpel. The maxillary nerve (V2) was identified around the foramen rotundum and could be preserved. The vidian nerve and pterygopalatine ganglion were resected with the tumor. Moreover, the tumor in the PPF was successfully removed without complications.

SUMMARY AND CONCLUSION: Endoscopic transnasal approach could be successfully used for the complete removal of malignant tumors in the

PPF. Although PPF is a difficult-to-access anatomic area, the endoscopic transnasal approach improves access and visualization, and potential to reduce complications compared with open approach. The endoscopic transnasal approach might become the treatment of choice for malignant tumors in the PPF.

ABSTRACT NUMBER: 1578

CORRELATION BETWEEN OUTCOMES OF ENDOSCOPIC MANAGEMENT OF SINUGENIC FACIAL PAIN OR HEADACHE AND PREOPERATIVE COMPUTED TOMOGRAPHY IN RHINOSINUSITIS

Mohamed Askar, MD

OBJECTIVES: The objective was to prospectively evaluate the relationship between the results of functional endoscopic sinus surgery (FESS) for management of sinogenic facial pain / headache due to chronic rhinosinusitis and the preoperative computed tomography (CT) scans.

STUDY DESIGN: The results were analyzed according to both pre- and postoperative degree of severity of pain according to visual analogue score from 0-10.

METHODS: This study was performed on 30 patients presented with facial pain/ headache as the main symptom of refractory chronic sinusitis. CT scans were graded according to Lund-Mackay score. All patients were subjected to FESS then followed up for 8 months. The degree of improvement was obtained by comparing the pre- and postoperative pain visual analogue scores.

RESULTS: The final postoperative subjective assessment showed that FESS had improved the pain to variable degrees in 93.4 % of patients. The visual analogue and Lund-Mackay scores were reviewed and analyzed using correlation coefficient and t-test. Both scores failed to significantly correlate ($r = 0.12$, p .value > 0.05).

CONCLUSION: FESS is a worthwhile procedure for treatment of sinogenic facial pain/ headache secondary to chronic rhinosinusitis. However, patient-based responses of sinunasal pain symptoms fail to correlate with the extent of pathology seen in patient CT scan. The location of mucosal disease is frequently much more significant than the extent of the disease.

ABSTRACT NUMBER: 1580

PARANASAL SINUS DISEASE AND AIRWAY INFLAMMATION IN PREDNISONE-DEPENDENT ASTHMA

Dr. Bosco Lui, Dr. Doron Sommer, Dr. Parameswaran Nair

BACKGROUND: Asthma is commonly associated with chronic rhinosinusitis in Otolaryngology and Respiriology practices. Although the exact mechanism remains unclear, some proposed theories include bacterial seeding of lungs, reflex bronchospasm, and enhanced α -adrenergic blockade. Computed tomography (CT) offers superior sensitivity in detecting sinus abnormalities and extent of disease, particularly in patients with difficult-to-treat asthma. There are few reports using sinus CT to assess the relationship between sinus abnormalities and asthma.

METHODS: A retrospective survey of 15 prednisone-dependent asthmatic patients with respect to measures of airway inflammation, airflow limitation, and CT sinus scans. The pathological changes in the CT scans were scored using the Lund-Mackay and JAMA staging systems; and several paranasal bony anatomical variations were recorded. These CT sinus measures were in turn correlated with quantitative analysis of

expectorated sputum for eosinophilia, prednisone dose requirement, and spirometry (FEV1).

RESULTS: With respect to prednisone requirement, both JAMA and Lund-Mackay staging systems showed that greater sphenoidal mucosal disease was associated with increased prednisone dose requirements (OR 1.7, $p=0.05$; OR 1.6, $p=0.021$). Generally, both staging systems showed that specific sinus site involvement correlated with higher levels of sputum eosinophils; these include sphenoid, maxillary, ethmoid sinuses, and the osteomeatal complex. Finally, there appeared to be a limited role for sinus anatomy as a predictive factor in prednisone dependent asthma.

CONCLUSIONS: Sinus anatomy does not seem to play an important role in prednisone-dependent asthma. However, sinomucosal thickening appears to be an important predictor of prednisone requirement and severity of eosinophilic bronchitis.

ABSTRACT NUMBER: 1583

HEMODYNAMIC EFFECTS OF TOPICAL ADRENALINE IN NASAL SURGERY

Suja Sreedharan, MS, Kishore Prasad, MS, Madhusudan Upadya, MD, Waheeda Cherukattil, MS

OBJECTIVES: Optimal mucosal decongestion in nasal surgery is achieved by adrenaline nasal packing. Adrenaline, a powerful vasoconstrictor can have significant hemodynamic effects on the circulation. This study evaluates the hemodynamic effects of topical adrenaline under both local and general anesthesia when used prior to adrenaline infiltration in nasal surgery.

METHODS: The study group comprised of 90 subjects undergoing nasal surgeries in whom topical adrenaline of 1:30,000 (Group 1), 1:6,000 (Group 2) or 1:4,000 (Group 3) was used followed by sub-mucosal adrenaline infiltration. Each of these 3 groups had 20 patients under general anesthesia (GA) and 10 patients under local anesthesia (LA). Controls (40 patients 20 GA and 20 LA) were subjects undergoing ENT or head and neck surgeries where only adrenaline infiltration was done without prior nasal packing. Serial intra-operative heart rate, blood pressure and ECG monitoring was done and relevant changes were recorded. The field during surgery was subjectively assessed by the surgeon. The ANOVA method was used for statistical analysis.

RESULTS: It was observed that there were no statistically significant changes in heart rate, systolic and diastolic BP between the control and study groups after adrenaline nasal packing under both LA and GA. Similarly after adrenaline infiltration these three groups did not show statistically significant alteration in the parameters when compared to the control group. But adrenaline infiltration did cause significant changes in the hemodynamic parameters in both the control and study groups when compared to their own baselines.

CONCLUSION: Topical Adrenaline does not significantly affect the hemodynamic parameters when used as a vasoconstrictor agent in nasal surgery.

ABSTRACT NUMBER: 1585

CONSTRUCTION AND EFFECTIVENESS OF ENDOSCOPIC SINO-NASAL SURGERY MODEL

Joao Nogueira, MD, Aldo Stamm, PhD, Shirley Pignatari, PhD

INTRODUCTION & OBJECTIVES: Functional endoscopic sinus surgery is the “gold standard” for the treatment of many diseases. Long periods of training are necessary for the adequate learning of professionals. This process has been impaired in some places. Virtual simulators have been used with positive results. However virtual images and impossibility to use real instruments are disadvantages. Our study aims to: show the development of an endoscopic nasal surgery model; discuss the effectiveness in anatomical knowledge gain and present major advantages and disadvantages.

METHODS: We developed models used by 32 Otolaryngologists divided into 3 groups according to levels of experience. Scores were requested for consistency tissue color and identification of anatomical structures. The results were compared and analyzed statistically.

RESULTS: The mean score assigned by participants for consistency was 32. For the color the overall average was 36. The mean score for identification of anatomical structures was 94.

CONCLUSIONS: We presented an endoscopic nasal surgery model showing the steps of development. 82% of participants reported improvement in anatomical knowledge. The advantages are: use of instruments similar to the real and no involved biological hazards. The disadvantage was the single dissection at the nasal lateral wall.”

ABSTRACT NUMBER: 1588

SURGICAL STAGING OF ESTHESIONEUROBLASTOMA FOR ENDOSCOPIC-ASSISTED TRANSNASAL-CRANIECTOMY

Joao Nogueira, MD, Aldo Stamm, PhD, David, Kennedy, MD, Fernando Balieiro, MD

BACKGROUND: The goal of surgical treatment of patients with esthesioneuroblastomas (ENB) is total tumor removal including an adequate margin of normal surrounding tissue. The classical craniofacial approach has achieved time tested results despite significant morbidity. However, endoscopic technology, surgical techniques and concepts of endoscopic oncologic surgery have evolved in recent years. Endoscopic assisted transnasal-craniectomy (EATNC) allows resection of all cranial base structures that are related to the tumor with a margin of normal tissue (oncologic resection) and eliminates the need for frontal craniotomy and brain retraction, even in many cases with intracranial invasion.

OBJECTIVE: To re-evaluate the relevance of the Kadish staging system to endoscopic surgical approaches for ENB and discuss modifications appropriate for the endoscopic era in the light of experience with EATNC.

METHODS: Review of 10 cases of ENB treated endoscopically, including patients presenting with intradural extension.

RESULTS: According to the Kadish staging system, these would be classified as follows, two Stage A, four Stage B, four Stage C. All cases were treated exclusively with EATNC. Nine of the ten patients (90%) were free of disease 2 to 126 months after resection (average 55 months). The Kadish system did not provide guidance regarding appropriate surgical approach.

CONCLUSION: The limitations of the Kadish staging system of ENB have been recognized in prior publications. Those limitations are highlighted by the new surgical approaches now available. Based upon our experience we propose a surgical staging system which provides greater tumor stage precision and therapeutic guidance for surgeons performing EATNC.

ABSTRACT NUMBER: 1589

NOVEL “CROSS-OVER FLAP” TECHNIQUE FOR NASAL SEPTAL PERFORATIONS

Joao Nogueira, MD, Shirley Pignatari, PhD, Aldo Stamm, PhD

INTRODUCTION: A nasal septum perforation is a defect in any portion of the cartilaginous or bony septum with no overlying mucoperichondrium or mucoperiosteum on either side. In the perforation the mucosal edges epithelialize, preventing closure of the defect. Although some patients may be completely asymptomatic, symptoms arise from altered nasal laminar airflow, and they may be severely disturbing to the patient.

OBJECTIVE: The aim of this paper is to describe our surgical “cross-over” technique for the treatment of nasal septum perforations.

METHODS: We use nasal septum flaps that are crossed at the nasal septum perforation.

RESULTS: We used this novel technique in 5 patients. One patient presented an idiopathic anterior septum perforation and four had postoperative perforations. In four patients, the perforation was successfully closed with a follow-up of 6 months. One patient remained with the nasal septum perforation after the procedure.

CONCLUSION: We described this novel “cross-over” technique for the closure of nasal septum perforations. This technique is feasible and seems to be effective at the closure of nasal septum perforations. A larger series with a longer follow-up is being done in order to assure the technique efficacy.

ABSTRACT NUMBER: 1598

THE EFFECTS OF BIPOLAR RADIOFREQUENCY ABLATION ON SINONASAL MUCOSA IN A SHEEP MODEL

Laura Swibel Rosenthal, MD, Mark Zacharek, MD, Chad, Stone, MD, Michael Benninger, MD

OBJECTIVES: To determine the pattern of injury in the sinuses using a bipolar radiofrequency plasma process (BRFP) and evaluate healing.

METHODS: Based on prior experience using a rabbit model, three sheep underwent endoscopic sinus surgery. BRFP was applied to turbinate mucosa in three areas for 2, 4, or 6 seconds. After resection of the contralateral middle turbinate and ethmoidectomy, BRFP was applied to the lateral wall or lamina papyracea for 2 seconds. The ethmoid and turbinate specimens were resected en bloc during necropsy immediately for the first sheep and on post-operative day 14 for the second and third sheep.

RESULTS: BRFP resulted in immediate loss of surface respiratory epithelium and thermal-type injury to the underlying seromucinous glands. On post-operative day 14, the site demonstrated re-epithelialization with respiratory epithelium. The underlying seromucinous glands were replaced by mild fibrosis. There was a well-defined zone of injury, no larger than the device. Longer use did not result in a deeper injury. Rather, the depth of injury was dependent on the type of submucosal tissue. Cartilage acted as a barrier to injury. Underlying bone had reactive, regenerative change. There were no histologic changes in the orbit.

CONCLUSIONS: Sheep mucosa after BRFP shows a similar injury and healing pattern to rabbit mucosa. Sinus mucosa heals appropriately after BRFP. The depth of injury is well demarcated and dependent on the type of tissue injured. Based on this and the previous rabbit study, BRFP may be an additional surgical tool to consider in endoscopic sinus surgery.

ABSTRACT NUMBER: 1599

ENDOSCOPIC SEPTOPLASTY WITH POWERED INSTRUMENTS

Aderito De Sousa, MD, Aidmar Salas, MD, Minaret Sandra, MD

INTRODUCTION: The septoplasty is an the procedures well known and perform in the ENT practice. The endoscopic approach to the nasal septum and the treatment of estructural pathology of this through powered instruments constitute a useful tool to treat back and attical deviations with more precision, besides conserving improve the septal cartilaginose phatology.

METHODS: A prospective study was conducted in 141 patients undergoing septoplasty with powered instruments since january to june 2007, all patients consent participate in this study. The variables evaluated prior and after surgery were: changes in the severity of rhinosinusitis syntoms and rigid endoscopic, likewise postoperative complications. The test t was applicated, a p value <0,05 was regarded as statistically significant.

RESULTS: The change in the severity of rhinosinusitis syntoms after surgery decrease from 6,12 (preoperative) to 2,01 (postoperative)=p <0,05. 100% of the patients to manifest was content with the surgery outcome. About complications postoperatives was present in a 4,96% and was represent subnasal hematoma (n=4), septal perfoaration, <0,5 cms (n=2) andd epistaxis (n=1).

CONCLUSIONS: The endoscopic septoplasty through powered insturments offer a better corrections to back and attical septal deviation, with confortable recover, minor complications and important decrease of syntoms in the patient with crhonic rhinosinusitis refractory to medical treatment.

ABSTRACT NUMBER: 1600

A NEW MODEL FOR ANALYZING THE FLOW EFFECTS ON ELECTRICAL BARRIER OF NASAL EPITHELIUM

Masato Miwa, MD, Kensuke Watanabe

INTRODUCTION: The barrier function of nasal epithelium is critical to the host defense. Hemodynamic shear stresses have important roles in both the normal and pathophysiological conditions of the vascular endothelium. Airway epithelial cells are exposed to luminal shear stress generated by airflow. Recent data have shown that phasic motion like respiration is a key feature of airway physiology including the regulation of epithelial barrier function. The short-circuit technique on epithelial cells delivers a measured amount of current. Short circuit current (SCC) is an index of net electrogenic ion transport across epithelium. The measurement of SCC had been proved to be an important method for assessing the efficiency of the airway epithelium as an electrical barrier. The aim of this study is to develop a new model to evaluate the effect of sheer stress on the electrical barrier function of nasal mucosal epithelium.

METHODS: To stimulate the hemodynamic environment of the circulation and to examine the effect of various fluid shear stresses, we have developed a flow apparatus to subject primary cultured nasal epithelial cells excised from guinea pig to well-characterized shear. Short circuit currents (SCC) measurements were made in those cells by using our system before and after applying sheer stress.

RESULTS: The low levels of shear stresses enhanced airway epithelial electrical barrier function. On the other hand, higher levels of shear stresses down regulated the electrical barrier function.

CONCLUSION: We have shown in this study that our original model might be very useful for analyzing the effect of shear stress on the nasal epithelium. The data obtained from this model would contribute to understand the pathogenesis and therapy of the upper airway diseases with the rupture of the barrier function by pathological shear stresses.

ABSTRACT NUMBER: 1601

MANUKA HONEY: THE NEW TREATMENT FOR RECALCITRANT CHRONIC SINUS DISEASE

Andrew Thamboo, BSc, Andrea Thamboo, BPh, Dr. Carl Philpott, Dr. Amin Javier

BACKGROUND: Some patients continue to suffer from symptoms of sinusitis after maximal medical and surgical treatment for chronic rhinosinusitis (CRS) or allergic fungal rhinosinusitis (AFRS). Manuka honey has well-documented anti-microbial and anti-fungal properties and is currently being used by physicians across the world for a wide variety of medical problems.

OBJECTIVE: To determine the effectiveness of MEDIHONEY™ Anti-microbial Active Manuka Honey in patients who continue to suffer from CRS or AFRS resistant to conventional medical treatment after bilateral FESS and post operative maximal medical management.

METHODS: A randomized, double-blind, placebo-controlled, prospective study at a tertiary centre. Thirty-one patients with CRS and thirty-one patients with AFRS had one side irrigated with saline and the other side irrigated with a 50/50 mixture of honey and saline once a week for four weeks. A one grade improvement in endoscopic grading was considered significant and patients filled a SNOT-22 questionnaire to assess subjective nasal symptoms.

RESULTS: The patients with CRS showed an absence of mucopus discharge in a significant number of cases on the treated side ($p=0.03$). In the AFRS patients there was also a significant number of cases in whom the staging improved on the treatment side ($p=0.01$). The symptom scores however did not show a significant difference although the mean score in both groups was slightly lower after treatment.

CONCLUSION: Manuka Honey is an effective topical anti-microbial agent post-operatively among patients who continue to suffer from CRS and AFRS.

ABSTRACT NUMBER: 1604

ALLERGIC FUNGAL SINUSITIS—A NEW STAGING SYSTEM

Dr. Carl Philpott, Dr. Amin Javier

BACKGROUND: In 1997, Kupferberg et al described the endoscopic staging system for allergic fungal sinusitis (AFS). This allows 4 stages, 0-3 which is further qualified with A or B to indicate the presence of allergic mucin. It has been noted however that patients may show visual improvement on endoscopic examination, in response to treatment, and yet remain at the same stage.

OBJECTIVE: To introduce a new system that allows greater sensitivity for demonstrating changes in mucosal oedema and polyposis.

METHODS: A series of 50 patients with AFS who attended the St Paul's Sinus Centre in Vancouver were endoscopically staged at the clinic appointment. Photos were recorded of all the sinus cavities bilaterally.

These photos were then retrospectively staged using a new system: each sinus cavity (maxillary, ethmoid, frontal and sphenoid) has a scale of 0-9 with an extra point for the presence of allergic mucin. Thus each side of the nose has a maximum score of 40; a total of 80 for both sides. The staging is based on the old Kupferberg staging.

RESULTS: Restaging the patients showed a greater variety in the spectrum of mucosal disease than indicated by the old staging system and allowed for a more descriptive analysis of the current severity of their disease and its response or lack of to treatment.

CONCLUSION: Use of the new staging system provides greater information to the clinician seeing patients with allergic fungal sinusitis in determining their response to treatment and is also useful for research into new treatment regimes.

ABSTRACT NUMBER: 1605

ENDOSCOPIC MANAGEMENT OF SINO-NASAL TUMOURS: LONG-TERM RESULTS—THE ST PAUL'S EXPERIENCE

Dr. Carl Philpott, Dr. Amin Javier, Alia Dharamsi

OBJECTIVES: To demonstrate that computer-assisted endoscopic management of sino-nasal tumours yields excellent results in terms of preventing recurrence and minimizing significant morbidity and mortality.

METHODS: A retrospective chart review of patients who are being followed up for tumour recurrence or have undergone tumour removal between 2000 and 2008.

RESULTS: Inverted papillomas are the most numerous tumours managed endoscopically accounting for 40% of cases. Approximately 50% of these cases had undergone previous surgery in another centre where the tumour was either not recognized or the resection was incomplete. 30% of patients with inverted papillomas had a recurrence but only three required a revision procedure using an open approach; otherwise recurrences were successfully managed endoscopically. Other common benign tumours included osteomas (8%), haemangiomas (2%) and angiofibromas (2%). The most common malignancy was squamous cell carcinoma (7%) with all malignant tumours accounting for 17% of cases and, to date, none of the patients that were dealt with primarily at our centre have died of their sino-nasal tumour. Two patients that were initially managed elsewhere died of their disease.

CONCLUSIONS: Endoscopic management of sino-nasal tumours using computer navigation allows good control of the disease and avoids unnecessary morbidity associated with open procedures. Although there is a higher initial recurrence rate, these recurrences can be successfully managed endoscopically.

ABSTRACT NUMBER: 1606

THE EXPRESSION OF THE IMMUNOREGULATORY ENZYME INDOLEAMINE 2,3-DIOXYGENASE IN PATIENTS WITH NASAL POLYPS

Sanna Toppila-Salmi, MD, PhD, Mikko Lehtonen, MD

Indoleamine 2,3-dioxygenase (IDO), an enzyme involved in the catabolism of the essential amino acid tryptophan (trp), suppresses T cell activity and is up-regulated with various inflammatory stimuli. It is expressed broadly in cells, such as eosinophils, antigen presenting cells and epithelial cells. Although many hypotheses have been suggested, the pathogenesis of nasal polyps (NP) is still largely unknown. We sought to establish whether IDO expression is involved in the pathogenesis of NP. We analyzed immunohistochemically the expression of IDO in specimens of healthy nasal mucosa, NP, antrochoanal polyps (ACP), and maxillary sinus biopsies from healthy controls and patients with chronic rhinosinusitis (CRS) with or without NP diagnosis. IDO was expressed in sinonasal epithelial cells, leukocytes and intraepithelial glands. The epithelial expression of IDO was significantly lower in the nasal mucosa from healthy control subjects compared to patients with either eosinophilic NP, or with non-eosinophilic NP. The epithelial expression of IDO was significantly higher in maxillary sinus mucosa from patients with CRS without NP compared to patients with CRS with NP. Interestingly, the positivity of epithelial IDO 9 months after endoscopic sinus surgery (ESS) correlated with the appearance of nasal polyps in 5 years after ESS. Before performing ESS, only 13 % of patients had nasal polyps. 5 years after ESS, 31 % of patients reported that they had gotten NP diagnosis. Our results suggest that the induction of epithelial IDO might play a role in the pathogenesis of both eosinophilic and non-eosinophilic nasal polyposis. By reducing locally the essential amino acid, trp, epithelial IDO might suppress either the activation of inflammatory cells, or inhibit bacterial growth ("suppression by starvation"). In maxillary sinus mucosa, the differences in the positivity of epithelial IDO in groups CRS NP+ and CRS NP-, might reflect a distinct property of the sinus mucosa. It remains open, whether the expression of epithelial IDO is beneficial or detrimental for sinus mucosa. When observing the sinus specimens taken 9 months after ESS, the correlation between the positivity of epithelial IDO and the growth of NPs in 5 years, might reflect to reduced post-operative epithelial trp and thus abnormal epithelial healing among patients who developed NPs.

ABSTRACT NUMBER: 1607

COMPUTED TOMOGRAPHY FINDINGS IN SINONASAL WEGENER'S GRANULOMATOSIS

Pete Batra, MD, David Grindler, BA, Steven Cannady, MD

BACKGROUND: Wegener's granulomatosis (WG) is intimately associated with the sinonasal tract, with involvement reported in 85% of patients during the course of the disease process.

OBJECTIVES: The objective of the study was: (1) to describe Lund-Mackay (L-M) scores and patterns of neo-osteogenesis and bony erosion and (2) to analyze the impact of surgery on the CT findings of WG patients.

METHODS: Retrospective review was performed of 74 patients presenting with WG to a tertiary care referral center. CT analysis was performed and graded by two independent reviewers.

RESULTS: The mean age was 53 years with a male:female ratio of 0.6:1. The average Lund-Mackay score was 10.0. Neo-osteogenesis was

evident in 78% of the patients with overall average neo-osteogenesis score of 4.2. Bony erosion was noted on imaging in 62% of patients with overall average score for bony erosion of 2.0. Patients having undergone previous surgical intervention compared to no surgery had statistically significant elevation of overall L-M, bony erosion, and neo-osteogenesis scores (p value = 0.024, 0.0009, and 0.0015, respectively). Prior surgical intervention was significantly associated with an increased bone erosion and osteoneogenesis scores as compared with surgically naïve patients (p value = 0.013).

CONCLUSIONS: CT imaging in WG patients commonly demonstrated elevated L-M scores and evidence of bony erosion and osteoneogenesis. Furthermore, surgical manipulation in WG patients may lead to increased bony abnormalities and greater elevations of LM scores, possibly due to worsening vasculitis and/or inflammation. The presence of concurrent neo-osteogenesis and bony destruction of the paranasal sinus wall should raise clinical suspicion of WG.

ABSTRACT NUMBER: 1608

THE CALCIUM SENSING RECEPTOR IN SINONASAL EPITHELIUM: A MODULATOR OF CILIARY BEAT FREQUENCY?

Dawn Sharp, MD, Shaoyan Zhang, PhD, John Kostrzewa, MD, Brad Woodworth, MD

INTRODUCTION: Modulation of ciliary beat frequency (CBF) is complex, but is, in part, regulated by fluxes in intracellular calcium $[Ca^{2+}]_i$. Zinc and ATP can increase $[Ca^{2+}]_i$ and CBF in a low sodium (Na^+), high extracellular calcium $[Ca^{2+}]_e$ environment via activation of Ca^{2+} -permeable, non-selective, P2X receptor channels. Our prior studies have also demonstrated an increase in CBF under low Na^+ , high $[Ca^{2+}]_e$ conditions in the absence of zinc and ATP, although to a lesser extent. The calcium sensing receptor (CaSR) is a metabotropic receptor that responds to $[Ca^{2+}]_e$ by increasing $[Ca^{2+}]_i$ via inositol triphosphate (IP3) mediated release from intracellular stores. The present study investigates whether CaSR is present in sinonasal epithelium and whether CaSR is responsible for the $[Ca^{2+}]_e$ -mediated CBF amplification in a low Na^+ environment.

METHODS: CaSR was detected and localized in murine septal and human sinonasal cultures using RT-PCR and immunofluorescence. Cultures were bathed in graded concentrations of $[Ca^{2+}]_e$ (up to 10 mM) in a physiologic (140 mM) NaCl solution. CBF was captured and analyzed using high-speed digital video imaging. $[Ca^{2+}]_i$ levels were investigated using Fura-2 Ca^{2+} imaging.

RESULTS: CaSR was detected in murine and human cultures and localized to ciliated epithelial membranes. However, a graded increase in $[Ca^{2+}]_e$ in a normal Na^+ environment did not augment CBF. Furthermore, no increase in $[Ca^{2+}]_i$ signal was detected in the presence of $[Ca^{2+}]_e$.

CONCLUSIONS: CaSR is present on ciliated sinonasal epithelial cells, but $[Ca^{2+}]_e$ was unable to stimulate CBF via Ca^{2+} release from intracellular stores in a physiologic, normal Na^+ environment. CaSR function in sinonasal epithelium deserves further investigation.

ABSTRACT NUMBER: 1609

RADIOFREQUENCY COBLATION DECREASES BLOOD LOSS DURING ENDOSCOPIC SINONASAL AND SKULL BASE TUMOR REMOVAL.

John Kostrzewa, MD, Jumin Sunde, MS-3, Kristen Riley, MD, Bradford Woodworth, MD

OBJECTIVES: Minimizing bleeding during transnasal resection of sinonasal tumors is imperative for optimizing visualization and decreasing complications. The purpose of the present study was to determine whether radiofrequency coblation decreases blood loss during endoscopic tumor removal.

METHODS: A review of all sinonasal and skull base tumors treated with transnasal endoscopic techniques in 2008 was performed. Data collected included demographics, histopathology, operative technique, duration of procedure, intraoperative complications, and estimated blood loss (EBL). Videoendoscopy was available in all cases and edited to include the use of a microdebrider or coblation during the approach and/or initial debulking portion of the procedure. All videos were reviewed by the authors and scored using the 11-point Wormald Surgical Field Grading Scale.

RESULTS: Twenty-one patients with sinonasal or skull base tumors treated with transnasal endoscopic resection were identified. Average age was 48.6 years (8-80). The coblation device was used during the initial approach and/or debulking portion of the procedure in 7 cases. Sinus and skull base tumors included were esthesioneuroblastoma (n=6), squamous cell carcinoma (n=2), adenocarcinoma (n=2), inverted papilloma (n=2), intracranial dermoid (n=2), melanoma (n=2), adenoid cystic carcinoma (n=1), juvenile nasopharyngeal angiofibroma (n=1), and fibromyxosarcoma (n=1). There were no intraoperative complications. Use of the coblation device was associated with a significant decrease in all blood loss categories, including EBL (386 vs. 979 ml, $p=0.0012$), EBL divided by operative time (58 vs 164 ml/hr, $p=0.0001$), and Wormald Grade (2.92 vs 6.07, $p=0.0002$).

CONCLUSION: Radiofrequency coblation can significantly decrease blood loss during endoscopic sinonasal and skull base tumor removal and is a useful tool in the armamentarium of the endoscopic skull surgeon.

ABSTRACT NUMBER: 1610

ULTRASTRUCTURAL CILIARY CHANGES OF MAXILLARY SINUS MUCOSA FOLLOWING FUNCTIONAL ENDOSCOPIC SINUS SURGERY: AN IMAGE ANALYSIS QUANTITATIVE STUDY

Ahmed Atef, MD

This was a study of the effect of functional endoscopic sinus surgery (FESS) on the ciliary regeneration of maxillary sinus mucosa in patients with chronic maxillary sinusitis, using objective quantitative methods. Twenty specimens from the mucosa of both the superolateral wall and the ostium of the maxillary sinus were sampled during FESS and then six to 12 months later. They were light examined first by light microscopy and then by scanning electron microscopy in combination with image analysis software in order to study the cilia under higher magnification and to calculate proportion of the field that was ciliated. Samples were taken and studied at Cairo University hospital. This study showed that the maxillary sinus mucosa in chronic sinusitis is capable of regeneration and could return towards normal with the improvement of ventilation and drainage of the maxillary sinus following FESS. There were no significant changes in the degree of glandular hyperplasia, goblet cells or pathological glands after surgery.

ABSTRACT NUMBER: 1611

COMPARISON OF LARYNGEAL MASK WITH ENDOTRACHEAL TUBE

Ahmed Atef, MD, Ahmed Fawaz

BACKGROUND: The purpose of this study was to compare surgical conditions, including the amount of intraoperative bleeding as well as intraoperative blood pressure, during functional endoscopic sinus surgery (FESS) using flexible reinforced laryngeal mask airway (FRLMA) versus endotracheal tube (ETT) in maintaining controlled hypotension anesthesia induced by propofol-remifentanyl total i.v. anesthesia (TIVA).

METHODS: Sixty normotensive American Society of Anesthesiologists I-II adult patients undergoing FESS under controlled hypotension anesthesia caused by propofol-remifentanyl-TIVA were randomly assigned into two groups: group I, FRLMA; group II, ETT. Hemorrhage was measured and the visibility of the operative field was evaluated according to a six-point scale.

RESULTS & CONCLUSION: In summary, our results indicate that airway management using FRLMA during controlled hypotension anesthesia provided better surgical conditions in terms of quality of operative field and blood loss and allowed for convenient induced hypotension with low doses of remifentanyl during TIVA in patients undergoing FESS.

ABSTRACT NUMBER: 1612

BIOFILMS AND MUCOSAL HEALING IN POSTSURGICAL PATIENTS WITH CHRONIC RHINOSINUSITIS

Zi Zhang, MD, Demin Han, MD, PhD, Deyun Wang, MD

INTRODUCTION: There are considerable studies on biofilms in chronic rhinosinusitis. However, few studies have specifically looked at biofilm production in the sinus cavities after functional endoscopic sinus surgery. This study observed the presence of biofilms on postsurgical mucosa, scar tissue and adhesion.

METHODS: Patients were followed up for six months, after intraoperative mucosal samples were obtained for the confirmation of biofilm. According to endoscopic evaluation, the postsurgical edema, scar or adhesion of sinonasal mucosa were obtained. In order to evaluate the mucosal healing and biofilms simultaneously, samples were prepared for hematoxylin and eosin stains and standard scanning electron microscopy.

RESULTS: Twenty patients with biofilms were enrolled. Five patients showed no sign of infection in the postoperative study, so no samples were obtained. In the six patients who had adhesions in the nasal meatus, biofilms were identified in four of the scars and adhesions both under hematoxylin and eosin stains and standard scanning electron microscopy. In the nine patients with apparent mucosal edema, various degrees of ciliated columnar epithelial healing with lamina propria edema and dilated capillaries were observed, while no basement membrane thickness and mucous gland hyperplasia could be seen in the recovered mucosa. Moreover, five samples showed various configurations of biofilms. Scattered bacteria were also shown both under scanning electron microscopy and hematoxylin and eosin stains.

CONCLUSIONS: Biofilms could form on the postsurgical edema, scar and adhesion of sinonasal mucosa. Hematoxylin and eosin stain is an efficient way to identify apparent biofilms like plaque. Postsurgical mucosa has different structures.

ABSTRACT NUMBER: 1616

LONG TERM RESULTS OF SEPTAL-TURBINATE-SUTURE IN ENDOSCOPIC SINUS SURGERY

Mona Ashoor, MD, Gerhard Rettinger, MD, Kerstin Lindemann, MD, Joerg Lindemann, MD

INTRODUCTION: Synechia formation between the middle turbinate (MT) and the lateral nasal wall is a common postoperative complication in endoscopic sinus surgery (ESS) often leading to revision surgery. To keep the middle meatus open several procedures were described in order to medialize the MT. Long term results of these techniques are missing. Therefore, the purpose of the study was to evaluate the long term results of fixing the heads of the MT to the septum by means of a resorbable septal-turbinate-suture (STS) in ESS.

METHODS: 17 patients (10 males, 7 females) were included in the retrospective study. All patients underwent ESS with STS in addition with septoplasty because of chronic rhinosinusitis with (8) and without polyps (9). The median follow up was 81 months (range, 36 – 105 months). All the patients underwent nasal endoscopic examination. In a total 34 nasal cavities were examined. Additionally, rhinomanometry and olfaction test were performed.

RESULTS: According to the endoscopic findings, the MT was found in a central position in 10 nasal cavities (29%), medial in 24 (71%) and none lateral. Only 2 patients presented a synechia, one between MT and septum and one to lateral nasal wall. The middle meatus was bilaterally open in all patients. In 3 patients (18%) minimal recurrent polyps were found.

CONCLUSIONS: Synechia of the MT to the lateral nasal wall in ESS can be avoided by a resorbable suture between MT and septum. Our long term results showed that STS maintains the MT in a medial position with a free middle meatus without relevant synechia.

ABSTRACT NUMBER: 1619

MUCOCELE AND OSTEOMA OF FRONTAL SINUS: THE CLINIC AND HISTOPATHOLOGIC ANALYSIS OF COEXISTENCE

Prof. Mustafa Gerek

OBJECTIVES: The rhinologic and ophthalmologic signs and symptoms of mucocele and osteoma of the frontal sinus were investigated and histopathologic characteristics of the removed specimens were analyzed to find an answer of the etiology of their coexistence.

METHODS: Fifty-one patients diagnosed as having co-existing frontal sinus osteoma and mucocele. The patients were divided to three different groups according to their lesions and were underwent osteoplastic flap and/or endonasal endoscopic technique to remove the osteoma and mucocele from the frontal sinus. The specimens were evaluated with light microscopy and the symptoms and signs before and after the surgery were compared.

RESULTS: In our series, the presenting symptom and its duration showed a discrepancy; however, the frontal headache was the most common one. The patients in the first and second group had usually a long history of recurrent sinusitis and 11 patients had undergone sinus surgery but their complaints persist after the surgery. The ophthalmologic symptoms and signs had wide range as lid swelling, periocular pain, ocular motility problem with diplopia. Bacterial growth from frontoetmoid sinus mucocèles cultures were investigated in 22 cases

and only in one specimen had positive result for Klebsiella pneumonia. The histopathologic examination shows the osteoma with dense, mature, predominantly lamellar bone covered with hyperplastic columnar epithelial cells of mucocele and some cases shows wide and haphazardly interconnecting bone trabeculae that are predominantly rimmed by osteoblasts.

CONCLUSION: The association of paranasal sinus osteoma and intracranial mucocele extension is a rare entity and paranasal sinus osteoma is the primary pathology. Although osteoma is the primary pathology, unexpected enlargement of the osteoma might have been due to calcification of the mucocele.

ABSTRACT NUMBER: 1620

ENDOSCOPIC VERSUS OPEN APPROACHES IN TREATING HUGE LOCALLY ADVANCED ANGIOFIBROMAS

Hossam El Bosraty, Ahmed Atef, Ehab Abou Zeid, Mossad Abdelaziz

HYPOTHESIS & BACKGROUND: Juvenile nasopharyngeal angiofibromas (JNA) is combined vascular and fibrous neoplasm arising in the nasoptarynx of prepubertal and adolescent males. These tumors are usually managed surgically through open surgical approaches but in the recent year's interest endoscopic resection -particularly in small tumors -raised up but all the published data in the literature are descriptive data discussing technique of endoscopic resection of JNA but no comparative studies between this technique and the more established open approaches exist.

MATERIAL & METHODS: Retrospective chart analysis study was done evaluating a total of 42 male patients grouped into two groups (1) open surgical approach (2q patients) and (2) endoscopic approaches 13 patients. Comparative study between two groups was done as regard A local control parameters 2 Morbidity parameters.

RESULTS & CONCLUSION: endoscopic approach offers patients with huge locally advanced angiofi vomas less morbidity with equal or even better local control.

ABSTRACT NUMBER: 1623

CAN CT SCORE PREDICT SUCCESS IN PEDIATRIC ENDOSCOPIC SINUS SURGERY?

Hassan Arshad, MD, Hassan Ramadan, MD

INTRODUCTION: The risk factors for endoscopic sinus surgery (ESS) failure in children have not been well characterized. The purpose of this study was to determine if the pre-operative Lund-MacKay CT score could predict ESS failure in children.

METHODS: Retrospective review of 172 patients age 2-15 (mean, 9.57 years), all of whom had sinus CT scans. All patients had follow-up for at least 1 year. Success was defined as improvement of symptoms or cure at 1 year post-ESS.

RESULTS: Overall success rate was 78%. Patients undergoing successful and unsuccessful ESS had an average pre-operative CT score of 9 and 10, respectively. This was not statistically significant (p=0.108).

CONCLUSIONS: Pre-operative CT score can not reliably predict a successful outcome in children undergoing ESS.

ABSTRACT NUMBER: 1625

ENDOSCOPIC SURGERY FOR JUVENILE ANGIOFIBROMA (JA): INDICATIONS AND LIMITS

Sylvie Nadeau, Piero Nicolai, Andrea Bolzoni Villaret

INTRODUCTION: At present, endoscopic surgery is considered a viable option in the management of selected sinonasal benign and malignant tumors. The authors critically review their 14-year experience in endoscopic management of JA to better define indications and limits.

METHODS: From January 1994 to November 2008, 46 patients were treated after angiography and vascular embolization (87%). All patients were followed by endoscopic and MR examinations.

RESULTS: Lesions were classified according to Andrews et al. (1989): type I, n=5; type II, n=24; type IIIa, n=14; stage IIIb, n=3. Unilateral blood supply was detected in 39 (85%) cases. Feeding vessels from the internal carotid (ICA) artery were reported in 14 (30%) patients. Intraoperative blood loss ranged from 250 to 1300 mL (mean, 580 mL), and blood transfusion was required in 5 (11%) cases. Follow-up ranged from 6 to 173 months (mean, 65). In 4 (8.7%) cases suspicious residual disease was detected by MR. In one patient, a 1-cm persistence was endoscopically removed. because of slight progression. The other 3 lesions, all located into the roots of the pterygoid plates, are stable in size and under MR follow-up.

CONCLUSIONS: Endoscopic surgery is a safe approach in stage I-II JA. The improvement of surgical instrumentation and the experience acquired have contributed to expanding the indications to stage IIIa-b lesions unless the ICA is encased. Switching to an external approach may be necessary when critical areas (ICA, cavernous sinus, optic nerve) are involved in recurrent lesions.

ABSTRACT NUMBER: 1626

ENDOSCOPIC TRANSNASAL CRANIOTOMY (ETC) IN THE MANAGEMENT OF SELECTED SINO-NASAL MALIGNANCIES: SURGICAL TECHNIQUE AND MORBIDITY

Andrea Bolzoni Villaret, Piero Nicolai, Andrea Bizzone, Paolo Castelnuovo

INTRODUCTION: This study critically reviews endoscopic transnasal craniotomy (ETC) and in the management of selected sino-nasal malignancies.

METHODS: From April 1996 to October 2008, 182 patients affected by malignant tumors of the sino-nasal tract were treated by endoscopic resection at two referral University Hospitals. Starting from 2004, 60 patients underwent ETC, which extended antero-posteriorly from the frontal sinus to planum sphenoidale and latero-laterally from the nasal septum to the lamina papyracea (unilateral resection, N=27) or from papyracea to papyracea (bilateral resection, N=33). Whenever a lateral extension over the orbital roof, or involvement of the frontal sinus was detected, subfrontal or frontal craniotomy was performed. Duraplasty with a “3-layer” technique was carried out using fascia lata. All patients underwent a CT scan of the brain the day after surgery to rule out complications.

RESULTS: The most frequent histotypes were adenocarcinoma (57%) and olfactory neuroblastoma (22%). Thirty-one (77%) patients were previously untreated. The complication rate was 15% (cerebrospinal fluid leak in 8 cases and septic fever in 1). The mean hospitalization time was 11 days (range, 5-32). The dura was involved in 14 (23%) cases. Overall, 30 (50%) patients received adjuvant treatment. After a

mean follow-up of 17.5 months (range, 1-54), 58 (97%) patients had no evidence of disease.

CONCLUSIONS: ETC is a safe procedure with an acceptable complication rate, and allows wide resection of the dura, with a correct assessment of its involvement. The surgeon must be able to switch to an external approach whenever necessary.

ABSTRACT NUMBER: 1627

NASOPHARYNGEAL ENDOSCOPIC RESECTION (NER) IN THE MANAGEMENT OF SELECTED MALIGNANCIES: SURGICAL TECHNIQUE AND PRELIMINARY RESULTS

Andrea Bolzoni Villaret, Piero Nicolai, Andrea Bizzone, Paolo Castelnuovo

INTRODUCTION: This study evaluated the efficacy of endoscopic surgery in the management of selected malignant nasopharyngeal tumors (NPT). Three different types of nasopharyngeal endoscopic resections (NER) are described.

METHODS: From January 1997 to October 2008, 17 consecutive patients affected by NPT were treated by endoscopic resection in two referral University Hospitals. Five patients were previously untreated (3 adenoidcystic carcinoma, 1 adenocarcinoma, 1 undifferentiated sarcoma). Recurrent or persistent lesions were 9 carcinomas, 2 adenocarcinomas, and 1 melanoma. The extent of NER was classified as follows: type 1: limited to the postero-superior NP wall; type 2: superiorly extended to the sphenoid sinus; type 3: with lateral extension including the cartilaginous portion of the Eustachian tube and parapharyngeal space.

RESULTS: Type 1 NER was performed in 4 cases, type 2 in 6, and type 3 in 7. In case of resection of the Eustachian tube, trans-tympanic drainage was always positioned. No complications were observed. Mean hospitalization stay was 4 days (range, 1-7). The lesions were staged as follows: stage I, 10 (63%); stage II, 2 (12%); stage III, 3 (13%) and stage IV, 2 (12%). Postoperative adjuvant treatment was performed in 5 (29%) cases. Mean follow-up was 33 months (range, 1-129). Twelve (71%) patients are free of disease, 3 (17%) alive with disease, 2 (12%) dead of disease.

CONCLUSIONS: These preliminary results show that NER is a feasible surgical technique in the treatment of selected NPTs. Larger series of patients and a longer follow-up are needed.

ABSTRACT NUMBER: 1628

ALTERATIONS IN COMPLEMENT PATHWAY GENE AND PROTEIN EXPRESSION IN CHRONIC RHINOSINUSITIS

Rodney Schlosser, MD, Ryan Mulligan, Juan Varela, Carl Atkinson

INTRODUCTION: The complement cascade forms part of the initial innate response to pathogens in the airway. Complement activation is important in the maintenance of host homeostasis, but excessive and uncontrolled activation may lead to inflammation and disease. The role of the complement pathway in the innate response in chronic rhinosinusitis is poorly characterized.

METHODS: Sinus mucosa biopsies from the anterior ethmoid and middle meatus of patients with allergic fungal rhinosinusitis (AFRS), chronic rhinosinusitis without nasal polyps (CRSsNP) and controls was harvested and gene and protein expression of C3, factor B (fB), C5 and C7 complement proteins were analyzed using quantitative polymerase chain reaction and immunohistochemical techniques.

RESULTS: fB and C3 gene expression was increased 3-10 fold in both AFRS and CRSsNP compared to controls ($p < 0.05$). C7 expression was increased in AFRS, but decreased in CRSsNP ($p < 0.05$). C5 expression was not significantly different among groups. Immunohistochemistry studies demonstrated the presence of C3, fB and C5 on the mucosal surface and in sub-mucosa of both AFRS and CRSsNP, but not normal controls.

CONCLUSION: Both AFRS and CRSsNP display up regulation of the complement pathway, in particular the alternative pathway (Factor B) and common pathways (C3). Enhanced innate responses as demonstrated by alterations in complement components may play a pivotal role in the inflammatory response noted in CRS and provide potential therapeutic targets in the future.

ABSTRACT NUMBER: 1630

A PROSPECTIVE STUDY IDENTIFYING VARIATIONS IN PARANASAL SINUS ANATOMY & COMPLICATION RATES IN ENDOSCOPIC SINUS SURGERY

Kevin Welch, MD, Alexander Chiu, MD, Bert O'Malley, MD, James Palmer, MD

INTRODUCTION: Endoscopic Sinus Surgery (ESS) is a safe method of treating chronic rhinosinusitis. Retrospective reviews of complications resulting from ESS have been widely published. There are no prospective studies examining high risk anatomy and the rates of complications. Therefore, we devised a prospective study to identify high risk anatomy preoperatively in an effort to reduce intraoperative complications.

METHODS: Preoperative triplanar CT scans of consecutive patients were prospectively analyzed in order to identify high risk anatomy known to be associated with complications during ESS. ESS was performed in all patients. Frequency of anatomic variations were noted and intraoperative complications were recorded.

RESULTS: 161 patients with 375 high risk structures (2.32/patient) were identified. Anatomic dehiscences were noted in the following structures: carotid artery (6.2%), lamina papyracea (18.0%), optic nerves (13.7%), ethmoid roof (9.9%), and sphenoid roof (3.1%). The anterior ethmoid artery was pedicled in 24.8% of cases. An Onodi cell was present in 27.3% of cases. The skull base was asymmetric in 13.7% of cases and was classified as Keros II and Keros III in 46.6% and 6.8% of cases, respectively. The maxillary-to-ethmoid ratio was $>2:1$ in 7.5% of cases. There were a total of 2 complications (1.2% of cases), and no complication was due to a previously identified high risk anatomic structure.

CONCLUSIONS: Variations in paranasal sinus anatomy are common and are frequently encountered. The rate of complications during ESS is low. Complications due to variations in sinus anatomy can be minimized by identifying high risk anatomic structures preoperatively.

ABSTRACT NUMBER: 1631

SINUS CULTURE DIRECTED MANAGEMENT OF SINUSITIS IN A TERTIARY RHINOLOGY CENTRE

Dr. Carl Philpott, Miss Krista Genoway, Dr. Amin Javer

BACKGROUND: With recent concerns over the increasing prevalence of coagulase negative Staphylococcus aureus (CNSA) and in consideration of recent guidelines for antibiotic treatment of chronic rhinosinusitis, the potential pathogens yielded from nasal cultures before any treatment is commenced is increasingly important in preventing unnecessary use of antibiotics and encouraging appropriate prescriptions.

OBJECTIVES: To examine the yield of pathogens in a tertiary rhinology centre from 320 patients with chronic rhinosinusitis with particular reference to the prevalence of CNSA and current antibiotic regimes.

METHODS: A retrospective review of the microbiological log in the St Paul's Sinus Centre looking at the different pathogens yielded, the frequency of these pathogens and the implications for future practice.

RESULTS: The most common bacterial pathogen was Staphylococcus aureus (SA), accounting for 33% of cultured samples. Fungi, moulds and yeast were cultured in 15% of cases. Only one case of MRSA was found in a patient with cystic fibrosis.

CONCLUSION: MRSA does not appear to pose a significant source of morbidity for patients with sinusitis. Antibiotic therapy directed at specific culture results will help to reduce resistant strains of bacteria.

ABSTRACT NUMBER: 1633

MUCOSAL EXPRESSION OF NERVE GROWTH FACTOR AND BRAIN-DERIVED NEUROTROPHIC FACTOR IN CHRONIC RHINOSINUSITIS

Charles Coffey, MD, Ryan Mulligan, MS, Rodney Schlosser, MD

INTRODUCTION: Allergic rhinitis is characterized in part by hyperresponsiveness to non-specific stimuli, a phenomenon which reflects the fundamental role of nasal neural pathways in chronic airway inflammation. Neurotrophins may serve pivotal roles in mediating hyperresponsiveness in allergic airway disease, though the role of such neurogenic mediators in chronic rhinosinusitis (CRS) is not well understood. We examined the expression of two potent neurotrophins, nerve growth factor (NGF) and brain-derived neurotrophic factor (BDNF), in CRS.

METHODS: Inferior turbinate and sinus mucosa was obtained from CRS patients with and without nasal polyps (NP) and from non-allergic controls. ELISA was used for quantitative determination of tissue concentrations of NGF and BDNF.

RESULTS: 94 tissue samples from 48 patients were included. Mean concentration of NGF in sinus mucosa was significantly higher in CRS than controls. CRS without NP was associated with a 60% increase in sinus NGF over controls ($p < 0.05$), while CRS with NP was associated with a 140% increase ($p < 0.05$). Mean sinus NGF concentration was significantly elevated in allergic subjects compared to controls ($p < 0.01$). A similar trend was noted in subjects with non-allergic CRS, though this did not reach significance. Mean BDNF concentration was decreased

in CRS compared to controls, with the most significant decrease in patients with polyps ($p < 0.05$). Mean turbinate concentration of both NGF and BDNF were similar in controls and CRS.

CONCLUSION: Increased expression of NGF may contribute to neural hyperresponsiveness in CRS sinus mucosa, particularly those patients with NP and/or allergies. BDNF expression is decreased in CRS sinus mucosa. Alterations in neurogenic inflammation may contribute to the pathophysiology of CRS and provide alternative therapeutic targets.

ABSTRACT NUMBER: 1639

THE USE OF BIORESORBABLE STAPLES FOR MUCOPERICHONDRIAL FLAP COAPTATION IN SEPTOPLASTY

Thomas Tami, MD, Ron Kuppersmith, MD, James Atkins, MD

INTRODUCTION: During septoplasty surgery, the formation of dead space between the mucosal flaps must be minimized to prevent septal hematoma and promote healing. Historically, this has been achieved by utilizing techniques such as nasal packing or the continuous septal quilting suture. This study presents the first clinical results using a septal stapling device that utilizes bioresorbable staples to achieve mucoperichondrial flap coaptation during septoplasty.

METHODS: The septal stapler was used in 15 patients undergoing septoplasty surgery. The primary outcome measure was whether septal coaptation was accomplished. The extent of tissue reaction at the site of staple placement was also evaluated.

RESULTS: Septal coaptation was accomplished in all subjects with no septal hematoma formation. At one week follow-up, there was either no or minimal tissue reaction at the site of staple placement.

CONCLUSION: The use of bioresorbable staples appears to be a safe, efficient, and effective alternative to other methods used in septoplasty for mucoperichondrial flap coaptation.

ABSTRACT NUMBER: 1640

DECREASED EXPRESSION OF CONNEXIN (CX)26 AND 43 IN ALLERGIC NASAL EPITHELIUM

Huabin Li, Geng Xu

The aim of the present study was to elucidate whether Dermatofagoides pteronissinus (Der p) 1 affects the expression of connexin (Cx) 26 and 43, which are tight junction proteins that constitute the airway epithelium barrier, as well as their possible mechanisms of action. Expression of Cx26 and Cx43 was examined in nasal mucosa of 14 Der p1-sensitized allergic rhinitis (AR) patients. Primarily cultured nasal epithelial cells (NECs) and BEAS-2B cells were stimulated by Der p1, then Cx26, 43 and protease-activated receptors (PARs) 1-4 were investigated. Effects of glucocorticoids and PAR2 siRNA on Cxs expression were also evaluated. Expression of Cx26 and Cx43 was down regulated in AR patients compared to normal controls. Der p1 was found to suppress Cx26 and Cx43 production in cultured epithelial cells via PAR2 activation. Glucocorticoids and PAR2 siRNA were able to prevent the reductions of Cx26 and Cx43. The present results provide the first evidence that Cx26 and Cx43 are downregulated in Der p1-sensitized AR patients, and that airway epithelial cells utilize a PAR2-mediated signaling pathway to suppress gene expression of Cx26 and Cx43 in response to Der p1 challenge. Thus, targeting PAR2 or Cxs is capable of preventing allergic sensitization.

ABSTRACT NUMBER: 1641

ENDOSCOPIC TREATMENT OF INVERTED PAPILLOMA: A REPORT OF 109 CASES

Vittorio Sciarretta, MD, Giulia Tenti, MD, Paolo Farneti, MD, Ernesto Pasquini, MD

PURPOSE: In this study, the endoscopic management of an inverted papilloma (IP) of the nose and paranasal sinuses performed at our Institution is reviewed. Moreover, to help in the choice of the correct endoscopic procedure for the treatment of this lesion, a staging system with endoscopic surgical implications is reported.

METHODS: One hundred nine patients affected by an IP originating at the level of the lateral nasal wall or adjacent sinuses were surgically treated using an endoscopic technique at the ENT Department of Bologna University between January 1994 and July 2008.

RESULTS: The endoscopically treated patients had a mean follow-up of 55 months (12-112 months). Five cases of recurrence was observed in the patient treated endoscopically for his primary tumor (4.6%). In 5 cases (4,6%), the IP was associated with a malignancy.

CONCLUSIONS: In our study, the endoscopic approach showed itself to be a useful tool for the radical resection of an IP. This new surgical staging system may help the surgeon in choosing the correct endoscopic approach for treating an IP, owing to the wide variety of anatomical sites within the sinuses that could be involved by this neoplasm and the different surgical implications.

ABSTRACT NUMBER: 1642

CIGARETTE SMOKE EXTRACT STIMULATES INTERLEUKIN-8 PRODUCTION IN HUMAN SINUS EPITHELIUM VIA REACTIVE OXYGEN SPECIES

Rodney Schlosser, M.D., Richard Harvey, M.D., Ryan, Mulligan, M.S., Carl Atkinson, Ph.D.

BACKGROUND: Cigarette smoke exposure results in extensive inflammation in the upper airways. Free-radicals and reactive oxygen species (ROS) have been shown to be potent mediators of this inflammation. Superoxide dismutase (SOD) catalyzes ROS into less reactive metabolites.

METHODS: Human sinonasal epithelial cells (HSNECs) were isolated, maintained in culture and treated with varying concentrations of cigarette smoke extract (CSE) with or without SOD. Supernatants and cell lysates were examined for the pro-inflammatory cytokine interleukin-8 (IL-8). Sinus mucosal biopsies were also processed for immunohistochemical staining by 3,3'-diaminobenzidine (DAB) for the presence of reactive oxygen species (ROS).

RESULTS: CSE induces production of the pro-inflammatory cytokine IL-8 by HSNECs in a dose-dependent manner with 20% CSE resulting in a 2.5 fold increase in IL-8 both in cell lysates and secreted supernatant ($P < 0.05$). This IL-8 up-regulation can be suppressed by free SOD (100 $\mu\text{g}/\text{ml}$, $P < 0.05$). Modified DAB staining confirms the presence of ROS on the epithelial surface as well as in the sub-epithelial space of sinus mucosa.

CONCLUSION: Inflammation in the upper airway after cigarette smoke exposure is, in part, due to the presence of ROS. The ability to attenuate this inflammation with SOD could provide a therapeutic approach for individuals with cigarette smoke exposure or other inciting agents that lead to inflammation via free radical production.

ABSTRACT NUMBER: 1643

CLINICAL EXPERIENCE USING CANINE FOSSA ACCESS DURING TRANS-ANTRAL, ENDOSCOPICALLY GUIDED BALLOON DILATION OF THE OSTIOMEATAL COMPLEX (OMC)

Theodore Truitt, MD, James Atkins, MD, James Stankiewicz, MD, Thomas Tami, MD

INTRODUCTION: A new balloon dilatation device (FinESS™ Sinus Treatment; Entellus Medical, Inc.) is available to treat chronic rhinosinusitis (CRS) via a canine fossa (CF) puncture. Procedural outcomes are reported from a prospective study.

METHODS: Forty-three (43) subjects with CRS limited to the OMC were enrolled in a multi-center clinical study (BREATHE I). Each subject underwent unilateral or bilateral balloon dilation of the maxillary ostium and ethmoid infundibulum under trans-antral, endoscopic guidance via a CF access. Post-procedural outcome data was gathered at 1 week, 3 months, 6 months and 12 months.

RESULTS: Eighty (80) CF punctures were performed by 9 trained physician investigators. All subjects completed follow-up through 1 week. Follow-up evaluation at 3 months and 6 months has been completed by 39 and 30 subjects respectively. Seven subjects completed the end of study requirement of 12-month follow-up. No serious device or procedure-related adverse events have been reported. Facial numbness was reported as a mild adverse event in 1 subject and tooth numbness was reported in 2 subjects (3/80; 3.8%). One event was transient and spontaneously resolved without treatment. Two events remain ongoing. No other device-related complications have been reported. There were no mucosal wound infections related to the puncture site including oral antral fistula or abscess formation.

CONCLUSION: These results indicate that treatment of the OMC via canine fossa access and endoscopically-guided trans-antral balloon dilation can be safely performed.

ABSTRACT NUMBER: 1644

EARLY RESULTS FOR TRANS-ANTRAL BALLOON ANTROSTOMY UNDER LOCAL ANESTHESIA IN THE OFFICE

Theodore Truitt, MD, James Atkins, MD, James Stankiewicz, MD, Thomas Tami, MD

INTRODUCTION: Balloon dilatation of the maxillary sinus outflow tract is a promising treatment for chronic rhinosinusitis (CRS). Although most of these procedures are performed under general anesthesia, a new balloon-based technology (Entellus Medical, Inc.) is available to treat patients in an office setting under local anesthesia.

METHODS: Seven (7) subjects with CRS of the maxillary sinuses with or without anterior ethmoid disease were treated under local anesthesia without IV sedation in the office. Through a canine fossa access and using trans-antral endoscopic visualization, a balloon catheter was inserted into the ethmoid infundibulum and inflated to a maximum diameter of 5 millimeters. Subjects were monitored during the procedure, at discharge from the clinic, and at 1 week and 3-months post-procedure.

RESULTS: Four (4) unilateral and 3 bilateral procedures were successfully completed. Sino Nasal Outcome 20 (SNOT 20) scores were 2.79 +/- 0.78 at baseline and improved to 0.92 +/- 0.87 at 3-month follow-up. The

Wong-Baker FACES Pain Scale scores were 1.4 during the procedure and 1.1 at discharge. Six (6) subjects reported a pain score of 0, (No Hurt) at discharge. No device-related, procedural, or serious adverse events were reported. Four (4) subjects were able to return to normal activity in less than 24 hours and all subjects were back to normal activities within 48 hours.

CONCLUSION: These results indicate that endoscopically-guided trans-antral balloon dilatation of the ostiomeatal complex can be safely performed under local anesthesia in an office setting with minimal pain and rapid recovery.

ABSTRACT NUMBER: 1647

THE EFFECT OF TOPICAL INTRANASAL BUDESONIDE SALINE IRRIGATIONS ON SERUM AND URINARY CORTISOL LEVELS IN PATIENTS WITH RECURRENT POLYPOSIS FOLLOWING ENDOSCOPIC SINUS SURGERY

Kevin Welch, MD, Erica Thaler, MD, James Palmer, MD, Alexander Chiu, MD

INTRODUCTION: The delivery of topical intranasal corticosteroid sprays has traditionally been the primary method of treating recurrent nasal polyposis. An emerging treatment for polyposis is budesonide nasal irrigations. Delivered at concentrations nearly 100 times greater than found in prescription nasal sprays, there have been little studies on the effects of budesonide irrigation on the adrenal axis. Therefore, we investigated whether irrigation with budesonide solution was associated with any increase in serum cortisol and 24-hour urinary cortisol levels.

METHODS: Patients who previously had undergone ESS and were not taking prednisone for 3 months were prospectively enrolled in this study. Patients irrigated twice daily with 0.5mg/2mL budesonide mixed with 240 mL saline solution. Serum cortisol and 24-hour urinary cortisol were collected prior to drug administration and 6 weeks after continuous use.

RESULTS: Ten patients were enrolled in this study. The average serum cortisol and 24-hour urinary cortisol prior to drug administration were 9.8±5.4 mcg/dL and 28.1±15.0 mcg/24h, respectively. After 6 week follow-up, the average serum cortisol and 24-hour urinary cortisol were 13.5±3.2 mcg/dL and 16.5±5.6 mcg/24h, respectively. Normal ranges for serum cortisol and 24-hour urinary cortisol are 5-25 mcg/dL and 4-50 mcg/24h.

CONCLUSIONS: Irrigation with budesonide 0.5mg/2mL in 250 mL of saline solution does not result in increases of serum cortisol and 24-hour urinary cortisol levels. Based on this, we feel irrigation with budesonide solution is safe to perform in patients as an alternative to traditional aerosolized steroid sprays or systemic corticosteroids.

ABSTRACT NUMBER: 1650

REGULATION OF PROTON (H+) SECRETION OF FRESHLY EXCISED NASAL TISSUES

Do-Yeon Cho, MD, Horst Fischer, PhD, Beate Illek, PhD, Peter Hwang, MD

INTRODUCTION: The airway surface epithelium is lined with a protective layer of fluid called the airway surface liquid (ASL). Acidic luminal pH has been shown to inhibit ciliary beating and to cause loosening of the epithelium and detachment from the basement membrane. The purpose of this study is to measure acid secretion by freshly excised human nasal tissues and investigate its regulation.

METHODS: Human nasal tissue was collected during sinus surgery and grouped by condition: i) normal, ii) chronic rhinosinusitis (CRS) without asthma, and iii) CRS with asthma. We determined mucosal equilibrium pH values and rate of proton (H+) secretion for each tissue using the pH-stat technique. The pH of the mucosal solution was maintained at pH 8.0 (to increase the driving force for H+ secretion) and 10 μ M ZnCl₂ (blocks HVCN1 proton channel) was used to block H+ secretion.

RESULTS: CRS with asthma had an equilibrium pH 6.79 \pm 0.4 (n=3) above which tissues started to secrete H+ at a rate of 114 \pm 7.8 nmol \cdot min⁻¹ \cdot cm⁻². This rate was significantly higher compared to normal (63.3 \pm 7.1, n=4) and CRS without asthma (63.2 \pm 22.6, n=5). Mucosal addition of ZnCl₂ resulted in block of 51.8%, 42.5%, and 33.0%, respectively, of H+ secretion in the normal, CRS without asthma, and CRS with asthma, indicating a role of apical HVCN1 H+ channels in H+ secretion by these tissues.

CONCLUSION: Freshly excised human nasal epithelium secretes H+ into an alkaline ASL. Our data suggests that inflammatory processes in asthma activate H+ secretion by the nasal airway epithelium and acidify the ASL.

ABSTRACT NUMBER: 1652

WOUND HEALING MODEL OF NASAL MUCOSA IN A RAT

Roza Khalmuratova, Sea-Yueng Jeon, Dae Woo Kim

OBJECTIVES: Postoperative wound healing of nasal mucosa is a highly organized process. However, this process has not yet been fully understood. The study aimed to explore histomorphological changes in nasal mucosa of the rat after mechanical injury and establish wound healing model of nasal mucosa.

MATERIALS AND METHODS: Unilateral wound in nasal cavity was induced using the brushing technique in 4-week-old, Sprague-Dawley rats. Experimental rats were divided into 5 groups (n=7 for each group). Animals were sacrificed 1 hour, 2, 5, 14, and 28 days after injury. The histological sections were examined for inflammatory cell infiltration, goblet and ciliated cell formation in H&E staining. The subepithelial and epithelial thickness was measured and expressed as subepithelial thickness index (STI) and epithelial thickness index (ETI). Fibrosis was evaluated by subepithelial fibrosis index (SFI) in Masson's trichrome stained sections.

RESULTS: Respiratory epithelial discontinuity and hemorrhage were observed 1 hour after injury. On day 2, edematous subepithelium and infiltration of neutrophils could be found on injured sites. Day 5 was characterized by the infiltration of monocytes and granulation tissue. SFI and ETI values increased significantly at day 14. Goblet cells and ciliated cells began to regenerate from day 14, and restored to near normal at day 28.

CONCLUSION: Using mechanical injury, wound healing model of nasal mucosa was established in a rat. The regeneration of respiratory mucosa was completed on day 28 after injury

ABSTRACT NUMBER: 1653

SINUS IRRIGATION BOTTLES: A POTENTIAL SOURCE OF INFECTION?

Dr. Eun Hae Estelle Chang, Dr. Kevin Wong, Dr. Carl Philpott, Dr. Amin Javer

INTRODUCTION: Normal saline irrigation is an important component of the treatment of sinusitis. Sinus irrigation bottles are commonly utilized to perform this task. It is not uncommon for the irrigation solution to backflow out of the nasal cavity into the tubing of the irrigation bottle itself, potentially contaminating it.

OBJECTIVE: To determine if organisms responsible for sinusitis can be cultured from the tubing and the sinus irrigation bottles.

METHODS: A prospective study was performed. Twenty patients were given sinus irrigation bottles for a period of four weeks for the treatment of their sinusitis. All patients had endoscopically guided swabs taken directly from the middle meatus on the first visit prior to the initiation of the sinus bottle use. The bottles were then returned and cultured. Microbiology data was collected.

RESULTS: All twenty irrigation bottle tubing had positive cultures. There was a significant correlation between initial nasal cavity cultures and those from the sinus bottle tubing.

CONCLUSIONS: Sinus irrigation bottles are potential source of sinus re-infection. We recommend that patients change their irrigation bottles on a biweekly basis and clean them after each use. A sinus irrigation bottle without tubing and one that is not prone to nasal backwash may be an alternative option.

ABSTRACT NUMBER: 1655

EPIDEMIOLOGICAL FINDINGS OF CHRONIC RHINOSINUSITIS IN OUR POPULATION

Rafael Hijano, MD, Jordi Serra, MD, Francisco Crego, MD, Anabella Hernandez, MD

INTRODUCTION: Despite consensus documents which have established the definition of chronic rhinosinusitis (CRS) with and without polyps lately, the data regarding epidemiology remain short. The aim of this study is to identify individual and environmental risk factors by means of epidemiological data in order to increase the knowledge of the pathological process.

METHODS: A prospective data collection in an SPSS data base from April 2007-October 2008 was carried out. 124 patients were included according to the definition of CRS by the European Position Paper on Rhinosinusitis and Nasal Polyps (EP3OS). All patients were asked about their rhinological symptoms, as well as indicated on a visual analogic scale (VAS) how troublesome their symptoms of CRS were. An endoscopy, a CT scan and allergic tests were performed to all of them. It was taken into consideration whether they were suffering from asthma or aspirin intolerance.

RESULTS: 47 patients presented CRS without polyps and 77 were diagnosed from CRS with polyps (CRS-P). Those with CRS-P were older than those without polyps. Nasal obstruction was more associated with CRS-P, and it was more severe. Smell abnormalities were more frequent and worse in patients with CRS-P (p=0.00005). Furthermore, patients suffering from asthma had a more severe grade of smell abnormality (p=0.015).

CONCLUSIONS: The epidemiological knowledge of CRS will help us to establish accurately its actual incidence and to know the real natural history of the pathological process. Proper selection of population is fundamental when establishing clinical trials.

ABSTRACT NUMBER: 1658

RHINOTOPIC THERAPY FOR REFRACTORY CHRONIC RHINOSINUSITIS USING THE VIBRATING MESH NEBULIZER

Alan Shikani, MD, Karim Chahine, MD

INTRODUCTION: The vibrating mesh nebulizer (VMN) is a small portable device that is significantly faster and more efficient than conventional jet and ultrasonic nebulizers. It creates an aerosol mist by rapidly vibrating a mesh with hundreds of 4 to 8 microns holes, and allows a fast and uniform delivery of tiny aerosolized medication particles inside the sinuses. This study evaluates the effectiveness of VMN-nebulized antibiotics and corticosteroids, coupled with weekly nasal toilet (a method that we call: "rhinotopic therapy"), in patients with rhinosinusitis that is refractory to endoscopic sinus surgery.

METHODS: This is a prospective open-crossover clinical trial that included forty patients. Inclusion criteria were (1) previous endoscopic sinus surgery, (2) recurrent sinusitis symptoms despite patent sinus ostia (3) failure of oral antimicrobial treatment. All patients were treated with topically aerosolized corticosteroids, along with aerosolized antibiotics selected on the basis of culture-specific sensitivity. Treatment lasted 4 to 6 weeks and was self-administered, using a VMN, twice daily by the patients. In addition, weekly endoscopic sinus cleansing and biofilm removal was performed by the treating rhinologist, followed with direct installation of the topical antibiotic and corticosteroids preparations inside the sinus cavities.

RESULTS: The great majority of the patients showed significant improvement in sinusitis symptoms, endoscopic sinus appearance, and bacterial eradication. Less than 5% had persistent symptoms and/or required revision sinus surgery.

CONCLUSION: Rhinotopic therapy using the VMN is a well-tolerated and effective method for managing refractory chronic rhinosinusitis.

ABSTRACT NUMBER: 1663

CEREBROSPINAL FLUID RHINORRHOEA: NEW CLASSIFICATION AND GUIDELINES FOR ENDOSCOPIC MANAGEMENT

Prof. Reda Kamel, Prof. Alghohary Alghohary, Tarek Kandil, Consu Khaled Anbar, Ass P

BACKGROUND: Cerebrospinal fluid (CSF) rhinorrhoea is uncommon. It may be traumatic, developmental, pathological, or spontaneous. A lot of modalities were suggested to define the site of the leak prior to surgery. Different routes were suggested to approach the defect and many techniques were introduced for repair. Satisfactory results entail precise identification of the defective site, enough exposure of all the margins and proper repair.

PROSPECTIVE DESCRIPTIVE STUDY/AIM OF WORK: To present a new classification of cerebrospinal fluid rhinorrhoea based on the detailed site of the skull base defect and demonstrate how to utilize it in determining the best approach followed for repair.

PATIENTS AND METHODS: Fifty two cases of CSF leak having 58 skull base defects with or without meningocele or meningo-encephalocele were classified according to their sites. The approach followed to repair the defect was designed according to the exact site of the leak. These approaches included the endoscopic direct transnasal, transethmoid, axillary flap technique, transnasal transsphenoid, transpterygopalatine and external osteoplastic flap.

RESULTS: The transnasal endoscopic approach was useful to approach all sites except the lateral frontal sinus defects, where the external osteoplastic flap was mandatory. Direct transnasal approach was effective in anterior and posterior cribriform plate defects. Transnasal transethmoid approach was useful in anterior and posterior ethmoids leaks. The axillary flap technique was sufficient in medial frontal sinus and frontal recess lesions. Transnasal transsphenoid was efficient in central sphenoid sinus defects and transpterygopalatine fossa in lateral recess leaks. These different approaches offered enough exposure of the defect for repair and handling of any associated meningo-encephalocele and/or pathology. Primary closure of the defect was achieved in 92.7%.

CONCLUSION: Classification of cerebrospinal fluid rhinorrhoea according to the site of skull base defect helps select the most direct and least invasive approach with effective repair.

ABSTRACT NUMBER: 1664

EUSTACHIAN TUBE ENDOSCOPY: VALIDITY AND LIMITS

Stefano Millarelli, M.D., Claudio Maria Pianura, M.D., Gianluca Bellocchi, M.D

In the last 2 years we have performed Eustachian tube endoscopy in 440 patients who subsequently underwent ear surgery. We used this method to evaluate the Eustachian pathology that could cause problems for the subsequent ear surgery. We used a 2.7 mm flexible fiberoptic tube which allowed us to evaluate the morphology, the motility during swallowing, the presence of secretions and the presence of perieustachian pathology. In almost 80 patients we reached the tubaric isthmus but the size of the optic tube prevented further vision. In the cases of an absence of pathology we treated the ear otherwise we solved the nasal pathology before doing the ear surgery. The endoscopic evaluation is easy and quick and can be an important aid to prevent ear surgery failure. The objective is to reach the isthmus with a tiny instrument to analyze the ear from an internal point of view.

ABSTRACT NUMBER: 1665

DIFFERENT ENDOSCOPIC SURGERGICAL STRATEGIES IN THE TREATMENT OF JUVENILE NASOPHARYGEAL ANGIOFIBROMA—SHANGHAI EENT HOSPITAL' EXPERIENCE

Prof. DeHui Wang, XiCai Sun, MD, HuaPeng Yu, MD, Li Hu, MD

OBJECTIVE: The aim of this study is to present our management experience of Juvenile nasopharygeal angiofibroma (JNA).

METHODS: This is a retrospective observational study of patients with JNA treated in our department between January 2002 to January 2007. Fifty-eight patients were presented in this time period. According to the Radkowski staging system, there were 4 patients with Ia, 9 with Ib, 12 with IIa, 12 with IIb, 10 with IIc, 9 with IIIa, and 2 with IIIb. All patients were divided into two groups according to operative approach. The traditional group with 28 cases. The endoscopic group with 30 cases. Basically, three endoscopic approaches were adopted in relation to the site and extent of tumor. Strictly endoscopic approach (type I) was performed on patients with Ia-IIb. Whenever the lesion extended into infratemporal fossa, orbit, middle cranial fossa and cavernous sinus, the modified endonasal endoscopic Denker approach (type II) was used. If tumor was very large in infratemporal fossa, endoscopic-assistant approach (type III approach) was adopted. Preoperative embolization was performed on all patients with IIc+ stage.

RESULTS: With 12-69 months follow-up, Recurrent tumor was seen in 11 patients with traditional approaches (11/28). Meanwhile, with endo-

scopic approaches there were only 4 recurrence cases (4/30) ($p < 0.01$). No serious complication was observed except short-term nasal crusting.

CONCLUSION: With proper preoperative evaluation and embolization, majority of JNA can be successfully resected via different endoscopic approaches with low recurrence rate. In our department, the traditional approach was replaced by the endoscopic approach.

ABSTRACT NUMBER: 1669

COMPLICATIONS AND SEQUELAE OF FRACTURES INVOLVING THE SPHENOID SINUS

Joseph Sciarrino

BACKGROUND: The sphenoid sinus has important anatomic relationships with many skull base structures, including the carotid arteries and various cranial nerves. Craniofacial trauma may cause fractures involving the walls of the sphenoid sinus, resulting in injury of any of these important structures. The aim of this study was to determine the incidence and clinical course of complications resulting from sphenoid sinus fractures.

METHODS: 68 patients presented to our institution with fractures involving the sphenoid sinus between March 2005 and May 2008. Imaging and clinical data were available in 41 patients. Records were reviewed for fracture location, associated injuries, clinical symptoms, and clinical outcomes.

RESULTS: The mechanisms of injury in this series were falls (42.6%), motor vehicle collisions (23.8%), and motor vehicle versus pedestrian accidents (21.4%). 27 (65.8%) of patients had a fracture of the sphenoid sinus wall adjacent to the course of the carotid arteries. Only one patient had an associated carotid artery injury (pseudoaneurysm). 12 (28.6%) patients showed evidence of fracture involving the optic canal, with 3 showing evidence of traumatic optic neuropathy. 3 (7.1%) patients showed evidence of CSF leak originating from the sphenoid sinus.

CONCLUSION: The literature contains little information regarding the evaluation and treatment of complications associated with sphenoid sinus fractures. Based on this study, a small proportion of patients with sphenoid sinus fractures may have injury to surrounding structures. Optic nerve injuries and CSF leaks are more common than carotid artery injuries. The information presented will help to direct optimal evaluation and treatment for patients with sphenoid sinus fractures.

ABSTRACT NUMBER: 1670

EPSTEIN-BARR VIRUS–MILD ACQUIRED IMMUNE DEFICIENCY SYNDROME IN SINUSITIS, IMPLICATIONS FOR TREATMENT OF BIOLOGIC CHRONIC FATIGUE SYNDROME

Paul Toffel, M.D., Paul Phail, B.Sc., Joshua Christensen, B.Sc.

BACKGROUND: Recent studies have reported on and investigated association of chronic fatigue syndrome with chronic rhinosinusitis (CRS). These studies have noted the association of chronic fatigue with CRS but have not postulated a unifying theory of causation. They have noted that functional endoscopic sinus surgery (FESS) in chronic rhinosinusitis patients with this associated co-morbidity could result in improved quality of life. We reported in 2002 (American Journal of Rhinology 16, 291-295, 2002) that FESS has remarkably improved the treatment of chronic rhinosinusitis patients. Most experienced practitioners achieve reported success rates of 85-95% among their surgical patients. However, the 5-15% refractory patients reported by all rhinologic surgeons

leaves a perplexing group, who, despite appropriate mechanical corrections, continue to experience debilitating rhinosinusitis episodes requiring repeated extensive medical therapy. In our experience, these patients have also reported the consistent co-morbidity of chronic fatigue.

METHODS: Recent studies have indicated that immune mechanisms may be altered in sinusitis patients. After years of observation, we found that these difficult patients may suffer from a common thread of significant partial immunocompromise. Drawing on military experience of treating immune-immature populations prone to Epstein-Barr Virus (EBV) infectious mononucleosis, and the consequent fatiguing post-mono-nucleosis syndrome, it was sought to screen refractory post-surgical sinusitis patients for this factor, and treat them with long-standing military protocols for the immune-immature populations dispatched to third-world combat conditions.

RESULTS: Treatment of refractory sinusitis patients with Epstein-Barr Virus - Mild Acquired Immune Deficiency Syndrome (EBV-MAIDS) consisted of periodic intramuscular serum immune globulin injections (immunomodulator therapy), after obtaining their thorough written informed consent, which produced substantial and sustainable improvement in patient's quality of life, including consistent improvement of chronic fatigue.

CONCLUSION: Detection of mild-to-moderate acquired immune deficiency among chronic rhinosinusitis patients can lead to successful treatment and an improved quality of life. This treatment has also resulted in overwhelming evidence of sustainable improvement of associated chronic fatigue syndrome in a cadre of 181 patients.

ABSTRACT NUMBER: 1671

APPLICATION OF GENETIC ASSOCIATION STUDIES TO THE STUDY OF CHRONIC RHINOSINUSITIS: A NEW ERA DAWNS

Martin Desrosiers, MD, Leandra Mfuno Endam, Msc, Abdelali Filali-Mouhim, PhD, Yohan Bossé, PhD

Chronic rhinosinusitis is common inflammatory disease of the paranasal sinuses which is frequently debilitating and may require multiple surgeries for management. Biopsy specimens taken at time of surgery for CRS have documented a Th2 type inflammatory infiltrate, with eosinophilic and neutrophilic infiltrate. This has widely been held to be secondary to a dysregulation of Th2 regulation; however, the role of bacteria in the development of disease has not been explained. Our previous work has implicated bacterial biofilms of *Staphylococcus Aureus* and *Pseudomonas Aeruginosa* as etiologic agents. Over the past four years, we have developed a population of patients with severe CRS for studies of genetic factors associated with CRS and probed it using either candidate gene based approaches or an innovative pooling-based genome wide association study technique. The results have been surprising as they demonstrate significant polymorphisms within several receptors, effector mechanisms and regulatory elements of the innate immune defence mechanisms. This suggests that disorders in recognition and defence against pathogens are involved in the development of CRS, and is in distinctly opposition to what has previously believed to be responsible for this disease. If true, these findings suggest that therapy be reassessed and possible new therapeutic avenues and diagnostic strategies developed for maximal prevention and efficacy of therapy. Given the close relationship between CRS and asthma, it is possible that these findings may also apply to asthma. In this presentation, we present a practical review of progress in this area, with an emphasis on practical applications of these findings.

ABSTRACT NUMBER: 1673

BONE REMOVAL DURING TRANSPHENOIDAL HYPOPHYSECTOMY USING AN ULTRASONIC ASPIRATOR

Jastin Antisdell, MD, Raj Sindwani, MD

INTRODUCTION: Otolaryngologists are becoming increasingly involved with transsphenoidal hypophysectomy (TSH). Exposure of the sella during TSH requires the controlled removal of bone at the sphenoid face and within the sinus itself. Traditionally this has been accomplished using curettes, ronguers, or high-speed drills; all of which risk injury to adjacent vital structures. Advances in ultrasonic aspirator (UA) technology now permit in situ bone emulsification which is respectful of nearby soft tissue. We explored the utility of this technology in TSH.

METHODS: Case-control study. Data were collected on 20 patients undergoing endonasal TSH performed by the same surgeons. The same technique was used in all cases except that in the study group (n=10) bone removal was performed using the UA, whereas conventional instrumentation (high-speed drill and rongeurs) was used in the control group (n=10).

RESULTS: The mean age for the UA group was 71 years (range 61-76), and 59.5 years (range 35-89 years) for the control group. The UA was effective in removing bone within the sphenoid and adequately uncovering the sella in all cases. No instances of dural or mucosal injury were noted even when the back of the UA tip made contact with these structures intentionally. There was no significant difference in complications or operative time between groups.

CONCLUSIONS: UA's are safe and efficacious for bone removal in confined spaces such as the sphenoid sinus. Due to their non-rotational ultrasonic design they are less likely to traumatize adjacent soft tissues, which is especially advantageous in endonasal transsphenoidal surgery.

ABSTRACT NUMBER: 1674

VENTRAL SKULL BASE EROSIONS AS RISK FACTORS FOR THE RECURRENCE OF ALLERGIC FUNGAL RHINOSINUSITIS AFTER ENDONASAL ENDOSCOPIC SURGERY

Prof. Omar El-banhawy, Dr. Mohammad El-Tuajjiry, Ali El Amri, Bander Elkahany

OBJECTIVE: To study Ventral skull base erosion (VSBE) as a risk factors for the recurrence of allergic fungal rhinosinusitis (AFRS) after endonasal endoscopic surgery (EES).

DESIGN AND SETTING: Prospective controlled multicenter study conducted during 5 years period in Kingdome of Saudi Arabia and Egypt.

METHODS: Fifty patients (age range, 5-47 years) met previously published criteria for AFRS were included. They were divided into 2 groups A & B. Group A (study group) included 25 patients with VSBE and group B (control group) without VSBE. All underwent EES after short period of oral systemic corticosteroids followed by postoperative nasal corticosteroid spray. Age, sex, presentation, preoperative serum IgE levels, radiological extent of disease, intraoperative evaluation and postoperative recurrence were analyzed in both groups.

RESULTS: Twenty patients (80 %) in group A showed clinical and radiological evidence of postoperative recurrences during the follow-up period (range from 2 to 60 months, average 16.24 months, and median 8 months). They were 16 Saudis and 4 Egyptians. Six patients (24 %

in group B showed evidence of recurrence during the same follow-up period (range from 18 to 60 months, average 39.8 months, and median 40 months). They were 4 Saudis and 2 Egyptians.

CONCLUSION: Patients of AFRS with VSBE showed a higher incidence of early recurrence after EES. However, further studies would be necessary before the results of these studies could be generalized.

ABSTRACT NUMBER: 1675

MOLECULAR CHARACTERIZATION OF THE POLYMICROBIAL FLORA IN CHRONIC RHINOSINUSITIS (CRS)

Marie-France Stephenson, M.D., Martin Desrosiers, MD, Leandra Mfuna, MSc, Scot Dowd

INTRODUCTION: Conventional sinus cultures have identified staphylococcus aureus and coagulase-negative staphylococcus as the main pathogens implicated in CRS. These results are questioned by recent studies of biofilms using molecular probes that implicate Haemophilus Influenzae instead.

OBJECTIVES: 1) Identify all bacterial species present on sinonasal mucosa by using molecular techniques and 2) Compare molecular and conventional culture results.

METHODS: Patients undergoing endoscopic sinus surgery for chronic sinusitis (CRS) were recruited prospectively. Conventional swab culture performed was at time of surgery and processed in the hospital laboratory. A simultaneous mucosal biopsy was taken for genetically-based bacterial identification and analyzed using the 16-S molecular amplification technique.

RESULTS: Standard cultures on 18 patients were positive in 82% of subjects, identifying an average of 1.4 isolates/sample (range 0-3). In contrast, molecular cultures were positive in 100%, yielding a mean of 10 isolates/specimen (range 1-20). Conventional cultures demonstrated mainly coagulase negative staphylococci (53%) and staphylococcus aureus (18%). Molecular cultures demonstrated a predominance of anaerobes, particularly propionibacterium, diaphorobacter, petidophilus and corynebacterium, with a 50% prevalence of S Aureus. Haemophilus Influenza was only identified in 17%.

CONCLUSION: S aureus continues to be implicated as a major pathogen in CRS; however Haemophilus does not appear to play a major role. Surprisingly, anaerobes are more frequently recovered in CRS than previously presumed and may play a role in pathogenesis. These results suggest that molecular cultures represent powerful and innovative tools for bacterial identification in CRS. Their clinical role still remains to be determined.

ABSTRACT NUMBER: 1676

POLYMORPHISMS IN THE NOS1 AND NOS1AP GENES ARE ASSOCIATED WITH SEVERE CHRONIC RHINOSINUSITIS

Yuan Zhang, Maste Leandra Endam, Msc, Luo Zhang, MD, PhD, Martin Desrosiers, MD

INTRODUCTION: Bacterial biofilms have been implicated in the pathogenesis of chronic rhinosinusitis (CRS). Nitric oxide (NO) plays a role in control of bacterial biofilms both by a direct bactericidal effect and interference with quorum sensing, thus modifications in genes regulating NO may contribute to the development of CRS. We wished to determine whether polymorphisms in genes regulating NO synthesis are associated with CRS.

METHODS: An established population of 206 individuals with severe CRS and 196 postal matched controls has previously been screened using a pooling genome wide associations study (pGWAS) to estimate allelic frequency. Genes regulating NO synthesis and with a maximal probability of association were identified. High probability SNPs from the NOS1 and NOS1AP were retained for individual genotyping using the Sequenom platform. PLINK software was used to determine association.

RESULTS: 18 SNPs were genotyped successfully with a genotype distribution in agreement with Hardy-Weinberg equilibrium. Two of four SNPs for NOS1 (rs1483757, p-value: 0.0053, Odds ratio (OR): 0.64; rs965828, p=0.029; OR: 0.69) and two of fourteen SNPs for NOS1AP (rs4657164, p= 0.0071, OR: 1.81, rs12061249, p=0.037, OR: 1.71) were significantly associated with CRS. Subgroup analysis for polyps-only, gender and presence of asthma did not influence strength of associations.

CONCLUSION: Polymorphisms in the NOS1 and NOS1AP genes are associated with severe CRS. These may lead to functional modifications in NO metabolism and may contribute to the development of CRS, potentially by facilitating biofilm development. These results suggest that NO merits further study and may represent a new target for therapy.

ABSTRACT NUMBER: 1677

EXPLORING LEGAL RISKS RELATED TO ENDOSCOPIC SINUS SURGERY

David Keschner, MD, JD

OBJECTIVE: To provide the endoscopic surgeon with an overview of legal risks related to functional endoscopic sinus surgery (FESS). The presentation will review relevant aspects of US tort law and examine specific risks related to FESS. We will review opportunities to reduce legal risks, from decision-making and documentation to what constitutes an adequate informed consent. At the conclusion, it is hoped that a participant will have a fuller understanding of the basics related to tort law, specific issues of liability related to FESS, and how an unfavorable outcome might be addressed.

ABSTRACT NUMBER: 1678

MORPHOLOGICAL VARIATION OF NASAL CAVITY EFFECT ON NASAL PATENCY– CFD SIMULATION WITH A TURBULENT MODEL

Heow Pueh Lee, PhD, Xiaobing Chen, Meng, Vincent Fook Hin Chong, MD, De Yun Wang, MD

INTRODUCTION: The human nasal airways constitute one of the most complex airflow domains in nature due to the complex internal geometry. The purpose of this study is to analyze the effects of morphological variation on the aerodynamic flow pattern compared with a normal nose by Computational Fluid Dynamics (CFD) tools.

METHODS: A 3-dimensional model of nasal cavity was constructed from the MRI scans of a healthy human subject, with the use of the software MIMICS 12.0. Thereafter high resolution 3D volume meshes comprising boundary layer effect and computational domain exterior to the nose were constructed. Nasal cavities corresponding to healthy, moderate and severe nasal obstructions were simulated by enlarging the inferior turbinate geometrically. Numerical simulations were carried out using FLUENTS for CFD simulations. The Reynolds averaged Navier-Stokes equations were solved for the turbulent flow with the model.

RESULTS: With inhalation flow, the contours of turbulent kinetic energy show that the locations of peak values move from the inferior to the superior parts for the healthy, moderate and severely obstructed noses. However, due to the turbinate expansion, with exhalation flow, there is less noticeable turbulence in those regions for all the three cases. With a large inhalation flow rate of 34.8 L/min, a maximum velocity of 5.69 m/s, 7.39 m/s and 11.01 m/s, are detected respectively for the healthy, moderately and severely obstructed noses. For the severely obstructed nose, the total pressure loss from the ambient inlet to the nasopharynx increases by more than three times and the maximum shear stress is two times that of the healthy one. Increased flow rate will result in a much larger turbulent kinetic energy distribution, especially for the severely obstructed nose.

CONCLUSION: Nasal obstruction with inferior turbinate enlargement generates turbulent flow patterns inside the nose cavity, especially in the superior part of the nose for inhalation. The existence of turbulence increases the velocity and shear stress distribution drastically, which needs to be carefully treated as it may affect the olfactory functions of the nose.

ABSTRACT NUMBER: 1682

THE VALIDITY OF PEAK NASAL INSPIRATORY FLOW

Dr. Kornkiat Snidvongs, Dr. Valin Rujanavej, Dr. Supinda Chusakul, Dr. Songklot Aejmaturapat

INTRODUCTION: The peak nasal inspiratory flow (PNIF) is used as an outcome measure in post-treatment clinical and research evaluation. It is simple and cost effective. The objectives of this study were to assess its validity and to define the cut point.

METHODS: The nasal patency of one hundred and forty subjects was measured by the PNIF and anterior rhinomanometry. All subjects' sino-nasal symptoms, instant sensation of nasal obstruction and nasal endoscopy finding were recorded. The sensitivity, specificity, likelihood ratio, positive predictive value, negative predictive value of the PNIF was analyzed. The cut point was defined from the Receiver Operating Characteristic curve analysis. The agreement between the PNIF and the stuffiness and between the PNIF and the presence of sino-nasal diseases were assessed.

RESULTS: With the cut point of 90 L/min, the sensitivity of the PNIF was 87.1. The specificity was 52.3. The negative predictive value was 93.4. The positive predictive value was 34.2. The likelihood ratio was 1.81. The mean of the PNIF in normal subjects was 97.11 + 31.15. The agreement between the PNIF and the instant sensation of nasal blockage was 0.14 and the agreement between the PNIF and the sino-nasal diseases was 0.09.

CONCLUSIONS: The PNIF, regarding the cut point of 90 L/min, revealed good sensitivity and high negative predictive value but it had low specificity and low positive predictive value. The nasal peak flow did not agree well with the subjects' symptoms of blockage and sino-nasal diseases.

ABSTRACT NUMBER: 1683

PULP NECROSIS AND SEPTORHINOPLASTY

Mehdi Bakhshaei, Vahid Poursadegh, Saeed Moradi, Rayhaneh Bonyadimanesh

INTRODUCTION: Bony manipulation near the nasal spine or maxillary crest trimming can predispose teeth to be injured during septorhinoplasty especially when there is an aberrant vascular supply or a high situated root apex in the premaxilla.

METHODS AND MATERIALS: A prospective study on 438 teeth (maxillary incisors and canines) suppose to be affected and 73 control teeth (mandibular lateral incisors) in 73 candidates of septorhinoplasty was carried out pre and post-operation to determine the frequency of pulp necrosis using electrical, heat and cold pulpal tests. Those with difficult intubation, history of root canal or orthodontic procedures, history of dental trauma, preoperation positive test were excluded from the study. Patients were followed-up 1 week, 1 month, 3 months and 6 months postoperatively and the results of tests were compared preoperation and four intervals postoperation.

RESULTS: Seventy three consecutive patients including 62 females and 11 males (mean age = 24 ± 6) met the study criteria. Septoplasty with anterior maxillary crest trimming and anterior nasal spine manipulation was performed for 63 and 52 cases, respectively. Only 10 cases underwent septoplasty without manipulation of maxillary crest or anterior nasal spine. Considering pulp testing no case of pulp necrosis was seen through 6 months follow up.

CONCLUSION: There is a few report of dental problem during septorhinoplasty; however it is unlikely cause serious dental complication such as pulp necrosis. An aberrant vascular supply, or highly situated root apex in the premaxilla, might be a good explanation for such a rare condition.

ABSTRACT NUMBER: 1685

SPLUNC1 EXPRESSION OF NASAL POLYP EPITHELIAL CELLS IN AIR-LIQUID INTERFACE CULTURE TREATED WITH IL-13

Te-Huei Yeh, MD, Wei-Chung Hsu, MD

INTRODUCTION: Short palate, lung, and nasal epithelium clone 1 (SPLUNC1) protein is an airway epithelial cell-derived molecule exerting host defense against pathogen. However, the function and regulation of SPLUNC1 in nasal epithelial cells are still unclear. Chronic rhinosinusitis with nasal polyps (CRSwNPs) is a disorder characterized by eosinophilic Th2 inflammation and frequent microbial colonization. The pathogenesis has been postulated as a disturbed mucosal immune response. We try to investigate the SPLUNC1 expression of nasal polyp epithelial cells in air-liquid interface (ALI) culture and after treating with Th2 inflammatory cytokines IL-13.

METHODS: Human nasal polyp epithelial cells isolated from patients with CRSwNPs were put in ALI culture for 21 days developing ciliary differentiation and assessed for expression of SPLUNC1 by microarray. Cultured cells were then incubated with human recombinant IL-13 for up to 7 days. The expression of SPLUNC1 was assessed by real-time polymerase chain reaction, and western blot analysis.

RESULTS: Ciliary differentiated nasal epithelial cells constitutively expressed high levels of SPLUNC1. Instead, SPLUNC1 is reduced under traditional submerged culture. SPLUNC1 is also significantly down-regulated after incubation with IL-13.

CONCLUSIONS: SPLUNC1 expression in cultured human nasal polyps' epithelial cells is increasing with the degree of mucociliary cell differentiation. An allergic milieu containing IL-13 may be detrimental to the host innate immune response in part through the inhibition of SPLUNC1 production. One mechanism contributing to microbial colonization and abnormal immune responses associated with CRSwNP appears to be a direct effect of the leukocyte-derived Th2 cytokines present in the sinonasal mucosa.

ABSTRACT NUMBER: 1693

TRAUMATIC OPTIC NEUROPATHY : ROLE OF BONE MARROW MONONUCLEAR STEM CELL IMPLANT?

Ashok Gupta, MS, Neelam Marwaha, MD, Ratti Sharma, MD, Amod Gupta, MS

INTRODUCTION\BACKGROUND: Traumatic optic neuropathy presents with complete or partial visual loss. Spontaneous visual improvement is reported in 20 to 40% patients; whereas 40-50% patients failed to have visual improvement even after steroids, optic nerve decompression or both. There are evidence that stem cells from blood or other neural tissues of the body trans-differentiate into bonafide neural stem cells. These neural stem cells are known to give rise to neurons, astrocytes and oligodendrocytes and hold great potential for brain repair and regeneration.

PURPOSE: The aim is to study the role of allograft stem cells for the regeneration of optic nerve in cases with traumatic optic neuropathy.

DESIGN: Randomized, prospective observational study.

MATERIAL & METHODS: A total number of 184 patients of traumatic optic neuropathy were treated with loading dose of 30 mg/kg methyl prednisolone, followed by 15 mg/kg every 6 hours for 3 days. 132 cases who failed to steroids were subjected to endoscopic optic nerve decompression. Out of patients who had failed to treatment, 36 were randomly selected to study the role of stem cells for the reversal of visual loss. 18 patients comprised the study group where after decompression of intracanalicular part of optic nerve, 0.2 ml of processed bone marrow stem cells with a dose of 1×10^8 MNCs/ml were injected in the transected ends of optic nerve and an equal number of age and sex matched patients acted as a control where normal saline was injected in the transected ends of optic nerve. All patients were followed at monthly interval for evaluation of visual acuity, funduscopy and field of vision.

RESULTS: Out of patients who had presented within one week of injury, 71.8% had improvement compared to 39.3% visual improvement amongst those with late presentation ($p < 0.05$). 85.7% patients with compression of optic nerve had visual improvement compared to 45.8% patients with laceration ($p < 0.05$). In spite of all treatment 40% patients fails to show visual improvement and were considered for stem cell therapy. 18 patients (38.9%) with bone marrow mononuclear stem cell implant 38.9% showed visual improvement as compared to those in the control group ($p < 0.05$). The post period was uneventful.

CONCLUSION: In the present study, we have successfully used the adult human neural cells for the restoration of damaged optic nerve fibres in 38.9% cases. This reversal of visual loss points to the promise of using this therapy to help human to regain their lost vision.

ABSTRACT NUMBER: 1696

RELATIONSHIP BETWEEN OLFACTORY ACUITY AND PEAK EXPIRATORY FLOW DURING POSTOPERATIVE FOLLOW-UP IN CHRONIC RHINOSINUSITIS ASSOCIATED WITH ASTHMA

Katsuhisa Ikeda, MD, Hidenori Yokoi, Toru Yao, Tetsuya Saitoh

The link between nasal and bronchial disease has been conducted extensively for chronic rhinosinusitis (CRS) and asthma. The concept of “united airway allergy” has become widely accepted in the recent decade. Histopathologic features of CRS and asthma largely overlap. Heterogenous eosinophilic infiltration and the resultant features of airway remodeling are observed in the mucosa of CRS and asthma. Based on the hypothesis that both upper and lower respiratory airway is the same etiology and that genetic factors play a critical role in the manifestation of sinonasal and bronchial inflammation, the pathological changes are expected to occur simultaneously, which is explained by epiphenomenon. Precise and simultaneous observation of functions of both upper and lower respiratory airway is required to clarify these reliable relationship. Peak expiratory flow (PEF) is known to provide reliable data of daily pulmonary function. In contrast, reliable and objective measures to evaluate the upper airway function have not yet been established. CRS associated with asthma is characterized by the initial symptom of anosmia, which can be explained by the early development of polypoid pathology in the olfactory cleft. We developed self-smell test as a reliable tool to monitor the postoperative recurrence in CRS associated with asthma. The present study was designed to evaluate the relationship between upper and lower airways during follow-up after ESS by monitoring sinonasal and pulmonary functions. Eleven patients showed the similar changes between both parameters, namely concomitant decrease or recovery in both olfaction and PEF. In contrast, the smell capability was not correlated with PEF in post-ESS course. There were no changes in both parameters after ESS. These findings suggest the direct connection by which CRS could worsen asthma.

ABSTRACT NUMBER: 1697

MASTOID BONE AS A NEW GRAFT MATERIAL IN RHINOPLASTY

Mahmoud Sadoughi, MD, Ali Kouhi, MD, Mehdi Bakhshaei, MD

INTRODUCTION: Management of some nasal deformity including saddle noses, low radix especially in the secondary rhinoplasty challenges the surgeon to provide both cosmetic and functional improvement. We describe a new technique for creation of a split mastoid bone to provide dorsal support while increasing tip projection in patients with substantial saddle nose deformities due to trauma or excessive surgical resection.

MATERIALS AND METHODS: In a Case series since 2004, sculptured lateral cortex of mastoid bone was used in 56 patients for dorsal nasal augmentation, smoothing dorsal nasal irregularities or augmentation of radix. Eighteen patients had been suffered overresection of osteocartilaginous nose structures during previous aesthetic nose surgeries while 38 cases were candidate of primary rhinoplasties (18 low radix and 20 saddle nose) due to structural deformity or trauma.

RESULTS: Fifty six consecutive patients (mean age: 25±6 year, female/male: 45/11) with postoperative follow-up from 6 to 49 months (mean: 23 months) met the study criteria. All cases resulted in an augmented, straightened nasal dorsum, increased tip projection and adjusted

radix. The final results were satisfied throughout follow-up with no evidence of graft infection. Only in two cases the graft was displaced needing revision. The amount of graft absorption even 2 years after operation was acceptable.

CONCLUSIONS: This graft provides adequate autologous bone for large group of patients. Furthermore the donor site is in the field of an otolaryngologist task with low morbidity and camouflaged scar. We recommend overcorrection of the defect using additional bone graft considering some predictable future bone resorption.

ABSTRACT NUMBER: 1700

SPHENOPALATINE ARTERY PSEUDOANEURYSM AFTER FESS: A LITERATURE REVIEW AND CASE REPORT

Dr. Raewyn Campbell

INTRODUCTION: Iatrogenic SPA pseudoaneurysm (PA) has only been reported after transsphenoidal surgery or maxillofacial surgery. The purpose of this paper is to present the first case report of a SPA PA after functional endoscopic sinus surgery (FESS). We review the pertinent anatomy, pathophysiology, preventative and management considerations in this rare complication.

METHOD: We present a case of a 76 year old lady with a SPA PA after FESS and a literature review of the relevant issues.

RESULTS: A 76 year old lady with myelodysplastic disorder presented with a six month history of unilateral facial pain, anosmia and post-nasal drainage which was unresponsive to antibiotics. CT scanning revealed complete opacification of her left frontal, ethmoidal and maxillary sinuses and partial opacification of her left sphenoid sinus. Due to concerns of fungal or neoplastic processes septoplasty, unilateral FESS and bilateral inferior turbinate reduction was recommended. However, surgery was abandoned after the septoplasty and FESS due to generalized bleeding. The patient was packed anteriorly and posteriorly. After 2 failed attempts to remove the packing, angiography confirmed a SPA PA which was immediately and successfully embolised 14 days post-operatively.

CONCLUSION: SPA anatomy varies widely and therefore impacts on surgical technique. SPA PA is a rare, but significant complication of FESS and should be considered in patients with posterior epistaxis during or after FESS or posterior nasal packing. The pathogenesis may include intra-operative trauma, infection or pressure necrosis from packing. Optimal management involves either ligation or embolisation depending on anatomical, patient and staff factors.

ABSTRACT NUMBER: 1701

DETECTION OF STAPHYLOCOCCUS AUREUS IN NASAL TISSUE WITH PEPTIDE NUCLEIC ACID–FLUORESCENCE IN SITU HYBRIDIZATION

Marie-Noëlle Corriveau, MD, Nan Zhang, MD, PhD, Gabriele Holtappels, Claus Bachert, MD, PhD

BACKGROUND: Staphylococcus aureus (SA) in nasal tissue can act as a simple colonizer, as an intraepithelial reservoir causing recurrent infection or as a specific immune modulator through superantigen mechanisms. The detection of SA in the tissue is often difficult. The aim of this study was to identify SA in the nasal tissue of healthy and of CRS patients using PNA-FISH technique and to correlate it to the presence of inflammatory cytokines.

METHODS: Nasal tissue was collected in 40 subjects (9 controls, 21 chronic rhinosinusitis with (CRSwNP) and 10 chronic rhinosinusitis without nasal polyps (CRSsNP). Tissue was homogenized; cytokines and specific IgE against SA enterotoxins (SAE-IgE) were measured using ELISA kits and the UNICAP system. The tissue was analysed for the presence of SA with the PNA-FISH technique (AdvanDX) and a semi quantitative scoring system was applied. Mann Whitney exact test was used for statistical analysis.

RESULTS: SA was detected within the mucosal tissue, more frequently in CRSwNP subjects vs. controls and CRSsNP; this only reached significance in the aspirin sensitive patient subgroup ($p = 0,01$). In CRSwNP patients, Th2 markers were increased according to their SAE-IgE status (ECP $p = 0,05$ and total IgE $p = 0,08$). However, there was no correlation between those markers and the presence of SA in the tissue.

CONCLUSION: This is the first study describing the detection of SA within nasal tissue using the PNA-FISH technique. This study showed that SA is more prevalent in the aspirin sensitive CRSwNP patients. The increase of inflammatory markers is dependent on an immune reaction of the local TH2 cells to SA superantigens, but does not correlate to the number of SA in the tissue.

ABSTRACT NUMBER: 1702

REPAIR OF FRONTAL SINUS CEREBROSPINAL FLUID LEAK: SELECTING A SURGICAL APPROACH

Jian-bo Shi, Feng-hong Chen, Rui Xu, Geng Xu

OBJECTIVES/HYPOTHESIS: To clarify the process for selecting the safest and most effective procedure for repair of frontal cerebrospinal fluid (CSF) leak.

STUDY DESIGN: A retrospective chart review.

METHODS: Analysis of prospectively collected data in fourteen patients treated with frontal sinus CSF leaks at our institutions from 2002 to 2008. CSF leaks originated immediately adjacent to or within the frontal recess or frontal sinus proper for inclusion in the study. The transnasal endoscopic approach or combined transfrontal endoscopic approach was used to repair the fistulas. Data collected included demographics, presenting signs and symptoms, site and size of defect, surgical approach, repair technique, and follow up.

RESULTS: Four defects originated in the frontal recess, while ten others involved the posterior table of frontal sinus. Nine patients were directly repaired and four were repaired with frontal sinusotomy using transnasal endoscopic approach, while the other one patient was repaired using combined approach. First attempt was successful in thirteen cases (93%). One patient (7%) had recurrence CSF leak one month after initial repair and was successful repaired at the second attempt. Two patients had complications. One developed left frontal lobe abscess requiring

paranasal drainage and obliteration. Another one developed frontal sinus obstructive mucocele requiring endoscopic frontal sinusotomy.

CONCLUSIONS: Most of frontal CSF rhinorrhea could be successfully repaired using transnasal endoscopic approach, but selecting the approach should considering the site and size of the fistula to improve the success rate and reduce the complication.

ABSTRACT NUMBER: 1706

CORRELATION BETWEEN SUBJECTIVE ASSESSMENT AND OBJECTIVE MEASUREMENT OF NASAL OBSTRUCTION

Gehua Zhang, MD, Yuan Li, MD, Ronald S. Fenton, MD, Philip Cole

OBJECTIVE: To investigate the correlation between subjective assessment from clinician and patients and the objective measurement from active posterior rhinomanometry and acoustic rhinometry.

METHODS: Clinician and patients' assessment of nasal patency was achieved by visual analogue scale (VAS). Objective measurement included active posterior rhinomanometry and acoustic rhinometry. The mean of clinician's assessment and patients' VAS was compared by using paired-samples t-test. The correlation between unilateral nasal airflow resistance and unilateral nasal airway volume, unilateral minimal cross section area, and also subjective assessment and objective measurement of nasal patency were analyzed by using Spearman correlation analysis in total patients.

RESULTS: In total of 316 patients, pre-decongestion and post-decongestion, unilateral nasal airflow resistance and unilateral nasal airway volume, unilateral minimal cross section area had significant negative correlation respectively ($P = 0,000$). The mean of clinician's assessment and patients' VAS had significant difference ($P < 0,001$) before and after decongestion. Clinician's assessment had significant positive correlation with patients' VAS, nasal airflow resistance, and significant negative correlation with nasal airway volume, minimal cross section area of nasal cavity before and after decongestion ($P = 0,000$). Patients' VAS had significant positive correlation with nasal airflow resistance, and significant negative correlation with nasal airway volume, minimal cross section area of nasal cavity before and after decongestion ($P = 0,000$). The correlation coefficients from clinician's assessment and objective measurements were greater than those from patients VAS and objective measurements.

CONCLUSIONS: The parameter of active posterior rhinomanometry had significant negative correlation with the parameters of acoustic rhinometry. Clinician assessment of nasal patency had significant positive correlation with patients' VAS; both of them had significant correlation with the parameters of rhinomanometry and acoustic rhinometry. Clinician's assessment is more objective and reliable to the parameters of objective measurement than patients' VAS.

ABSTRACT NUMBER: 1708

PREVALENCE OF METABOLIC BONE DISEASE IN CHRONIC RHINOSINUSITIS

Karthik Rajasekaran, BA, Abby Abelson, MD, Rahul Seth, MD, Pete Batra, MD

BACKGROUND: The treatment of chronic rhinosinusitis (CRS) with/without polyposis often requires chronic oral steroid treatment which can result in adverse skeletal effects, including osteoporosis and increased risk of fracture.

OBJECTIVE: The purpose of this study was to determine the prevalence of low bone mass (osteopenia) and osteoporosis in patients with CRS.

METHODS: Retrospective chart analysis was performed at a tertiary-care rhinology practice. Patients with CRS with or without polyposis evaluated between September 2003 and July 2008 were included if they had (1) previous history of oral steroid usage (5mg or greater daily for at least 3 months) and (2) previous bone mineral density (BMD) evaluation.

RESULTS: A total of 197 patients were included with mean age of 51.1 years. The primary diagnoses included CRS with polyposis in 176 cases (89.3%) and CRS without polyposis in 21 cases (10.7%). Concomitant asthma was present in 161 patients (81.7%). Overall, the prevalence of osteopenia was 35.5% (70) and osteoporosis was 7.1% (14), respectively. Among postmenopausal women, the rates of osteopenia and osteoporosis increased to 48.9% (22) and 13.3% (6), respectively. Eighty patients (40.6%) were further evaluated by rheumatology. Management consisted of calcium and vitamin D supplementation in 164 cases (83.3%) and bisphosphonates in 99 patients (50.2%).

CONCLUSION: Patients with CRS with/without polyposis who have been treated with oral steroids have a high prevalence of osteopenia or osteoporosis. High index of suspicion is required to identify at risk patients and to initiate careful evaluation and treatment to prevent additional bone-related complications.

ABSTRACT NUMBER: 1709

DIFFUSION WEIGHTED MAGNETIC RESONANCE IMAGING OF PARA-NASAL DISEASES

Adam French, MD, Stephanie Joe, MD, Ali Sepahdari, MD, Mahmood Mafee, MD

INTRODUCTION: The purpose of this study is to examine the diffusion characteristics of benign and malignant diseases in the paranasal sinuses with diffusion weighted magnetic resonance imaging (DWI).

METHODS: Patients with a history of sinus pathology from a single academic institution underwent DWI of the paranasal sinuses. Sinus pathology was diagnosed by biopsy, culture results, or surgical excision. Apparent diffusion weighted imaging coefficients (ADCs) were calculated from the diffusion weighted imaging images. These ADC values were compared across malignant masses, benign masses, and inflammatory sinus diseases.

RESULTS: There were twenty-nine patients examined, including fifteen men and fourteen women. The benign group containing twelve patients was subdivided into eight inflammatory cases and four solid masses. The malignant group contained seventeen patients. There was a statistically significant difference in mean ADC values between the malignant (0.96, SD = 0.32) and benign (1.37, SD = 0.85) groups. The

ADCs were also significantly different between inflammatory pseudo-masses (2.04, SD = 0.92), benign masses (1.37, SD = 0.41), and malignant sinus lesions (0.96, SD = 0.32).

CONCLUSIONS: DWI can be used as an adjunctive tool in diagnosis of paranasal sinus pathologies and possibly aid in surveillance and detection of malignant disease recurrence.

ABSTRACT NUMBER: 1710

ENDOSCOPIC BACK AND FORTH SEPTOPLASTY TECHNIQUE

Trimarchi Matteo, MD, Bellini Chiara, MD, Recanati Paola, MD, Bussi Mario, MD

BACKGROUND: Septoplasty is a well-described surgical technique for management of nasal airway obstruction (NAO). The advances in endoscopic technique have facilitated endoscopic septoplasty (ES) that is now a good alternative to “headlight” approaches by limiting the dissection to the area of the deviation, in particular for endoscopic resection of septal spurs, deformities and posterior deviation.

METHODS: From January 2005 to November 2008, 243 patients, 50 females and 193 males (age range 21-60 yr) underwent ES at the Department of Otorhinolaryngology, San Raffaele Hospital Milan. The most common concomitant diagnoses included allergic rhinitis and turbinate hypertrophy. We excluded from the study patients with sinonasal polyposis and chronic rhinosinusitis. So concomitant procedures was turbinate reduction (95%). The endoscopic back and forth septoplasty (EBFS) facilitates the interruption of perichondrial and periosteal bridges that are more represented in the anterior portion of the septum between the caudal quadrangular cartilage and the vomeropremaxillary crest.

RESULTS: Among patients who underwent primary EBFS technique for NAO 74,1% achieved resolution, 16,4% reported improvement of their nasal obstruction and 9,5% noted persistence of symptoms. Complications included transient dental pain/hypesthesia (6,1%), septal hematoma (4,86%), septal perforation (1,64%), synechia formation (2,05%), epistaxis (2,05%), chick swelling (0,41%), septal abscess (0,41%).

CONCLUSION: EBFS is a viable alternative to traditional headlight septoplasty with very good outcomes and acceptable complications. This technique allows to lise the tissue fibers preserving the integrity of mucosa at the critical area using less force e reducing the probability of mucosal tears.

ABSTRACT NUMBER: 1711

ANASTOMOSIS OF NASAL MUCOSAL AND LACRIMAL SAC FLAPS: KEY ROLE IN ENDOSCOPIC DACRYOCYSTORHINOSTOMY

Chiara Bellini, MD, Matteo Trimarchi, MD, Antonio Giordano Resti, MD, Mario Bussi, MD

BACKGROUND: Endoscopic dacryocystorhinostomy (DCR) is a well-established alternative to external approaches in the treatment of nasolacrimal canal obstruction. It is a safe and less invasive compared to standard surgical procedures.

METHODS: From July 2004 to September 2008, 85 endoscopic DCRs (age range 5-76 yrs) were performed on 82 patients (18 male, 64 female) at the Department of Otorhinolaryngology, San Raffaele Hospital, Milan. All patients were affected by chronic dacryocystitis with epiphora. Preoperative work-up (performed by Ophthalmologists and ENT specialists) included lacrimal pathways irrigation, Jones Tests (1 and 2), nasal endoscopy, and imaging evaluation by computed tomography. The technique involved anastomosis of nasal mucosal, lacrimal sac flaps and a large bony ostium. A silicone tube was inserted in all patients that remained for a period of 3 months. Follow up assessment included nasal endoscopy to evaluate anatomical patency and symptoms with Jones tests. The average follow up time was 16 months (range 2-51 months).

RESULTS: The first endoscopic intervention was successful in 91,76% of patients. After a second revision endoscopic DCR the overall success rate raised to 96,47%.

CONCLUSIONS: Endoscopic DCR is an efficacious method with a higher success rate both in primary nasolacrimal obstructions and in revision cases. Anastomosis of nasal mucosal between lacrimal sac flaps plays a key role in endoscopic DCR success rate.

ABSTRACT NUMBER: 1714

FLUTICASONE PROPIONATE DELIVERED WITH THE OPTINOSE DELIVERY DEVICE EFFECTIVELY TREATS CHRONIC RHINOSINUSITIS

Dr. Per Djupesland, Fleur Hansen, Tony Flint, Prof. Wytse Fokkens

INTRODUCTION: Chronic Rhinosinusitis (CRS) severely impacts on quality of life, with few effective treatments currently available. OptiNose's breath-actuated, bi-directional nasal delivery improves middle meatus deposition, considered essential to achieve clinical effects in CRS with a topical steroid.

METHODS: Efficacy and safety of fluticasone propionate self-administered using OptiNose's delivery device (Opt-FP) were assessed in a prospective, single centre, randomized, double-blind, parallel group, placebo-controlled pilot study in 20 adult patients with CRS without nasal polyps or with only cobblestone polyps grade 1 (Lildholdt's scale). Opt-FP 400 µg or placebo (PBO) was delivered twice daily for 12 weeks (n=10 subjects/group). All patients also used saline rinse. Results are change from baseline at week 12 unless otherwise stated. P-values refer to differences with placebo.

RESULTS: Endoscopy score for oedema showed a highly significant and progressive improvement (Opt-FP -3.1, PBO -1.0, p<0.01). PNIF was increased (4 weeks: p<0,01; 8 weeks: p<0,05). Non-significant increases in nasal volumes were observed (Acoustic rhinometry). Total RSOM-31 QOL-score and all subscale scores also improved against placebo. The nasal RSOM-31 subscale was significantly improved (4 weeks: p<0,05,

8 weeks: p<0.01, 12 weeks: p=0.053). Overall VAS-score showed an improvement trend (Opt-FP -23.6, PBO -3.3, p=0,19). Diary scores for sense of smell, nasal discomfort and combined score, both morning and evening, were all significantly improved (p<0.05).

CONCLUSIONS: Fluticasone propionate (400 µg b.i.d) administered using OptiNose's breath-actuated bi-directional delivery device in combination with saline wash was highly effective in treating CRS with significant improvements over placebo. The treatment was safe and well tolerated.

ABSTRACT NUMBER: 1715

OUTCOMES TESTING FOR ENDOSCOPIC SKULLBASE SURGERY INCLUDING NASAL TISSUE RESECTION

Zara Patel, MD, Vijay Mukhija, MD, Eric Genden, MD, Satish Govindaraj, MD

INTRODUCTION: Resection of nasal tissue has been a source of much discussion in the rhinologic literature. As the pendulum has swung in favor of minimally invasive sinus surgery, rhinologists are simultaneously pushing the boundaries in the advancing field of endoscopic skull base surgery. The objective of our study was to take this unique population with no history of nasal complaints and assess the effect of increasingly invasive endoscopic surgery.

METHODS: All patients undergoing endoscopic skull base surgery at a tertiary care center from 1999 through 2008 were included in a retrospective chart review. The SNOT-20 was also performed on all subjects. T-test and ANOVA analysis were used.

RESULTS: 54 patients underwent endoscopic skull base surgery, with a male to female ratio of 1:1.8. Age ranged from 26 to 83. SNOT-20 scores were not correlative with age, gender, diagnosis, addition of radiation or extensiveness of middle turbinate resection. There was a significant inverse relationship between time from surgery and SNOT-20 score, with a significant difference at 2,4 and 6 years (p<0.001).

CONCLUSIONS: Preserving nasal tissue and natural physiology is always a goal in endoscopic surgery. However, as surgeons become more skilled at larger skull base resections they may occasionally need to take nasal tissue along with the pathologic specimen. Our data suggests that while we may need to help these patients through short term nasal symptoms, they do not appear to suffer long term nasal complications as a result.

ABSTRACT NUMBER: 1720

ORBITAL MASS LESIONSS: IMPLICATIONS AND LIMITATIONS OF ENDONASAL ENDOSCOPIC APPROACH

Mohsen Naraghi, MD

INTRODUCTION: Orbital Masses could be intraorbital, sinonasal or intracranial. Various surgical approaches have been applied for treatment of the orbital masses. The medial orbital wall is composed mainly of lamina papyracea which could be accessed through the ethmoid sinuses. In this article, our experience in endoscopic approach to the orbital masses have been explained.

METHODS: 224 patients with different orbital masses were referred to undergo endoscopic management with the mucocoeles as the most common lesions. In sinogenic orbital lesions, treatment was complete by treating sinus of origin. In the case of the intact lamina paryracea, it was removed followed by an incision through the periosteum. At the latter stage, much percision was applied to avoid bleeding and ocular muscles injury.

RESULTS: The outcomes were dependent on the type of the lesions. In the inflammatory conditions, the endoscopic surgery was performed as a curative modality with functional benefits for the sinuses. In the benign lesions, complete resection of the tumor was accomplished in most of the cases. In some cases it needed to add an external approach to have better exposure for removal of tumor. Malignant tumors required adjuvant modalities like chemotherapy.

CONCLUSION: Endoscopic surgery could be an alternative treatment for the selected cases with orbital masses. The minimally invasive nature of this approach could make it superior to the other approaches. Less edema and swelling, most cosmetic effects, eliminating the need to any dressing and in many cases capability of performing under local anesthesia are advantages of this approach.

ABSTRACT NUMBER: 1722

ENDOSCOPIC REPAIR OF BASAL SINONASAL CEPHALOCELES

Prof. Mohammed Hassab, Ali Ansari, MD

INTRODUCTION: a basal sinonasal cephalocele is a condition in which the brain and/or meninges herniated through a defect in the skull base to present endonasally within the sinonasal region. Surgical repair of these “herniations” is mandatory to avoid series complications such as meningitis. These lesions vary considerably in size and site of the underlying skull base defect. In the current study, an attempt is made to stratify these lesions based upon their size and site of the defect.

METHODS: a case series of 16 patients with basal sinonasal meningoceles/encephaloceles managed over a 12 year period is presented. None of the patients had a history of trauma to account for their cephalocele.

RESULTS: Fifteen of these lesions were managed endoscopically. An external approach was required in 1 patient. The lesions managed in this case series varied considerably in size from 2 mm up to 4 cm. Microcephaloceles 2 mm–6mm in length predominantly occurred in middle aged females (in 11 patients) along weak areas in the skull base. An empty sella on the CT studies occurred in 4 of these patients. The skull base defect in this group of patients was small allowing for a single layer repair. Macrocephaloceles 2 cm–4 cm in length occurred in a much younger age group (in 5 patients) with a sizeable skull base defect either in the cribriform plate or the fovea ethmoidalis. Because of the larger size of the skull base defect in this group of patients, a multiple layer repair was carried out. None of the patients had a recurrence except one of the patients with a microcephalocele and empty sella.

CONCLUSION: Based upon the findings of this case series, it is proposed that macrocephaloceles are true congenital lesions while microcephaloceles are acquired ones probably resulting from benign increased intracranial pressure.

ABSTRACT NUMBER: 1724

NASAL CONGESTIVE AND INFLAMMATORY RESPONSE TO INHALATION CHALLENGE WITH HEXAMETHYLENE DIISOCYANATE (HDI): A PILOT STUDY

Dr. Roberto Castano, Dr. Martin Desrosiers, Vic Johnson

INTRODUCTION: Diisocyanates are among the main causes of occupational asthma. Rhinitis symptoms are commonly reported by workers exposed to diisocyanates; however, they are rarely investigated despite evidence showing occupational rhinitis as a risk factor for asthma development. The purpose of this pilot study was to assess nasal congestive and inflammatory responses to inhalation challenges with diisocyanates.

METHODS: Nine workers (men, mean age 40.6 years) with a history of upper and lower respiratory symptoms associated to workplace exposure to diisocyanates were enrolled. After a control challenge day to assess nonspecific nasal responses, they underwent a specific challenge day with hexamethylene diisocyanate (HDI). We measured nasal volume (2-5 cm) before and hourly up to 6h after challenge by acoustic rhinometry to monitor nasal congestion. Nasal lavage (NAL) was performed in 6 subjects before and at 30min and 6h after challenge to assess changes in inflammatory cells.

RESULTS: The mean (SD) maximum percentage decrease in nasal volume compared with baseline values was 15.0 (9.2) % on the control day. After a 4 min-challenge with HDI, the maximum decrease was 21.3 (7.8) %. No significant changes were noted in the percentage of neutrophils and eosinophils in NAL on the control day. An increase in the percentage of eosinophils was observed in 4 subjects after challenge with HDI in comparison to baseline values and to values on the control day.

CONCLUSIONS: We demonstrated that inhalation challenges with HDI can induce changes in nasal patency and upper airways inflammation that may be indicative of occupational rhinitis.

ABSTRACT NUMBER: 1726

EXTRANODAL ROSAI-DORFMAN DISEASE INVOLVING PTERYGOPALATINE FOSSA, ORBIT AND MIDDLE CRANIAL FOSSA—CASE REPORT

Tsan-Jen Chiu, MD, Yuan Hsu, MD, Peir Chen, MD

Rosai-Dorfman disease (RDD), also recognized as sinus histiocytosis with massive lymphadenopathy (SHML), is characterized by a nonmalignant proliferation of distinctive histiocytic/phagocytic cells within lymph node sinuses and extranodal lymphatics. However, it is rare in pterygopalatine fossa. We report a 40-year-old woman who complained of severe right side headache and facial numbness for 6 months. Before being referred to our clinic, she had received dental treatment but in vain. Physical examination revealed no cervical lymphadenopathy. Right trigeminal neuralgia was suspected. Computed tomography (CT) scan of the skull showed a heterogeneous enhancing tumor in the right side pterygopalatine fossa, which invaded the orbit, infra-temporal fossa and abutted the cavernous sinus. Thereafter, a trans-maxillary sinus pterygopalatine fossa endoscopic biopsy was performed. Pathological examination confirmed RDD with emperipolesis and positive stain for S-100 protein. The headache improved much after two week's steroid therapy, but the steroid was tapered due to its side effects. After that, the headache flared up and CT showed tumor was of the same size. Then four courses of Rituximab were given. She became symptom-free with decreasing of the tumor size, and remained in stable condition as of 6 months' follow-up. We present this case to highlight that RDD may encounter on the uncommon site with aggressive clinical course, and intensive medical treatment is needed in this condition. Besides, the extranodal RDD diagnosis is still challenging for the pathologist. Fibrosis tends to be more evident and emperipolesis is less conspicuous in the extranodal type. The clinical features and treatment modalities of RDD are reviewed.

ABSTRACT NUMBER: 1727

ANTIBIOTIC PROPHYLAXIS IN SINUS SURGERY: A REVIEW OF CURRENT PRACTICES

Anita Sethna, MD, Sarah Wise, MD, Rodney Schlosser, MD,
John DelGaudio, MD

INTRODUCTION: Use of perioperative antibiotics is documented to prevent postoperative infectious complications in various surgical procedures. However, perioperative antibiotic use in sinonasal surgery has not been extensively studied. This study surveys members of the American Rhinologic Society (ARS) regarding perioperative antibiotic usage practices for rhinologic procedures.

METHODS: 650 U.S.-based, non-Resident members of the ARS were questioned using a 50-item survey. Participation was voluntary and anonymous. Data were analyzed for response frequencies and significant differences across the spectrum of sinonasal procedures.

RESULTS: Initial survey response rate was greater than 30%. A significant difference existed for the use of preoperative antibiotics across surgery types, with more preoperative antibiotics being used for inflammatory sinus procedures (functional endoscopic sinus surgery [FESS]) than expected and fewer preoperative antibiotics used for septoplasty and extended sinus procedures (orbital and skull base surgery) than expected, ($p < 0.05$). Fifty percent of respondents used intraoperative antibiotics for septoplasty, 57% for FESS, and 85% for extended sinus procedures. Postoperative antibiotic use ranged from 69% for septoplasty to over 80% for FESS and extended approaches. There was no statistical difference across surgery types for rates of intraoperative and postoperative antibiotic use ($p > 0.05$). Across surgery types, first generation cephalosporins were the most common intraoperative antibiotic (53-84%). Culture-directed antibiotics were used preoperatively in 26-32% and postoperatively in 10-17% of FESS cases.

CONCLUSIONS: A consensus on perioperative antibiotic use for sinonasal surgery is currently lacking. These trends may serve to initiate further investigation into quality-control standards in antibiotic use for sinonasal procedures.

ABSTRACT NUMBER: 1728

ORBITAL INFECTION ASSOCIATED WITH SINUSITIS IN THE ADULT POPULATION.

Geir Tryggvason, MD, Mohannad Al-Qudah, MD, Jeffrey Nerad, MD,
Scott Graham, MD

INTRODUCTION: Orbital infection secondary to bacterial sinusitis is a serious problem that carries potential dramatic complications including intracerebral abscess, bacterial meningitis, vision loss and cavernous sinus thrombosis. The subject has been well studied in pediatric patients however few studies addressed this complication in adult population. The aim of this study is to review adult cases with orbital infection secondary to sinusitis in a tertiary university hospital.

MATERIALS AND METHODS: Patients carrying the diagnosis of orbital cellulitis (ICD 376.01) and sinusitis (461.1-9) from July 2001 to March 2008 were found with a computer search of the the hospital's database. Retrospective chart review was done and information regarding the following factors was collected: age, sex, cultures, predisposing factors, site of sinus disease, site of ophthalmologic disease, visual status, management and complications.

RESULTS: A total of 18 cases were analyzed with an age range of 20-85years (average 46).Thirteen patients were male and five were female. Ten cases had involved the left eye and eight the right. Five patients had prior facial fracture, two prior sinus surgery, one was immunocompromised and another had massive frontoethmoid osteoma. All patients had maxillofacial CT scan. 14 (78 %) had ethmoid sinus involvement, 11 (61 %) frontal, 10(56 %) maxillary and 2 (11%) had sphenoid disease. Defect in orbital wall was seen in 10 cases (53%). Four patients had periorbital cellulitis the remaining had abscess ,six at the orbital roof, four at the medial wall ,two at the inferomedial wall and another two at orbital floor. Microbiology swabs had been taken in a total of 17 cases, of which fifteen grew specific organisms, staphylococci species in 5 patients, streptococci species in 3, hemophilus specious in 3, pseudomonas aeruginosa in 2, mixed anaerobes and mixed oral flora in the two others. Thirteen out of the 18 cases (72%) had required surgery, seven had combined open and endoscopic approach, 4 had endoscopic management and two had open procedure. The average visual acuity at presentation was 20/84 and -5.0 was the ocular motility. On discharge no patient's acuity or motility had worsened, the average acuity and motility were 20/40 and - 0.4 respectively. There was one case with intracranial extension who underwent frontal craniotomy for evacuation of subdural empyema one week after endoscopic management.

CONCLUSION: Orbital infection as a complication of sinusitis is uncommon in adult patients. In most cases swab culture can be used to guide antimicrobial treatment. In our series it occurred in patients with multiple sinus involvement and in those with orbital wall defect. The majority of patients required surgical intervention which is safe and effective.

ABSTRACT NUMBER: 1729

GENOME-WIDE ANALYSIS OF GENE EXPRESSION CHANGES IN THE CHRONIC RHINOSINUSITIS

Alla Solyar, MD, Joshua Rosenberg, MD, Thomas Belbin, PhD,
Marvin Fried, MD

OBJECTIVES: To determine differential gene expression patterns in the nasal mucosa of patients with chronic rhinosinusitis (CRS) without nasal polyps compared to normal controls using cDNA microarray analysis.

METHODS: Nasal mucosa samples were obtained from seventeen subjects, nine with CRS and eight healthy controls, at the time of their elective nasal surgery. After total RNA extraction, a microarray containing 27,323 cDNA clones was utilized to examine gene expression profiles by comparing CRS and non-CRS RNA to reference RNA containing pooled aliquots from both groups. Each gene on the microarray was ranked according to its ability to separate CRS subjects from normal control subjects based on its level of gene expression using a Student's t-test.

RESULTS: Microarray analysis resulted in 166 genes (68 more highly expressed in CRS subjects, 98 more highly expressed in control subjects) that could separate the two subject groups with a p-value < 0.01 . Genes that were up-regulated in CRS subjects relative to controls included glucose-6-phosphate transporter and multiple ubiquitin modifiers, while genes that were down-regulated included leukocyte associated Ig-like receptor, interleukin enhancer binding factor 2, and tumor necrosis factor receptor associated protein.

CONCLUSIONS: cDNA microarray analysis of nasal mucosal samples can detect quantitative changes in gene expression in patients with CRS compared to healthy controls. Differentially expressed genes may play significant roles in the pathogenesis of CRS. Furthermore, these expression patterns may provide molecular markers that may have implications for understanding pathogenesis of CRS as well as assessing disease severity, prognosis and response to specific treatments.

ABSTRACT NUMBER: 1731

CONTROLLED STEROID DELIVERY VIA BIOABSORBABLE STENT: SAFETY AND PERFORMANCE IN A RABBIT MODEL

Peter Li, MD, David Downie, MD, Peter Hwang, MD

INTRODUCTION: Middle turbinate lateralization, adhesions and inflammation are causes of sub-optimal sinus patency following surgery. A bioabsorbable, drug-eluting stent has been developed to maintain sinus patency while providing controlled steroid delivery to the sinus mucosa. The aim of this study was to characterize the in-vivo safety and performance of this stent in a rabbit model.

METHODS: Bioabsorbable stents coated with mometasone furoate were placed in the maxillary sinuses of 31 rabbits bilaterally via dorsal maxillary sinusotomy. Animals were sacrificed between 5 days and 18 weeks postoperatively. Safety was assessed by endoscopic and histologic evaluation of the sinus mucosa, and by measurement of plasma steroid concentrations. Performance was assessed by measuring tissue concentrations of steroid in maxillary sinus mucosa. Structural integrity of the stent over time was also assessed.

RESULTS: At all time points, endoscopic and histopathologic examinations of mucosa were normal, comparable to controls. Therapeutic mucosal drug concentrations were attained in a time-dependent fashion (range 175ng/g – 28,189ng/g). Plasma drug concentrations were generally near or below the lower limit of quantification (15pg/mL). Structural integrity of the stent was maintained to 14 days. Microscopic fungal hyphae were noted in a small proportion of both treatment and control sinuses, without evidence of associated adverse tissue reaction.

CONCLUSIONS: Drug-eluting sinus stents are safe and can provide controlled local steroid delivery with negligible systemic absorption. They may prove useful following endoscopic sinus surgery in maintaining sinus patency and reducing inflammation.

ABSTRACT NUMBER: 1732

A ROLE FOR OBSERVATION IN THE TREATMENT OF ISOLATED DISEASES OF THE PEDIATRIC SPHENOID SINUS AND CLIVUS

Vijay Ramakrishnan, MD, Jesse Smith, BA, Kenny Chan, MD

INTRODUCTION: It is unclear how to manage isolated sphenoid opacification or benign appearing irregularities of the clivus in asymptomatic or minimally symptomatic children. In adults, isolated sphenoid sinus opacification carries a 16-24% rate of neoplasm, and diagnostic surgery is often recommended in patients with mild symptoms.

METHODS: Retrospective chart review of all cases of sphenoid surgery performed at a pediatric hospital over a thirteen-year period.

RESULTS: Of 69 patients undergoing sphenoidotomy, 52 patients had concurrent sinonasal pathology of infectious, inflammatory,

or neoplastic etiology. On preoperative imaging, nine patients had isolated sphenoid sinus opacification, and eight patients had retrosphenoid irregularities. Of the nine patients with isolated sphenoid opacification, four were asymptomatic. The remaining five patients suffered from headache (75%), nasal obstruction (25%), or neurologic deficit (50%). The four asymptomatic patients had normal sinuses at the time of surgery, whereas the five symptomatic patients had demonstrable pathology. Of the eight patients with retrosphenoid abnormalities, three had obvious sellar and congenital abnormalities. The remaining five suffered from vague headaches and had benign appearing radiographic changes limited to the clivus. On pathologic analysis, four of these patients were found to have been benign fibroadipose and marrow tissue, and the fifth case was diagnosed as fibrous dysplasia.

CONCLUSIONS: Indications for sphenoid imaging and surgery are less defined in the pediatric population than in adults. Isolated sphenoid sinus opacification is uncommon, but appears relevant in a symptomatic child. Incidentally discovered sphenoid sinus opacification and benign appearing clival bony irregularities may be observed in asymptomatic patients.

ABSTRACT NUMBER: 1733

NASOPHARYNGEAL SWAB CYTOLOGY FOR NASOPHARYNGEAL CARCINOMA BY NON-OTORHINOLARYNGOLOGISTS

Dr. S Tiong, David Downie, MD, Peter Hwang, MD

INTRODUCTION: Middle turbinate lateralization, adhesions and inflammation are causes of sub-optimal sinus patency following surgery. A bioabsorbable, drug-eluting stent has been developed to maintain sinus patency while providing controlled steroid delivery to the sinus mucosa. The aim of this study was to characterize the in-vivo safety and performance of this stent in a rabbit model.

METHODS: Bioabsorbable stents coated with mometasone furoate were placed in the maxillary sinuses of 31 rabbits bilaterally via dorsal maxillary sinusotomy. Animals were sacrificed between 5 days and 18 weeks postoperatively. Safety was assessed by endoscopic and histologic evaluation of the sinus mucosa, and by measurement of plasma steroid concentrations. Performance was assessed by measuring tissue concentrations of steroid in maxillary sinus mucosa. Structural integrity of the stent over time was also assessed.

RESULTS: At all time points, endoscopic and histopathologic examinations of mucosa were normal, comparable to controls. Therapeutic mucosal drug concentrations were attained in a time-dependent fashion (range 175ng/g – 28,189ng/g). Plasma drug concentrations were generally near or below the lower limit of quantification (15pg/mL). Structural integrity of the stent was maintained to 14 days. Microscopic fungal hyphae were noted in a small proportion of both treatment and control sinuses, without evidence of associated adverse tissue reaction.

CONCLUSIONS: Drug-eluting sinus stents are safe and can provide controlled local steroid delivery with negligible systemic absorption. They may prove useful following endoscopic sinus surgery in maintaining sinus patency and reducing inflammation.

ABSTRACT NUMBER: 1734

THE EFFECT OF MIDDLE TURBINATE SUTURE MEDIALIZATION ON OLFACTION

Jay Dutton, MD, Mark Hinton

OBJECTIVE: To assess the effect of suture medialization of the middle turbinate (MT) during endoscopic sinus surgery (ESS) on olfactory sensation.

BACKGROUND: One of the primary goals of endoscopic sinus surgery (ESS) is to create widely patent sinus ostia, and lateralization of a middle turbinate following ESS can obstruct an otherwise patent ethmoid cavity. Numerous methods have been utilized to assist in the avoidance of this complication including the use of packing in the ethmoid sinus as a “spacer”, controlled creation of synechiae between the middle turbinate and septum, and suture medialization of the middle turbinate to the septum. The latter is an effective technique, but since the olfactory groove lies superior in the groove between the middle turbinate and septum, concerns have been raised as to the effect of this maneuver on olfaction. The aim of this study was to objectively evaluate olfaction before and after suture medialization of the middle turbinates, and secondarily to evaluate the effectiveness of this technique in preventing lateralization of the middle turbinate.

METHODS: Objective assessment of olfactory function using the University of Pennsylvania Smell Identification Test (UPSIT) was performed prior to and 6 months after ESS in 202 patients between January 2006 and January 2008. Post-operative follow up exams were also performed to determine the effectiveness of the medialization procedure and the patency of the ethmoidectomy cavities.

RESULTS: UPSIT testing did not show a statistically significant difference in the pre-operative and post-operative period. Post-operative endoscopic examination revealed that lateralization of the middle turbinate was a rare complication after suture medialization of the MT.

CONCLUSION: MT suture medialization during ESS is an effective method for preventing lateralization of the MT and does not impair olfaction postoperatively.

ABSTRACT NUMBER: 1736

UPREGULATION OF BCL-2 IN NASAL POLYPS OF PATIENTS WITH CYSTIC FIBROSIS

Victor Scapa, MD, Vijay Ramakrishnan, MD, Maxwell Smith, MD, Todd Kingdom, MD

INTRODUCTION: Nasal polyps in patients with cystic fibrosis (CF) are believed to be phenotypically different than polyps affecting non-CF, aspirin-tolerant patients. Preliminary data from our lab has suggested differences in cell cycle regulatory mechanisms of these two patient groups. The objective of this study was to further examine these differences in efforts to confirm preliminary findings. Multiple techniques were utilized to confirm the upregulation of anti-apoptotic Bcl-2 family proteins in CF polyps.

METHODS: Nasal polyps were prospectively obtained from CF and non-CF patients. The Sigma Panorama Protein Microarray was used to identify differences in protein expression between the two polyp groups. Western blot analysis confirmed altered expression of a subset of these proteins. Immunohistochemical staining was performed on archived tissue to further investigate Bcl-2 expression. Following review by a pathologist, slides were digitized using an Aperio ScanScope XT system and staining intensity was quantified with the Positive Pixel Count algo-

riethm. The mean staining intensity for each polyp group was compared using an unpaired t-test.

RESULTS: The protein microarray suggested a greater than two-fold upregulation of Bcl-xl in CF polyps relative to non-CF polyps. Western blot analysis confirmed the upregulation in CF polyps of Bcl-2, a more commonly studied protein analog of Bcl-xl. The CF polyp group was discovered to have a higher quantitative intensity of immunohistochemical staining for Bcl-2 compared to the non-CF group ($p < 0.05$).

CONCLUSION: Through multiple modalities of protein investigation, we have demonstrated an upregulation of Bcl-2 family proteins in CF polyps relative to polyps from non-CF patients.

ABSTRACT NUMBER: 1739

SNORING IN ADULT PATIENTS WITH NASOPHARYNGEAL TUBERCULOSIS

Dr. S Tiong

OBJECTIVE: Patients with nasopharyngeal tuberculosis (NPTB) is treated with anti-TB therapy (ATTBT) with effective response rather than conventional CPAC or surgery. This presentation resulted from study on such ENT patients with snoring.

METHODS: A retrospective study of all snoring adult patients seen in ENT Clinic in a developing country from January to December 2007 was undertaken and those treated for nasopharyngeal TB were selected.

RESULTS: This study found 54 patients, and 2 had nasopharyngeal TB. First was a 48 years old housewife with snoring of 16 months duration. She visited her aunt who had ATTBT 6 months before. Nasopharyngeal endoscopy showed hyperaemic swelling at posterior wall with biopsy showing features of TB. Her chest Xray(CXR) was normal. ATTBT was started. Six months after, she had no more snoring. Second patient, 53 years old nurse, worked at local hospital with no TB contact known. She had 5 months snoring and right hypoacusia. ENT examination showed right serous otitis media and nasopharyngeal endoscopy revealed oedematous swelling at lateral wall. The swelling biopsy was consistent with TB. Her CXR was normal. She responded well to ATTBT with normal hearing and no more snoring 6 months after. Ziehl-Neelsen smear and Lowenstein-Jensen culture of the biopsy tissues were negative in both patients.

CONCLUSIONS: The findings illustrate the importance of nasopharyngeal examination with biopsy for TB diagnosis in suspected cases especially in developing countries where TB is prevalent. Delay in diagnosis or conventional snoring treatment could result in risk of TB spread and public health.

ABSTRACT NUMBER: 1742

THE EFFECTIVENESS OF PULMICORT DELIVERY WITH THE MUCOSAL ATOMISATION DEVICE IN TREATING ALLERGIC FUNGAL SINUSITIS

Bedy Lau, MD, Carl Philpott, MD, Amin Javer, MD

BACKGROUND: Allergic fungal sinusitis (AFS) has proven itself to often be refractory to effective control without resorting to systemic steroids and oral antifungals. The ideal treatment would therefore reduce the risk of systemic side-effects whilst enabling disease control.

OBJECTIVES: To assess the effects of budesonide application using the mucosal atomisation device (MAD) in controlling allergic fungal sinusitis both in terms of objective i.e. mucosal staging, serum IgE and eosinophil counts and subjective i.e. SNOT-22 outcomes.

METHODS: A prospective study in a tertiary rhinology centre of 100 patients with AFS in whom the mucosal staging had worsened on their existing regime. Patients were asked to complete a SNOT-22 questionnaire and have an IgE level and full blood count blood sample taken. These investigations were repeated at follow-up visits at 6 and 12 weeks.

RESULTS: A significant change in endoscopic grading and symptom scores was observed in patients using the MAD application of budesonide at all 3 time intervals after commencement ($p=0.048$). A significant reduction in the SNOT-22 questionnaire scores was also observed ($p=0.017$). There was no significant correlation with serum IgE levels ($p=0.95$).

CONCLUSIONS: The use of topical Budesonide via the MAD is an effective means of controlling recurrent disease in patients with AFS following endoscopic sinus surgery, both subjectively and objectively.

ABSTRACT NUMBER: 1745

POLYSOMNOGRAPHIC EVALUATION OF THE EFFECT OF PROPOFOL ON SLEEP FOR BOTH HEALTHY AND OSAHS PATIENTS: PRELIMINARY RESULTS

Fabiana Valera, PhD, Fabio Rabelo, MD, Heidi Sander, MD, Daniel Küpper, MD

INTRODUCTION: Nasofibroscopy during sedation with propofol has been reported as the exam which is the most similar to regular sleep, predicting the areas collapsed during it. Nevertheless, it is being strongly questioned by some authors because of unknown effect of this drug during sleep, which could lead to possible adverse effects, and also changes the respiratory pattern. The objective of the present study was to determine changes in sleep parameters induced by propofol using polysomnographic examination and to validate evaluation by nasofibroscopy under sedation.

METHODS: Nine subjects (3 controls/6 with OSAHS) were submitted to diurnal polysomnography during 120 minutes both with and without the use of propofol. The exams were compared regarding the presence of snoring, apnea/hypopnea index (AHI), oxygen desaturation, and sleep architecture.

RESULTS: The use of propofol did not induce snoring in the control subjects, whereas 100% of the OSAHS patients snored. Apnea, hypopnea and AHI did not differ significantly in the diurnal exams with and without sedation ($P > 0.05$). The measurements of mean and minimum oxygen saturation (SaO₂) were significantly reduced during propofol sedation ($P < 0.05$), although the difference was not clinically important.

CONCLUSIONS: sedation with propofol permits evaluation under conditions close to physiological sleep regarding the main parameters evaluated in OSAHS, supporting the view that nasofibrolaryngoscopy under sedation with propofol is a promising exam for the management of this disease.

ABSTRACT NUMBER: 1747

COBLATION ASSISTED ENDOSCOPIC RESECTION OF A JUVENILE NASOPHARYNGEAL ANGIOFIBROMA WITH PRE-OPERATIVE TRANSNASAL EMBOLIZATION

Jose Ruiz, MD, Belachew Tessema, MD, David Neskey, MD

INTRODUCTION: Advances in endoscopic surgery allow for resection of selected juvenile nasopharyngeal angiofibromas (JNA). Methods to reduce intraoperative estimated blood loss (EBL) include hypotensive anesthesia and pre-operative embolization. In the literature, typical EBL for endoscopic JNA resection is approximately 200-650 mL. We report our experience using Coblation technology to assist in the endoscopic

resection of vascular JNA tumors and our experience with the delivery of pre-operative embolization using a transnasal endoscopic approach.

METHODS: A 23-year-old gentleman with epistaxis and nasal obstruction had a 3.4 cm tumor extending through the nasopharynx roof into the sphenoid. JNA staging was Radkowski stage IIA and Andrews stage II. Transnasal endoscopic embolization was performed 48 hours pre-operatively using an intratumoral injection of ethylene vinyl alcohol co-polymer (Onyx-18) under live fluoroscopy. Resection was completed via an exclusively endoscopic approach including removal of sphenoid and pterygomaxillary extension.

RESULTS: Preoperative embolization resulted in no complications. The tumor was resected in two parts, with the initial mass separated using the Coblator and delivered transoral with 75 mL of EBL. The final EBL was 150 mL and surgical time was 105 minutes. There were no peri-operative complications and no packing was required. The patient was discharged on post-operative day one.

CONCLUSIONS: Coblation can be used to assist in endoscopic resection of JNA tumors. Our patient had low EBL, short surgical time, no packing required, and early discharge. Transnasal pre-operative embolization was successful and resulted in no complications.

ABSTRACT NUMBER: 1750

FLUID RESIDUALS AND DRUG EXPOSURE IN NASAL IRRIGATION

Richard Harvey, MD, Nick Debnath, MD, Rodney Schlosser, MD

INTRODUCTION: Topical treatment options in the management of chronic rhinosinusitis (CRS) are rapidly growing with our increased understanding of the inflammatory process. Additives to irrigation devices have become increasingly popular. Some additives, such as menthol, provide little more than sensory feedback. However, glucocorticosteroids and antibiotics represent powerful pharmaceutical approaches with little knowledge regarding patient exposure and absorption. To date there is no data on residual volume and percentage of fluid retained after nasal irrigation in patients.

METHODS: To determine the residual volume and percentage of total nasal irrigation that is retained from a single delivery of fluid either from a neti pot (NasaFlo™) or a squeeze bottle (Sinus Rinse™). Patients were consenting adults (male and female, 18yrs+) already on nasal saline irrigations as part management of their CRS. Participants were divided into pre and post sinus surgery (ESS). 17 control irrigations on non-rhinological patients were collected for comparison. Nasal irrigation was performed with accurate collection of the excess to determine retained amount.

RESULTS: The overall retention of fluid was 2.14% +/- 1.14SD. This represents only 5.14ml+/-3.36mLSD for the 240ml irrigations. Squeeze bottles and Neti Pots were similar 2.36+/-1.18% and 1.70+/-1.08% respectively ($p=0.33$). CRS patients had the least retained volume 1.41+/-0.59%. The influence of group and device is discussed.

CONCLUSIONS: Quantification of the residual volume has important implications for both the treatment of inflammatory disease with saline as well as for potentially novel topical therapies.

ABSTRACT NUMBER: 1754

CASE STUDY: MECHANISMS OF ACTION FOR BALLOON DILATION OF THE OSTIOMEATAL UNIT (OMU) IN PATIENTS WITH CHRONIC RHINOSINUSITIS

James Atkins Jr., M.D., Theodore Truitt, M.D., James Stankiewicz, M.D., Thomas Tami, M.D.

INTRODUCTION: Balloon dilation of sinus outflow tracts is now widely used. However, little data on OMU remodeling is available and assessment of the anatomic impact of balloon dilation with computed tomography (CT) imaging can be challenging.

METHODS: High resolution CT scans before, and one month after, bilateral trans-antral maxillary balloon antrostomy were performed on a patient with CRS of the maxillary and anterior ethmoid sinuses. Both CT images were carefully aligned. Pre-treatment images in multiple coronal and axial slices at the maxillary ostium and infundibulum were selected and matched with the same slices in the post-operative scans. Dimensions were recorded and cross-sectional areas of infundibulum expansion in the coronal and axial planes were calculated.

RESULTS: The average cross-sectional area of the right infundibulum as measured from the 3 coronal slices increased from 9.6 mm² to 19.2 mm². The average cross-sectional area in the axial plane increased from 11.1 mm² to 20.1 mm². The left side was obstructed pre-operatively with an area of 0.0 mm². After dilation, the coronal and axial plane areas increased to 40.3 mm² and 28.4 mm² respectively. This patient also had a clinically significant improvement in symptoms. The Sino Nasal Outcome Test 20 score decreased from 2.5 at baseline to 1.1 at 12-month follow-up.

CONCLUSION: Dimensional analyses of high resolution CT images before and after balloon dilation demonstrate a significant increase in the cross-sectional area of the maxillary outflow tracts after treatment.

ABSTRACT NUMBER: 1758

IS LOOSE NASAL PACKING EFFICIENT AND SAFE AFTER INFERIOR TURBINECTOMY

Tung-Tsun Huang, M.D.

INTRODUCTION: Compact nasal packing is commonly used to control postoperative bleeding in patients undergoing inferior turbinectomy. However, it can be associated with significant pain on its removal. To our knowledge, loose nasal packing has not been tried before. The purpose of this study was to investigate the efficacy and safety of loose nasal packing following inferior turbinectomy.

METHODS: A prospective study was conducted on twenty patients undergoing inferior turbinectomy from November 2006 to November 2008. Loose nasal packing was applied with one piece of the surgical on the abraded surface of each inferior turbinate and two Vaseline gauzes (put inside the fingerstalls of the surgical glove) in each nasal cavity. Pain scores, using a visual analogue scale, and bleeding severity during packing removal were recorded. Another twenty patient undergoing inferior turbinectomy with compact nasal packing (one Merocel plus one or two Vaseline gauzes) before November 2006 were enrolled for comparison.

RESULTS: No patients in either group suffered from significant bleeding and required re-packing during the initial postoperative period. Pain score and bleeding severity on packing removal was statistically lower in loose packing group than in compact packing group ($p < 0.05$).

CONCLUSIONS: Loose nasal packing is as effective as compact nasal pack-

ing in controlling postoperative bleeding following inferior turbinectomy. Its removal, however, is less traumatic for the nasal mucosa and less painful for the patient. Therefore, we recommend the use of loose nasal packing to improve patient's comfort after inferior turbinectomy.

ABSTRACT NUMBER: 1760

ENDOSCOPIC TRANSMAXILLARY APPROACH TO THE PTERYGOPALATINE SPACE

Hwa Jung Son, MD, Rakesh Chandra, MD, David Conley, MD, Robert Kern, MD

INTRODUCTION: The pterygopalatine space (PPS) is a relatively inaccessible area that houses many neurovascular contents, including the second division of the trigeminal nerve, Vidian nerve, and internal maxillary arterial branches. The skull base in the PPS lies below the temporal lobe. Classic approaches to this region have required medial maxillectomy via lateral rhinotomy or midface degloving.

METHODS: We present 4 cases where an endoscopic transmaxillary approach was utilized to address pathology of the PPS.

RESULTS: The lesions addressed included recurrent lacrimal adenocarcinoma with perineural extension, schwannoma, JNA, and a large temporal lobe meningocele. All cases were successfully accomplished through an endoscopic maxillary antrostomy without complications. Image guidance was used in each procedure. We observed the following nuances of this approach: (1) wide antrostomy, (2) identification of the orbital process of the palatine bone, (3) control of internal maxillary arterial branches, (4) using a drill, when necessary, to address dense bone of the pterygoid root, and (5) consideration of a Caldwell-Luc if enhanced lateral exposure is required.

CONCLUSION: Transmaxillary access to the PPS can be accomplished safely and effectively via modifications of techniques originally described in the management of lateral sphenoid recess lesions.

ABSTRACT NUMBER: 1761

SECONDHAND TOBACCO SMOKE EXPOSURE AND CHRONIC RHINOSINUSITIS—A CASE-CONTROL STUDY

Douglas Reh, MD, Sandra Lin, MD, Sandra Clipp, BS, Ana Navas-Acien, MPH

BACKGROUND: Sinusitis is a costly and morbid disease that is influenced by environmental factors such as tobacco smoke, however few studies have evaluated the association between secondhand tobacco smoke (SHS) exposure and chronic rhinosinusitis (CRS). The objective of this study was to evaluate the association of SHS and the risk of CRS in a community-based case-control study of adult non-smokers.

METHODS: 100 cases with a confirmed diagnosis of CRS and 100 controls matched for age, sex, and former-never smoking status were recruited and interviewed among 7,386 residents from Washington County, MD. A validated questionnaire was used to assess past and present SHS exposure as well as disease-specific quality of life.

RESULTS: Cases were more likely to live with a smoker as children (78 vs. 67%, $p=0.08$) and to be exposed longer to SHS (median 9.9 vs. 5.0 hours/week, $p=0.06$), although these differences did not reach statistical significance. CRS cases exposed to SHS ($n=39$) had worse mean scores in nasal obstruction/blockage (3.1 vs. 2.5, $p=0.02$), nasal discharge (3.3 vs. 2.7, $p=0.03$), headaches (2.4 vs. 1.5, $p=0.01$), and cough (2.1 vs. 1.5, $p=0.04$) than cases without SHS exposure ($n=61$). Cases exposed to SHS were also more likely to use nasal decongestants (53.9 vs. 34.4%, $p=0.06$).

CONCLUSION: Exposure to SHS during childhood and adulthood may be a risk factor for CRS. While we found no association between current (SHS) exposure and CRS risk, cases with rhinosinusitis exposed to SHS reported worse nasal symptoms and used more nasal decongestants compared to unexposed cases.

ABSTRACT NUMBER: 1764

MINIMALLY INVASIVE TREATMENT MODALITY FOR SINONASAL MALIGNANCY WITH ANTERIOR SKULL BASE INVASION—A PRELIMINARY REPORT

Yu-Fu Chou

INTRODUCTION: Sinonasal malignancies are rarely encountered, frequently involving the anterior skull base. Traditionally, these diseases were treated surgically by external approach, such as craniofacial resection, often bringing major morbidities. Therefore, endoscopic excision of these tumors provides a possible less invasive way of treatment.

METHODS: We treated sinonasal malignancy with skull base invasion by endoscopic approach. The tumor was removed until the origin at anterior skull base was well defined and the operation field was created as wide as possible by pansinusectomy and endoscopic Lothrop operation. The bony roof of anterior skull base was removed along with the tumor stalk with adequate safety margin, keeping dura defect as small as possible, reconstructed with turbinate graft, and there were often inadequate intracranial resection margin. Subsequently, the patients received adjuvant therapy with Gamma knife radiosurgery or intensity modulated radiotherapy (IMRT) for intracranial safety margins. The patients were then followed regularly by sinuscopy and image studies.

RESULTS: From 2005~2008, we experienced four patients of sinonasal malignancies requiring surgical excision. Two of them were primary sinonasal cancer—One was esthesioneuroblastoma, and the other was the third recurrence of sinus cancer, previously treated by external approach. The other two were recurrent nasopharyngeal carcinoma after primary treatment with chemoradiation therapy. These patients were followed for 18 to 36 months, and no recurrence was found.

CONCLUSION: Endoscopic excision of sinonasal cancer boosted with radiotherapy or radiosurgery may provide a promising way that may have satisfactory tumor free rate and better life quality.

ABSTRACT NUMBER: 1765

OLFACTORY BULB VOLUME IN IDIOPATHIC OLFACTORY LOSS

Philippe Rombaux, MD, H el ene Potier, MD, Thierry Duprez, MD, Thomas Hummel, MD

INTRODUCTION: Olfactory loss is considered as idiopathic when no aetiology has been demonstrated in the history neither the clinical evaluation of the patient. Olfactory bulb (OB) volume has been related to the olfactory function both in normal and pathological condition. This study aimed to investigate the relation between the OB volume and the olfactory dysfunction in a group of patients with idiopathic olfactory loss.

MATERIAL AND METHOD: Twenty two patients were compared to 22 controls for their OB volume and olfactory ability with the psychophysical testing using the Sniffin stick test. Diagnosis of idiopathic olfactory loss was performed when others causes have been ruled out and when the olfactory deficit was acquired and not congenital.

RESULTS: As expected, psychophysical testing revealed that patients had lower scores than controls : $p < 0.001$ for threshold, discrimination, identification and global TDI score. Mean total OB volume was 53.4 mm^3 ($46.1\text{--}60.2 \text{ mm}^3$) for patients vs 74.5 mm^3 for controls ($74.5 \text{ mm}^3 - 81.9 \text{ mm}^3$) ($p < 0.005$ for right, left, total, and max volume of OB). Pearson's correlations were statistically significant for TDI scores and total OB volume when calculated for the 44 subjects ($0.549, p < 0.0001$).

CONCLUSIONS: Patients with idiopathic olfactory loss have lower OB volume than controls. This was already demonstrated for others causes of olfactory loss such as postinfectious and posttraumatic olfactory loss. Idiopathic olfactory loss is at least to a certain degree explained by this decreased OB volume and viewed as a constitutional disease speculating that such patients per se have more to lose than others when exposed to injury to their olfactory pathways.

ABSTRACT NUMBER: 1766

THE INFLUENCE OF SEPTAL FLAP RECONSTRUCTION ON SINONASAL FUNCTION AND QUALITY OF LIFE

Harshita Pant, MD, Amol Bhatki, MD, Carl Snyderman, MD

BACKGROUND: Septal flap reconstruction (SFR) for skull base defects has significantly improved clinical outcomes in patients undergoing endoscopic endonasal approach (EEA) to the skull base. However, the impact of SFR on patient's quality of life (QOL) and sinonasal function has not been addressed. The aim of this study was to evaluate the postoperative QOL and sinonasal function in patients who required SFR compared with those who did not.

METHOD: Prospective study. Patients undergoing transsellar EEA for pituitary lesions filled out SNOT 22 and a multidimensional disease-specific skull base QOL questionnaires at various time points after their surgery during routine post operative clinic visits. Minimum followup was 1 and maximum 18 months.

RESULTS: 36 patients were included in the study. 21 patients had SFR and 15 required no reconstruction. The QOL and SNOT 22 scores at 1 month were not significantly different between the study groups. However, at 2-3 months, scores were significantly better in patients without SFR compared with those who did. By 4-6 months and beyond, there was no significant difference in scores between the two groups. The impact of SFR on the sense of smell at 4-6 months and beyond showed no significant difference between the two groups.

CONCLUSION: SFR is associated with higher short-term sinonasal morbidity however this is temporary and in the long-term is not significantly different to patients without SFR. Overall, patients have a very good QOL after SFR of skull base defects.

ABSTRACT NUMBER: 1767

CLINICAL EVALUATION OF A NEW APPROACH IN ACUTE RHINOSINUSITIS

Anders Clemens, K Hörmann, Ludger Klimek, Oliver Pfaar

INTRODUCTION: It is currently estimated that 14% of the US population is affected by an episode of rhinosinusitis, afflicting all age groups and all segments of the population. Lyophilized extract of *Cyclamen europeum* nasal spray is a new treatment that facilitates physiological drainage and cleansing of the paranasal cavities through the mucous membranes. The objective of the clinical trial was to evaluate the efficacy and safety of this product in patients diagnosed with moderate to severe acute rhinosinusitis.

METHODS: A randomized, double-blind placebo-controlled trial was conducted in patients with acute rhinosinusitis. All patients received antibiotics during 8 days as base treatment. Efficacy was assessed at 2 weeks by patient reported symptoms (nasal obstruction, nasal secretion, facial pain, loss of smell) using a visual analogical scale. Mucous oedema and mucopurulent secretion was measured by endoscopy. Patient and Investigator satisfaction with treatment was evaluated. Safety evaluation was performed by reporting adverse events.

RESULTS: 99 patients were randomized (*Cyclamen*:48, Placebo:51). Study groups were homogeneous on demographic and clinical baseline data. The analysis shows statistically significant differences between means of facial pain (-1.2 with CI 95% from -2.3 to -0.1; $p=0,036$). Cure of endoscopic signs was higher ($p=0,043$) in *Cyclamen* (48,7%) than placebo (30,9%). Both patient ($p=0,0327$) and investigator ($p=0,0324$) satisfaction were in favor of *Cyclamen*. No serious or unexpected adverse events were reported.

CONCLUSION: *Cyclamen europeum* is a new therapy suitable in acute rhinosinusitis treatment that has demonstrated its efficacy and safety.

ABSTRACT NUMBER: 1768

ENDOSCOPIC TRANSPHENOIDAL APPROACH TO PETROUS APEX LESIONS

Leela Lavasani, M.D., James Evans, M.D., Gregory Artz, M.D., Marc Rosen, M.D.

INTRODUCTION: Multiple different surgical approaches have been utilized in the past for access to the petrous apex. These include transcochlear and translabrynthine, subcochlear, middle fossa and transethmoidal-sphenoidal approaches. Recently, with the advances made in image-guided endoscopic sinus surgery, minimally-invasive techniques of approaching these lesions has become a viable and safe option when lesions are located in the medial petrous apex. The endoscopic technique is advantageous as it allows for a shorter surgical time, obviates the need for a craniotomy and involves less risk to the facial nerve and otic capsule, while provide a drainage pathway and a easy means of surveillance by nasal endoscopy. This paper will review a series of patients who successfully underwent endoscopic transphenoidal petrous apex surgery. We will also discuss the anatomic considerations and the details of our surgical technique.

METHODS: Retrospective chart review.

RESULTS: We will review a series of five patients over the past three years with petrous apex lesions that were successfully managed via endoscopic techniques. Three of these patients were found to have cholesterol granulomas and two will low-grade chondrosarcomas.

CONCLUSIONS: The endoscopic transphenoidal approach is a safe and minimally invasive technique for the diagnosis and management of lesions of the petrous apex. It should be considered a first line surgical approach to lesions that involve the medial petrous apex.

ABSTRACT NUMBER: 1769

A 24-YEAR EXPERIENCE IN ENDOSCOPIC SURGICAL MANAGEMENT OF SINO-NASAL MUCOCELES

Devyani Lal, MD, Joshua Thom, BS, Jennifer Lavin, BA, Margaret S. Carter, BS, James Stankiewicz, MD

OBJECTIVES: 1. Characterize clinical presentation of sino-nasal mucoceles
2. Study outcomes from mucocele surgery

METHOD: Retrospective chart review of 204 mucocele patients from 1985-2008.

RESULTS: Patients included 105 males and 99 females aged 15 to 85 years. Frontal (38.7%), ethmoid (16.7%) and fronto-ethmoid (12.3%) mucoceles were most common. Headache (37.8%), congestion (30.9%), pressure over involved sinus (22.6%) and facial pain (20.6%) were frequent. Visual disturbances (10.8%), proptosis (9.3%), and periorbital cellulitis (4.4%) were rare. Mucoceles were managed purely endoscopically in 91.2%. Combined endoscopic–open approaches were used in 4.9%, and exclusively open approaches in 3.4%. Follow up ranged from 3 weeks to 10.5 years. Post-operative complications occurred in 6.4%. One case of periorbital cellulitis followed the combined approach. All other complications were associated with endoscopic surgery. Intra-operative cerebrospinal fluid (CSF) leak was repaired in one, and delayed CSF leak fixed in another two patients. Major intra-operative hemorrhage occurred in one patient, who was intubated for 4 days due to mental status changes. Post-operative diplopia occurred in two patients; anosmia and infra-orbital anesthesia were noted in one each. Two patients had epistaxis, one controlled under general anesthesia. Two patients had post-operative MRSA infection requiring intravenous antibiotics. Mucoceles recurred in 17 patients (8.3%). Recurrence was 14.3% with open surgery, 8.1% with endoscopic surgery, and 10% with the combined approach. Surgery for mucocele recurrence was performed in 15 patients, with 13 (87%) done endoscopically.

CONCLUSIONS: The study presents the largest experience in endoscopic surgery for mucoceles. The data confirms that mucoceles can be safely and effectively managed endoscopically. Open approaches are rarely indicated.

ABSTRACT NUMBER: 1775

INCIDENCE OF FONTANEL DEFECTS AND THE TWO HOLES SYNDROME

Ranko Mladina, MD, Katarina Vukovic, MD, Gorazd Poje, MD

INTRODUCTION: Defects in the fontanel region of the lateral nasal wall have been described in the literature as „accessory“ or „secondary“ ostia. The authors consider them a sign of chronic maxillary sinus inflammation. Along with mucus recirculation between the natural ostium and the fontanel defect we call it the Two Holes Syndrome (THS). The aim of this study was to determine the incidence of fontanel defects in patients with chronic sinusitis (CRS) and in healthy subjects.

METHODS: 8879 out-patients with CRS were examined by means of nasal fiberendoscopy. The control group consisted of 1442 healthy volunteers with no previous history of CRS.

RESULTS: defect in the posterior fontanel was found in 1713/8879 CRS patients (19.3 %). It was bilateral in 1165 cases (68.03%). Defect in the anterior fontanel was found in 54 patients (0.61%). The circulating mucus ring was identified in 162 patients with fontanel defects (9.17%). The defect in the posterior fontanel was found in 7/1442 healthy volunteers (0.48%). It was never bilateral, the circulating mucus was not observed and defect in the anterior fontanel was not found.

CONCLUSIONS: posterior fontanel defects were found more frequently in CRS patients than in healthy subjects. These defects have been clinically related to chronic infection of the maxillary sinus and should not be called “accessory” or “secondary” ostia. CRS with defects of the fontanel region and mucus recirculation can promote a number of health disturbances (chronic postnasal drip, headache, cough, alopecia areata, iridocyclitis). We call this entity the Two Holes Syndrome (THS).

ABSTRACT NUMBER: 1777

RADIOLOGIC EVALUATION OF ANTERIOR ETHMOID ARTERY ANATOMY IN THE NON-DISEASED FRONTAL RECESS

Gamwell Rogers, MD, Sarah Wise, MD, Amanda Corey, MD, John DelGaudio, MD

INTRODUCTION: The anterior ethmoid artery (AEA) is an important landmark to the sinus surgeon, with potential for significant complications if injured. This study evaluated AEA anatomy with respect to specific frontal recess structures and drainage pathways.

METHODS: Adult AEA and frontal recess anatomy was evaluated on an imaging workstation on thin-slice (0.625 mm) axial CT scans with triplanar reconstructions. Included CT scans did not have opacification, significant mucosal thickening, or a history of skull base (SB) or frontal recess surgery.

RESULTS: Fifty-four CT scans were reviewed (108 sides). 53/108 sides (49%) demonstrated a mesenteried AEA below the bony SB, with mean distance to the SB of 5.54 mm (range 3.4-9.4 mm, SD 1.6 mm). Supraorbital ethmoid cells (SOE) were observed in 49/108 sides (45%). A mesenteried AEA occurred concomitantly with SOE cells at a rate significantly higher than expected ($p < 0.001$). In 100% of cases, the SOE drainage pathway was anterior to the AEA. With respect to the middle turbinate basal lamella (MTBL) SB attachment, the AEA referenced at the lamina papyracea was anterior to the MTBL in 46/108 sides (43%) and within the MTBL in 58/108 sides (54%). Mesenteried AEA was not significantly associated with presence of an agger nasi cell, fontal cells, or AEA position with respect to the MTBL ($p = NS$).

CONCLUSION: AEA dehiscence and SOE cells were common, and were often seen concurrently. In all cases, SOE cells were noted to drain anterior to the AEA.

ABSTRACT NUMBER: 1778

A COMPREHENSIVE ALGORITHM AND SYSTEMATIC REVIEW FOR ENDOSCOPIC SKULL BASE RECONSTRUCTION

Mihir Patel, MD, Ricardo Carrau, MD, Amin Kassam, MD, Adam Zanation, MD

OBJECTIVES: As endoscopic skull base resections have advanced, the need for reconstruction options have also advanced. The ladder for skull base reconstructions includes avascular grafts, nasoseptal pedicled flaps (NSF), turbinate flaps, and novel endoscopic regional flaps (pericranial or temporoparietal). Given these recent advances, we review the options for reconstruction and provide an algorithm for endoscopic skull base reconstruction.

METHODS: Retrospective review of our skull base reconstructive data and systematic review.

RESULTS: Small CSF leaks may be repaired with avascular grafts with a 95% success rate. Typically repair incorporates sinus obliteration or the use of standard inlayed grafting techniques. The expanded endonasal approaches (EEA) usually have a much larger dural defect and often have high flow leak situations (cistern or ventricle opening). The success rate for EEA procedures using avascular reconstruction approaches 90%, however, in high flow leak situations the success rate is much lower (50-70%). From 150 prospective NS flaps, the NSF has an overall 96% success rate. If an NSF is not available, the anticipated location of the defect guides vascularized flap choice. Anterior and sellar defects are best managed with an endoscopically harvested pericranial flap. Clival and posterior defects may be reconstructed with an inferior turbinate flap or a transposed temporoparietal fascia flap. We discuss a reconstructive algorithm and display the success rates for each technique.

CONCLUSIONS: This review provides a comprehensive overview of the endoscopic reconstructive options and points to the increased use of various vascularized reconstructions for larger or higher complexity skull base defects.

ABSTRACT NUMBER: 1782

DEVELOPMENT OF A CHINCHILLA MODEL TO ALLOW DIRECT, CONTINUOUS IMAGING OF FLUORESCENT NONTYPEABLE HAEMOPHILUS INFLUENZAE DURING EXPERIMENTAL CHRONIC RHINOSINUSITIS

Subinoy Das, MD, Joseph Jurecsek, BS, Glen McGillivray, PhD, Lauren Bakaletz, PhD

OBJECTIVES: Nontypeable Haemophilus Influenzae (NTHI) is a common causative agent of chronic rhinosinusitis (CRS). To improve our ability to study CRS, we endeavored to develop a relevant and robust animal model using the chinchilla host and based on successful protocols developed in our laboratory for modeling otitis media. Herein, we demonstrate the ability to non-invasively monitor NTHI infection within the paranasal sinus cavities of the chinchilla after intranasal challenge via the use of a clinical isolate of NTHI which was modified genetically so that it could be used as a fluorescent reporter.

METHODS: A fluorescent NTHI reporter was constructed by digesting, purifying, and blunt end ligation of a GFP cassette to the outer membrane protein P2 promoter of NTHI. The ligated products were used to transform NTHI 86-028NP. An adult chinchilla (*Chinchilla lanigera*) was then inoculated intranasally with 10^8 CFU of this fluorescent reporter. The chinchilla was sedated and imaged with a Xenogen (TM) IVIS system and a small animal computed tomography (CT) scanner to detect fluorescent NTHI.

RESULTS: After inoculation, fluorescent NTHI were detected within the anterior nares. After 7 days, fluorescence was detected in the ethmoid sinuses, a location that was confirmed with CT scanning. Fluorescence was detectable for up to 28 days post-inoculation.

CONCLUSIONS: This model represents a significant improvement in our ability to non-invasively study CRS using a rodent host. We expect that future studies will allow us to monitor biofilm formation by NTHI within the sinuses and test molecular therapies aimed at therapeutic biofilm resolution.

ABSTRACT NUMBER: 1784

ENDOSCOPIC MANAGEMENT OF SPENOCLIVAL NEOPLASMS: ANATOMIC CORRELATES AND PATIENT OUTCOMES

Clementino Solares, MD, Amber Luong, MD, Martin Citardi, MD, Pete Batra, MD

INTRODUCTION: The sphenoclivar region poses a significant surgical challenge given the central location at the skull base and proximity to critical structures. The advent of minimally invasive endoscopic techniques has greatly facilitated management of pathology in this location.

MATERIALS & METHODS: Fresh-frozen cadaver heads were dissected to study the endoscopic anatomy of the sphenoclivar region. Retrospective chart review was performed of patients undergoing endoscopic resection of sphenoclivar neoplasms between 2000 and 2008.

RESULTS: Transnasal endoscopic access to the sphenoid sinus was obtained in 10 cadaver heads. A clival window with mean dimensions of 1.4 cm x 1.7 cm was created. Through the clival window, identification and dissection of the basilar and vertebral arteries, mamillary bodies, third ventricle and cranial nerves III-VI, IX, X, XI and cervical rootlets were possible. Twenty-two patients with mean age of 58 years were treated. The most common pathologies were chordomas (5), inverted papillomas (5), squamous cell carcinoma (2), and adenoid cystic carcinoma (2). All patients were managed endoscopically with surgical navigation with neurosurgical standby or involvement. None of the patients required adjunct craniotomies. Twelve patients received adjuvant therapies. The mean follow-up was 26 months.

CONCLUSIONS: The anatomy of the central skull base is complex and intimate knowledge is an absolute prerequisite prior to considering surgery in this region. This study demonstrates that transnasal endoscopic access to the sphenoclivar region is technically feasible and allows for successful surgical extirpation of tumors, obviating the need for a craniotomy.

ABSTRACT NUMBER: 1785

TREATMENT-RECALCITRANT CHRONIC RHINOSINUSITIS WITH POLYPS IS ASSOCIATED WITH ALTERED EPITHELIAL CELL EXPRESSION OF INTERLEUKIN-33

Andrew Lane, MD, Yadong Wang, BA, Douglas Reh, MD, Leda Pawliuk, BA

INTRODUCTION: Abnormalities in host mucosal immunity exist in CRSwNP, but it is unclear whether this is a cause or an effect of the eosinophilic inflammation and frequent microbial colonization that characterizes the disease. Sinonasal epithelial cells are critical participants in healthy anti-microbial innate immune defense. They also can promote Th2 inflammation with various mediators, including IL-33, which induces T helper cells to produce Th2 cytokines.

METHODS: CRSwNP sinonasal epithelial cells were obtained during sinus surgery and stored. Patients were subsequently classified as either treatment-responsive or treatment-recalcitrant, based on long-term outcomes of medical and surgical therapy. Epithelial cells from these patients were grown in air-liquid interface culture and treated with interleukin-13, as well as the bacteria-associated molecule, CpG. Expression of interleukin-33 mRNA was determined by real-time PCR.

RESULTS: Recalcitrant CRSwNP epithelial cells had increased baseline expression of IL-33 compared to responsive CRSwNP, which was further increased by 24 hour exposure to CpG. Treatment-responsive epithelial cells were not induced by CpG to express IL-33. Prolonged treatment with IL-13 during differentiation at the air-liquid interface diminished the baseline expression of IL-33 and prevented the subsequent induction of IL-33 by CpG.

CONCLUSIONS: Mucosal innate immunity likely plays an important role in CRSwNP pathogenesis. A definitive link between infectious triggers and the development of Th2 inflammation has been elusive. We have found constitutive IL-33 expression by sinonasal epithelial cells in recalcitrant CRSwNP, which can be further induced by a bacteria-associated molecular pattern. Dysregulated epithelial cell immune interactions between host and environment may contribute to Th2 inflammation in CRSwNP.

ABSTRACT NUMBER: 1786

CONCURRENT RESECTION OF PITUITARY ADENOMA AND PLANUM SPENOIDALE MENINGIOMA IN A PATIENT WITH CUSHING'S DISEASE: A CASE REPORT

Gopi Shah, MD, Marc Rosen, MD, Christina Mitchell, MD, James Evans, MD, Serge Jabbour, MD

BACKGROUND: The endoscopic approach to pituitary tumors has been well described in the literature and has become the preferred operation at many centers. Endoscopic resection of anterior skull base meningiomas still remains controversial. The coexistence of these two lesions provides an opportunity for simultaneous resection through an endoscopic approach.

CASE REPORT: We report a case of a 42 year old female who presented with a history of Cushing's disease, dysgeusia, nasal obstruction and visual disturbance. On imaging, she was found to have a pituitary microadenoma and a 2.7x2.1x1.3cm planum sphenoidale meningioma.

OPERATIVE TECHNIQUE: Using neuronavigation, an endoscopic transnasal resection of an ACTH-producing pituitary tumor was accomplished. This was followed by posterior ethmoidectomy and planum sphenoidale drill-out for intradural resection of meningioma. Repair of the dura was accomplished by fasciae late harvest, and repair of the skull base defect was accomplished by elevation of a nasoseptal pedicled vascularized flap.

DISCUSSION: Endoscopic transphenoidal approach for the simultaneous resection of a pituitary microadenoma and a meningioma is rare, and can be performed with favorable outcomes. Furthermore, the indications and limitations of this single endoscopic approach will be discussed as well as the effect of Cushing's disease on the healing and morbidity of endoscopic transphenoidal surgery.

ABSTRACT NUMBER: 1787

LARGE B-CELL LYMPHOMA OF THE FRONTAL SINUS: A CASE REPORT

Gopi Shah, MD, Marc Rosen, MD, James Evans, MD

OBJECTIVES: Isolated B cell Lymphoma of the frontal sinus is rare, and few cases have been reported. The goal of this presentation is to review a case of a large cell lymphoma found in the frontal sinus presenting initially as chronic rhinosinusitis and subsequently osteomyelitis with erosion of the posterior table of the frontal sinus.

CASE REPORT: We report a case of a 22 year old male who was treated with a functional endoscopic sinus surgery for frontal sinusitis and subsequent frontal sinus obliteration through a bicoronal approach for osteomyelitis. Symptoms of headache and frontal bone swelling continued to persist despite multiple courses of intravenous antibiotics. He was referred to our institution three months after the second surgery. At this time, an MRI showed abnormal signal within the right frontal bone and epidural enhancement extending into the right inferior frontal lobe consistent with infection. A CT showed mottled

appearance of the frontal bone. Both images were consistent with frontal bone osteomyelitis associated with reactive edema or cerebritis, and erosion of the posterior table of the frontal sinus. An endoscopic Draf Type III bilateral frontal drill out with intraoperative neuronavigation was performed. Pathology revealed benign respiratory mucosa with chronic inflammation and focal fat necrosis in the frontal sinus. Several weeks post-operatively, the patient returned with headache, forehead swelling, and tenderness. He was treated with oral antibiotics without improvement. However, his symptoms improved greatly after a course of oral steroids. A bone scan was negative for osteomyelitis. Repeat imaging revealed the frontal sinus outflow tract had narrowed significantly. A revision endoscopic frontal drill out was performed and routine biopsies were taken. Final pathology revealed a large B-cell lymphoma of the frontal sinus.

DISCUSSION: The diagnosis of B cell lymphoma explains this patient's improvement on steroids despite his poor response to aggressive sinus surgery and antibiotics. The unusual occurrence of a B- cell lymphoma or other neoplasm should be considered when an inflammatory process of the frontal sinus fails to respond to aggressive therapy. The importance of biopsy will be addressed. In addition, erosion of the posterior table and obliteration in the management and workup of posterior table defects will be discussed.

ABSTRACT NUMBER: 1788

AIRWAY MANAGEMENT AND PERIOPERATIVE CONCERNS SURROUNDING ENDOSCOPIC SURGERY FOR PITUITARY TUMORS IN ACROMEGALY PATIENTS

Douglas Johnston, MD, Marc Rosen, MD, James Evans, MD

OBJECTIVES: The purpose of this article is to review perioperative and airway concerns in acromegalic patients for the skull base surgeon in order to reduce preventable perioperative complications.

STUDY DESIGN: Review of comprehensive skull base surgery database and literature review.

SETTING: Tertiary Care Hospital

PARTICIPANTS: 19 patients with acromegaly

MAIN OUTCOME MEASURES: Literature review, airway management strategies, cardiovascular and respiratory comorbidities.

BACKGROUND: Patients with acromegaly present unique challenges to skull base surgery and anesthesia teams in the perioperative period, especially with regard to airway management. Abnormal airway anatomy may result from soft tissue hypertrophy and bony alterations. Additional perioperative challenges relate to the management of medical comorbidities and specific surgical technical issues.

RESULTS: Glide scope intubation (video assisted direct laryngoscopy) was required in 7/19 patients (36.8%) and fiberoptic intubation in 3/19 patients (15.8%). Cardiovascular comorbidities (hypertension and conduction abnormalities predominated) were present in 12/19 patients (63.1%) and obstructive sleep apnea, or other respiratory conditions existed in 11/19 patients (57.9%).

CONCLUSIONS: The views presented herein are based on the collective experience of otolaryngologists and neurosurgeons at a dedicated skull base center with several hundred endoscopic skull base surgeries. Pre-operative preparation and perioperative awareness of the challenges of acromegalic patients is essential in successful endoscopic skull base surgery in this unique population.

ABSTRACT NUMBER: 1790

REVISION RHINOPLASTY FOR CORRECTION OF DEVIATED NOSE

Yong Ju Jang, M.D.

BACKGROUND: Revision rhinoplasty for deviated nose carries special challenges both for patients and surgeon. Despite the complexity in managing this problem, there is paucity of available literature addressing revision surgery for deviated nose. Therefore, the author will present our experience in revision rhinoplasty, and will suggest a management strategy for this type of patients.

METHODS: Sixty-two patients who underwent revision rhinoplasty for correction of deviated nose between Jan 2003 and July 2008 were retrospectively reviewed. The medical records were analyzed with regard to the specialty of the primary surgeon, grafts used, techniques applied and surgical outcomes. Preoperative and postoperative photographic analysis was performed. Postoperative results were evaluated by two otolaryngologists. Patient's satisfaction was also assessed.

RESULTS: Forty-three patients (69.4%) had previous septoplasty in primary surgery and in 17 of them an additional harvesting of septal cartilage was possible leaving enough L-strut to support septal cartilage framework. When additional grafting for straightening and strengthening the cartilaginous framework was required, autologous costal cartilage was used in 30 cases and homologous costal cartilage was selected in 15 cases. Dorsal augmentation was performed in all 62 patients. In the objective assessment of surgical outcome by independent surgeons, Surgical outcomes were classified as the following; "completely corrected (n = 50)" and "corrected but residual deviation (n = 12)".

CONCLUSIONS: For a successful correction of deviated nose in revision, reconstruction of the septal cartilage framework using septal or costal cartilage is of critical importance. Dorsal augmentation using adequate graft material was required in revision rhinoplasty.

ABSTRACT NUMBER: 1791

CLASSIFICATION AND TREATMENT OUTCOME OF CONVEX NASAL DORSUM DEFORMITY IN ORIENTALS

Ji Heui Kim, M.D., Ji-Sun Kim, Hyung-Min Song, Yong Ju Jang

BACKGROUND: The degree and types of convex nasal dorsum deformity on profile view varies greatly among patients requiring their dorsal hump correction. The authors would suggest a classification system of dorsal hump and its treatment outcome according to the different types of deformity.

METHODS: Ninety-three patients (62 men, 31 women) who underwent rhinoplasty for the correction of convex nasal dorsum deformity from January 2003 to July 2007 were analyzed. By anthropometric measurements of proportional length of hump base and tip height with regard to the nasal length, the convex nasal dorsum was classified into three types: generalized hump, isolated hump, and relative hump with low tip. The postoperative photographic analysis was performed by two independent rhinoplastic surgeons.

RESULTS: Of the 93 patients, 51 (54.8%) had generalized hump, 38 (40.9%) had isolated hump, and 4 had relative hump with low tip. When we compared the surgical techniques required for proper management between the generalized hump and isolated hump group, open approach was used in 92% of generalized hump and in 79% of isolated hump. Osteotomies were conducted in 92% of generalized hump and in 82% of isolated hump. Open roof deformity was closed using spreader grafts in 78% of generalized hump and in 55% of isolated hump. Successful surgical outcome was achievable in 65% of generalized hump, but in 84% of isolated hump.

CONCLUSIONS: Our classification system could help surgeon for tailored management of convex nasal dorsum deformity. Generalized hump needs to be reduced more aggressively to have better surgical outcome.

ABSTRACT NUMBER: 1792

TECHNICAL MODIFICATIONS OF THE PEDICLED NASOSEPTAL FLAP FOR ENDONASAL SKULL BASE RECONSTRUCTION

Amol Bhatki, M.D., Annie Lee, M.D., Carl Snyderman, M.D., Ricardo Carrau, M.D.

OBJECTIVES: The introduction of the expanded endonasal approach to the ventral skull base has posed new challenges for the repair of the resultant skull base defects. The Hadad-Bassagasteguy (HB) pedicled nasoseptal flap has become the cornerstone for providing a reliable, watertight reconstruction. Technical modifications of the HB flap increase its versatility and allow it to accommodate specific skull base defects. This paper reviews the specific anatomy and technique of the HB flap, and also presents our experience with its technical variations.

METHODS: The anatomy and technique of the HB flap was initially studied in cadavers and, later, tested in an extensive clinical experience of over 300 endonasal skull base procedures in 3 years. Modifications have evolved over this experience and data was collected prospectively.

RESULTS: Technical variations include augmentation of the mucosal paddle, adjustments for septal perforations, and strategies to increase reach. Large defects following endoscopic transcribriform resection (n=47) require anterior extension while a bifid flap (n=6) may be used to remucosalize a transsphenoid fenestration of a petrous cho-

lesterol granuloma. Also, the “rescue” flap provides a more conservative technique that allows for the preservation of the flap pedicle and septal mucosa during tumor exposure so that it may be used only if arachnoid penetration occurs.

CONCLUSION: The HB nasoseptal flap is the workhorse for endonasal skull base reconstruction. Technical modifications increase the versatility of this flap without compromising the reliability. Furthermore, variations of this technique may help overcome anatomical obstacles and also provide reconstruction for especially challenging defects.

ABSTRACT NUMBER: 1794

LUMBAR DRAIN UTILIZATION IN ENDOSCOPIC SKULL BASE SURGERY

Ameet Singh, MD, Seth Brown, MD, Gurston Nyquist, MD, Vijay Anand, MD

INTRODUCTION: Lumbar drains are utilized to prevent post-operative cerebrospinal fluid (CSF) leaks and promote skull base healing by decreasing CSF volume and pressure. Inherent risks include headaches, prolonged immobility, pneumocephalus and herniation. The goal was to study patient and tumor characteristics which prompted pre-operative drain placement, report complications, and ascertain predictors of post-operative leaks.

METHODS: A retrospective review of 234 patients undergoing endoscopic skull base surgery was performed. Patient characteristics, tumor type and size, duration of surgery, and complications were analyzed. Pivot table and statistical analysis was performed.

RESULTS: Pre-operative drains were placed in 60 of 234 (25%) patients with preferential placement in patients with higher BMIs (31 vs 27.8), female gender (40 vs 20), and larger tumors (2.81 vs 2.15cm). Drains were more commonly placed in patients with meningiomas, encephaloceles and craniopharyngiomas. Sixteen of 234 (7%) patients had post-operative CSF leaks, 8 of whom had pre-operative drains. Among leak patients, surgery duration (260 vs 176min) and tumor dimension (2.92 vs 2.13cm) were statistically higher in patients with pre-operative drains. Eighty seven percent (14/16) of patients with post-operative leaks were successfully managed with lumbar drain, bedrest, and stool softeners. A trend toward increased leakage in patients with meningiomas, encephaloceles, expanded approaches, larger tumors, and higher BMIs was noted.

CONCLUSIONS: Patients with non-sellar lesions, larger tumors, female gender and a higher BMI received preferential lumbar drains pre-operatively. This is likely secondary to anticipation of a complex resections, larger defects, and higher CSF pressure. No statistically significant predictors of post-operative CSF leak were found.

ABSTRACT NUMBER: 1797

SINUS SPACER: A PRELIMINARY ANALYSIS OF EFFICACY & SAFETY

Mark Thong, MD, Vincent Chan, MD, Ray Weiss, MD, Peter Catalano, MD

INTRODUCTION: Standard surgical treatment for chronic inflammatory disease of the ethmoid sinus is endoscopic ethmoidectomy. A new surgical tool, the Sinus Spacer, was recently introduced into clinical practice as an option for minimally invasive treatment of chronic ethmoid mucosal disease. This device is easily and temporarily implanted into the ethmoid complex to enable local targeted delivery of a therapeutic agent for a sustained period of time. The device is easily removed in the office setting. The aim of this study is to evaluate the preliminary outcomes and safety of this device.

METHODS: A prospective study involving 23 patients (a total of 40 ethmoid sinuses) treated with the Sinus Spacer infused with triamcinolone, and followed for 6-months. Outcomes were assessed by interval changes in 20-item Sino-Nasal Outcome Test (SNOT-20) and Lund-Mackay CT scores, respectively. Safety was determined by adverse events.

RESULTS: Overall, the pre-op SNOT-20 mean score was 2.07, versus post-op score of 0.97, an improvement of 1.10 ($p < 0.001$). Pre-op Lund-Mackay mean score was 5.33, compared with post-op score of 2.91, an improvement of 2.42 ($p < 0.001$). When ethmoid sinuses were specifically evaluated, pre-op Lund-Mackay ethmoid score was 1.73, versus post-op score of 1.00, an improvement of 0.73 ($p < 0.001$). There were no intra-op or post-op complications encountered.

CONCLUSIONS: The Sinus Spacer appears safe and effective in treating chronic ethmoid sinus disease. The ability to deliver medication directly to diseased mucosa holds wide-ranging potential.

ABSTRACT NUMBER: 1798

CLINICAL PROTOCOL FOR ENDONASAL SKULL BASE RECONSTRUCTION—THE PITTSBURGH ALGORITHM

Annie Lee, MD, Amol Bhatki, MD, Carl Snyderman, MD, Ricardo Carrau, MD

OBJECTIVES: The introduction of the expanded endonasal approach to the skull base has posed new challenges for the repair of the resultant defect. The evolution of vascularized, pedicled tissue flaps has dramatically increased the reliability and durability of the reconstruction of more extensive defects. This paper reviews the anatomical and technical details of several vascularized flaps and presents an algorithm for their use in skull base reconstruction.

METHOD: These flaps were initially developed in cadavers and then clinically tested in an extensive experience of over 300 cases. An algorithm has evolved as new techniques became available and were incorporated into the clinical experience.

RESULTS: The following flaps provide reconstructive options for a wide range of skull base defects. The nasoseptal flap ($n=220$) serves as the workhorse because of its generous size and large arc of rotation. If the nasoseptal flap is unavailable, a posteriorly-based inferior turbinate flap ($n=11$) is a viable option for clival defects, while a posteriorly-based middle turbinate flap ($n=5$) may be used for sellar and planum sphenoidale defects. The endoscopic pericranial flap ($n=7$) and the transpterygoid temporo-parietal flap ($n=4$) may provide coverage of larger cribriform/planum defects, and planum, sella or clivus defects, respectively. Lastly, the Oliver palatal flap can serve to reconstruct defects of the planum, sella, and clivus when other options are unavailable.

CONCLUSIONS: There are various vascularized flaps that may be utilized for the skull base reconstruction after expanded endonasal surgery. Although the nasoseptal flap is often adequate, endonasal skull base surgeons should be familiar with alternative reconstructive options.

ABSTRACT NUMBER: 1800

ENDOSCOPIC REPAIR OF EXPANDED ENDONASAL SKULL BASE DEFECTS USING A STABLE BILAYER “BUTTON” CLOSURE

Marc Rosen, MD, Adam Luginbuhl, MD, James Evans, MD

INTRODUCTION: As experience with the expanded endonasal approach to the skull base has grown, larger and more difficult lesions have been approached. One of the greatest problems to date with the technique has been the closure of the skull base defects and prevention of post-operative CSF leaks. Even with the advent of mucoperiosteal vascularized flaps, such as the pedicle septal flap, which have revolutionized the closure, the skull base repair still begins with a direct repair of the dural defect. This closure is still the first line in the maintenance of a barrier between the intracranial and intranasal spaces. A problem with placing inlay (intradural) and onlay (epidural) dural grafts is the migration of the inlay graft away from the defect prior to healing. Factors affecting graft migration may include physiological and gravitational forces. Many innovative techniques have been described to stabilize these grafts, including compression balloon catheters, “gaskets”, and packing. In our experience, the majority of postoperative leaks and reoperation were found to be related to migration of the graft leaving a gap in the dural repair.

SURGICAL TECHNIQUE: The “button” is constructed so that the inlay portion is at least 25% larger than the dural defect and the onlay portion is just large enough to cover the dural defect. The two grafts are sutured together using two to four #4-0 neuroton sutures depending on the size of the grafts. The graft is then endoscopically placed with the inlay portion intradurally and the onlay portion extradurally with the edges of the graft flush with the respective dural surface. If needed, a septal flap, turbinate flap, or free mucosal graft can be used to reinforce the repair.

RESULTS: The benefit of this new technique is the lack of migration of the inlay graft away from the dural defect. The “button” technique seems superior to previous attempts of securing the inlay graft with biological glue, which can actually act as a barrier to graft ingrowth/healing and mucosalization. We have utilized synthetic collagen grafts to perform the “button” repair for pituitary macroadenomas with CSF leaks. For intradural endonasal procedures with open basal cisterns or third ventricle, we utilize autologous fascia to make a “button” repair. This button technique seems to eliminate the need for additional structural support from balloon catheters or fat packing. We have used the button graft in 14 patients to date that have large dural defects for craniopharyngioma, meningioma and chordoma resections and our leak rate has dropped to below 20% and when combined with the mucoperiosteal vascularized flaps ($n=10$) our leak rate has been 0%.

CONCLUSION: This series of button graft repairs as compared to reconstruction methods during the previous two years where the leak rate approached 60% for large resections is a promising technique for reducing our complications rates.

ABSTRACT NUMBER: 1801

PROSPECTIVE EVALUATION OF 70 NASOSEPTAL FLAPS FOR ENDOSCOPIC RECONSTRUCTION OF HIGH FLOW INTRAOPERATIVE CSF LEAKS DURING ENDOSCOPIC SKULL BASE SURGERY

Adam Zanation, MD, Carl Snyderman, MD, Ricardo Carrau, MD, Amin Kassam, MD

INTRODUCTION: Over the past 10 years, significant anatomic, technical and instrumentation advances have facilitated the exposure and resection of intradural lesions via a fully endoscopic expanded endonasal approach (EEA). The vascularized nasoseptal flap (based on the posterior nasoseptal artery) has become our primary endoscopic reconstructive technique. The goals of this study are to prospectively evaluate the nasoseptal flap and high risk CSF leak variables.

METHODS: Prospective evaluation EEA patients with intraoperative high flow leaks (either a cistern or ventricle open to nasal cavity during tumor dissection) who underwent nasoseptal flap reconstruction.

RESULTS: Seventy consecutive nasoseptal flaps for high flow intraoperative leaks were evaluated prospectively by the primary author. Twelve risk factors were then graded at the time of the operations and correlated to CSF leak outcomes. The overall post operative CSF leak rate was 5.7% (4/70). All four post operative leaks were successfully managed with endoscopic repair and CSF diversion. A multivariate analysis of all 12 risk factors is detailed. Pediatric patients, large dural defects and radiation therapy were noted to be factors in reconstructive failure. One flap death occurred in a patient with prior surgery and proton therapy, this leak was managed with a temporoparietal flap and endonasal repair.

CONCLUSIONS: The nasoseptal flap is an excellent anterior skull base reconstructive technique. Patients with high flow intraoperative CSF leaks had a 94% successful reconstruction rate. Patients with skull base proton radiation therapy are at higher risk for flap failure and preparation for non radiated tissue reconstruction should be discussed with the patient.

ABSTRACT NUMBER: 1802

ENDOSCOPIC MANAGEMENT OF CEREBROSPINAL FLUID LEAKS OF THE SPHENOID SINUS

Annie Lee, MD, Amol Bhatki, MD, Carl Snyderman, MD, Ricardo Carrau, MD

OBJECTIVE: To illustrate a single institution's experience of endoscopic repair of cerebrospinal fluid (CSF) leaks in the sphenoid sinuses with specific details regarding intraoperative and post-operative management strategies.

METHODS: Retrospective review of medical records was performed on patients who underwent endoscopic repair of CSF leaks of the sphenoid sinus in a tertiary care medical center between July 1998 and December 2007.

RESULTS: Twenty-seven patients who underwent endoscopic repair of CSF leaks of the sphenoid sinuses were included in this study. The causes of CSF leaks included posttraumatic, spontaneous, and iatrogenic causes. A transpterygoid approach was utilized in 10 patients. The sinuses were obliterated in 18 cases (67%). Layered reconstruction using banked pericardium, cadaveric dermal allograft, or collagen dural graft matrix was used in 18 cases (67%) and a pedicled nasoseptal flap was used in 9 cases (33%). Four patients had persistent or

recurrent CSF leak necessitating a revision repair. Fourteen patients had a lumbar drain placed following their repair. All of these patients underwent a lumbar puncture 24 hours after the removal of the drain with subsequent ventriculoperitoneal shunting if the opening pressure exceeded 20cm H₂O. Four patients had a shunt placed according to this algorithm.

CONCLUSION: Endoscopic repair of the sphenoid sinus CSF leak is a highly successful approach. The repair strategies evolved towards vascularized pedicled flap as our experience with skull base reconstruction grew. Also, an algorithm was developed to quickly recognize and efficiently treat those patients with high-pressure hydrocephalus as the cause of their CSF leak.

ABSTRACT NUMBER: 1804

COMPARISON OF DISEASE-SPECIFIC QUALITY OF LIFE INSTRUMENTS IN THE ASSESSMENT OF CHRONIC RHINOSINUSITIS

Jamie Litvack, MD, MS, Timothy Smith, MD, MPH

INTRODUCTION: Multiple disease-specific quality of life (QOL) instruments exist for chronic rhinosinusitis (CRS), leading to confusion about the potential role and application of each instrument. The purpose of this study was to compare two instruments, the Rhinosinusitis Disability Index (RSDI) and the Chronic Sinusitis Survey (CSS). The results are discussed in the context of a review of the validated disease-specific QOL instruments in the CRS literature and the strengths and weaknesses of various approaches.

METHODS: 481 patients from a multi-institutional prospective cohort study were examined. Pearson's correlation coefficients between two instruments, the RSDI and CSS, were calculated. A systematic review of the adult English-language literature was then performed using MEDLINE to identify the types and frequencies of disease-specific QOL instruments currently available and to determine the validity, reliability and sensitivity to change of each instrument.

RESULTS: Total RSDI and physical RSDI subscale moderately correlated with CSS symptom scores ($r=0.44$, $r=0.54$; both $p<0.001$); physical RSDI also moderately correlated with CSS total score ($r=0.41$; $p<0.001$). RSDI did not correlate with CSS medication scores (all $r\leq 0.12$). Patients with asthma, allergy, and aspirin intolerance reported worse disease-specific QOL whereas patients with nasal polyposis reported better QOL. The three most frequently referenced validated disease-specific QOL instruments in the adult CRS literature were the Sinonasal Outcome Test (SNOT-20), CSS, and RSDI. Several other instruments also exist; many are modifications to older measures.

CONCLUSIONS: Disease-specific QOL is an important and informative measure of CRS. Different instruments provide complementary information regarding patients' disease experience.

ABSTRACT NUMBER: 1805

ENDOSCOPIC TRANSSPHEOIDAL APPROACH TO CRANIOPHARYNGIOMAS

Adam Luginbuhl, MD, Scott Troob, Brian McGettigan, MD, Marc Rosen, MD

INTRODUCTION: The following is our experience with endonasal resection of craniopharyngiomas.

METHODS: The TJUH Minimally Invasive Cranial Base Center database and surgical pathology database were queried for all patients who underwent endoscopic resection of craniopharyngiomas. Inclusion criteria included pure endoscopic endonasal resection and planned second stage procedures after a craniotomy approach. Completeness of tumor resection was determined by surgeon-input and postoperative MRI.

RESULTS: The final patient population consisted of 13 patients who underwent a total of 14 transnasal transsphenoidal (endonasal) endoscopic resection of craniopharyngiomas from November 2005 to June of 2008. Of the 13 patients, 3 had previous resections of the tumor by frontotemporal (N=2) or temporal (N=1) craniotomy. One patient with a >10 centimeter, calcified craniopharyngioma underwent endonasal resection as a planned second stage procedure to an interhemispheric, transcallosal approach. Ninety three percent (13/14) of the patients presented with visual complaints and 11 of those 13 (85%) had visual improvements after surgery. Based on surgical observation and post op MRI resection was considered complete in 4/14 cases. In the remaining 10 cases gross residual tumor was left unresected, due to its adherence to critical neurovascular structures. Of the 14 surgical procedures that were performed, 8 were free of postoperative complications. The remaining 6 patients developed CSF leaks which resolved with immediate surgical repair and/or temporary lumbar drains. One of these patients required a VP shunt for hydrocephalus. Preoperative diabetes insipidus was present in 4/14 cases. None of these cases had resolution of DI postoperatively and of the 10 cases with no preoperative DI only one went on to have persistent DI at time of discharge. No vascular injuries or deaths occurred in this series.

CONCLUSIONS: Endonasal resection of craniopharyngiomas can provide equivalent or better results to the traditional approaches to these challenging tumors. Compared to historic controls, we feel that the endonasal approach can provide excellent resections, shorter hospital stays, and minimal long term complications. With experience, the degree of tumor resection and of successful cranial base repair without CSF leak both improve. As the technology, instruments, and the collective experience with endonasal surgery advances, this technique will likely become the primary surgical means of treating craniopharyngiomas.

ABSTRACT NUMBER: 1806

“GASKET-SEAL” RECONSTRUCTION OF THE SELLAR FLOOR USING NON-AUTOLOGOUS MATERIAL IN REVISION ENDOSCOPIC PITUITARY SURGERY

Abtin Tabaei, MD, Raj Shrivastava, MD

INTRODUCTION: A variety of techniques and materials for reconstruction of the sellar floor following endoscopic pituitary surgery have been described. Reconstruction in the setting of revision surgery, high volume intraoperative cerebrospinal fluid (CSF) leak and large skull base defect represents a unique challenge.

METHODS: The medical records of three patients undergoing revision endoscopic pituitary surgery with high volume intraoperative CSF leak and a large skull base defect are described. Reviewed are the

patient and tumor demographics and outcomes at last follow up. The “gasket-seal” technique of sellar repair using non-autologous material is described.

RESULTS: The indications for surgery were macroadenoma with suprasellar extension and optic nerve compression in 2 patients and growth hormone secreting tumor (acromegaly) in 1 patient. All patients underwent a multilayered closure consisting of autologous fat placed in the tumor cavity followed by reconstruction of the sellar floor with an oversized sheet of acellular dermal matrix placed over the skull base defect and sunken into the sella with a bioabsorbable miniplate. No patients underwent perioperative lumbar drainage. There were no instances of postoperative CSF leak and all patients remained free of leak at follow up. Postoperative nasal endoscopy revealed a well mucosalized sphenoid sinus in all patients.

CONCLUSION: Sellar reconstruction following endoscopic pituitary surgery represents an ongoing technical challenge. A robust closure is especially required in revision cases with high volume intraoperative CSF leak. The early experience with the “gasket-seal” closure using non-autologous material appears favorable.

ABSTRACT NUMBER: 1807

LOCAL MUCOSAL FLAPS IN THE MANAGEMENT OF POST-SPHENODOTOMY STENOSIS

John Lee, MD, Jayakar Nayak, MD, Alexander Chiu, MD

BACKGROUND: Traditional endoscopic techniques at enlarging the natural sphenoid ostium is an effective procedure for the majority of sphenoid sinus disease. However, in the background of significant bony inflammation or infection, post sphenoidotomy stenosis can be a difficult long term problem to manage and treat.

OBJECTIVE: To describe our technique of using local mucosal flaps in the management and prevention of post-sphenoidotomy stenosis.

METHODS: This was a prospective study of patients undergoing our described procedure in the Division of Rhinology at the University of Pennsylvania. Patient etiologies, intra-operative findings, as well as long term sphenoid patency rates were recorded.

RESULTS: We will first describe our technique of using local flaps in the prevention and management of post-sphenoidotomy stenosis (video). Indications for this procedure in our series of patients included sphenoid neo-osteogenesis and fungal mycetoma. This procedure resulted in decreased crusting in the post-operative period while achieving 100% long term patency rates.

CONCLUSION: The use of local mucosal flaps appears to be an effective technique at managing and preventing the development of post-sphenoidotomy stenosis.

ABSTRACT NUMBER: 1808

LIMITATIONS OF THE PEDICLED NASOSEPTAL FLAP FOR ENDOSCOPIC RECONSTRUCTION OF TRANSELLAR SKULL BASE DEFECTS IN PEDIATRIC PATIENTS

Rupali Shah, MD, Ricardo Carrau, MD, Carl Snyderman, MD, Adam Zanation, MD

INTRODUCTION/PURPOSE: Retrospective data has shown an overall 11% postoperative CSF leak following expanded endoscopic approaches (EEA) in pediatric patients. Anecdotal data by the senior author revealed a limitation in flap size in the youngest patients. We discuss the limitations of the nasoseptal flap reconstruction for transsellar defects in pediatric patients.

METHODS: In a prospective series of 150 nasoseptal flaps, four pediatric patients were identified who underwent transsellar EEA with nasoseptal flap reconstruction. Patients were analyzed for intraoperative available flap area compared to defect size and defect coverage. In addition, age stratified radioanatomic correlations were performed in 50 CT scans.

RESULTS: Clinical data revealed inadequate flap coverage of transsellar defects in patients <12 years; this was significant ($p < 0.05$) in comparison to a cohort of patients 13-20 years old and in adult patients (>20 years). Radioanatomic data revealed septal length to be smaller than potential sphenoidal/transsellar defect length in patients < 7 years. Rate of septal growth is highest between 10 and 13 and the ratio of septum to the largest anterior skull base defect is over 1.0 after the age of 13/14.

CONCLUSIONS: The nasoseptal flap may be inadequate for reconstruction of endoscopic transsellar defects in the youngest children (<7 years old—high risk and 7-13—intermediate risk). In these cases, preoperative counseling with parents is critical and the patient should be consented for fat bolstering if needed. The effect of the nasoseptal flap on craniofacial growth has not yet been determined but is a consideration and should be discussed preoperatively.

ABSTRACT NUMBER: 1810

OUTCOME RESULTS OF ENDOSCOPIC VERSUS CRANIOFACIAL RESECTION OF SINONASAL MALIGNANCIES: A POOLED-DATA ANALYSIS

Thomas Higgins, MD, Brian Thorp, BS, Brad Rawlings, MD, Joseph Han, MD

INTRODUCTION: Endoscopic approaches to the management of sinonasal malignancies are now being described. This study aims to conduct a systematic review with a pooled-data analysis to compare outcomes of endoscopic versus craniofacial resection of sinonasal malignancies.

METHODS: A search was conducted of MEDLINE (1966 to 2008), EMBASE (1980 to 2008), Cochrane Central Register of Clinical Trials (CENTRAL), Cochrane Database of Systematic Reviews, clinicaltrials.gov, and The National Guideline Clearinghouse databases and supplemented by references in retrieved articles. All authors used a detailed list of inclusion and exclusion criteria to determine articles eligible for final inclusion. The authors extracted data regarding study criteria appraisal, sinonasal malignancy characteristics, survival outcomes, and recurrence. Kaplan-Meier survival and locoregional control rates were calculated and compared using the Log-rank test.

RESULTS: Of the 2,314 citations reviewed, the search yielded 15 case series with individual data on 226 patients. The most common

malignancies were esthesioneuroblastoma (47%), adenocarcinoma (24%), and undifferentiated carcinoma (22%). The overall 5-year survival rate for the sample was 56.5% (SE ± 3.8). Among low-stage malignancies (T1-2 or Kadish A-B), the endoscopic and open approaches demonstrated no statistically significant difference in outcome results. The 5-year overall survival was 87.4% (SE ± 5.3) in the endoscopic group versus 76.8% (SE ± 8.3) for open approaches [$P = 0.351$]; disease-specific survival was 94.7% (SE ± 3.7) versus 87.7% (SE ± 6.7) [$P = 0.258$]; and locoregional control rate was 89.5% (SE ± 5.0) versus 77.2% (SE ± 10.4) [$P = 0.251$].

CONCLUSION: Transnasal endoscopic resection appears to be a reasonable alternative to craniofacial resection in the management of low-stage sinonasal malignancies.

ABSTRACT NUMBER: 1814

AN INITIAL CLINICAL EVALUATION OF A THREE DIMENSIONAL ENDOSCOPE SYSTEM FOR ENDOSCOPIC SINUS AND SKULL BASE SURGERY

Adam Zanation, MD, Rupali Shah, MD, William Leight, MD, Anand Germanwala, MD

PURPOSE: As endoscopic surgery has progressed into the realm of skull base surgery, one criticism is that the 2D endoscope does not allow for microneurovascular dissection like the open microscopic approaches. Recently, advances have been made to improve visualization with the development of three-dimensional (3-D) endoscope systems. In order to evaluate the utility of a 3-D endoscope system (VISIONSENSE), we performed a small clinical cohort with the system as well as a laboratory evaluation to attempt to measure which tasks the 3D endoscope was most helpful/limited.

METHODS: Prospective clinical cohort and controlled laboratory evaluation of the 3D endoscope.

RESULTS: Eight endoscopic cases were performed with the 3D endoscope. Four skull base and four functional sinus cases. Both single handed (FESS) and two handed (skull base) surgery was performed. Analysis of the system was evaluated by the resident surgeon, the attending otolaryngologist and the attending neurosurgeon if he was involved in the case. The utility and limitations of the system was recorded after each case. A series of laboratory exercises was created to evaluate the usefulness of the system in various endoscopic tasks. The results showed trends for improved accuracy with the 3D system. We discuss and show (via video presentation) our operative experience and what we feel are the limitation of the current system as well as strength for future development.

CONCLUSIONS: The 3D endoscope is a promising tool for endoscopic sinus and skull base surgery. We discuss the advantages, limitations and potential future for such technology in our field.

ABSTRACT NUMBER: 1815

CURRENT PRACTICE IN THE USE OF SYSTEMIC STEROIDS IN CRS

Amy Anstead, S. Joe, Kristen Pytynia

BACKGROUND: Systemic steroids have been widely used for CRS, although paucity exists in the literature of trials determining efficacy, dosing schedule, and side effects of this treatment. We set out to identify which disease variations of chronic rhinosinusitis are considered appropriate for systemic steroid treatment by practicing Rhinologists and to determine awareness of steroid side effects among these physicians.

METHODS: Survey distributed to practicing Rhinologists registered with the American Rhinologic Society, American Academy of Otolaryngologists and the American Academy of Otolaryngic Allergy. The survey consisted of three sections: (1) Questions regarding oral steroid use in eighteen different CRS disease states; (2) Components of CRS in which oral steroids are beneficial; (3) Common side effects of oral steroids. Demographic data on each clinician was also obtained.

RESULTS: 353 surveys were collected and analyzed. We found that steroids were widely used for nasal polyposis, even if no significant symptoms were present. There was a decrease in steroid use with medical comorbidities, but still >50% of physicians stated they would still use the medication. There was more use of oral steroids as initial therapy in patients with nasal polyposis. Use in CRS without polyps more than doubles when refractory to initial medical management. This trend is across all clinical situations, including multiple medical comorbidities. Side effect profiles were largely acknowledged by Otolaryngologists.

CONCLUSION: This survey shows that oral steroids are widely used among Rhinologists. Physicians are aware of the possible side effects and use the medication especially in the treatment of CRS with polyposis.

ABSTRACT NUMBER: 1816

ANTIMICROBIAL LIPID COMPOSITION OF SINUS SECRETIONS IN PATIENTS WITH AND WITHOUT CHRONIC RHINOSINUSITIS

Jivianne Lee, MD, Mike Jansen, BS, David Keschner, MD, Edith Porter, MD

INTRODUCTION: Airway secretions possess intrinsic antimicrobial properties that contribute to the innate host defense of the respiratory tract. These microbicidal capabilities have largely been attributed to the presence of antibacterial polypeptides. However, recent investigation has demonstrated that lipids also exhibit similar antimicrobial properties. The purpose of this study was to determine whether sinus secretions contain such antimicrobial lipids and to compare the lipid composition in patients with and without a history of CRS.

METHODS: Maxillary sinus fluid was obtained via antral lavage through the canine fossa from subjects with (9) and without (10 controls) a history of CRS. Following specimen collection, lipid quantification was performed by subjecting specimens to lipid extraction according to Bligh & Dyer followed by reverse phase HPLC on a C18 PA2 column. Lipid contents (total, cholesterol + cholesteryl esters, and cholesteryl esters) were then calculated based on the extracted volume and protein content.

RESULTS: Antimicrobial lipids were identified in the maxillary sinus secretions of patients with and without CRS. However, levels of lipid composition differed between the two groups, with CRS patients exhibiting statistically significantly greater amounts of all classes of lipids (total, cholesterol, and cholesteryl esters) when compared to controls.

CONCLUSIONS: Sinus secretions of patients with CRS demonstrate elevated levels of antimicrobial lipids compared to controls. This upregulation suggests that host-derived lipids act as mediators of mucosal immunity in CRS. Further study is necessary to determine if such antimicrobial lipids function in isolation or synergistically with antibacterial peptides in conferring such inherent microbicidal properties.

ABSTRACT NUMBER: 1818

AN ADJUSTABLE IMPLANT FOR NASAL VALVE DYSFUNCTION: A 3 YEAR EXPERIENCE

Charles Hurbis, MD

OBJECTIVE: To measure the degree of improvement and the maintenance this improvement when using the Monarch Nasal Implant for surgically correcting the dysfunctional nasal valve.

METHODS: We present our long term data for the Monarch Implant. Currently, over forty patients have been implanted with follow-up extending beyond 36 months for 9 of the patients. Implant effectiveness was determined through the use of anterior acoustic rhinometry and a NOSE format subjective patient questionnaire. These studies were administered pre-operatively and at 1–3 month intervals post-operatively.

RESULTS: Rhinomanometry studies and patient questionnaires revealed a significant initial improvement in the internal nasal valve areas and an improvement in patient symptomatology respectively. These results were maintained or even improved at 36 months. The cosmetic changes imparted by the implant were acceptable to the patients in exchange for the symptomatic improvement they receive. The average patient age for this study was 66 years and this implant clearly is designed for correction of nasal valve problems of a senile nature. The avoidance of complications, which should be rare when the implant is properly used, will be discussed.

CONCLUSIONS: The Monarch Nasal Implant provides a consistent and lasting correction of nasal valve dysfunction in the geriatric patient with minimal downside when properly used.

ABSTRACT NUMBER: 1819

COMPARISON OF EXTERNAL RHINOPLASTY VERSUS ENDOSCOPIC APPROACH TO TRANSPHENOIDAL SELLAR MASS RESECTION

Naveen Bhandarkar, MD, Stephanie Joe, MD, Mike Yao

OBJECTIVE: 1) Compare outcomes between the external rhinoplasty versus endoscopic approach to access the sella and discuss advantages of each. 2) Compare outcomes in endoscopic versus microscope assisted resection of sellar masses.

METHODS: Retrospective chart study. External rhinoplasty approach is described in detail.

RESULTS: 100 total patients were studied. Mean follow-up was 18 months. 48 patients underwent an external rhinoplasty approach with microscope-assisted resection. Interventions to correct functional nasal deformities were performed in greater than 50% of patients, including cartilage grafting and septoplasty. 52 patients had an endoscopic approach to expose the sella, of which 22 had endoscopic and 30 had microscope-assisted resection. Post-operative incidence of diabetes insipidus or hypopituitarism was higher for the purely endoscopic group (55% vs 23%). However, frequency of residual tumor was higher in microscope assisted resection group (53% vs 23%). With regards to microscope-assisted resection, 20% of patients in the endoscopic group had intranasal complications including septal perforation and synechiae formation requiring intervention compared to 0% in the external group. Incidence of post-operative cerebrospinal fluid leak was equally rare in all groups.

CONCLUSIONS: Advances in technology have resulted in a trend towards a purely endoscopic approach for resection of sellar masses, but we should not overlook the external rhinoplasty approach and its potential advantages in exposure and improving quality of life in carefully selected patients. Intranasal complications are fewer in the external versus endoscopic approach when the microscope is used. The difference between outcomes of endoscopic versus microscope-assisted resection following an endoscopic approach may relate to the improved angled visualization allowing for more complete resection of tumors.

ABSTRACT NUMBER: 1822

LATERAL CRUS PULL-UP FOR THE COLLAPSE OF EXTERNAL NASAL VALVE: RHINOMANOMETRIC AND RHINOMETRIC STUDY.

Ignazio Tasca, MD, Giacomo Ceroni, MD

INTRODUCTION: Collapse of the nasal vestibule during inspiration is a frequently encountered condition, often caused by weak or medially displaced lateral crura in the lower lateral cartilages. Various surgical techniques to restore the external nasal valve have been described. We herein report our experience on the lateral crus pull-up technique and evaluate the effectiveness of this procedure by means of rhinomanometry and acoustic rhinometry.

METHODS: Fourteen patients (8 males, 6 females) with a mean age of 36 years (range: 25–41 years), suffering from impaired nasal breathing due to external nasal valve collapse were recruited for this study. Rhinomanometry and acoustic rhinometry were performed before the operation and at 1–6–12 month follow-ups. The lateral crura were mobilized using a delivery approach, then rotated in a superolateral direction and held in place by bringing a suture through the skin.

RESULTS: There were no intraoperative or postoperative complications. All patients expressed immediate substantial improvement in their nasal

breathing and this level of satisfaction persisted at end point follow-up. Rhinomanometry showed a decrease in nasal resistances, while acoustic rhinometry revealed an increase in minimal cross-sectional areas. These results remained stable at 1 year follow-up.

CONCLUSIONS: We demonstrated that lateral crus pull-up is an effective method to increase the vestibule width, by providing a superolateral rotation of the lateral crura and is useful to improve nasal respiration by giving additional support for the lateral wall of the nasal vestibule.

ABSTRACT NUMBER: 1823

NASAL DORSUM COSMETIC CONTOUR BY CARTILAGINOUS SANDWICH GRAFT TECHNIQUE

Ignazio Tasca, MD, Giacomo Ceroni, MD

INTRODUCTION: A very frequent cause of secondary rhinoplasty is the occurrence of residual nasal dorsum irregularities after a primary procedure. This makes often the patient unsatisfied and asking for a revision surgery. In order to prevent this possible event, we have developed a technique effective for the camouflage of slight nasal dorsum irregularities as final step of rhinoplasty. This procedure can be useful also for rhinoplasty requiring minimal to moderate dorsal augmentation.

METHODS: 36 patients undergoing rhinoseptoplasty in our ENT Department were treated by nasal dorsum camouflage using the cartilaginous sandwich graft technique. After the infracture of nasal bones, irregularities of nasal dorsum were appreciated digitally. Graft consisted of two thin strips of Spongostan™ containing autologous crushed cartilage, previously harvested from the septum. Graft is inserted into position after elevating the dorsal skin. Stabilization is obtained by undermining the dorsal skin only to the extent need for graft insertion so that the resulting tight pocket restricts the movement of the graft.

RESULTS: This technique has yielded consistently good aesthetic results: after dressing removal, nasal dorsum appeared smooth and regular in all patients. These results remained stable at 1 year follow-up.

CONCLUSIONS: Cartilaginous sandwich graft technique is a reliable cosmetic procedure for the contouring of residual nasal dorsum irregularities. Spongostan™ serves as a carrier and support for the cartilage implant. After sponge resorption, cartilage remains in situ surrounded by a thin connective tissue capsule. Autologous septal cartilage, being harvested from the same operative field, does not determine an increase in morbidity.

ABSTRACT NUMBER: 1824

SEPTOPLASTY IN CHILDREN BY ENDONASAL APPROACH: RESULTS AT LONG-TERM FOLLOW-UP

Ignazio Tasca, MD, Giacomo Ceroni, MD

INTRODUCTION: The opportunity of septoplasty in childhood is still a matter of open debate in literature, since it is thought that a surgical procedure on a developing structure can produce some adverse effects on the normal facial growth; on the other hand, a percentage of septal deformities are bound to worsen following the growth of the nose. In order to clarify this topic, we report our experience on septoplasty in children, analyzing the anatomic and functional results in a long-term.

METHODS: 44 patients, 25 males and 19 females, aged between 5 and 12 years (average: 8.5 years), underwent septoplasty by endonasal approach. All the patients were reassessed after a 9 year follow-up (range 5–12 years) by means of morphometry, rhinomanometry, and acoustic rhinometry.

RESULTS: Complications did not occur during or after surgery. During the last follow-up, nasal septum was in axis in 36 patients. In these patients, rhinomanometric and rhinometric measurements revealed normal tracings. The remaining 8 patients, manifesting a residual septum deformity, were scheduled for a revision surgery. Morphometric evaluation did not identify any growth retardation in all patients.

CONCLUSIONS: Pediatric septoplasty is indicated in selected cases of congenital or posttraumatic obstructive nasal septum deformity and in cases of symptomatic septal alterations that are associated with recurrent inflammatory diseases of the upper airways. However, recurrent septum pathology may occur even several years after surgery. Therefore, adequate information should be given regarding long follow-up and the possibility of a second operation after the adolescent growth spurt.

ABSTRACT NUMBER: 1827

ENDOSCOPIC DACRYOCYSTORHINOSTOMY WITH MUCOSAL FLAP FIS SILICONE STENT NECESSARY?

Prof. DeHui Wang, HuaPeng Yu, MD, Prof. ChaoPing Zang, Prof. HouYong Li

OBJECTIVE: Many kind of new innovative surgical techniques are being to introduced continually to increase the successful rate of endoscopic dacryocystorhinostomy (DCR). The aim of this study is to present our experience of endoscopic DCR with mucosal flap, but without silicone tubing stent for the patients with chronic nasolacrimal duct obstruction.

METHODS: From January 2003 to DEC 2007, thirty four consecutive endoscopic DCR procedures were performed in 31 patients with post sac lacrimal duct obstruction, with 3 patients having bilateral surgery. The age of patient ranged from 8 to 52 years old (average, 34 years old). The mean duration of postoperative follow-up was 16 months (ranging from 3 to 60 months). Surgical success was defined as complete relief of epiphora and patent ostium of nasolacrimal drainage tract on endoscopic examination.

RESULTS: Surgical success rate was 94.1% (32/34), postoperative endoscopic examination revealed that 3 patients (8.8%) had granulation tissue at the rhinostome site. No other severe complications were observed.

CONCLUSIONS: Considering the similar success rate, but less granulation formation comparing, we suggest endoscopic dacryocystorhinostomy with mucosal flap, but without intubation as the management of choice of postsaccal obstruction of lacrimal canal. The silicone stent is not necessary for endoscopic dacryocystorhinostomy.

ABSTRACT NUMBER: 1828

ENDOSCOPIC MODIFIED ENDONASAL DENKER OPERATION FOR MANAGEMENT OF TUMOR IN PTERYGOPALATINE AND INFRATEMPORAL FOSSAE

Prof. DeHui Wang, JingJing Wang, MD, HuaPeng Yu, MD, Thomas Pasic, MD

OBJECTIVE: Although endoscopic approaches allow good visualization and access for many areas of the skull base, the lesions in the pterygopalatine fossa (PPF) and infratemporal fossa (ITF) are a challenge for otolaryngologists. The aim of our report is to describe an endoscopic modified endonasal Denker operation for the treatment of nonmalignant tumors in the PPF and ITF.

METHODS: From January 2004 to June 2007, five patients who had tumors in the PPF and/or ITF and underwent surgical resection of the tumors with the endoscopic modified endonasal Denker operation, were

reviewed regarding demographics, preoperative images, tumor cell type, surgical techniques and outcomes.

RESULTS: Five patients underwent the procedure mentioned above; 3 females and 2 males with a mean age of 38 and a range from 21 to 58 years of age. All patients had adequate exposure and total tumor resection with the endoscopic modified endonasal Denker operation. None of the patients required an external approach for tumor extirpation. There were no major postoperative complications. Transient epiphora and hypoesthesia in the infraorbital nerve distribution resolved fully in all affected patients.

CONCLUSION: The Endoscopic modified endonasal Denker operation for the management of lesions of the PPF and ITF provides excellent exposure and results with good hemostasis and low morbidity. This approach is a viable alternative to the open approaches to these areas.

ABSTRACT NUMBER: 1829

ENDOSCOPIC REMOVAL OF A SILENT MIDDLE TURBINATE ANGIOFIBROMA

Ping-Hung Shen, MD

Angiofibroma is a rare nasopharyngeal tumor that primarily occurs in adolescent males. Extranasopharyngeal angiofibroma is relatively rare, and the most affected site is the maxillary sinus reported in the literature. We present an extremely rare case of extranasopharyngeal angiofibroma in a 42-year-old man arising from the right middle turbinate. The tumor was incidentally found during an operation for endoscopic inferior turbinoplasty. We report this case of an extranasopharyngeal angiofibroma and discuss the possibility of endoscopic resection of this tumor without preoperative embolization.

ABSTRACT NUMBER: 1832

A PILOT STUDY OF A CHINESE VERSION OF THE UNIVERSITY OF PENNSYLVANIA SMELL IDENTIFICATION TEST FOR APPLICATION IN TAIWAN

Rong-San Jiang, MD, Mao-Chang Su, MD, Kai-Li Liang, MD, Jiun-Yih Shiao, MD

OBJECTIVES: The 40-item University of Pennsylvania Smell Identification Test (UPSIT) is the most widely used smell test in the world. It has the advantages of high reliability, convenience, and accuracy. Presently, culturally modified versions of this test are available in 12 languages. This study describes the first assessment of a prototype Chinese version of the UPSIT (UPSIT-C) that has been translated into traditional Chinese for administration in Taiwan.

METHODS: The American English language version of the UPSIT and the UPSIT-C were administered to 40 healthy Taiwanese subjects on two test occasions separated from one another by two weeks.

RESULTS: The mean (SD) UPSIT score was 28.2 (3.8) for the first test administration and 28.4 (4.5) for the second. The mean (SD) UPSIT-C score was 33.2 (2.9) for the first administration and 32.6 (3.8) for the second. The UPSIT-C scores were significantly higher than those of the UPSIT on both test occasions ($p < 0.0001$). Despite a marked attenuation of test scores due to the narrow age range assessed, Pearson correlations computed across the two test occasions were positive and statistically significant for both the UPSIT and the UPSIT-C (respective $r_s = 0.81$ & 0.63 , $p < 0.001$).

CONCLUSION: As expected, the scores on the prototype UPSIT-C were significantly higher than those on the American UPSIT when administered to a Taiwanese sample. Both versions of the UPSIT were stable across repeated test sessions.

ABSTRACT NUMBER: 1833

FLAP RECONSTRUCTION OF NASAL SEPTAL PERFORATION

Yaser Khalil, MD, Ahmad Al barah, MD

OBJECTIVE: In this work we compare between bilateral bipediced nasal mucosal flaps and upper buccal mucosal flap from upper lip, in closing nasal septal perforation.

STUDY DESIGN & SETTING: We reviewed a sample of 12 patients all having septal perforation. All patients underwent preoperative and postoperative C.T scan nose and paranasal sinuses (P.N.S). and diagnostic endoscopy. The patients were randomized into two groups each group includes six patients. Group (A): Six patients were managed by using bilateral bipediced nasal mucosal flap through an external approach rhinoplasty. Group (B): Six patients were managed by using superior labial flap using external approach rhinoplasty.

RESULTS: Complete closure of the perforation in group (A) patients was achieved in four cases, one of the remaining two cases showed central perforation 1.5 cm while the other one showed complete failure. Regarding results of the patients in group (B) five patients showed complete closure, only one patient shows slight posterosuperior perforation.

CONCLUSION: Reconstruction of nasal septal perforation using bipediced nasal mucosal flap is a good method for repair particularly when using wide approach like external rhinoplasty approach but it needs high skills to elevate the nasal mucosal flap & suturing without tension on suture line. In the other method of repair of septal perforation using upper labial flap gives good results also but the patients complaints not improved greatly.

ABSTRACT NUMBER: 1834

QUALITY OF LIFE IS IMPROVED BY ENDOSCOPIC SINUS SURGERY IN NASAL POLYPOSIS WITH ASTHMA

Anders Ehnhage, MD, Petter Olsson, MD, Prof. Steven Nordin, Pär Stjärne, MD

INTRODUCTION: Nasal polyposis (NP) is associated with asthma. The aim of this study was to investigate the health impact of NP with asthma and to study effects of endoscopic sinus surgery (ESS), as well as addition of fluticasone propionate nasal drops (FPND), on health related quality of life (HRQoL) in this patient group.

METHODS: A prospective 21-week study of 68 patients, with NP and asthma. Effects of ESS were measured with Study 36-Item Short Form (SF-36). A randomized, double-blind, placebo-controlled 14-weeks phase measuring additive effects of FPND 400µg twice daily was included.

RESULTS: At baseline HRQoL was significantly decreased in both Physical Component Summary, PCS, (45 vs 48, $p=0.049$) and Mental Component Summary, MCS, (43 vs 51, $p<0.001$), as well as in six out of eight domains compared with the reference population. ESS significantly improved five out of eight SF-36 domains as well as PCS ($p=0.027$) and MCS ($p=0.021$) after 5 weeks. We found significant additional benefit of FPND 400µg twice daily on three domains (RP, $p=0.002$; VT, $p=0.007$; SF, $p=0.002$). The increase in HRQoL with FPND 400µg twice daily reached reference population levels in all domains, as well as in both PCS and MCS, 5 weeks after ESS.

CONCLUSIONS: ESS has benefits on HRQoL. FPND 400µg twice daily can be added to improve, and to reach population levels of, HRQoL already 5 weeks post-ESS. Physicians should evaluate HRQoL and consider ESS in their assessment of these patients.

ABSTRACT NUMBER: 1835

THE EFFECT OF POSTAURICULAR FASCIAL FLAP IN OTOPLASTY

Yaser Khalil, MD

BACKGROUND: Prominent ears are the most common congenital deformity of the external ear. Corrective otoplasty is a commonly performed procedure but the multitude of surgical techniques described suggests that the ideal procedure is yet to be found. This paper compares the addition of a post-auricular fascial flap to the posterior suturing technique and cartilage scoring, with the posterior suturing technique and cartilage scoring, without the post-auricular fascial flap in terms of morbidity and aesthetic outcome.

PATIENTS AND METHODS: 50 patients underwent otoplasty in, from August 2004 to September 2006. Considering every ear on the same patient as an independent variable, a total of 80 procedures have been performed (30 bilateral and 20 unilateral). The patients were divided into two groups: Group A: (31 patients) with 51 ears: Posterior suturing and anterior scoring with post-auricular fascial flap; Group B: (19 patients) with 29 ears: Posterior suturing and anterior scoring without post-auricular fascial flap.

RESULTS: The recurrence rate was 2.5% and 10% in Groups A and B respectively ($p < 0.0214$) (HS). Complications were more common in Group B (25%) compared to Group A (2.5%) ($P < 0.0208$) (HS). Late complications were also minimum in Group A, compared to Group B.

CONCLUSION: The fascial flap is a simple and safe procedure and seems to act as a double-breasting layer over the sutures preventing extrusion, increasing postauricular support, and reducing recurrence.

ABSTRACT NUMBER: 1840

TRANSNASAL ENDOSCOPIC IMAGE-GUIDED ORBITAL APEX SURGERY

Chester Griffiths, MD, Howard Krauss, MD

Image-Guidance has emboldened surgeons while at the same time allowed safer surgery. Transnasal Endoscopic Orbital Surgery has been described in the treatment of Nasolacrimal Duct Obstruction and Graves' Ophthalmopathy and as an approach to optic canal decompression in cases of Traumatic Optic Neuropathy. To expand the utility of this technology, we have utilized a Transnasal Endoscopic Image-Guided approach to biopsy or excise medial orbital apex tumors since 2001. Collaboration of a Surgical Neuro-Ophthalmologist and Head and Neck Surgeon has brought together unique skills to achieve a less invasive, safer and more cost effective treatment for these disease processes which can now be treated on an outpatient basis. Specifically in the case of orbital apex tumors, obviating the need for a neurosurgical or extended lateral approach affords a greatly decreased morbidity. Case presentations, including our first transnasal orbital apex tumor excision performed in 2001 will detail our surgical planning with emphasis on radiologic anatomic boundaries of dissection leading to a safe surgical approach. Potential disease states applicable to this approach will be presented to highlight our 8 year experience.

ABSTRACT NUMBER: 1841

COMPARISON OF RETROPALATAL AND RETROGLOSSAL AIRWAY OBSTRUCTION IN OBSTRUCTIVE SLEEP APNEA SYNDROME

Baharudin Abdullah, MMED, Khairul Azhar, MD, Suzina Sah, MMED

INTRODUCTION: Endoscopic upper airway evaluation either awake or during sleep is predictive and useful in identifying patient with OSAS. It may also assist surgeons to accurately define the location of upper airway obstruction and address it with appropriate surgery.

OBJECTIVES: To assess the level of upper airway obstruction and its severity in obstructive sleep apnea syndrome (OSAS).

METHODOLOGY: Flexible nasopharyngolaryngoscopy (NPLS) was performed in seated erect and supine position. Continuous video recording at the retropalatal and retroglossal regions was done during quiet breathing and Muller maneuver in both positions. Captured images were measured using computerized image processor and narrowing rate was calculated.

RESULTS: A total of 59 patients participated in this study and the majority of them fell into a severe group, 29 (49.2%) followed by moderate group, 16 (27.1%) and 14 (23.7%) in mild group. Based on Fujita classification, 29 (49.1%) participants had type 1 (retropalatal) obstruction, 23 (39.0%) type 2 (retropalatal and retroglossal) and 7 (11.9%) type 3 (retroglossal) obstruction. The retropalatal region in supine position (SRP) was affected the most with 50 (84.7%) participant in the severe obstruction group (51 – 100% collapse) followed by retropalatal region in erect position (ERP) 35 (59.3%). The retroglossal region in erect position (ERG) and retroglossal region in supine position (SRG) fell into the less severe obstruction group (0–49% collapse).

CONCLUSION: The retropalatal region was more affected compared to retroglossal region either in erect or supine position. The retropalatal region in supine position has more severe obstruction as compared to the erect position.

ABSTRACT NUMBER: 1842

QUALITY OF LIFE IN PATIENTS WITH CHRONIC RHINOSINUSITIS, NASAL SEPTAL DEVIATION, OBSTRUCTIVE SLEEP APNEA, HEADACHES, AND GERD

Helen Perakis, MD, Troy Woodard, MD, Sunny Khichi, BS, Stilianos Kountakis, MD

INTRODUCTION: The 20-Item Sino-Nasal Outcome Test (SNOT-20) has been well validated as a measure of rhinosinusitis health status and quality of life in patients with Chronic Rhinosinusitis (CRS). Our goal was to compare quality of life outcomes in patients with CRS to those with obstructive sleep apnea (OSA), nasal septal deviation (NSD), Headaches (HA) and GERD.

STUDY DESIGN: Retrospective analysis of prospectively collected data

METHODS: 41 patients with CRS, 84 patients with OSA, 58 patients with nasal septal deviation, 35 patients with HA and 20 patients with GERD were evaluated at a tertiary medical center over one year. All patients subjectively completed SNOT-20 questionnaires when first evaluated. The SNOT-20 scores of the all groups were then divided into a score for the first 10 questions and a score for the last 10 questions. Comparisons between all groups were performed using Tukey-Kramer Multiple Comparison Test and comparison of each groups separate SNOT-20 scores were evaluated with paired t-test.

RESULTS: Mean SNOT-20 score for patients with CRS was 28.1 +/- 13.2, with OSA was 28.4 +/- 10.7, with NSD was 22.7 +/- 13.4, with HA was 28.3 +/- 13.3 and for GERD was 22.4 +/- 12.8. Although there was no significance between the total SNOT-20 scores among groups, when evaluating the scores of the last ten questions, the OSA patients had significantly higher scores than the CRS, NSD, and CRS group (p 0.02). When comparing the first 10 question score to the last 10 question score, there was a significant difference in the OSA patients (p < 0.0001), a significant difference in the CRS group (p 0.03) and a significant difference in the NSD group (p 0.02).

CONCLUSION: There appears to be a difference in the pattern of distribution between SNOT 20 scores for CRS, NSD, and OSA. This study demonstrates that the last 10 questions of the SNOT 20 may be used as a separate questionnaire to evaluate patients with presumed OSA.

ABSTRACT NUMBER: 1844

VALIDITY OF “HYDRODISSECTION” FOR SUBPERICHONDRAL SEPTOPLASTY – AN EXPERIMENTAL ANATOMICAL STUDY.

Dr. Patrick Dubach, Dr. Mantokoudis Georgios, Yara Banz, MDPhD, Prof. Marco Caversaccio

AIMS: The validity of hydrostatic dissection by local anesthetics and vasoconstrictive agents in creating a surgical subperichondral plane is controversial. Classical textbooks promote it “as the essential step in septoplasty” or consider its practicability “a mere fable”. The literature is full of apodictic statements based on theoretical considerations but experimental tests are missing. Not only is this a technical question, but various reports exist about fatal side effects of hydrodissection (cardiovascular events, blindness).

METHODS: Three surgeons simulated subperichondral septoplasty with 19 mineral salt fixated human cadaveric heads infiltrating 1ml of Lidocain/Adrenaline mixture with 1:10 China ink unilaterally into the septum. Each septum was histologically examined using serial 3mm sections in 100mm intervals through the center of the infiltrated area. Tissue cleavage containing the ink deposits with minimal distance to the proposed subperichondral zone, intravasal spread and tissue deposition were analyzed.

RESULTS: Physical dissection between different anatomical layers of the nasal septum was possible (n=19). However, dissected planes showed random distribution within the perichondrium (n=9) or adjacent connective tissue layers. Only five cases showed dissection in a subperichondral zone. Infiltrated matter did not only accumulate in the split connective tissue layers but also penetrated the surrounding vessels and the large sinusoids of the septal swell body (n=8).

CONCLUSION: A reliable subperichondral dissection plane by hydrostatic infiltration could not be reproduced experimentally. A risk of penetration into the venous sinusoids and vessels exists when large volumes of vasoactive substances are used, promoting rapid systemic distribution and leading to potentially serious side effects.

ABSTRACT NUMBER: 1849

SINONASAL ORBITAL LESIONS AND THEIR MANAGEMENT

Hossam Elbasraty, MD

INTRODUCTION: The orbit lies in a very intimate relation to the nose. The nose and paranasal sinuses share in the orbital boundaries. Many orbital lesions might be primarily nasal lesions extending to the orbit giving rise to orbital symptoms.

METHODOLOGY: Various types of sinonasal-orbital lesions (Traumatic, inflammatory & neoplastic) were demonstrated and how they are managed endoscopically.

RESULTS: Sinonasal surgery might be used as an access to the orbit or might sometimes results in orbital complications. In this paper we presents a variety of naso-orbital cases that might face the otolaryngologists.

CONCLUSIONS: Otolaryngologists should be aware and capable of dealing with some orbital pathologies because it lies in their surgical field.

ABSTRACT NUMBER: 1850

DEVELOPMENT OF A MOUSE MODEL OF CHRONIC MAXILLARY SINUSITIS

Xiaoyang Hua, MD, Brent Senior, MD, Stephen Tilley, MD

BACKGROUND: Chronic rhinosinusitis (CRS) is a very common chronic disease. Its pathogenesis remains largely unknown. Mouse models with human diseases have been extensively used in biomedical research for both disease pathogenesis studies and drug discovery. However, mouse model with CRS is less developed.

METHODS: We intraperitoneally sensitized the C57BL/6 mice with OVA and intranasally challenged them to generate a mouse model with chronic maxillary sinusitis. Mouse noses and sinuses were histologically analyzed by different stains (eosinophils, H&E; mast cells, toluidine blue; goblet cells, AB-PAS).

RESULTS: Mice challenged with OVA all exhibited eosinophil infiltration and goblet cell metaplasia in the maxillary sinuses. We also observed the mast cell infiltration in the nasal cavity, maxillary sinuses and nasal septums.

CONCLUSIONS: We successfully generated a mouse model with maxillary sinusitis, which exhibited several chronic features of human CRS.

SIGNIFICANCE: The generation of mouse model with maxillary sinusitis provides us a useful tool to study the pathogenesis of CRS.

ABSTRACT NUMBER: 1852

IMPACT OF NASAL POLYPS ON QUALITY OF LIFE OF CHRONIC SINUSITIS PATIENTS

Prof. Lakshmi Vaid, Prof. Pritampal Singh, Dr. Seema Khanna

INTRODUCTION: To study the significance of nasal polyps on the symptoms of chronic rhinosinusitis (CRS) and their influence on surgical outcomes.

METHODS: Retrospective analysis of prospectively collected data comparing two groups of patients diagnosed with CRS with and without polyps who underwent surgery with a minimum of 3 month follow up period. Subjective scoring was performed using the Sino-nasal Outcome Test (SNOT-20) questionnaire. Computed tomography (CT) scans were compared using the Lund –Mackay scoring system. Endoscopic findings were graded according to Lanza and Kennedy staging system. The two groups were analyzed for the need of revision surgery. 30 patients underwent surgical management of CRS over a period of one year. 20 were male, 10 were female and the average age was 26 years (range 15-55years). Polyps were present in 15 patients with CRS while, the other 15 did not have polyps. The average CT score was 10.13 for the polyp group and 9.79 for patients without polyp. The Polyp group SNOT-20 preoperative scores averaged 20.27 with improvement to 3.80 at 2 weeks, 2.67 at 1 month and 2.93 at 3 months (86.21% improvement $p=0.001$). Non-polyp group SNOT-20 scores were 18.80 preoperatively with improvement to 4.67 at 2 weeks, 3.40 at 1 month and 3.27 at 3 months (81.83% improvement). Preop diagnostic endoscopy on polyp group was 5.27 which improved to 2.13 in 2 weeks, 1.33 in 1 month and 1.53 in 3 months (73% improvement). In the non polyp group it was 4.53 pre-operatively which improved to 1.20 in 2 weeks, 0.93 in 1 month and to 1.13 in 3months (69% improvement). 6 patients required revision surgery (20%), 3(10%) belonging to polyp group and 3 (10%) who did not have polyps.

CONCLUSION: Nasal Polyp has a significant negative impact on the patients with CRS. Patients with polyps have higher symptom scores, worse objective findings compared with patients without polyp, but patients with polyp show more improvement after surgical intervention and need for revision surgery is equal in both groups.

ABSTRACT NUMBER: 1853

PGE2 SUPPRESSES STAPHYLOCOCCAL ENTEROTOXIN-INDUCED EOSINOPHILIA-ASSOCIATED CELLULAR RESPONSES DOMINANTLY VIA AN EP2-MEDIATED PATHWAY IN NASAL POLYPS

Mitsuhiro Okano, MD, Takaya Higaki, MD, Seiichiro Makihara, MD, Kazunori Nishizaki, MD

BACKGROUND: Recent investigations have revealed that Staphylococcal enterotoxins (SEs) and/or cyclooxygenase (COX) metabolism may participate in the pathogenesis of eosinophilic airway diseases such as chronic rhinosinusitis with nasal polyps.

OBJECTIVE: We sought to determine whether COX metabolism, especially prostaglandin E2 (PGE2), plays a significant role in SE-induced cellular responses in nasal polyps.

METHODS: Dispersed nasal polyp cells (DNPC) were prepared from nasal polyps by enzymatic digestion. DNPC were cultured with SEB in the presence or absence of COX inhibitors (diclofenac and indomethacin) for 72 hours; then, the levels of IL-5, IL-13, RANTES, and eotaxin in the supernatants were measured. The effect of PGE2 on SEB-induced responses by diclofenac-treated DNPC was examined, especially in terms of receptor specificity.

RESULTS: DNPC produced significant amounts of IL-5, IL-13, and RANTES in response to SEB. COX inhibitors significantly increased the production of these cytokines. The degree of local eosinophilia was significantly and positively correlated with the changes in IL-5 production induced by diclofenac treatment. PGE2 significantly and dose-dependently inhibited SEB-induced IL-5, IL-13 and RANTES production by diclofenac-treated DNPC. EP2 receptor-selective agonist strongly inhibited the production of all of three cytokines. EP3 and EP4 receptor-selective agonists partially suppressed these responses while EP1 receptor-selective agonist did not. Interestingly, all of the combined treatments with two of the four EP receptor-selective agonists significantly inhibited the SEB-induced responses by diclofenac-treated DNPC.

CONCLUSIONS: These results suggest that PGE2 inhibits the pathogenesis of SEB-induced eosinophilic inflammation primarily via the EP2-mediated pathway in patients with chronic rhinosinusitis with nasal polyps.

ABSTRACT NUMBER: 1855

THE ROLE OF TITANIUM PLATES IN SEPTORHINOPLASTY

Andres Godoy, Inter, Jose Godoy, MD, Jose Godoy

INTRODUCTION: Reconstruction of the nose is a complex issue in revision septorhinoplasty patients, due to a distorted anatomy, excessive scarring, and decreased nasal function. Multiple options for nasal reconstruction have been used, including alloplastic materials, autogenous tissues or a combination of both.

OBJECTIVE: The authors propose a novel technique for the use of a titanium plate in septorhinoplasty reconstruction utilizing one or more of the following as indications: 1) Lack of support of the nasal tip. 2) Deviated nasal septum. 3) Traumatic nasal Reconstruction. We expose its proper use, main advantages and disadvantages.

METHOD: A retrospective chart review of patients undergoing septorhinoplasty with this technique utilizing a titanium plate between 2001-2008 was performed. Twenty-five patients who fulfilled the criteria where operated. Patient demographics, surgical indication, immediate and late complications outcomes were recorded.

RESULTS: In twenty-one cases, the indication was to correct a previously operated deviated nasal septum. In four cases, the indication was reconstruction of the nasal valve with elevation of the tip in revision rhinoplasty. In this eight year review, the procedure has shown no side effects, rejection nor any other clinical disadvantages compared to traditional methods.

CONCLUSION: The titanium plate is a light weight, high strength, inert and highly biocompatible material, making it a viable alternative for reconstructive septorhinoplasty. We advocate the use of this technique and material in revision septorhinoplasty cases and in primary deviated nasal septum with a complete occlusion of the nasal fossa.

ABSTRACT NUMBER: 1859

FUNCTIONAL VOICE OUTCOMES FOLLOWING EXTERNAL MEDIALIZATION THYROPLASTY USING AUTOLOGOUS NASAL SEPTAL CARTILAGE UNDER LOCAL ANESTHESIA

Tamer Mesallam, MD, Yaser Khalil, MD

HYPOTHESIS/OBJECTIVES: A persistent insufficiency of glottal closure is mostly a consequence of unilateral vocal fold movement impairment. It can also be caused by vocal fold atrophy or scarring processes. Because of consequential voice, breathing, and swallowing impairments, a functional surgical treatment is required. The goal of the study was to outline the functional outcomes after medialization thyroplasty with autologous septal cartilage from the nose.

METHODS: External vocal fold medialization using autologous septal cartilage was performed on 14 patients (4 females and 10 males). The patients were in the age range of 23 to 67 years. Eight patients had a right vocal fold paralysis, and six patients had paralysis on the left vocal fold. Detailed functional examinations were executed on all patients before and after the surgery including: perceptual voice assessment according to the modified GRBAS “over-all grade, roughness, breathiness” scale, acoustic voice analysis, and videostroboscopic examination.

RESULTS: All patients reported improvement of voice quality post-operatively, Videostroboscopy revealed an almost complete glottal closure after surgery in all of the patients. All voice-related parameters showed a significant improvement.

CONCLUSIONS: The results confirm the external medialization of the vocal folds as an adequate method in the management of voice impairment attributable to an insufficient glottal closure. The autologous septal cartilage implant offers, apart from good tissue tolerability, the advantage of an easy, time-saving, and individually adjustable application during the operation.

ABSTRACT NUMBER: 1861

PACKINGLESS RHINOLOGIC SURGERY: A 20 YEAR EXPERIENCE

Chester Griffiths, MD, Cadvan Griffiths, MD

The authors will present an analysis of their combined experience in over 2000 cases over 20 years of rhinologic surgery, the majority completed without use of nasal packing. Routine nasal packing in rhinologic surgery including rhinoplasty, septoplasty, and sinus surgery has been curtailed without major adverse sequelae and resulting in a significant reduction in post-operative morbidity and increased patient satisfaction. Techniques and results will be presented.

ABSTRACT NUMBER: 1864

IS LATERAL OSTEOTOMY AN OBLIGATION IN RHINOPLASTY FOR CROOKED AND NON-CROOKED NOSE OR NOT

Shahriar Nazari, M.D.

INTRODUCTION: Lateral osteotomy is one of most prevalent steps in rhinoplasty and for correcting of some deformity like broad base nose and open roof deformity after hump removal and also for correcting of misaligned nasal bone it seems that its obligatory but many surgeons do this procedure in all rhinoplastic surgery as an inevitable step ,but a question will remained is it an obligation in all rhinoplastic surgery or not.

MATERIAL AND METHOD: In 112 patients,77 of them had some criteria of crooked nose ,and who had done rhinoplasty by the author from 2006 till 2008, I used a flexible approach for their operation and in some of them that I assessed the shape of nose and the alignment and broadness of nose after completion of operation is good I finished the operation without doing lateral osteotomy, all of cases had pre- operative photography and post operative photo in 1,3,6,and 12 month after operation in cases of long follow up. all patient followed up for 3 month to 24 month and all asked about their satisfaction of the shape and alignment and broadness of their noses and the photos are compared by the surgeon to assess the results after operation then the results are compared to each other between two groups of osteotomized and non osteotomized group by statistical proportion test.

RESULTS: In 112 patients who had done rhinoplasty from 2006 to 2008,77 patients had crooked nose(68.7%)and 35 patients had not deviated nose(31.3%).in these group of patients in 30 cases I had not done lateral osteotomy(26.7%) and in 82 case I had done lateral osteotomy in both side (73.3%) .in these 30 patients ,19 patients(63.7%) had crooked nose and 11 patients had not twisted nose(36.3%) .in these 30 patients in ,3 cases unilateral osteotomy had done(10%) and in 27 cases any lateral osteotomy had not done ,in these 77 patients in 7 cases crooked not repaired completely,(9%),6 cases in osteotomized patients and 1 in non osteotomized .there is no statistically significant difference between these two groups.

CONCLUSION: Lateral Osteotomy is one of the most prevalent and most important step in rhinoplasty especially after hump removal ,for correcting open roof deformity ,misalignment of nasal bones , and broad nasal vault base ,but it can cause step deformity ,lacrimial system injuries ,prolonged hematoma and bruising and also bleeding and narrowing of nasal airway system , and if it is possible to achieve the same results without osteotomy and with less trauma to nasal airway it will be preferable ,in this article it is shown that lateral osteotomy could be avoided with the same aesthetic result as the osteotomized patients with less trauma to nasal airway and less possibilities of complication and the same satisfaction of results by patients and surgeon.

ABSTRACT NUMBER: 1865

MULTILAYER SPREADER GRAFTS

Shahriar Nazari, M.D.

INTRODUCTION: Correcting crooked nose is one of the most challenging issues in rhinoplasty and recurring the deviation is not a rare condition .to have straighten nose after crooked nose surgery ,we introduced a new technique of multilayer spreader grafts.

MATERIAL AND METHODS: In a series of 112 patients who had done rhinoplasty by the author, 77 patients had crooked nose. each crooked nose has two side, one depressed or longer side and the other compressed or shorter side ,for correcting the deviation ,by open approach septoplasty was done for all of them and a big L strut in anterior and dorsal part was left ,the upper lateral cartilages were separated submucosally ,and then spreader grafts in different length were inserted, the longest one, inside and most medial to septum and the second or even third spreader graft in the depressed or longer side or concave side of septum, in some cases bilateral spreader grafts inserted and fixed in their place by 2 to 3 ,5-0 nylon sutures .after 1,3,6 and,12 months follow up post operative photos was taken and compared to their preoperative photos ,and correction of deviation of nose was determined by the surgeon and the satisfaction of patients were determined.

RESULTS: In 112 patients, 56 of cases had spreader grafts,(50%),total number of grafts inserted was 112 grafts, in 26 cases in right,20 cases in left, and in 10 cases bilaterally between 1 to 3 grafts inserted.77 of cases had crooked nose. in 49 cases(63%)of this group spreader graft inserted. in 7 non crooked noses, spreader grafts used as well. In 39 cases (50%),2 (32 cases or 82%) or 3 (7 cases or 18%) layer spreader grafts were inserted in concave side of deviation or longer side of crooked nose .in 2(4%) cases crooked not corrected even with use of multilayer spreader grafts .but in 47 cases(96%) crooked corrected in significant degree .in follow up pictures the broadness of midvault was assessed and interestingly there was not significant difference between non spreader and spreader group and patients do not complain of broadness of the nose.

DISCUSSION: For correcting twisted nose septoplasty is the main step of the operation but ancillary procedures like spreader grafting, beveling hump removal, multiple osteotomy, allar batten grafting, were discussed by different authors ,in this report it is shown that multiple layer spreader grafts in one side of septum could be inserted without broadness of midvault and good and long lasting results will be achieved and its result in some cases is superior to one layer spreader graft.

CONCLUSION: Multilayer spreader grafting in one side of septum is a good and amenable technique for correcting crooked nose.

ABSTRACT NUMBER: 1866

INCIDENCE OF MIDDLE TURBINATE PNEUMATIZATION, CONCHA BULLOSA IN TWISTED NOSE

Shahriar Nazari, M.D.

OBJECTIVE: To investigate whether the presence of middle turbinate pneumatization, concha bullosa, (CB) is related to twisted or deviated nose or not.

METHODS: CT scan was done for 112 patients who had done aesthetic septorhinoplasty for reshaping of their noses and correcting twisted noses, and these CT scans analysed for the presence of CB.

RESULTS: CB was detected in 53 cases of 112 patients(47.32%), 77 of 112 patients have some apparent axis deviation or twisted nose. 45 cases of these 77 patients had CB(58.44%)in 13 patients of these 45 cases CB was bilateral (28.8%) with predominancy of size of CB in concave side of septal deviation. With statistical test of proportions, correlation of CB with twisted nose in comparison of CB in the study group was checked and we found a p value <0.01 that was statistically significant.

CONCLUSION: It seems a strong correlation between twisted nose and CB would be coexisted. It may be a compensatory mechanism of air flow regulation like inferior turbinate hypertrophy in concave side of septal deviation and may need especial concern in correcting the deviated nose.

ABSTRACT NUMBER: 1870

ORBITAL COMPLICATIONS OF RHINOSINUSITIS

Fatma Kayhan, As.Pr, Ibrahim Sayin, M.D, Zahide Yazıcı, M.D, Omer Erdur, M.D.

OBJECTIVE: One of the most common complications of rhinosinusitis are orbital complications. This report presents our clinical experience on orbital complications of rhinosinusitis.

METHODS: The current report is a retrospective study of 59 consecutive patients admitted to the ENT Clinic of the Bakýrköy Sadi Konuk Education and Research Hospital in Istanbul, Turkey between January 2002 and January 2009 with complications of rhinosinusitis.

RESULTS: The mean age of the patients was 19.8.(range 6 months to 55). Twenty out of 59 patients (33.9%) were female where as 40 (66.1%) of the patients were male. One (1) patient showed 3 distinct complications, 3 patients showed 2 distinct complications at different times. The complications were classified according to Chandler's orbital complication classification. 43 (67.2%) complications were diagnosed as preseptal cellulitis, 9 (14.1%) complications were diagnosed as orbital cellulitis, 8 (12.5%) complications were diagnosed as subperiosteal abscess and 4 (6.2%) patients were diagnosed as orbital abscess. Forty eight (48 patients-75%) complications were treated with medical therapy alone whereas in 16 (25%) complications additional surgical intervention was needed.

DISCUSSION: Fifty nine (59) patients characteristics including age, sex, type of the complication, medical history, accompanying diseases, presenting symptoms, findings of rhinologic and ophthalmologic examination, results of imaging techniques, bacteriological findings, medical and surgical therapy and prognosis are presented and discussed.

CONCLUSION: Although orbital complications of rhinosinusitis were uncommon, these complications were regarded as therapeutic emergency and should be treated properly.

ABSTRACT NUMBER: 1871

THE EFFECT OF MONTELUKAST ON QUALITY OF LIFE IN PATIENTS WITH NASAL POLYPOSIS ACCOMPANYING ASTHMA BRONCHIALE- PRELIMINARY RESULTS

Fatma Kayhan, Zahide Yazıcı, M.D, Ibrahim Sayin, M.D, Eyüp Bozkurt, M.D

OBJECTIVE: Nasal polyposis occurred as a result of chronic mucosal irritation. Previous reports showed that nasal polyposis restricted the daily activity and decrease the quality of life. In this report we have evaluated the effect of montelukast on quality of life in patients with nasal polyposis accompanying asthma bronchiale.

STUDY DESIGN: Prospective study.

METHODS: Thirty (30) patients with nasal polyposis were included for this study. All patients were treated with appropriate medication (antibiotic, nasal steroid, antihistaminic) previously at least for three months. Previous medication was continued and an additional 10 mg montelukast therapy was added. Patients were evaluated with rhinosinusitis disability index (RDI) previous the montelukast therapy and 1 months after the therapy started. All patients were evaluated for aspirin hypersensitivity.

RESULTS: Twenty (20-66.6%) out of 30 patients were male and 10 (33.3%) patients were female. The mean age was 43,0±12,36 years (range 18 between 72). Emotional subscales of RDI showed decrease after treatment (45,30±22,64 vs 40,10±23,49). This difference did not show a statistically significant difference ($p>0.01$). Functional subscales of RDI showed decrease after treatment (38,36±21,52 vs 36,63±23,36). This difference did not show a statistically significant difference ($p>0.01$). Physical subscales of RDI showed decrease after treatment (53,55±22,89 vs 41,44±23,61). This difference showed a statistically significant difference ($p<0.01$).

CONCLUSION: These results suggest that the addition of montelukast on standard therapy of nasal polyposis improves quality of life in these patients.

ABSTRACT NUMBER: 1874

TREATMENT OF NASAL POLYPOSIS WITH ORAL METHYLPREDNISOLONE AND DOXYCYCLINE: A DOUBLE-BLIND, RANDOMIZED, PLACEBO-CONTROLLED TRIAL WITH EVALUATION OF CLINICAL AND BIOLOGICAL ACTIVITY.

Van Zele Thibaut, PhD, Gevaert Philippe, PhD, Holtappels Gabi, Bachert Claus, PhD

RATIONALE: Oral corticosteroids (CS) are commonly used in the treatment of nasal polyposis (NP) because their obvious efficacy. However, investigation of oral CS in NP has been remarkably insufficient. Secondly *S. Aureus* and high MMP-9 levels are implicated in the pathogenesis of nasal polyps. This study aims to evaluate the immediate and long-term effect of oral CS and doxycycline on NP size, nasal peak inspiratory flow (nPIF), nasal symptoms and local inflammatory markers.

METHODS: In a double-blind, placebo-controlled, randomized, multicenter study, 48 subjects with bilateral NP were randomized to receive either methylprednisolone, doxycycline or placebo for 20 days. During 3 months the clinical and biological activity was assessed by nasal peak inspiratory flow (nPIF), symptoms, nasal endoscopy, and markers of inflammation like eosinophils, ECP, MMP-9, MPO and IgE in peripheral blood and nasal secretions.

RESULTS: Methylprednisolone and doxycycline decreased significantly NP size during. A fast recurrence one and two months after treatment was seen in the methylprednisolone group. Methylprednisolone significantly decreased rhinorrhea, loss of smell, congestion and post nasal drip and increases nPIF significantly until week 4. Afterwards a rapid increase of symptoms and a fast decrease of nPIF was observed. Only a minimal but significant inhibition of ECP release was observed for methylprednisolone while doxycycline reduced significantly MMP-9 and ECP levels.

CONCLUSION: This is the first double-blind, placebo controlled study that shows that doxycycline reduces nasal polyps and a recurrence of polyps and symptoms is observed four weeks after treatment with methylprednisolone.

ABSTRACT NUMBER: 1878

SENSATION OF NASAL PATENCY THROUGH MUCOSAL HEAT LOSS RATHER THAN AIR TEMPERATURE

Kai Zhao, PhD, Kara Blacker, Yuehao Luo

The lack of sensation of nasal airflow (i.e. nasal patency) is the primary cause that drives patients with nasal sinus diseases to seek medical treatment. However, to objectively assess the degree of nasal patency remains a challenge to clinicians as objective measurements such as rhinomanometry or acoustic rhinometry do not correlate well with perceived patency. The current study examined other factors that may influence the perception of patency, including air temperature, humidity, nasal resistance, and trigeminal sensitivity. 44 healthy subjects unilaterally rated patency under different conditions using a visual analogue scale. In one condition, subjects sampled untreated air in a test room. In three other conditions (cold air, untreated room air, and dry air), air was pumped into a face box. In all conditions, temperature and relative humidity were recorded. Nasal resistance and airway cross section area were measured unilaterally using rhinomanometry and acoustic rhinometry, respectively. Trigeminal sensitivity was assessed by measuring lateralization thresholds for butanol. No significant correlation was found between perceived patency and nasal resistance, although, within subjects, there was a significant difference in perceived patency between the high and low resistance nostrils. In contrast, air temperature, humidity and butanol threshold, taken together, could significantly predict ratings of patency ($R^2=0.145$, $p<0.000$), with temperature being the most heavily weighted predictor. However, the significance of air humidity in patency rating suggests that the heat loss in the nasal mucosa rather than temperature alone, and the trigeminal feedback may likely play a central role in individual's perception of patency.

ABSTRACT NUMBER: 1879

OBJECTIVE ASSESSMENT OF THE IMPACT OF CHRONIC RHINOSINUSITIS (CRS) ON OLFACTORY FUNCTION

Kai Zhao, PhD, Edmund Pribitkin, MD, Nancy Rawson, PhD, Beverly Cowart, PhD

Chronic rhinosinusitis (CRS) is both one of the most common chronic diseases in the U.S., afflicting over 30 million adults, and one of the most common causes of smell loss. Yet, not all sufferers of CRS experience smell problems. In order to develop targeted therapies for this form of smell loss, it is critical to identify effective tools that can evaluate the functional impact of the disease process on the olfactory system. To this end, the Monell-Jefferson Chemosensory Clinical Research Center has enrolled 55 patients with clearly defined CRS and performed a battery of objective assessments on them, including acoustic rhinometry, rhinomanometry, CT scans and nasal endoscopic evaluations, with each tool indexing different aspects of disease status. Rhinometry primarily reflects the airway cross-sectional area and resistance contributed by the anterior portion of the nasal cavity, endoscopy evaluates the main nasal airway, ostiomeatal complex and olfactory cleft, whereas CT staging scores weight heavily on the surrounding sinuses. Our findings indicate that none of these tools by themselves discriminate degrees of olfactory loss due to CRS. Endoscopy scores and CT scores of the ethmoid sinuses are excellent indices for the most severe olfactory loss, anosmia, yet fail to differentiate hyposmic patients from those with no olfactory loss. The minimum cross sectional area (MCA) measured by acoustic rhinometry correlates significantly with unilateral olfactory thresholds of patients, but only for the high soluble odorant l-carvone, not for the low soluble d-limonene, which may reflect a conductive mechanism. In the future, carefully weighted combinations of multiple objective tools may provide a better evaluation of the aspects of this disease process that impact olfactory function. Supported in part by NIH grant DC 006760.

ABSTRACT NUMBER: 1880

BIOFILM-FORMING CAPABILITY IN PSEUDOMONAS AERUGINOSA INCREASES UPREGULATION OF THE PRO-INFLAMMATORY CYTOKINE CXCL1/KC IN MURINE NASAL EPITHELIUM

Nicholas Smith, MD, John Kostrzewa, MD, Shaoyan Zhang, PhD, Bradford Woodworth, MD

INTRODUCTION: Chronic rhinosinusitis (CRS) that is refractory to medical and surgical treatment may involve a particularly resistant form of infection known as a bacterial biofilm. *Pseudomonas aeruginosa* is a notorious biofilm-forming culprit in severe CRS that modifies the secretion of a number of virulence factors according to environmental and host conditions. Whether biofilm-forming capacity confers the ability to incite more host inflammation has yet to be fully investigated.

METHODS: After identical growth conditions, the supernatants from wild-type *Pseudomonas aeruginosa* (PAO1) and two mutant, non-biofilm-forming strains (sad-31 and sad-36) were administered to the apical surface of murine nasal septal epithelial (MNSE) cultures (grown at an air-liquid interface) and incubated for 24 hours. A potent lipopolysaccharide derived from *Escherichia coli* (100ng/ml) acted as a positive control. The apical and basal media of the cultures were collected and analyzed using the Mouse CXCL1/KC Immunoassay (functional homolog of human IL-8).

RESULTS: MNSE cultures exposed to PAO1 supernatant produced significantly elevated CXCL1/KC concentrations (1267.4 ± 54.3 pg/ml) when compared to sad-31 and sad-36. ($p < 0.001$) There was no difference in cytokine production between mutant strains ($p = 0.135$). KC concentration in the basal medium was 65% higher than in apical fluid measurements ($p < 0.0001$).

CONCLUSIONS: Secreted factors in the extracellular milieu of the biofilm forming strain of *Pseudomonas aeruginosa* incited significant upregulation of the pro-inflammatory chemokine CXCL1/KC in murine nasal respiratory epithelium when compared to mutant strains. Furthermore, cytokine production was greater in the media of the basal compartment indicating the appropriate area of measurement for future studies.

ABSTRACT NUMBER: 1884

DIFFERENTIATION OF CHRONIC RHINOSINUSITIS (CRS) AND ITS COUPLING TO LOWER AIRWAYS

Kåre Håkansson, MD, Prof. Christian von Buchwald, Simon Thomsen, PhD, Jacob Thyssen, MD

BACKGROUND: A close relation between the nose and lungs is increasingly accepted and has led to the hypothesis of the “united airways”. In this study, a descriptive analysis of rhinitis in a Danish general population was performed as a preparation for a future study focusing on Chronic Rhinosinusitis (CRS) and its association to lower airway disease.

METHOD: A general health examination was performed in 2006 in Copenhagen, the capital of Denmark. A postal questionnaire including questions about rhinitis were mailed to a random sample from the general population ($n = 7931$, age 18-69 years) and 3471 (44%) participants showed up for a health examination including specific IgE to common aeroallergens. A chi-square test was used to test for differences between the following groups: I) positive specific IgE but no rhinitis, II) positive specific IgE and rhinitis (allergic rhinitis), III) negative specific IgE and rhinitis (non-allergic rhinitis, NAR), and IV) negative specific IgE and no rhinitis.

RESULTS: NAR was significantly more prevalent among women, smokers and subjects with symptoms of COPD. Also, we found a diminished quality of life in subjects with NAR compared with other groups. We found a similar distribution of asthma in subjects with allergic rhinitis and NAR. Social status and alcohol consumption was not found to be significantly associated to any group.

CONCLUSION: This study indicates that not only asthma, but probably also COPD is an important co-morbidity in NAR.

ABSTRACT NUMBER: 1885

ENDOSCOPIC REPAIR OF CSF LEAK RHINORRHEA IN 165 PATIENTS: THE OUTCOMES

Marina Nersesyan, MD, Dmitry Kapitanov, PhD, Prof. Andre Lopatin, Prof. Alexander Potapov

OBJECTIVE. A retrospective study of the surgical outcomes of patients who underwent endoscopically guided repair of CSF rhinorrhea over a 10-year period.

METHODS. 165 patients were included in the study. The evaluation was conducted by chart review. The follow-up period ranged from 7 months to 10 years.

RESULTS. Of the 165 patients of the age 3 - 85 y. o. (mean 41,8): 75 were spontaneous, 38 - iatrogenic (30 after neurosurgeries and 8 after FESS) and 52 - traumatic. 132 patients (80%) were successfully treated with

endoscopic guidance at the first approach. Of the 24 (14,5%) who were underwent endoscopic revision for 18 patients had lumboperitoneal shunting. 9 patients (5,5%) had CSF leak recurrence 4 of whom required a subsequent intracranial approach and in 5 an endoscopic revision. Recurrence of CSF leakage was found to be associated with: raised CSF pressure and was higher in spontaneous leaks as well as in iatrogenic leaks after eurosurgeries. Interestingly, in spontaneous CSF leakage we found recurrence to be more commonly associated with fistulous tracts located along the lateral wall of well pneumatized sphenoid sinuses. Spontaneous CSF leaks were more common in women (mean age 46*7 years), who were obese (BMI>39,6 kg/m²), with empty sella syndrome, hypertensive, with respiratory pathology.

CONCLUSION. CSF rhinorrhea is successfully treated with endoscopic guidance, however, when the patient is an obese woman, hypertensive, and/or with pulmonary pathology, the neurosurgical colleagues, who are part of the skull base surgical team, should be on *stand by*, as their help may be needed for a successful outcome.

ABSTRACT NUMBER: 1887

COMPUTATIONAL MODELING OF NASAL AIRFLOW AND ODORANT TRANSPORT IN PATIENTS WITH CHRONIC RHINOSINUSITIS

Kai Zhao, PhD, Edmund Pribitkin, MD, Beverly Cowart, PhD, Pamela Dalton, PhD

Our 5-year multi-center study seeks to quantitatively characterize the conductive mechanisms contributing to olfactory loss in chronic rhinosinusitis (CRS) patients and in patients with other inflammatory disorders. As yet, the functional impact of the nasal obstruction experienced by CRS patients and the treatment outcomes in these patients have not been successfully indexed using existing tools such as acoustic rhinometry (AR), rhinomanometry (RM) or computed tomography (CT), the measurements of which correlate poorly with subjective symptoms. In this study, computational fluid dynamics (CFD) techniques are utilized to simulate nasal airflow and predict odorant delivery rates to the olfactory epithelium for each patient based on their pre & post-treatment CT. In this report, 37 CRS patients have been evaluated using AR, RM and CT, and their olfactory function characterized using measures of unilateral threshold sensitivity to l-carvone, d-limonene and phenethyl alcohol. Patient symptoms and pathology varied considerably, as did their olfactory abilities. Correlations between measured olfactory sensitivity and CFD, AR and RM predictions were examined. We preliminarily supported the hypothesis that the calculated olfactory delivery rate from the individualized nasal CFD models is a better predictor of olfactory sensitivity among CRS patients than are conventional methods. In the future, we envision that CFD modeling techniques may provide predictive models of treatment for CRS and an important pre-treatment guide to optimize airflow and odorant delivery in human nose. NIH P50 DC006760

ABSTRACT NUMBER: 1888

CEREBROSPINAL FLUID DETECTION IN NASAL FLUIDS USING THE Â – TRACE PROTEIN NEPHELOMETRIC METHOD

Erica Ortiz, Marcelo Sampaio, Eulalia Sakano, Carlos Chone

INTRODUCTION. CSF rhinorrhea is an abnormal communication between the anterior skull base and the nasal cavity. Its presence increases the incidence of complications, as meningitis, with risk of sequels. The early and correct diagnosis of the CSF leaks is important in order to perform surgical treatment as soon as possible. The CSF detection in nasal fluids could be made through the â2-transferrin test, an expen-

sive immunological test, non available to the majority of the Brazilian hospitals. Recently, the detection of â-trace protein for identification of CSF leaks has been described. Literature data suggests the same sensibility and specificity to the â2-transferrin, because â-trace protein is also a specific brain protein and it is present in CSF in high concentrations. The majority of Brazilians hospitals have the nephelometric equipment for â-trace protein detection.

OBJECTIVE: To determine the cut-off value for the â-trace protein concentration measurement in nasal cavity secretions to confirm or not presence of CFS leak.

MATERIAL & METHODS: Nasal secretions were collected from patients with suspicion of CSF leak and from healthy volunteers. A nephelometric assay was used to determine the â-trace protein concentration.

RESULTS: It was found a value between 0.29 and 0.43 mg/L for the cut-off.

CONCLUSION: Concentrations above values between 0.29 and 0.43 are highly suggestive of the presence of cerebrospinal fluid in nasal secretion. The â-trace protein can be a good alternative for the detection of CSF leak in Brazilians hospitals.

ABSTRACT NUMBER: 1892

COMPARISON OF PRICK, INTRADERMAL TESTING, AND INVITRO TESTING IN PREDICTING RESPONSE TO NASAL PROVOCATION WITH RAGWEED ANTIGEN

Camysha Wright, MD, Jing Shen, MD, Matthew Ryan, MD

BACKGROUND: Skin prick testing is increasingly promoted as an alternative to intradermal dilutional testing (IDT). However, the sensitivity and specificity of skin prick testing as compared to traditional IDT is still in question. An additional consideration is that test results with these methods may be dependent on the allergen tested. In this study, the role of skin prick testing in detecting ragweed allergy has been brought into question. The purpose of this study is to define the relationship between the Multi-test II skin prick and intradermal test results in testing for ragweed allergy using nasal provocation as the gold standard and comparing modified RAST results.

METHODS: Subjects with suspected ragweed allergy and controls were tested using the Multi-Test II skin prick test and skin endpoint titration using intradermal dilutional testing. They had baseline assessment of nasal cross-sectional area using acoustic rhinometry and underwent nasal provocation with increasing ragweed concentrations. Cross sectional area and nasal visual analog scale were assessed with each concentration. Blood was drawn and sent for mRAST testing for each subject.

RESULTS: 27 subjects have completed the protocol to date. Of these subjects, 30% have been positive to skin prick, 33% have been positive by intradermal testing, 50% have been positive by nasal provocation testing, and 12% have been positive by RAST. No statistically significant difference has been noted thus far between intradermal and skin prick testing.

CONCLUSIONS: Further study is warranted to determine the generalizability and clinical significance of these findings.

ABSTRACT NUMBER: 1893

COBLATION ASSISTED ENDOSCOPIC SINUS SURGERY

Maurice Roth, MD

Coblation is a process of tissue dissociation using a plasma-based radiofrequency device which includes a variable degree of bipolar cautery. Coblation can be used to remove soft tissue within the nose and paranasal sinuses. In addition, coblation can assist with ethmoidectomy, maxillary antrostomy, sphenoidotomy, as well as middle turbinate resection. The device can also be used during endoscopic sinus surgery to limit bleeding, improve visibility, and reduce the quantity of epinephrine injection during polypectomy. However, if coblation is used improperly during endoscopic sinus surgery, serious complications may arise. The purpose of this video poster is to share my five year experience with coblation assisted endoscopic sinus surgery. Through high definition video the safe application of coblation to each of the tasks listed above will be demonstrated. Potential complications and pitfalls will be shared. Limits of coblation assisted endoscopic sinus surgery will be discussed. The relevant basic and clinical science will be reviewed. This poster highlights patient safety above all else. This poster is recommended for any otolaryngologist interested in the application of coblation to endoscopic sinus surgery even if the surgeon is an experienced coblation user.

ABSTRACT NUMBER: 1894

NEW FOCUS-OLD DISEASE: THE PARANASAL SINUSES A FOCUS FOR BACTERIAL LUNG INFECTIONS IN PATIENTS WITH CYSTIC FIBROSIS (CF)

Kasper Aanaes, MD, Christian Buchwald, MD, Helle Johansen, MD, Niels Høiby, MD

BACKGROUND: Sinusitis is a common complication of CF causing significant symptoms associated with the lung disease. CF patients who have had a lung transplant are colonised in their new lungs with the same clones as those that were cultured from their old lungs. The sinuses may serve as a bacterial reservoir for lung infections.

STUDY DESIGN: 47 CF patients (19 male, 28 female) (median age: 6y, range 6-50 y) have been treated with FESS using CT image guidance to evaluate whether their sinuses serve as a bacterial reservoir. 19 patients were chronically infected (14 with *P. aeruginosa* (PA), 2 with *Burkholderia*, 2 with *Achromobacter*, 1 with *Moraxella*) and 28 were intermittently colonised (17 with PA, 11 with other CF pathogens) in their lungs.

RESULTS: We found good agreement between lung and sinus bacteriology in 15 out of 17 (88%) of the intermittently colonised patients. Seven patients chronically infected with PA had the same genotype in their lungs for more than 15 years and this genotype was identical to the PA obtained from the paranasal sinuses. In Gram stained smears from the sinuses we found that the bacteria were organised in biofilm structures similar to those seen in the lungs. In sinus smears we detected only few inflammatory cells compared to lung smears. Most of the children colonised with PA had growth of the same genotype of PA in their sinuses and sputum samples collected up to two years prior to the FESS operation. Five of 17 children intermittently colonised with PA were free of PA in their lungs after FESS operation (range 14-424).

CONCLUSIONS: The sinus colonisation might be immunological silent in intermittently colonised patients and cause only an insignificant anti-*P. aeruginosa* antibody response (Th1 response). Because of the weak signs of infection, the sinus colonisation can proceed unnoticed into a per-

manent infectious focus that cannot be eradicated with antibiotics. We believe that FESS operations can prevent lung infections in CF patients especially with an intensive postoperative treatment. This abstract will help physicians understand patients with cystic fibrosis, their chronic rhinosinusitis, the liberal indications for sinus surgery and the importance of postoperative treatment

ABSTRACT NUMBER: 1895

THE LONG-TERM EFFICACY OF MUCOSAL CpG OLIGODEOXYNUCLEOTIDES IN THE TREATMENT OF EUSTACHIAN TUBE DYSFUNCTION IN RATS

Deidra Blanks

BACKGROUND: Otitis media with effusion (OME) is a chronic inflammatory disease of the middle ear. Increasing evidence demonstrates an association between allergy and chronic OME. The binding of synthetic DNA-based immunotherapy agents composed of unmethylated cytosine-guanine dinucleotides (CpG ODN) to toll-like receptors are capable of inducing a shift in the cytokine profile and immune response that favors the Th1 pathway and suppress the Th2 pathway.

OBJECTIVE: The aim of the present study is to evaluate the long-term differences and ability of transtympanic and nasopharyngeal CpG ODNs to treat the allergic response to repeated allergy challenges, in ovalbumin sensitized Brown Norway rats.

DESIGN: Fifty Brown-Norway rats were divided into control and treatment groups. Eustachian tube dysfunction was evaluated by passive opening pressures, passive closing pressures, active clearance of negative pressure and mucociliary clearance transit time.

RESULTS: All CpG ODN treatment groups on day 43 required approximately 50% less pressure to open ($P < 0.001$) and close ($P < 0.001$) the Eustachian tube compared to the OVA allergic groups. The CpG ODN treatment groups had significantly lower opening and closing pressures until day 57.

CONCLUSION: CpG ODNs via transtympanic and nasopharyngeal application can treat allergy-induced eustachian tube dysfunction in rats for approximately 2 weeks without repeat treatment. CpG ODNs may offer substantial promise in the future management of eustachian tube dysfunction and OME.

ABSTRACT NUMBER: 1896

VALIDATION OF OPTICAL RHINOMETRY USING NASAL PROVOCATION TESTING IN ALLERGIC AND NONALLERGIC SUBJECTS

Amber Luong, MD, PhD, Esther Cheung, MD, Martin Citardi, MD, Pete Batra, MD

INTRODUCTION: Optical rhinometry (ORM) is a new method that quantifies light absorption in optical density (OD) to assess nasal blood flow as a measure of nasal patency. The purpose of this study is to validate ORM as an objective evaluation of nasal patency using nasal provocation testing (NPT) with histamine and oxymetazoline.

METHODS: Five adult subjects with and 5 without allergic rhinitis (AR) underwent NPT with histamine and oxymetazoline. Patients underwent NPT with increasing concentrations of histamine while undergoing ORM monitoring. The minimum concentration of histamine to cause a positive OD reading was recorded. The same subjects then underwent

histamine challenge with this minimum positive concentration followed by oxymetazoline. Nasal patency was assessed subjectively after each challenge with the visual analog scale (VAS).

RESULTS: The average minimum histamine concentration to cause a positive response on ORM was statistically lower in AR patients as compared to healthy controls at 210 g/ml and 330 g/ml, respectively ($p=0.035$). When comparing the relative change in light extinction in ORM with subjective nasal congestion based on VAS after histamine and afrin challenges, there was a statistically significant correlation with $r=0.589$ ($p < 0.003$).

CONCLUSION: This initial study demonstrates a correlation between subjective symptoms of nasal patency with measurements from the ORM. The lower histamine concentration necessary to incite nasal congestion on ORM in AR suggests that these patients are primed to the effects of histamine. ORM appears to represent a valid technique for assessment of nasal congestion.

ABSTRACT NUMBER: 1897

HISTOPATHOLOGY OF NASAL POLYPS FOR CRS; PRELIMINARY RESULTS

Joseph Han, MD, Rachel Moebus, BS, Marc Silverberg, MD

OBJECTIVE: Chronic rhinosinusitis (CRS) is an extremely common but yet poorly understood disease process of inflammation and infection. To better define the various forms of CRS, histopathologic pattern will be evaluated among the different forms of CRS.

MATERIALS & METHODS: Consecutive patients undergoing endoscopic sinus surgeries had their polyps undergo microscopic photodocumentation. The diverse forms of CRS that were examined were non-eosinophilic sinusitis, eosinophilic sinusitis with and without allergy, allergic fungal sinusitis (AFS), CRS among cystic fibrosis patients (CF), and aspirin triad. Control group was also examined. Samples were prepared histologically and examined. The area of most dense cellular population was found and a total of 500 cells were counted for eosinophils, PMNs, lymphocytes, and plasma cells. The epithelial morphology was recognized and the amount of ratio of epithelial cell to goblet cells was also determined. Cellular distribution was analyzed between each group and the control.

RESULTS: Seventy five samples were obtained and examined. Aspirin Triad, eosinophilic sinusitis with allergy, and eosinophilic without allergy had higher eosinophil counts than the control, non-eosinophilic, or CF groups ($p<0.05$). Among the eosinophilic diseases such as aspirin triad, eosinophilic sinusitis, and AFS, the disease with an allergy component had a higher amount of lymphocyte ($p<0.01$). There was no statistical difference in the amount PMN, plasma cell, and goblet cells amongst all the groups ($p>0.05$). Variants of CRS with less eosinophils and more likely associated with infection had cells densely located in the subepithelial space, while the eosinophilic sinusitis had cells located in the stromal tissue.

CONCLUSIONS: Histopathologic patterns can be used to assist in the diagnosis for the diverse presentation of CRS, which in term affect the prognosis and treatment of the patient.

ABSTRACT NUMBER: 1898

SAFETY AND EFFICACY OF CITRIC ACID/ZWITTERIONIC SURFACTANT (NOVUS) CLEANSING SOLUTION IN A RABBIT MODEL OF SINUSITIS.

Jennifer M. Kofonow MS, Jennifer Medina MS, Eric Tam, Bei Chen MD, Laurel Dogrhamji, RN, Matthew Myntti, PhD, Alexander G. Chiu, MD, James N. Palmer, and Noam A. Cohen, MD, PhD

INTRODUCTION: Persistent Chronic rhinosinusitis (CRS) may involve a particularly resistant form of infection known as a bacterial biofilm that is recalcitrant to antibiotics secondary to physical barrier characteristics. Recently, a novel sinus cleansing solution, Citric Acid/Zwitterionic Surfactant (CAZS) was demonstrated to be extremely effective in disrupting biofilms in vitro however with substantial ciliotoxicity. The purpose of this study was to investigate the toxicity and efficacy of a second generation CAZS, termed Novus, in the rabbit sinusitis model.

METHODS: Scanning electron microscopy (SEM) and ciliary beat frequency (CBF) were performed at 1, 3, and 6 days following treatment with Novus. Acute pseudomonal maxillary sinusitis was treated with one application of Novus or saline. Daily saline irrigations were performed and viable bacteria assessed for three consecutive days.

RESULTS: Morphologic analysis revealed mixed deciliation one and three days following Novus treatment, with $62\% \pm 17.8\%$ (range 47 - 79%) and $64\% \pm 23.2\%$ (range 36% - 81%) ciliation respectively, while six days post irrigation, near complete reciliation was evident ($96\% \pm 5.8\%$). Physiologic analysis demonstrated blunted CBF at 1 and 3 days following irrigation with frequency values 60% (range 39% - 88%) of the non-irrigated side while at 6 days CBF was 86% of non- irrigated side (range 76% -97%). Antibacterial activity, demonstrated a 1.5 log reduction in recovered viable bacteria at days 1 - 3 following treatment compared to saline.

CONCLUSIONS: This study demonstrates that in the rabbit acute pseudomonal maxillary sinusitis model a one time treatment with Novus sinus cleansing solution is able to reduce bacterial load by 1.5 logs for up to three days compared to saline but has mild reversible ciliotoxicity.

ABSTRACT NUMBER: 1553

THE IMPACT OF PROGNOSTIC FACTORS ON THE OUTCOME OF FUNCTIONAL ENDOSCOPIC SINUS SURGERY IN CHRONIC RHINOSINUSITIS

Prof. Ahmed Gama, Prof. Jean Lacroix, Hossam Elsherif Lectu

OBJECTIVE: To identify the prognostic factors that may affect the outcome of endoscopic sinus surgery (ESS) in chronic rhinosinusitis (CRS).

METHODS: 68 patients having CRS were studied including history taking, endoscopic examination, CT and measurement of nasal nitric oxide (nNO), nasal carbon monoxide (nCO) and total nasal airway resistance. All patients underwent ESS. The specimens were studied histopathologically (for eosinophilia) & Bacteriologically (for intracellular *S. aureus*).

STUDY DESIGN: Prospective study.

RESULTS: Intracellular *S. aureus*, old age, tissue eosinophilia, and Widal syndrome were found to be associated with a less favorable long-term outcome. In contrast, anatomic variants, allergy, bronchial asthma, and smoking do not seem to affect the prognosis of ESS in patients with CRS. Post-operatively, there was a significant increase in nNO and decrease in nCO production. Patients with polyposis showed less nNO level and olfactory threshold, but higher CT and endoscopic scores. The CT score correlated positively with the endoscopic score, the surgery score, and the degree of tissue eosinophilia.

CONCLUSION: 1- The prognostic factors that may affect the outcome of ESS in CRS have been identified. 2- The postoperative increase in nNO and decrease in nCO levels raises the question of whether they can be used to monitor the treatment of CRS like their use in bronchial asthma or not. 3- The olfactory deficit in patients with polyposis is most likely due to mucosal inflammation rather than airway obstruction.

ABSTRACT NUMBER: 1557

IMMUNOLOGICAL ROLE OF NASAL STAPHYLOCOCCUS AUREUS CARRIAGE IN PATIENTS WITH PERSISTENT ALLERGIC RHINITIS

Prof. Maged Refaat, Tarek Mansor, Zenab Ashour, Mohamed Attia

INTRODUCTION: Nasal carriage of staphylococcus aureus (*S. aureus*) exerts immunomodulatory effect in patients with atopic dermatitis and it may contribute to airway inflammation and allergic response in patients with allergic rhinitis.

OBJECTIVE: Investigate the frequency of nasal *S. aureus* carriage in patients with persistent allergic rhinitis and its possible influence on their symptoms and immune markers.

METHODS: We chose 20 non smoker patients with house dust mite (HDM) allergy causing allergic rhinitis and 20 non smoker healthy subjects matched for age and sex. For all subjects rhinoscopy was done, skin prick test, nasal culture for *S. aureus*, nasal interleukin 4, nasal total IgE, serum total IgE and serum specific IgE (SSiGE) for HDM. Results: Nasal *S. aureus* was detected in 16/20 patients (80%) and 5/20 (25%) in healthy subjects with highly significant statistical difference $p < 0.01$. Correlation of nasal staph. aureus count and different systemic and local immune markers revealed highly significant positive correlation between nasal staph. aureus count and serum total IgE ($r = 0.78, p < 0.01$) and significant positive correlation with SSiGE (HDM) ($r = 0.53, p < 0.05$), nasal total IgE ($r = 0.39, p < 0.05$) and nasal IL-4 ($r = 0.55, p < 0.05$).

CONCLUSION: Nasal staph. aureus actively modulated the immune reaction in persistent allergic rhinitis patients by promoting local IgE production, so we recommend early detection and treatment of *S. aureus* carriage in patients with allergic rhinitis.

ABSTRACT NUMBER: 1559

NEED OF ATTENTION TO THE NASOPHARYNGEAL TRACT HYGIENE

Fereidoun Heydarpour, Ph.D, Pouria Heydarpour, M.D, Robabeh Samadi, M.D

INTRODUCTION: Oral and dental hygiene has been in the center of attention, but nasopharyngeal tract hygiene left behind. Clearing nasopharyngeal tract reduced symptoms of nasal obstruction, sinusitis, allergic rhinitis, and epistaxis. In this study the effect of cleaning nasopharyngeal tract with warm normal saline was evaluated.

METHODS: About 10 g of purified salt which produced by re-crystallization method was poured in a jar with 1200 ml volume and warm water was added until the jar was filled. Washing of nasopharyngeal tract was performed twice daily, after waking up in the morning and before going to bed. Salt solution was gradually poured from the jar into one hand and doing suction with nose and pushing it out from the mouth.

RESULTS: Washing method of nasopharyngeal tract with warm normal saline is more tolerable than cold normal saline. Washing method removed all of the abnormal nasal discharge which could not be evacuated by blowing the nose. The nasopharyngeal passage remained clear for 12 hours after each washing, crust formation was prevented and normal nasal secretions were restored.

CONCLUSION: Pollution is a worldwide problem and its potential to influence the physiology of human populations is great, air pollution increases the rate of allergic rhinitis. Washing of nasopharyngeal tract help to remove allergens, and allergic rhinitis symptoms reduced. Removing of abnormal secretions reduced sinusitis symptoms and dissolution of crusts contributed to control epistaxis. Chloride help to turn abnormal nasal secretion to normal and remain open nasal passage.

ABSTRACT NUMBER: 1560

ENDOSCOPIC REMOVAL OF GIANT CELL REPARATIVE GRANULOMA OF THE SINUSES: CASE REPORT AND REVIEW OF THE LITERATURE

Eugene Chang, MD, James Brookes, MD, Richard Smith, MD

INTRODUCTION: Giant cell reparative granuloma (GCRC) is an inflammatory process characterized by bone formation and repair most often involving the maxilla, mandible and long bones. GCRC of the paranasal sinuses is extremely rare. We present an illustrative case and review all reported cases of GCRC in this location.

METHODS: 27 cases of surgically confirmed GCRC of the paranasal sinuses have been reported.

CASE STUDY: A 16-year-old female evaluated for left-sided headaches and diplopia by MRI was found to have a left anterior ethmoid mass that abutted the skull base, encroached into the left orbital cavity and pushed the nasal septum to the right. The mass was endoscopically excised, with final pathology showing GCRC. One month later, a second and definitive endoscopic procedure was completed to remove residual disease. Endoscopic examination four months later showed no evidence of disease, which was confirmed by CT.

RESULTS: All patients who presented with GCRC of the paranasal sinuses underwent surgery. Approaches ranged from isolated concha bullosa

removal to craniofacial resections; follow up ranged from one month to 14 years. Recurrences (7/21) and persistent disease (3/21) were noted early after the primary procedure (avg-3 months) and were treated with more extensive surgery, radiation, or antiangiogenic therapy.

CONCLUSION: GCRC is rarely encountered in the paranasals. Because it can be locally aggressive, treatment in this location can be challenging. Extensive surgery can be required, but as we describe, endoscopic removal is also possible and minimizes the morbidity of this disease.

ABSTRACT NUMBER: 1562

CT-MR IMAGE FUSION FOR THE MANAGEMENT OF SINONASAL LESIONS

Dr. Harvinder Singh, Prof. Dharambir Sethi, Dr. Leong

OBJECTIVE: To investigate the indications and accuracy of computed tomography (CT) and magnetic resonance (MR) (CT-MR) image fusion in intra-operative image guidance system during endoscopic nasal surgery.

METHODS: Patients that underwent CT-MR fusion studies between March 2007 till January 2008 were reviewed. CT scan images (1-mm axial) were obtained on a multi-detector CT scanner. MR images (1-mm axial) were obtained with a T1-weighted, volume acquisition technique. CT-MR fusion images were created on the Landmarx (Medtronic Xomed Jacksonville, Florida) Workstation. The accuracy of fused images was analysed. The optical tracking system used infrared technology for intraoperative navigation. Protocols used for registration are paired point registration (PPR) and contour-based registration (CBR). True intra-operative evaluation (TRE) of navigation accuracy was obtained by repeated referencing against known anatomical landmarks.

RESULTS: Fifty-four patients were included in this study. All CT-MR image fusion studies were carried out for diagnostic evaluation or pre-operative planning. The patient group included 34 men and 20 women with mean age of 47.74 years (range =18-79 years). Some patients had more than 1 indications. The diagnoses included neoplasms (13 benign and 5 malignant), chronic sinusitis (20), mucocoeles (7), nasal polyposis (10) each, 4 cerebrospinal fluid (CSF) leak, antrochoanal polyp (3), and one each of clival cyst and post choanal stenosis. The indications for performing the fusion scans were to assess tumor extent, mucocoele loculation, bony erosions along skull base or orbital walls and the integrity of the optic nerve and internal carotid artery. The resulting composite CT-MR images were accurate and clear. During pre-operative planning and intra-operative navigation, CT-MR fusion facilitated the delineation of the anatomic relationships of the paranasal sinuses, the lesions and the skull base.

CONCLUSIONS: CT-MR image fusion yields composite images that combine features of each component imaging modality. Image fusion, when combined with surgical navigation, further enhances applications of minimally invasive endoscopic surgery in complicated sinonasal and skull base cases.

ABSTRACT NUMBER: 1566

STUDY ON PROTEIN KINASE C ACTIVITY IN PERIPHERAL BLOOD T LYMPHOCYTES WITH ALLERGIC RHINITIS AND ITS SIGNIFICANCE

Shuqi Qiu, Xianhai Zeng

OBJECTIVE: To investigate the protein kinase C (PKC) activity in peripheral blood T lymphocytes with allergic rhinitis (AR) and the relationship between PKC activity and Th2 cytokines.

METHODS: 20 seasonal allergic rhinitis patients and 20 normal control persons participated in the study, T lymphocytes were isolated and purified from blood of each person who was divided into 2 groups: control group, the group were stimulated with phorbol 12-myristate 13-acetate(PMA), The total PKC activity of was detected by non-radioactive assay. The expression of IL-4 and IL-5 protein in supernatants were measured by ELISA.

RESULTS: PKC activity, the expression of IL-4 and IL-5 protein in supernatants in AR T lymphocyte stimulated with PMA were significantly higher than those of AR T lymphocyte stimulated without PMA and those of normal($P<0.01$, respectively), compared with those normal, PKC activity in AR control was significantly enhanced ($P<0.01$, respectively). The expression of IL-4 and IL-5 protein in supernatants of AR T lymphocyte stimulated without PMA weren't significantly higher than those of normal ($P>0.05$, respectively), There were good positive correlation between PKC activity of T lymphocyte and the expression of IL-4 and IL-5 protein in supernatants ($P<0.01$ respectively).

CONCLUSIONS: PKC activity and the expression of IL-4 and IL-5 in AR w significantly enhancer than those of normal control, The activation of PKC signal pathway of T lymphocyte may play an important role in the pathogenesis of allergic rhinitis.

ABSTRACT NUMBER: 1568

NOCTURIA IN OBSTRUCTIVE SLEEP DISORDERS

Bilal Cetin, Murat Erdem, Sinan Yetkyn, Fuat Ozgen

INTRODUCTION: Nocturia is a common complaint in obstructive sleep disorders (OSD) and its extremely effect life quality. There is no much more study prevalence and frequency of nocturnal urination in a OSD patients. In this study its aimed that to determine the prevalence and frequency of nocturnal urination among patients with SDB of different severities and to discover the factors related to nocturia.

METHOD: A retrospective review was conducted among 200 OSD and 100 snoring patients. These patients were compared with regard to frequency of nocturnal urination, age, sex, apnea- hypopnea index (AHI), body mass index (BMI) and current medical conditions.

RESULTS: Nocturi prevalence was found %62 in severe OSD patients. This result was significant difference mild OSD and snoring patients. There were found significant correlations between OSD patients and age, AHI.

CONCLUSION: Age and AHI were effect nocturia, BMI and current medical status were no effect nocturia.

ABSTRACT NUMBER: 1570

HISTOLOGICAL CHANGES IN INFERIOR TURBINATES POST COBLATION FOR TURBINATE HYPERTROPHY

Itzhak Braverman, M.D., Shelton Malatskey, M.D., Mary Amar, M.D.

INTRODUCTION: Although most cases of nasal obstruction respond to conservative anti-allergic treatment, some cases still require surgery. Surgical treatment is controversial; many methods have been implemented and literature reports debates relating to the amount of turbinate reduction necessary and resultant histological changes encountered. Coblation technology is based on an electric current flow in fluid resulting in tissue degradation without heat production or damage to surrounding tissues. We evaluated histological changes in patients who underwent inferior turbinectomy (IT) following coblation therapy.

METHODS: 121 patients who suffered from chronic nasal obstruction and failed to respond to conservative treatment were referred for IT coblation. 4/121 patients did not respond to this procedure and underwent turbinectomy. Eight IT's were subtotally removed with scissors and sent for pathological examination.

RESULTS: 117/121 (96.7%) showed significant improvement in nasal breathing. The 4/121 (3%) patients who did not respond were given a three-week interval follow-up, two months post-procedure. On pathological examination the specimens macroscopically appeared well-preserved; on microscopic examination minimal changes were observed. The respiratory covering epithelium was largely intact with only few areas showing squamous metaplasia. Some underlying areas showed fibrosing stroma with a slight degree of atrophy to the regional mucus glands. Compared to normal IT histology these changes in glandular and fibrotic components were minor.

DISCUSSION: IT coblation presented a high success rate; is a safe and effective office procedure, with relatively minimal histological changes observed by pathological examination. Less glandular tissue in post-coblation turbinates is a favorable factor in IT reduction for allergic patients with hypertrophic turbinates.

ABSTRACT NUMBER: 1574

ISCHEMIC BRAIN DAMAGE INDUCED AFTER ADENOTONSILLECTOMY IN ACHONDROPLASIA

Tae-Hoon Lee, MD, Bo-Young Kim, MD, Jeong-Yup Son, MD

INTRODUCTION: Sleep apnea is commonly found in children with achondroplasia. They can have obstructive and/or central sleep apnea related to neurological complications. These neurological complications can lead to morbidity and sometimes mortality and are associated with sudden infant death syndrome (SIDS). In addition, special care should be taken during anesthesia and adenotonsillectomy because existing cervicomedullary compression can result in apnea as well as cervical myelopathy and consequent paralysis and death.

CASE STUDY: We describe a 5-year-old girl with achondroplasia who suffered ischemic brain damage after adenotonsillectomy, and discuss the evaluation of sleep apnea and mechanisms of ischemic brain damage in patients with achondroplasia.

ABSTRACT NUMBER: 1581

TH2 CYTOKINE INHIBITOR SUPPLAST TOSILATE INHIBITS ANTIGEN-INDUCED MUCUS HYPERSECRETION IN THE NASAL EPITHELIUM OF SENSITIZED RATS

Takeshi Shimizu, MD, Shino Shimizu, MD, Reiko Hattori, MD

OBJECTIVES: Th2 cytokines such as Interleukin (IL)-4 and IL-13 are potential mediators for mucus hypersecretion in allergic inflammation. To elucidate the functions of Th2 cytokines in allergic rhinitis, we examined the in vivo effects of Th2 cytokine inhibitor suplastat tosilate on mucus hypersecretion and eosinophil infiltration in rat nasal epithelium.

METHODS: We induced hypertrophic and metaplastic changes in goblet cells in the nasal epithelium of ovalbumin (OVA)-sensitized rats by intranasal challenge with OVA. The effects of orally administered suplastat tosilate on mucus production and eosinophil infiltration were examined.

RESULTS: Suplastat tosilate (30 and 100 mg/kg) dose-dependently inhibited OVA-induced mucus production and eosinophil infiltration. These suppressions of mucus production and eosinophil infiltration were only effective when suplastat tosilate was given in the effector phase; administration in the induction phase resulted in no effect.

CONCLUSION: These results indicate that Th2 cytokines are important mediators for mucus hypersecretion and eosinophil infiltration in allergic rhinitis. Suplastat tosilate may be useful for the treatment of allergic rhinitis by attenuating the inflammation of the effector phase.

ABSTRACT NUMBER: 1591

NOVEL 5MM, 0-DEGREE WIDE-ANGLED SKULL BASE ENDOSCOPE

Joao Nogueira, MD, Aldo Stamm, PhD, Shirley Pignatari, PhD

INTRODUCTION: The development of nasal endoscopic surgical techniques paralleled advances in the technology of optic fibers, crystal lenses, angled endoscopes, new light sources, and camera systems. These concurrent advances allowed surgeons to perform more complicated procedures in the nose, paranasal sinus, skull base, and beyond. But as new frontiers are crossed, more complex procedures require the development of special instrumentation to optimize the safety and feasibility of the more complicated procedures.

OBJECTIVE: To describe the development of a 5-mm, 0-degree wide-angled 18 cm nasal endoscope, and its use in surgical procedures involving the nose, paranasal sinuses, and skull base.

METHODS: We used the novel endoscope in transnasal/transseptal binostrial pituitary operations, and compared the visual field, quality and brightness of lighting, focus capability, image sharpness and technical difficulties to the traditional 4-mm, 0-degree endoscope.

RESULTS: In every case, the visual field appeared larger with the 5-mm, 0-degree wide-angled endoscope than the images generated by the traditional 4-mm. endoscope. The novel endoscope also exhibited slightly better quality of light and image sharpness. There was more difficulty obtaining optimal focus with the novel endoscope, specially at the peripheral areas of the visual field. The larger size was more difficult to use in small nasal cavities.

CONCLUSIONS: The new 5-mm, 0-degree wide-angled endoscope is a magnificent addition for endoscopic nasal, paranasal and especially, skull base surgery. No significant difficulties or limitations were noticed with this new device.

ABSTRACT NUMBER: 1593

USE OF NASAL SEPTUM FLAPS IN ENDOSCOPIC SURGERY

Joao Nogueira, MD, Aldo Stamm, PhD, Shirley Pignatari, PhD, Maria Silva, MD

INTRODUCTION: The surgery of the nose, paranasal sinus, skull base and brain has changed dramatically with endoscopic techniques in the past few decades. One of these new techniques is the use of nasal flaps. These flaps can be originated almost in every spot of the nasal cavity, from the septum to the lateral wall of the nose, allowing access to structures, treatment of lesions and reconstruction of defects. There are several applications for the use of nasal flaps, from pediatric to elderly patients.

OBJECTIVE: Review the surgical technique, use and applications of the most common nasal flaps in endoscopic surgery.

METHODS: Literature and chart review from patients submitted to endoscopic surgery of the nose, paranasal sinus and skull base, the nasal flaps created, its application and efficacy.

RESULTS: Several nasal flaps were reviewed: from flaps in the treatment of choanal atresia to closing large skull base defects.

CONCLUSION: Nasal flaps, pediculated or not, can be used for several purposes. The surgical technique is feasible and its use can help surgeons in many different applications.

ABSTRACT NUMBER: 1595

EXPRESSION OF GLUTAREDOXIN-1 IN NASAL POLYPS AND AIRWAY EPITHELIAL CELLS

Yong-Dae Kim, MD, Hyun-Jae Woo, MD, Heung-Man Lee, MD

BACKGROUND/OBJECTIVE: Glutaredoxins-1 (GRX-1) are glutathione-dependent oxidoreductases. However, the role of these enzymes remains unknown in airway inflammatory diseases. Therefore, we aimed to demonstrate the expression pattern of GRX-1 in the nasal polyps (NPs) and to assess the regulatory mechanisms associated with GRX-1 expression in IL-1 α -treated airway epithelial cells.

METHODS: The expression of GRX-1 in NPs and normal nasal mucosa were analyzed by RT-PCR and immunohistochemical staining. IL-1 α -induced reactive oxygen species (ROS) formation and GRX-1 expression in the airway epithelial cells was determined by flow cytometry and immunoassay.

RESULTS: The expression level of GRX-1 in NPs was significantly higher than in the normal nasal mucosa ($p < 0.05$). GRX-1 was highly expressed in the surface epithelial cells and the submucosal glandular cells in the NPs. IL-1 α increased the intracellular ROS formation and GRX-1 expression in airway epithelial cells. The inhibition of IL-1 α -induced ROS production by N-acetyl-cystein, a ROS scavenger, reduced GRX-1 expression. Diphenylene iodonium and apocynin, NADPH oxidase inhibitors, did not abolish IL-1 α -induced ROS formation and GRX-1 expression, whereas budesonide attenuated it.

CONCLUSION: High GRX-1 expression in NP might be a primary defense against chronic inflammatory stress in nasal mucosa. IL-1 α -induced up-regulation of GRX-1 in airway epithelial cells is probably mediated by ROS. Glucocorticoids can regulate IL-1 α -induced ROS formation and GRX-1 expression.

ABSTRACT NUMBER: 1596

CLINICAL CLUES TO DIFFERENTIATE ALLERGIC AND NONALLERGIC RHINITIS IN A LARGE SAMPLE OF REFERRED PATIENTS

Mustafa Akarcay, Dr. Murat Miman, Tamer Erdem, Semih Oncel

OBJECTIVE: The aim of this study is to emphasize on the value of the clinical history of rhinitis and to fill some of the gaps of knowledge about differential diagnosis of rhinitis.

METHODS: A total number of 910 patients were set by their diagnosis into one of the rhinitis groups; seasonal allergic rhinitis (SAR), perennial allergic rhinitis (PAR) and non-allergic rhinitis (NAR). Patients' admitting seasons to clinic, types and duration of symptoms, triggering factors, parental history, associated allergic diseases (skin, lung, eye), findings in nasal examination, and skin prick test results were analyzed for statistical difference between groups.

RESULTS: Patients with SAR were found younger than both the patients with NAR and PAR. It was found that patients with SAR were most commonly admitted in spring and summer, while least in winter when compared with other groups. Itchy complaints and eye redness were found more frequent in SAR patients. The most common inducing factors were temperature changes, detergent odor and cold air for NAR and green area visit for SAR. In nasal examination, pale nasal mucosa was statistically more prominent in the NAR group.

CONCLUSION: Seasonal exacerbations of rhinitis symptoms is a typical information in allergic rhinitis sufferers, particularly in SAR. Common physical and chemical factors inducing rhinitis symptoms are not sufficient to differentiate rhinitis, with the exception of green area visit and some activities in the rural area. Nasal examination, alone, adds nothing to clinical data when trying to differentiate rhinitis subgroups.

ABSTRACT NUMBER: 1597

DO CO-MORBIDITIES INFLUENCE OBJECTIVE AND SUBJECTIVE RECOVERY RATES OF NASAL POLYPOSIS?

Dr. Yezdan Firat

OBJECTIVES: To investigate the clinical and laboratory outcomes both objectively and subjectively in nasal polyposis patients with or without co-morbidity (CoM) (asthma and allergy).

MATERIALS AND METHODS: Thirty-three nasal polyposis patients (13 females, 20 males) were included into the study. The mean age was 39.23 ± 9.13 years. CoM(+) and CoM(-) nasal polyposis patients were compared with each other. Evaluations contained endoscopic nasal examination, acoustic rhinometry, rhinomanometry, visual analog scale score of nasal blockage, olfactory function score, respiratory function test, skin prick tests and paranasal sinus computerized tomography.

RESULTS: Total recovery was observed in all followed evaluations for endoscopic and radiologic staging, nasal obstruction and sense of smell compared with the first evaluation in all patients regardless of the subgroups. Although objective measurements of respiratory functions did not show any change, clinical improvement was detected in CoM(+) patients with a decrease of the need to their anti-asthmatic medical treatment.

CONCLUSION: Relatively worse results in CoM(+) patients led no statistical difference when compared with CoM(-) subgroup. This may bring not more than the need for close follow-up of the patients with co-morbidities when applied such as predefined treatment protocol for nasal polyposis.

ABSTRACT NUMBER: 1613

THE EFFECTS OF SEPTOPLASTY ON MIDDLE TURBINATE SIZE

Sohrab Shahab, MD, Hassan Ramadan, MD

INTRODUCTION: The chicken and egg argument of whether turbinate hypertrophy or septal deviation comes first has been heavily debated for decades. In an attempt to resolve this ongoing debate, it seems intuitive to examine the effects of septoplasty on middle turbinate (mt) size. It has been noted that the mt on the convex side of severe septal deviation is often thin, foreshortened and flimsy. The cause for this underdevelopment has not been elucidated, however it seems that a lack of airflow on the convex side of the septum may contribute to this phenomenon.

METHODS: The preoperative and postoperative CT scans of patients who underwent septoplasty and unilateral concha bullectomy were retrospectively reviewed. The height and width of the mt on the convex side of the septum were measured at the tip of the mt and at the level of the uncinat process on the preoperative and postoperative scans. Statistical analysis was then performed using SAS software.

RESULTS: The width of the mt at its tip increased by 28.9%, 0.9mm ($p=0.0166$), the width of the mt at the level of the uncinat process increased by 21.7%, 1.0mm ($p=0.0098$), the height of the mt at its tip increased by 5.4%, 1.3mm ($p=0.0085$), the height of the mt at the level of the uncinat process increased by 2.8%, 0.7mm ($p=0.2932$).

CONCLUSION: Unilateral mt hypertrophy occurs after septoplasty in patients with severe septal deviation. This is most likely secondary to exposure of increased airflow of the previously airflow deprived underdeveloped turbinate.

ABSTRACT NUMBER: 1615

ANTROCHOANAL POLYPS WITH ASSOCIATED OSSEOUS FRAGMENTS: NIDUS OF INFLAMMATION AND ORIGIN OF DISEASE?

David Darley, MD, Parul Goyal, MD

OBJECTIVES: Antrochoanal polyps (ACP) can be associated with recurrence despite surgical resection. This report presents the finding of bone fragment at the base of ACP and how this finding may play a role in the pathogenesis and adequate treatment of ACP.

STUDY DESIGN: Case report and literature review.

METHODS: The medical records, imaging studies, and intraoperative findings of two patients with ACP are reviewed. The literature is also reviewed.

RESULTS: Two patients with ACP underwent endoscopic sinus surgery. Both patients were found to have a region of bony irregularity at the base of the polyp on pre-operative CT scan. Intraoperatively, a loose bone fragment was seen submucosally at the base of the ACP in both cases. The fragment was removed after the attachment site of the polyp was resected.

CONCLUSION: ACP have been observed to arise from chronic inflammation of the nasal mucosa of the paranasal sinuses. The underlying pathophysiology is unknown, but bacterial, fungal, and allergic etiologies have been proposed. This report describes the presence of osseous fragments at the base or origin of the ACP. Although cause and effect cannot be determined based on this limited report, it is possible that the bone fragments represent a nidus of inflammation. Removal of the polyp attachment site and any associated bone fragments may be im-

portant in decreasing the likelihood of recurrence. These findings may provide further insight into the pathogenesis of the disease and further may help to improve clinical treatment and outcome through recognition and removal of the fragments.

ABSTRACT NUMBER: 1621

IS THERE ANY RELATIONSHIP BETWEEN TURBULENCE MADE BY SEPTAL DEVIATION AND ALLERGIC SEVERITY

Bumjo Jung

BACKGROUND AND OBJECTIVE: Turbulence through the nasal cavity by septal deviation can make allergen Contact to nasal mucosa more time. So I want to know the relationship between septal deviation severity and allergic status especially measured by MAST(multiple allergen stimulation test).

MATERIAL AND METHODS: I reviewed 100 allergic patient living in ilsan KOREA, and checked Water's view & Caldwell's view and MAST result. I checked Septal deviation severity by sum of triangular area which was made by the distance between anterior nasal spine and cribriform plate and distance between this line and deviated septal apex.

RESULTS: Regression analysis was done for Evaluation of septal deviation and allergic status. And there is no statistically significance between two variable.

CONCLUSION: The aggravating factor to allergic rhinitis should be found in many method. That can be make human life more better. So we had better find may factor to aggravating allergic rhinitis.

ABSTRACT NUMBER: 1624

FIBROEPITHELIOMA OF PINKUS ON MUCOCUTANEOUS JUNCTION AT THE NOSTRIL

Joohwan Kim, MD

ABSTRACT NUMBER: 1629

THE NASAL ENDOSCOPIC SIMULATOR AS A TEACHING TOOL FOR SURGICAL ANATOMY

Erdal Seren, M.D.

BACKGROUND: Nasal endoscopic simulators allow trainees to practice techniques without consequences, reduce potential risk associated with training, and help to develop standards and optimize procedures before endonasal surgery.

METHODS: We developed a software program that is called "Nasal endoscopic simulator; NES". Computer algorithms were developed using Microsoft Visual Basic 6.0 languages. Texture-mapped digitized images provided a close anatomic similarity to actual video-endoscopic images.

RESULTS: NES is expected to provide benefits in many aspects of surgical procedure training and evaluation.

CONCLUSION: NES can be beneficial as a tool for training and preoperative planning. Computer based simulation provides not only a cost effective alternative to traditional training but also a way to assess the surgeons performance. Disadvantages identified were time consumption, absence of force feedback.

ABSTRACT NUMBER: 1634

EFFECTS OF DIETARY POLYPHENOLS ON MUC5AC GENE EXPRESSION IN RESPIRATORY EPITHELIAL CELLS AND ON CILIARY MOVEMENT

Kyung-Su Kim, MD, Hyun Jun Kim, Kee Jae Song, Joo-Heon Yoon

INTRODUCTION: Dietary polyphenols have been widely consumed in food, and their anti-inflammatory, anti-oxidative and anti-mutagenic activities have been recently studied. However, the effect on mucin hypersecretion or mucociliary movement of dietary polyphenol has not been elucidated yet. Therefore, this study was to investigate whether dietary polyphenols ([6]-gingerol, EGCG, curcumin, quercetin) inhibit MUC5AC gene expression, and if so, whether they would have effect on the ciliary movement of human nasal mucosa.

MATERIALS AND METHODS: After NCI-H292 cells had been treated with IL-1 α (10 ng/ml) and pretreated with 4 different dietary polyphenols ([6]-gingerol, EGCG, curcumin, quercetin), the mRNA expression of MUC5AC was determined by real-time polymerase chain reaction. Normal nasal mucosa was obtained during sphenoid sinusotomy and treated with minimal inhibitory concentration of each polyphenol. Ciliary movement was assessed via inverted microscope and computerized program.

RESULTS: Minimal inhibitory concentration of MUC5AC gene expression in each polyphenol was found as following; [6]-gingerol 1 μ M, EGCG 20 μ M, quercetin 40 μ M, and curcumin 10 μ M. Each polyphenol did not influence cell proliferation at this minimal inhibitory concentration. In assessment of ciliary movement, [6]-gingerol, quercetin, EGCG did not show any difference between control group and experiment group, but curcumin showed decrease of ciliary movement.

CONCLUSION: [6]-gingerol, quercetin, and EGCG suppress MUC5AC gene expression and maintain normal ciliary movements. Therefore, these polyphenols may be used as anti-hypersecretory agents and the further clinical study will be needed.

ABSTRACT NUMBER: 1635

INCREASED EXPRESSION OF MUC16 MUCIN GENE IN CHRONIC RHINOSINUSITIS

Heung-Man Lee, MD, Hyo-Hyun Park, MS, Yong-Dae Kim, MD

BACKGROUND: The primary mechanisms leading to mucus hypersecretion in chronic sinus inflammation are not well understood. MUC16 encodes a cell surface membrane-anchored mucin expressed in the normal gastrointestinal tract, trachea, cornea, middle ear mucosa, lacrimal gland and kidney as well as colorectal, esophageal, gastric, pancreatic, and lung cancers. However the expression of MUC16 in sinus mucosa is not known yet.

OBJECTIVES: This study aims to investigate the expression of MUC16 messenger RNA (mRNA) and to localize the protein and to compare between normal and chronically inflamed sinus mucosa.

METHODS: Twenty patients with chronic rhinosinusitis who were undergoing functional endoscopic sinus surgery were recruited for the study. Twenty patients with no evidence of sinus disease were used as control subjects. RNAs were extracted from sinus mucosa, and semiquantitative reverse transcription-polymerase chain reaction was performed for MUC16. Localization and expression of MUC16 protein was sought by immunohistochemical staining and western blotting analysis.

RESULTS: The level of MUC16 mRNA expression in chronic rhinosinusitis was significantly increased compared with that in normal sinus mucosa. We found more intense expression of MUC16 protein in the sinuses with chronic rhinosinusitis than in normal sinus mucosa.

CONCLUSION: These results suggest that increased expression of MUC16 in chronic rhinosinusitis may play an important role in the pathogenesis of sinus hypersecretion in chronic rhinosinusitis.

ABSTRACT NUMBER: 1638

THROMBIN STIMULATES VEGF PRODUCTION FROM NASAL EPITHELIAL CELLS

Shino Shimizu, MD, Eriko Hoshi, MD, Satoshi Seno, MD, Takeshi Shimizu, MD

BACKGROUND: Thrombin does not only serve as a coagulation factor, but also relates airway inflammation by activating protease-activated receptors (PARs). Vascular endothelial growth factor (VEGF) is an important mediator for airway remodeling of the nasal cavity such as polyp formation.

OBJECTIVES: In the present study, we evaluated whether inflammation increases generation of thrombin in nasal secretion, and whether thrombin stimulates VEGF production from nasal epithelial cells.

METHODS: We measured the concentration of thrombin in nasal secretion from patients with chronic sinusitis and nasal allergy, using thrombin specific substrate. The effects of thrombin on VEGF production from cultured human nasal epithelial cells were examined. The expressions of PARs and VEGF in human nasal mucosa were also examined by the immunohistochemical staining.

RESULTS: We found that the concentration of thrombin is elevated in allergen-induced nasal secretion from patients with nasal allergy. Enzyme immunoassay demonstrated that thrombin and agonist peptide of PAR-1 stimulated VEGF secretion from human nasal and bronchial epithelial cells. Immunohistochemistry revealed the expressions of PAR-1 and VEGF in nasal epithelial cells from patients with nasal polyps.

CONCLUSION: These results indicate that thrombin plays an important role in airway remodeling by stimulating the VEGF production from nasal epithelial cells via its receptor PAR-1.

ABSTRACT NUMBER: 1646

OLFACTORY DISTORTIONS: ETIOLOGIC-BASED DIFFERENCES IN CLINICAL PRESENTATION

Wendy Smith, MD, Terence Davidson, MD, Claire Murphy, PhD

INTRODUCTION: Dysosmias (i.e., phantosmias and parosmias) are sensory distortions estimated to occur in 10-60% of patients with olfactory loss. However, relatively little is known about this condition. This study aimed to characterize differences in clinical presentation, symptom ratings and psychophysical measures of olfaction in patients with dysosmia based on etiology of smell loss.

METHODS: Retrospective chart review of patients who presented to a university-based nasal dysfunction clinic with complaint of dysosmia. Workup included complete history, examination, psychophysical testing, and imaging. Data were analyzed using univariate and post-hoc analysis.

RESULTS: One hundred and two patients (males=45, females=57) with dysosmias were identified. Thirty-nine patients presented with only phantosmia, 32 patients with only parosmia, and 31 patients with both. The most common etiology in males was inflammatory disease (36%), compared to post-viral (35%) for females. Parosmias were significantly more likely to occur among patients with post-viral olfactory loss (means significantly different, $p < 0.05$), whereas phantosmias were more likely amongst patients with inflammatory and traumatic etiologies (means significantly different, $p < 0.05$). Patients with traumatic smell loss were significantly more likely to have lower olfactory function scores as compared to inflammatory and “other” etiologies (means significantly different, $p < 0.01$). No significant group differences were seen in rates of reported hypogeusia or dysgeusia, trigeminal function, or ability to identify the odor associated with dysosmia. Attempted treatments include observation, oral steroids, antibiotics, nasal irrigation, and olfactory ablation.

CONCLUSIONS: Olfactory distortions affect many types of patients with olfactory loss. Significant differences in clinical presentation are found between etiological groups.

ABSTRACT NUMBER: 1648

CHONDROID CHORDOMA OF THE SELLA MIMICKING A PITUITARY ADENOMA

Arthur Wu, MD, Neil Martin, MD, Marilene Wang, MD

INTRODUCTION: The vast majority of masses in the sella are pituitary adenomas. Chordomas of the sella are rare lesions but the presenting symptoms are similar to a pituitary mass. Here we describe a patient who presented with slowly progressive right-sided visual loss and bitemporal visual field deficits. MRI demonstrated a 2 cm sellar mass, extending superiorly to compress the optic chiasm. Neuroradiology interpreted the mass as a pituitary macroadenoma. Surgical resection was done, and the pathology results demonstrated a chondroid chordoma. The radiographic and pathologic findings will be presented and compared with those of a pituitary adenoma.

METHODS: Case report.

RESULTS: A 50 year-old patient presented with signs and symptoms of a pituitary adenoma. He underwent endoscopic transnasal transphenoidal resection of this tumor. At the time of surgery a gelatinous mass was found in the sella with involvement of the sellar bone. Areas where the bone was invaded by tumor were drilled down. The final pathology was chondroid chordoma. Post-operative imaging demonstrated complete gross removal of the mass.

CONCLUSION: Chondroid chordomas are rare, slow growing but locally aggressive tumors derived from embryonic remnants of the notochord. Intracellular chordomas are very rare and can be confused clinically and radiographically with pituitary adenomas. The lesions are nearly identical on MRI; however T2-weighted imaging can sometimes demonstrate higher density in chondroid chordomas versus adenomas. CT scans also may be helpful demonstrating bony destruction from these lesions, as well as intralésional calcifications. Surgical removal via a transnasal endoscopic approach is the treatment of choice.

ABSTRACT NUMBER: 1649

ENDOSCOPIC REMOVAL OF A LOBULAR CAPILLARY HEMANGIOMA OF THE NASAL CAVITY INVADING THE DURA

Arthur Wu, MD, Neil Martin, MD, Marilene Wang, MD

INTRODUCTION: Lobular capillary hemangiomas, also known as pyogenic granulomas, are benign skin and mucosal lesions of unclear etiology, associated with trauma, pregnancy, and oral contraceptive use. The majority of pyogenic granulomas are found in the oral cavity, with rare occurrence in the nasal cavity. Here we describe an unusual case of a patient with a large nasal pyogenic granuloma invading the dura.

METHODS: Case report.

RESULTS: A 56 year-old patient presented with a several month history of increasing headache, hyposmia, and nasal congestion. The patient denied epistaxis, a history of nasal trauma, or previous sinus problems. She was found to have a large friable mass of the left nasal cavity. MRI revealed a 3.5 cm mass centered in the left ethmoid, eroding through the cribiform plate with adjacent dural enhancement. Biopsy demonstrated a benign vascular lesion. The patient underwent endoscopic resection of the mass. The mass thinned the lamina papyracea, eroded through the cribiform, and adhered to the dura. A dural defect was closed with fascia lata and fat grafts. Postoperative imaging showed complete removal of tumor. Final pathology demonstrated lobular capillary hemangioma.

CONCLUSION: Pyogenic granulomas of the nasal cavity are rare and may be detected later than those of the oral cavity. While small lesions are amenable to endoscopic removal, larger lesions in the literature have typically necessitated open craniofacial techniques, with bleeding being the main deterrent. This case report demonstrates that even large lesions with intradural extension can be completely resected via endoscopic techniques.

ABSTRACT NUMBER: 1651

CLINICAL ANALYSIS OF SINONASAL INVERTED PAPILLOMA ACCORDING TO STAGING SYSTEM

JooHwan Kim, MD, Jin-Hee Cho, MD, Sung Won Kim, MD, Soo Whan Kim, MD

OBJECTIVE: To evaluate our results in the treatment of the nasal inverted papillomas according to staging system using a retrospective case series.

METHODS: Between March, 1997 and July, 2007 we treated 157 patients with nasal inverted papillomas. A retrospective review was performed to evaluate the demographic data, clinical presentations and involved site of tumor. Histologically proven cases with a minimum of 12 months follow-up period were included. All patients were staged according to the Krouse's staging system and new staging system by Citardi et al. We compared the recurrence rate according to the tumor stage.

RESULTS: The median age was 53.7 years and 71% were male. The most frequent presenting complaint was nasal obstruction. The most common site of involvement was the lateral nasal wall. According to the Krouse's staging system, T1, T2, T3 and T4 were 29 (19.3%), 69 (46%), 51 (34%) and 1 (0.7%). According to the staging system by Citardi et. al. group A, B and C were 98 (65.3%), 51 (34%) and 1 (0.7%). The recurrence rates of T1, T2, T3 and T4 were 3 (10.3%), 8 (11.6%), 8 (15.7%) and 1 (100%). The recurrence rates of group A, B and C were 11 (11.2%), 8 (15.7%) and 1 (100%).

CONCLUSIONS: The Krouse's staging system, based on the involvement of IP, is a simple tool for grading IP. New staging system by Citardi et. al. provides information about recurrence rates after surgery. Both staging system could provide important objective data.

ABSTRACT NUMBER: 1654

EXPRESSION OF GLUTAREDOXIN-1 IN NASAL POLYPS AND AIRWAY EPITHELIAL CELLS

Yong-Dae Kim, MD, Hyun-Jae Woo, MD, Heung-Man Lee, MD

BACKGROUND/OBJECTIVE: Glutaredoxins-1 (GRX-1) is glutathione-dependent oxidoreductase. However, the role of these enzymes remains unknown in airway inflammatory diseases. Therefore, we aimed to demonstrate the expression pattern of GRX-1 in the nasal polyps (NPs) and to assess the regulatory mechanisms associated with GRX-1 expression in interleukin (IL)-1 α treated airway epithelial cells.

METHODS: The expression of GRX-1 in NPs and normal nasal mucosa were analyzed by RT-PCR and immunohistochemical staining. IL-1 α -induced reactive oxygen species (ROS) formation and GRX-1 expression in the airway epithelial cells was determined by flow cytometry and immunoassay.

RESULTS: The expression level of GRX-1 in NPs was significantly higher than in the normal nasal mucosa ($p < 0.05$). GRX-1 was highly expressed in the surface epithelial cells and the submucosal glandular cells in the NPs. IL-1 α increased the intracellular ROS formation and GRX-1 expression in airway epithelial cells. The inhibition of IL-1 α -induced ROS production by N-acetyl-cystein, a ROS scavenger, reduced GRX-1 expression. Diphenylene iodonium and apocynin, NADPH oxidase inhibitors, did not abolish IL-1 α -induced ROS formation and GRX-1 expression, whereas budesonide attenuated it.

CONCLUSION: High GRX-1 expression in NP might be a primary defense against chronic inflammatory oxidative stress in nasal mucosa. IL-1 α -induced up-regulation of GRX-1 in airway epithelial cells is probably mediated by ROS. Glucocorticoids can regulate IL-1 α -induced ROS formation and GRX-1 expression.

ABSTRACT NUMBER: 1659

THE COMPANSATION MECHANISM OF ETHMOID CELL VOLUME IN NASAL SEPTUM DEVIATION

Ahmet Firat, MD, Murat Miman, Yezdan Firat, Hakký Karakas

BACKGROUND: The aim of this study was to evaluate the effect of nasal septal deviation (NSD) on ethmoid cell volume and to determine whether there was any correlation between NSD grade and ethmoid cell volume.

METHODS: Fortyfive computerized tomography (CT) scans from patients with rhinosinusitis symptoms with NSD were evaluated. Septal deviations were classified into three groups according to the degree of deviation on CT. Ethmoid cells volume were measured and relationship between NSD and ethmoid cell volume was investigated.

RESULTS: There was a moderate but significant negative correlation between the septal deviation angle and the percentage of the ethmoid volumes Total ethmoid cell volume on the ipsilateral side compared with the contralateral side was found to decrease as the degree of NSD increased.

CONCLUSIONS: Nasal septal deviation affects the total ethmoid cell volume of the nasal cavity. The results of our study underline the role of ethmoid cell volume in the compensation mechanism equalizing the nasal cavity airflow changes due to NSD. With this findings, additional ethmoid cell reconstruction may be proposed to enhance the airflow dynamic in both nasal cavity additional to NSD adjustment.

ABSTRACT NUMBER: 1660

PREEMPTIVE ANALGESIC EFFECT OF RINOEBASTEL AND OLIVE OIL FOR NASAL PACKING REMOVAL

Kun Hee Lee, Hoon Jung, Seung Yup Shin, Sung Wan Kim

OBJECTIVE: The most frequent complaint of patients after septoplasty is severe pain felt during removal of nasal packing placed on the operation. Various methods have been described to decrease pain and to increase patient comfort during removal of nasal packing. However, previous methods are not practical. There has been an increase in the number of studies on preemptive analgesia use for postoperative pain relief. The aim of this study was to evaluate analgesic effect of Rinoebastel (antihistamine and pseudoephedrine) and olive oil during removal of Merocel packs placed in septoplasties.

METHODS: A prospective study was conducted on 45 patients undergoing septoplasty in our hospital. Merocel packing was applied in each side and kept for 2 days post-operatively. The patients were randomly assigned into four groups: control, rinoebastel, olive oil and rinoebastel with olive oil groups. In the rinoebastel group patients received two tablets for two days, In olive group merocel was rehydrated with 30ml olive oil every 6 hours for two days. Visual analog scale (VAS) scores were measured immediately after removal of nasal packing. We compare removed merocel volume among all study groups.

RESULTS: VAS scores immediately after the removal of nasal packs more significantly decreased in the study group than control group ($p < 0.05$). There was no significant difference in VAS values between rinoebastel group and rinoebastel with olive oil group. ($p < 0.005$), but rinoebastel group and rinoebastel with olive oil group show significantly lower VAS values than olive oil group. ($p < 0.05$). There was no significant difference in removed merocel volume among three study groups.

CONCLUSIONS: It can be concluded that olive oli decreases pain during removal of nasal packing placed in septoplasties and rinoebastel can show synergic effect with olive oil for decreasing pain.

ABSTRACT NUMBER: 1661

HISTOLOGIC STUDY OF E-PTFE REMOVED AFTER RHINOPLASTY

Ji Yun Choi, MD

OBJECTIVES: Gore-Tex is known to be a relatively safe material. However, it leads to complications. Although wide use, the reason why complications were occurred is poorly understood. Thus, this study attempted to investigate histological changes of the Gore-Tex removed within a certain period of time after rhinoplasty between the Gore-Tex and its neighboring tissues.

METHODS: This study involved 122 Gore-Tex samples obtained at the time of reoperation in patients who had undergone augmentation rhinoplasty. The subject group included 31 men and 91 women. The mean patient age was 30.2 years, and the mean Gore-Tex implantation period was 23.2 months (range: 1 week to 13 years). We noted the shapes of the Gore-Tex samples, their relationships and extent of adhesion with neighboring tissues, and the changes of thickness. We also observed tissue ingrowth, calcification, inflammation, foreign body reaction, and structural changes using light microscopy and electron microscopy.

RESULTS: After the Gore-Tex samples had been in place for an extended period of time, the neighboring tissues grow into the central portions of the samples, which enhanced adhesions between the samples and the tissues. In addition, Gore-Tex samples that had been implanted for longer periods of time were associated with decreased thickness and calcification, foreign body reactions and structural changes increased.

CONCLUSIONS: In contrast to previous studies, our study showed that Gore-Tex samples implanted in human bodies for extended periods of time prompted ingrowth of neighboring tissues; calcified tissue degeneration, inflammation, and foreign body reactions were found in a large number of samples. The Gore-Tex structures were destroyed and transformed. As a result, it is important to follow the stability of Gore-Tex material on a long-term basis.

ABSTRACT NUMBER: 1667

ISOLATED SPHENOID SINUSITIS

Rafael Hijano, MD, Isabel Homs, Frances Xavier Subirana, Francina Aguilar

INTRODUCTION: Isolated sphenoid sinusitis is an uncommon entity which has a different clinical presentation compared to chronic rhinosinusitis affecting more than one sinus. Different pathogens are commonly involved.

METHODS: 85 years-old female suffering from headache and diplopia. A nasal endoscopy was carried out, showing a white rhinorrhea in the superior meatus. Its culture was sterile. A CT scan and an MRI were performed, showing an image of occupation of the entire sphenoid without bony erosion. A surgical procedure was planned after a non-successful medical treatment.

RESULTS: An endoscopic transnasal approach was used to enter the sphenoid. The superior turbinate was used as the critical landmark. After location of the natural ostium, a large enough indentation was created. Purulent content was aspirated, as well as debris removed. Posterior lavage of the sinus was carried out. The results of the cultures were *Pseudomonas aeruginosa* and *Aspergillus* sp. No complementary antibiotics were used after the procedure. The patient is currently asymptomatic and the CT scan shows a healthy sphenoid with a competent ostium.

CONCLUSIONS: The diagnosis of isolated sphenoid sinusitis may be suspected by unspecific symptoms and supported by radiological

imaging, which will be used as a guide during the surgical procedure. When medical treatment fails, an endoscopic transnasal approach is safe and a successful surgical procedure. After the complete removal of debris, the preservation of the natural ostium of the sphenoid seems to have more importance to the total restoration than the microbiological agent causing it.

ABSTRACT NUMBER: 1672

CORRELATION BETWEEN SYMPTOM SCORES (SN-2) VERSUS (SN-5) AND CT SCORES IN YOUNG CHILDREN WITH CHRONIC RHINOSINUSITIS

Andrew Terrell, MD, Hassan Ramadan, MD

INTRODUCTION: The SN-5 is a validated symptom score questionnaire for the evaluation of chronic rhinosinusitis (CRS) in children. This study evaluates whether the first two domains of the questionnaire (sinus infection symptoms and nasal obstruction symptoms) correlate more closely with CT scores than when all five domains are combined.

METHODS: Thirty-five patients ages 2-12 were seen prospectively in the office for symptoms of CRS. The mean age was 7.43 years (range 4-12; SD = 2.42 years). The care takers completed the SN-5 during their visit when a CT scan of the paranasal sinuses was obtained. The SN-2 and the SN-5 were then compared to the Lund-MacKay CT score.

RESULTS: The mean SN-2 was 5.11, the mean SN-5 score was 4.07, and the mean CT score was 6.8. There was a significant correlation between the both the SN-2 scores ($r=0.62$; $p<0.0001$) and the SN-5 ($r=0.67$; $p<0.0001$) scores with the CT scores. The correlation between the SN-2 and CT scores was similar to the SN-5 and CT scores. Comorbidities such as age and allergy did not significantly affect scoring correlations. Asthma did have a significant effect on scoring correlations.

CONCLUSION: Both the SN-2 and SN-5 scores had a positive correlation with CT scores. Children with asthma seem to have a very poor correlation between their SN-5 and the CT score. The ability to correlate subjective symptom questionnaires to objective CT scores is essential in order to evaluate therapeutic interventions while minimizing radiation exposure to the pediatric population.

ABSTRACT NUMBER: 1680

THE EFFECT OF TOTAL NASAL OBSTRUCTION ON NOCTURNAL OXYGEN SATURATION IN AN ASIAN POPULATION

Dr. Chua Dennis, Dr. Siew Sheun Chao, Annabelle Tay

INTRODUCTION: Nasal obstruction influences respiration during sleep and nasal packing may cause nocturnal oxygen desaturation and obstructive sleep apnoea. There have been various studies in the literature on the effect of bilateral nasal packing on nocturnal oxygen desaturation during sleep. The results are conflicting with no definite conclusions. More importantly, there have not been any studies done in an Asian population.

METHODS: A prospective study on 50 Asian patients with bilateral nasal packing admitted overnight was conducted. Their oxygen saturation was checked prior to nasal packing and then continuously monitored overnight for 12 hours using a pulse oximeter. Significant oxygen desaturation was defined as a decrease in peripheral arterial oxygen saturation to $<95\%$. Various data such as the patient's biodata, Epworth score, types of surgery, types of packs, presence of co-morbidities and the time of oxygen desaturation was collected.

RESULTS: Eighteen percent of our patients had significant deoxygenation <95%, the lowest being 92%. The average Epworth score for the patients who had significant deoxygenation was 8.4 compared with 6.2 for those without significant oxygen desaturation. Body Mass Index was not found to be a significant factor in determining which patients will experience significant oxygen desaturation. Interestingly, none of the patients with oxygen desaturation had any co-morbidities. There was also no relationship of the type of packs used to the presence of significant oxygen desaturation.

CONCLUSIONS: In an Asian population, bilateral nasal packing results in significant oxygen desaturation in only a small proportion of patients. In this group, the lowest oxygen level was still >91%. There are no significant clinical predictors of the type of patients that will experience significant oxygen desaturation. Therefore it is safe to conclude that most Asian patients with bilateral nasal packs can be managed in an outpatient setting without oxygen saturation monitoring.

ABSTRACT NUMBER: 1688

EOSINOPHILIC GRANULOMA OF THE PARANASAL SINUSES & ORBIT

Stephanie Joe, MD, Jasmin Kapoor, MBBS

This case report discusses a rare case of eosinophilic granuloma in a child which presented with headache and decreased vision after blunt head trauma.

INTRODUCTION: Eosinophilic granulomas are benign tumours which tend to affect haemopoietically active bone marrow. It is rare to affect the orbit (approximately 1% of all tumours affecting the orbit). The differential diagnosis includes other tumours and infections.

METHOD: Case report

RESULTS: This child complained of headache and decreased vision. He had a history of blunt head trauma for which the family did not seek medical attention. The child developed medial rotation of his left eye and presented to the physician. CT scans showed extensive sinus disease. An MRI revealed an expansile mass involving the orbital apex, lesser wing of the sphenoid bone, and adjacent paranasal sinuses. He underwent an endoscopic sphenoidectomy with biopsies of the left sphenoid mass. The pathologic impression was of Langerhans cell histiocytosis with optic nerve compression. The following day he began radiation therapy and the tumour responded well. The patient's vision returned and he remained stable over nineteen month follow up.

CONCLUSION: This case illustrates the presentation of an unusual case of vision loss in a child. This case report discusses the differential diagnosis, the diagnosis and management of eosinophilic granuloma in the paranasal sinuses and orbit. This is a diagnosis which should be considered in all presentations of headache and vision changes.

ABSTRACT NUMBER: 1690

CARTILAGE CONTAMINATED ON THE FLOOR: A PROSPECTIVE STUDY

Dr. Kevin Wong, Dr. Bedy Lau, Dr. Philpott Carl, Dr. Amin Javer

INTRODUCTION: Cartilage is utilized frequently for reconstruction of nasal defects during surgery. There is no data examining the consequences of utilizing cartilage dropped on the floor.

OBJECTIVE: 1. Determine if cartilage that has contacted the floor is adequately sterilized by washing in a normal saline solution versus an antibiotic (gentamycin) solution.

METHODS: Cartilage was obtained from 10 consecutive patients undergoing septoplasty. A 1x1cm portion of cartilage was dropped on the operating room floor for 60 seconds. The cartilage was then cut into 4 equal sizes and then divided into the following experimental groups: a) no irrigation b) irrigation with normal saline for 1 minute c) irrigation with gentamicin solution for 1 minute and d) irrigation with gentamicin for 5 minutes. These specimens were then sent for C&S and gram stain. Culture swabs were also taken from the operating room floor and the nasal vestibule.

RESULTS: A total of 11 patients were recruited for this study. 9 of 11 cartilage specimens dropped on the floor cultured positive. Bacteria were also cultured from 8 out of 11 cartilage pieces irrigated with normal saline. No bacteria were cultured from any of the dropped cartilage irrigated with gentamicin for either 1 minute or 5 minutes. Swabs of the floor and nasal cavity were positive in all patients.

CONCLUSION: In the event that cartilage has contacted the floor, we recommend that it not be utilized for the possibility of contamination. If an alternative does not exist, our study demonstrates that contaminated cartilage can be sterilized by irrigating with gentamicin for at least 1 minute if not longer.

ABSTRACT NUMBER: 1691

THE PREVENTIVE EFFECT OF ALLERGIC INFLAMMATION BY ORAL TOLERANCE IN A MOUSE MODEL OF ALLERGIC RHINITIS

Soo Whan Kim, MD, Sung Won Kim, MD, Jin Hee Cho, MD, Jun Myung Kang, MD

OBJECTIVE: Induction of oral tolerance(OT) has been known to prevent allergic inflammation in acute asthma model. The purpose of this study was to investigate preventive effect of oral tolerance and airway remodelling in a mouse model of allergic rhinitis.

METHODS: 5-week-old female BALB/c mice divided into 4 groups-control group,allergic rhinitis group,low dose OT group,and high dose OT group. To induce oral tolerance mice were fed ovalbumin(OVA) before sensitization with OVA and aluminum hydroxide-1mg for 6 consecutive days in the low dose OT group and 25mg once in the high dose OT group. Mice in the allergic rhinitis group were fed phosphate buffered saline instead of OVA. After sensitization followed by repeated challenge with OVA during 6 weeks,enhanced pause(Penh),nasal symptom,IL-13,and IFN-r levels in nasal lavage (NAL) fluids as well as OVA-specific IgE,IgG1,and IgG2a levels in serum were measured. In addition the degree of goblet cell hyperplasia and submucosal thickness were observed from nasal tissue by PAS and Masson's trichrome stain.

RESULTS: Both OT groups showed a significant decrease in Penh, inflammatory cells, IL-13, and IFN-r levels in NAL fluids as well as OVA-specific IgE, IgG1, and IgG2a levels in serum compared with the allergic rhinitis group. In addition, the degree of goblet cell hyperplasia and submucosal thickness were significantly attenuated in both OT groups compared with the allergic rhinitis group.

CONCLUSION: These results suggests that induction of OT may effectively prevent allergic inflammation as well as airway remodelling in a mouse model of allergic rhinitis.

ABSTRACT NUMBER: 1692

PARTIAL CRANIALIZATION OF FRONTAL SINUS FRACTURES—A 10 YEAR EXPERIENCE

Terry Shibuya, MD, Paul Schalch, MD

INTRODUCTION: Management of frontal sinus fractures with dural injury, laceration or CSF leak can be very challenging. In selected frontal sinus injuries we have used a partial cranialization technique to explore and repair the dura followed by obliteration of the nasofrontal duct and dead space. This technique has been used to preserve non-injured frontal bone and enhance future protection of the brain/cranium from injury.

OBJECTIVE: This study measures the surgical outcomes of our partial cranialization technique over the past 10 years.

METHOD: 12 patients who have undergone our partial cranialization technique were followed and outcomes were measured using post-op radiograph, incidence of infection, CSF leak, pneumocephalous, cranial nerve V & VII function and cosmetic result.

RESULTS: There were no intra-cranial complications of meningitis, CSF leak or pneumocephalous. All cases had complete obliteration of the frontal sinus dead space. One pt developed superficial wound cellulites, which resolved with antibiotics. There was no change in V & VII function postoperatively. All cosmetic results were excellent.

CONCLUSION: Partial cranialization with frontal sinus obliteration has been used successfully to treat selected frontal sinus injuries for the past 10 years. We believe this technique may be useful for preservation of the non-injured frontal bone and enhance future protection of the brain/cranium.

ABSTRACT NUMBER: 1694

RECRUITMENT OF EOSINOPHILS AND MUCOSAL REMODELING INDUCED BY INTERLEUKIN-17A IN CHRONIC RHINOSINUSITIS WITH NASAL POLYPS ASSOCIATED WITH ASTHMA

Tatsuya Saitoh, Takeshi Kusunoki, Katsuhisa Ikeda

BACKGROUND: IL-17A is a highly inflammatory cytokine with a robust effect on stromal cells in many tissues. Although IL-17A is known to be associated with inflammatory lung disorders by triggering an accumulation of neutrophils, the effect of IL-17A on the upper airway is still uncertain. The expression of IL-17A and its role were investigated in the nasal polyps of chronic rhinosinusitis associated with asthma.

METHODS: IL-17A was detected by immunohistochemistry and quantitative real-time RT-PCR. The cellular source of IL-17A was examined by double staining with EG2, CD4 and neutrophil elastase. The tissue remodeling of the nasal polyps was evaluated by assessing the epithelial damage and basement membrane thickness.

RESULTS: Both the protein and mRNA of IL-17A was significantly detected in the nasal polyps in comparison to control normal sinus mucosa. The localization of IL-17A expression predominantly coincided with eosinophils and CD4-positive lymphocytes. Furthermore, the number of IL-17A positive cells correlated with tissue eosinophils, but not with neutrophils. The degree of epithelial damage and basement membrane thickness was dependent on the number of infiltrated IL-17A positive cells.

CONCLUSION: The present study revealed, for the first time, that IL-17A plays a significant role in the recruitment of eosinophils and the remodeling of the nasal polyps of chronic rhinosinusitis associated with asthma.

ABSTRACT NUMBER: 1695

FUNCTIONAL COOPERATION BETWEEN EPITHELIAL GOBLET CELL SECRETION AND CILIARY ACTIVITY IN THE NOSE.

Atsushi Kamijo, MD, Susumu Terakawa, PHD, Keisuke Masuyama, MD

INTRODUCTION: The mucociliary transport system is a crucial defense mechanism in the airways. This system is dependent on both the ciliary beats and the properties of the periciliary fluid. In the nasal mucosal epithelial surface, there are 2 major types of cells which play an important role in the system, ciliated cells and goblet cells.

METHODS: We used the nasal mucosa of rats and examined the effects of neuropeptides on these 2 types of cells by a video-enhanced microscopic technique. We could observe ciliated cells and epithelial goblet cells on the same preparation simultaneously. The effect on ciliated cells was estimated by measuring the frequency of ciliary beat with a fast Fourier transformation (FFT) analyzer (ciliary activity), and the effect on goblet cells was evaluated by counting every exocytotic response in a single goblet cell (secretory activity).

RESULTS: SP (1 μ M), NKA (1 μ M), and VIP (1 μ M) stimulated the secretory responses of goblet cells significantly, and also promoted the ciliary activity. Increased secretion of goblet cells by those neuropeptides was simultaneously or a few seconds later when ciliary activity was accelerated. These 2 responses seemed to be functionally cooperative. In contrast, CGRP (1 μ M) did not stimulate both secretory and ciliary activity.

CONCLUSION: We showed that neuropeptides in the trigeminal sensory neurons and parasympathetic neurons are involved in regulating both ciliated cells and goblet cells and play an important role in the host defense mechanism in the rat.

ABSTRACT NUMBER: 1703

HOUSE DUST MITE NASAL PROVOCATION IN PERENNIAL ALLERGIC RHINITIS

Supinda Chusakul, Songklot Aemjaturapat, Chuntima Phannaso, Kornkiat Snidvongs

INTRODUCTION: In perennial allergic rhinitis, skin prick test is the gold standard as diagnostic tool to identify the specific allergens. Nasal provocation is also used to identify relevant allergens. The aims of this study were to evaluate sensitivity and specificity of D. pteronyssinus (Dp) nasal provocation test as a diagnostic tool and also determine the relationship of the changes of symptoms in nasal provocation and the wheal size of skin prick test in house dust mite allergic rhinitis.

METHODS: 105 patients with clinical symptoms of perennial rhinitis underwent skin prick test to inhalant allergens and nasal challenges to Dp allergen. Nasal provocation response was assessed by changes of symptoms (visual analogue score) and peak nasal inspiratory flow (PNIF).

RESULTS: 48 patients had positive skin prick test to Dp, of whom 33 had positive nasal provocation test by increases of symptom score and 20 had positive nasal provocation test by decreases of PNIF. 49 patients had negative skin test to inhalant allergens. The nasal provocation test by symptom score was positive in 7 patients in this group. The sensitivity of nasal provocation was 69% and specificity was 86% using symptom score. By PNIF changes, the sensitivity was 42% and specificity was 84%. There was a significant correlation between wheal size of skin test and the clinical changes of nasal provocation to Dp.

CONCLUSIONS: Nasal provocation is valuable test to confirm the diagnosis of house dust mite allergy and it correlates with the diameter of the skin prick test.

ABSTRACT NUMBER: 1705

NASAL QUALITY OF LIFE BEFORE AND AFTER MINIMALLY INVASIVE PITUITARY SURGERY

Charles Ebert, Jr., MD, Maher Younes, MD, William Leight, MD, Brent Senior, MD

INTRODUCTION: Since the introduction of the endoscope, minimally invasive endoscopic pituitary surgery (MIPS) has revolutionized pituitary surgery. Multiple studies have shown MIPS to be a safe and efficacious marriage of the endoscope to the transsphenoidal approach. Surgical outcomes and complication rates comparable to traditional transsphenoidal approaches have resulted but with less dissection and tissue manipulation, reduced need for packing, and believed greater patient comfort and acceptance. No studies have assessed nasal quality of life before and after MIPS. Our goal was to assess the QoL as it relates to the sinuses and rhinosinusitis in patients having MIPS.

METHODS: Patients having MIPS filled out a validated nasal-specific questionnaire, the Rhinosinusitis Disability index (RSDI). RSDI scores, patient demographics, tumor characteristics surgical outcomes, and intraoperative/postoperative complications were recorded. Data were analyzed using Student's t-test to compare the RSDI mean pre-operative and post-operative scores. One-way analysis of variance (ANOVA) compared RSDI scores between different tumour groups.

RESULTS: Thirty-five patients completed the RSDI. There was no significant difference in the preoperative and postoperative scores ($p=0.17$). There was a trend to improved scores in the post-operative scores. No patients developed acute or chronic rhinosinusitis after MIPS. The length of follow-up ranged between 0.25 years and 7 years.

CONCLUSIONS: Minimally invasive pituitary surgery is safe, efficacious, and results in minimal impairment of nasal-specific quality of life in patients.

ABSTRACT NUMBER: 1707

SURGICAL TREATMENT OF A RECURRENT CLIVAL CHORDOMA THROUGH THE EXPANDED ENDOSCOPIC APPROACH: CASE REPORT

Trimarchi Matteo, MD, Boari Nicola, MD, Bussi Mario, MD, Mortini Pietro, MD

INTRODUCTION: Clival chordomas are rare disembryogenic tumors. Because of their critical location and invasive nature clival chordomas are challenging tumors to treat. Surgical removal followed by high-dose radiation therapy, particularly proton beam therapy, are effective in tumor control and improve survival rates.

BACKGROUND: Between February 1990 and June 2008, 37 consecutive patients with pathological diagnosis of chordoma were managed by multimodal treatment at the Department of Neurosurgery of San Raffaele Medical Center, Milan, Italy.

CASE REPORT: We report a case of a 69-year-old woman with recurrent clival chordoma. Two previous surgical procedures were performed at other institutions in 1998 and 2006, achieving a partial resection by a microsurgical trans-sphenoidal approach. After second surgery the patient underwent conventional radiotherapy and medical therapy with tyrosin-kinase inhibitor. The patient presented at our Institution complaining of double vision. The neurological evaluation on admission revealed a left partial third cranial nerve palsy. The MRI scan

showed a midline extradural tumor of middle-upper clivus with left paraclival extension, bigger than showed by the previous MRI study. The lesion was gross-totally removed by an extended endoscopic endonasal approach, using the transclival module. Histology was diagnostic for chondroid chordoma. Neurological evaluation after surgery revealed improvement of the third cranial nerve palsy. MRI scan performed three months after surgery showed no residual tumor.

CONCLUSIONS: The EEA provides an excellent exposure of the clival and paraclival region from the sella turcica to the foramen magnum, allowing a good visualization and control of critical lateral neurovascular structures.

ABSTRACT NUMBER: 1713

INTRACRANIAL MUCOCELE: AN UNUSUAL COMPLICATION AFTER REPAIR OF AN ANTERIOR SKULL BASE DEFECT

Paul Schalch, MD, Marc Rubinstein, MD, David Keschner, MD, JD

OBJECTIVE: The purpose of this study is to present an intracranial mucocele that developed as an unusual complication after repair of a fovea ethmoidalis CSF leak with a mucosal overlay graft.

STUDY DESIGN: Retrospective review of a case of intracranial mucocele in a patient with previous fovea ethmoidalis injury related to endoscopic sinus surgery. The study was conducted at a University-affiliated institution.

METHODS: A 51 year old female underwent revision endoscopic sinus surgery for recurrent polyposis. A CSF leak from the fovea ethmoidalis on the right side was found intraoperatively. Repair was performed by means of a free inferior turbinate mucosal graft. Two years later, she presented with migraine headaches, right ocular pain and blurry vision. CT and MRI evaluation revealed the presence of an extra-axial right frontal lobe mass, arising from the ethmoid roof. The lesion was found to be hyperintense on T2 and slightly hyperintense on T1.

RESULTS: Through an endoscopic approach, a 2.6x2.4x2.4 cm intracranial mucocele was found and drained. The ensuing defect was then repaired by means of a composite, multi-layer graft.

CONCLUSION: Intracranial mucoceles after repair of CSF leaks and other anterior skull base defects are rare complications that may result from intracranial placement of the mucosal end of the graft or dislodgement/migration of a correctly placed graft. This complication should be kept in mind in patients that develop an intracranial mass after repair of anterior skull base defects.

ABSTRACT NUMBER: 1716

LATERAL SPHENOID RECESS CEREBROSPINAL FLUID LEAKS AND ENCEPHALOCELES: UTILITY OF THE ENDOSCOPIC TRANSPTERYGOID APPROACH

Paul Schalch, MD, Marc Rubinstein, MD, David Keschner, MD, JD

OBJECTIVE: The purpose of this study is to describe our experience with the endoscopic transpterygoid approach to the lateral sphenoid recess for repair of CSF leaks that are difficult to access through a strictly transnasal approach.

STUDY DESIGN: Retrospective review of a case of lateral sphenoid recess CSF leak. The study was conducted at a University-affiliated institution.

METHODS: A 54 year old, obese female presented with profuse, right unilateral CSF rhinorrhea. This patient did not have any history of head trauma or previous sinus surgery. After nasal endoscopy and review of CT and MRI studies, the patient was diagnosed with right lateral and superior sphenoid dehiscence and encephalocele.

RESULTS: Endoscopic, image guidance-assisted repair through an extended transpterygoid approach with lateral recess exposure was performed without complications. A composite graft with both over- and underlay technique was used to repair the defect. Long-term follow-up of this patient has not revealed recurrence of CSF leak or encephalocele.

CONCLUSION: The endoscopic transpterygoid approach to the lateral sphenoid recess is a safe, effective and efficient endoscopic surgical technique for the repair of lateral sphenoid recess CSF leaks that are difficult to approach through a purely transnasal endoscopic approach.

ABSTRACT NUMBER: 1717

DIFFUSE B CELL LYMPHOMA OF THE PTERYGOPALATINE FOSSA, INFRATEMPORAL FOSSA, ORBITAL APEX, AND MECKEL'S CAVE

Mark Domanski, M.D., Neil Tanna, M.D., Ameet Singh, M.D.

INTRODUCTION: The pterygopalatine fossa is an inverted pyramidal space communicating with the nasal cavity, orbital, palate, and infratemporal fossa. Primary lesions of the pterygopalatine fossa are rare. Even more unusual are malignant lymphomas of the pterygopalatine fossa spreading into the paranasal sinuses, orbit and surrounding skull base. Paresthesias in the trigeminal distribution, dental pain, visual symptoms, and obstruction of lacrimal system are only some of the clinical symptomatology.

METHODS: Review of a single case including radiographic, inoperative, and pathologic findings was performed, followed by a discussion of the literature.

RESULTS: An 80 year old female presented with numbness and parathesias in the trigeminal distribution followed by intermittent dull left maxillary dental pain for a period of 2 years. Extensive dental work including a root canal failed to provide pain relief. After intensification of the pain, a CT scan was performed which relieved an extensive soft tissue mass involving the left pterygopalatine fossa, maxillary sinus, orbital apex, and infratemporal fossa. Endoscopic maxillary antrostomy and minimal exposure of the pterygopalatine fossa allowed a biopsy. Pathology revealed a diffuse large B cell lymphoma. Bone marrow biopsy and CT-PET did not show any other site of disease. The patient was started on a rituximab-CHOP (cyclophosphamide,

adriamycin, vincristine, prednisone) chemotherapy regimen with improvement of her trigeminal and maxillary pain.

CONCLUSIONS: Malignant lymphomas of the pterygopalatine fossa extending to the nose and paranasal sinuses and skull base are extremely rare. A high clinical suspicion is necessary for timely diagnosis of these lesions.

ABSTRACT NUMBER: 1718

HELICOBACTER PYLORI COLONIZATION AND NASAL POLYPOSIS

Masoud Borojerdi, MD, Ziba Rahbar, MS, Mohsen Naraghi, MD

INTRODUCTION: Helicobacter pylori (HP) infection is the most prevalent infection all over the world. It is found to be associated with chronic inflammatory diseases such as gastric cancer, lymphoma and rhinosinusitis. Also, gastroesophageal reflux to the aero digestive system is reported to cause mucosal inflammation which may have potential to result in some chronic inflammatory assaults such as nasal polyposis.

OBJECTIVE: To investigate the prevalence of HP in the nasal polyposis and to correlate it with the severity of polyposis.

METHODS: Patients diagnosed with nasal polyposis who had not used antacids since 4 weeks before functional endoscopic sinus surgery (FESS), referred to ENT referral hospital were enrolled. HP was investigated in nasal polyp biopsies, using rapid urease testing. CT scans were graded according to the Lund-MacKay scoring system to evaluate the severity of polyposis. Gastrointestinal symptoms and treatments were asked.

RESULT: RUT was positive for 7 (37%) of 19 enrolled patients. Only two patients reported dyspepsia, one had also HP in gastric biopsy. The mean Lund-MacKay score ($P = 0.42$) and clinical scores ($P = 0.97$) were not related to the presence of HP.

CONCLUSIONS: HP may exist in the nasal mucosa of some patients with nasal polyposis. However, no significant correlation between the severity of polyposis and intranasal HP colonization was detected.

ABSTRACT NUMBER: 1719

JUVENILE NASAL ANGIOFIBROMA IN ELDERLY

Giulia Tenti, MD, Vittorio Sciarretta, MD, Ernesto Pasquini, MD

PURPOSE: We report a rare case of Juvenile Nasal Angiofibroma (JNA) in a 62 years old man. The radiologic features and surgical approach are discussed. More over a review of the literature about different theories of genesis of JNA and the efficacy of endoscopic transnasal technique are debated.

MATERIALS AND METHODS: A 62 years old man complaining of nasal obstruction presented endoscopically with unilateral nasopharynx papillomatous-like mass. MRI was not diagnostic for a vascular or malignant lesion. An endoscopic subperiosteal centripetal technique were adopted to perform a sphenoidotomy with wide middle meatotomy. Thanks to the endoscopic angled view was observed the lesion invaded the pterygopalatine fossa. Therefore the sphenopalatine process and the pterygoid plate were drilled out and the mass of maxillary were removed. Histological exam was diagnostic for JNA.

RESULTS: No signs of recurrence were observed after 22 months of endoscopic and radiologic follow up. The patient is free of any symptoms.

CONCLUSIONS: The case focalize the attention on considering JNA a possible diagnosis among the different vascular lesion despite the age of presentation. Besides considering the endoscopic approach as the technique of choice for its versatility on converting a functional to more extensive resection.

ABSTRACT NUMBER: 1721

THE USE OF LUND-MACKAY SCORE AS A PREDICTOR OF REVISION ENDOSCOPIC SINUS SURGERY

Matthew Oliverio, M.D., Hassan Ramadan, M.D.

INTRODUCTION: Functional Endoscopic Sinus surgery is a useful procedure for treating patients with chronic rhinosinusitis. Some research indicates this procedure has a twenty percent failure rate. The Lund-Mackay scoring system is useful to determine the severity of sinus disease on CT scan. This study evaluates patients by Initial Lund-Mackay score to determine if a higher initial score indicates that a patient is likely to undergo revision endoscopic sinus surgery.

METHODS: Initial patient Lund-Mackay scores were reviewed retrospectively. Patients with sinonasal carcinoma, cystic fibrosis or immunodeficiency were excluded. All the patients in the study received maximal medical therapy prior to undergoing sinus surgery. The preoperative Lund-Mackay score was assigned by the same reviewer in all cases and all patients had adequate follow up after the initial procedure. Statistical analysis was then used to determine the significance of the Lund-Mackay score in predicting the need for revision sinus surgery.

RESULTS: The patients in this study who underwent revision sinus surgery had a statistically significant higher Lund-Mackay score. Patients who underwent revision surgery had an average lund-mackay score of 15.90 compared to 10.44 for those not undergoing revision surgery. Analyzing this data using the T-Test demonstrated a p-value of less than .0001 which is statistically significant.

CONCLUSIONS: The Lund-Mackay score is a useful clinical tool in evaluating the CT scan of the patient undergoing first time endoscopic sinus surgery. This study illustrated that a high initial score is an indicator that the patient will require revision endoscopic sinus surgery in the future.

ABSTRACT NUMBER: 1723

SINGLE-NUCLEOTIDE POLYMORPHISM IN THE TOLL-LIKE RECEPTOR 4 BETWEEN CHRONIC RHINOSINUSITIS WITH POLYP AND NORMAL CONTROL GROUP

Chan-Soon Park, Assp, Soo-Whan Kim, Joo-Hwan Kim

INTRODUCTION: Although many diverse explanations for the development of CRS have been suggested, its mechanism has not been elucidated until now. But the association between bacterial pathogen and CRS have been mainly studied up to now. Major bacteria found in chronic rhinosinusitis are Staphylococcus aureus, coagulase-negative staphylococcus, and anaerobic and gram-negative bacteria. The initial recognition of these Gram negative bacteria is done by TLR4. Therefore this study aims to investigate the difference of the frequency of single nucleotide polymorphism(SNP) in human TLR4 genes between chronic rhinosinusitis group and normal control group.

METHODS: Patients with chronic rhinosinusitis with polyps and healthy individuals without CRS were prospectively selected for the study, who visited St. Vincent's Hospital from June 2008. For the purpose of SNP assay, 4 ml whole blood was sampled with the bottle coated with EDTA and then transported to laboratory for DNA extraction and thereafter performed direct DNA sequencing.

RESULTS AND CONCLUSIONS: The results showed that the frequency of TLR4 SNP was not largely different between 2 groups but further investigation will be needed.

ABSTRACT NUMBER: 1730

AIRWAY REMODELING AND EXPRESSION OF YKL-40 IN THE NASAL MUCOSA OF ALLERGIC RHINITIS

Byoung-Joon Baek, M.D.

INTRODUCTION: YKL-40, a member of chitinase-like protein, has been known to be involved in the process of inflammation and tissue remodeling. Nasal airway remodeling appears in allergic rhinitis, but it appears to be far less extensive than in asthma. Although it has been known that the expression of YKL-40 was increased during Th2 type inflammation, its expression in allergic rhinitis has not been investigated. The aims of this study were to characterize nasal airway structural changes in allergic rhinitis and to examine the expression of YKL-40 in patients with allergic rhinitis and in healthy subjects. We also investigated whether the YKL-40 may take part in the process of airway remodeling in allergic rhinitis.

METHODS: Nasal mucosa specimens were obtained from 20 patients with allergic rhinitis and 10 healthy subjects. Using histologic analysis, the following microscopic findings were compared between patients with allergic rhinitis and controls ; goblet cell hyperplasia, submucous gland formation, eosinophil infiltration, lymphocyte infiltration and macrophage infiltration. Immunohistochemical stain was performed for the detection of YKL-40.

RESULTS: The number of eosinophils present within epithelial cells and in the submucosa (6.9 ± 7.7 cells/HPF vs. 1.9 ± 1.7 cells/HPF), and the thickness of basement membrane (11.6 ± 2.7 μ m vs. 2.5 ± 1.5 μ m) were significantly elevated in patients with allergic rhinitis as compared with controls ($p < 0.05$). The numbers of goblet cells, submucous gland formation, lymphocytes and macrophages present in the submucosa were not significantly different between patients with allergic rhinitis and controls ($p > 0.05$). In the majority of patients with allergic rhinitis and controls, YKL-40 staining was seen in subepithelial cells near the basement membrane. Positive correlation was found between the number of YKL-40-positive cells and the thickness of basement membrane($r = 0.52$), the number of macrophage($r = 0.41$).

CONCLUSIONS: we have shown that YKL-40 was found in increased quantities in patients with allergic rhinitis, in whom the expression of YKL-40 correlated positively with the thickness of the subepithelial basement membrane. Our data suggest that YKL-40 may participates in the process of airway remodeling of allergic rhinitis.

ABSTRACT NUMBER: 1741

A SINGLE BLINDED RANDOMIZED CONTROLLED TRIAL OF GLOVED VERSUS UNGLOVED MEROCEL MIDDLE MEATAL SPACERS FOR ENDOSCOPIC SINUS SURGERY

Nael Shoman, MD, Carl Philpott, MD, Amin Javer, MD

OBJECTIVE: The use of middle meatal spacers (MMS) is common in functional endoscopic sinus surgery (FESS) but the effects on postoperative mucosal healing remain unknown. The type of MMS utilized may result in variable degrees of mucosal damage that could result in adhesions and consequently lateralization of the middle turbinate. The objective of this study was to compare histologic mucosal changes, patient discomfort and bleeding following FESS when a gloved Merocel® sponge versus an ungloved sponge was placed in the middle meatus.

METHODS: 35 consecutive adults undergoing bilateral FESS were randomized and blinded to receive an ungloved Merocel® sponge on one side and Merocel® within a rubber glove finger on the other. Patients completed a pain assessment questionnaire during their first postoperative week. Patients were seen at one week postoperatively for spacer removal during which time a small biopsy was taken from the lateral surface of the middle turbinate on both sides. The samples were sent for histological analysis to assess for mucosal changes.

RESULTS: Histological examination of the turbinate mucosal membrane that was against the rubber gloved Merocel® sponge showed only a minor inflammatory response. Mucosal membrane biopsies from the turbinate laying against the ungloved Merocel® showed significant mucosal inflammatory response, with shortening of the epithelium and ciliary loss. There was no significant difference with regards to postoperative discomfort or bleeding between the two groups (1.1 and 1.07 respectively).

CONCLUSIONS: A rubber gloved Merocel® middle meatal spacer (MMS) is associated with less postoperative mucosal inflammatory response, which may lead to faster healing and lesser chance of adhesions compared to an ungloved Merocel® middle meatal spacer.

ABSTRACT NUMBER: 1743

COMPARISON OF THE SKIN PRICK TEST AND PHADIA IMMUNOCAP AS TOOLS TO DIAGNOSE HOUSE DUST MITE ALLERGY IN ELDERLY PATIENTS

Yong gi Jung, MD, Hyun-jin Cho, MD, Jin-young Min, MD, Hun-jong Dhong, MD

BACKGROUND: When the skin prick test (SPT) and ImmunoCAP assay are performed simultaneously, however, the results do not coincide in some patients. **Objectives:** To assess differences in allergic test results according to age group, and to establish appropriate guidelines for diagnosing mite allergy according to age.

METHODS: A total of 692 patients complaining of allergic rhinitis symptoms were enrolled. We divided patients according to age; the mean age was 32 years (range: 8-76). The SPT and ImmunoCAP assays were performed to detect allergies to house dust mites *Dermatophagoides pteronyssinus* and *D. farinae*. The association between age and the result of each allergy test were examined, then a cut-off age for proper application of each test was estimated.

RESULTS: 313 (45.3%) were allergic to *D. pteronyssinus* and 339 (49%) were allergic to *D. farinae*. Confounding variables were evenly distributed in each age group. ImmunoCAP was useful for all age groups,

but SPT showed decreased ratio of positive result for both allergens in older age groups ($p < 0.0001$). The cut-off age for each test with maximal discrimination was 50 years for *D. pteronyssinus* ($p < 0.0001$) and 30 years for *D. farinae* ($p < 0.0001$).

CONCLUSIONS: This study is the first to compare the result of allergy tests according to age using true allergens. The allergic reaction to house dust mites varied according to age of the patients. For patients over 30 years of age, the ImmunoCAP is the preferred method for detecting allergy to house dust mites.

ABSTRACT NUMBER: 1744

ANALYZING THE DEVELOPMENT OF THE NASAL SEPTUM WITH USING MAGNETIC RESONANCE IMAGING

Young-Jun Chung, MD, Jeong-Beom Kim, MD

BACKGROUND: There are some reports about septal development such as cadaveric studies or studies using simple x-ray, but there have been no studies based on magnetic resonance imaging (MRI).

OBJECTIVES: This study was designed to evaluate the normal development of the nasal septum using sagittal MR images

MATERIAL & METHODS: Two hundred eighty patients who had their whole nasal septum visualized in the midline sagittal view were selected among 3904 patients who underwent brain MRI from January, 2004 to December, 2006. Parameters such as bony dorsal length, cartilaginous dorsal length, total dorsal length, length of the septal cartilage (SC)-nasal bone (NB) overlap, total septal area, septal cartilage area, proportion of the cartilage area to the total septal area and maximal harvestable cartilage for grafting were calculated using the PACTM program.

RESULTS: All parameters were increased until adolescence; then the bony dorsal length, the cartilage dorsal length, the total dorsal length, the total septal area and the maximal harvestable cartilage for grafting were not changed significantly with age, while the SC-NB overlap length, the septal cartilage area, and proportion of the cartilage area to the total septal area were significantly decreased with age. The SC-NB overlap length was positively correlated with the septal cartilage area and the proportion of the cartilage area

CONCLUSION: Small septal cartilage area and its proportion were significantly correlated with a short overlap length of the septal cartilage under the nasal bone. Septal procedures should be carefully performed in the elderly due to the risk of incurring saddle nose.

ABSTRACT NUMBER: 1746

ULTRA-STRUCTURAL CILIARY EVALUATION IN PRIMARY AND SECONDARY DISKINESIAS

Ricardo Demarco, MD, Fabiana Valera, PhD, Maria Rossato, Wilma Anselmo-Lima, PhD

INTRODUCTION: Primary ciliary dyskinesia (PCD) is a genetic disease characterized through a systemic ciliary mobility, especially in upper airways. Specific alterations in ciliary axonemes are pathognomical to the syndrome. Secondary ciliary dyskinesia (SCD) is defined to differ to PCD and it is caused by ultra-structural abnormalities observed during or after injuries, as respiratory infections.

METHODS: 21 biopsies from patients with PCD and 15 from patients

with SCD were evaluated. They all had previous diagnosis based on both transmission and scanning electronic microscopy.

RESULTS: The most frequent alterations in SCD were composed cilia, small cilia, changes in peripheral microtubules and alterations in respiratory epithelium. The most frequent changes in PCD were loosen or shortening of dynein arms, absence of central microtubules and displacement in one of the nine peripheral pairs.

CONCLUSIONS: We stress the differences in ultra-structural alterations examined between PCD and SCD, especially to those observed in chronic rhinosinusitis refractory to conventional treatments.

ABSTRACT NUMBER: 1748

CASES OF CHOANAL POLYPS WITH UNUSUAL ORIGINS : PREOPERATIVE ENDOSCOPIC AND CT EVALUATION

Young-Jun Chung, MD, Jeong-Beom Kim, MD

INTRODUCTION: Choanal polyps usually arise from the maxillary sinus. However, choanal polyps originating from unusual site such as sphenoid or ethmoid sinus has occasionally been reported and it may be diagnosed after excision. Preoperative accurate evaluation for the origin of these polyps is very important to prevent possible surgical risks and a recurrence by resecting the sinus component. The origin of choanal polyp could be evaluated by nasal endoscopy and CT preoperatively. In case of sphenochoanal polyp, nasal endoscopic examination reveals that the polyp is between the nasal septum and the middle turbinate. CT scans reveal an unilateral polyp filling the sphenoid sinus and extending through its ostium into the posterior choana with normal aeration of other paranasal sinuses as in our first case. If a large sphenochoanal polyp obstructs the middle meatus and the maxillary antrum become opaque on CT scan, it may be difficult to identify the origin of the polyp. In this situation, finding of the widened natural ostium on CT scans is valuable. In case of ethmochoanal polyp, both anterior and posterior sinus could be the origin. In choanal polyp from posterior sinus, pedicle is between the nasal septum and the middle turbinate like spheno-choanal polyp on nasal endoscopic examination. In choanal polyp from anterior ethmoid sinus which is seen in the middle meatus, it is important to differentiate that from antrochoanal polyp. Therefore, Serial detailed evaluation with CT scans can help identify the origin of polyp in case of ethmochoanal polyp.

METHODS: In this paper, we present four cases of choanal polyps with unusual origin diagnosed preoperatively by nasal endoscopy and CT which enable us to evaluate the origin.

ABSTRACT NUMBER: 1752

OUR EXPERIENCE OF INTRACTABLE FRONTAL SINUS DISEASES

Hiroto Honma, Takeshi Kusunoki, Toru Yao, Katsuhisa Ikeda

INTRODUCTION: Although endonasal approach of frontal sinus inflammatory disease has been recently established as a minimally invasive surgery, several problems have been encountered. Previous surgery of external frontal surgery or osteogenic inflammatory process of the frontal sinus often causes difficult access to or stenosis of frontal sinus outflow tract.

METHODS: We present our cases of intractable frontal sinus diseases and discuss the surgical approaches.

RESULTS: We experienced 6 cases of frontal sinus inflammatory diseases (4 males and 2 females, 27 to 74 years). Recurrent 4 cases of frontal sinus diseases were performed Draf type II or III drainage with stenting. One case of a primary frontal sinus mucocele with extensive bone destruction was drained by Draf type III. One case of several recurrent frontal sinus inflammatory lesion with marked ossification of the frontal sinus outflow tract was operated by obliteration using fatty tissues. All of the cases showed no recurrence after a relatively short follow-up less than 3 years.

CONCLUSIONS: In spite of our experiences of a relatively small numbers and short follow-up, recurrent and extensive lesion of the frontal sinus inflammation may require tailor-made strategy of treatment in both endoscopic and external approach.

ABSTRACT NUMBER: 1753

A CASE OF CHRONIC EOSINOPHILIC LEUKEMIA WITH SINUSITIS AND GRANULATION TISSUE IN THE PHARYNX

Takanori Yamamoto, MD, Atsushi Kamijo, MD, Keisuke Masuyama, MD

INTRODUCTION: Chronic eosinophilic leukemia is a myeloproliferative disease.

METHODS, CASE REPORT: We experienced an extremely rare case of chronic eosinophilic leukemia with granulomatous lesions in her nasal cavity and pharynx. A 23-year-old woman was referred to our hospital in June 2007 with a 1-year history of severe nasal obstruction. She had been diagnosed as sinusitis, however an oral antibiotic treatment failed to resolve her symptoms in other hospital. At fiberoptic examination, granulomatous lesions occupied in her nasal cavity and pharynx. Computed tomographic scan showed opacification of both sides of ethmoid and sphenoid sinuses, as well as soft tissue lesions arising from the nasopharynx to the oropharynx. White blood cell and eosinophil count in her blood was 14000 / ul and 2940 / ul, respectively. PR3-ANCA and MPO-ANCA were negative and total IgE levels in her serum was 73.9 IU/ml. Biopsies of the lesion in the nasal cavity and the pharynx revealed granulation tissue with marked eosinophil infiltration. Based on these findings, we carried out corticosteroid-pulse-therapy, however, eosinophil counts in the blood temporary dropped and increased again. Finally, chromosome analysis identified FIPL1-PDGFR in her bone marrow, and diagnosis of chronic eosinophilic leukemia was established. Unfortunately, treatment by imatinib was not effective, and hydroxyurea failed to improve her condition, she died of the disease in one month after the diagnosis. The importance of chromosome analysis and treatment of chronic eosinophilic leukemia will be discussed.

ABSTRACT NUMBER: 1755

SURGICAL OUTCOME OF ENDOSCOPIC DACRYOCYSTORHINOSTOMY ACCORDING TO OBSTRUCTION LEVEL OF LACRIMAL SYSTEM

Woo Shim, MD, Ji Choi, MD

BACKGROUND AND OBJECTIVES: Many factors influence the outcome of endoscopic dacryocystorhinostomy (DCR), but the level of obstruction in the lacrimal drainage system is important prognostic factor. The aims of this report are to evaluate both the frequency of obstruction by anatomical region of lacrimal drainage system on dacryocystography (DCG) and the surgical outcome of endoscopic DCR.

MATERIALS AND METHODS: A retrospective series of 48 patients (60 eyes) diagnosed as acquired lacrimal system obstruction were enrolled. Preoperative evaluation consisted of a standard examination that included conventional DCG and OMU CT. Patients were classified into four groups by obstruction level on DCG. These patients underwent endoscopic endonasal DCR with silicone tube insertion for chronic epiphora. Surgical outcome was evaluated by improvement of subjective symptoms and nasal endoscopy, post-operatively.

RESULTS: Of 60 eyes, the site of obstruction was the common canaliculus in 14 eyes (23.33%), the pathology of lacrimal sac in 13 eyes (21.66%), the duct-sac junction in 13 eyes (31.66%) and nasolacrimal duct (NLD) in 20 eyes (33.33%). The duct-sac junction was treated most successfully (100%), followed by NLD obstruction (90%), common canaliculus obstruction (78.57%) and pathology of lacrimal sac (69.23%).

CONCLUSION: In patients with acquired lacrimal system obstruction, preoperative confirmation of obstruction site through DCG may be helpful to expect patient's prognosis after endoscopic endonasal DCR. And the pathology of lacrimal sac itself may have poorer prognosis than duct-sac junction.

ABSTRACT NUMBER: 1757

CLINICAL STUDY ON CARDIOVASCULAR SAFETY OF THE SECOND GENERATION H1-ANTAGONIST LORATADINE IN TREATMENT OF PERSISTENT ALLERGIC RHINITIS

Lei Cheng, M.D., Ying Liu, M.D.

OBJECTIVE: To evaluate cardiovascular safety of the second generation H1-antagonist loratadine in treatment of patients with allergic rhinitis.

METHODS: A total of 50 patients with persistent allergic rhinitis were enrolled, of which 19 cases (38.0%) had a history of cardiovascular diseases and/or presented abnormal electrocardiogram (ECG) findings without prolonged QT-interval. There were 30 males and 20 females, aged 20 to 88 years (mean, 41.8 years). For all patients, 10 mg loratadine tablet was orally administered once-daily in duration of 30 days. ECG examinations were carried out both before and after treatment. Affects of cardiovascular of loratadine were determined by the comparison of the two ECGs.

RESULTS: There was no alteration in sinus rhythm in all patients after 30-day administration of loratadine. No statistically significant difference was found in regarding to heart rates, P durations, PR or QRS intervals between the baseline and end-point ECGs (all, $P > 0.05$), as well as no significant prolongation of the QT or QTc corrected for heart rate using Bazett's formula ($P > 0.05$).

CONCLUSIONS: The results demonstrate cardiovascular safety of loratadine, a second generation H1-antagonist, in long-term treatment of allergic rhinitis at routinely recommended dose.

ABSTRACT NUMBER: 1759

SIMULTANEOUS ENDOSCOPIC SINUS SURGERY AND ORGAN TRANSPLANTATION

Tae-Hoon Lee, M.D., Hyun-Ho Park, M.D., Joong-Keun Kwon, M.D., Jeong-Yup Son, M.D.

INTRODUCTION: As the development of organ transplantation medicines, the indication of the transplantation has been getting wider and increased numbers of patients want transplantation. However, the number of the donors is insufficient for the recipients, which result in long waiting period for transplantation. Moreover, it is difficult to predict the time of transplantation, when the donor is a sudden brain death patient. Because of the need for posttransplant immunosuppression period, the recipients should be free of infection preoperatively and it can make them remain on active status on the transplant list. The operation must be performed before the multi-organ failure, thus early operation is recommended.

CONCLUSION: We have conducted the endoscopic sinus surgery with organ transplantation simultaneously to the patients who have solitary unilateral maxillary sinusitis and chronic hepatic failure or chronic renal failure due to some unavoidable circumstances and had successful results in all three cases, and we would like to share our experiences.

ABSTRACT NUMBER: 1770

DHMEQ EFFECT ON ICAM-1, VCAM-1 AND RANTES EXPRESSION IN NASAL POLYPS

Fabiana Valera, PhD, Kazuo Umezawa, PhD, Luiz Tone, PhD, Wilma Anselmo-Lima, PhD

OBJECTIVES: To evaluate the effect of DHMEQ (a NF- κ B inhibitor) and/or either of fluticasone on nasal polyp fibroblasts, through ICAM-1, VCAM-1 and RANTES expression.

METHODS: 6 nasal polyps were obtained from 6 patients, and their fibroblasts were cultured into 11 flasks: the negative (free of additive) and positive (TNF- α 25 ng/ml) controls, as well as TNF- α added to DHMEQ, fluticasone or their associations, in 3 different concentrations (1, 10 and 100 nM each). After 24 hours, ICAM-1, VCAM-1 and RANTES expression was evaluated through ELISA and real time-PCR. Nuclear NF- κ B was also assessed through ELISA.

RESULTS: TNF- α significantly increased both protein and RNA expression for ICAM-1 ($p < 0.005$ and $p < 0.0005$), VCAM-1 ($p < 0.05$ and $p < 0.01$) and RANTES ($p < 0.05$ for both) when compared to negative control. When either fluticasone or DHMEQ was added to TNF- α , there was a significant decrease of VCAM-1, ICAM-1 and RANTES expression. When DHMEQ was associated to fluticasone and TNF- α , there was an optimization of each drug efficacy, although it was not statistically significant for the majority of analyzed situations. The same results could be obtained for NF- κ B translocation.

CONCLUSIONS: DHMEQ also acts as an anti-inflammatory drug as powerful as fluticasone. Moreover, DHMEQ enhances fluticasone effect on nasal polyp fibroblasts, decreasing ICAM-1, VCAM-1 and RANTES expression at lower concentrations than only with fluticasone exposure. Since the analyzed proteins are pro-inflammatory molecules, the reduction of their expression could presume that there might be a decrease of the inflammatory process on nasal polyps with DHMEQ, either isolated or associated to topical glucocorticoids.

ABSTRACT NUMBER: 1771

EFFECT OF LONG-TERM USE OF INTRANASAL GLUCOCORTICOIDS ON NASAL EPITHELIUM, DENTAL ALVEOLAR BONE, AND ORTHODONTICALLY INDUCED DENTAL MOVEMENT IN RATS.

Danielle Park, Wilma Anselmo-Lima

INTRODUCTION: An orthodontic treatment depends among many factors on bone remodeling. Several hormones, including glucocorticoids, play a key role in bone turnover. Despite the well-known effects of glucocorticoids on bone metabolism the influence of variations in plasmatic concentrations of them on bone resorption and nasal epithelium due to orthodontic treatment remain to be determined. This study aimed at investigating the effect of intranasal glucocorticoids compared to systemic glucocorticoid on nasal epithelium, dental alveolar bone, and orthodontically induced dental movement in rats.

METHODS: Rats were treated daily with intranasal mometasone furoate, intranasal triamcinolone acetonide and subcutaneous sodium succinyl methylprednisone for seven weeks and submitted to orthodontic dental movements for the last seven days of experimentation. An orthodontic device was placed in the incisive and first upper molar with an initial force of 75 g. The contralateral hemiarc was used as untreated control.

RESULTS: Histomorphometric analysis of dental alveolar bone showed that treatments with triamcinolone and methylprednisone tend to reduce but nonstatistically significant the bone trabeculae areas in both hemiarc irrespective the treatment.

CONCLUSIONS: Treatment with methylprednisone increase the magnitude of dental orthodontic movement while treatments with mometasone and triamcinolone tend to raise the orthodontic movement. Important morphological modifications of nasal epithelium were observed in rats treated with triamcinolone.

ABSTRACT NUMBER: 1772

LOW IMMUNOGLOBULINS, COMPLEMENT C4 DEFICIENCIES AND SEX DIFFERENCES IN RHINOSINUSITIS AND NASAL POLYPOSIS

Jari Suvilehto, MD, Marja-Liisa Lokki, M.Sc., Seppo Meri, Prof., Mikko Seppänen, MD

BACKGROUND: Low plasma immunoglobulin G subclass levels and complement factor C4 deficiencies may predispose to severe chronic rhinosinusitis. Chronic rhinosinusitis commonly leads to operations, but clinically presents differently in females and males.

OBJECTIVE: We analyzed, in patients coming for sinonasal operations, whether frequencies of common defects in immunity differ between sexes in chronic rhinosinusitis and/or nasal polyposis.

METHODS: The clinical phenotypes, C4 gene copy numbers, levels of C3, C4, immunoglobulins A, M, G, and IgG subclasses were studied in 97 female and 92 male patients coming for endoscopic operation. Laboratory results were compared with those of sex-matched controls.

RESULTS: Female patients more commonly had symptomatic non-polypotic chronic rhinosinusitis and other mucosal infections but less mucosal changes in computed tomography than men. Men frequently had nasal polyposis, rarely with recurrent rhinosinusitis. Total plasma IgA and IgG2 levels were higher in patients than controls. Low IgG1 and IgG3 were equally frequent in both sexes.

However, female patients had lower absolute levels of plasma IgG1 and IgG3 than men. In female patients, all C4B deficiencies were more common than in female controls; total C4B deficiency was associated with chronic and recurrent rhinosinusitis together with polyposis. In male patients, serum C3 and C4 levels were higher than in other groups.

CONCLUSION: In patients coming to endoscopic sinus surgery, severe primary antibody deficiencies were rare. In females, total C4B deficiency predisposes to all types of rhinosinusitis. Regardless of sex, changes in plasma immunoglobulin profiles suggested an altered cytokine balance in all patients.

ABSTRACT NUMBER: 1773

CLINICAL TRIAL OF LONG TERM CLARITHROMYCIN TREATMENT IN PATIENTS WITH CHRONIC RHINOSINUSITIS: MICROBIOLOGICAL CHANGES AND CLINICAL IMPROVEMENT.

Khashayar Ahmadi, MD, Mozafar Sarafraz, MD, Azar Khosravi, MD

INTRODUCTION: Chronic rhinosinusitis is defined as sinusitis lasting longer than 12 weeks. The purpose of this study was to examine the effect of long-term Clarithromycin treatment of patients with chronic sinusitis who did not respond to sinus surgery and traditional conservative therapy.

METHODS: Thirty nine patients without immunodeficiency and with persistent symptoms of chronic sinusitis after one or several functional endoscopic sinus surgical procedures were included in the study. They had all been treated with systemic steroids and long-term antibiotics other than macrolides. Nasal swabs were performed for microbiological evaluation. All patients were treated with Clarithromycin 500 mg twice daily with other routine medications for chronic rhinosinusitis.

RESULTS: Twenty six patients responded to the treatment (66.6%). There were no significant statistical differences between non-responders and responders in defined parameters at study commencement. After 3 months, in the Visual Analog Scale (VAS) scoring, the most significant change was in nasal obstruction ($p < 0.05$). No significant changes were seen in the sense of smell. According to the results of microbiological investigation, *Staphylococcus aureus* was the most prevalent organism isolated from patients followed by *Pseudomonas aeruginosa* and coagulase negative staphylococcus. At 3 months, there were no *S. aureus* on cultures.

CONCLUSION: Long-term, macrolide antibiotic therapy could be effective in some surgical failures of chronic sinusitis. The positive cultures did not seem to influence the improvement experienced by the patients. We recommend a minimum treatment period of 3 months to evaluate the efficacy of the treatment.

ABSTRACT NUMBER: 1774

CURRENT THERAPY OF ALLERGIC RHINITIS AND ASSESSMENT AND INCIDENCE OF STEROID PHOBIA IN GERMANY.

Oliver Kaschke, MD, Bernd Tischer, PhD

INTRODUCTION: According to evidence-based guidelines, standard treatment of allergic rhinitis (AR) includes application of topical steroids. Clinical experience indicates that at least some patients are reluctant to steroid use and show decreased adherence to treatment. One of the major reasons is an aversion to steroids in general. The so-called “steroid phobia” is well-known in other allergic diseases. Purpose of the study was first to clarify the current treatment of AR in relation to the knowledge about topical steroid therapy and the sources of information. Second purpose was to estimate the degree of steroid phobia in AR-patients as a cause for topical steroid refusal.

METHOD: In online interviews 406 patients with AR, 201 physicians and 100 retail pharmacists were asked by questionnaires. Information given by the patients about the current medications and the compliance were collected, also the mannerism of physicians prescription. All were asked to describe the emotional reactions to steroid treatment and a topic cortisone treatment, to identify the reasons for a suggested steroid phobia.

RESULTS: Based on the OSNABRÜCK interpretation scale, 64% of the AR patients express steroid phobia. Main reasons why patients refuse steroids or stop using it are concerns about possible side effects and concerns about the agent in general. Healthcare professionals underestimate the true prevalence of steroid phobia.

CONCLUSIONS: Physicians expect that only 32% of the patients have objections to nasal steroids. Results support the thesis that steroid phobia is associated with lack of knowledge about modern steroids.

ABSTRACT NUMBER: 1776

RESORBABLE OSTEOSYNTHESIS IN THE RECONSTRUCTION OF ANTERIOR TABLE FRONTAL SINUS FRACTURES.

Aaron Pearlman, MD, Rita Roue, MD

INTRODUCTION: Fixation of traumatic frontal sinus fractures poses a surgical dilemma. Titanium mini plates have been the mainstay in reconstruction of the upper face, but long term complications such as extrusion, infection, and palpation are possible. Resorbable osteosynthesis techniques offer the advantage of temporary fixation for non-load bearing locations and negate the long term risks of extrusion and plate palpation. Poly D, L-lactic acid (PDLLA), a resorbable material, can be constructed into low profile mini plates and pins (KLS Martin, Jacksonville, FL) that retain strength for approximately ten weeks and can be easily molded and shaped intra-operatively. We present a case in which a traumatic anterior table fracture of the frontal sinus was well reduced using PDLLA materials.

METHODS: Case-report

RESULTS: The patient is a 42 year old male who sustained an isolated comminuted left anterior and posterior table fracture of the frontal sinus with an overlying vertical laceration extending from the upper brow to the upper eye lid with no evidence of cerebrospinal fluid leak following an assault. Computed tomography (CT) revealed significant displacement of both the anterior and posterior tables of the frontal sinus. The intersinus septum was intact and the patient underwent unilateral cranialization. Using PDLLA mini plates, the anterior table was

restored with normal aesthetic contour to the forehead. CT examination revealed successful reduction at follow-up.

CONCLUSIONS: Successful reduction and fixation of the anterior frontal sinus can be achieved using PDLLA resorbable mini plates and pins with adequate stability and the advantage of easy intra-operative plate molding and shaping.

ABSTRACT NUMBER: 1779

ENDOSCOPIC RESECTION OF SINONASAL GLOMANGIOPERICYTOMA: CASE REPORT

Marta Canas Marques, MD, Marco Alveirinho Simao, MD, Alberto Santos, MD, Maria Ivone Camacho, MD

INTRODUCTION: Glomangiopericytoma (GPC), before termed sinonasal haemangiopericytoma-like tumour is a rare perivascular tumour (<0,5% of all sinonasal neoplasms) which has hybrid origin in glomus body cells and pericyts. Most GPC are benign and simple excision is usually curative, although a local recurrence rate of 18% and few cases of metastasis (2,5%) have been reported.

METHODS: We present a case report of a 55 year old male who had a 4-year history of progressive nasal obstruction and recurrent epistaxis. Rhinoscopy/Contact Endoscopic revealed a large reddish polypoid mass at the level of the superior meatus extending to the posterior part of the nasal cavity and nasopharynx.

RESULTS: Endoscopic resection of the tumour was performed after angiography with embolization. The tumour was connected to the septum with a narrow stalk, it was excised by a small septectomy. The postoperative period was uneventful and the follow-up at 12 months showed no evidence of recurrence.

CONCLUSIONS: Both clinical and imaging findings are not helpful for a conclusive diagnosis; only histology with immunohistochemical study can give the final diagnosis. The endoscopic approach offers better visualization of the site of origin and permits adequate resection even of large tumours. We recommend preoperative angiography with embolization in these tumours as it reduces the perioperative bleeding. Long follow-up by endoscopy is mandatory as the recurrence is possible even after 15 years.

ABSTRACT NUMBER: 1780

A CONTROLLED COMPARISON OF STANDARD TWO-DIMENSIONAL ENDOSCOPY VERSUS THREE-DIMENSIONAL ENDOSCOPY.

Rupali Shah, MD, Mihir Patel, MD, Joshua Surowitz, MD, Adam Zanation, MD

INTRODUCTION/PURPOSE: One of the criticisms of current video systems for minimally invasive endoscopic surgery is that two-dimensional (2-D) images lack depth perception and may impair surgical dissection. Recently, advances have been made to improve visualization with the development of three-dimensional (3-D) visual systems. In order to objectively measure the utility of 3-D endonasal endoscopy, we designed a model with specific tasks to demonstrate any advantages or disadvantages when compared to standard 2-D endoscopy.

METHODS: Fifteen subjects volunteered for the study and were grouped according to endoscopic experience: novices and experts. A training model was constructed to include five tasks- incision manipulation, ring transfer, nerve hook, distance estimation-visual only, and distance estimation- visual and tactile. A standard 2D endoscope and a 3D ste-

reoscopic vision system were tested by each participant.

RESULTS: Of the 15 subjects, 6 (40%) were true novices. Overall, the number of errors committed during any one task was not significant. Novices trended towards more success during the nerve hook task using the 3D system. With tactile feedback versus visualization alone, distance estimation was significantly more accurate; however, there was no difference in accuracy between the systems (2D vs. 3D). Novices preferred the 3D system while experienced endoscopic surgeons disliked the initial learning curve with the new technology.

CONCLUSIONS: There were trends in improvement in novice performance using three-dimensional optics. Tactile feedback used by experienced endoscopic surgeons does enhance 2D performance and may reduce differences that may exist between the 2D and 3D visual systems. Evaluation in the operating room and larger studies are necessary to further clarify advantages of stereoscopic visual systems.

ABSTRACT NUMBER: 1793

INTERNET-BASED SURVEY OF EFFECTIVENESS OF NEILMED NASOGEL, A SODIUM HYALURONATE-BASED NASAL LUBRICATING GEL.

Martin Desrosiers, MD

RATIONALE: Nasal dryness characterises multiple nasal disorders and causes discomfort in afflicted individuals and interfering with nasal defences against colds and sinusitis. Nasal gels compensate by delivering moisture locally in a viscous formulation. NeilMed NasoGel is an innovative nasal gel which contains 1% sodium-hyaluronate for superior moisturizing characteristics.

PURPOSE: We wished to assess end-user responses on the effectiveness of NeilMed NasoGel for the management of nasal dryness.

METHOD: 260 individuals having purchased NeilMed NasoGel via the Internet were contacted and invited to complete an internet-based survey. 165 individuals responded to a series of questions relating to attributes of NeilMed NasoGel, an innovative sodium hyaluronate-based nasal gel.

RESULTS: 85% of respondents rated NasoGel as good or better, with 54% rating it 'excellent'. 94% noted an improvement in their nasal dryness, 80% moderately or better. 52% noted a reduction in colds or sinus infections with use. 22% reported a reduction or stopping in use of other medications. 77% reported duration of 3 hours or more, while 15% reported duration of 2 hours. 24% use the product DIE, 25% BID, and 48% on a PRN basis. 11% reported side effects preventing them from continuing NasoGel use. 67% rated NasoGel as superior to other products they had used before, and 92% would recommend NasoGel to someone else.

CONCLUSION: According to results of this survey, NeilMed NasoGel is an effective and well-tolerated nasal product which relieves nasal dryness and can contribute to reducing cold and sinus infections. Perceived prolonged duration of effect may be secondary to the hyaluronate component.

ABSTRACT NUMBER: 1795

MAXILLARY AMELOBLASTOMA

Jayne Dowdall, MD, David Hackenson, Michael Hoa, MD, Robert Robert Mathog, MD

INTRODUCTION: 19 year old experienced a two-month history of a lump in her left cheek. Imaging demonstrated a 4.6 x 3.9 x 5.0 cm mass lesion

occupying the left maxillary sinus and extending into the left anterior ethmoid air cells with involvement of the left orbital floor. Biopsy consistent with ameloblastoma. Left total maxillectomy, ethmoidectomy, sphenoidectomy, partial palatotomy and dacrocystorhinostomy. Reconstruction was performed with a temporalis fascia sling, split thickness skin graft and custom palatal obturator.

METHODS: Case report including review of imaging studies, pathology and perioperative photography; literature review of reconstructive options.

RESULTS: Patient was found to have clean margins and is satisfied with her facial appearance after aggressive surgical management.

CONCLUSIONS: Ameloblastoma is an uncommon benign tumor of enamel organ accounting for 1% of tumors of the mandible and maxilla. Though typically benign, these tumors often exhibit locally invasive, destructive behavior. Maxillary ameloblastomas account for only one in five cases of osseous (central) ameloblastomas. The delicate bony structure of the midface and nasal structures permit rapid and extensive growth, as is seen in this case. Surgical treatment must be correspondingly aggressive. Historically conservative treatment included enucleation and curettage. Secondary to high recurrence rates with conservative methods, radical approaches including composite resection continue to be utilized. Multiple reconstructive approaches may be employed including temporalis sling with skin grafting, palatal obturator placement and microvascular free tissue transfer. We suggest aggressive surgical approaches may continue to be performed with satisfactory cosmetic and functional outcomes.

ABSTRACT NUMBER: 1796

PRESENCE OF MICROABSCESSES IN THE EPITHELIUM OF NASAL POLYPS IN PATIENTS WITH CYSTIC FIBROSIS

Vijay Ramakrishnan, MD, Todd Kingdom, MD

INTRODUCTION: Chronic rhinosinusitis with nasal polyps in patients with cystic fibrosis (CF) is known to be molecularly and phenotypically unique from disease in patients without CF. Known histologic findings in CF polyps include: lack of tissue eosinophilia, degranulated mast cells, presence of an apical mucus blanket, and thinning of the basement membrane. It has been our anecdotal experience that intraepithelial microabscess formation is also a unique histologic finding in CF polyps, and has not yet been described.

METHODS: Archived surgical specimens of nasal polyps from 5 patients with CF and 8 patients without CF were stained with hematoxylin and eosin and examined under light microscopy for the presence of intraepithelial microabscesses. Results of bacterial and fungal cultures taken at the time of surgery were reviewed.

RESULTS: Intraepithelial microabscesses were seen in 4/5 (80%) of CF specimens and 0/8 (0%) of non-CF specimens. Epithelial intracytoplasmic vacuoles and neutrophil presence are associated findings. A two-tailed Fisher's exact test demonstrates statistical significance ($p=0.007$). Of the four patients with microabscesses, three had cultures positive for *P. aeruginosa* and two positive for *S. aureus*.

CONCLUSIONS: Microabscesses and associated histologic findings are frequently present in the epithelial layer of nasal polyps in patients with cystic fibrosis. This finding is not present in nasal polyps of patients without cystic fibrosis. Many pathophysiologic and potentially therapeutic questions can be raised for future investigation.

ABSTRACT NUMBER: 1799

THE USE OF AN ILLUMINATED GUIDE WIRE AND SINUS BALLOON CATHETER FOR ASSISTED REDUCTION OF ANTERIOR TABLE FRONTAL SINUS FRACTURE WITH FRONTAL RECESS INVOLVEMENT – A CASE REPORT.

Macario Camacho, MD, Jeffrey Cutler, MD, Christopher Cote, MD, Andrew Battiatia, MD

INTRODUCTION: A 19 year-old sustained a frontal sinus fracture after head trauma, involving the right anterior table of the frontal sinus with involvement of the frontal recess. This paper describes the novel use of illuminated guide wire and sinus balloon catheter for widening the fractured frontal recess and assisting in anterior table reduction.

METHODS: Under endoscopic visualization, an illuminated guide wire was used to access the right frontal recess. Fluoroscopy was utilized for placement because the fracture involved the frontal recess. A 7-mm balloon was inserted into the distal frontal recess. Dilation of the distal frontal recess was necessary prior to full insertion of the illuminated guide wire. Both light visualization through the anterior table and fluoroscopy confirmed proper location. Full frontal recess dilation was achieved, reducing small fragments. The anterior table was partially reduced. An endoscopic brow-lift technique was utilized to attempt full reduction of the anterior table. Due to multiple fragments, complete restoration of the anterior table was unsuccessful. A bi-coronal approach was utilized for complete anterior table repair. Fractures were plated with resorbable plates.

RESULTS: The patient's anterior table and frontal recess fractures were successfully repaired using a combination of endoscopic sinus balloon osteal dilation and open bi-coronal frontal sinus reduction with resorbable plates. 6-month scans demonstrate full aeration of the frontal sinus and a patent frontal recess. Cosmetic appearance was without obvious external contour defect.

CONCLUSION: An illuminated guide-wire and sinus balloon catheter can assist in repairing anterior table frontal sinus fractures with frontal recess involvement.

ABSTRACT NUMBER: 1813

REVISION SINUS SURGERY FOLLOWING BALLOON SINUPLASTY FAILURE

Roy Thomas, M.D., Winston Vaughan, M.D.

INTRODUCTION: Balloon catheters are an emerging new technology in management of chronic sinus disease. Safety and efficacy have been shown in previous studies, however as with many new techniques, data on long term success is still being gathered. This study assesses the failure rate of balloon catheters used in endoscopic dilatation of the paranasal sinuses in a tertiary sinus practice.

METHODS: All cases performed by a single rhinology practice as part of the multi-site Clinical Evaluation to Confirm Safety and Efficacy of Sinuplasty in the Paranasal Sinuses (CLEAR) study were reviewed. Information on site of dilation, failure, and average time of follow up were collected. In cases where revision was required, operative reports were examined to determine factors involved.

RESULTS: A total of 14 patients were identified, with 25 separate sinuses being treated with balloon sinuplasty. There were no major adverse events associated with use of balloon catheters. The revision rate was

8% (2/25) with both revised sinuses being maxillary sinuses. Average follow-up was 22.29 months.

CONCLUSIONS: Balloon catheter dilatation of the paranasal sinuses is a safe, effective means of performing sinus surgery with a low revision rate. Both revisions involved the maxillary sinus. This is likely due to the position of the natural ostium and its relationship to the uncinat process. To decrease the chances of failure and subsequent revision it is recommended that the location of the natural ostium be confirmed by visualization with angled telescopes.

ABSTRACT NUMBER: 1817

REDUCING NASAL MORBIDITY AFTER SKULL BASE RECONSTRUCTION WITH THE NASOSEPTAL FLAP: FREE MIDDLE TURBINATE MUCOSAL GRAFTS.

William Leight, MD, Adam Zanation, MD

INTRODUCTION: Expanded Endonasal Approaches (EEA) to the ventral skull base are increasingly common. The nasoseptal flap has become the standard in our practice for reconstruction. It provides hearty, vascularized tissue for reconstruction along the entire anterior ventral skull base. Although an excellent material for reconstruction, its harvest produces significant donor site morbidity due to exposed cartilage on the nasal septum. The process of remucosalization of the septum takes 6-12 weeks and requires multiple debridements and patient cooperation with frequent saline rinses and sprays. EEA often requires a large nasal corridor which usually necessitates removal of one or rarely both middle turbinates. The present study addresses the reduction of nasal morbidity by providing early remucosalization with free mucosal grafts from a previously harvested middle turbinate.

METHODS: Three patients undergoing EEA for benign lesions of the ventral skull base were enrolled, the donor site healing was compared with nasoseptal flap patients without free grafts. At the end of each case, sacrificed middle turbinate mucosa was harvested and placed as a free mucosal graft on the anterior exposed septal cartilage. This was then splinted for 3 weeks.

RESULTS: At the end of 3 weeks, all patients exhibited remucosalization rates of 50-70%. By 6 weeks, all patients were completely remucosalized. The 3 and 6 week mucosalization rates are significantly higher than those without free grafts. Preoperative and postoperative SNOT-20 scores were unchanged in all 3 patients.

CONCLUSIONS: The nasoseptal flap is quickly becoming the standard of care for skull base reconstruction; however, donor morbidity is not insignificant. It is possible to reduce the short-term nasal morbidity of the nasoseptal flap by reusing mucosa from already sacrificed middle turbinate.

ABSTRACT NUMBER: 1820

CHRONIC RHINOSINUSITIS MUCOSA VERSUS NORMAL SINONASAL MUCOSA: A PROTEOMICS STUDY.

Dr. Armin Deroee, Dr. Mohsen Naraghi, Prof. Werner Hosemann, Dr. Christian Scharf

INTRODUCTION: Despite many studies on chronic rhinosinusitis (CRS), many aspects of this disease are still controversial. CRS is divided to two major groups: CRS with nasal polyposis (CRSwNP) and CRS without NP (CRSsNP). Gene expression and protein biomarkers have recently

gained a lot of attention. As proteins are the final products of genes, comparing the protein structure of sinonasal mucosa in large scale may enable us to detect the processes leading the transformation of normal mucosa to CRS mucosa. In this study we investigated the protein profile of normal sinonasal mucosa with CRSwNP and CRSsNP mucosa.

METHODS: Samples were taken from nasal mucosa of the control group, CRSwNP and CRSsNP patients. Proteins from these samples were extracted and separated by immobilized pH gradient -based two-dimensional difference gel electrophoresis (2-D DIGE). Resulting 2D-gel images were statistically analyzed using Delta2D software and differently expressed protein spots were identified by matrix-assisted laser desorption/ionization time-of-flight mass spectrometry (MALDI-TOF/TOF-MS).

RESULTS: A reference map of approximately 2000 proteins could be established. 64 proteins were significantly different (2-fold, $p < 0.05$) between CRSwNP and CRSsNP mucosa. Up to now several of these significantly changed proteins could be identified by MALDI-TOF/TOF-MS.

CONCLUSION: Major significantly changed proteins and their biological functions will be discussed regarding the pathogenesis of CRS. Knowing the protein structure of mucosa in normal mucosa and CRS can enlighten the pathways leading to this disease. This can direct us to new ways for CRS treatment.

ABSTRACT NUMBER: 1821

RETROGRADE ENDOSCOPIC DACRYOCYSTORHINOSTOMY AFTER FAILED EXTERNAL DACRYOCYSTORHINOSTOMY.

Kevin McLaughlin, MD

INTRODUCTION: Endoscopic DCR after failed external DCR can be complicated by severe scarring secondary to the primary procedure. Scarring can preclude successful ventilation of the lacrimal system at the lacrimal sac. A variation on endoscopic DCR is presented where the lacrimal system is cannulated distally within the lacrimal duct and followed in a retrograde fashion to the sac and canaliculi. This alternative technique uses consistent landmarks usually unaffected by external DCR. Video clips of the technique are presented. Causes for persistent lacrimal duct obstruction after external DCR are identified.

METHODS: Case series

RESULTS: From July 2005 to June 2007, 22 patients with persistent nasal lacrimal duct obstruction after failed external DCR underwent endoscopic retrograde DCR. 21 (95%) patients had patent lacrimal systems at one year follow-up. One patient required conjunctivodacryocystorhinostomy (CDCR).

CONCLUSIONS: An alternative, technically easier, retrograde approach to endoscopic DCR is presented. Anecdotaly, the technique is easier to master by residents. Results are comparable or better than the traditional endoscopic approach.

ABSTRACT NUMBER: 1825

THE ROLE OF ESTROGENS INFLUENTS ON DEVELOPMENT AND TREATMENT OF ALLERGIC RHINITIS.

Prof. Dmitro Zabolotny, Yaremchuk Eduardovna, PhD

INTRODUCTION: Last decades actively develop and the concept according to which influence of sexual steroids are to some extent distributed to a functional condition of all bodies and systems including a respiratory

path. Now presence of membrane learning structures and/or endocellular receptors of sexual hormones not only in cells of genitals, but also of some others - for example, for estrogens it is liver, muscles, pancreas, some structures of brain, bone tissue, and also cardiovascular and respiratory systems. Thus in the image, presence of receptors to sexual hormones in bodies of not reproductive sphere proves variety of their biological activity as system regulators of physiological processes at the level of the whole organism. The allergic rhinitis (AR) are widely spread diseases of nasal cavity and sinuses, which commonly occur in female than in male (2:1).

METHODS: We interrogated 200 women, who suffered AR and revealed signs of hyperestrogenia (80%), such as mastopathy 23 %, before menstrual syndrome 60 %, long-term administration of estrogens contraceptives 46%.

RESULTS: We used in our treatment not only nasal steroids and antihistamines and special diet with low concentration of phytoestrogens and drugs with antagonistically properties for estrogens (Mastodinon, made by Bionorica company). Compared main recorded their daily nasal and eye symptoms such as sneezing, nasal blockage, rhinorhea, itching, watery eyes, itching of eyes, red eyes, swollen eyes before treatment and after 3 month treatment in main group (20 persons) and control (20 persons) we revealed better results in main group.

CONCLUSIONS: Our data suggested about important role of estrogens in develop of symptoms of AR and possibility of include drugs with antiestrogenic properties for treatment of this pathology.

ABSTRACT NUMBER: 1826

SO CALLED ORGANIZED HEMATOMA OF THE MAXILLARY SINUS—REPORT OF FIVE CASES

Hidenori Yokoi, MD, Tatsuya Saito, MD, Fumihiko Matsumoto, MD, Katsuhisa Ikeda, MD

INTRODUCTION: Organized hematoma of the maxillary sinus is a rare clinical disease. It is a chronic state of fibrous tissue surrounding a hemorrhage. Factors that may predispose to hematoma formation vary, and pathogenesis of the mass is still uncertain.

METHODS: We have treated 5 cases of organized hematoma of the maxillary sinus and herein present the clinical images, while specifically focusing on the histopathological images. The subjects consisted of 2 females and 3 males ranging in age from 19 to 68 years old. All of the patients complained of epistaxis, varying from 2 weeks to 3 years from the onset of symptoms until visiting our hospital. A mass lesion was suspected when viewing the CT images and an organized hematoma was suspected in 4 of the 5 cases when viewing the MRI images.

RESULTS: It was possible to successfully perform curative treatment via endoscopic nasal sinus surgery in all of the cases. Histopathologically, papillary endothelial hyperplasia was suspected in 1 of the 5 cases, and the underlying conditions of hemangioma were suspected in 3 cases, and therefore we examined the vascular proliferation and proliferative activities via immunohistochemical staining.

CONCLUSIONS: Regarding the formation of such organized hematoma, a review of our cases in this study suggests that mainly angiomatoid lesions are encountered, and bleeding tended to result from some other inflammation. Therefore, the use of anticoagulants or the involvement of hemodialysis, are therefore considered to subsequently cause fibrin deposits, fibrous hyperplasia, and hyaline degeneration.

ABSTRACT NUMBER: 1836

ULTRA-STRUCTURAL CILIARY EVALUATION IN PRIMARY AND SECONDARY DISKINESIAS

Edwin Tamashiro, MD, Wilma Anselmo-Lima, PhD, Fabiana Valera, PhD, Ricardo Demarco, MD

INTRODUCTION: Primary ciliary dyskinesia (PCD) is a genetic disease characterized through a systemic ciliary mobility, especially in upper airways. Specific alterations in ciliary axonemes are pathognomonic to the syndrome. Secondary ciliary dyskinesia (SCD) is defined to differ to PCD and it is caused by ultra-structural abnormalities observed during or after injuries, as respiratory infections.

METHODS: 21 biopsies from patients with PCD and 15 from patients with SCD were evaluated. They all had previous diagnosis based on both transmission and scanning electronic microscopy.

RESULTS: the most frequent alterations in SCD were composed cilia, small cilia, changes in peripheral microtubules and alterations in respiratory epithelium. The most frequent changes in PCD were loosen or shortening of dinein arms, absence of central microtubules and displacement in one of the nine peripheral pairs.

CONCLUSIONS: we stress the differences in ultra-structural alterations examined between PCD and SCD, especially to those observed in chronic rhinosinusitis refractory to conventional treatments.

ABSTRACT NUMBER: 1838

BORRELIOSIS & OBSTRUCTIVE SLEEP APNEA SYNDROME

Dr. Antje Buettner

INTRODUCTION: Borreliosis and Sleep apnea syndromes (SAS) are a common disorders, which are characterized by impaired daytime functioning in various (neuro)psychological and affective domains. The objective of our study was to estimate the relationship between Borreliosis and OSAS.

METHODS: Our study was carried out involving gradually patients with Borreliosis of the Neurological Rehabilitation in Bad Liebenstein. During admission to the clinic, all neurology patients were examined neurologically and neuropsychologically. All test persons must not suffer from any severe psychiatric disorders. In addition the doctor have to fill a special SBAS-Questionnaire at the anamnesis. On the end the patients were screened with MicroMesam (MAP). So far, data have been gathered for 62 patients with Borreliosis (30 male, 32 female; mean age: 54.05, b11.28; Barthel index: 95.42, b13.82) (SBAS-Questionnaire). Of these 51 study participants were screened with MicroMesam (25 male, 26 female; mean age: 54.86, b11.69; Barthel index: 94.80, b14.90); 11 patients refused the screening.

RESULTS: Among the 51 in the study included patients (SBAS-Screening) the prevalence of patients with OSAS was 76.5 % (39), 13.7 % (7) were high risk patients and at 9.8 % (5) patients SBAS could be excluded. Among this patients ca. 1/3 suffered additional under cardiovascular diseases and/or adipositas: 23 under hypertension (37.70 %), 1 under coronary heart disease (1.64 %), 12 unter arrhythmia (19.67 %) und 9 under adipositas (56.18%). 1 Patient (1.64 %) have had a myocardial infarction, 11 (18.03) an apoplex.

CONCLUSIONS: Our data indicates that there is a causal and strong relationship between Borreliosis and OSAS.

ABSTRACT NUMBER: 1839

CLINICAL ANALYSIS OF ENDOSCOPIC TRANSNASAL TRANSSPHEOIDAL SURGERY

Jin Hee Cho, M.D., Chang Hoon Lee, M.D.

OBJECTIVES: Endoscopic transnasal transsphenoidal approach were common approaches to pituitary and sellar area and is used for more than 95% of surgical indications in this region. The objectives of our study is to report efficacy, safety and complication of endoscopic transnasal transsphenoidal surgery.

PATIENTS AND METHODS: We retrospectively reviewed the medical records of 79 patients who had received endoscopic transnasal transsphenoidal surgery to sellar region between June, 2003 to May, 2008. We evaluated the effectiveness of endoscopic hypophysectomy by analyzing operative findings, symptoms improvement, hospital days, and complications after surgery.

RESULTS: Forty nonfunctioning pituitary adenomas, 15 prolactin, 6 growth hormone and 1 thyroid stimulating hormone secreting pituitary adenomas, 4 pituitary apoplexys, 5 craniopharyngiomas, 3 chordomas, 3 meningiomas, 1 hemangioma, 1 arachnoid cyst. The average length of hospital day was 13.5 days. Postoperative complications were 5 CSF leak, 7 epistaxis, 8 diabetic insipidus, 1 intracranial hemorrhage, 1 blurred vision and 1 death. Visual symptom was improved in all patients with preoperative visual symptom.

CONCLUSIONS: We suggest that the endoscopic endonasal transsphenoidal surgery is a safe, minimally invasive and efficient surgical technique for removal of sellar region tumor, providing good visualizing of the operative field, short procedure duration, and minimal postoperative complications.

ABSTRACT NUMBER: 1843

PRIMARY SINONASAL SQUAMOUS CELL CARCINOMA WITH CONTRALATERAL NECK METASTASIS

Dr. Yong Bok Kim, Dr. Tae Hoo Kim, Dr. Dong Jun Choi

INTRODUCTION: Sinonasal malignant tumors comprise less than 1% of all cancers and 3% of all malignant tumors of head and neck, which explains a lack of large series addressing the clinical characteristics and management of these tumors. Neck node metastasis occurs in only about 7 to 15% of malignant tumors compared with other head and neck cancers.

METHODS: Case presentation.

RESULTS: A 90-yr-old woman presented with left palpable neck mass and right nasal mass occupying nasal cavity. Fine needle aspiration biopsy of left neck mass results in metastatic squamous cell carcinoma (SCC). PET/CT shows intense FDG uptake in right nasal cavity with bony invasion. Histopathologic examination of excised lesion in right nasal cavity revealed SCC. We report here on a primary sinonasal SCC with contralateral lymph node metastasis of neck.

ABSTRACT NUMBER: 1845

COMPUTED TOMOGRAPHY RADIATION DOSE REDUCTION FOR COMPUTER-ASSISTED ENDOSCOPIC SINUS SURGERY (CAS-SINUS CT) – AN EXPERIMENTAL STUDY ON HUMAN CADAVER HEADS AND CLINICAL PRAGMATICS.

Dr. Dubach Patrick, Claude Nauer, MD, Eichenberger Adrian, MD, Prof. Marco Caversaccio

INTRODUCTION: Many radiology departments do not distinguish between diagnostic sinus CT and CAS-CT for sinus surgery. Moreover, the radiation dose used varies considerably. We investigated to which extent radiation dose for CAS-Sinus CT could be reduced while still warranting a safe operation.

METHODS: With a GE Light Speed^a Scanner, 5 CAS-Sinus CTs with different reduced radiation doses were made of human cadaver heads and compared to CAS-Sinus CTs with the standard dose of 65 mGy. First, we tested whether clinically used surface registration with dose-reduced CAS-CT leads to reduced accuracy of screw fixed anatomical points. Second, 5 surgeons had to reliably identify anatomical landmarks on the basis of the 5 different dose-reduced CAS-CTs with the VectorVision^a system and graded their confidence in the image quality on a scale of 1 to 10.

RESULTS: First, we could not find a difference in accuracy for the technical registration with dose-reduced CAS-Sinus CTs. Second, each of the sinus surgeons managed to promptly identify the anatomical landmarks up to a dose reduction to ~4 mGy at a satisfactory estimated image quality of 9 points.

DISCUSSION: The results of our experiments with cadaver heads show that a reduction in radiation dose for CAS-Sinus CT is compatible with a preservation of technical registration accuracy as well as a with sufficient image quality for standard sinus operations. However, we cannot deduce a universal recommendation for radiation doses to be used in reality from our in vitro findings. Nevertheless, an empirical stepwise dose reduction for CAS-Sinus CT was possible in our clinical practice.

ABSTRACT NUMBER: 1846

ENDOSCOPIC TRANSPTERYGOID INTERVENTION OF MENINGOENCEPHALOCELE

Bing Zhou, MD, Demin Han, MD, Shunjiu Cui, MD, Jialiang Zhang, MD

OBJECTIVE: To report the results of endoscopic transpterygoid intervention of 21 patients with meningoencephalocele and CSF leaks within lateral recess of sphenoid sinus (LRSS). The diagnosis of this congenital disease, operative techniques and their related problems were discussed.

METHODS: 21 hospitalized patients with meningoencephalocele and CSF leaks within LRSS were included in this paper. 13 were male and 8 were female, aged from 27 to 58 years old. 2 patients had the histories of intranasal endoscopic repair surgery. The preoperative orientation of CSF leaks and meningoencephalocele depended on CT scan and MRC. Endoscopic transpterygoid intervention and the repair or reconstruction of skull base defects were undertaken under general anesthesia.

RESULTS: All the operations were successful. 17 patients had only one site of defect of skull base, 2 patients had 2 sites and the other 2 patients had 3. Two patients had a postoperative intracranial hypertension and hydrocephalus. 6 patients had a postoperative ipsilateral facial, upper lip and palatal hypesthesia. One of them had a xerophthalmia. All the symptoms above relieved gradually 6 months after operation. No recurrences were

observed during 8 to 64 months follow up (mean follow up 27.2 months).

CONCLUSIONS: Endoscopic transpterygoid intervention for the treatment of meningoencephalocele and CSF leaks within LRSS is a minimally invasive technique and a straightforward approach.

ABSTRACT NUMBER: 1848

A MURINE MODEL OF ALLERGIC RHINITIS WITH SUBLINGUAL IMMUNOTHERAPY

Kaoru Goda, Takaya Yamada, Miki Tongu, Hideyuki Kawauchi, Noriaki Aoi

INTRODUCTION: Sublingual immunotherapy (SLIT) has been considered to be a painless and efficacious therapeutic treatment for allergic rhinitis which is known as type-I allergy of nasal mucosa in a large number of clinical and basic trials. Putative immunological mechanisms of SLIT are induction of neutralizing antibodies with decrease in IgE/IgG4 ratio and/or induction of antigen-specific regulatory T cells, however those remain controversial. Indeed, the amount of allergen needed in SLIT is 50 to 100 times more than that in subcutaneous desensitization.

METHODS: In this study, we constructed an efficient murine model of allergic rhinitis with sublingual immunotherapy, in which mice were sublingually administered with ovalbumin (OVA) followed by intraperitoneal sensitization and nasal challenge of OVA.

RESULTS: Sublingually-treated mice showed significantly decreased allergic responses as well as suppressed Th2 immune responses.

CONCLUSIONS: These results demonstrated the use of our experimental murine model for the elucidation of the mechanism of SLIT in allergic rhinitis.

ABSTRACT NUMBER: 1851

MODERN ASPECTS OF HYPOPHYSES SURGERY

Heier Abdulkarimov, Ksenia Kartashova

INTRODUCTION: Among the intracranial tumors hypophyses adenoma is on the third place by its localization. After typical transcranial operations remains severe transgressions of endocrinological and optical functions, and enough amount of relapses – 17,3% (Samotokin B.A. 1985). At last ten years for extraction of hypophyses adenoma widely spread transnasal mode with using new medical technologies and optical instruments. (Revscoi U.K., 1973; Gofman V.R. et al. 2002; Renn W.H. et al. 1975; Abolirg P.R. et al. 1980)

OBJECTIVE: Application of new diagnostics and treatment algorithms in hypophyses surgery.

MATERIALS AND METHODS: we observe 122 patients with adenoma of hypophyses. Among them 73 women and 49 men in the age of 27 to 57 years old. Size of the tumor vary from 10,0 × 15,0 mm to 47,0 × 28,0 mm. In all cases we used trans sphenoid mode with endovideoscopic equipment, microscope, micro instruments and electro optical reformer (EOR) “Siemens” During the operation to all patients reconstruction of the upper wall of sphenoidal sinus has been spent, so as the actions directed to normalization of level of intracranial pressure.

RESULTS: No complications in intra and post operation periods were found. All patients were ordered in satisfaction condition.

CONCLUSIONS: using new achievement of medicine, general tactics and post operation treatment with neural surgeons can prevent complications, relapses and lethality.

ABSTRACT NUMBER: 1854

ALLERGEN-SPECIFIC IMMUNOTHERAPY ALTERS THE EXPRESSION OF BTLA, A CO-INHIBITORY MOLECULE, IN ALLERGIC RHINITIS.

Seiichiro Makihara, MD, Mitsuhiro Okano, MD, Takaya Higaki, MD, Kazunori Nishizaki, MD

BACKGROUND: B7/CD28 family co-signaling molecules play a key role in regulating T cell activation and tolerance. Allergen-specific immunotherapy (SIT) alters allergen-specific T cell responses. However, the effect of SIT on the expression of various co-signaling molecules has not been clarified.

OBJECTIVE: We sought to determine whether SIT might affect the expression of three co-inhibitory molecules, PD-1, B7-H1 and BTLA, in Japanese cedar pollinosis (JCP).

METHODS: Peripheral blood mononuclear cells (PBMC) were isolated from JCP patients with that had or had not received SIT. PBMC were cultured in the presence or absence of Cry j 1, after which the cell surface expression of PD-1, B7-H1, and BTLA, as well as IL-5 production, were determined. In addition, the effect of BTLA cross-linking on IL-5 production was examined.

RESULTS: After Cry j 1 stimulation, no significant differences in PD-1 and B7-H1 expression were observed among SIT-treated and untreated patients. BTLA expression was down-regulated in untreated patients after Cry j 1 stimulation and up-regulated in SIT-treated patients. Up-regulation of BTLA in SIT-treated patients was particularly apparent in a CD4+ T cell subset. IL-5 production was clearly reduced among SIT-treated patients, and the observed changes in BTLA expression correlated negatively with IL-5 production. Moreover, immobilization of BTLA suppressed IL-5 production in JCP patients.

CONCLUSION: These results suggest that both IL-5 production and down-regulation of BTLA in response to allergen are inhibited in SIT-treated patients with JCP. BTLA-mediated co-inhibition of IL-5 production may contribute to the regulation of allergen-specific T cell responses in patients receiving immunotherapy.

ABSTRACT NUMBER: 1856

GLUCOCORTICOID EFFECTS ON REGULATORY T CELLS IN NASAL POLYP

Takaya Higaki, Mitsuhiro Okano, Seiichiro Makihara, Kazunori Nishizaki

INTRODUCTION: It is known that glucocorticoids (GCs) display its anti-inflammatory role via “switch on” anti-inflammatory gene expression and/or “switch off” pro-inflammatory gene expression. The production of a large number of cytokines with inflammatory properties is down-regulated by GCs. Recently, several reports suggested that GCs can induce regulatory cytokines such as IL-10 and regulatory T cells such as CD4+CD25+Foxp3+ regulatory T cells (Tregs). Foxp3 mRNA expression in peripheral blood CD4+ cells was increased in patients with bronchial asthma taking GCs. However, little is known whether GCs can induce these regulatory molecules in the upper airway.

METHODS: In the present study, we investigate the effect of GCs on the induction of regulatory cytokines and Tregs in dispersed nasal polyp cells (DNPCs).

RESULTS: Dexamethasone (Dex) did not change the proportion of CD25+Foxp3+ cells in CD4+ cells. In the presence of IL-2, however, Dex dose-dependently induces CD25+Foxp3+ expression, suggesting

that IL-2 and Dex synergistically induce Tregs in DNPC. It is reported that both CD4+ and CD8+ T cells in nasal polyps express intracellular IL-2. And we also observed a significant production of IL-2 in DNPC in response to SEB. Thus these results suggest that GCs can induce Tregs in the nasal polyps. Dex induced IL-10 but not TGF-beta production by DNPC. Dex inhibited IL-5, IL-13 and RANTES production by DNPC stimulated with SEB in a dose-dependent manner. Interestingly, neutralization of IL-10 significantly recovered the inhibition induced by the Dex together with IL-2.

CONCLUSIONS: These results suggest that GCs displays an anti-inflammatory effect via inducing Tregs in inflamed tissue containing IL-2.

ABSTRACT NUMBER: 1857

RADIOGRAPHIC IDENTIFICATION OF PERINEURAL INVASION IN NASAL AND PARANASAL SINUS CANCER

Kimberly Lee, MD, Sunita Bhuta, MD, Elliot Abemayor, MD, PhD, Claudia Kirsch, MD

OBJECTIVES: Nasal and paranasal sinus malignancies occur in locations that are close to vital structures, including the brain, orbit, and cranial nerves. Few signs are noted in the early stages which are often minimized as they can be signs of more common and less serious conditions. By the time ominous symptoms arise, these malignancies are advanced. Although perineural invasion (PNI) can be clinically silent, it is critical for patient prognosis as it is associated with poor locoregional control, increased recurrence, and decreased survival. Radiographic imaging can identify PNI prior to the development of clinical symptoms. The purpose of this study is to identify critical radiographic features of perineural invasion which may be identified prior to its clinical development.

METHODS: This study retrospectively reviewed preoperative images of twenty patients with nasal and paranasal sinus malignancies with histopathologically proven PNI. CT, PET-CT and gadolinium-enhanced MRI images were then retrospectively reviewed by a head and neck radiologist and surgeon to assess for findings of PNI.

RESULTS: Important radiographic features identified included loss of fat planes around the nerve, enhancement and nerve thickening, and enlargement of the corresponding neural foramina. Histopathology was used as the gold standard for determining the presence of PNI.

CONCLUSIONS: PNI can be present in asymptomatic patients with nasal and paranasal sinus malignancies; therefore imaging and early identification of PNI is essential for adequate surgical resection, therapeutic treatment planning, and patient prognosis.

ABSTRACT NUMBER: 1858

AN UNUSUAL INTRANASAL MASS: PLEOMORPHIC ADENOMA

Omer Saglam, MD, Ersin Ozturk, MD

A case of pleomorphic adenoma of the nasal septum is herein presented. Computed tomography and magnetic resonance imaging of a 65-year-old woman who presented with nasal obstruction and epistaxis revealed a lobular mass in the right nasal cavity. Histopathologic examination revealed a pleomorphic adenoma. Computed tomography and magnetic resonance imaging findings of this rare neoplasm are discussed.

ABSTRACT NUMBER: 1863

EFFICACY OF CICLESONIDE AQUEOUS NASAL SPRAY FOR TREATMENT OF PERENNIAL ALLERGIC RHINITIS BY BASELINE SEVERITY

John Karafilidis, PhrMD, Paul Chervinsky, MD, Mark Wingertzahn, PhD, Holly Holly Huang, MS

INTRODUCTION: Ciclesonide is available as an aqueous intranasal corticosteroid formulation for treatment of seasonal (≥6 years old) and perennial (≥12 years old) allergic rhinitis (PAR). A post hoc analysis was conducted to assess the long-term efficacy of ciclesonide aqueous nasal spray in improvement of symptoms of PAR in subjects with varying baseline severity.

METHODS: This post hoc analysis consisted of 633 patients (≥12 years) with PAR from a 52-week, double-blind, placebo controlled, multicenter safety trial of ciclesonide (Chervinsky et al, Ann Allergy Asthma Immunol. 2007;99:69-76). This study was designed to evaluate the long-term safety (primary end point) and efficacy of ciclesonide. Patients received ciclesonide 200µg (n=441) or placebo (n=222) QD for 52 weeks. Data was stratified by baseline reflective total nasal symptom score (rTNSS) of <6 and ≥6 (out of a total of 12) and improvement in patient-recorded 24-hour rTNSS score following 52 weeks of ciclesonide treatment was evaluated.

RESULTS: There were 294 patients (ciclesonide, n=191; placebo, n=103) in the <6 baseline rTNSS group and 359 patients (ciclesonide, n=244; placebo, n=115) in the ≥6 baseline rTNSS group. Ciclesonide significantly improved 24-hour rTNSS in the <6 baseline rTNSS group (LS mean change from baseline (-1.14) vs placebo (-0.49): treatment difference, 0.66[p=0.0003] and ≥6 baseline rTNSS group (LS mean change from baseline (-3.21) vs placebo (-2.74): treatment difference, 0.47[p=0.045]).

CONCLUSION: In this post hoc analysis of a long-term safety study which also evaluated efficacy, ciclesonide aqueous nasal spray improved the rTNSS of PAR patients with different baseline severities over 52 weeks.

ABSTRACT NUMBER: 1867

NASAL DERMOID SINUS CYST

Murat Salihođlu, Omer Sađlam

INTRODUCTION: Nasal Dermoid Sinus Cyst is one of rarely seen congenital anomalies. Nasal Dermoid Sinus Cyst is more prevalent in males and usually diagnosed during childhood. There is a potential risk of intracranial extension, frequently localized extradural. For this reason all patients must undergo radiologic evaluation. Differential diagnosis should be made with glioma, encephalocell, congenital anomalies, inflammatory lesions, benign and malign tumors. Regardless of intracranial extension treatment choice is total excision. Best surgical method is external rhinoplasty approach with medial crural dissection. In case of intracranial extension craniotomy is added for adequate resection.

METHODS: Case presentation.

RESULTS: Case of this study is 21 years old male without intracranial extension.

CONCLUSION: Nasal Dermoid Sinus Cyst is treated with total excision using external rhinoplasty approach with medial crural dissection.

ABSTRACT NUMBER: 1868

COMPARISON OF FOUR OFFICE-BASED METHOD IN TREATMENT OF INFERIOR TURBINATE HYPERTROPHY, WHAT SHOULD BE FIRST INITIAL TREATMENT

Naruwat Kesornsukhon

OBJECTIVES: To compare the efficacy of submucosal non-temperature-controlled radiofrequency tissue volume reduction (RFTVR), temperature-controlled radiofrequency tissue volume reduction (TCRFTVR), submucosal resection with microdebrider (SMRM), Carbon dioxide (CO₂) laser ablation in chronic inferior turbinate hypertrophy. We wanted to find out the first line for initial treatment in our CPG.

METHODS: Prospective, randomized, and single-blinded clinical trial between August 2002 and September 2007. 120 symptomatic nasal obstruction patients with inferior turbinate hypertrophy refractory to medical treatment in Samutsakorn Hospital were randomized separated into four group, 30 for each procedure. Visual analogue scale (VAS), saccharine transport time (STT), complication were evaluated preoperatively and at 12th week and 6th month postoperatively.

RESULTS: Significant improvement was achieved in VAS scores after all procedures (p<.05). STT showed no significant posttreatment variation in comparison of three submucosal method. CO₂ laser ablation impaired STT initially more than submucosal method. SMRM were comfortable to do in operation room than OPD. The study suspected RFTVR and TCRFTVR is less invasive, identical results in objective and subjective parameters were observed for both techniques. RFTVR is faster operated than TCRFTVR (P<.05). No serious complication in all method.

CONCLUSION: We choose RFTVR to do as our first initial office-based procedure in treatment for inferior turbinate hypertrophy. The reason are identical result, cheap, no serious complication and faster operation time.

ABSTRACT NUMBER: 1869

THE EFFECT OF ANTERIOR NASAL PACKING WITH AIRWAY TUBES ON PULMONARY FUNCTION FOLLOWING SEPTOPLASTY.

Hanifi Kurtaran, MD, Nebil Ark, MD, Fatih Sadikoglu, MD, Serife Boynukalin, MD

INTRODUCTION: It is well known that nasal packing influences respiratory function and results with hypoxemia and hypocapnia. A “nasopulmonary reflex” has been proposed as the cause of this dysfunction. However to the best of our knowledge there is no study measuring pulmonary function of patients with anterior nasal pack with airway tube. Therefore we aimed to investigate the effects of anterior nasal packing with airway tubes on pulmonary function following septoplasty.

STUDY DESIGN: A prospective, cross-sectional study.

PATIENTS AND METHODS: Fifty patients who were operated for nasal septal deviation between years 2006-2008, were included to our study. Nasal packs with airway tube used for all patients following septoplasty. Pulmonary function tests and PO₂ measurements with pulse oximetry were performed preoperatively and in the second postoperative day just before removal of the nasal pack. Forced Vital Capacity (FVC), Forced Expiratory Volume in 1. Second (FEV₁), FEV₁/FVC (FEV₁%), Forced Expiratory Flow (FEF₂₅₋₇₅%), and PO₂ values were compared.

RESULTS: The mean age of study population was 35,3±12.6 years (range:18-64). There was no significant differences found regarding; FVC (4.2±0.9 vs. 4.1±0.9), FEV₁ (3.5±0.8 vs. 3.5±0.9), FEV₁% (85.3±9.3 vs. 83,6±10,7), FEF₂₅₋₇₅% (4.1±1.5 vs. 4.0±1.6), PO₂ (98.3±0.8 vs. 98.2±0.5) between preoperative and in the second postoperative day just before removal of the nasal pack. (p>0.05).

CONCLUSION: The results indicate that anterior nasal packing with airway tubes is not a cause for respiratory dysfunction and hypoxia.

ABSTRACT NUMBER: 1872

THE ENDOSCOPIC APPROACH OF INVERTED PAPILLOMA - OUR EXPERIENCE ON 94 CASES

Vlad Budu, MD. P.

INTRODUCTION: Inverted papilloma is the most common sinonasal tumor with a high risk of recurrence and malignancy transformation.

METHODOLOGY: We performed a retrospective analysis on the endoscopic approach of the inverted papilloma in the last 10 years at the ENT Institute, Bucharest.

RESULTS: We performed a videofibroscope and a CT scan to every patient selected for this study with indication for endoscopic surgery (KROUSE stage I, II and III). The study group consisted of 71 male and 23 female patients with a mean age of 45. We performed endoscopic tumor removal and a long-term follow-up. Recurrence rate was 11% and malignancy transformation was 4%.

CONCLUSIONS: Endoscopic approach has a good surgical outcome and an increasing long term result in selected case of inverted papilloma, but this pathology remains a never ending challenge for the rhinologist.

ABSTRACT NUMBER: 1873

IS THERE ANY RELATIONSHIP BETWEEN NASAL POLYPOSIS AND ABO BLOOD GROUPS?

Nebil Ark, MD, Hanifi Kurtaran, MD, Gultekin Kizilbulut, MD, Turker Yilmaz, MD

INTRODUCTION: It is well known that blood group antigens are related to the development of some diseases such as oral carcinoma, peptic ulcer and gastric carcinoma. However to the best of our knowledge there is no study in the literature analyzing the relationship between blood group antigens and nasal polyposis. Therefore we performed this study to determine the relationship between nasal polyposis and ABO blood groups.

STUDY DESIGN: A prospective, cross-sectional study.

PATIENTS AND METHODS: One hundred forty four patients underwent nasal surgery (64 with nasal polyposis and 80 septorhinoplasty) between years 2006-2008 were enrolled in the study. Demographic data recorded for each patient included age and gender. ABO/Rhesus blood group antigen typing was performed.

RESULTS: The mean age of study population was 33.8±13.6 years (range: 15-73). Prevalence of blood groups in the nasal polyposis group were A 42% (27), B 12.5%(8), AB 7.8%(5), O 37.5%(24) and in the septorhinoplasty group were A 45% (36), B 13.8%(11), AB 3.8%(3), O 37.5%(30). There were no significant relationship found regarding ABO blood groups and nasal polyposis. (p>0.05)

CONCLUSION: The results of this study demonstrate that ABO blood groups are not related with development of nasal polyposis. However further studies with a bigger patient population needed for a better understanding of the relationship.

ABSTRACT NUMBER: 1875

EFFECTS OF PARENTERAL CORTICOSTEROID ADMINISTRATION ON PERIORBITAL EDEMA AND ECCHYMOSIS AFTER SEPTORHINOPLASTY

Güven Yildirim, MD, Yavuz Atar, MD

INTRODUCTION: Ecchymosis occurring after septorhinoplasty operation is an annoying complication for patients although they are informed preoperatively. It may cause mistrust between patient and physician. We aimed to investigate effects of preoperative administration of single type and combined corticosteroid on periorbital edema and ecchymosis after open technique septorhinoplasty.

METHODS: This study is an analysis of 75 patients who had undergone open technique septorhinoplasty. All patients were performed bilateral osteotomy and hump resection. We divided patients into five groups. First group was received 250 mg methylprednisolone intravenously, second group was received 8 mg dexamethasone intravenously, third group was received 250 mg methylprednisolone and intramuscular betamethasone, fourth group was received intravenous 8 mg dexamethasone and intramuscular betamethasone. Corticosteroid administrations were performed 15 minutes before beginning of surgical procedures. Fifth group was control group so patients didn't have corticosteroid administration. All patients were graded for ecchymosis and periorbital edema on 2nd, 5th and 7th days according to a scale between 0 to 4.

RESULTS: When we evaluated the groups on the second day, edema and ecchymosis were significantly lower in the fourth and third groups than the other three groups. Results on the fifth day were similar to

second day. There were no significant difference between groups on the 7th day except control group.

CONCLUSION: Preoperative administration of betametasone combined with methylprednisolone or dexamethasone decreased postoperative periorbital edema and ecchymosis more effectively than administration of methylprednisolone or dexamethasone alone.

ABSTRACT NUMBER: 1876

NASAL MUCOSA HISTOLOGICAL FEATURES OF BONE MARROW TRANSPLANTATION PATIENTS AND GRAFT VERSUS HOST DISEASE.

Erica Ortiz, MD, Eulalia Sakano, PhD, Luciana Meirelles, PhD, Carlos Chone, PhD

INTRODUCTION: the Bone marrow transplantation (BMT) has often been performed nowadays. Immunosuppression is the leading cause of recurrent sinus infection in Bone Marrow Transplantation (BMT). High frequency of sinusitis in BMT and chronic graft versus host disease (GVHD) patients is often observed. It is a graft donor lymphocytes reaction against the HLA antigens receptors in the cell membrane of host tissues. The GVHD has multifactorial features that are not yet completely understood and its diagnosis is based on histological, immunological and clinical aspects. However, there are no descriptions of nasal histological features in BMT and chronic GVHD. Only the oral mucosa, lung ciliar epithelium and intestinal mucosa have specific histological descriptions related to BMT and GVHD on the literature. Objective: to verify the histological and ultrastructural aspects of nasal mucosa of BMT and chronic GVHD patients so that the cause of increased rhinosinusitis frequency is understood, mainly in chronic GVHD.

METHODS: histological evaluation of uncinat process from 24 BMT patients between 19 and 64 years-old was performed by light microscopy and transmission electron microscopy. The optic features were: intraepithelial lymphocytes and eosinophils, Globet cells concentration, apoptotic bodies, inflammatory infiltrated, edema and fibrosis. The ultrastructural features were cilia structure and orientation, mitochondria quantity alterations, microvilli, cytoplasm vacuolization and Globet cells. The minimum BMT period was 15 days and the maximum, 11 years. Nineteen patients have chronic GVHD and five do not.

RESULTS: the mononuclear cells, lymphocytes and platelets counting weren't significant. There were no difference on rhinosinusitis occurrence between BMT and chronic GVHD (70-80% had rhinosinusitis). However, all BMT patients with rhinosinusitis have significant loss or absence of cilia (P=0,018). Related to optic microscopy, only the apoptotic bodies were increased in nasal epithelium from chronic GVHD (P=0,04). The lymphocyte inflammatory infiltrated was predominant in both groups (77-100%), but there was no statistical significance. Only the Globet cells were significantly decreased in chronic GVHD on the electron microscopy. There were ultrastructural ciliary abnormalities in both groups: compound cilia, triple central microtubules and internal dinein absence.

CONCLUSION: BMT patients have loss and/or absence of cilia on the sinonasal mucosa. The increase of apoptotic bodies and the decrease of Globet cells were the unique sinonasal mucosa features in chronic GVHD patients. The lymphocyte inflammatory infiltrated was not increased as expected in chronic GVHD, disaccording with literature. BMT and GVHD may have gradual structural modifications on the nasal mucosa and may trigger sinusitis recurrence.

ABSTRACT NUMBER: 1877

PRESENTATION AND SEVERITY OF BENIGN SINONASAL DISEASE IN PATIENTS WITH CHRONIC IMMUNODEFICIENCY

Edward McCoul, MD, Krishnamurthi Sundaram, MD

OBJECTIVES: 1. To establish the relative severity of chronic inflammatory sinonasal disease in patients with comorbid immunodeficiency states. 2. To identify anatomic factors that may contribute to disease severity in this patient population.

STUDY DESIGN: Retrospective cohort study.

METHODS: The study group included patients with chronic rhinosinusitis and a chronic immunodeficiency state that were treated at a public hospital between 2001 and 2008. Comorbidities of interest included human immunodeficiency virus (HIV) infection, sickle cell disease (SCD) and diabetes mellitus (DM). All patients had sinus CT scans, which were reviewed and graded according to the Lund-McKay and Kennedy staging systems. A control group of randomly-selected immunocompetent patients with chronic sinonasal disease was used for comparison.

RESULTS: One hundred five patients with immunodeficiency and 67 control patients were included for study. CT severity scores were significantly higher for patients with DM, SCD, or HIV compared with controls. However, there was no difference in recorded symptom frequency between the groups. Nasal polyposis was associated with more severe disease and found more frequently in patients with comorbid conditions. Conversely, surgical management was more frequent in the control group. Adenoid enlargement was more frequent in patients with HIV compared with controls, whereas septal deviation, turbinate hypertrophy, and concha bullosa were equally present in both groups.

CONCLUSIONS: Patients with comorbid conditions that affect the immune system may be at risk for more severe manifestations of chronic rhinosinusitis. Despite this risk, they are more often treated nonsurgically. These findings suggest that patients with HIV, SCD or DM should be considered for earlier or more aggressive surgical treatment.

ABSTRACT NUMBER: 1882

EXPERIENCE WITH CONGENITAL ANOSMIA AT THE UCONN TASTE AND SMELL CENTER

Yvonne Richardson, MD, Denis Lafreniere, MD

INTRODUCTION: Congenital anosmia is a rare disorder. Its association with Kallmann syndrome and other developmental abnormalities has been well described. Less is available in the literature on congenital anosmia as an isolated phenomenon.

METHODS: To identify common elements of isolated congenital anosmia, a retrospective chart review was conducted for all patients evaluated at the University of Connecticut Taste and Smell Center between January 2006 and January 2009 with the presumptive diagnosis of congenital anosmia.

RESULTS: Features of the history including age at which anosmia was first noticed, how it was noticed, history of trauma, and, if applicable, history of development of secondary sexual characteristics were extracted from the charts. Results of chemosensory smell and taste testing were also recorded, as well as any abnormalities on thorough physical exam. If available, CT and MRI results were examined, paying particular attention to presence of sinus disease and olfactory bulbs. Workup and management is discussed.

ABSTRACT NUMBER: 1548

NASOLACRIMAL DUCT PROBING: FAILURE AND TREATMENT

Shawky Elmorsy, MD

INTRODUCTION: when probing treatment for congenital nasolacrimal duct obstruction fails, it is often unclear whether it is due technical difficulties, or the severity of obstruction. So, our aim is to study the causes of probing failure and how to treat them.

METHOD: In a prospective study, 36 nasolacrimal ducts of 26 children aged 12 months to 4 years with congenital nasolacrimal duct obstruction (CNLDO) were treated by probing. In all children probing was done under direct vision using nasal endoscopy. Different forms of CNLDO were treated and studied to determine the potential predictors for treatment failure.

RESULTS: The overall success rate was 95.5%. Expected failure was attributed mainly to the construction of different forms of membranous penetration on probing. Surgical membranotomy at the area of Hasner's valve under direct nasal Endoscopic visualization is an essential step for proper management of CNLDO.

CONCLUSION: Probing combined with intranasal endoscopy can be helpful in identifying causes of failure and their proper management. This can minimize intranasal trauma and lead to better surgical outcome.

ABSTRACT NUMBER: 1567

MICRONIZED COLLAGEN INJECTION FOR THE MANAGEMENT OF PATULOUS EUSTACIAN TUBE

Rakesh Chandra, MD, Andrew Fishman, MD, Michiel Bove

Patulous eustacian tube (ET) may be a significant source of distress secondary to symptoms of autophony of one's voice and/or respiration. Multiple approaches have been described to manage this problem, including myringotomy and tube placement, as well as procedures directed towards the tubal orifice itself, which may be accomplished via transoral and/or transnasal access. These include ET ligation, augmentation with autologous cartilage or fat grafts, and translocation of the tensor veli palatini muscle. Herein, we employ video footage to illustrate the case of a 37 year old female with chronic troubling symptoms of unilateral patulous ET that was refractory to myringotomy and tube placement. The patient underwent an endoscopic trans-nasal approach with submucosal injection of Cymetra® into the posterior cushion of the ET orifice using a 23G spinal needle. Total procedure duration was <20 minutes, which included the time necessary for nasal decongestion, as well as preparation of the material for injection. The patient tolerated the procedure well and blood loss was negligible. She expressed immediate relief and has since been symptom free, without otorrhea or hearing loss. Observed advantages of this technique include precision, speed, and lack of morbidity related to the approach or a donor site.

ABSTRACT NUMBER: 1576

ENDOSCOPIC MAXILLARY FAILURES

Robert Meyers, M.D.

INTRODUCTION: Uncommonly, endoscopic maxillary osteotomy fails to resolve the underlying sinusitis. Several reasons have been postulated, including inadequate surgical creation of an ostium, underlying fungal etiology, unspecified cilia dyskinesia and others. Regardless, the surgeon faces an unhappy patient.

METHOD: By creating a wide inferior window and connecting it with the previously widened maxillary osteotomy, in essence, a partial medial maxillectomy is created.

RESULTS: This almost always results in resolution of the maxillary sinusitis.

CONCLUSION: The postulated mechanism could be that the cilia were not capable of an active anti-gravity system and a newly created window effects mucous clearance by gravity. Before the advent of ESS, inferior windows were effective most of the time.

ABSTRACT NUMBER: 1577

AN ALTERNATIVE TO REVISION ENDOSCOPIC PROCEDURES IN FRONTAL SINUS FAILURES

Robert Meyers, M.D.

INTRODUCTION: There are basically two types of open frontal sinus surgery. The first, more traditional, involves frontal sinus obliteration technique, while the second involves recreating the outflow tract. The latter procedure is required when entities, such as mucoceles and mucopyoceles have eroded the adjacent structures, mainly the orbit and/or posterior frontal wall. In these situations, the periorbita or dura become intimately involved with the mucocele. The mucous membrane of the mucocele becomes inextricably adherent to the periorbita or dura and cannot be removed without sacrificing these structures. This open technique can be adapted for endoscopic failures.

METHOD: This operation is designed to bypass the need for resection of the dura or periorbita by leaving the mucous membrane lining of the mucocele in place and marsupializing the contents of the frontal sinus into a widely created frontal outflow tract.

RESULTS: This method has had almost 100% success as measured by the need for additional frontal surgical procedures as exemplified by 15 cases in 15 years.

CONCLUSION: It is also effective for endoscopic frontal failures. Of course, some revisions can be done endoscopically by very experienced operators, however, the less experienced surgeon may not be comfortable with revision frontal techniques, but should be able to easily accomplish this open technique.

ABSTRACT NUMBER: 1579

ENDOSCOPIC MANAGEMENT OF CHRONIC ISOLATED FRONTAL SINUSITIS: THE UNCINECTOMY APPROACH

Mohamed Askar, MD

OBJECTIVES: Chronic isolated frontal sinusitis occurs due to either anatomical or pathological abnormalities confined to the frontal recess obstructing the sinus drainage pathway. The aim is to describe a targeted endoscopic approach to the frontal sinus depending upon resection of the upper two thirds of the uncinate process only without violation of the other anterior ethmoidal structures.

STUDY DESIGN: From 2001 to 2006, 27 patients with isolated chronic frontal sinusitis refractory to medical treatment underwent the endoscopic uncinctomy approach. The main symptom in all patients was persistent or recurrent frontal pain. Follow up ranged between 8 to 32 months (mean 20.7). The results were obtained depending on both the subjective and objective assessments.

METHODS: It was crucial to study preoperatively the computed tomograph (CT) scanning to delineate the anatomy of the frontoethmoidal connection area including the attachment of the upper end of the uncinate process and the presence of any type of frontal recess cells. With 0° endoscope, the technique was started usually by dividing the uncinate process at the junction between the upper anterosuperior two thirds and its lower posteroinferior third using the backbitting cutting forceps. The upper two thirds were then medialized using a ball tipped probe and then removed with soft tissue shaver or upturned forceps. With 30°, 45° or 70° telescope, the bony cap of recessus terminalis, agger nasi or frontal; cell was removed meticulously in order to expose the underneath frontal sinus ostium.

RESULTS: Twenty two patients were asymptomatic or markedly improved postoperatively. Three patients reported mild improvement while the other two had no improvement. The frontal sinusotomy opening was widely patent postsurgically in 15 patients, stenosed in 9 and closed in the remaining 3 patients. No major complications were encountered.

CONCLUSION: The uncinctomy approach provides a minimal invasive technique for management of chronic isolated frontal sinusitis. The lower third of the uncinate process protecting the maxillary sinus ostium is preserved avoiding the occurrence of iatrogenic maxillary sinusitis. The bulla ethmoidalis and the suprabullar recess were kept intact to avoid injury of the skull base or the anterior ethmoidal artery. This also gives support to the middle turbinate and minimizes the incidence of its lateralization.

ABSTRACT NUMBER: 1590

FRONTAL SINUS APPROACH: THE CONCEPT OF THE “VERTICAL BAR”

Joao Nogueira, MD, Aldo Stamm, PhD, Ronaldo Americo, MD

INTRODUCTION: Endoscopic frontal sinus surgery is considered difficult and risky to the patient by many surgeons. Surgery on the frontal recess and frontal sinus remains a challenge because requires experienced surgeon, who has a precise knowledge of the anatomy of the lateral nasal wall and skull base. The frontal sinus outflow tract has a complex and variable anatomy. It is tightly situated between the orbit and the anterior skull base at an angle that makes visualization difficult from an intranasal approach. Objective: This paper has an objective to describe our frontal recess and sinus approach surgical technique, presenting the concept of the “vertical bar”.

METHODS: Cadaver dissections were performed in order to assure our frontal sinus endoscopic surgical access.

RESULTS: The “vertical bar” was found in all dissections.

CONCLUSIONS: We described our frontal sinus approach technique and the concept of the “vertical bar”. This technique can help surgeons in the identification of the frontal sinus and recess, providing a safe and predictable access to this challenging region.

ABSTRACT NUMBER: 1592

NASAL OUTCOMES AFTER NOVEL BINOSTRIL APPROACH FOR ENDOSCOPIC PITUITARY SURGERY WITH SEPTAL PRESERVATION

Joao Nogueira, MD, Aldo Stamm, PhD

BACKGROUND: Endoscopic Pituitary Surgery is a well established technique for the treatment of sellar tumors. For its location, the pituitary gland is well accessed through the nasal cavity and sphenoid sinus, and several endoscopic approaches had been described: transnasal direct, transeptal, modified transeptal, and transnasal/transeptal binostril.

OBJECTIVE: The objective of our work is to report the nasal outcomes of patients who underwent to endoscopic pituitary surgery using the transeptal/transnasal binostril technique. Methods: A review of 22 datasheets elaborated to describe the most common nasal complaints of patients submitted to endoscopic pituitary surgery using the transeptal/transnasal binostril technique from May 2007 and February 2008 in Sao Paulo, Brazil.

RESULTS: Our series consisted of 15 females (68%) and 7 males (32%) with age between 19 and 70 years old. Nine patients (41%) did not have any nose related complaints. Eleven patients (50%) presented nasal obstruction, mainly for crusts, granulation tissue and clots that required debridement and suction at the office. Two (9%) patients presented nasal bleeding at the first week after the discharge. No patients presented signs of infection, nasal synechia or CFS leaks.

CONCLUSION: The most common nasal complaint in the postoperative assessment in our series was a transitory nasal obstruction in 50% of the patients. After analysis of the results we can conclude that the transnasal/transeptal binostril technique allows a minimum postoperative nasal morbidity allowing the conservation of the natural anatomy and physiology of the nasal cavity.

ABSTRACT NUMBER: 1656

NASAL TURBINATE VIDEOENDOSCOPIC SURGERY

Stefano Millarelli, M.D., Massimiliano Del Ninno, M.D., Gianluca Bellocchi, M.D.

The possibility of carrying out videoassisted nasal surgery under local anesthesia is due to the improvement of anesthesiological techniques and the miniaturisation of instruments. This technique gives us an ideal visualization of the area to be operated on and so can be done with complete ease and therefore obtain better results. In the last two years we have performed nasal turbinate reduction with radiofrequency on 150 patients using the traditional method. Results were very good with only a small percentage of complications. 15 patients underwent surgery using videoendoscopy and on 4 of them we used the microdebrider. In this group there were no complications. This method is based on an adequate selection of patients and well established surgical timing. The results for this method are without doubt better the traditional one.

ABSTRACT NUMBER: 1686

AN EFFECTIVE TECHNIQUE FOR ENDOSCOPIC RESECTION OF ANGIOFIBROMA

Mojtaba Mohammadi Ardehali, Seyed-Hadi Samimi, Mehdi Bakhshaei

INTRODUCTION: Recently surgical management of angiofibroma has been greatly influenced by endoscopic techniques. However, large tumor which extent into difficult anatomic sites presents major challenges for its management by either endoscopy or the open approach. By further refinement of surgical techniques and instrumentation, most of these tumors will be amenable to endoscopic removal.

METHODS AND MATERIALS: We introduced a simple endoscopic transnasal technique for the resection of angiofibroma via pushing and pulling the mass by 1/10000 soaked adrenalin tampons. 47 patients treated using this endoscopic technique through 7 years. Mean follow up period was 33 months. The staging, average blood losses, complications, length of hospitalization, residual, and/or recurrent rate of tumor were the main outcomes, measured.

RESULTS: According to Radkowski staging 5, 10, 3, 3, 22, 3, and one patient were at stage IA, IB, IIA, IIB, IIC, IIIA, and IIIB respectively. 43 cases were operated exclusively via transnasal endoscopy while 4 patients were managed endoscopic assisted. Embolization was performed only in 5 (10.64 %) cases. Mean blood loss in patients with and without embolization were 770 cc and 1403cc, respectively. Recurrence rate was 19.1% (9 cases). Mean hospitalization was 2.55 days. Complications included 2 cheek paresthesia, 2 epiphora, one transient II, III and VI cranial nerves weakness, 2 cases of cavernous sinus rupture.

CONCLUSION: Using this effective technique, endoscopic removal of even more advanced angiofibroma is possible. Better visualization, less intraoperative blood loss, lower rate of complication and recurrence and shorter hospitalization are some of the advantages.

ABSTRACT NUMBER: 1712

TRANSNASAL ENDOSCOPIC DRAINAGE OF A PETROUS APEX CHOLESTEROL GRANULOMA

Jeffrey Suh, MD, Marvin Bersneider, MD, Rinaldo Canalis, MD, Marilene Wang, MD

INTRODUCTION: Lesions of the petrous apex are traditionally resected via transcranial or transmastoid approaches. Here we describe a patient with a petrous apex cholesterol granuloma who underwent successful transnasal endoscopic drainage. The purpose of this study is to illustrate this minimally invasive approach to petrous apex, along with the relevant skull base anatomy.

METHODS: Case report

RESULTS: A 58 year-old man had a history of a cholesterol granuloma of the left petrous apex that was drained previously via a transzygomatic infratemporal approach. He presented with recurrent headaches and hearing loss, and was found to have recurrence of the granuloma in the petrous apex on MR and CT imaging. The patient underwent transnasal endoscopic drainage of the granuloma with the assistance of intraoperative image guidance and placement of a tympanostomy tube. A drain from the petrous apex to the nasal cavity was sutured to the septum and left in place for several weeks. Final pathology confirmed the diagnosis of a cholesterol granuloma.

CONCLUSIONS: Lesions of the petrous apex have traditionally been removed through transcranial or transmastoid approaches. The endoscopic transnasal approach offers an effective minimally invasive method to approach select lesions of the petrous apex.

ABSTRACT NUMBER: 1725

ENDOSCOPIC MANAGEMENT OF JUVENILE NASOPHARYNGEAL ANGIOFIBROMA

Teresa Oliveira Matos, Joana Filipe, João Subtil, Paulo Borges Dinis

Juvenile nasopharyngeal angiofibroma is a rare, tumour-like, vascular malformation of the nasopharynx, almost exclusive to adolescent males, that arises from the sphenopalatine foramen. Angiography is an important tool in diagnosis and a significant number of surgeons advocate the systematic pre-operative embolization of the lesion as a mandatory first step in the surgical management of the pathology, in order to reduce intra-operative bleeding. Embolization is, however, not without its risks, and surgeons working at centers with imaging departments that are less familiar with the procedure, certainly welcome surgical tips that may reduce intra-operative bleeding and eventually dispense embolization, altogether.

We present on video, in a Fish type 2 angiofibroma case with important pterygopalatine fossa invasion, a totally endoscopic technique in which tumour resection was preceded by the endonasal trans-antral ligation of the internal maxillary artery, with immediate impact on intra-operative bleeding, thus showing that embolization can be effectively dispensed. At the same time the endoscopic pterygopalatine fossa dissection itself is invaluable in the management of the tumour invasion at this particular site.

ABSTRACT NUMBER: 1781

THE ENDOSCOPIC PERICRANIAL FLAP FOR ENDOSCOPIC ANTERIOR SKULL BASE RECONSTRUCTION: A TECHNICAL REPORT

Adam Zanation, MD, Carl Snyderman, MD, Ricardo Carrau, MD, Amin Kassam, MD

INTRODUCTION: Vascularized tissue reconstruction has become a standard for endoscopic skull base reconstruction. The nasoseptal flap is now the workhorse due to its size, availability in the operative field and its reliable vascular pedicle. There are times however, often during sinonasal tumor or revision cases, that the nasoseptal flap is not available. Due to this situation a novel endoscopic pericranial flap was conceived. This report demonstrates the techniques, limitations and effectiveness of an endoscopically harvested pedicled pericranial flap during reconstruction of anterior skull base defects.

STUDY DESIGN/METHODS: Operative Technique Description with Intraoperative Videos.

RESULTS: A technical description and clinical outcomes of the first endoscopic pericranial flap skull base reconstructions in an 80 years old patient with an endoscopically resected Kadish C Esthesioneuroblastoma are described. This patient had excellent intranasal healing and no postoperative CSF leak. She also underwent post-operative radiotherapy without subsequent flap complications. There was no facial nerve (CN 7) or trigeminal nerve (CN 5) dysfunction. Radioanatomic dimensions, particularly the area required to reconstruct an anterior skull base defect, are also described.

CONCLUSIONS: Minimally invasive endonasal surgical techniques for skull base tumor removal are novel. While reconstruction has often lagged behind the ablative techniques for skull base surgery, the emerging use of the vascular pedicled nasoseptal flap has reduced CSF leak rates to less than 5%. However, anterior skull base defects from tumors such as esthesioneuroblastomas test the limits of endonasal reconstruction since nasoseptal tissue is often involved with tumor. A novel, endoscopic approach to harvesting the well-known and versatile pericranial flap has been performed with good result and provides another option for reconstruction of large anterior skull base defects.

ABSTRACT NUMBER: 1881

USE OF DEXAMETHASONE ON THE PROPHYLAXIS OF NAUSEA & VOMITING AFTER ESS

Mohannad Al-Qudah, MD, Yaser Al-Rashdan, MD

INTRODUCTION: Endoscopic sinus surgery (ESS) is a common otolaryngology operation that has been proven to be effective procedure in management chronic rhinosinusitis. Literature examining outcomes following ESS has focused exclusively on longer-term outcomes. Early recovery and complications such as nausea & vomiting (N & V) are still largely unexplored. Dexamethasone is effective medication in preventing N & V associated with chemotherapy as well as different surgical procedures. However this has never been tested in patients undergoing ESS. The objectives of this study were to determine the incidence and severity of postoperative N & V after ESS and to evaluate the efficacy and safety of dexamethasone in N& V management in adult patients undergoing ESS.

METHOD: After obtaining the approval of our hospital's research and human ethics committee, written informed consents were obtained from 62 consecutive adult patients, ASA (American Society of Anesthesiologists) physical status I or II, undergoing general anesthesia for elective ESS. Patient under 16 year old or those who had previous systemic steroid treatment for more than 3 months at any time or within 1 month before randomization were excluded, Patients with grade 3 nasal polyposis were also excluded. No premedication was given to the patients. When the patient arrived in the operating room, baseline hemodynamic data were recorded after placement of routine monitors. All patient were anaesthetized in a standard way. Patients were randomly divided into two groups, group 1 received 8 mg (2 mL) dexamethasone intravenously; group 2 received 2 mL saline intravenously. Randomization was performed using a table of random numbers and sealed envelopes. The patients and the investigators who collected the postoperative data were unaware of the content of the syringes. ESS was performed by using standard ESS technique. Surgery progresses anatomically in a stepwise manner. Sphenoidotomy and frontal recess opening were performed in selected cases when computer tomography scan showed diseased sinuses. Upon completion of surgery, surgicell was placed into the middle meatus to help prevent synechiae, nasal pack was not inserted routinely. Postoperatively, patients were observed for 24 hours. The data of nausea and vomiting were collected every 4 hours, except when patients were asleep, by direct questioning by trained resident on the ward or by spontaneous complaint of the patients. Vomiting that occurred more than three times within 24 hours was considered as severe vomiting. The time when the patients had their first meal after surgery was also reported. The occurrence of side effects accompanying dexamethasone use during hospital stay or follow up visits was recorded. Data were analyzed using appropriate statically tests. A P value less than.05 was considered significant.

RESULT: All 62 patients completed the study. The subject's characteristics (e.g., age, weight, and gender), duration of anesthesia and surgery were similar between the two groups. The incidence of nausea and vomiting was 30 % in group 1 compared to 60% in group 2, this was statistically significant. 4 patients in group 2 had severe vomiting compared to none in the dexamethasone group, this was also statistically significant. Patients in group 1 had their first meal 3.5 hour average after surgery compared to 4.5 in the control group, again this was statistically significant. No patients reported wound infection, delayed wound healing, GI bleeding or glucose intolerance.

CONCLUSION: N & V are relatively common complication during early recovery after ESS. Prophylactic intravenous administration of 8 mg dexamethasone significantly reduces the incidence of postoperative N & V in patients undergoing ESS with out complications.

ABSTRACT NUMBER: 1883

ENDOSCOPIC ENDONASAL REPAIR OF ORBITAL BLOW-OUT FRACTURE

Shoji Matsne, MD, Kousuke Yoshifuku, MD, Tamon Hayashi, MD, Yuichi Kurono, MD

BACKGROUND: Orbital blow-out fracture is a common result of facial trauma. Enophthalmos, diplopia resulting from extraocular muscle dysfunction may occur. The indication as well as timing for surgical approach have been under debate. While endoscopic endonasal treatment is now quite common for the medial wall fracture among otolaryngologists, three approaches, at least, are now evolved to access to the orbital floor; traditional transmaxilla, transconjunctiva with subciliary incision and endoscopic endonasal approach. In this seminar, we would like to show our endoscopic endonasal technique for the orbital floor fracture as well as the medial wall fracture with the aid of video presentation.

MATERIAL AND METHODS: Orbital blow-out fracture cases of the floor type as well as the medial wall type were treated by the endoscopic endonasal approach. Chief complains of these cases were diplopia and enophthalmos. In order to access to the orbital floor endonasally, the unchinate process and the bulla lamella were removed and opened the fontanelle adequately under general anesthesia. With observation under 70-degree rigid endoscope, fractured bony wall was confirmed and removed carefully without damaging herniated orbital soft tissue. The balloon was inserted endonasally into maxilla and sustained the prolapsing tissue put into orbita. Postoperative course were assessed clinically.

RESULTS: Not only in cases of medial wall fracture but also in the floor fracture cases, diplopia was improved without postoperative complication.

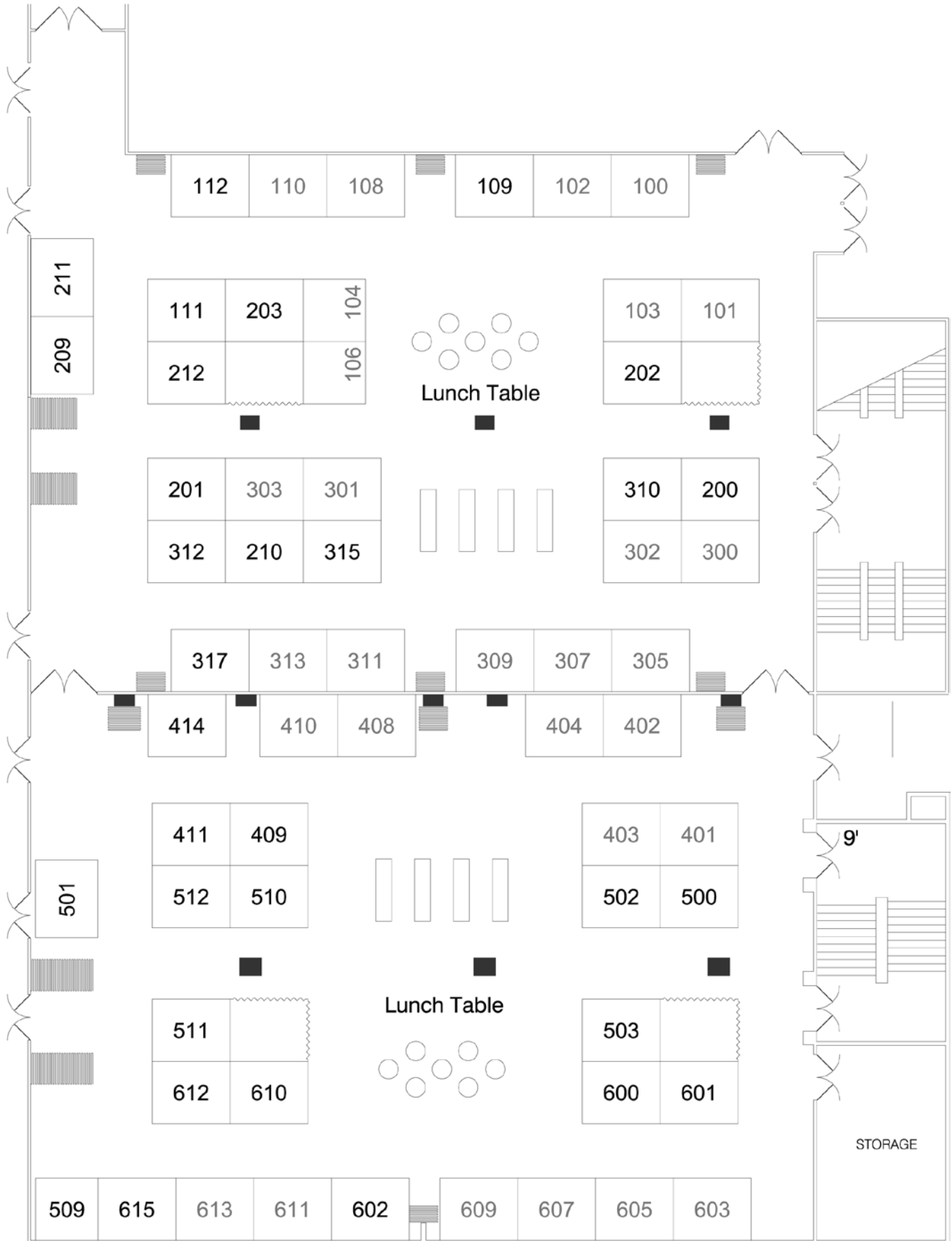CONCLUSION: Endoscopic endonasal approach for orbital blow-out fracture is quite useful technique not only in cases of medial wall fracture but also in the floor fracture type.

Exhibitor Floor List

BOOTH NUMBER	COMPANY
305/307/309	Acclarent
212	All-American Allergy Alternatives, LLC
203	Allergychoices, Inc.
511	Allergy Laboratories, Inc.
209	American Academy of Otolaryngology– Head and Neck Surgery
509	American Journal of Rhinology & Allergy
502	Antigen Laboratories
408/410	ArthroCare ENT
310	ASL Pharmacy/Sinus Science
500	Bien Air Surgery
607/609	Bionorica AG
612	Boston Medical Products
603/605	BrainLab
315	Commonwealth Medical Labs
112	Ellman International
611/613	Entellus Medical, Inc.
601	ENT Today
301/303	Entrigue Surgical, Inc.
317	Ethicon, A Johnson & Johnson Company
202	Eyemaginations
402/404	GE Healthcare
101/103	Gyrus ACMI
501	Hanson Medical, Inc.

BOOTH NUMBER	COMPANY
111	Hartington Pharmaceutical, S.L.
600	Healthworld
211	IAPO Interamerican Association of Pediatric Otorhinolaryngology
503	Instrumentarium
201	ICACTL Intersocietal Commission for Accreditation
300/302	KayPentax
610	Lippincott Williams & Wilkins
409	Longtek Scientific Co. Ltd.
108/110	Meda Pharmaceuticals
312	Medical Digital Developers
602	MediCapture
104/106	Medtronic ENT
210	Mosby/Saunders/Elsevier
510	NeilMed Pharmaceuticals
200	Parnell Pharmaceuticals, Inc.
414	Penn Medicine (Physician Liaisons)
401/403	Karl Storz Endoscopy-America, Inc.
411	Sinus Dynamics
311/313	Stryker
109	Synthes CMF
615	TechWorld Corporation, Inc.
512	Richard Wolf Medical Instruments
100/102	Xoran Technologies

Exhibitor Floor Plan • Freedom/Independence Ballroom



Visit us
at Booth 408/410

a clear improvement in sinus surgery



Coblation® assisted
sinus surgery (CASS)

PROcise™ EZ View Sinus Wand: A Precise and Versatile Device that Optimizes Sinus Surgery

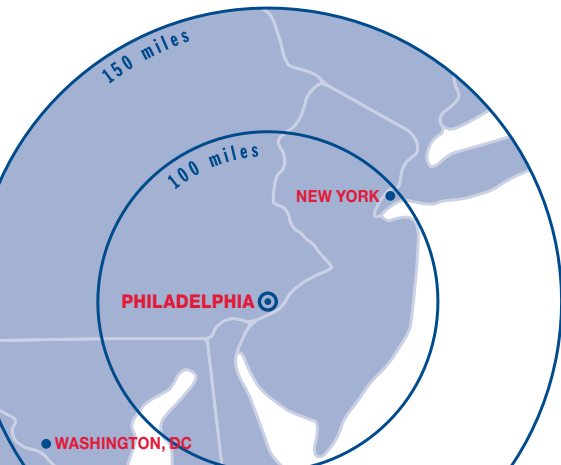
- Integrated ablation, suction, and bipolar hemostasis in a single device
- Clear access to target tissue in a virtually bloodless operating field
- Ergonomic instrument enhances flexibility and precision during sinus surgery

A Clear Improvement in Sinus Surgery



www.ArthroCareENT.com

© 2009 ArthroCare Corporation. All rights reserved. Coblation and PROcise EZ View are registered trademarks of ArthroCare Corporation.



April 15-19, 2009

Sheraton Philadelphia City Center Hotel and
Four Seasons Hotel

www.rhinologyworld.com

Driving Directions to Sheraton Philadelphia City Center Hotel and Conference Center

17th and Race Street • Philadelphia, PA 19103

Phone: 215-448-2000 • Fax: 215-448-2853

From West

Take the Pennsylvania Turnpike to Exit 24. Proceed on Highway 76 East to Exit 344. Continue to the Broad Street/Central Philadelphia Exit. Turn right onto 15th Street and proceed one block to Spring Street and turn right. Continue 1 block to 16th Street and turn right. The hotel is located 0.25 blocks down on the left.

From East

Take the New Jersey Turnpike to Exit 4. Proceed on Highway 73 North to Highway 38 West. Continue to Highway 30 West over the Benjamin Franklin Bridge. After crossing the bridge, continue on Vine Street and turn left onto 17th Street. The hotel is located 1 block further on the left.

From Interstate 95 South (North/South)

Take Interstate 95 South to Exit 22. Proceed on Highway 676 West to the Broad Street Exit; this will take you to 15th Street. Continue 0.5 blocks to Spring Street and turn right. Proceed 1 block and turn right onto 16th Street; the hotel is 0.25 blocks further on the left.

From Philadelphia International Airport

Go North on Phila Intl Airport, toward the Parking Lot. Phila Intl Airport becomes a ramp. Merge onto PA-291/Penrose Avenue. Turn left onto PA-291/S. 26th Street and stay straight to go onto I-76 W./Schuylkill Expressway West. Take the 30th Street exit toward the Train Station. Turn right onto Chestnut Street. Turn left onto S. 22nd Street. Turn right onto PA-3/Market Street. Turn right onto S. 17th Street.

