Autoimmune Cytopenias: Diagnosis & Management

CHRISTIAN P. NIXON, MD, PhD; JOSEPH D. SWEENEY, MD

ABSTRACT

The autoimmune cytopenias are a related group of disorders in which differentiated hematopoietic cells are destroyed by the immune system. Single lineage disease is characterized by the production of autoantibodies against red cells (autoimmune hemolytic anemia [AIHA]), platelets (autoimmune thrombocytopenia [ITP]) and neutrophils (autoimmune neutropenia [AIN]) whereas multilineage disease may include various combinations of these conditions. Central to the genesis of this disease is the breakdown of central and/or peripheral tolerance, and the subsequent production of autoantibodies by both tissue and circulating self-reactive B lymphocytes with support from T helper lymphocytes. These disorders are classified as primary (idiopathic) or secondary, the latter associated with an underlying malignancy, systemic autoimmune disease, infectious disease or a specific drug. Non-specific immunosuppression with corticosteroids remains the first-line therapy for many of these disorders, and although associated with high response rates, is compromised by significant toxicity and high relapse rates. Management of patients with chronic refractory autoimmune cytopenias who have failed first-line and second-line (cytotoxic immunosuppressant therapy and or splenectomy) is particularly complex, with definitive treatment in select patients requiring hematopoietic stem cell transplantation. Given the toxicity concerns of non-selective immunosuppressants, development of therapeutic regimens that avoid steroids has progressed rapidly in recent decades.

KEYWORDS: autoimmune cytopenias, WAIHA, CAD, ITP, AIN

INTRODUCTION

Failure to maintain self-tolerance is the dominant pathophysiologic mechanism binding the autoimmune cytopenias, a group of disorders characterized by the immune mediated destruction of differentiated hematopoietic cells. Central tolerance is governed by apoptosis of autoreactive cells upon binding to self-antigen (negative selection), which occurs early in B and T cell differentiation in the bone marrow and thymus, respectively. In contrast, the active process of peripheral tolerance, is driven by CD4+/CD25+ regulatory T cells (Tregs) and CD8+ suppressor T lymphocytes which maintain anergy or suppression against self-antigens. (1) Numerous mechanisms to account for central and peripheral tolerance breakdown in the context of autoimmune cytopenias have been proposed. The emergence of "forbidden clones" as proposed by Burnett more than sixty years ago, (2) hinges on the persistence of self-reactive clones that should have been deleted via central tolerance, and may play a role in autoimmunity seen in lymphoproliferative diseases or polyclonal lymphocyte activation in viral infection. Molecular mimicry in the context of viral, bacterial and mycoplasma infections may also result in the initiation and acceleration of autoimmunity due to the presence of common antigenic epitopes in proteins and carbohydrates, particularly on the surface of red blood cells. (3) Additional mechanisms to account for the failure to maintain self tolerance include neo-antigen generation by environmental agents or drugs, as observed in drug-induced AIHA, (4) and immunoregulatory disturbances stemming from the alteration of cytokine networks. Interestingly, although autoimmunity is commonly thought to arise from the interplay between environmental factors and genetic predisposition, the HLA linkages documented for various organ and systemic autoimmune diseases such as type-1 insulin-dependent diabetes, pemphigus vulgaris, systemic lupus erythematosus, rheumatoid arthritis, etc., have not yet been clearly demonstrated for the autoimmune cytopenias.

AUTOIMMUNE HEMOLYTIC ANEMIAS

Pathogenesis

Autoimmune hemolytic anemia (AIHA) is defined by the destruction of mature red blood cells (RBCs) by anti-RBC autoantibodies produced by autoreactive B lymphocytes facilitated as otherwise by complement. Autoantibodies can result in erythrocyte destruction via numerous mechanisms including; a) phagocytosis of erythrocytes opsonized by autoantibodies and complement by activated macrophages, b) direct erythrocyte osmotic lysis through complement fixation and sequential activation of the membrane attack complex (MAC), and c) antibody-dependent cell-mediated cytotoxicity (ADCC) mediated by cytotoxic CD8+ T cells and natural killer (NK) cells that carry membrane receptors for the Fc portion of bound immunoglobulin G (IgG). ADCC and erythrophagocytosis preferentially occur in the

spleen and lymphoid organs, whereas complement mediated destruction is primarily intravascular or occurs in the liver. AIHAs are divided into warm and cold types according to the thermal characteristics (reactivity at 37°C or 4°C) of the predominant autoantibody formed, which in large part is predicated on the antibody class (IgG versus IgM), and the chemical characteristics of the epitope (protein or carbohydrate).

Table 1. The Autoimmune Cytopenias

Disorder	Clinical Features	Laboratory Tests	Treatment
Warm Autoimmune Hemolytic Anemia	Fatigue, jaundice	CBC, MCV, reticulocyte count, bilirubin, haptoglobin, LDH, haptoglobin, direct Coomb's test (IgG ± C3), blood smear examination for spherocytes	Steroids Splenectomy Erythropoiesis-stimulating agents (ESA) Rituximab
Cold Autoimmune Hemolytic Anemia	Fatigue, jaundice, passage of brown urine induced by cold	CBC, direct Coomb's test (C3+/IgG-), blood smear examination for agglutination, spherocytes or erythrophagocytosis (Figure 1)	RBC transfusion Chlorambucil Cyclosporine Rituximab
Autoimmune Thrombocytopenia	Bruising, bleeding from mucosal surfaces	Platelet count, antigen-specific autoantibody assays, blood smear examination to exclude pseudothrombocytopenia and confirm large platelets	Steroids Splenectomy Rituximab IVIG Thrombopoeitin (TPO) mimetics
Autoimmune Neutropenia	Recurrent infections	Total white cell, differential and neutrophil count	G-CSF

WARM AUTOIMMUNE HEMOLYTIC ANEMIA

Clinical Features & Laboratory Findings

Optimal reactivity of the autoantibody at 37°C (mainly IgG1 and IgG3 subclass), defines warm autoimmune hemolytic anemia (WAIHA) which can affect all age groups and accounts for 80-90% of adult cases of AIHA. Clinical and laboratory features are shown in **Table 1**. In vivo binding of antibody and/or complement to the red blood cell (RBC) surface can be detected in a direct Coomb's or antiglobulin test (DAT). In nearly half of all WAIHA cases, these pan-reactive autoantibodies exhibit specificity for Rh protein epitopes. (5)

Management

Transfusion of allogeneic red cells for rapid symptomatic improvement of hypoxic anemia along with controlled non-specific immunosuppression with pharmacologic doses of corticosteroids represents front-line therapy. Initial hemoglobin stabilization and prompt symptomatic improvement is observed in up to 70–80% of patients. However, disease relapse after steroid-induced remission is common. (6) Corticosteroid non-responders can be managed with other non-specific immunosuppressants such as cyclosporin A, azathioprine and cyclophosphamide. (7) Although splenectomy has played a dominant historical role in the management of WAIHA, with the first series of patients (n = 28) described by Chertkow and Dacie in 1955, (8) data regarding durable remission remains unclear with an approximate response rate of 38-70% in patients with WAIHA. (9) Recombinant erythropoiesis-stimulating agents (ESA) represent an alternative promising treatment modality that may be more widely employed in the future, (10,11) and high dose IVIG, although less successful than in ITP, may be efficacious in some non-responder cases. (12)

Targeted therapy with Rituximab, a potent, humanized monoclonal antibody directed against CD20 on pre-B cells, mature B lymphocytes, and immature plasma cells, has been increasingly used as second-line therapy in relapsed or refractory cases. Binding of rituximab to CD20-positive cells results in B-lymphocyte depletion via a combination of apoptosis, complement activation and antibody-dependent cell cytotoxicity. (13) Small case series have supported the efficacy and safety of this drug in children and adults with WAIHA with durable responses of up to 3 years. (14,15) Response rates of 33–s77% with complete remission in 29–55% have been reported in an evidence-based focused review, (16) with the beneficial effect greatest in neonates and children compared to adult patients with WAIHA. (14,15,17) Long-term side effects remain to be explored, yet mild infusion reactions including hypotension and fever are the most common complications of rituximab with a very low incidence of serious infection. (18) A battery of additional treatment modalities in various stages of the investigational and licensure pipeline include such drugs as alemtuzumab (anti-CD52), bortezumib, kinase inhibitors and IgG-specific endoglycosidase EndoS. (19-22)

COLD ANTIBODY AUTOIMMUNE HEMOLYTIC ANEMIAS

Pathogenesis

Cold antibody autoimmune hemolytic anemias are serologically characterized by autoantibodies with optimal reactivity at 4°C, with the majority of cases being either cold agglutinin syndrome (CAS) or paroxysmal cold hemoglobinuria (PCH). The autoantibodies in primary CAS are monoclonal IgM, and polyclonal IgM in secondary CAS due to infectious diseases such as Mycoplasma pneumonaie and infectious mononucleosis. The polyclonal antibodies produced in response to these infections typically demonstrate specificity to the RBC blood group antigens I and i, respectively. The antibody specificity in PCH is a polyclonal IgG immunoglobulin directed toward the P blood group antigen.

This bi-phasic hemolysin (Donath-Landsteiner antibody) reacts with RBCs in the peripheral circulation when the temperature drops below 20°C, and initiates complement fixation. Upon returning to the warmer central circulation, complement mediated erythrocyte osmotic lysis ensues. (23)

Clinical Features & Laboratory Findings

Clinical features are shown in **Table 1**. CAS typically manifests as moderate chronic hemolytic anemia in middle-aged or elderly patients, often with cold exacerbation of signs (acrocyanosis of the extremities), splenomegaly, anemia and mild jaundice. Prognosis is generally fair although significant mortality has been described. (24) PCH is characterized clinically by acute hemolytic anemia often with hemoglobinuria, predominantly in children with a history of a recent viral illness. Although PCH typically follows a mercurial, acute, often severe course, prognosis is excellent with the majority of cases spontaneously resolving within a few days to several weeks following onset. The direct Coomb's test will be positive for complement (C3) and negative for IgG. Erythrophagocytosis of complement sensitized cells can be observed in the peripheral blood films of up to 80% of young children with acute transient PCH (**Figure 1**).

Figure 1. Peripheral blood smear of a biphasic hemolysin positive case of paroxysmal cold hemoglobinuria (PCH) in a four-year-old child, exhibiting prominent monocytic erythrophagocytosis with occasional spherocytes.

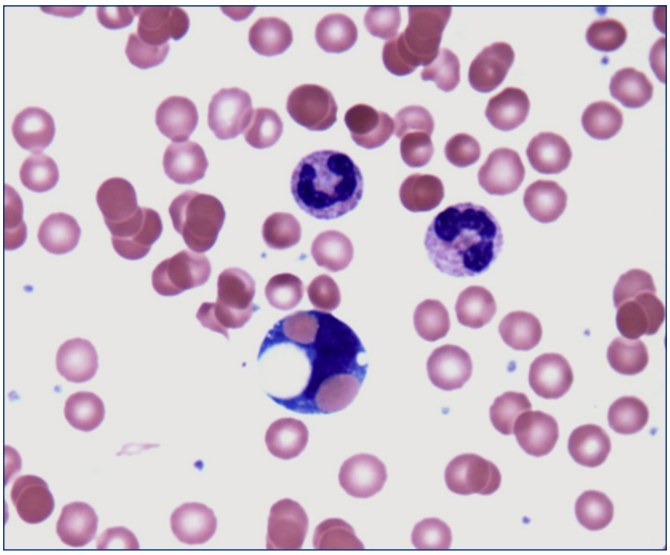

Management

Cold exposure avoidance, red cell transfusion for hypoxic anemia, and immunosuppression with the alkylating agents chlorambucil and/or cyclophosphamide represent front-line therapy for CAS. B lymphocyte depletion with rituximab to remove the pathologic clonal B cells, has been investigated in case reports, small retrospective series and phase 2 trials. (25,26) In these studies, rituximab monotherapy achieved partial responses in greater than 50% of patients with CAS, complete responses in 5% and disease improvement in those who had previously received rituximab. However, median duration response of 11 months and failure rates of 40-50% remain impediments to universal implementation of this drug in the treatment of CAS. In PCH, the severe acute intravascular hemolysis (**Figure 2**), may necessitate transfusion of red blood cells along with supportive care provided in a heated room.

Figure 2. Three plasma samples collected from the same patient with PCH at 0 (A), 3 days (B), and 4 days (C) after admission. Hemoglobinemia resulting from intravascular hemolysis is most readily apparent in the plasma sample collected on presentation (day 0), which quickly resolved in the ensuing week. Hemoglobin concentrations (mg/dL): A = 83; B = 43; C = 28 (normal < 2 mg/dL).



AUTOIMMUNE THROMBOCYTOPENIA

Pathogenesis

Immune mediated destruction of platelets along with attenuated platelet production characterize ITP (27) which is mediated in part by anti-platelet IgG and T-cell subset abnormalities. (28,29) Using antigen-specific assays that measure autoantibodies capable of binding to platelet surface glycoproteins, anti-platelet autoantibodies can be detected in only 50-60% of ITP patients. (30) A limited number of B-cell clones produce these antiplatelet antibodies as a result of antigen-driven somatic mutation. (31) Platelets coated with autoantibody are cleared in the reticuloendothelial system by phagocytosis and possibly complement-mediated lysis. (32) Hepatic clearance of platelets by an anti-GPIb-IX mediated Fc-independent mechanism involving the Ashwell-Morell receptor may also occur. (33) Furthermore, the lack of autoantibodies in many ITP patients has led to the discovery that cytotoxic CD8+ T lymphocytes can lyse platelets in vitro and impair megakaryocyte function. (34)

Clinical Features & Laboratory Findings

Autoimmune thrombocytopenia (ITP) is the most common of the autoimmune cytopenias with an incidence of five out of 100,000 children per year and two out of 100,000 per year in adults. ITP may be primary, secondary to autoimmune disease, infection (CMV, HIV, Hepatitis C, Helicobacter pylori) and malignancy, drugs (35) or occur in association

with AIHA (Evan's syndrome). Common clinical features are listed in **Table 1**. Adults tend to run a chronic course, whereas shorter disease duration (approximately 6 months) and much higher spontaneous remission rates occur in children. Bone marrow biopsy indicated in patients > 60 years of age to exclude an underlying B cell malignancy may reveal normal or increased megakaryopoiesis. (36)

Management

Corticosteroid taper and intravenous immunoglobulin represent front line therapy for ITP, with approximately 70-80% response rate in newly-diagnosed, previously untreated ITP patients. (37) However, recurrence of thrombocytopenia in the majority of patients, necessitates additional intervention. Optimal second line therapy remains uncertain, although traditionally splenectomy for steroid refractory patients has been employed at the risk of post-operative complications and 1% mortality due to septicemia. (38) High-dose dexamethasone instead of prednisone has been advocated in adults as a different strategy to avoid second-line therapy altogether. Numerous alternative strategies such as B-cell depletion with the monoclonal antibody rituximab, anti-D immunoglobulin, thrombopoiesis-stimulating agents and Fc receptor blockade have been investigated. Retrospective and prospective single-arm trials have shown a beneficial effect of rituximab therapy in adult and childhood ITP, (39) which may be boosted with combinatorial regimes involving rituximab and dexamethasone, (40) or even triple therapy with the inclusion of cyclosporine (TT4). (41) Rapid platelet responses have been observed with the thrombopoeitin (TPO) receptor agonists (romiplostim and eltrombopag), although medication discontinuation is often followed by a platelet count drop to pretreatment levels. (42,43) In non-splenectomized Rhesus positive individuals with ITP, anti-D immunoglobulin therapy may be similarly efficacious as conventional treatments through the saturation of macrophage Fc receptors by opsonized red blood cells. (44) Targeted Fc receptor blockade with monovalent anti-Fcγ receptor/albumin fusion proteins and/or neutralization of autoimmune IgG Fc by soluble FcγRs is also being pursued. (45,46) Inhibition of platelet glycoprotein desialylation with the antiviral sialidase inhibitor, oseltamivir phosphate, has resulted in significant platelet count increases in anti-GP1b autoantibody positive chronic ITP patients refractory to all other conventional therapies, representing a promising antigen specific area of future research. (47) Platelet transfusion is usually reserved only for patients with acute life-threatening bleeding (retinal or intracranial hemorrhage) due to the rapid clearance of infused platelets.

AUTOIMMUNE NEUTROPENIA

Pathogenesis

Autoantibodies directed against neutrophils are primarily responsible for the rare entity autoimmune neutropenia (AIN). AIN be primary or secondary to viral infections, drug-induced mechanisms, hematological malignancies such as large granular lymphocyte leukemia, autoimmune diseases and primary immune deficiency syndromes. Antigens in the polymorphic human neutrophil antigen system (HNA), particularly HNA-1 and HNA-4, located on the FcγRIIIb (CD16) and CD11b molecules respectively, are the primary targets of anti-neutrophils antibodies which can be demonstrate in up to 70% of cases. (48) Cell-mediated destruction of granulocytes may also occur due to inhibitory CD8+ cytotoxic T-cells present within the marrow space.

Clinical Features & Laboratory Findings

As with other autoimmune cytopenias, the natural history of AIN varies between children and adults, with a relatively benign course and spontaneous remission within 6-24 months commonly occurring in children, in contrast to a more pronounced, chronic course in adults. Upper respiratory tract infections, skin sepsis, recurrent fevers, otitis media in children and chronic tiredness in adults may all be presenting signs.

Management

Front line therapy with recombinant human granulocyte colony stimulating factor (rhG-CSF) can be used in the immediate treatment of severe infections as well as for infection prophylaxis at a decreased dosing schedule. (49) Immunosuppression, intravenous immunoglobulin and splenectomy have produced variable to disappointing results in the treatment of AIN. Rituximab likewise, has met with limited efficacy in this disorder, presumably due to the central role of the inhibitory CD8+ cytotoxic T cells. (50)

SUMMARY

Immune mediated destruction of hematopoietic cells characterize the autoimmune cytopenias. The complexity of these cases indicate that referral to a hematologist is indicated in nearly all cases. Viral infections, autoimmune diseases, drugs, solid tumors and hematopoietic malignancies underlie many of the cases of secondary autoimmune cytopenias. Natural history variation between children and adults generally predicts higher rates of spontaneous remission and shorter disease duration in children. Non-specific immunosuppression with corticosteroids represents front-line therapy for many of these disorders yet active investigation into steroid sparing regimes has uncovered multiple new treatment modalities. Notably, autoreactive B lymphocyte depletion via targeted therapy with the humanized, chimeric monoclonal anti-CD20 antibody, rituximab, has provided durable responses in AIHA and ITP, whereas the mammalian target of rapamycin inhibitor, sirolimus, may provided safe and efficacious mono-therapy treatment for patients with refractory autoimmune multilineage cytopenias. (51) Recombinant erythropoiesis-stimulating agents may in the future become standard therapy in WAIHA, and newly vetted targets to treat ITP include monovalent Fc receptor blockade and combinatorial therapy including rituximab, dexamethasone, thrombopoietin receptor analogues and cyclosporine.

References

1. Abbas AK, Lichtman AH, Pillai S. Cellular and Molecular Immunology, Philadelphia, Saunders, 2012.
2. Burnett FM. A reassessment of the forbidden clone hypothesis of autoimmune disease. *Aust J Exp Biol Med Sci* 1972;50:1-9.
3. Fagiolo E. Immunological tolerance loss vs. erythrocyte self antigens and cytokine network dysregulation in autoimmune hemolytic anaemia. *Autoimmun Rev* 2004;3:53-9.
4. Salama A. Drug-induced hemolytic anemia. *Expert Opin Drug Saf* 2009;8:73-79.
5. Vos GH, Petz L, Funenberg HH. Specificity of acquired haemolytic anaemia autoantibodies and their serological characteristics. *Br. J Haematol* 1970;19:57-66.
6. Petz LD. Treatment of autoimmune hemolytic anemias. *Curr Opin Hematol* 2001;8:411-6.
7. Elebute M, Marsh J. Autoimmune cytopenias. *Medicine* 2009;37:159-163.
8. Chertkow G, Dacie JV. Results of splenectomy in autoimmune haemolytic anemia. *Br J Haematol* 1956;2:237-49.
9. Salama A. Treatment options for primary autoimmune hemolytic anemia; A short comprehensive review. Transfus Med Hemother 2015;42:294-301.
10. Sinclair AM. Erythropoiesis stimulating agents: approaches to modulate activity. *Biologics* 2013;7:161-74.
11. Salama A, Hartnack D, Lindemann HW, Lange HJ, Rummel M, Loew A. The effect of erythropoiesis-stimulating agents in patients with therapy-refractory autoimmune hemolytic anemia. *Transfus Med Hemother* 2014;41:462-8.
12. Bussel JB, Cunningham-Rundles C, Abraham C. Intravenous treatment of autoimmune hemolytic anemia with very high dose gammaglobulin. *Vox Sang* 1986;51:264-69.
13. Reff ME, Carner K, Chambers KS, Chinn PC, Leonard JE, Raab R, Newman RA, Hanna N, Anderson DR. Depletion of B cells in vivo by a chimeric mouse human monoclonal antibody to CD20. *Blood* 1994;83:435-45.
14. Zecca M, Nobili B, Ramenghi U, Perrotta S, Amendola G, Rosito P, et al. Rituximab of the treatment of refractory autoimmune hemolytic anemia in children. *Blood* 2003;101:3857-61.
15. D'Arena G, Califano C, Annunziata M, Tartarone A, Capalbo S, Villani O, et al. Rituximab for warm-type idiopathic autoimmune hemolytic anemia: a retrospective study of 11 adult patients. *Eur J Haematol* 2007;79:53-8.
16. Crowther M, Chan YL, Garbett IK, Lim W, Vickers MA, Crowther MA. Evidence-based focused review of the treatment of idiopathic warm immune hemolytic anemia in adults. *Blood* 2011;118:4036-40.
17. Svahn J, Fioredda F, Calvillo M, Molinari AC, et al. Rituximab-based immunosuppression for autoimmune haemolytic anaemia in infants. *Br J Haematol* 2009;145:96-100.
18. Newman K, Owlia MB, El-Hemaidi I, Akhtari M. Management of immune cytopenias in patients with systemic lupus erythematosus-old and new. *Autoimmunity Reviews* 2013;12:784-91.
19. Cheung WW, Hwang GY, Tse E, Kwong YL. Alemtuzumab induced complete remission of autoimmune hemolytic anemia refractory to corticosteroids, splenectomy and rituximab. *Haematologica* 2006;91:ECR13.
20. Dasanu CA. Bortezomib: friend or foe of hemolytic anemia? *J Oncol Pharm Pract* 2011;17:233-5.

References 21–51

Authors

Christian P. Nixon, MD, PhD, Center for International Health Research, Rhode Island Hospital and Alpert Medical School of Brown University, Providence, RI.

Joseph D. Sweeney, MD, Department of Transfusion Medicine, Rhode Island Hospital and The Miriam Hospital, Alpert Medical School of Brown University, Providence, RI.

Conflicts of Interest

None.

Funding

Christian P. Nixon, MD, PhD, is funded by NIGMS Exploratory Grant # 1P20GM104317-01

Correspondence

Christian P. Nixon, MD, PhD
Center for International Health Research,
Rhode Island Hospital
593 Eddy St.
Providence, RI, 02903
401-444-3164
Fax 401-444-7854
cnixon@lifespan.org