

MENINGIOMA CORDOIDE MAS ANEMIA  
HIPOCROMICA MICROCÍTICA

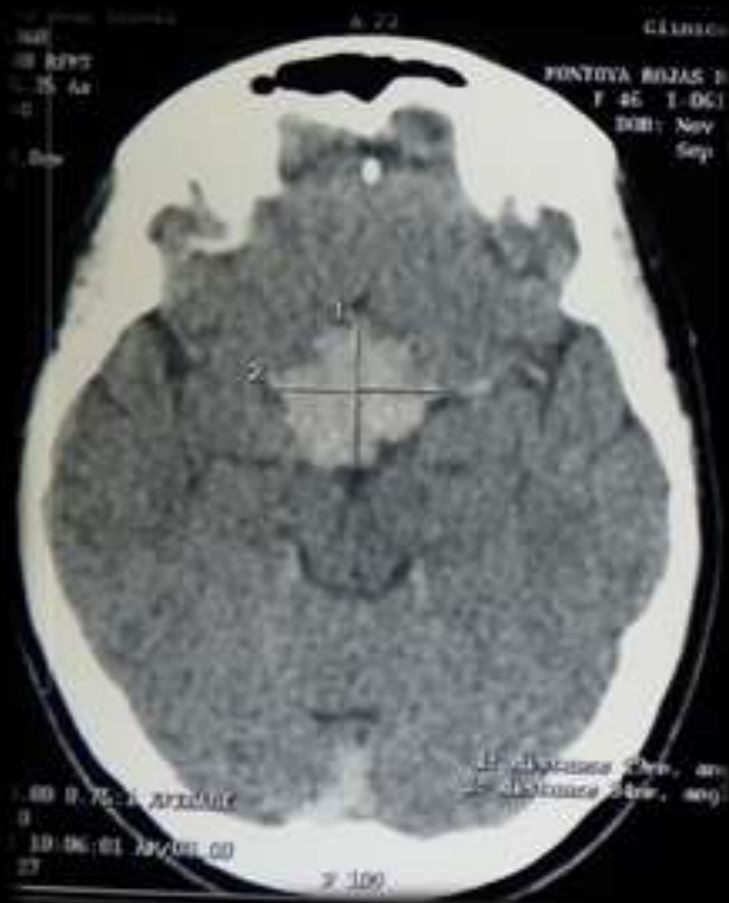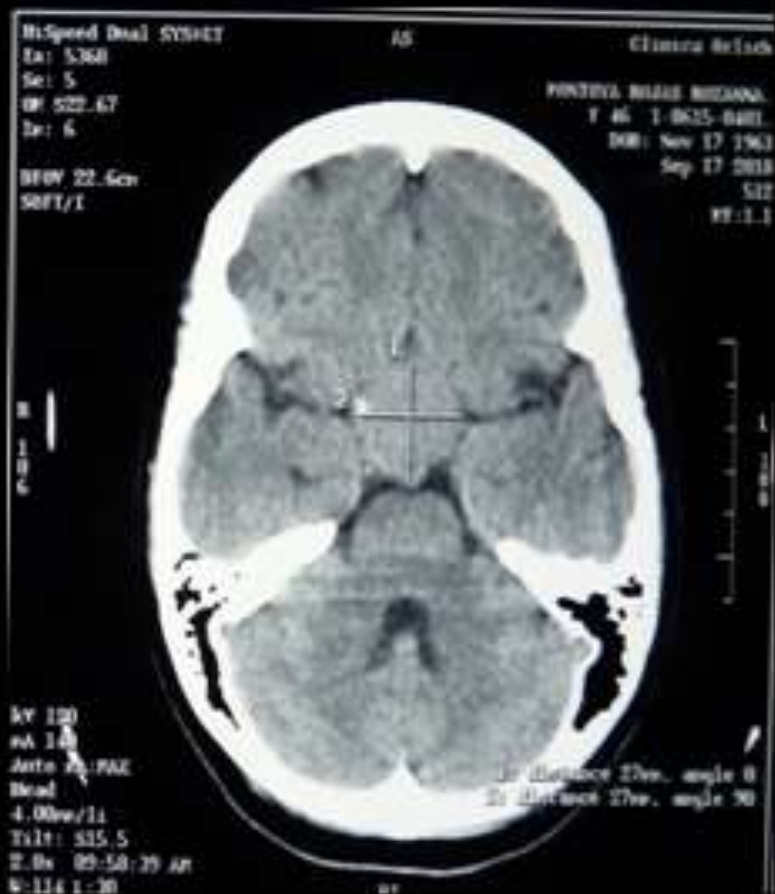DR FERNANDO ALVARADO ACOSTA  
HOSPITAL MÉXICO. CCSS  
UNIVERSIDAD DE COSTA RICA.  
SAN JOSÉ . COSTA RICA.

# Meningioma cordoide más anemia microcítica hipocrómica

- Femenina de 47 años, cuadro clínico de seis meses de evolución de disminución de la agudeza visual, fotofobia, cefalea bifrontal y hemianopsia bitemporal, Examen de laboratorio mostró anemia microcítica hipocrómica (hierro sérico 13, ferritina 2.5, transferrina 384, saturación de transferrina 2%. Estudios de TAC y resonancia magnética mostraron una lesión espacio ocupante sellar y supraselar .

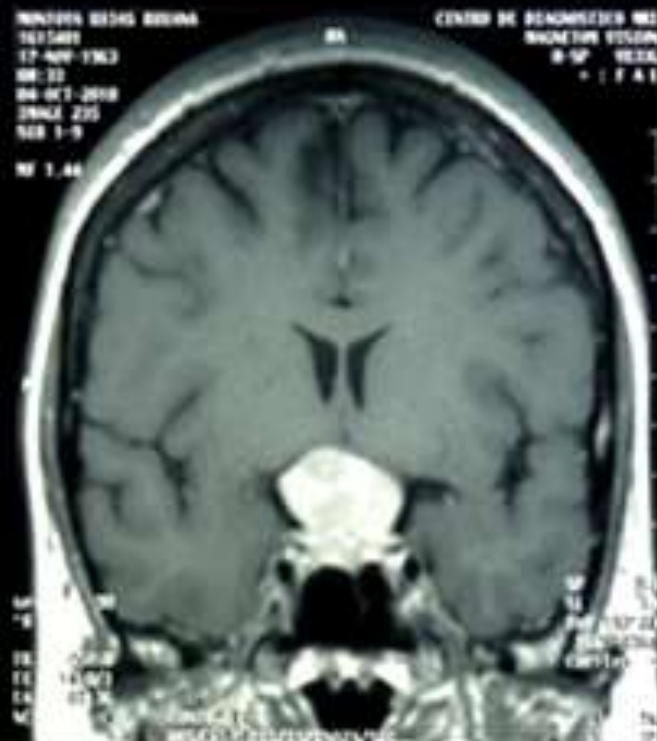
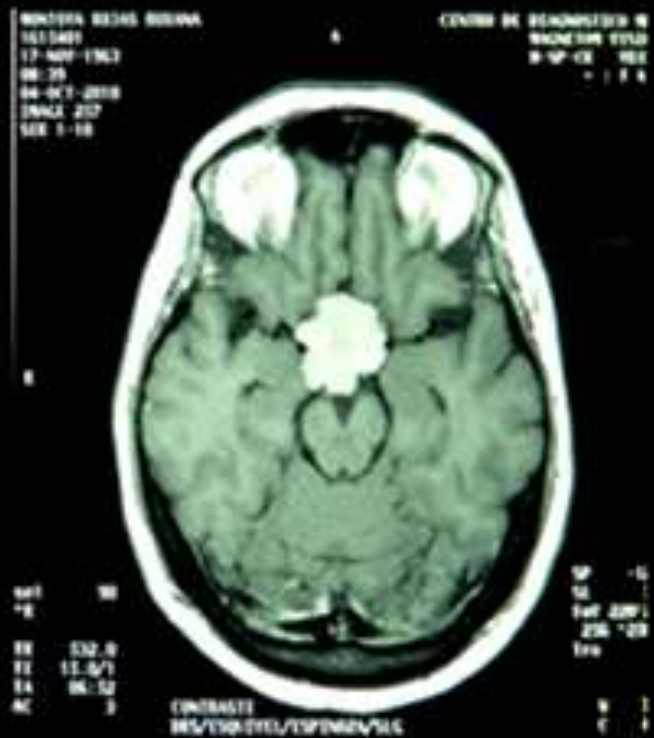R.M.R.

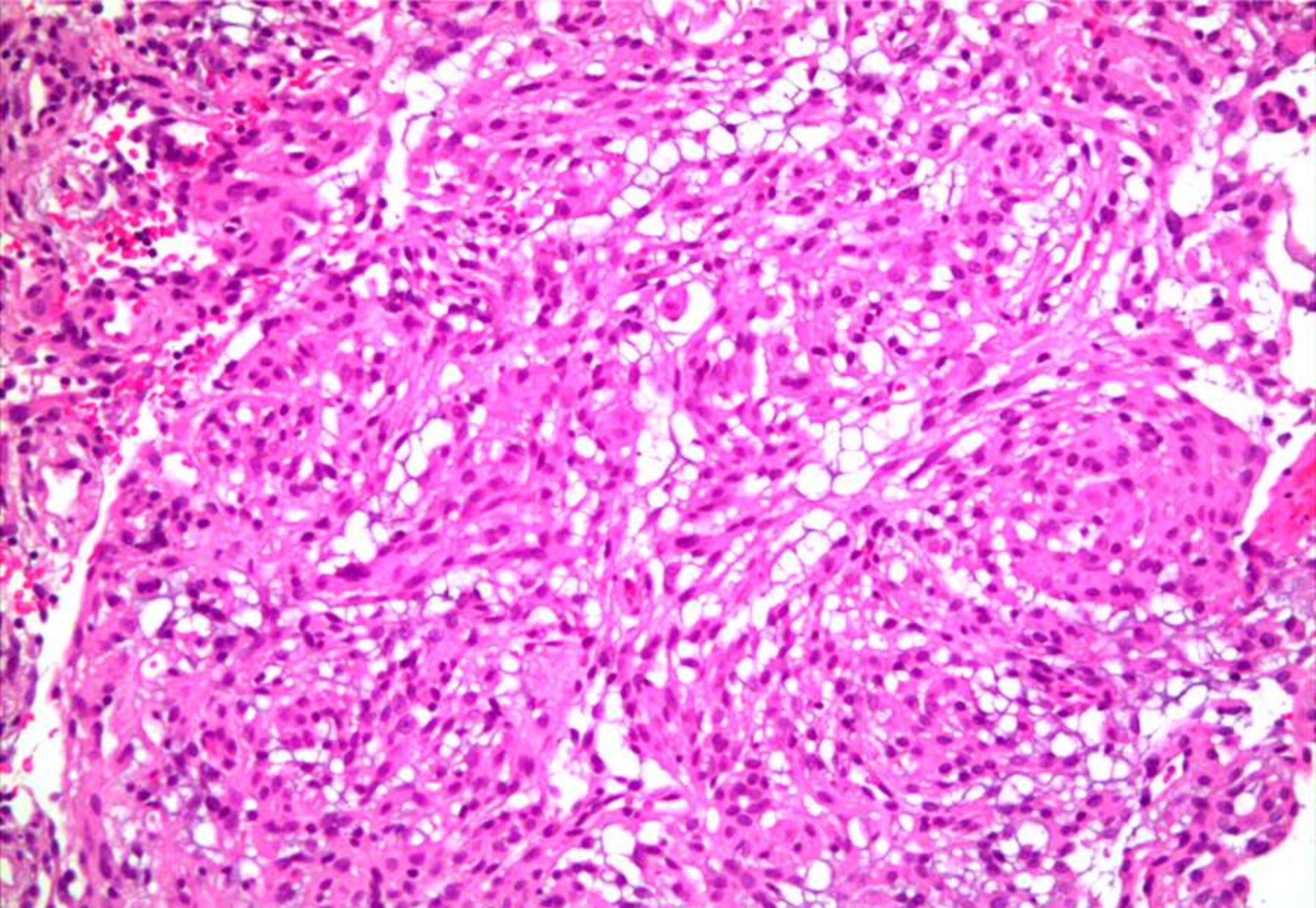
TAC 17/09/10



R.M.R.

IRM 04/10/10

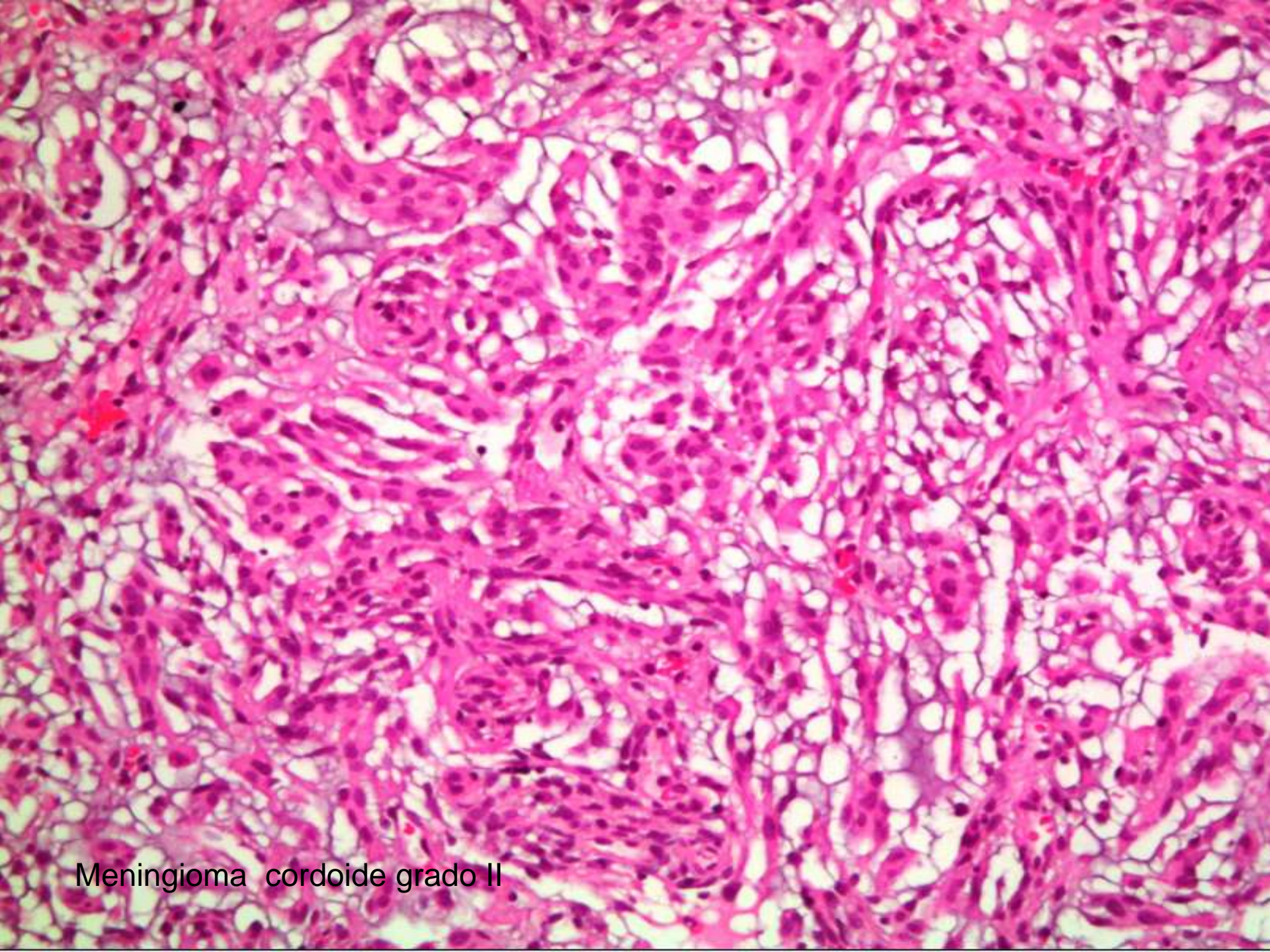




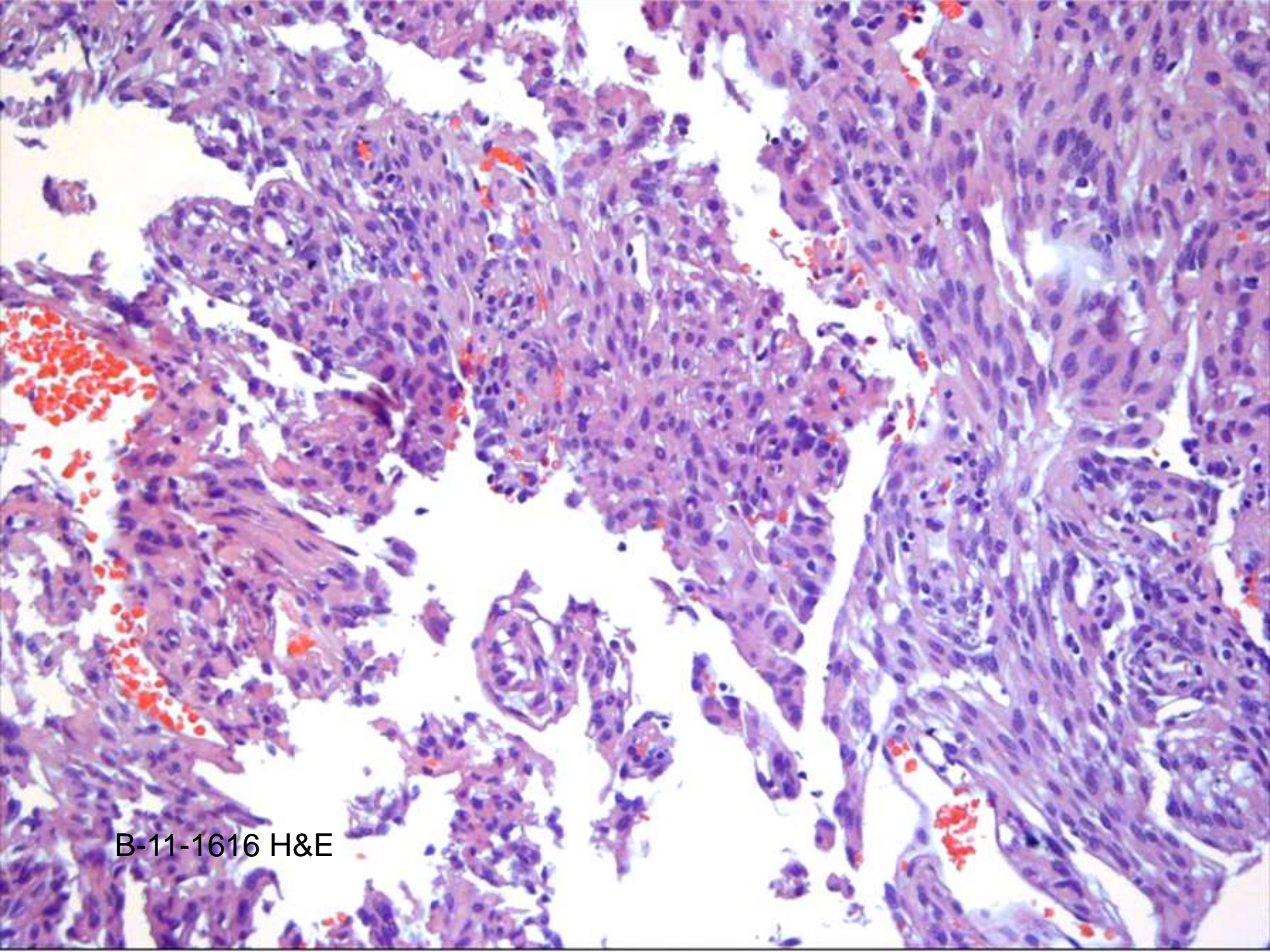
Meningioma cordoide grado II

B 11-01616

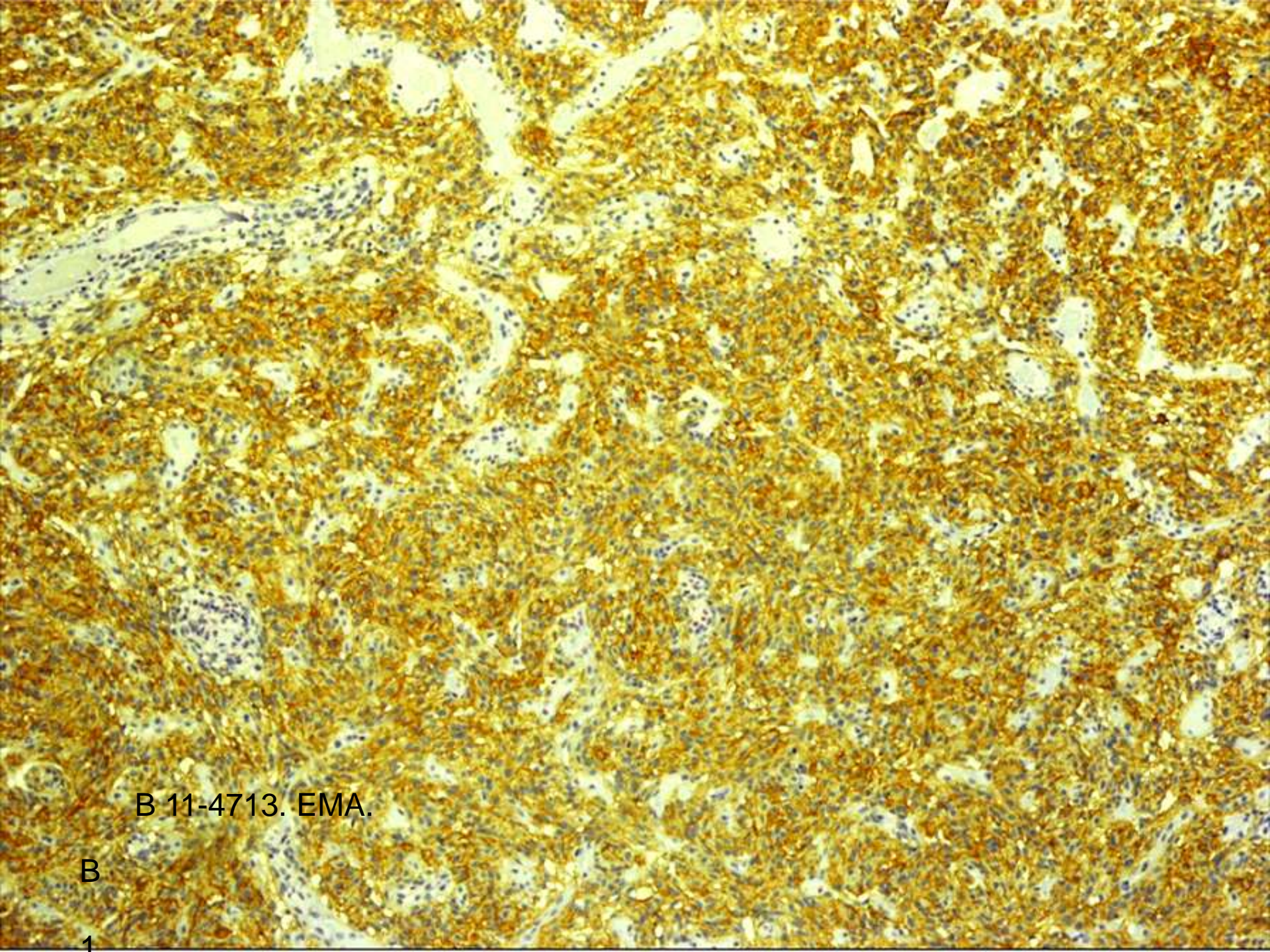
H&E



Meningioma cordoide grado II



B-11-1616 H&E

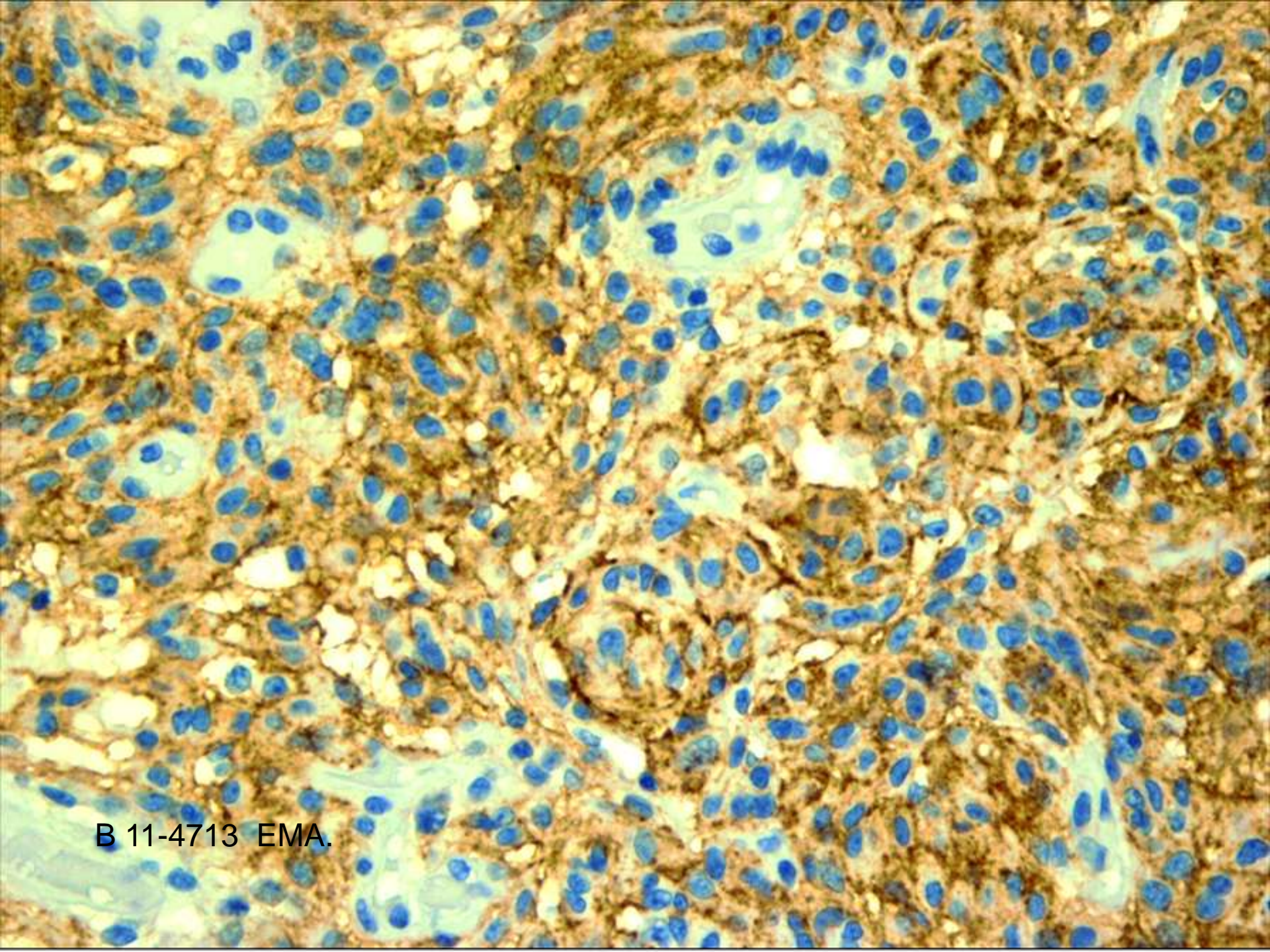


B 11-4713. EMA.

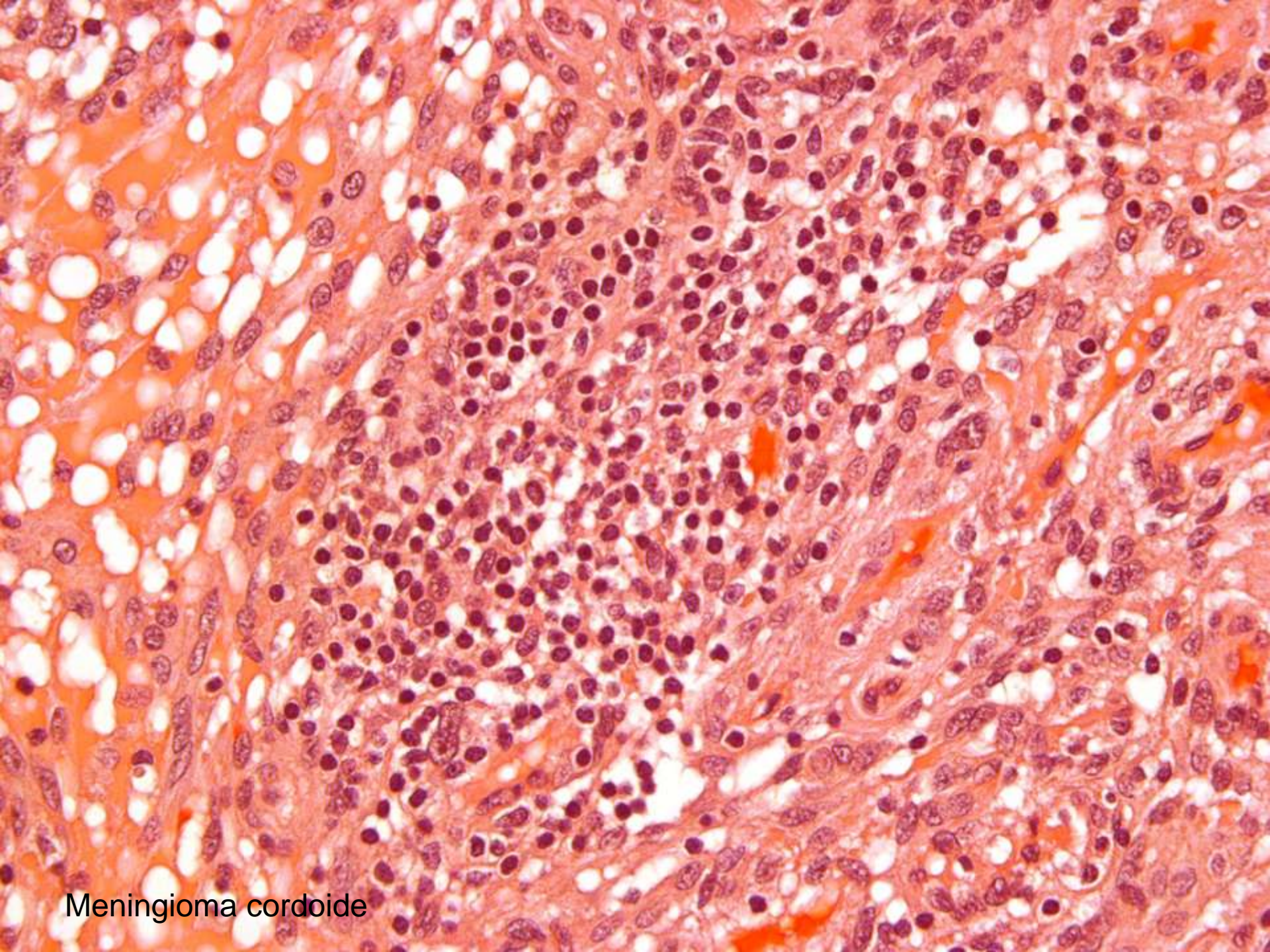
B

1



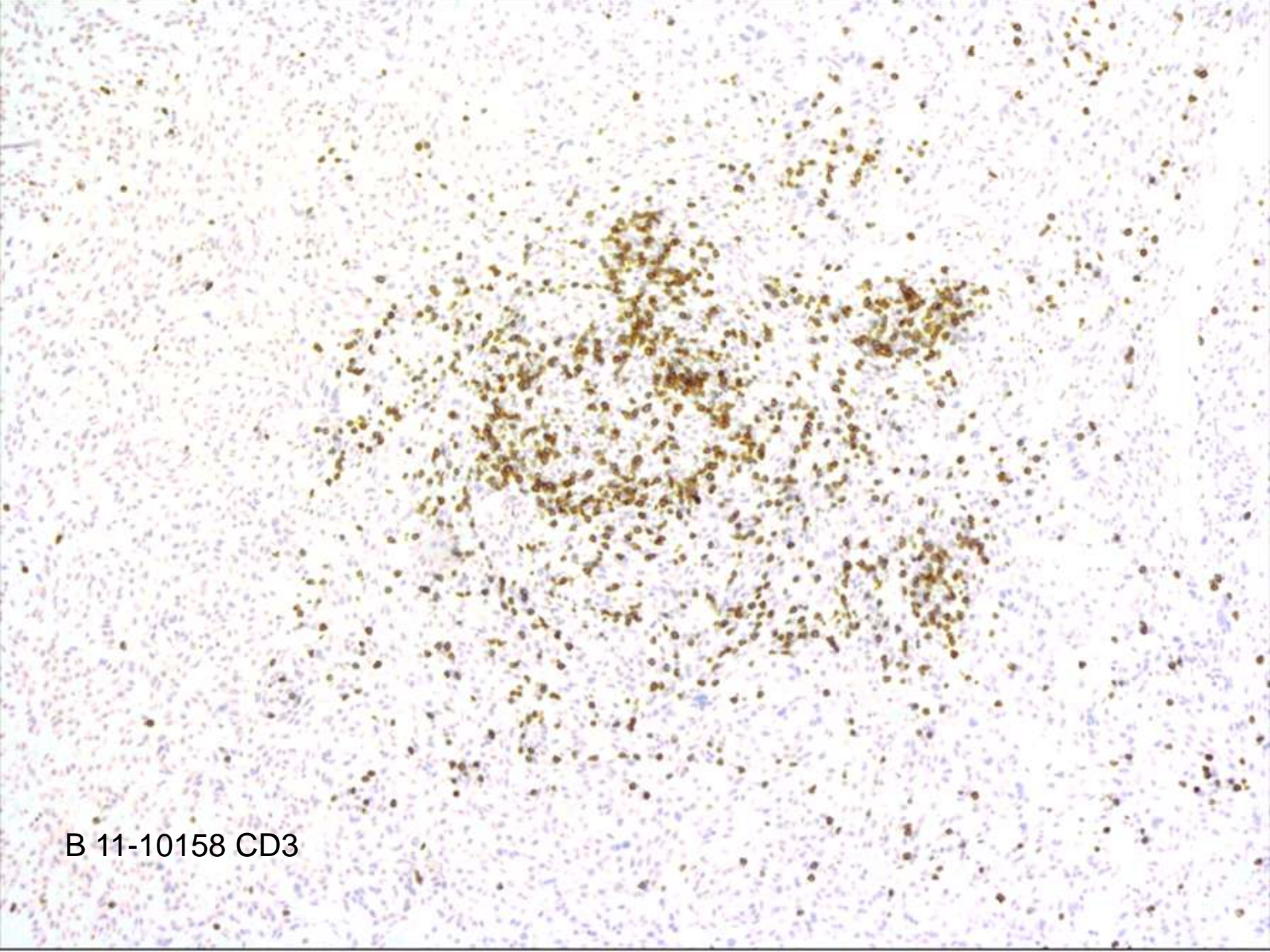


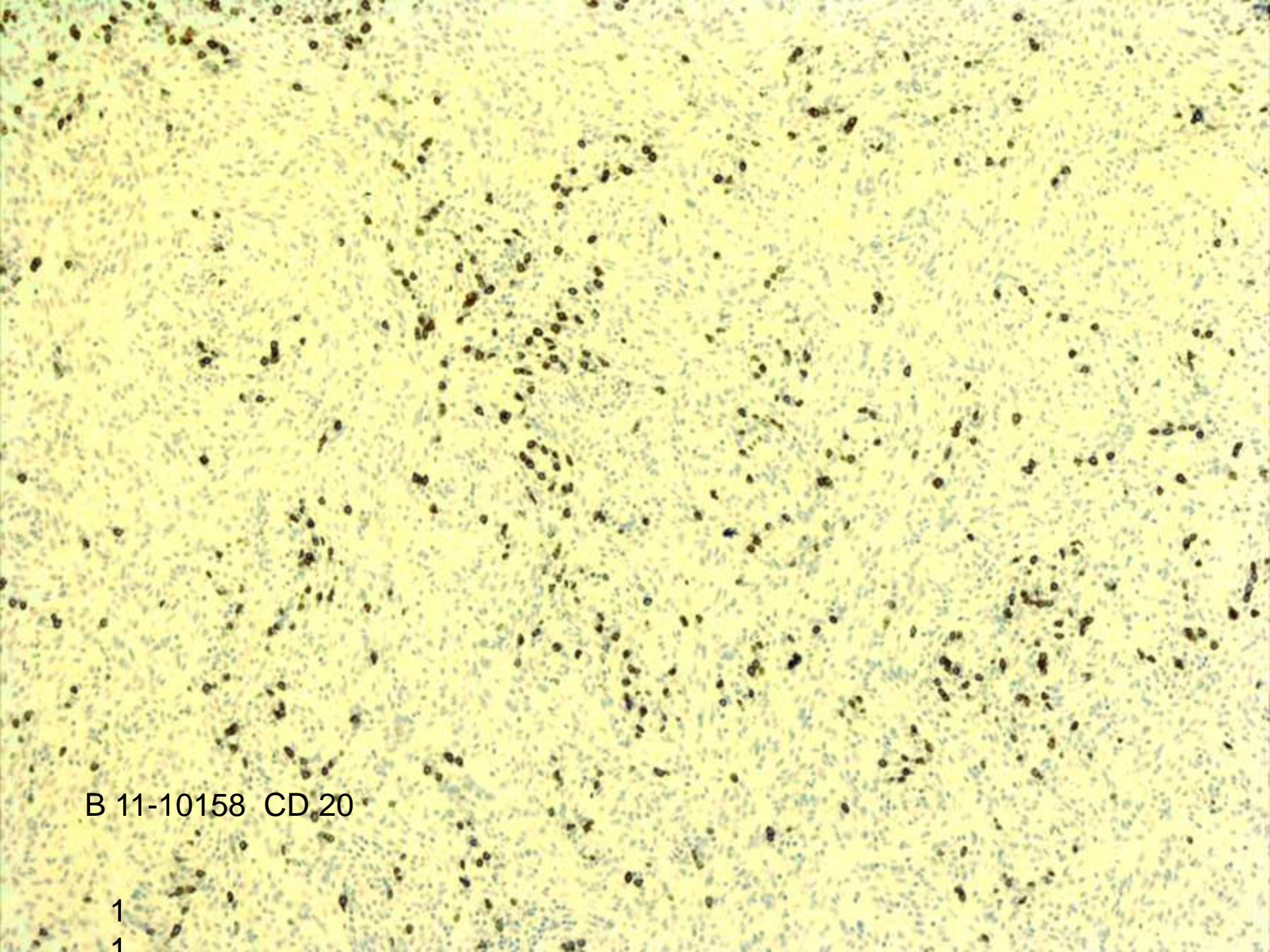
B 11-4713 EMA.



Meningioma cordoide

B 11-10158 CD3





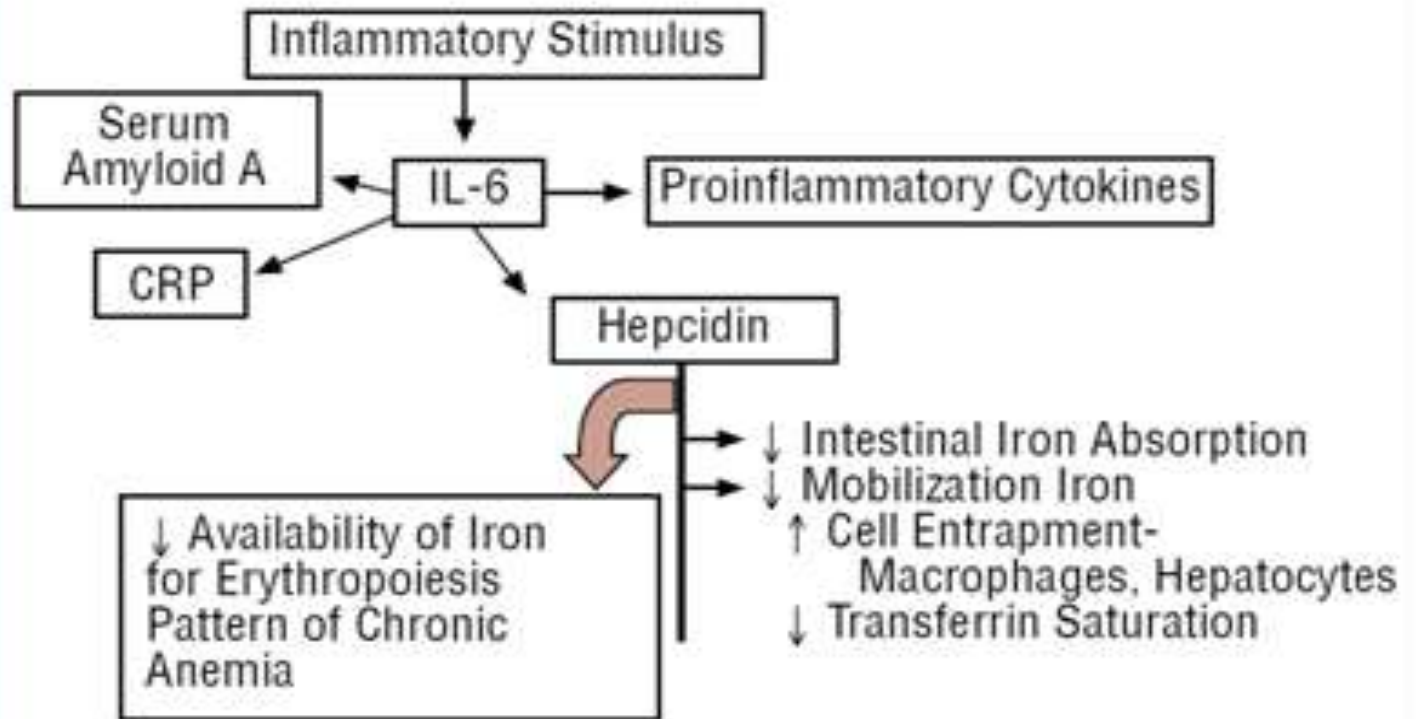
B 11-10158 CD 20

1

1

B 11-9582 Ki-67.

# IL-6



Caramelo et al. Anemia in Heart Failure: Pathophysiology, Pathogenesis, Treatment, and Incognitae. *Rev Esp Cardiol. Madrid* 2007;60:848-60.

Arlet J et al. Iron-deficiency anemia in Castleman disease: implication of the interleukin 6/hepcidin pathway. *Pediatrics*. 2010 Dec;126(6):e1608-12.

TABLE 1

*Published cases of chordoid meningioma\**

Authors & Year	No. of Cases	Age (yrs)	Feature	Tumor Location
Kepes, et al., 1988	7	8-19	anemia	intracranial
Glasier, et al., 1993	1	15	anemia	intracranial
Zuppan, et al., 1994	1	10	no CS	NA
Kumar, et al., 1996	1	5	NA	NA
Civit, et al., 1997	1	21	NA	intracranial
Kobata, et al., 1998	1	15	anemia	intracranial
Kajiwara, 1999	1	52	NA	intracranial
Couce, et al., 2000	42	12-77 (2 children)	no CS	41 of 42 intracranial 1 of 42 cervical spine
Yano, et al., 2000	1	44	no CS	intracranial
Lee, et al., 2001	1	55	gammopathy	intracranial
Mori, et al., 2001	1	62	no CS	intracranial
de Tella, et al., 2003	2	19 & 52	NA	intracranial

\* CS = Castleman syndrome; NA = not applicable.

TABLE 1

*Synopsis of chordoid meningiomas reported in the literature\**

Authors & Year	No. of Patients	Mean Age in Yrs (range)	Associated Manifestations
Kepes, et al., 1988	7	14.7 (8–19)	anemia
Glaiser, et al., 1993	1	15	NA
Zuppan, et al., 1994	1	10	none
Kumar, et al., 1996	1	5	NA
Civit, et al., 1997	1	21	anemia, fever, elevated ESR
Kobata, et al., 1998	1	15	anemia
Kajiwara, et al., 1999	1	52	none
Shino, et al., 1999	1	NA	NA
Couce, et al., 2000	42	47.4 (12–77)	none
Yano, et al., 2000	1	44	none
Lee, et al., 2001	1	55	increased gamma-globulinemia
Mori, et al., 2001	1	62	none
de Tella, et al., 2003	2	52 & 19	none
Varma, et al., 2003	2	20 & 33	elevated ESR in 1 patient
Yeon, et al., 2003	1	33	none
Inagawa, et al., 2004	1	57	none
Salinero, et al., 2004	1	45	none
Soo, et al., 2004	1	60	none

\* NA= not available.

Denaro L et al. Pyrogenic cytokine interleukin-6 expression by a chordoid meningioma in an adult with a systemic inflammatory syndrome. *J Neurosurg* 103:555–558, 2005



# BIBLIOGRAFIA

- Arlet J et al. Iron-deficiency anemia in Castleman disease: implication of the interleukin 6/hepcidin pathway. *Pediatrics*. 2010 Dec;126(6):e1608-12.
- Arima T et al. Intraventricular chordoid meningioma presenting with Castleman disease due to overproduction of interleukin-6. *J Neurosurg* 102:733–737, 2005
- Caramelo et al. Anemia in Heart Failure: Pathophysiology, Pathogenesis, Treatment, and Incognitae. *Rev Esp Cardiol*. 2007;60:848-60.

# BIBLIOGRAFIA

- Connors M. Growth and maturation arrest, hypochromic anemia and hyperglobulinemia associated with a brain tumor. West J Med 133:160-163, Aug 1980
- Couce ME, Aker FV, Scheithauer BW. Chordoid meningioma: A clinico-pathologic study of 42 cases. Am J Surg Pathol 2000; 24: 899-905
- Cui et al. Iron-Refractory Iron Deficiency Anemia: New Molecular Mechanisms. Kidney Int. 2009 December ; 76(11): 1137–1141.

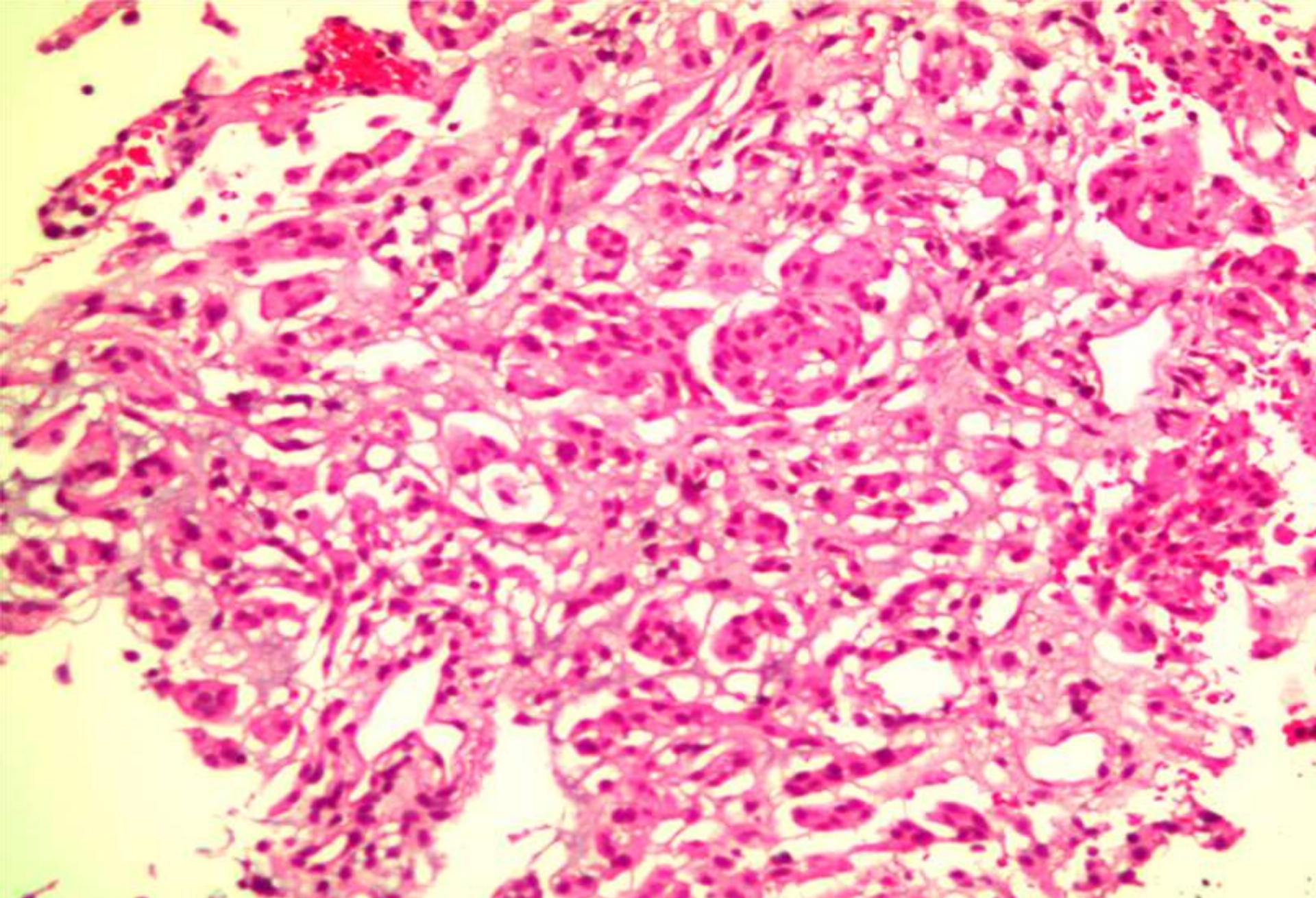
# BIBLIOGRAFIA

- Liu A et al. Chordoid meningioma: a report of two cases Chin Med J 2007; 120 (8): 726-728
- Serrano R; Acevedo A. Meningioma cordoide. A propósito de un caso y revisión de la literatura. Rev Esp Patol 2007; Vol 40, n.º 4: 243-246
- Song K et al. Third ventricle chordoid meningioma. J Neurosurg Pediatrics 2:269–272, 2008
- De Tella O et al. Chordoid meningioma. Arq Neuropsiquiatr. Brazil. 2003;61(1):91-94
- Yeon J et al. Chordoid meningioma. J Korean Med Sci 2003; 18: 768-71

# Bibliografía.

- Julio Escalona Zapata, Aurelio Ariza, Francisco Cruz Sánchez. Curso corto Clasificación de los tumores del Sistema Nervioso Central.

• FIN

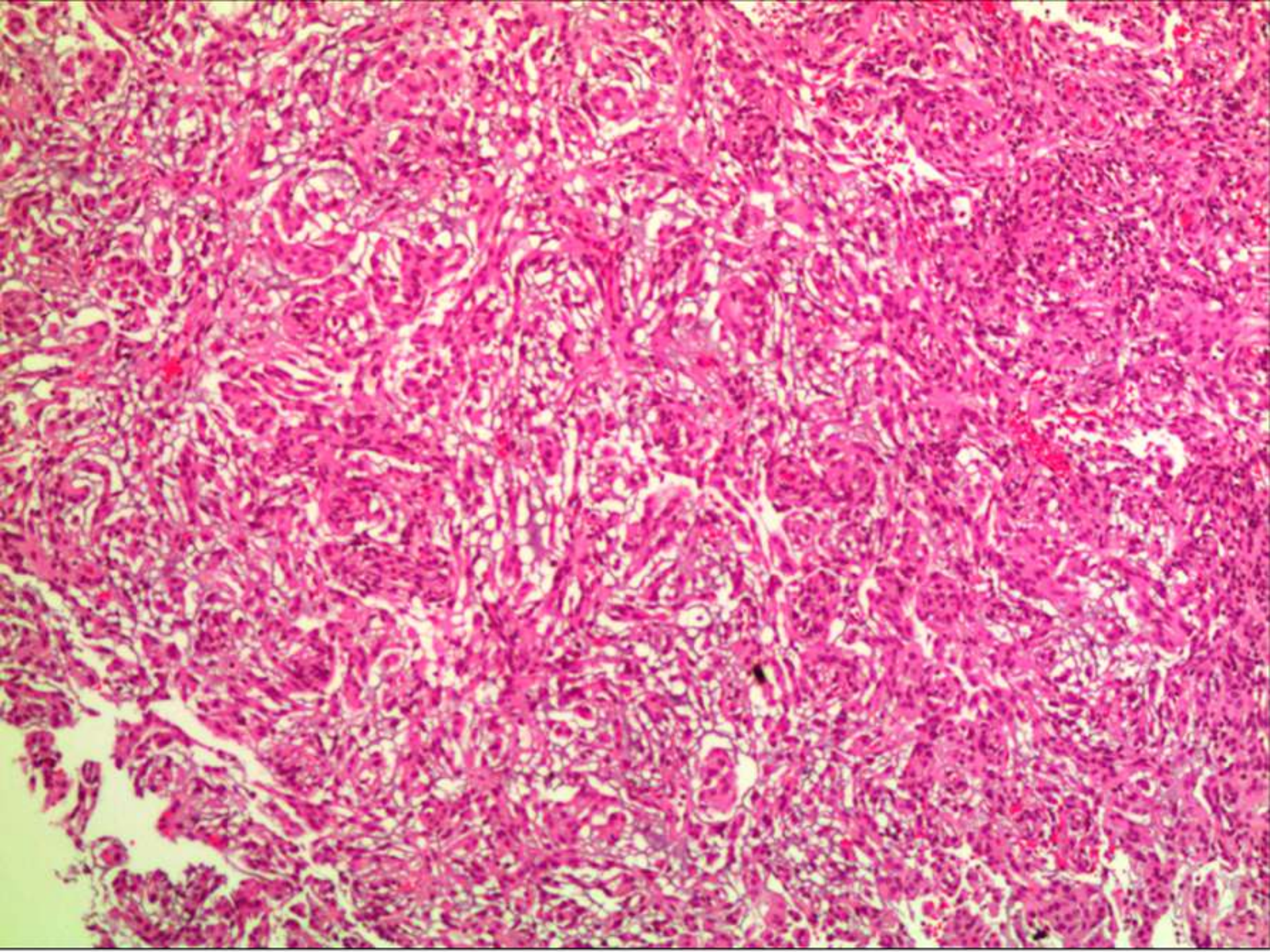


Meningioma cordoide grado II

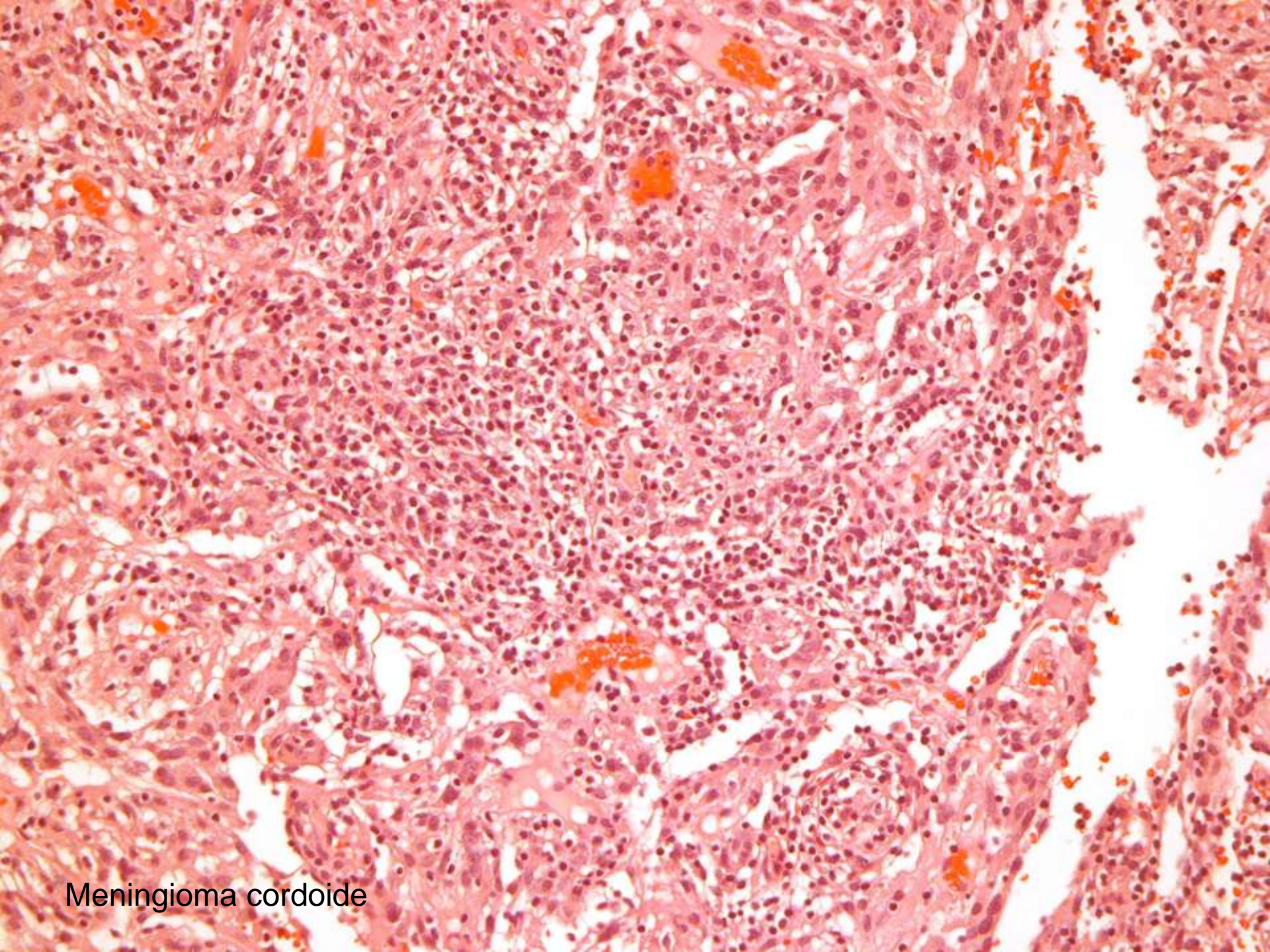
# MENINGIOMA CORDOIDE

- DIAGNOSTICO DIFERENCIAL
- 1 Meningioma de células claras
- 2. Meningioma micro quístico
- 3. Cordoma
- 4. Condrosarcoma mixoide
- 5. Glioma Cordoide.

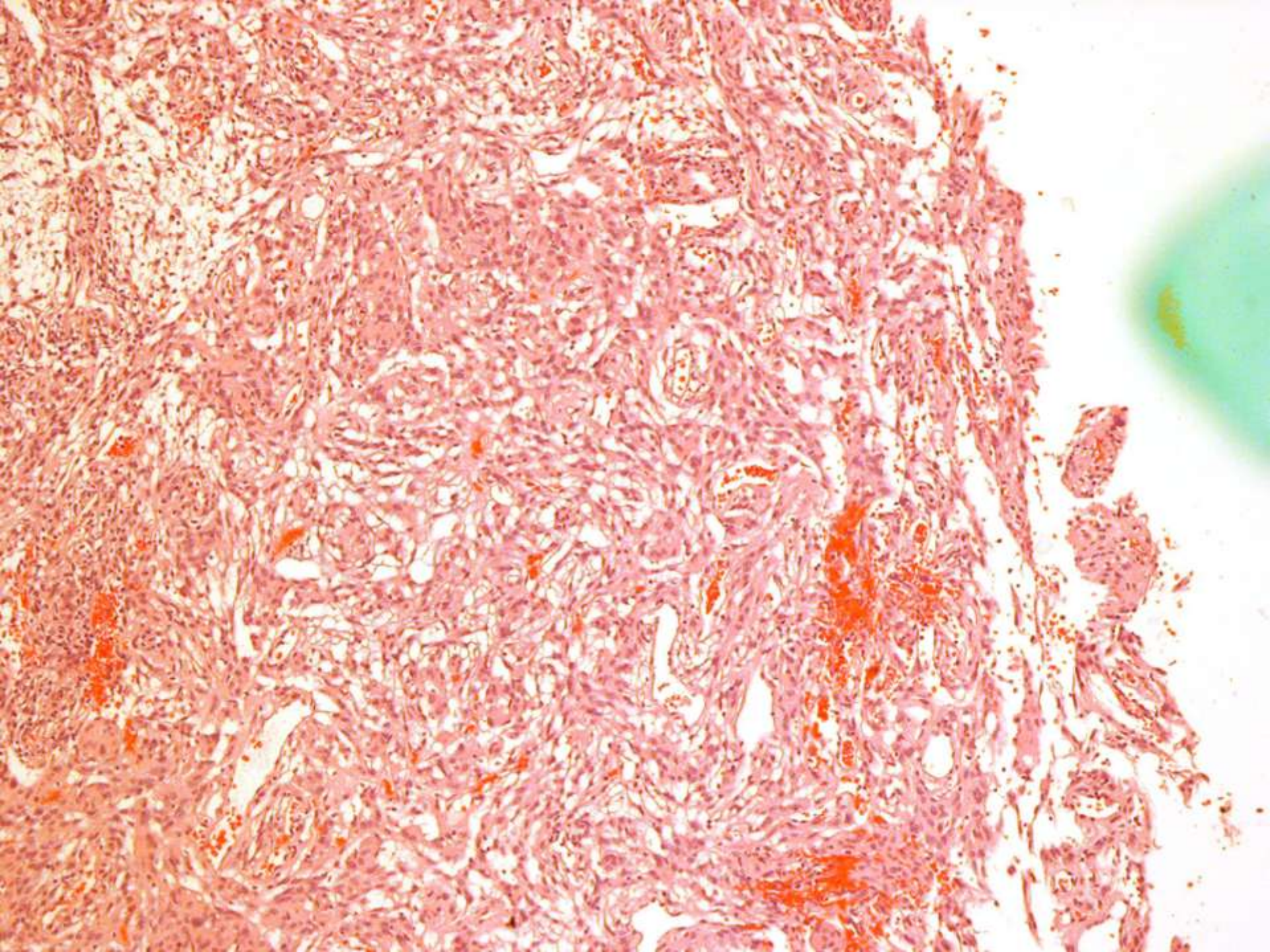
-







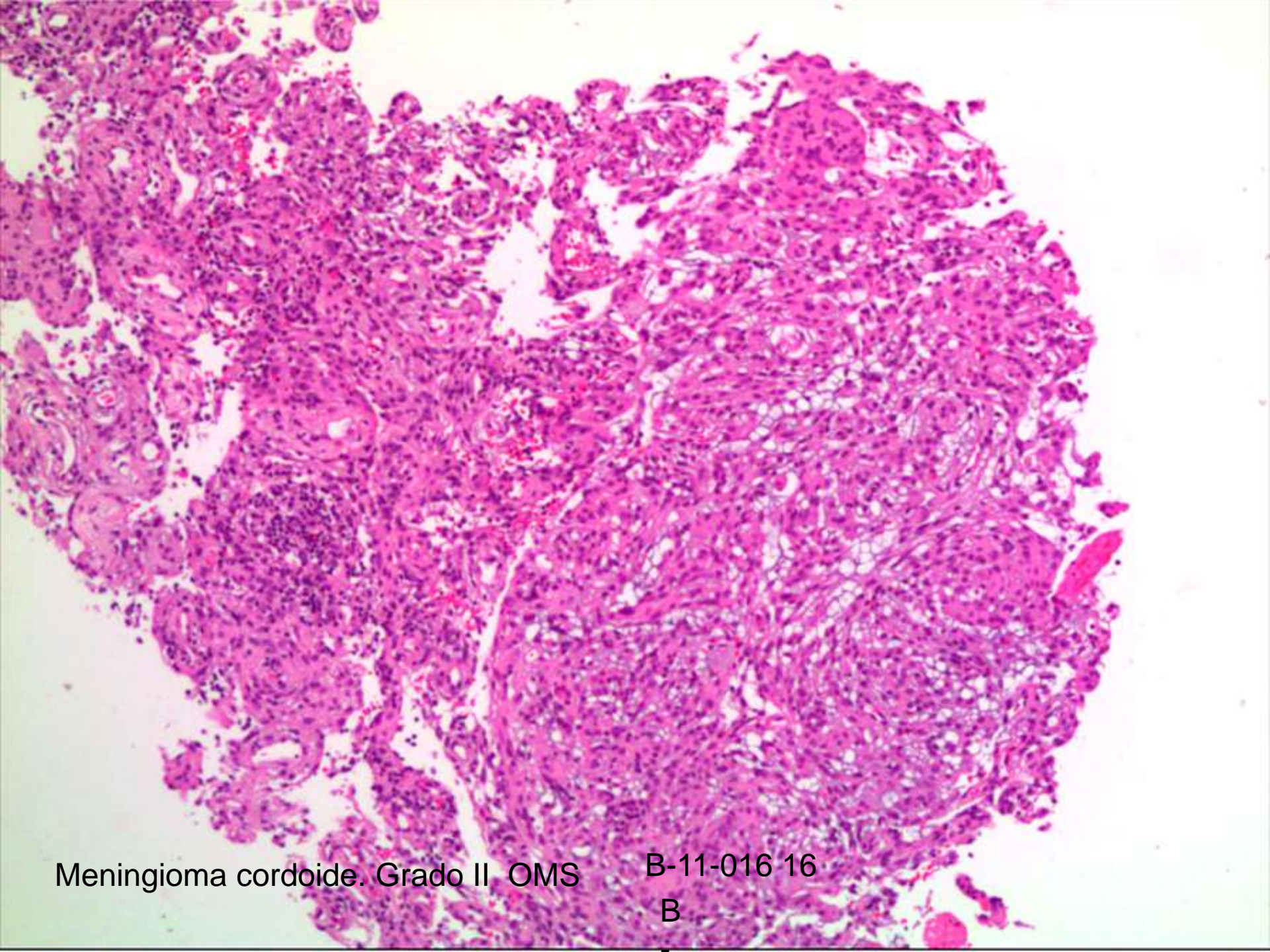
Meningioma cordoide



**DIAGNOSTICO**

**MENINGIOMA CORDOIDE**

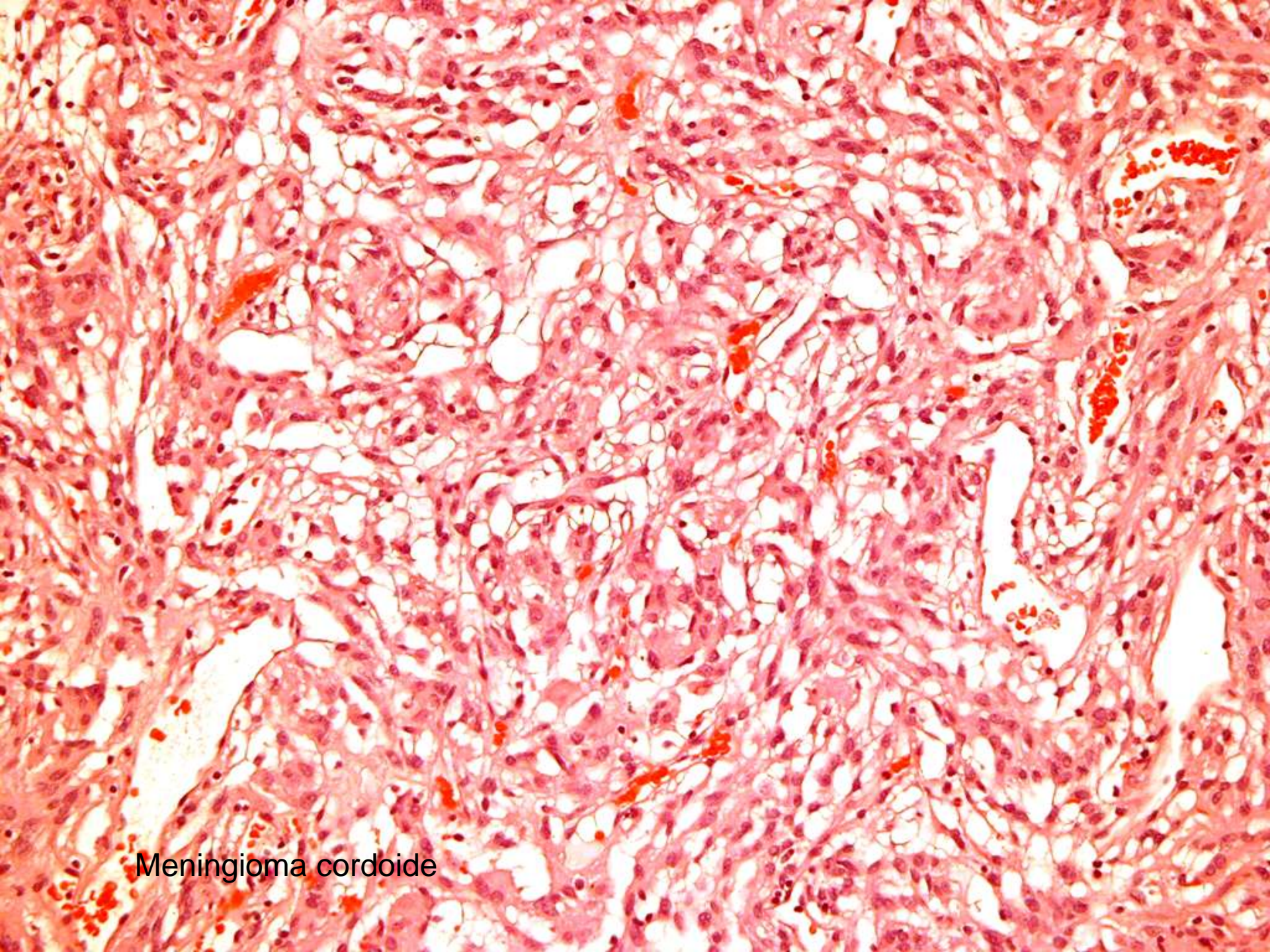
**GRADO II.**



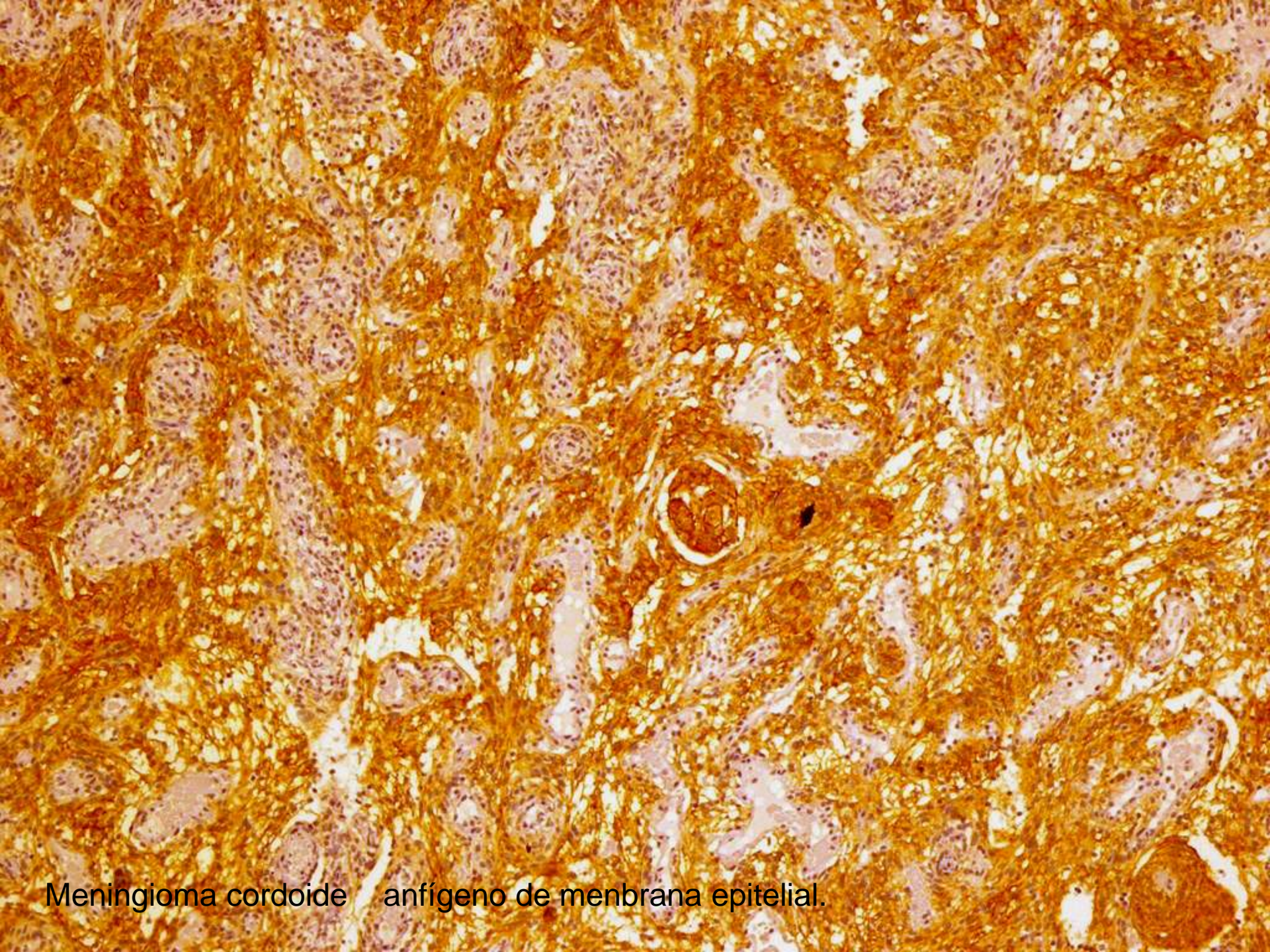
Meningioma cordoide. Grado II OMS

B-11-016 16

B



Meningioma cordoide



Meningioma cordoide anfigeno de membrana epitelial.