

Acute Retinal Necrosis Syndrome Complicating Chickenpox

J R Smith, S P Chee

ABSTRACT

Chickenpox may be complicated by ocular involvement. In these patients, acute retinal necrosis usually forms a relatively mild course. Systemic antiviral treatment during the acute phase of the disease is recommended. Rarely, retinal detachment may develop, resulting in blindness. It is strongly recommended that patients with chickenpox who develop visual symptoms should be referred for an ophthalmological opinion early.

Keywords: chickenpox, acute retinal necrosis syndrome, retinal detachment, retinitis

Singapore Med J 2000 Vol 41(12):602-603

INTRODUCTION

Acute retinal necrosis syndrome is a herpetic retinitis which if untreated, progresses to rhegmatogenous retinal detachment^(1,2). Although the condition commonly affects otherwise healthy adults, on rare occasions, it may complicate chickenpox⁽³⁻⁹⁾. In this situation, the disease is said to follow a relatively mild course. We report a series of four patients who presented with retinal inflammation of quite varied severity after contracting chickenpox, alerting physicians to this association.

Case 1

Fourteen days after contracting chickenpox, an otherwise healthy 21-year-old Malay man developed

right visual blurring and floaters. Slit lamp examination of the eye revealed moderate anterior uveitis and dense vitritis, with an area of necrotising retinitis in the temporal periphery, measuring one clock hour in length (Fig. 1). There was marked retinal arteritis, particularly in the area of necrosis. Right visual acuity was 6/9. The left eye appeared normal. Treatment was with intravenous acyclovir at 500 mg/12 hours, in keeping with a relatively low glomerular filtration rate. Over the ensuing five days, partial regression of the retinitis was accompanied by resolution of the uveitis and improvement of visual symptoms. Good visual acuity was maintained. Subsequently, the patient completed a four week course of oral acyclovir, and complete resolution of the inflammation was observed.

Case 2

A 29-year-old Chinese man presented with blurred vision of the left eye two weeks following the onset of chickenpox. Apart from myopia, there was no past medical history. Presenting best corrected visual acuities were 6/6 and 6/9 in the right and left eyes, respectively. There was moderate left anterior uveitis, without posterior segment involvement, and right eye examination was normal. He was reviewed on several occasions over the ensuing week, and this inflammation was observed to respond partially to treatment with topical corticosteroid. However, at the one week check, with left visual acuity reduced to 6/15, a tiny focus of retinitis was observed superiorly in an area of lattice degeneration. There was also mild retinal arteritis and moderate vitritis. Treatment was commenced with intravenous acyclovir at a dose of 500 mg/8 hours. Two days later, the retinitis had resolved, and by the end of the fifth day of antiviral therapy, vasculitis was no longer apparent. At this time, a one month oral course of acyclovir was prescribed. Left visual acuity recovered to 6/9.

Case 3

One week after the onset of typical chickenpox, a 5-year-old Chinese boy with no past medical history presented with a red left eye. The referring physician had commenced treatment with oral acyclovir. On

Singapore National
Eye Centre
11 Third Hospital
Avenue
Singapore 168751

J R Smith, PhD,
FRACO, FRACS
Senior Registrar in
Ophthalmology

S P Chee,
MMed (Ophth),
FRCOphth, FRCS
Consultant
Ophthalmologist

Correspondance to:
Dr Justine R Smith
Tel: (65) 227 7255
Fax: (65) 227 7290
Email: jrsmith@
cyberway.com.sg

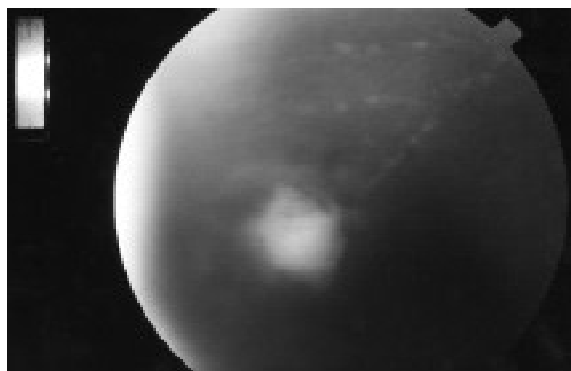


Fig. 1 Right fundus photograph showing a single small focus of necrotising retinitis and adjacent retinal vasculitis in the temporal periphery.

presentation, left visual acuity was 6/6. There was mild scleritis and anterior uveitis, but no posterior eye signs. However, left fundus examination four days later revealed widespread, but low grade peripheral retinal arterial vasculitis. This was not associated with retinitis or vitritis. Intravenous acyclovir was now instituted at 50 mg/m²/8 hours. Within 48 hours of commencing intravenous anti-viral therapy, improvement of the vasculitis was evident. Three days later, the inflammation had completely resolved, and visual acuity remained 6/6. The right eye did not become involved. Acyclovir was continued orally for a further month.

Case 4

A 23-year-old healthy Chinese woman contracted chickenpox during the third trimester of pregnancy. Seven days following onset of the rash, she developed floaters in the left eye. Unfortunately, a clear account of any medical treatment is not available as the patient was overseas at that time. However, it appears that she was prescribed oral corticosteroid. One month later, immediately following delivery, she suddenly lost vision in that eye, and was referred to the Singapore National Eye Centre. Left visual acuity was recorded at "counting fingers". There was anterior chamber inflammation as well as vitritis in this eye and the temporal retinal periphery contained an atrophic focus with a U-shaped tear. A total retinal detachment was present. Right eye examination was unremarkable. Left scleral buckling did not achieve retinal re-attachment, and vitrectomy fluid-gas exchange and endolaser were performed. Perioperatively, she was treated with oral prednisolone in a dose of 1 mg/kg/day. Although the retina remains flattened two years postoperatively, left visual acuity has not improved.

DISCUSSION

First reported in the 1970s, acute retinal necrosis syndrome describes a rapidly progressive necrosis of the peripheral retina, associated with occlusive retinal arteritis and accompanied by a prominent inflammatory reaction in the vitreous and anterior chamber⁽¹⁾. The disease is caused by infection with either varicella zoster or herpes simplex viruses, and a new mutation in the herpes virus has been proposed as explanation for its very recent appearance⁽²⁾. Systemic acyclovir is indicated to limit the retinal necrosis which is frequently complicated by one or more retinal tears⁽²⁾. Up to 75 percent of patients may suffer retinal detachment, and surgical repair is generally difficult⁽²⁾. A mild subtype with slow progression and limited extent of the retinitis, and consequent favourable prognosis is described⁽¹⁰⁾.

Acute retinal necrosis usually occurs in otherwise healthy adults, presumably representing a re-activation

of latent herpes virus infection⁽²⁾. However, the international literature contains a small number of reports describing presentation in the context of primary infection, including 12 cases which accompanied typical chickenpox⁽³⁻⁹⁾. Both immunocompetent and immunocompromised individuals were affected, but all cases were of the mild subtype. No patients developed retinal detachment and 11 patients (92%) retained normal visual acuity. One hypothesis suggests that a strong anti-varicella immune response, already activated in response to the cutaneous eruption, limits ocular inflammation in these cases⁽⁵⁾.

We have reported four additional cases of chickenpox-associated retinal inflammation. These present a spectrum of disease severity, from a mild retinal vasculitis which did not fulfil the standard diagnostic criteria for the acute retinal necrosis syndrome⁽¹⁾ (Case 3) to a fulminant syndrome with retinal detachment (Case 4). Case 1 and 2 were typical of other reported cases. Treatment may certainly influence presentation. Commencement of acyclovir for anterior segment disease, prior to the onset of clinical retinal involvement, may have led to the very limited inflammation observed in Case 3. On the other hand, Case 4 presented following regression of the necrosis, and had not received the recommended anti-viral treatment during the acute phase of the syndrome.

Acute retinal necrosis syndrome is a rare complication of chickenpox. This case series highlights the variable severity of the retinal involvement, with the possibility of blinding disease. It is strongly recommended that chickenpox patients with visual symptoms have early ophthalmological review including fundus examination.

REFERENCES

- Holland G, Executive Committee of the American Uveitis Society. Standard Diagnostic Criteria for the Acute Retinal Necrosis Syndrome. *Am J Ophthalmol* 1994; 117:663-7.
- Duker JS, Blumenkranz MS. Diagnosis and management of the acute retinal necrosis (ARN) syndrome. *Surv Ophthalmol* 1991; 35:327-43.
- Matsuo T, Koyama M, Matsuo N. Acute retinal necrosis as a novel complication of chickenpox in adults. *Br J Ophthalmol* 1990; 74:443-4.
- Kelly SP, Rosenthal AR. Chickenpox chorioretinitis. *Br J Ophthalmol* 1990; 74:698-9.
- Culbertson WW, Brod RD, Flynn HW, Taylor BC, Brod BA, Lightman DA, Gordon G. Chickenpox-associated acute retinal necrosis syndrome. *Ophthalmology* 1991; 98:1641-6.
- Barondes MJ, Tellez F, Siegel A. Acute retinal necrosis after chickenpox in a healthy adult. *Ann Ophthalmol* 1992; 24:335-6.
- Capone A, Meredith TA. Central visual loss caused by chickenpox retinitis in a 2-year-old child. *Am J Ophthalmol* 1992; 113:592-3.
- Friedman SM, Mames RN, Sleasman JW, Whitcup SM. Acute retinal necrosis after chickenpox in a patient with acquired immunodeficiency syndrome. *Arch Ophthalmol* 1993; 111:1607-8.
- Ehongo-Bidime A, Pereleux A, Zanen A. Necrose retinienne aigue postvaricelleuse. *Bulletin de la Societe Beige d'Ophthalmologie* 1995; 255:61-8.
- Matsuo T, Nakayama T, Koyama T, Koyama M, Matsuo N. A Proposed mild type of acute retinal necrosis syndrome. *Am J Ophthalmol* 1988; 105:579-83.