

CME Article

Palpitations and narrow-complex tachycardia

Tan J K B, Guo K W Q, Hsu L F

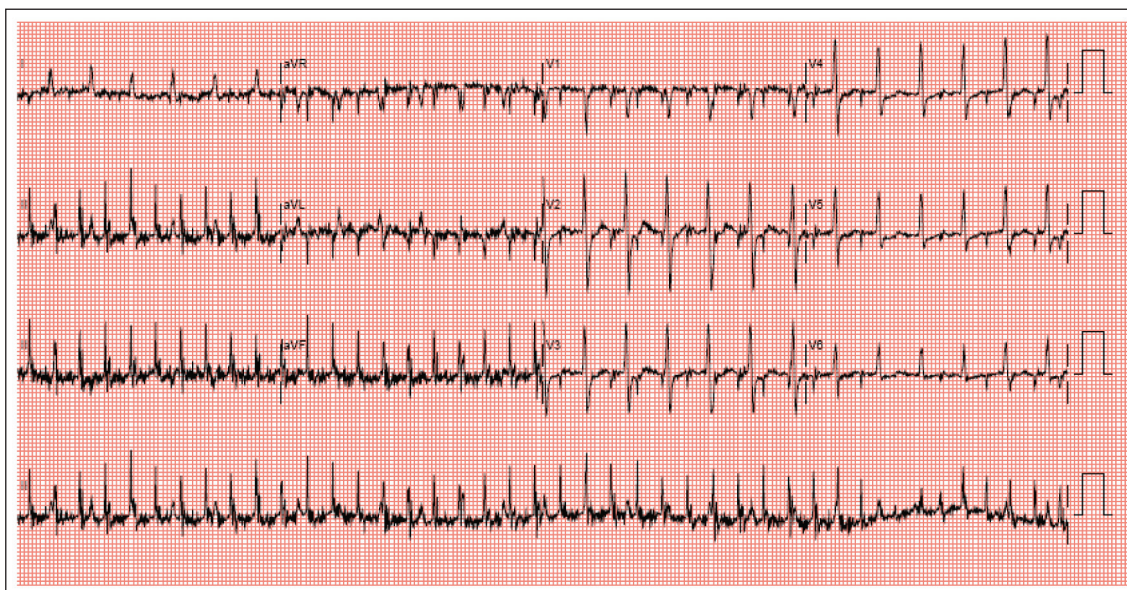


Fig.1 12-lead ECG shows a narrow complex tachycardia with an irregular-looking ventricular rate.

CLINICAL PRESENTATION

A 56-year-old Chinese man complained of palpitations occurring intermittently over three years. These episodes, usually lasting around 30 minutes and self-terminating, were described as a rapid, racing heartbeat associated with dyspnoea. The patient had a history of hypertension and Parkinson's disease on treatment. His resting tremors were well-controlled with madopar and artane. He presented to the Emergency Department

with a recurrence of palpitations that did not abort spontaneously. On examination, the patient was anxious and in obvious distress. Blood pressure and oxygen saturation were normal. His pulse rate was 150 beats per minute and there were no signs of heart failure. The initial 12-lead electrocardiogram (ECG) is shown in Fig. 1. This clearly shows a narrow complex tachycardia, with an irregular-looking ventricular rate. What is the diagnosis?

Department of
Cardiology,
National Heart
Centre Singapore,
17 Third Hospital
Avenue,
Mistri Wing,
Singapore 188752

Tan JKB, MBBS,
MMed, MRCP
Registrar

Guo KWQ, MBBS,
MMed, MRCP
Registrar

Hsu LF, MBBS,
FRCPE, FAMS
Senior Consultant

Correspondence to:
Dr Julian KB Tan
Tel: (65) 9750 8481
Fax: (65) 6468 7154
Email: jaetee@
yahoo.com

ECG INTERPRETATION

Although the ECG shows a narrow complex tachycardia with a seemingly irregular ventricular rate, a closer examination of the QRS complexes reveals that this irregularity is caused by a discrepancy in the ventricular rate between the precordial and limb lead ECG complexes. The R-R intervals in the precordial leads are about 0.4s (Fig. 2), giving a ventricular rate of about 150 beats per minute, corresponding to the patient's clinical pulse rate. On initial glance at the narrow QRS complexes in the limb leads, the presumed R-R interval is slightly above 0.2s (Fig. 3; horizontal arrows), giving a ventricular rate of about 260–280 beats per minute.

The clue lies in lead I, where the QRS complexes are slower and correspond to those observed in the precordial leads (Fig. 3). Extrapolating these complexes to leads II and III (Fig. 3; vertical arrows), the true QRS complexes

(Fig. 3; circle), which are smaller in amplitude, can be seen among the larger potentials. These large potentials, which can easily be mistaken for QRS complexes, are actually myopotentials from the resting tremors (at a frequency of about 4–5 Hz or 4–5 tremors per second, corresponding to about 250–300 beats per minute). This is further supported by the fact that the spikes are of varying amplitudes.

DIAGNOSIS

This is a 12-lead ECG of a patient with supraventricular tachycardia (ventricular response rate of about 150 bpm), while having resting tremors (at a frequency of about 4 Hz) due to Parkinson's disease. The myopotentials are most prominent on the limb leads, as in most such patients, and are easily misread as being QRS complexes. The rapid and seemingly irregular ventricular rate can sometimes lead to a mistaken diagnosis of atrial fibrillation or flutter.

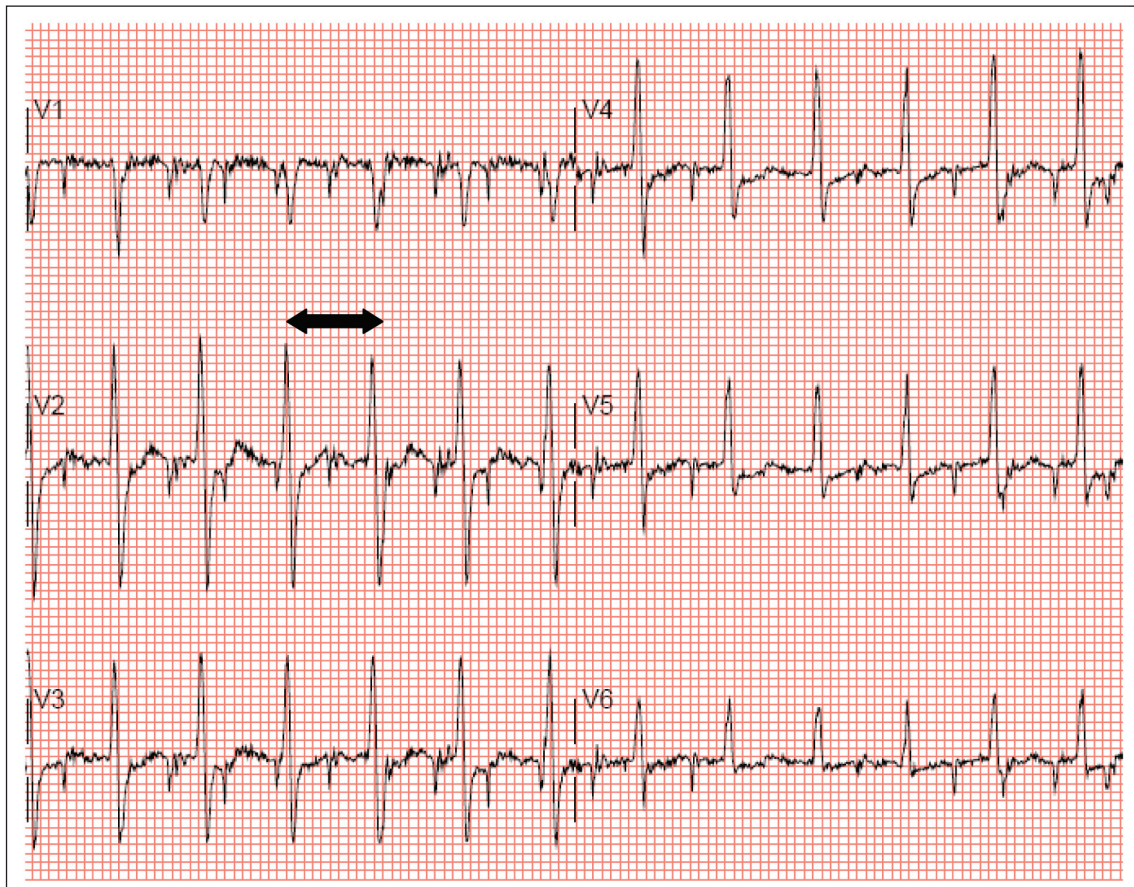


Fig. 2 Precordial leads. R-R interval of 0.4s (arrows).

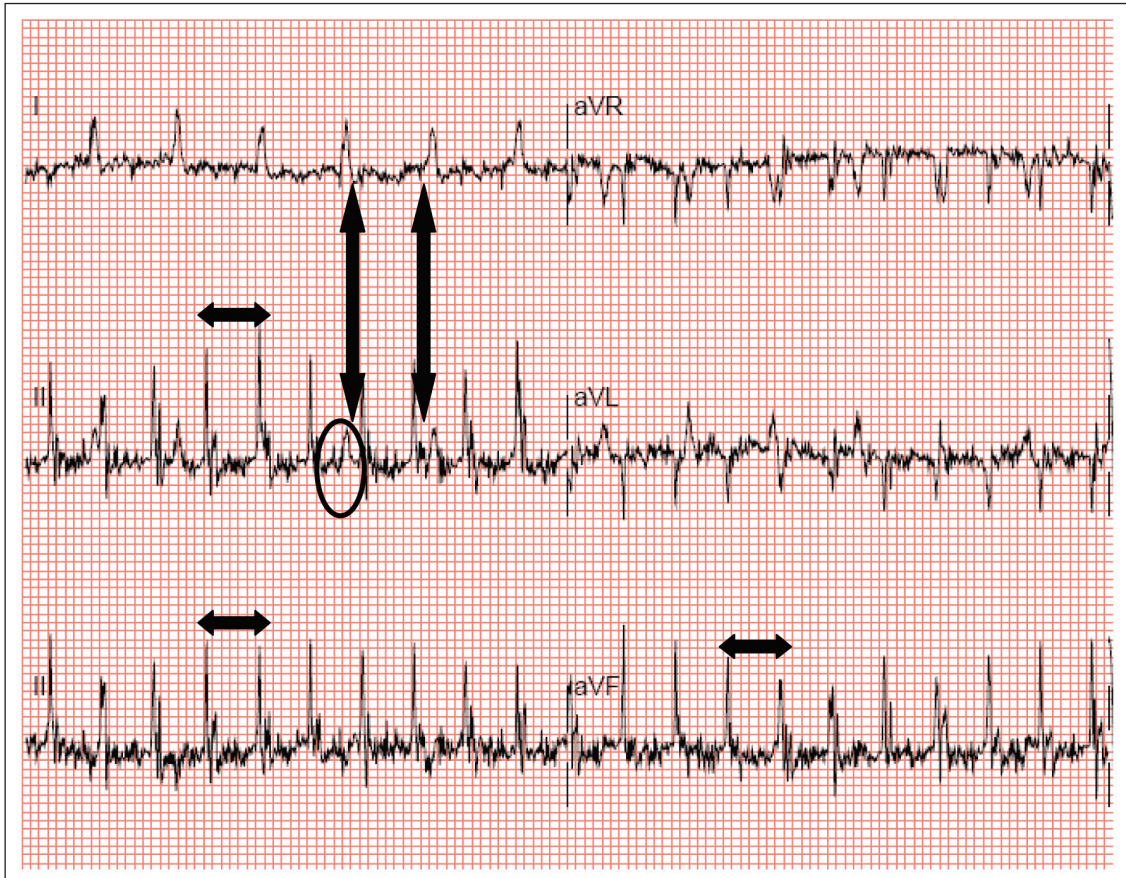


Fig. 3 Limb leads. Presumed R-R interval of 0.2s (horizontal arrows) and true QRS complex (circle).

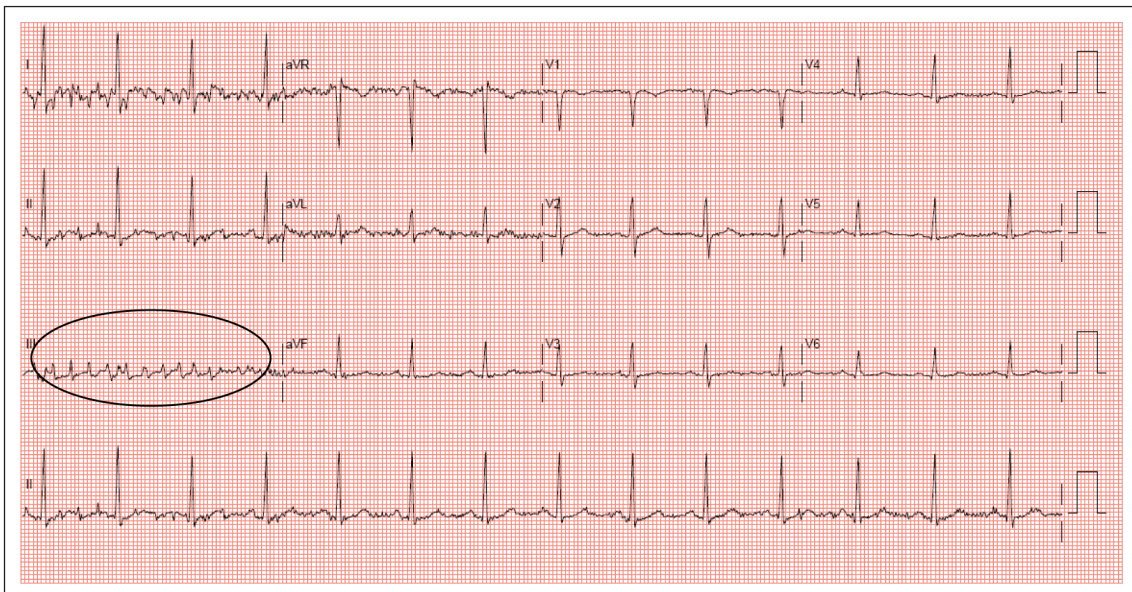


Fig. 4 12-lead ECG (after IV adenosine) shows myopotentials (circle).

CLINICAL COURSE

The patient was successfully cardioverted with intravenous (IV) Adenosine. Fig. 4 shows the 12-lead ECG immediately after IV adenosine was administered. Notice the myopotentials (Fig. 4;

circle) that were still present after the patient returned to sinus rhythm. The patient subsequently underwent an electrophysiological study that showed a typical slow-fast AV nodal reentrant tachycardia, which was successfully ablated.

DISCUSSION

Somatic tremors, especially in Parkinson's disease, can be recorded on the ECG.⁽¹⁾ They can sometimes mimic arrhythmias, having been mistaken for atrial tachycardia, atrial flutter⁽²⁾ and even ventricular tachycardia^(3,4) in published cases. In this case, the patient had a true arrhythmia (supraventricular tachycardia), during which the ECG interpretation was complicated by the presence of tremors, with the myopotentials showing an unusually high amplitude. This case also illustrates the fact that myopotentials are not necessarily always smaller in amplitude compared to true QRS complexes.

Several features may help differentiate myopotentials from QRS complexes.⁽⁵⁾ Firstly, the amplitudes of myopotentials are usually variable and the baselines are more often than not, wandering. Secondly, the frequency of myopotentials can easily be mapped to the frequency of resting tremors, which are usually between 4–6 Hz (240–360 beats/min). This is usually too fast to represent a haemodynamically stable tachycardia. Finally, it is important to look out for discrepancies in the R-R intervals between the precordial leads and the limb leads, especially in someone with prominent resting limb tremors.

ABSTRACT

A 56-year-old patient with a history of

Parkinson's disease presented with palpitations and an apparently irregular narrow-complex tachycardia on electrocardiogram. The discrepancy in ventricular rate between the limb and precordial leads was the result of myopotentials from his tremors mimicking the QRS complexes in the limb leads. These myopotentials can be differentiated from true QRS complexes by the fact that they are usually variable in amplitude and occur at a frequency similar to that of limb tremors.

Keywords: supraventricular tachycardia, tremors

Singapore Med J 2011;52(4):241-245

REFERENCES

1. Bhatia L, Turner DR. Parkinson's tremor mimicking ventricular tachycardia. *Age Ageing* 2005; 34:410-1.
2. Hwang WJ. Tremor-induced electrocardiographic artifact mimicking atrial flutter. *Acta Neurol Taiwan* 2008; 17:151-2.
3. Freedman B. Tremor-induced ECG artifact mimicking ventricular tachycardia. *Circulation* 2001; 103:E112-2.
4. Llinas R, Henderson GV. Images in clinical medicine. Tremor as a cause of pseudo-ventricular tachycardia. *N Engl J Med* 1999 21; 341:1275.
5. Huang CY, Shan DE, Lai CH, et al. An accurate electrocardiographic algorithm for differentiation of tremor-induced pseudo-ventricular tachycardia and true ventricular tachycardia. *Int J Cardiol* 2006; 111:163-5.

SINGAPORE MEDICAL COUNCIL CATEGORY 3B CME PROGRAMME
Multiple Choice Questions (Code SMJ 201104A)

- | | True | False |
|---|--------------------------|--------------------------|
| Question 1. What is the rhythm of the ECG in Fig.1? | | |
| (a) Sinus tachycardia. | <input type="checkbox"/> | <input type="checkbox"/> |
| (b) Atrial tachycardia. | <input type="checkbox"/> | <input type="checkbox"/> |
| (c) Atrial flutter. | <input type="checkbox"/> | <input type="checkbox"/> |
| (d) Atrial fibrillation. | <input type="checkbox"/> | <input type="checkbox"/> |
|
Question 2. What is the ventricular rate shown in the ECG in Fig.1? | | |
| (a) 150 bpm. | <input type="checkbox"/> | <input type="checkbox"/> |
| (b) 200 bpm. | <input type="checkbox"/> | <input type="checkbox"/> |
| (c) 250–300 bpm. | <input type="checkbox"/> | <input type="checkbox"/> |
| (d) Not conclusive because of artefacts. | <input type="checkbox"/> | <input type="checkbox"/> |
|
Question 3. Based on the ECG in Fig.1, how would you treat a patient who is haemodynamically stable? | | |
| (a) Oral beta-blockers. | <input type="checkbox"/> | <input type="checkbox"/> |
| (b) IV adenosine. | <input type="checkbox"/> | <input type="checkbox"/> |
| (c) IV amiodarone. | <input type="checkbox"/> | <input type="checkbox"/> |
| (d) DC cardioversion. | <input type="checkbox"/> | <input type="checkbox"/> |
|
Question 4. Which of the following statements regarding myopotentials are true? | | |
| (a) Myopotentials are always smaller in amplitude compared to QRS complexes. | <input type="checkbox"/> | <input type="checkbox"/> |
| (b) Myopotentials usually vary in amplitude. | <input type="checkbox"/> | <input type="checkbox"/> |
| (c) Myopotentials occur at a rate or frequency similar to that of the patient's resting tremors. | <input type="checkbox"/> | <input type="checkbox"/> |
| (d) Myopotentials can always be seen in all the 12 leads of an ECG. | <input type="checkbox"/> | <input type="checkbox"/> |
|
Question 5. What is the usual frequency of tremors in Parkinson's disease? | | |
| (a) 1–2 Hz. | <input type="checkbox"/> | <input type="checkbox"/> |
| (b) < 1 Hz. | <input type="checkbox"/> | <input type="checkbox"/> |
| (c) 4–5 Hz. | <input type="checkbox"/> | <input type="checkbox"/> |
| (d) > 20 Hz. | <input type="checkbox"/> | <input type="checkbox"/> |

Doctor's particulars:

Name in full: _____

MCR number: _____ Specialty: _____

Email address: _____

SUBMISSION INSTRUCTIONS:

(1) Log on at the SMJ website: <http://www.sma.org.sg/cme/smj> and select the appropriate set of questions. (2) Select your answers and provide your name, email address and MCR number. Click on "Submit answers" to submit.

RESULTS:

(1) Answers will be published in the SMJ June 2011 issue. (2) The MCR numbers of successful candidates will be posted online at www.sma.org.sg/cme/smj by 01 June 2011. (3) All online submissions will receive an automatic email acknowledgment. (4) Passing mark is 60%. No mark will be deducted for incorrect answers. (5) The SMJ editorial office will submit the list of successful candidates to the Singapore Medical Council.

Deadline for submission: (April 2011 SMJ 3B CME programme): 12 noon, 25 May 2011.