

# Nocardioform Placentitis: A Continuing Question

Hossam Elsheikh Ali, BVc, DVM, MVSc, PhD; Barry A. Ball, DVM, PhD, DACT\*;  
 Carleigh E. Fedorka, PhD; Kirsten E. Scoggin, MS, PhD;  
 Maria R. Schnobrich, VMD, DACT; Erdal Erol, DVM, MS, PhD;  
 Rebecca E. Ruby, MSc, BVSc, DAVCP; Alan T. Loynachan, DVM, PhD, DACVP;  
 Jacqueline L. Smith, PhD; Craig N. Carter, DVM, PhD, DACVPM; and  
 Pouya Dini, DVM, PhD, PhD, DECAR, DACT†\*

Nocardioform placentitis (NP) is defined as a focal mucoid placental inflammation in which the bacterial infection (*Amycolatopsis* spp., and/or *Crossiella equi* as the most common isolates) is limited to the chorionic surface of the ventral placenta without infection of the fetus. NP was first diagnosed in Central Kentucky in 1986 and continued to result in episodic outbreaks of abortion and preterm birth in mares in 1998, 1999, 2011, 2017, and 2020. To date, the pathogenesis of the disease remains an enigma and attempts to induce an experimental infection in mares have been unsuccessful. While episodic in nature, NP remains a problem to the equine breeding industry, as its diagnosis and treatment remain challenging and economic impact is immense. In some cases, NP can be diagnosed through transabdominal ultrasonography to detect placental separation and the accumulation of hyperechoic exudate. However, since a limited area of the placenta is accurately visualized by transabdominal ultrasonographic scanning, the lack of apparent lesions in the placenta does not exclude the possibility of disease. NP treatment has been empirically applied and has been based on common treatments for ascending placentitis and the results of culture and antimicrobial susceptibility patterns of bacteria isolated from lesions post-foaling. The aim of this paper is to provide a comprehensive review and updates on equine NP. Authors' addresses: Gluck Equine Research Center, Department of Veterinary Science, University of Kentucky, Lexington, KY 40503 (Elsheikh Ali, Ball, Fedorka, Scoggin); LeBlanc Reproduction Center, Rood and Riddle Equine Hospital, Lexington, KY 40511 (Schnobrich); Veterinary Diagnostic Laboratory, Department of Veterinary Science, University of Kentucky, Lexington, KY 40503 (Erol, Ruby, Loynachan, Smith, Carter); Department of Population Health and Reproduction, School of Veterinary Medicine, University of California, Davis, CA 95616 (Dini); e-mails: pdini@ucdavis.edu, b.a.ball@uky.edu. \*Corresponding authors; †presenting author. © 2021 AAEP.

## 1. Introduction

In the United States, approximately 3-5% of Thoroughbred broodmares suffer late-term pregnancy losses due to placentitis, making it the single most

common cause of abortions, stillbirths, and perinatal losses.<sup>1,2</sup> These outcomes lead to multimillion-dollar losses in the equine breeding industry in addition to their effects on the mares' well-being and the emotional impacts on the owners.<sup>3</sup> Based on the lesion

---

## NOTES

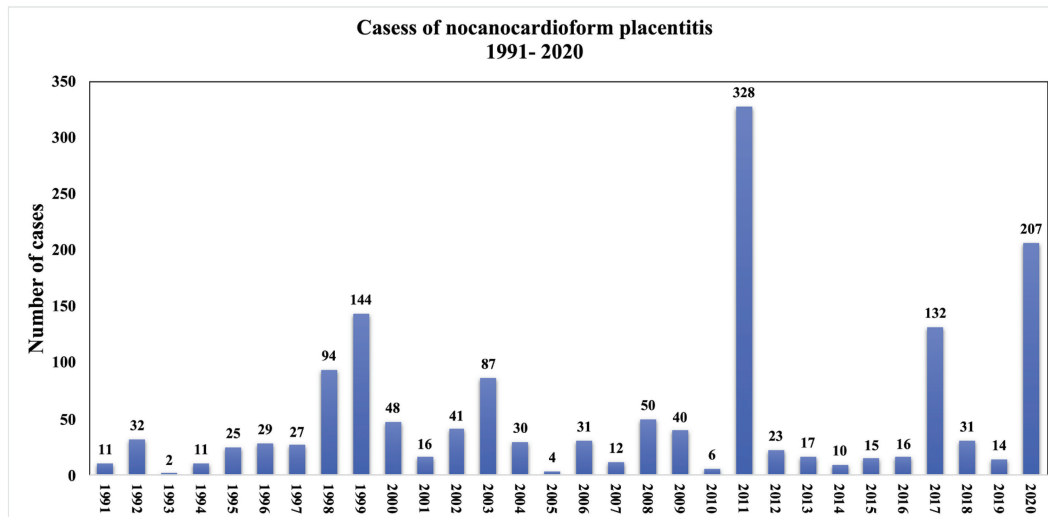


Fig. 1. Historical nocardioform placentitis trends from 1991 to 2020 in Central Kentucky. Source UK-VDL 2020.

site, distribution, and pathogenesis, there are 4 recognized forms of equine placentitis: ascending, focal mucoid (nocardioform), diffuse (hematogenous), and multifocal placentitis. Ascending placentitis is the most frequent type of equine placentitis.<sup>3</sup> In this type, the ascending infection (predominately caused by *Streptococcus equi subspecies zooepidemicus*) gains access to the caudal pole of the chorioallantois (cervical star region) through the vagina and consequently breaches the uterine cervical barrier.<sup>4-8</sup> At the infection site, the bacteria colonize, and the resultant inflammatory response and leukocytic infiltration lead to thickening and separation of the chorioallantois from the endometrium.<sup>4,7,9,10</sup> Multifocal and diffuse placentitis are less common forms and are usually a result of hematogenous spread of microorganisms to the uterus, such as leptospirosis, salmonellosis, histoplasmosis, and candidiasis.<sup>3</sup> On the other hand, nocardioform placentitis (NP) is a distinct type of equine placentitis, characterized by infection of the chorionic surface. Most often, NP causes a focal, well-demarcated mucoid placental inflammation located most commonly at the ventral base of the uterine horns, with rare involvement of the allantoic fluid, amnion, amniotic fluid or fetus.<sup>11,12</sup> The location and nature of NP lesions do not fit with ascending or hematogenous bacterial infection. Thus, pathogenesis of NP remains unclear. The following review aims to present a comprehensive review and updates on equine NP.

#### History and Outbreaks

NP was first diagnosed and characterized in Central Kentucky (KY) in 1986.<sup>13</sup> The term “nocardioform” was historically adopted due to phylogenetic relatedness of the causative agents (i.e., *Amycolatopsis* spp., *Crossiella equi*, and *Streptomyces* spp.) to the

*Nocardia* species.<sup>13,14</sup> Subsequent NP outbreaks occurred in KY and were reported in 1998, 1999, 2011, 2017, and 2020 (Fig. 1).<sup>11,15</sup> Sporadic cases of NP also have been reported in Florida,<sup>16</sup> Louisiana,<sup>17</sup> South Africa,<sup>18</sup> Italy,<sup>19</sup> Australia,<sup>20</sup> and most recently in New Zealand.<sup>21</sup> Anecdotally, NP cases have also been reported sporadically in California, Indiana, Maryland, New York, North Carolina, Ohio, Pennsylvania, and Texas. Additionally, some of these cases were recorded in Standardbred mares in Ohio and Pennsylvania.

#### Etiology

Nocardioform placentitis is believed to be associated with gram-positive, branching Actinomycetes (Fig. 2) including *Amycolatopsis* spp., and *Crossiella equi* along with more recently characterized isolates of *Streptomyces atriruber* and *Streptomyces silaceus*, among others.<sup>22-24</sup> Characterization of Actinomycetes associated with abortions during the 2011 outbreak of NP in KY revealed that *Amycolatopsis* spp. (49% of cases) was the most common isolate, with *Crossiella equi* (29% of cases) as the next most frequent isolate.<sup>14</sup> It has been suggested that *Crossiella equi* infections may be more likely to result in abortion, whereas infections with other types of Actinomycetes tend to result in live, but premature foals.<sup>25</sup> Although Actinomycetes are a group of common soil microorganism, attempts in 2011 to culture *Amycolatopsis* spp. and *Crossiella equi* from KY soil samples from the environment of affected mares failed.<sup>25</sup> Similar to the findings of the 2011 outbreak, characterization of Actinomycetes associated with the 2020 NP outbreak in KY revealed that *Amycolatopsis* spp. (35.05% of cases) was the most common, with *Crossiella equi* (16.49% of cases) as the next most frequent isolate.<sup>26</sup> In the 2020 NP outbreak, 45.36% of cases of mucoid placentitis were negative for either *Amycolatopsis* spp. or *Crossiella equi*. This might suggest the possibility that other bacteria

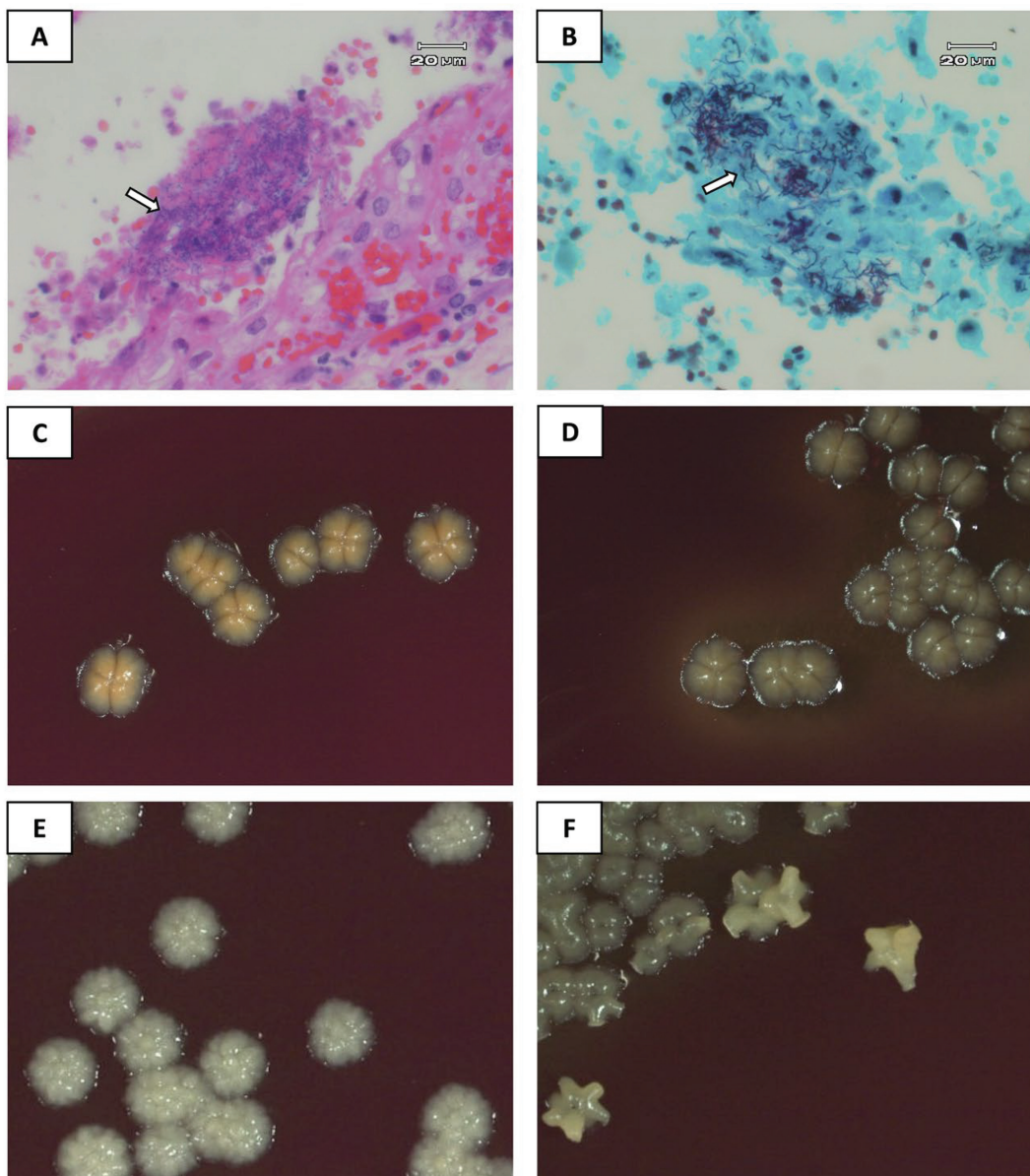


Fig. 2. Microscopic appearance of the Gram-positive, branching actinomycetes associated with nocardioform placentitis. HE (A) and Brown and Brenn Method (B) for Gram staining in tissue. Courtesy of Dr. Alan T. Loynachan. Colony morphologies of *Amycolatopsis kentuckyensis* (C), *Amycolatopsis lexingtonensis* (D), *Amycolatopsis pretoriensis* (E), *Crossiella equi* (F). Working stock cultures, provided by UKVDL, were stored at  $-80^{\circ}\text{C}$  until inoculation. Each strain of bacteria was streaked on blood agar plate (Hardy Diagnostics, Santa Maria, CA), followed by incubation at  $36^{\circ}\text{C}$  for 5 days. Pictures of colonies were captured at 10x magnification. Courtesy of Kinga Graniczowska.

are involved in mucoid placentitis and/or the difficulty of detecting bacteria following antimicrobial treatment. In support of this notion, the authors' preliminary data using 16s rRNA and RNA sequencing suggests that focal mucoid placentitis could be associated with other bacteria.<sup>a</sup> The analysis demonstrated that Proteobacteria, Actinobacteria, Firmicutes, and Bacteroidetes were the most abundant phyla in the NP cases, however, it is still not clear whether these bacteria are involved in the pathogenesis of NP or are environmental contaminants.

#### Possible Predisposing Factors and Occurrence

This form of equine placentitis is likely multifactorial and may involve factors such as host factors and environmental conditions. NP tends to manifest during the last trimester of pregnancy. Abortions typically occur between November and June, with the highest incidence in January and February.<sup>26</sup> Interestingly, the NP epizootic outbreaks in central KY were usually preceded by hot and dry weather in August and September in 2010, 2016, and 2019.<sup>27</sup> For instance, there is a negative association between August and September rainfall and the number of NP

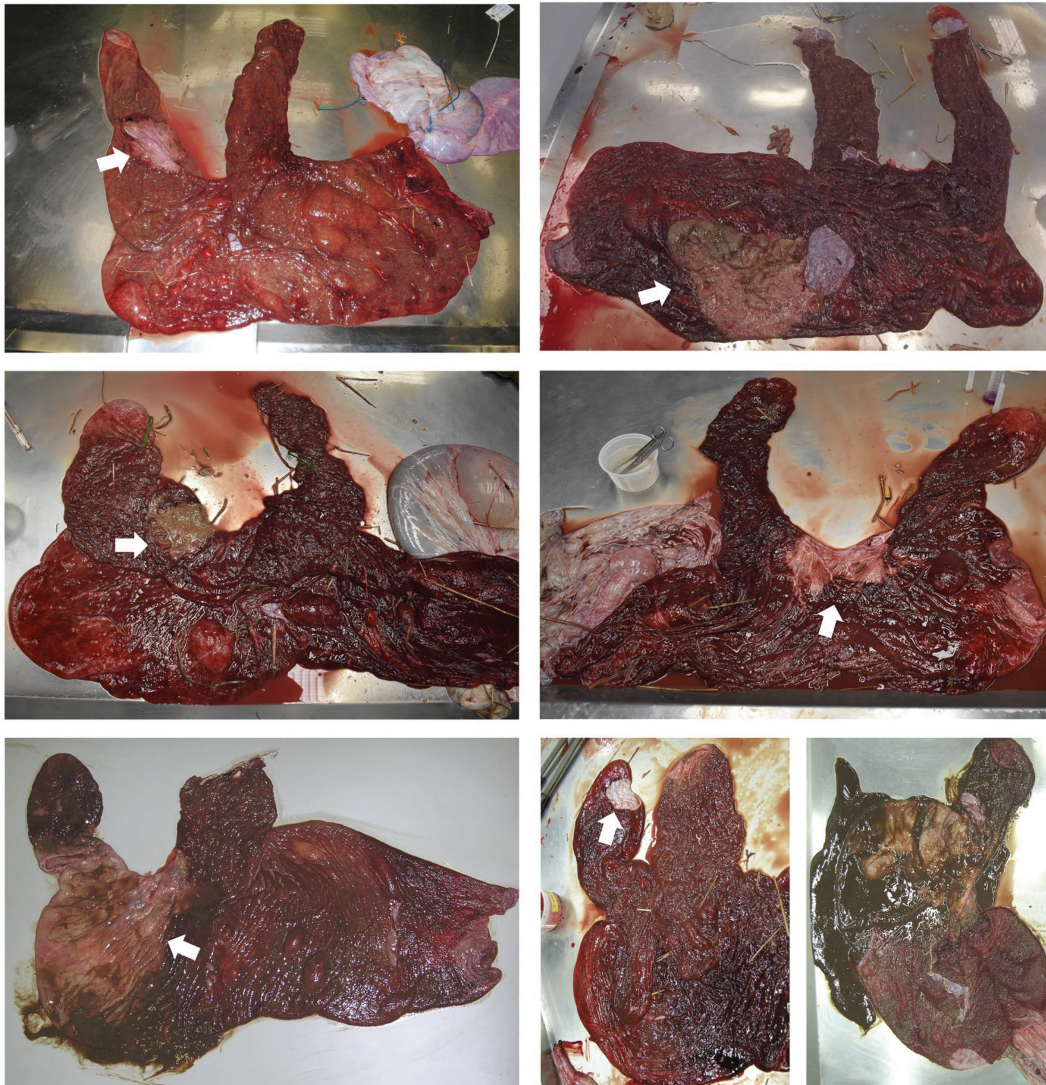


Fig. 3. Gross appearance photographs for seven different cases of nocardioform placentitis. Notice the lesions' (white arrow) different sizes and locations and the variation in the mucoid material's amount and coloration. Courtesy of Dr. Rebecca E. Ruby and Dr. Alan T. Loynachan.

cases submitted to University of Kentucky Veterinary Diagnostic Laboratory (UKVDL) for the subsequent foaling season. Also, there is positive correlation between mean temperatures in August and September and the number of NP cases submitted the next foaling season.<sup>27</sup> The previous observations suggest environmental conditions as a predisposing factor for the disease.<sup>27</sup> The method of breeding does not appear to be a factor in NP. NP has been reported with live cover, artificial insemination, and embryo transfer.<sup>26</sup> Large farms with higher stocking density are more at-risk.<sup>15</sup>

#### Lesion (Gross and Histopathological Appearance)

The NP lesions from the 2020 foaling season varied in size (range; 5 X 3 cm – 100 X 50 cm).<sup>b</sup> The distribution of the placental lesion in NP is distinct from those of ascending bacterial placentitis with lesions of NP

mainly distributed in the cranial-ventral portion of the placenta near the junction of the uterine horns and body (Fig 3).<sup>11,12</sup> The lesion is often demarcated from the surrounding normal placenta, and the affected placenta is covered with a thick, mucoid material (Fig 3).<sup>11,12</sup> Variation in volume, coloration and consistency of the mucoid material can be seen among different NP cases.<sup>b</sup> It is worth noting that some cases do not have the characteristic mucoid exudate (i.e., avillous chorion with no mucoid exudate), but will have a similar exudate evident microscopically.<sup>26</sup> This distinction might be attributed to disease chronicity or treatment. Of note, cystic adenomatous hyperplasia on the allantoic surface has been reported in association with NP but has also been reported with a variety of placental pathologies.<sup>28</sup> Based on historical findings, it appears that bacterial infection starts at the center of the lesion and then expands outward. This notion

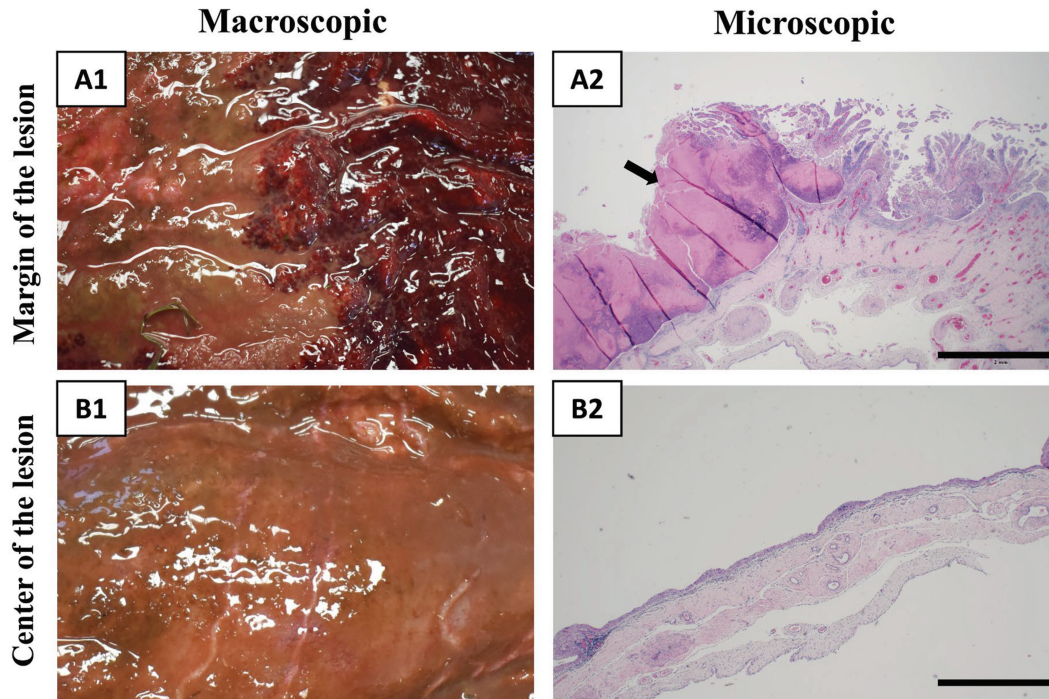


Fig. 4. Microscopic appearance of two different sampling sites in a case of nocardioform placentitis (A1, the margin of the lesion; B1, the center of the lesion). At the margin of the lesion (A2), notice the significant amount of inflammation associated with some mucoid exudative material adherent to the top of the chorionic surface (black arrow). At the center of the lesion (B2), you can notice the avillous chorionic surface (i.e., no chorionic villi left) and minimal inflammation. It is worth noting that it is very rare to see the microorganisms at the center of the lesion, therefore, it is recommended to sample the margin of the lesion to perform culturing or PCR for the microorganisms. Courtesy of Dr. Rebecca E. Ruby.

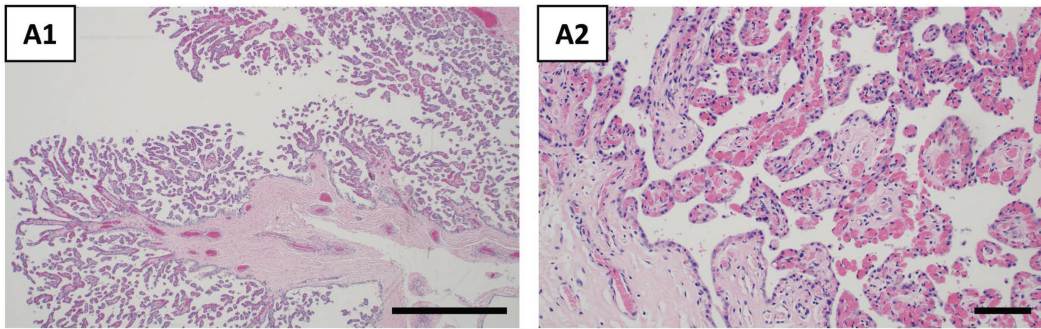
could be explained by the fact that the center of the lesion is most commonly avillous (complete loss of chorionic microvilli), whereas the margin of the lesion has raised, irregular and red areas (Figs. 3 and 4). Therefore, the margin of the lesion is the best sampling site for bacterial culture, PCR, and histopathology.<sup>b</sup> Histologically, the center of the lesion usually demonstrates blunted and atrophied chorionic villi with lymphocytic infiltrates; however, at the margin of the lesion the chorioallantois may demonstrate the infiltration of neutrophils, lymphocytes, and plasma cells with squamous metaplasia, blunting and loss of the chorionic microvilli (Figs. 4 and 5). The surface exudate contains sloughed epithelial cells, leukocytes, and an eosinophilic, amorphous material.

## 2. Pathogenesis and Pathophysiology

The site and solitary nature of NP lesions does not fit with ascending or hematogenous bacterial infection. The placental lesion in NP is mainly distributed in the cranial-ventral portion of the placenta near the junction of the uterine horns and body.<sup>11</sup> The classic lesion of NP is a thickened, tenacious mucoid material overlying a moderately well demarcated section of the chorionic surface with a central area (chronically infected areas) of tan

discoloration exhibiting loss of villi, surrounded by a raised, irregular red-tan chorion (Figs. 3 and 4). The areas correspond respectively to chronic, squamous metaplasia and mild to moderate mononuclear inflammation and more active inflammation with blunting and necrosis of chorionic villi (Fig. 5).<sup>11,12</sup> As mentioned previously, the pathogenesis of the disease remains poorly understood. Attempts to induce the infection in mares by intrauterine inoculation of *Crossiella equi* at the time of breeding or in pregnant mares via oral, intravenous, and intranasal routes with *Crossiella equi* were unsuccessful.<sup>25</sup> In Australia, experimental trials to induce equine amnionitis and fetal loss (EAFI) by feeding mares with processionary caterpillar resulted in unexpected cases of focal mucoid placentitis. Therefore, the possible implication of sources other than bacteria in NP should not be neglected.<sup>29</sup> NP is associated with three major events: placental inflammation (focal mucoid placentitis), chorionic separation from the endometrium (placental separation), and placental insufficiency. Understanding the molecular mechanisms of these three events holds potential for the development of new diagnostic tools and therapies to forestall NP and its detrimental effects on the pregnancy. Recently, using a transcriptomic approach (i.e., ribonucleic acid (RNA) sequencing), the authors elucidated the key regulators and molecular

### Normal chorioallantois



### Nocardioform placentitis

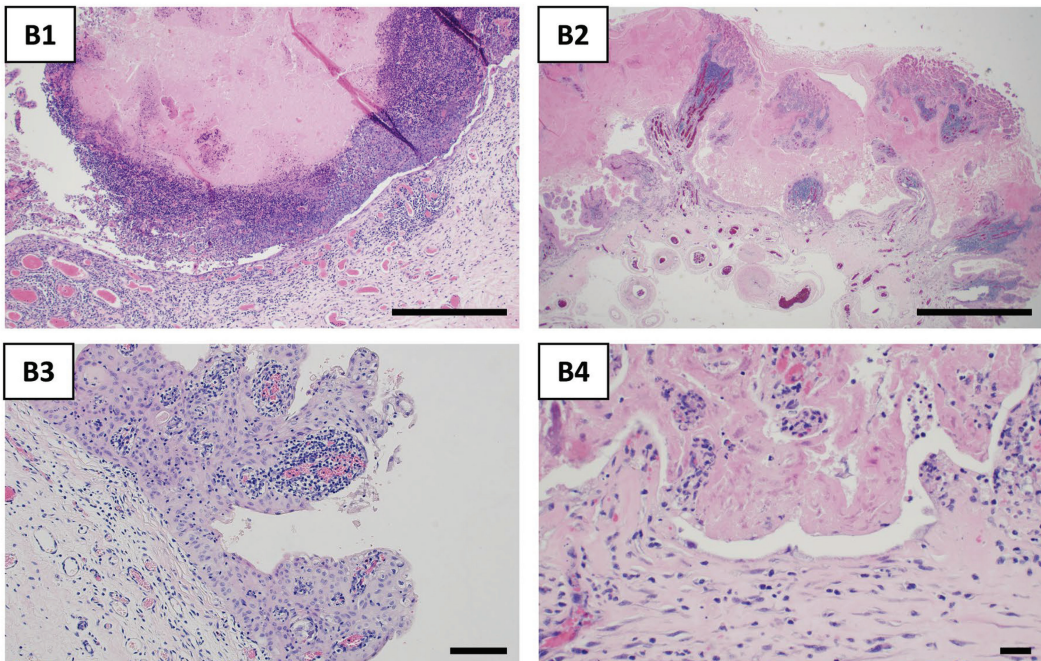


Fig. 5. Microscopic appearance of chorioallantois retrieved from normal postpartum mares (A) and nocardioform placentitis affected mares (B). In images (B1-4), notice the infiltration of neutrophils, lymphocytes, and plasma cells with squamous metaplasia, blunting, and loss of the chorionic microvilli. The surface exudate contains sloughed epithelial cells, leukocytes, and an eosinophilic, amorphous material. Courtesy of Dr. Rebecca E. Ruby.

mechanisms triggering these events in clinical cases of NP. Results revealed that inflammatory signaling, toll-like receptor signaling, inflammasome activation, chemotaxis, and apoptosis pathways are involved in NP.<sup>30</sup> NP is associated with the upregulation of a set of genes encoding the key regulators of the inflammatory cascade.<sup>30</sup> These include pattern recognition receptors (PRRs) such as Toll-like receptors (*TLRs*).<sup>30</sup> Of note *TLRs* are the primary and earliest recognition mechanism for pathogen associated molecular patterns (PAMPs) unique to the microorganisms with subsequent activation of the inflammatory cascade.<sup>31,32</sup> Among *TLRs*, several *TLRs* (*TLR1*, *TLR2*, *TLR3*, *TLR5*, *TLR7* and *TLR8*) were significantly upregulated in NP.<sup>30</sup> It is noteworthy that *TLR1/TLR2* heterodimers are responsible for

recognition of gram-positive bacteria, consistent with the *Amycolatopsis* spp. infection,<sup>31</sup> which is the major isolate from NP cases. Taken all together, these findings address the crucial role of *TLRs* in triggering the inflammatory response associated with NP. Therefore, strategies to block *TLRs* hold potential for future therapies to mitigate the inflammatory cascade and to forestall NP. This notion is supported by studies showing that TLR antagonists (*TLRAs*) were highly effective in preventing preterm birth induced by lipopolysaccharides (*LPS*), heat-killed *E. coli* or platelet activating factor (*PAF*) in primates and mice.<sup>33,34</sup> The authors' preliminary data also shows an association between the abundance of metabolically active bacteria and global gene expression patterns in the placenta, suggesting interactions between the host and

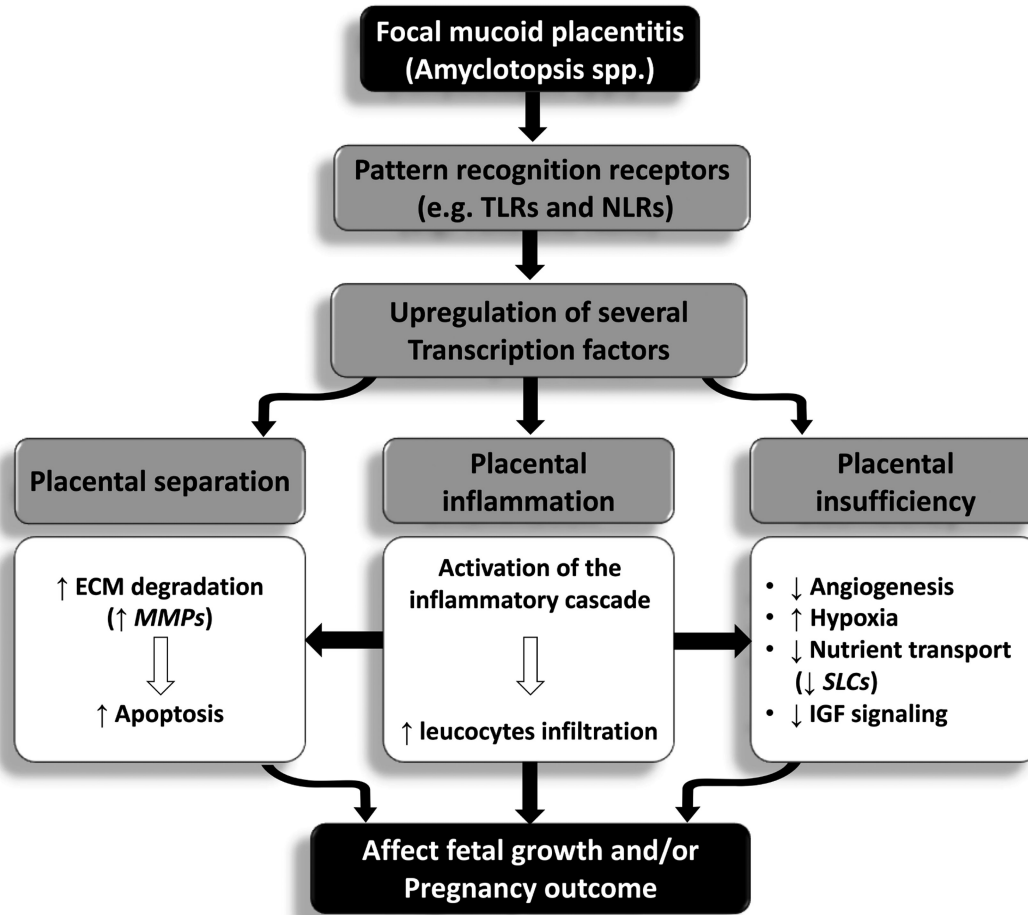


Fig. 6. Schematic illustration of possible mechanisms associated with nocardioform placentitis in mares. Adapted and modified from El-Sheikh Ali, et al.<sup>30</sup> Abbreviations: IGF, insulin-like growth factor; ECM, extra cellular matrix; MMPs, matrix metalloproteinases; NLRs, NOD-like receptor; SLCs, solute carrier family; TLRs, toll-like receptors.

pathogen. The increased leukocytic infiltration in NP was associated with the upregulation of matrix metalloproteinase (*MMP1*, *MMP3*, and *MMP8*) and apoptosis-related genes, such as caspases (*CASP3* and *CASP7*), which could explain placental separation associated with NP.<sup>30</sup> Preliminary data on the transcriptome of the bacteria in NP cases also demonstrates that bacteria are involved in metabolic pathways and biosynthesis of secondary metabolites in the area of the placenta without a gross lesion, increasing their abundance, perhaps leading to increase leukocytic infiltration and placental separation. Also, NP was associated with downregulation of several placenta-regulatory genes (*ABCG2*, *GCM1*, *EPAS1*, and *NR3C1*), angiogenesis-related genes (*VEGFA*, *FLT1*, *KDR*, and *ANGPT2*), and glucose transporter coding genes (*GLUT1*, *GLUT10*, and *GLUT12*), as well as upregulation of hypoxia-related genes (*HIF1A* and *EGLN3*), which could potentially be associated with the placental insufficiency accompanying NP.<sup>28</sup> Since NP is associated with angiogenesis dysregulation, the use of therapeutics that improve placental angiogenesis and/or blood flow might be beneficial for NP treatment. The significant pathways associated

with placental inflammation, separation and insufficiency are summarized in Fig. 6.

### 3. Sequel and Pregnancy Outcomes

Multiple outcomes have been associated with NP: late term-abortion, weak yet viable foals, or normal parturition. These different pregnancy outcomes might be dependent on several factors such as size of the lesion, severity of inflammation, and causative bacteria, among others. For instance, increased lesion size is associated with a growth-retarded foal or a dead foal.<sup>27</sup> There is a negative correlation between the lesion size and the foal weight (i.e., the larger the lesion, the smaller the foal and vice versa).<sup>27</sup> NP is also associated with decreased gestational length (10 days less than unaffected mares) and decreased neonatal weight (10 lbs less).<sup>27</sup> Although neonates may be smaller, they do not have abnormal or altered IgG or WBCs.<sup>27</sup> NP lesions may also be seen in the chorioallantois in mares with normal neonates. Interestingly, affected mares have normal postpartum fertility, with an average of 1.5 cycle per pregnancy.<sup>27</sup>

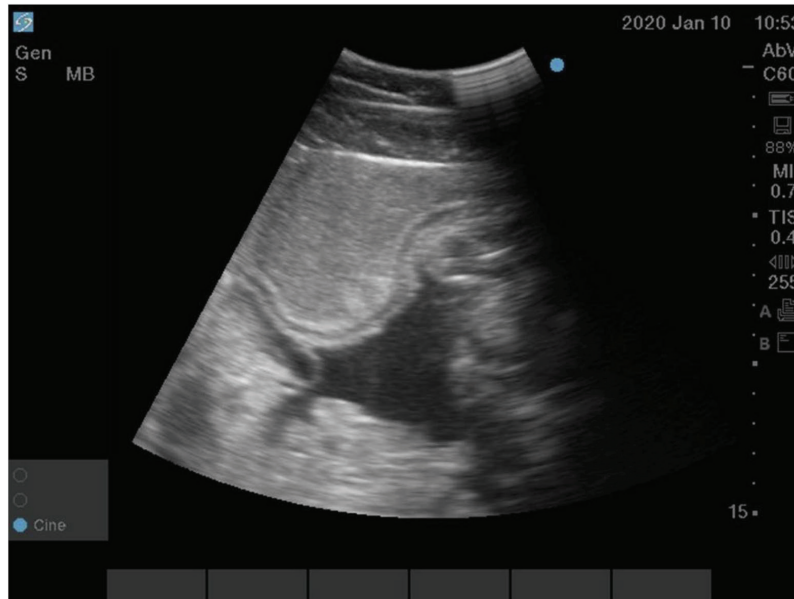


Fig. 7. Transabdominal ultrasonography of the chorioallantois in a case of nocardioform placentitis. Note fluid accumulation and separation of the chorioallantois from the uterus. Courtesy of Dr. Maria Schnobrich.

#### 4. Diagnosis

While costs associated with NP can be significant, its diagnosis and treatment remain challenging. Clinically, large NP lesions are usually associated with premature mammary gland development, which might reflect a late stage of the disease. Vulvar discharge is not commonly observed in NP cases unless the mare is about to abort.<sup>3</sup> NP can be diagnosed through transabdominal ultrasonography to detect placenta separation (i.e., separation of the chorion from the endometrium) and the accumulation of hyperechoic exudate (Fig. 7).<sup>35,36</sup> However, since a limited area of the placenta is accurately visualized by ultrasonography, the lack of apparent lesions in the placenta does not exclude the possibility of disease. Transrectal ultrasound can also be useful in advanced cases where there is sufficient diffuse inflammation leading to an increased combined thickness of the uterus and placenta (CTUP), or the focal lesion is located caudally enough to be identified on transrectal evaluation. There are no clear recommendations for the most appropriate window to screen, but many elect to perform a transrectal and single transabdominal ultrasound evaluation in late gestation to screen for placental and fetal health. The use of more frequent scans is dictated by the history of the mare and the incidence of NP that season. A recent retrospective work has described the serum profile of mares with focal mucoid placentitis (n=6; two placentas were PCR positive for the *Amycolatopsis* spp, while the other four had no bacteria detected), and found alterations in endocrine, cytokine, and fetosecretory markers in the weekly assessed samples. The focal

mucoid placentitis was associated with an increase in progestins, decrease in estradiol-17B, and increase in the fetosecretory protein Alpha-Fetoprotein (AFP).<sup>37</sup> Additionally, this study showed an increase in pro-inflammatory IL-2 and IFN $\gamma$ , pleiotropic IL-6 and tumor necrosis factor (TNF), and anti-inflammatory IL-5, and IL-10 in the maternal serum.<sup>38</sup> It is important to mention that all of the mares with focal placentitis within this study produced a viable neonate. While abnormal estrogen and progesterone profiles and changes in serum cytokines have been reported for placentitis, still there is no sensitive and specific biomarker available to diagnose and predict this condition. This emphasizes the importance and urgent need to develop sensitive and reliable diagnostic blood biomarkers for this disease. Postpartum diagnosis is dependent on the characteristic NP/focal mucoid placentitis lesion, as mentioned earlier, which could be confirmed by obtaining swabs to culture and isolate nocardioform Actinomycetes on blood agar and Columbia CNA agar with sheep (or horse) blood, and using culture isolates (or swab/placental tissue) to perform PCR for nocardioform Actinomycetes (i.e., *Crossiella equi* and *Amycolatopsis* spp). It is worth noting that the PCR primers used for *Amycolatopsis* spp. are designed to identify Genus *Amycolatopsis*, not specific species. Aborted fetuses had a decreased body weight/smaller than normal, lack of internal adipose tissue, and decreased musculature.<sup>26</sup>

#### 5. Treatment

Given that the pathogenesis of NP is still unknown, and there are no established experimental models to study NP, treatment for nocardioform placentitis has



Table 1. Common Therapeutic Agents Used to Treat Mares with Placentitis

Therapeutic Agent	Suggested Dose	Mode of Action/Proposed Effect	Ref
Trimethoprim (TMP)-sulfamethoxazole (SMZ)	15–30 mg/kg, PO, q12h	Antibacterial	40-42
Gentamicin	6.6 mg/kg, IV, q24h	Antibacterial	41, 43
Doxycycline	10 mg/kg, PO, q12h	Antibacterial	44
Enrofloxacin	5 mg/kg, IV, q24h	Antibacterial	45
Potassium penicillin G	22,000 IU/kg, IV, q6h	Antibacterial	41, 43
Altrenogest	0.088 mg/kg, PO, q24h	Tocolytic (block uterine contractions)	41, 42
Firocoxib	57 mg (loading dose) then 1 tab q24h	Non-steroidal anti-inflammatory medication (NSAID)	46
Flunixin meglumine	1.1 mg/kg, PO/IV, q24h, or q12h	Anti-inflammatory	41
Dexamethasone	40, 35, 25 mg, q24h, IV for 6 d, decreasing dose every 2 d	Anti-inflammatory; stimulate fetal maturation.	41
Acetylsalicylic acid (ASA, Aspirin)	50 mg/kg, PO, q12h	Improve blood flow to the placenta.	41
Pentoxifylline	8.5 mg/kg, PO, q12h	Improve blood flow to the placenta; Block endotoxin-induced TNF, IL-6; anti-cytokine activity	40-42
Estradiol cypionate	10 mg/mare, IM, q3d for 3 treatments	Improve blood flow/angiogenesis in the placenta and improve immunity.	47

been empirically applied and based on treatments used for ascending placentitis.<sup>3</sup> The treatment protocols vary by practitioner and severity of disease, but tend to include broad spectrum antimicrobials, anti-inflammatories, tocolytics and other therapeutics that improve uterine/placental blood flow and help to maintain uterine quiescence as summarized in Table 1. Treatment outcomes might be dependent on several factors (stage of the disease/size of the lesion, causative bacteria, gestational age, among others). Recently, *in vitro* studies revealed that nocardioform Actinomycetes are susceptible to ceftriaxone, doxycycline, minocycline, linezolid, and trimethoprim/sulfamethoxazole as depicted in Table 2,<sup>c</sup> confirming earlier study results.<sup>39</sup> However, it is unclear whether these antimicrobials are effective *in vivo*.

Further studies to investigate the placental diffusion of these antibacterial treatments are warranted.

## 6. Conclusion

Nocardioform placentitis continues to cause episodic outbreaks of abortion and preterm birth in mares. While NP is an important equine placental pathology and cause of reproductive loss, its route of infection and the pathogenesis is still unknown. Due to the knowledge gap in the pathogenesis of NP, the diagnosis of disease is limited and the current treatment regime is empirical with a debatable success rate. Using high-dimensional biology should improve the understanding of the pathophysiology and the host-pathogen interaction, allowing for the

Table 2. In Vitro Anti-Microbial Susceptibility Patterns of Nocardioform<sup>a</sup>: 2019-2020 Foaling Season

Antimicrobials	<i>Amycolatopsis</i> Spp. (n=91)			<i>Crossiella equi</i> (n=60)			Unidentified (n=20)		
	S (%)	I (%)	R (%)	S (%)	I (%)	R (%)	S (%)	I (%)	R (%)
Amikacin	90	0	10	10	0	90	65	0	35
Amox/Clav. Acid	74.7	16.4	8.8	56.7	30	13.3	75	15	10
Cefepime	26.4	12.1	61.5	8.3	8.3	83.4	45	10	45
Ceftriaxone	73.6	16.5	7.7	81.7	12.7	5.6	80	15	5
Ciprofloxacin	31.9	53.9	14.2	8.3	0	91.7	45	25	30
Clarithromycin	78	7.7	14.3	11.7	5	83.3	55	5	40
Doxycycline	81.3	7.7	11	96.6	1.7	1.7	95	0	5
Imipenem	0	40.7	59.3	0	15	85	0	50	50
Linezolid	100	0	0	100	0	0	100	0	0
Minocycline	84.7	3.3	12	98.3	1.7	0	95	0	5
Tobramycin	36.3	12	51.7	10	0	90	50	5	45
TM/SMZ	80.2	0	19.8	95	0	5	80	0	20

Abbreviation: TMP-SMX, trimethoprim-sulfamethoxazole; S, susceptible; I, intermediate; R, resistant.

<sup>a</sup>As there are no interpretative criteria for antimicrobial susceptibility of nocardioform actinomycetes for horses, the criteria have been extrapolated from human *Nocardia* spp. It should be kept in mind that these results are only *in vitro* test results and may not necessarily be applied to actual clinical placentitis cases in mares. Further studies to investigate the placental diffusion of these antibacterial treatments and their efficacy are warranted.

development of diagnostic tools and therapeutic strategies to prevent losses due to NP.

### Acknowledgments

Part of this work was funded by the Koller Emergency Response Fund, the Grayson Jockey Club Research Foundation, and the Albert G. Clay Endowment. The authors would like to thank Dr. Emma Adam and Dr. David Horohov for their help and support. The authors would also like to thank all veterinarians, farm owners and managers, and UKVDL personnel who participated in these studies and surveys.

### Declaration of Ethics

The Authors have adhered to the Principles of Veterinary Medical Ethics of the AVMA.

### Conflict of Interest

The Authors have no conflicts of interest.

### References and Footnotes

- Troedsson M, Zent W. in *Proc Workshop on the Equine Placenta* 66–67.
- Lof HK, P.-N A, Gregory JW, et al. Evaluation of the combined utero-placental thickness (CUPT) and of vulvar conformation as indicators of placentitis in pregnant mares. *Animal Reproduction Science* 2010;121:329–330. doi: <http://dx.doi.org/10.1016/j.anireprosci.2010.04.134>.
- Canisso IF, Ball BA, Erol E, et al. Comprehensive review on equine placentitis, in *Proceedings*. Am Assoc Equine Pract 2015;61:490–509.
- Hong CB, Donahue JM, Giles RC, et al. Etiology and pathology of equine placentitis. *J Vet Diagn Invest* 1993;5:56–63.
- Platt H. Infection of the horse fetus. *J Reproduction and Fertility. Supplement* 1975;605-610.
- LeBlanc MM. Ascending placentitis in the mare: An update. *Reprod Domest Anim* 2010;45 Suppl 2:28–34.
- Whitwell KE. Infective placentitis in the mare. *Equine Infectious Diseases V* 1988;172–180.
- Acland H. Abortion in mares. *Equine reproduction* 1993;554-562.
- Giles RC, Donahue JM, Hong CB, et al. Causes of abortion, stillbirth, and perinatal death in horses: 3,527 cases (1986-1991). *J Am Vet Med Assoc* 1993;203:1170–1175.
- El-Sheikh Ali H, Dini P, Scoggin K, et al. Transcriptomic analysis of equine placenta reveals key regulators and pathways involved in ascending placentitis. *Biol Reprod* 2020;102:1306–1325.
- Donahue JM, Williams NM. Emergent causes of placentitis and abortion. *The Veterinary clinics of North America. Vet Clin North Am Equine Pract* 2000;16:443–456. viii
- Ball BA, Loux SC, Kennedy L, et al. Transcriptomic analysis of the chorioallantois from mares with nocardioform placentitis. *J Equine Vet Sci* 2018;66:231.
- Giles R, et al. in *Proceedings 37th Annual Meeting, American College of Veterinary Pathologists*.
- Erol E, Sells SF, Williams NM, et al. An investigation of a recent outbreak of nocardioform placentitis caused abortions in horses. *Vet Microbiol* 2012;158:425–430.
- Carter C, Erol E, Cohen N, et al. Diagnostic epidemiology of nocardioform placentitis and abortion in Kentucky, 1991-2015. *J Equine Vet Sci* 2016;39:S59–S60.
- Christensen BW, Roberts JF, Pozor MA, et al. Nocardioform placentitis with isolation of *Amycolatopsis* spp in a Florida-bred mare. *J Am Vet Med Assoc* 2006;228:1234–1239.
- Gomes VCL, Del Piero F, Langohr IM, et al. Equine focal mucopurulent placentitis associated with *Stenotrophomonas maltophilia*. *Equine Vet Educ*. doi: <https://doi.org/10.1111/eve.13310>.
- Volkman DH, Williams JH, Henton JH, et al. The first reported case of equine nocardioform placentitis in South Africa. *J S Afr Vet Assoc* 2001;72:235–238.
- Cattoli G, Vascellari M, Corrò M, et al. First case of equine nocardioform placentitis caused by *Crossiella equi* in Europe. *Vet Rec* 2004;154:730–731.
- Chopin J, Muscatello G, Goswami P, Begg A. Nocardioform placentitis from Australia with implications for EAFL and MRLS. *SPONSORS* 2010;94.
- Hanlon DW, McLachlan AD, Gibson I. The first reported case of equine Nocardioform placentitis in New Zealand. *N Z Vet J* 2016;64:198–199.
- Donahue JM, Williams NM, Sells SF, et al. *Crossiella equi* sp nov., isolated from equine placentas. *Int J Syst Evol Microbiol* 2002;52:2169–2173.
- Labeda DP, Donahue JM, Williams NM, et al. *Amycolatopsis kentuckyensis* sp. nov., *Amycolatopsis Lexingtonensis* sp. nov. and *Amycolatopsis pretoriensis* sp. nov., isolated from equine placentas. *Int J Syst Evol Microbiol* 2003;53:1601–1605.
- Labeda DP, Price NP, Kroppenstedt RM, et al. *Streptomyces atriruber* sp. nov. and *Streptomyces silaceus* sp. nov., two novel species of equine origin. *Int J Syst Evol Microbiol* 2009;59:2899–2903.
- Canisso IF, Ball BA, Erol E, et al. Attempts to induce nocardioform placentitis (*Crossiella equi*) experimentally in mares. *Equine Vet J* 2015;47:91–95.
- The Virtual Nocardioform Placentitis Workshop 2020 (VNPW 2020), September 28, 2020; <https://gluck.ca.uky.edu/nocardioform-sept2020>.
- Fedorca CE, Scoggin KE, Ruby RE, et al. Clinical, pathologic, and epidemiologic features of nocardioform placentitis in the mare. *Theriogenology* 2021 Sep 1;171:155–161.
- Dini P, Carossino M, Loynachan AT, et al. Equine hydrallantois is associated with impaired angiogenesis in the placenta. *Placenta* 2020;93:101–112.
- Cawdell-Smith AJ, Todhunter KH, Perkins NR, et al. Exposure of mares to processionary caterpillars (*Ochrogaster lunifer*) in early pregnancy: An additional dimension to equine amnionitis and fetal loss. *Equine Vet J* 2013;45:755–760.
- El-Sheikh Ali H, Loux SC, Kennedy L, et al. Transcriptomic analysis of equine chorioallantois reveals immune networks and molecular mechanisms involved in nocardioform placentitis. *Vet Res* 2021 Dec;52(1):1–22.
- Medzhitov R. Toll-like receptors and innate immunity. *Nat Rev Immunol* 2001;1:135–145.
- Waring GJ, Robson SC, Bulmer JN, et al. Inflammatory signalling in fetal membranes: Increased expression levels of TLR 1 in the presence of preterm histological chorioamnionitis. *PLoS One* 2015;10:e0124298. e0124298.
- Adams Waldorf KM, Persing D, Novy MJ, et al. Pretreatment with toll-like receptor 4 antagonist inhibits lipopolysaccharide-induced preterm uterine contractility, cytokines, and prostaglandins in rhesus monkeys. *Reproductive sciences* 2008;15:121–127.
- Robertson SA, Wahid HH, Chin PY, et al. Toll-like receptor-4: A new target for preterm labour pharmacotherapies? *Curr Pharm Des* 2018;24:960–973.
- Wolfsdorf KE, Williams NM, Donahue JM. Theriogenology question of the month. Bacterial placentitis attributable to a gram-positive filamentous branching bacillus organism. *J Am Vet Med Assoc* 2000;216:1915–1916.
- Troedsson MH, Ml M. in *Equine reproduction* Vol. 2 (eds McKinnon, Squires EL AO, Vaala WE, & Varner DD) 2359–2367 (Wiley-Blackwell 2011).
- Fedorca CE, Ball BA, Wynn MAA, et al. Alterations of circulating biomarkers during late term pregnancy

- complications in the horse Part II: Steroid hormones and alpha-fetoprotein. *J Equine Vet Sci* 2021;99:103395.
38. Fedorka CE, Ball BA, Walker OF, et al. Alterations of circulating biomarkers during late term pregnancy complications in the horse Part I: Cytokines. *J Equine Vet Sci* 2021;99:103425, 103425.
  39. Erol E, Williams NM, Sells SF, et al. Antibiotic susceptibility patterns of *Crossiella equi* and *Amycolatopsis* species causing nocardioform placentitis in horses. *J Vet Diagn Invest* 2012;24:1158–1161.
  40. Rebello S, Macpherson M, Murchie T, et al. in *Animal Reproduction Science* 432-433 (Elsevier Science BV PO BOX 211, 1000 AE Amsterdam, Netherlands).
  41. LeBlanc M. Ascending placentitis in the mare: An update. *Reproduction in Domestic Animals* 2010;45:28–34.
  42. Bailey CS, Macpherson ML, Pozor MA, et al. Treatment efficacy of trimethoprim sulfamethoxazole, pentoxifylline and altrenogest in experimentally induced equine placentitis. *Theriogenology* 2010;74:402–412.
  43. Murchie TA, Macpherson ML, LeBlanc MM, et al. Continuous monitoring of penicillin G and gentamicin in allantoic fluid of pregnant pony mares by in vivo microdialysis. *Equine Vet J* 2006;38:520–525.
  44. D'el Rey Dantas F, Canisso IF, Li Z, et al. Doxycycline diffuses through the fetoplacental unit of late pregnant mares and accumulates in the joints of resulting foals, in *Proceedings. Am Assoc Equine Pract* 2019;65:61–62.
  45. Ellerbrock RE, Canisso IF, Roady PJ, et al. Diffusion of enrofloxacin to pregnancy fluids and effects on fetal cartilage after intravenous administration to late pregnant mares. *Equine Vet J* 2019;51:544–551. doi: <https://doi.org/10.1111/evj.13044>.
  46. Macpherson ML, Giguère S, Pozor MA, et al. Evidence for anti-inflammatory effects of firocoxib administered to mares with experimentally induced placentitis. *Am J Reprod Immunol* 2021;86:e13396. doi: <https://doi.org/10.1111/aji.13396>.
  47. Curcio BR, Canisso IF, Pazinato FM, et al. Estradiol cypionate aided treatment for experimentally induced ascending placentitis in mares. *Theriogenology* 2017; 102:98–107. doi: <https://doi.org/10.1016/j.theriogenology.2017.03.010>
- <sup>a</sup>van Huele M, El-Sheikh AH, Dini P. Unpublished data, 2021.
- <sup>b</sup>Ruby RE. Unpublished data, 2021.
- <sup>c</sup>Erol E. Unpublished data, 2021.