

Pathology of the Synovium

John X. O'Connell, MB, FRCPC

Key Words: Synovium; Synovitis; Tumor; Crystal; Chondromatosis; Loose body; Arthroplasty

Abstract

Synovium is specialized mesenchymal tissue that is essential for the appropriate function of the locomotor apparatus. It is the site for a series of pathologic processes that are characteristic, and in some cases specific, to this distinctive tissue. In this article, the normal microscopic anatomy of synovium is briefly reviewed. Synovial proliferative disorders, including pigmented villonodular synovitis, giant cell tumor of tendon sheath, hemosiderotic synovitis, and fatty infiltration of the synovial membrane are discussed. Additionally, the subjects of intrasynovial cartilaginous lesions (primary and secondary synovial chondromatosis) and crystal deposition diseases are reviewed. Finally, the response of synovial tissues to implanted foreign materials that are used in large and small joint arthroplasty are described.

Phylogenetically, synovium is one of the newer attributes of the vertebrate locomotor apparatus. The first synovial joints developed in the piscine jaw of ancestors of modern lungfish by an evolutionary process that modified preexisting fibrous and cartilaginous joints, which were the predominant articulation of the early sea- and land-dwelling vertebrates.¹ Embryologically, synovium is derived from specialized mesoderm termed the *interzonal mesenchyme* ■Image 1■.¹ This differentiates from the primitive mesenchyme that lies between developing mobile cartilaginous skeletal elements. Fully developed mature connective tissue retains the capacity to differentiate into synovium as exemplified by the development of adventitial bursae and pseudarthroses and the synovial reaction to fixed foreign implanted material such as breast implants. As *Gray's Anatomy* eloquently proposes, "...once a region of pliant connective tissue is established between rigid skeletal elements [or foreign material], their ultimate separation by a synovial cavity appears to be an evolutionary probability."¹

Normal Anatomy

Synovium is composed of 2 to 3 layers of specialized cells termed *synoviocytes*. The synoviocytes overlie loose connective tissue consisting of fat, collagen, and blood vessels.^{2,3} Synoviocytes, like their mesodermal first cousins, mesothelial cells, grow as layers that surround fluid-filled spaces. By light microscopy, synoviocytes are relatively indistinct, appearing only as flattened, oval, dark-staining nuclei that usually seem removed from the immediate luminal surface by a fine layer of eosinophilic tissue.^{2,3} Most of the time, cytoplasmic borders are not visible, although

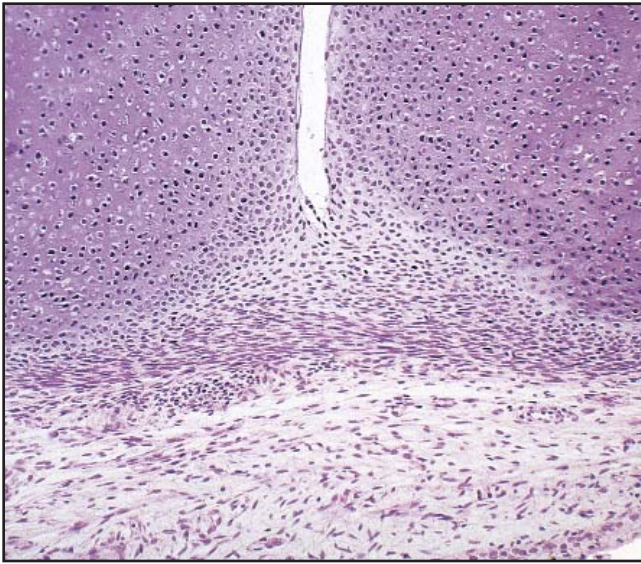


Image 1 Condensed interzonal mesenchyme at the developing synovial joint between 2 fetal cartilaginous long bones (H&E, $\times 150$).

when the cells are stimulated to divide or react to injury, they achieve rounded epithelioid morphologic features. Ultrastructurally, the cells lining the luminal aspect of the synovial cavity have ovoid nuclei, inconspicuous nucleoli, and long cytoplasmic processes that extend in a tendril-like arrangement circumferentially from the nucleus. The cytoplasmic processes contain flattened endoplasmic reticulum, ribosomes, a well-developed Golgi complex, and numerous subplasmalemmal pinocytotic vesicles.²⁻⁴ The processes interdigitate extensively, but cell junctions are not present. The surface synovial cells traditionally have been termed *B cells*.^{3,4} Deep beneath the tangled web of surface cell processes are oval to rounded cells that have nuclear features similar to those of B cells. These so-called A cells lack cytoplasmic processes, but they have short filopodia.^{3,4} The A cells have cytoplasmic organelles similar to those of the B cells, as well as occasional lysosomes. Transitional forms between the A and B cells also are found. A and B cells are embedded in an extracellular matrix rich in collagen and pools of amorphous ground substance.^{3,4}

The supporting connective tissue beneath the surface synoviocytes varies in its composition depending on anatomic site. In large joints that contain folds of synovium, there typically is a well-developed vascular network and relatively abundant mature adipose tissue.⁴ Deep beneath this loose connective tissue is the dense, supporting, fibrous joint capsule. In tendon sheaths, the supporting connective tissue network is scant, and the synovial cells lie in close apposition to the fibrous layer of the tendon sheath or the tendon.^{2,3} Immunohistochemically, synoviocytes stain positively for vimentin and focally for CD68 (KP1). They are not labeled

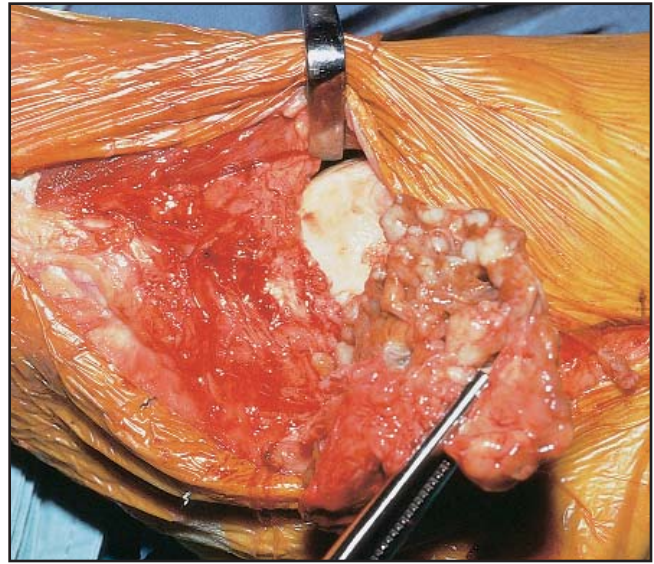


Image 2 The synovial surface of the knee joint (intraoperative photograph) is diffusely nodular, tan-gold, and thickened, the typical appearance of pigmented villonodular synovitis.

by antibodies to cytokeratin, S-100 protein, actins, desmin, CD34, or leukocyte common antigen.⁵

Synovial Proliferative Disorders

Pigmented Villonodular Synovitis and Giant Cell Tumor of Tendon Sheath

Pigmented villonodular synovitis (PVNS) is a proliferative disorder of the synovial lining of joints that produces localized or diffuse nodular thickening of the synovial membrane.⁶⁻¹⁰ Any synovial joint may be affected, but the knee is affected the most frequently.⁶⁻¹⁰ PVNS affects males and females with equal frequency and occurs in a wide age range, with greatest incidence in the second to fourth decades.⁶⁻¹⁰ Patients typically complain of pain, swelling, or both of the affected joint.⁶⁻¹⁰

PVNS appears as a villous and nodular thickening of the synovial membrane **Image 2**. Diffuse involvement of the synovium results in thin, finger-like excrescences admixed with 0.5- to 2.0-cm rounded nodules that cover the normally smooth synovial membrane. Localized nodular synovitis produces a single bulging mass within the synovium.^{6,7,10}

Microscopically, PVNS results in a papillary, villous, and nodular expansion of the synovial membrane. The surface synovial cells overlie a lobular and sheet-like arrangement of mononuclear rounded and epithelioid cells, multinucleated osteoclast-like giant cells, and lipid-rich cells.⁶⁻¹⁰ The mononuclear cells frequently contain large hemosiderin granules and have central round nuclei, often

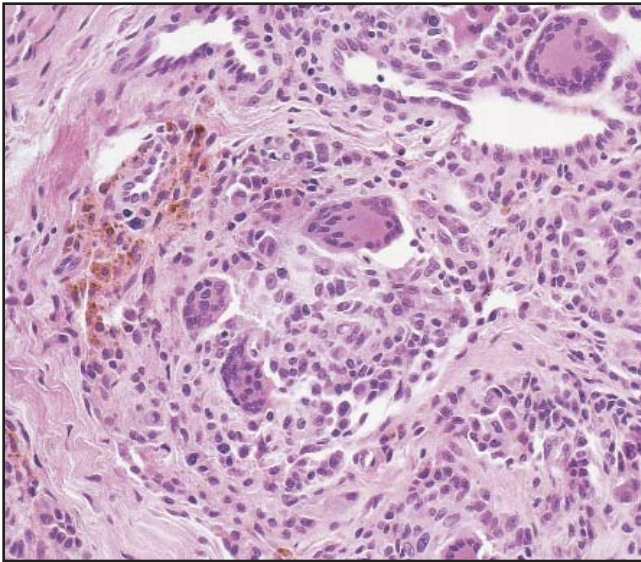


Image 3 A cluster of multinucleated giant cells with an adjacent aggregate of hemosiderin-laden cells (H&E, $\times 200$).

with prominent nucleoli. Mild nuclear pleomorphism often is seen. Mitotic counts rarely exceed 5 per 10 high-power fields. Necrosis is rare. The sheets and nodules of mononuclear cells, which likely represent proliferated surface synovial cells, are embedded in a collagenous stroma.⁵ In some cases, the nodular growth pattern is accentuated by broad bands of collagen. Most of the hemosiderin in PVNS lies beneath the surface synovial layer, and it often is found in aggregates in the rounded nodules **Image 3**.^{6,7,10} A minority of cases of diffuse PVNS can result in bone erosion, sometimes involving adjacent bones of a joint.⁶

PVNS is treated by surgical excision. Localized disease responds well to this approach; however, lesions that diffusely affect the synovium have a high rate of local recurrence (>50%).^{8,9} PVNS that is refractory to repeated surgical excisions may be managed by low-dose radiation therapy.¹¹

Localized giant cell tumor of tendon sheath (GCTTS) is histologically virtually identical to PVNS and represents its extra-articular analogue.⁶ GCTTS may arise in any synovial sheath; however, the tendon sheaths of the hands are affected preferentially **Image 4**.^{5-7,10,12} Because of restricted space, localized GCTTS usually is small and only rarely exceeds 2.0 cm. However, diffuse GCTTS, which arises in extra-articular bursae, may exceed 10.0 cm.^{6,13} Unlike PVNS, GCTTS is grossly exclusively nodular, although microscopically it is identical to an individual lobule of PVNS.^{5,6} In general, GCTTS contains less hemosiderin than does PVNS. Diffuse GCTTS frequently demonstrates microcystic cleft-like spaces.

When GCTTS is treated by local excision, local recurrence is approximately 10% to 20%. As with PVNS, some

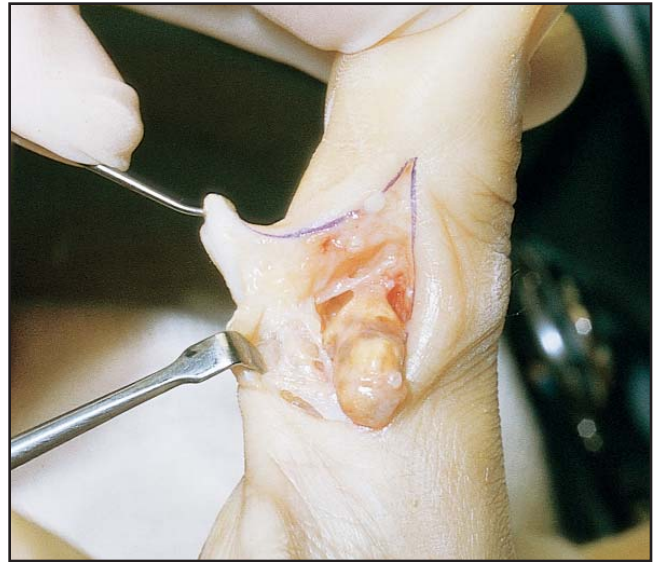


Image 4 Characteristic golden-brown circumscribed nodule of giant cell tumor of tendon sheath. Note the attachment to the synovial sheath.

GCTTS may exhibit local aggressive growth, including invasion of bone.^{6,8,10}

Immunohistochemically, PVNS and GCTTS have a similar staining reaction to normal and reactive synovium, ie, the mononuclear cells and multinucleated osteoclast-like giant cells react positively with antibodies to CD68 and vimentin.⁵ Ultrastructurally, PVNS and GCTTS are composed of cells that predominantly exhibit intermediate features of type A and B cells.^{12,14}

Whether PVNS/GCTTS represents a neoplasm or an exuberant reactive proliferation is controversial. The detailed microscopic observations of Jaffe et al⁶ have provided most of our understanding and classification of these synovial proliferations, and they believed that the proliferations were nonneoplastic reactive lesions. This has been the predominant viewpoint for many years. More recently, however, cytogenetic abnormalities, including trisomy 7, have been identified in short-term cell cultures of PVNS and GCTTS.^{15,16} This has been suggested as evidence that they are true neoplasms.^{15,16} An alternative method of evaluating clonality in cell populations from females involves assaying for patterns of X chromosome inactivation. By using this method, some investigators have demonstrated that GCTTS is composed of a nonclonal population of cells,¹⁷ supporting the original assertions of Jaffe et al.⁶

Hemosiderotic Synovitis

Hemosiderotic synovitis develops as a result of chronic intra-articular hemorrhage. It occurs in hemophiliac males who are predisposed to hemarthrosis, especially of the knees.¹⁸⁻²⁰ Patients with hemosiderotic synovitis typically

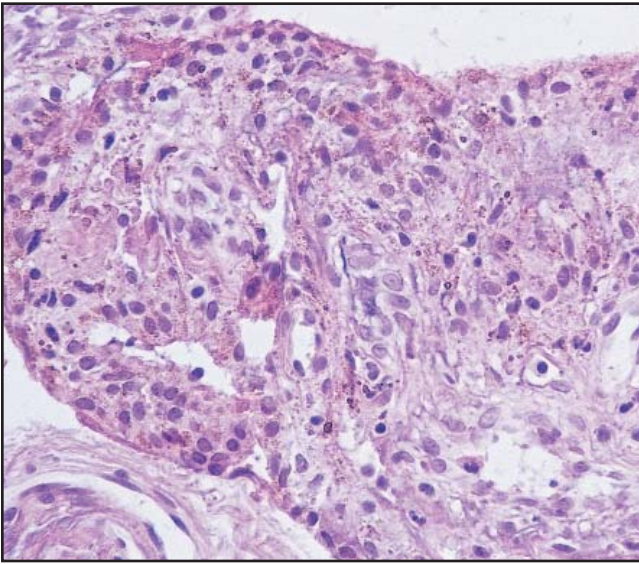


Image 5 Fine granules of hemosiderin within surface synovial cells and macrophages. There are no nodules or sheets of proliferated synovial cells (H&E, $\times 200$).

complain of pain and stiffness of the involved joint, because almost invariably, secondary osteoarthritis develops in association with chronic intra-articular hemorrhage.^{18,20,21}

Hemosiderotic synovitis appears as a brown or rust color of the normal glistening translucent synovial membrane. In early hemosiderotic synovitis, fine villous projections extend into the joint cavity, but the larger nodules and thickened fronds of PVNS do not occur. In the later stages, after chronic repeated hemorrhage, the synovium becomes thickened and opaque owing to intrasynovial and subsynovial fibrous scarring.^{19,20}

In hemosiderotic synovitis, cuboidal, plump, surface synovial cells contain granules of hemosiderin, and they line the flat synovial surfaces and the villous processes.^{19,22} In addition, hemosiderin-laden macrophages lie within the subsynovial connective tissue, often in association with small blood vessels **Image 5**.^{19,22} Sheets of mononuclear synovial cells, lipid-laden cells, or multinucleated osteoclast-like giant cells are not a feature of hemosiderotic synovitis.

Hemosiderotic synovitis often is associated with severe degenerative articular cartilage disease. Hence, the treatment revolves around surgical and conservative management of the arthritis.^{18,20}

A subset of hemosiderotic synovitis is caused by intrasynovial hemangiomas.²²⁻²⁴ These are rare tumors; fewer than 200 have been reported.²² Any joint may be affected, although the knee is the most frequent site.²² Intrasynovial hemangiomas are localized tumors that occur exclusively within the supporting synovial connective tissue. Most patients complain of pain, a mass, or both. The hemangiomas traditionally are classified as capillary, cavernous,



Image 6 Diffuse papillary thickening of the synovial membrane by mature fat typical of lipoma arborescens.

and arteriovenous types. They average about 4.0 cm.²² Occasionally, thrombosed large vascular spaces with papillary endothelial hyperplasia may be found. Intra-articular hemorrhage may cause acute pain and swelling of the joint and, if repeated, may produce histologic features of hemosiderotic synovitis.²² The hemorrhage is rarely as progressive as that in the bleeding diatheses, and accelerated osteoarthritis is not usually a feature. Synovial hemangiomas are managed by local excision, and recurrence is uncommon.

Villous Lipomatous Proliferation of the Synovial Membrane (Lipoma Arborescens)

Lipoma arborescens, which is characterized by fatty infiltration of the subsynovial connective tissue, is one of the rarest of the synovial proliferative lesions.²⁵ The disorder preferentially affects adult men and manifests as a slowly developing swelling.²⁵⁻²⁹ Any synovial-lined joint may be involved, but the knee is the favored site.²⁵ Grossly, the entire synovium assumes a bright yellow, nodular, papillary appearance. It does not have the golden-brown color of PVNS or hemosiderotic synovitis **Image 6**.²⁵⁻²⁹ Microscopically, the subsynovial connective tissue is thickened massively by an infiltrate of mature adipose tissue.²⁵⁻²⁹ The surface synovial cells typically appear reactive and epithelioid. Mitoses are not found. Minor degrees of fatty infiltration of the subsynovial space are normal in certain parts of the synovial membrane, particularly in the knee joint, and slight nodular thickening is a nonspecific finding in the synovium of osteoarthritic joints. In a single microscopic field, this may simulate lipoma arborescens, but this diagnosis should be made only when there is diffuse villous and nodular involvement.

Most investigators think that lipoma arborescens is nonneoplastic and merely represents an excessive accumulation of fat in the subsynovial space.²⁵ The cause is unknown. Treatment is synovectomy, and recurrence is rare.

Cartilage and Crystals

Cartilaginous Lesions of the Synovium

Primary Synovial Chondromatosis

In primary synovial chondromatosis, multiple nodules of metaplastic hyaline cartilage expand the subsynovial connective tissue.³⁰⁻³² This disorder affects patients in a wide age range from childhood to late adult life; the disease shows no sex preference.³⁰⁻³² Patients complain of pain and swelling related to the involved joint.³⁰⁻³² Any joint may be affected, including the extra-articular synovial tendon sheaths.^{33,34} There is no association between synovial chondromatosis and antecedent trauma, although an injury may draw attention to an involved joint.

Synovial chondromatosis appears as numerous glistening blue-gray nodules in the synovial membrane **Image 7**.³⁰⁻³⁴ Nodules range from 2.0 mm to more than 1.0 cm and are firm on cut section. They often demonstrate chalky yellow regions that represent calcification, foci of enchondral ossification, or both.

Microscopically, nodules of hypercellular hyaline cartilage are embedded in the synovial connective tissue.³⁰⁻³⁴ Individual nodules are circumscribed and round and demonstrate greater cellularity than articular cartilage. Chondrocytes

typically are clustered rather than evenly distributed throughout the matrix.³⁰⁻³⁴ The individual cells exhibit a considerable size range and nuclear chromaticity. Most have pyknotic dark-staining nuclei, but many cells have atypical features, including large nuclei, dispersed chromatin, and nucleoli. Occasional mitoses may be found. The degree of cellularity and nuclear atypia found in synovial chondromatosis in most cases equals or exceeds that seen in low- and intermediate-grade intraosseous chondrosarcoma **Image 8**.³⁰⁻³⁴ Hence, care must be taken to avoid an erroneous diagnosis of malignant neoplasm in this setting. Knowledge of the radiographic and clinical features is, therefore, essential. Enchondral ossification, when present, proceeds from the periphery toward the center of the lobules. Synovial chondromatosis is managed by synovectomy of the involved joint. Recurrence develops in up to 15% of cases.³⁵

Bona fide chondrosarcomas of synovium are extremely rare neoplasms.^{35,36} These tumors may arise de novo or secondary to preexisting primary synovial chondromatosis.³⁶ The exact incidence of the latter event is unknown but generally is considered rare. A recent review of cases of synovial chondromatosis managed at a single hospital in Northern Ireland demonstrated the surprisingly high rate of malignant transformation of 5%.³⁵ Clinical and radiographic information is extremely important for establishing a diagnosis of synovial chondrosarcoma. The chondrosarcomas are frequently larger than synovial chondromatosis and more consistently present as soft tissue masses.³⁶ Bone destruction adjacent to the joint also should arouse suspicion,³⁶ although this also may be seen in a minority of cases of synovial chondromatosis.³⁵ Histologically, chondrosarcomas of the

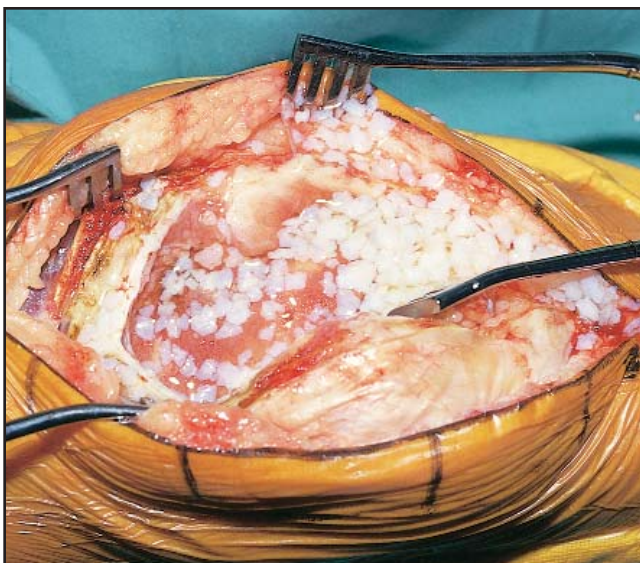


Image 7 Knee arthroscopy. Innumerable nodules of glistening blue hyaline cartilage are demonstrated throughout the synovial surface.

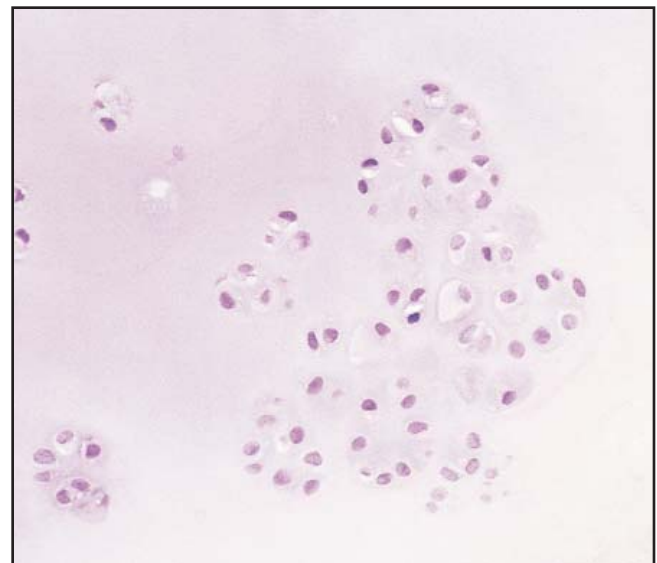


Image 8 Typical clustered arrangement of mildly atypical chondrocytes characteristic of synovial chondromatosis (H&E, ×200).

synovium exhibit diffuse hypercellularity that lacks the chondrocyte clustering typical of synovial chondromatosis.^{35,36} In addition, spindling of tumor cells at the periphery of lobules suggests chondrosarcoma. The degree of nuclear atypia is not helpful for establishing a diagnosis of malignant neoplasm unless extreme anaplasia is present, since primary synovial chondromatosis characteristically has mild to moderate atypia of the chondrocyte nuclei.³⁶ Mitotic figures and myxoid change of the stroma favor a diagnosis of malignant neoplasm.³⁶ The most useful and definitive finding for a diagnosis of malignant neoplasm is permeative destructive invasion of the bones around the joint.^{35,36} When benign synovial chondromatosis “invades” bone, it does so in a pushing manner, which is in contrast with the permeative growth that characterizes chondrosarcoma. When chondrosarcoma develops in the synovium, it typically is high-grade, and pulmonary metastases frequently occur.^{35,36}

Secondary Synovial Chondromatosis and Loose Bodies

“Loose” bodies develop when intra-articular fragments of bone or hyaline articular cartilage come to lie free in the joint cavity.³⁰ Causes of loose bodies include idiopathic epiphyseal osteonecrosis, osteochondral fracture, and osteochondritis dissecans.^{37,38} Some of these “loose” fragments are incorporated rapidly in papillary folds of synovium and, thus, are attached to the lining of the joint by a long pedicle, permitting mobility within the joint cavity. This interposition of the fragment between the articulating ends of the bones causes joint locking, which is the cardinal symptom of intra-articular loose bodies.³⁷ Other symptoms include pain and swelling.³⁰

Loose bodies may be single or multiple and often are larger than individual nodules of synovial chondromatosis, measuring more than 1.5 cm each. The external aspect of an individual loose body is hard, white, and usually nodular and bosselated. Sectioning the nodule sometimes demonstrates the central osteoarticular fragment that initiated the process.^{37,38}

Loose bodies are composed predominantly of reactive or metaplastic cartilage; however, in contrast with synovial chondromatosis, this is usually not lobular and exhibits features intermediate between hyaline cartilage and fibrocartilage.^{30,37,38} The matrix typically stains eosinophilic in H&E-stained sections and exhibits a more uniform cellularity than primary synovial chondromatosis, in addition to a distinctly laminar arrangement of cells and matrix **Image 9**. Loose bodies rarely have the chondrocyte pleomorphism, atypia, and mitotic activity that are features of synovial chondromatosis.

The inciting fragment is frequently at the center of the loose body.^{37,38} It is usually hyaline articular cartilage or an osteochondral fragment consisting of articular cartilage and

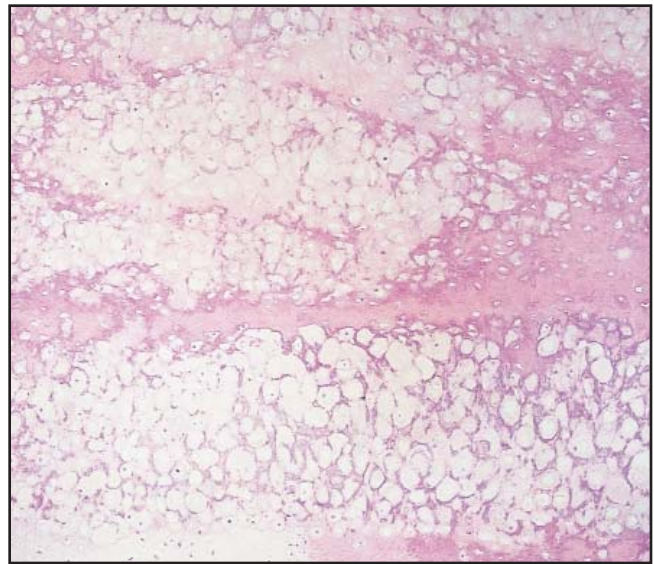


Image 9 Laminated eosinophilic cartilage matrix. Note the even distribution of the chondrocytes and the lack of clustering (H&E, $\times 150$).

subchondral bone plate. The latter may seem viable or necrotic depending on the underlying disease that produced the loose body. At the edge of the inciting fragment, osteoclastic resorption is frequently prominent, and islands of metaplastic cartilage “invade” and replace its substance.³⁸ Careful examination of the external surface of the loose body may reveal an attenuated layer of synovium, at least focally. This layer of cells is, however, extremely fragile and not uncommonly is removed by handling the specimen, explaining its frequent apparent absence.

Loose bodies are managed by local removal only; total synovectomy is unnecessary. Recurrences are less common than for primary synovial chondromatosis and depend on the underlying disease process.

Crystal-Induced Synovial and Joint Diseases

Deposition of crystals within synovium, articular cartilage, and periarticular soft tissue is associated with a spectrum of clinical conditions ranging from asymptomatic soft tissue aggregates through severe chronic destructive arthropathies.^{39,40} The 3 endogenously formed crystals that produce disease are monosodium urate, calcium pyrophosphate dihydrate, and calcium hydroxyapatite.

Crystal formation occurs slowly and requires months or years to develop. In general, crystal deposition needs locally elevated levels of the precrystalline constituents in the affected tissues. In addition, alterations in composition and structure of the extracellular matrix contribute to crystal formation.

The pathogenesis of joint destruction and synovial inflammation is related to the ingestion of the crystals by

phagocytic cells. They release chemotactic agents that magnify the inflammatory reaction.³⁹ Ultimately, the bone, cartilage, and soft tissue injury that characterizes all of the crystal deposition diseases is produced by enzymatic degradation of the osseous and cartilaginous extracellular matrix.³⁹ The stimulus that initiates the inflammatory reaction in each crystal deposition disorder varies and often is incompletely known.

Monosodium Urate Crystal Deposition Disease (Gout)

Gout is a systemic disease characterized by elevated serum uric acid levels to more than 7 mg/dL (0.42 mmol/L), tissue deposits of monosodium urate (tophi), recurrent acute arthritis precipitated by urate deposits, and renal disease, including uric acid lithiasis.³⁹ Gout is relatively common, with an overall prevalence of 2 per 1,000 of the population; however, the prevalence increases dramatically with age to a rate of 15 per 1,000 in men during the fourth and fifth decades of life.³⁹ About 30% of patients have primary hyperuricemia. The remaining 70% exhibit hyperuricemia secondary to another disease, usually renal failure, or as an adverse effect of drug therapy.³⁹

Tophi may occur at any connective tissue site, but the first metatarsophalangeal joint and the soft tissues around the pinna of the ear are affected preferentially.⁴⁰ Acute attacks of gout may be precipitated by sudden changes in serum uric acid levels, trauma, and a variety of other causes. Clinically, acute gouty arthritis closely mimics acute septic arthritis and manifests as a painful, swollen, red joint.³⁹ After resolution of the first attack, patients may remain asymptomatic or chronic gouty arthritis may develop.³⁹

Pathology.—Monosodium urate crystal deposits within synovium result in a papillary thickening and opacification of the membrane.^{40,41} The tophi are cream-white and usually soft. Larger tophi may be tan because of abundant admixed fibrous tissue, and these may manifest clinically as hard nodules. Since monosodium urate is dissolved by aqueous solutions, formalin fixation and conventional tissue processing usually result in the loss of the crystal from tissue sections.^{40,41} If white deposits are recognized on fresh or even partially fixed gross specimens, smearing the material on a slide with a blade is an effective way to identify the crystals. Microscopically, these smear preparations demonstrate elongated needle-shaped crystals that are refractile and exhibit intense negative birefringence when viewed with red-compensated polarized light **Image 10**. The crystals usually can be recognized readily based on their shape and intense birefringence alone. Since they are dissolved by water, the most efficient way to recognize them in tissue sections is to perform a frozen section of the affected region or process tissue that has been fixed in absolute alcohol using a processing cycle that eliminates extended exposure to

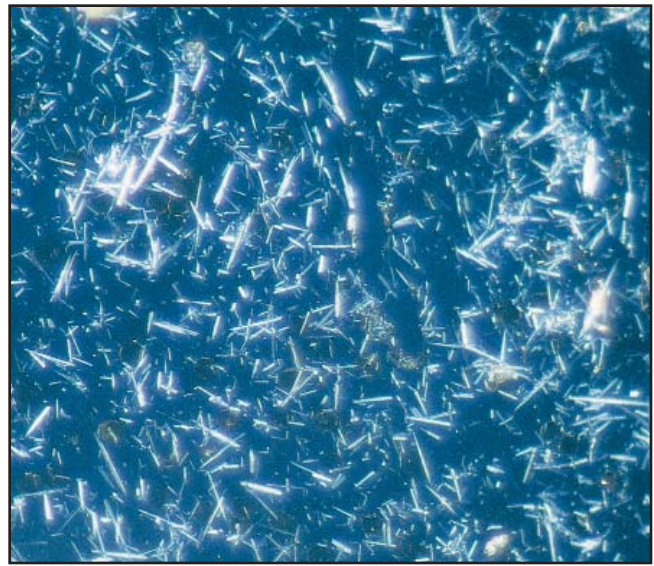

Image 10 Intensely birefringent needle-shaped crystals from a smear preparation of unfixed tissue viewed with polarized light (×200).

formalin or dilute alcohol.^{40,41} Minor losses of crystal occur during staining; however, enough crystals usually survive to be visible in H&E-stained sections. The monosodium urate appears as amorphous granular aggregates of yellow-brown material embedded in thickened fibrotic synovium.^{40,41} Usually, the deposits are associated with a brisk histiocytic and foreign body giant cell reaction. If the synovium or any connective tissue deposit of monosodium urate has been processed routinely, all of the crystals usually are dissolved.⁴¹ By light microscopy, pools of pale blue to eosinophilic amorphous material remain at the site of previous crystal deposition, representing the proteinaceous matrix that surrounds the crystals. It survives the tissue-processing and staining procedures. Frequently, this matrix bears the imprint of the crystals, which are arranged as linear clusters, and, hence, a fibrillary or feathery pattern of lines may be seen within this substance **Image 11**.⁴¹ Larger tophi may exhibit ossification at their periphery, and, similarly, intraosseous deposits commonly show ossification. In acute attacks of gouty arthritis, the synovial membrane contains a dense neutrophilic infiltrate in addition to the crystal deposits. Joint aspiration is an equally effective way of identifying the needle-like crystals of monosodium urate during an acute attack.

Calcium Pyrophosphate Dihydrate Crystal Deposition Disease (Pseudogout)

Pseudogout is so named because it is a clinical syndrome characterized by recurrent paroxysmal attacks of severe arthritis that may proceed to a chronic destructive arthropathy.^{39,40,42} Like gout, the acute and chronic joint

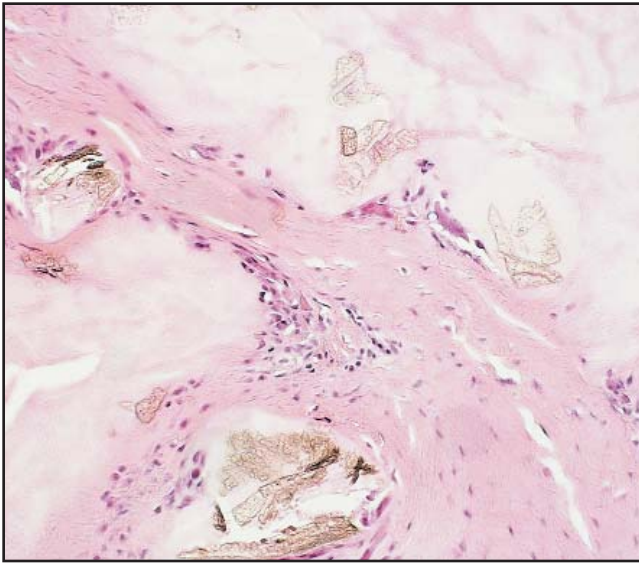


Image 11 In this formalin-fixed conventionally processed section, most of the crystals have been dissolved (H&E, $\times 200$).

injury is a manifestation of intra-articular crystal deposition, in this case, calcium pyrophosphate dihydrate ($\text{Ca}_2\text{P}_2\text{O}_7 \cdot 2\text{H}_2\text{O}$). In addition to deposits in the synovial membrane and periarticular tissues, crystals also are found in hyaline articular cartilage, fibrocartilaginous menisci, and intervertebral disks (chondrocalcinosis).⁴³⁻⁴⁶ Chondrocalcinosis affects up to 15% of adults older than 65 years, and radiographically detectable deposits are present in the hyaline and fibrocartilage of the knees, symphysis pubis, and wrist.^{39,42} Chondrocalcinosis and pseudogout occur as primary idiopathic abnormalities in about 90% of affected persons. Pseudogout also is associated with other metabolic disorders, including hyperparathyroidism, gout, hemochromatosis, and hypophosphatasia.³⁹

Acute pseudogout arthritis most commonly develops in the knee. Patients typically seek care because of an acutely inflamed joint. Synovial fluid aspiration reveals an elevated polymorphonuclear leukocyte count and free and intracellular calcium pyrophosphate dihydrate crystals (within neutrophils). These crystals are considerably shorter than monosodium urate crystals and are rhomboidal rather than needle-shaped.⁴³⁻⁴⁶ In addition, they demonstrate positive birefringence when examined with compensated polarized light. *Chronic pyrophosphate arthropathy* refers to an accelerated form of destructive arthritis that radiographically and clinically closely resembles severe osteoarthritis.⁴²

Pathology.—Grossly, the synovial deposits of calcium pyrophosphate dihydrate appear as flecks of chalky white material on the surface of the membrane. These rarely achieve the large size of gouty deposits. In addition to the synovial crystals, similar deposits are present in the articular

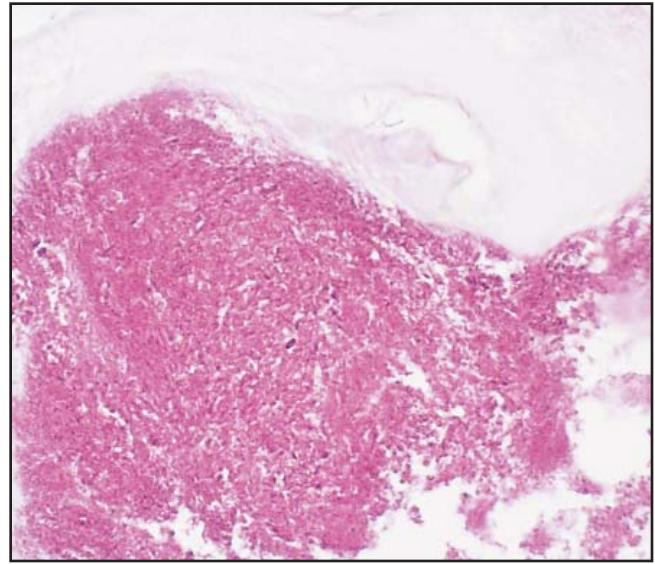


Image 12 High-power view of one of the deposits demonstrating the granular staining and lack of a cellular reaction (H&E, $\times 300$).

cartilage and fibrocartilaginous menisci. Microscopically, pyrophosphate deposits appear dark blue to purple in nondecalcified H&E-stained slides.^{45,46} These deposits have a distinctly granular appearance that may be enhanced by lowering the microscope condenser or reducing the intensity of the light source. **Image 12**. Examination with polarizing light usually identifies only a few short rhomboidal crystals; however, a larger number of crystals may be seen on unstained slides.^{43,44} Within the articular cartilage and fibrocartilage, the crystal deposits characteristically are not associated with a histiocytic or foreign body giant cell reaction. However, the chondrocytes in the vicinity of the deposits may exhibit “degenerative” features, including swelling and a basophilic alteration of the adjacent cartilage matrix.⁴⁵ These cells are thought to represent the source of the pyrophosphate that forms the crystalline deposits.⁴⁵ The synovial deposits are associated with small foci of metaplastic cartilage, and these more commonly elicit a histiocytic reaction.⁴⁵ Decalcification of tissue often results in complete removal of the crystals and leaves oval to rounded pools of basophilic material. They often lack a cellular reaction and may be overlooked easily. Like the gouty deposits that have been dissolved in aqueous solution, the regions of decalcified pyrophosphate demonstrate a fibrillar or feathery appearance; however, the striations are shorter than those in gouty tophi.

Basic Calcium Phosphate (Hydroxyapatite) Crystal Deposition Disease

Hydroxyapatite crystal deposition disease is the least well known but possibly the most common of these disorders.³⁹ The basic calcium phosphates are the calcium crystals

that are found in periarticular soft tissues, most frequently around the shoulder joint, and are responsible for the clinical syndrome known as *calcific tendinitis*.⁴⁷⁻⁴⁹ These crystals also may be found in tendons and synovial sheaths at multiple other locations and in intervertebral disks.⁵⁰ Clinically, calcific tendinitis produces recurrent acute episodes of shoulder pain that frequently evolves into chronic shoulder disability.^{39,50} Intra-articular deposition of the basic calcium salts may produce a rapidly destructive arthritis. This accelerated arthritis is most common in elderly women and may occur in any joint.⁵¹ Unlike gout and pseudogout, which are associated with acute synovitis, in hydroxyapatite crystal deposition disease, the destructive arthritis and synovitis lack an acute inflammatory component.

Pathology.—Synovial deposition of basic calcium phosphate is associated with a papillary and fibrous thickening of the membrane.⁵⁰ Macroscopically, recognizable crystal deposits appear cream-white and occasionally aggregate to produce small cysts that discharge viscous, paste-like material when incised.⁵⁰ Individual calcium hydroxyapatite crystals are extremely small, measuring only 75 to 250 nm, and they cannot be resolved by the light microscope. Specific identification of these crystals, therefore, can be accomplished only by transmission electron microscopy or x-ray diffraction studies.⁴⁹⁻⁵¹ By light microscopy, the crystals may be recognized when they aggregate into large clumps. The crystals stain blue-purple by H&E before decalcification and palely eosinophilic or basophilic after decalcification.^{47,50} The undecalcified crystal aggregates are poorly refractile and do not exhibit birefringence. A laminated psammomatous appearance usually can be appreciated in at least some of them **Image 13**.⁴⁷ In joint fluids, the aggregated crystals form irregularly sized and shaped microspheroids. In soft tissue, the hydroxyapatite is associated variably with a histiocytic or foreign body giant cell reaction; however, a neutrophilic inflammatory reaction is not seen.⁵⁰ Intra-articular deposition of the crystals frequently is associated with severe destructive degenerative joint disease.⁵² It is postulated that histiocytic and synovial ingestion of the crystals stimulates proteolytic enzyme release that contributes to the breakdown of cartilage and tendon.⁵⁰ Crystal deposition in tendons near their osseous origin or insertion may result in cortical erosion and simulate a malignant bone neoplasm.⁵³

Synovial Reaction to Loosened Joint Arthroplasties

Large Joint Detritic Synovitis

Large joint arthroplasty is one of the most common elective orthopedic surgical procedures performed. More

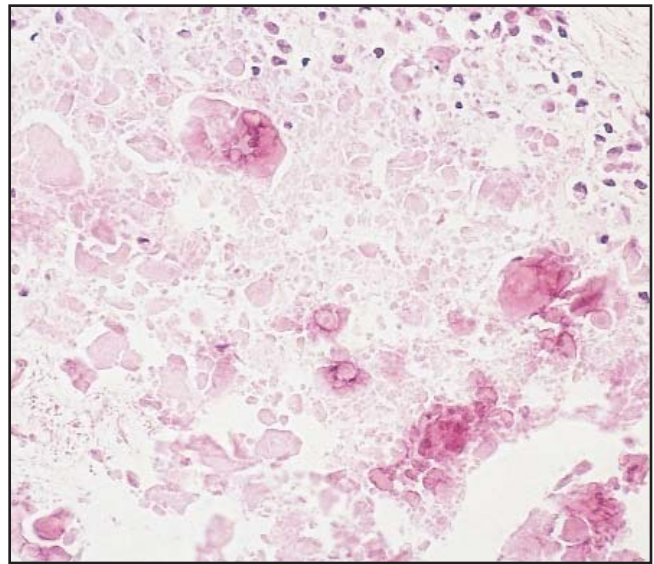


Image 13 Partially decalcified tissue section of a calcium hydroxyapatite crystal deposit within a synovial tendon sheath. Note the psammomatous appearance of the undecalcified crystals (H&E, $\times 200$).

than 120,000 such operations are performed each year in the United States, and the results of these are generally excellent.⁵⁴ Complications are few; however, as arthroplasties have been performed on younger and more physically active patients, an increased incidence of aseptic loosening of the prostheses has occurred.⁵⁵ This loosening occurs because the materials used in large joint reconstruction, ie, polyethylene, metal alloys, and methyl methacrylate (bone cement), although highly durable and relatively inert, have a tendency to undergo mechanical failure over time, particularly with excessive use. In vivo, this mechanical failure usually is manifested by progressive fragmentation of the components.^{54,56,57} This fragmentation occurs at the interface between moving parts of the artificial joint or between host tissue and foreign material. The net result is that microscopic fragments of the arthroplasty components are extruded into the joint cavity where they elicit an inflammatory reaction.^{54,56,57} This reaction usually is accompanied by osteolysis of the involved bones, producing clinically detectable loosening of the arthroplasty. The cardinal symptom of loosened prostheses is progressive pain.⁵⁵

Pathology

Detritic synovitis is the descriptive term applied to the constellation of changes seen in the synovium and soft tissue that surrounds loose large joint arthroplasties. The most commonly involved joints are the hips and knees. Detritic synovitis manifests as red-tan nodular thickening of the synovium.⁵⁴ In a few cases, the synovium may be black owing to the extensive deposition of metal debris.

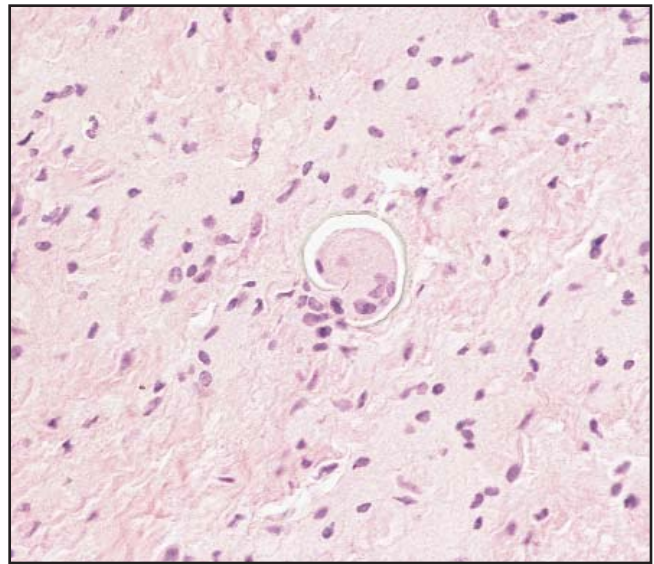
In detritic synovitis, particles of synthetic material in the synovium are associated with an intense histiocytic and foreign body giant cell reaction.^{54,56,57} The histiocytes are oval and rounded and have abundant eosinophilic foamy to granular cytoplasm. Nuclei are central and round and lack nucleoli. Mitoses are not seen. Three types of foreign material are recognizable.⁵⁴ Methyl methacrylate is dissolved during tissue processing. It elicits a foreign body giant cell reaction that surrounds large oval and rounded defects. The defects appear empty but often contain fine granules of refractile nonpolarizable barium.⁵⁴ Needle-shaped fragments of polyethylene also are found in foreign body giant cells.^{54,56,57} These fragments are typically small and may be overlooked unless the slides are examined under polarized light. Larger pieces of polyethylene appear green-yellow with conventional H&E stains ■ **Image 14**.⁵⁴ The metal debris is the most inconspicuous and, therefore, most easily overlooked of the foreign material. Although the metal particles rarely exceed 50 μm , most pieces measure less than 1 μm and are dispersed evenly as single fragments in the cytoplasm of histiocytes.^{54,56,57} Additional histologic findings include papillary fibrocartilaginous metaplasia of the synovial surface, sheets of coagulative necrosis without inflammation, aggregates of hemosiderin-laden macrophages, and, in a few cases, reactive myofibroblastic proliferations that resemble nodular-proliferative fasciitis.⁵⁴ Stromal infiltrates of neutrophils are correlated strongly with bacterial infection surrounding the prosthesis.^{54,56,57}

Particles of metal and polyethylene and the typical histiocytic reaction that accompanies them can be found in regional lymph nodes. The lymph nodes often are enlarged and may be suggestive of malignant tumor.⁵⁸ This can result in confusion at the time of staging procedures performed during treatment of pelvic malignant neoplasms, usually prostatectomy in men and hysterectomy and oophorectomy in women.

Detritic synovitis occurs in a background of loose large joint prostheses, and, hence, its management revolves around reconstruction of the affected joint. This frequently is troublesome because of the severe localized osteoporosis that usually accompanies loosening of the prosthesis.

Small Joint Detritic Synovitis

The prostheses used to replace damaged small synovial joints, such as those in the hands and feet, are different from those used for large joint arthroplasty. Small joint prostheses are composed of silicone polymers. Silicone (dimethylsiloxane) is composed of carbon, oxygen, hydrogen, and silica. Depending on the length of polymer chain and the degree of cross-linking between individual chains, silicone



■ **Image 14** Curving yellow piece of polyethylene within a foreign body giant cell (H&E, $\times 200$).

may have the properties of a liquid, a gel, or a solid. The solid silicone prostheses, which often are referred to by their proprietary name, Silastic, have been used extensively for small joint reconstruction. Like their large joint counterparts, they have, for the most part, been extremely successful for alleviating pain and dysfunction. Unfortunately, as with large joint arthroplasties, a minority of patients encounter problems due to mechanical failure, particularly in joints subjected to great degrees of stress and activity, such as the thumb and hallux.⁵⁹⁻⁶¹ The abraded silicone particles are capable of eliciting an inflammatory reaction that differs somewhat from large joint detritic synovitis.

Pathology

Small joint detritic synovitis produces a nodular thickening of synovial membrane similar to its large joint counterpart.⁵⁹⁻⁶¹ Blackening of the membrane does not occur since metal alloys are not a part of these prostheses. Microscopically, the subsynovial space is expanded by a histiocytic and multinucleated giant cell infiltrate that surrounds small fragments of yellow-green lobulated foreign material (the fragmented solid phase silicone).⁵⁹⁻⁶¹ This material predominantly occurs in the cytoplasm of mononuclear histiocytes, synovial cells, and multinucleated giant cells; however, small pieces may be found in an entirely extracellular location ■ **Image 15**. Solid silicone is refractile but not birefringent and, hence, is not visible when viewed with polarized light.⁵⁹⁻⁶¹ Neutrophils typically are not found unless there is a coexistent bacterial infection. Other changes in the synovial membrane include scattered lymphocytes and plasma cells, strands of fibrous tissue, and embedded shards of bone. The latter probably arise from the adjacent bones,

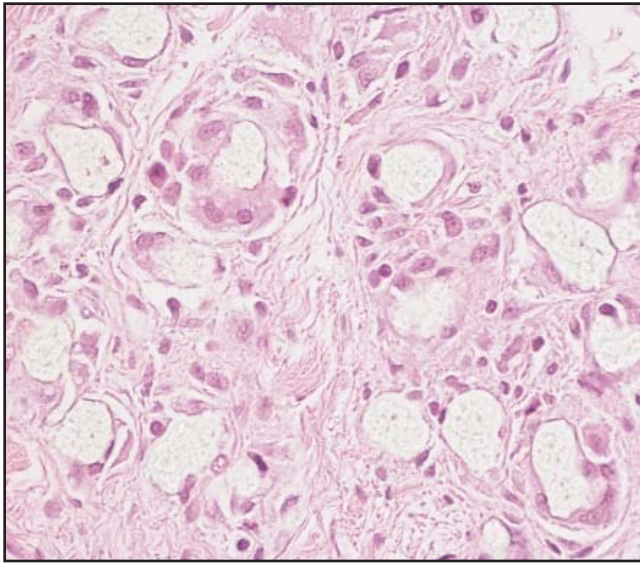


Image 15 Intracellular green-yellow fragments of silicone debris (H&E, ×300).

which also may contain large amounts of silicone particles.^{60,61} In a few cases, the intraosseous silicone elicits intense osteoclastic resorptive activity that may produce radiographically and surgically detectable cystic defects.⁶² Silicone synovitis is managed by thorough curettage and reconstruction of the affected joint, if possible.

From the Department of Pathology, Vancouver General Hospital, Vancouver, British Columbia.

Address reprint requests to Dr O'Connell: Dept of Pathology, Vancouver General Hospital, 855 W 12th Ave, Vancouver, BC Canada V5Z 1M9.

References

- Williams PL, Warwick R. Arthrology. In: Williams PL, Warwick R, eds. *Gray's Anatomy*. 36th ed. Edinburgh, Scotland: Churchill-Livingstone; 1980:424-425.
- Cohen MJ, Kaplan L. Histology and ultrastructure of the human flexor tendon sheath. *J Hand Surg Am*. 1987;12:25-29.
- Schmidt D, Mackay B. Ultrastructure of human tendon sheath and synovium: implications for tumor histogenesis. *Ultrastruct Pathol*. 1982;3:269-283.
- Steinberg PJ, Hodde KC. The morphology of synovial lining of various structures in several species as observed with scanning electron microscopy. *Scanning Microsc*. 1990;4:987-1020.
- O'Connell JX, Fanburg JC, Rosenberg AE. Giant cell tumor of tendon sheath and pigmented villonodular synovitis: immunophenotype suggests a synovial cell origin. *Hum Pathol*. 1995;26:771-775.
- Jaffe HL, Lichtenstein L, Sutro CJ. Pigmented villonodular synovitis, bursitis and tenosynovitis. *Arch Pathol*. 1941;31:731-765.

- Dorwart RH, Genant HK, Johnston WH, et al. Pigmented villonodular synovitis of synovial joints: clinical, pathologic and radiologic features. *AJR Am J Roentgenol*. 1984;143:877-885.
- Myers BW, Masi AT, Feigenbaum SL. Pigmented villonodular synovitis and tenosynovitis: a clinical epidemiologic study of 166 cases and literature review. *Medicine (Baltimore)*. 1980;59:223-238.
- Schwartz HS, Unni KK, Pritchard DJ. Pigmented villonodular synovitis: a retrospective review of affected large joints. *Clin Orthop*. 1989;247:243-255.
- Rao AS, Vigorita VJ. Pigmented villonodular synovitis (giant cell tumor of tendon sheath and synovial membrane): a review of eighty-one cases. *J Bone Joint Surg Am*. 1984;66:76-94.
- O'Sullivan B, Cummings B, Catton C, et al. Outcome following radiation treatment for high-risk pigmented villonodular synovitis. *Int J Radiat Oncol Biol Phys*. 1995;32:777-786.
- Eisenstein R. Giant-cell tumor of tendon sheath: its histogenesis as studied in the electron microscope. *J Bone Joint Surg Am*. 1968;50:476-486.
- Rowlands CG, Roland B, Hwang WS, et al. Diffuse-variant tenosynovial giant cell tumor: a rare and aggressive lesion. *Hum Pathol*. 1994;25:423-425.
- Alguacil-Garcia A, Unni KK, Goellner JR. Giant cell tumor of tendon sheath and pigmented villonodular synovitis: an ultrastructural study. *Am J Clin Pathol*. 1978;69:6-17.
- Choong PFM, Willen H, Nilbert M, et al. Pigmented villonodular synovitis: monoclonality and metastasis: a case for neoplastic origin. *Acta Orthop Scand*. 1995;66:64-68.
- Ray RA, Morton CC, Lipinski KK, et al. Cytogenetic evidence of clonality in a case of pigmented villonodular synovitis. *Cancer*. 1991;67:121-125.
- Vogrincic GS, O'Connell JX, Gilks CB. Giant cell tumor of tendon sheath is a polyclonal cellular proliferation. *Hum Pathol*. 1997;28:815-819.
- Luck JV, Kasper CK. Surgical management of advanced hemophilic arthropathy: an overview of 20 years experience. *Clin Orthop*. 1989;242:60-82.
- Mainardi CL, Levine PH, Werb Z, et al. Proliferative synovitis in hemophilia: biochemical and morphologic observations. *Arthritis Rheum*. 1978;21:137-144.
- Stein H, Duthie RB. The pathogenesis of chronic haemophilic arthropathy. *J Bone Joint Surg Br*. 1981;63B:601-609.
- Rippey JJ, Hill RRH, Lurie A, et al. Articular cartilage degradation and the pathology of hemophilic arthropathy. *S Afr Med J*. 1978;54:345-351.
- Devaney K, Vinh TN, Sweet DE. Synovial hemangioma: a report of 20 cases with differential diagnostic considerations. *Hum Pathol*. 1993;24:737-745.
- Greenspan S, Azouz EM, Matthews J, et al. Synovial hemangioma: imaging features in eight histologically proven cases, review of literature and differential diagnosis. *Skeletal Radiol*. 1995;24:583-590.
- Llauger L, Monill JM, Palmer J, et al. Synovial hemangioma of the knee: MRI findings in two cases. *Skeletal Radiol*. 1995;24:579-581.
- Hallel T, Lew S, Bansal M. Villous lipomatous proliferation of the synovial membrane (lipoma arborescens). *J Bone Joint Surg Am*. 1988;70:264-270.

26. Chaljub G, Johnson PR. In vivo characteristics of lipoma arborescens utilizing fat suppression and contrast administration. *J Comput Assist Tomogr.* 1996;20:85-87.
27. Grieten M, Buckwalter KA, Cardinal E, et al. Case report 873. *Skeletal Radiol.* 1994;23:652-655.
28. Martinez D, Millner PA, Coral A, et al. Case report 745. *Skeletal Radiol.* 1992;21:393-395.
29. Sola JB, Wright RW. Arthroscopic treatment for lipoma arborescens of the knee: a case report. *J Bone Joint Surg Am.* 1998;80:99-103.
30. Villacin AB, Brigham LN, Bullough PG. Primary and secondary synovial chondrometaplasia: histopathologic and clinicoradiologic differences. *Hum Pathol.* 1979;10:439-451.
31. Apte SS, Athanasou NA. An immunohistological study of cartilage and synovium in primary synovial chondromatosis. *J Pathol.* 1992;166:277-281.
32. Leu J, Matsubara T, Hirohata K. Ultrastructural morphology of early cellular changes in the synovium of primary synovial chondromatosis. *Clin Orthop.* 1992;272:299-306.
33. Sim FH, Dahlin DC, Ivins JC. Extra-articular synovial chondromatosis. *J Bone Joint Surg Am.* 1977;59:492-495.
34. Sviland L, Malcolm AJ. Synovial chondromatosis presenting as painless soft tissue mass: a report of 19 cases. *Histopathology.* 1995;27:275-279.
35. Davis RI, Hamilton A, Biggart JD. Primary synovial chondromatosis: a clinicopathologic review and assessment of malignant potential. *Hum Pathol.* 1998;29:683-688.
36. Bertoni F, Unni KK, Beabout JW, et al. Chondrosarcomas of the synovium. *Cancer.* 1991;67:155-162.
37. Milgram JW. The classification of loose bodies in human joints. *Clin Orthop.* 1977;24:282-291.
38. Milgram JW. The development of loose bodies in human joints. *Clin Orthop.* 1977;24:292-303.
39. Fox IH. Crystal induced synovitis. In: Kelley WN, ed. *Textbook of Internal Medicine.* 3rd ed. Philadelphia, PA: Lippincott-Raven; 1996:1130-1136.
40. Schumacher HR. Pathology of crystal deposition diseases. *Rheum Dis Clin North Am.* 1988;14:269-288.
41. Schumacher HR. Pathology of the synovial membrane in gout: light and electron microscopic studies: interpretation of crystals in electron micrographs. *Arthritis Rheum.* 1975; 18:771-782.
42. Fam AG, Topp JR, Stein HB, et al. Clinical and roentgenographic aspects of pseudogout: a study of 50 cases and a review. *CMAJ.* 1981;124:545-551.
43. Ishikawa K, Masuda I, Ohira T, et al. A histological study of calcium pyrophosphate dihydrate crystal-deposition disease. *J Bone Joint Surg Am.* 1989;71:875-886.
44. Keen CE, Crocker PR, Brady K, et al. Calcium pyrophosphate dihydrate deposition disease: morphological and micro-analytical features. *Histopathology.* 1991;19:529-536.
45. Beutler A, Rothfuss S, Clayburne G, et al. Calcium pyrophosphate dihydrate crystal deposition in synovium: relationship to collagen fibers and chondrometaplasia. *Arthritis Rheum.* 1993;36:704-715.
46. Chaplin AJ. Calcium pyrophosphate: histological characterization of crystals in pseudogout. *Arch Pathol Lab Med.* 1976;100:12-15.
47. Gravanis MG, Gaffney EF. Idiopathic calcifying tenosynovitis: histopathologic features and possible pathogenesis. *Am J Surg Pathol.* 1983;7:357-361.
48. Uhtoff HK. Calcifying tendinitis, an active cell mediated calcification. *Virchows Arch A Pathol Anat Histol.* 1975; 366:51-58.
49. Uhtoff HK, Sarkar K, Maynard JA. Calcifying tendinitis: a new concept of its pathogenesis. *Clin Orthop.* 1976;118:164-168.
50. Halverson PB, Garancis JC, McCarty DJ. Histopathological and ultrastructural studies of synovium in Milwaukee shoulder syndrome: a basic calcium phosphate crystal arthropathy. *Ann Rheum Dis.* 1984;43:734-741.
51. Dieppe PA, Huskisson EC, Crocker P, et al. Apatite deposition disease: a new arthropathy. *Lancet.* 1976;1:266-269.
52. Fam AG, Pritzker KPH, Stein JL, et al. Apatite-associated arthropathy: a clinical study of 14 cases and 2 patients with calcific bursitis. *J Rheumatol.* 1979;6:461-471.
53. Hayes CW, Rosenthal DI, Plata MJ, et al. Calcific tendinitis in unusual sites associated with cortical bone erosion. *AJR Am J Roentgenol.* 1987;149:967-970.
54. Shokeir MO, Duncan CP, O'Connell JX. Revision hip arthroplasty: a histologic review. *Int J Surg Pathol.* 1996;3:247-256.
55. Goldring SR, Clark CR, Wright TM. The problem in total joint arthroplasty: aseptic loosening. *J Bone Joint Surg Am.* 1993;75:799-801.
56. Mirra JM, Marder RA, Amstutz HC. The pathology of failed large joint arthroplasty. *Clin Orthop.* 1982;170:175-183.
57. Spector M, Shortkroff MS, Hsu HP, et al. Tissue changes seen around loosened prostheses. *Clin Orthop.* 1990;261:140-152.
58. Zaloudek C, Treseler PA, Powell CB. Postarthroplasty histiocytic lymphadenopathy in gynecologic oncology patients: a benign reactive process that clinically may be mistaken for cancer. *Cancer.* 1996;78:834-844.
59. Christie AJ, Pierret G, Levitan J. Silicone synovitis. *Semin Arthritis Rheum.* 1989;19:166-171.
60. Christie AJ, Weinberger KA, Dietrich M. Silicone lymphadenopathy and synovitis: complications of silicone elastomer finger joint prostheses. *JAMA.* 1977;237:1463-1464.
61. Gordon M, Bullough PG. Synovial and osseous inflammation in failed silicone-rubber prostheses: a report of six cases. *J Bone Joint Surg Am.* 1982;64:574-580.
62. Harboldt SL, Gumley GJ, Balough K. Osteolysis after silicone arthroplasty. *Am J Clin Pathol.* 1992;98:594-597.

First and Only FDA Cleared Digital Cytology System

Genius™ Cervical AI

Genius™ Review Station

Genius™ Digital Imager



Empower Your Genius With Ours

Make a Greater Impact on Cervical Cancer
with the Advanced Technology of the
Genius™ Digital Diagnostics System



Click or Scan
to discover more

ADS-04159-001 Rev 001 © 2024 Hologic, Inc. All rights reserved. Hologic, Genius, and associated logos are trademarks and/or registered trademarks of Hologic, Inc. and/or its subsidiaries in the United States and/or other countries. This information is intended for medical professionals in the U.S. and other markets and is not intended as a product solicitation or promotion where such activities are prohibited. Because Hologic materials are distributed through websites, podcasts and tradeshows, it is not always possible to control where such materials appear. For specific information on what products are available for sale in a particular country, please contact your Hologic representative or write to diagnostic.solutions@hologic.com.

genius™
DIGITAL DIAGNOSTICS