

Clinical and Pathologic Features of *Mycobacterium fortuitum* Infections

An Emerging Pathogen in Patients With AIDS

Michael B Smith, MD,¹ Vicki J. Schnadig, MD,¹ Michael C. Boyars, MD,² and Gail L. Woods, MD¹

Key Words: *Mycobacterium*; Lymphadenitis; AIDS; Nontuberculous mycobacteria

Abstract

The clinical and pathologic features of *Mycobacterium fortuitum* infection in 11 patients with AIDS were characterized. Nine patients had cervical lymphadenitis; 2 had disseminated infection. The infection occurred late in the course of AIDS, and the only laboratory abnormality seen in more than half of patients (7/11) was relative monocytosis. Absolute monocytosis also was seen in 4 of 11 patients. In both cytologic and histologic preparations, the inflammatory pattern was suppurative with necrosis or a mixed suppurative-granulomatous reaction. *M fortuitum*, a thin, branching bacillus, stained inconsistently in direct smear and histologic preparations. Staining was variable with Gram, auramine, Brown-Hopps, Gram-Weigert, Kinyoun, Ziehl-Neelsen, modified Kinyoun, and Fite stains. Organisms, when present, were always seen in areas of suppurative inflammation. Incorrect presumptive diagnosis, based on misinterpretation of clinical signs and symptoms or on erroneous identification of *M fortuitum* bacilli as *Nocardia* species, led to a delay in proper therapy for 7 of 11 patients. Definitive therapy after culture identification resulted in complete resolution of infection in all patients except 1.

Mycobacterium fortuitum is a rapidly growing mycobacterium, first isolated from an amphibian source in 1905 and subsequently identified as the cause of a human cutaneous infection in a patient in 1938.¹ The bacterium is found worldwide in soil and water and is an infrequent human pathogen. Major types of disease caused by *M fortuitum* include, in decreasing order of frequency, infections of postsurgical wounds, soft tissue, skin, and lung.^{1,2} Occasionally reported miscellaneous infections include keratitis, endocarditis, lymphadenitis, meningitis, hepatitis, peritonitis, catheter-related sepsis, and disseminated infections.^{1,2} In general, immunocompetent patients tend to experience limited infections associated with low mortality, although not necessarily low morbidity.^{2,3} Deep organ involvement and disseminated infections occur in immunocompromised patients or patients with a comorbid condition and manifest both high mortality and high morbidity.^{2,3} Despite the severe degree of immunosuppression associated with AIDS, few *M fortuitum* infections in patients with AIDS have been described in the literature. Three cases of cervical lymphadenitis and 2 cases of meningitis due to *M fortuitum* in patients with AIDS have been reported.^{4,5} Infections with this mycobacterium have been noted with increasing frequency during the last 5 years at this institution, which serves a large population of patients with AIDS. A retrospective review was undertaken to characterize the clinical, cytologic, and histopathologic characteristics of *M fortuitum* infection in patients with AIDS.

Materials and Methods

Cases with positive cultures for *M fortuitum* from January 1995 through December 2000 were selected from

the laboratory records at the University of Texas Medical Branch, Galveston. Positive cultures were correlated with cytopathology and surgical pathology archive files to identify cases with concomitant cytology and histology. Available slides stained with Papanicolaou, rapid Romanowsky, Gram, Gram-Weigert, Kinyoun, and modified Kinyoun stains were reviewed for cases with cytologic preparations, and available slides stained with H&E, Brown-Hopps modification of the tissue Gram stain, Ziehl-Neelsen, and Fite stains were examined for cases with histologic material. If slides were unavailable, paraffin blocks were recut and slides stained as appropriate. Patient charts were reviewed for medical history, symptoms associated with acute illness, physical examination, radiographic findings, diagnostic tests performed, laboratory results, treatment, and clinical course.

All specimens had been cultured using both liquid and solid media according to standard protocols.⁶ *M fortuitum* was identified based on growth on solid media in 7 days or less, a positive 3 day arylsulfatase test, a positive nitrate test, and susceptibility to polymyxin B. Isolates were sent to the Nocardia/Mycobacteria Research Laboratory, University of Texas Health Center at Tyler, for antimicrobial susceptibility testing.

Results

Demographics and Epidemiologic Features

Ten cases of coexistent AIDS and *M fortuitum* infection were identified from January 1995 through December 2000. **Table 1.** Nine had associated cytologic or histologic material. An additional case from 1991, which has been reported previously from this institution, was added to the series.⁵ Ten of the patients were men and 1 was a woman. The median age was 34 years (range, 25-59 years). Five patients were African American, 3 Hispanic, and 3 white. Risk factors for HIV infection were intravenous drug abuse in 3, heterosexual promiscuity in 2, and homosexuality in 1; risk factors were undocumented in 4. The median CD4 cell count at the time when *M fortuitum* infection was diagnosed was 33/ μ L ($0.033 \times 10^9/L$; range, 6-102/ μ L [0.006 - $0.102 \times 10^9/L$]).

Initial Signs and Symptoms

Initial signs and symptoms are summarized in Table 1. The most prevalent was cervical lymphadenopathy, seen in 9 of the 11 patients. Only 2 symptoms were described in 50% or more of patients, a subjective feeling of an enlarging neck mass (9 patients) and fever (8 patients).

Table 1
Patients With AIDS With *Mycobacterium fortuitum* Infections

Case No./ Sex/Age (y)	CD4 Count/ μ L ($\times 10^9/L$)	Initial Symptoms	Physical Examination Findings	Comorbid Conditions
1/M/43	89 (0.089)	Fever and malaise for 4 d withodynophagia and pharyngitis for 2 d	5 \times 5-cm right-sided cervical mass	Thrush; numerous dental caries
2/M/31	28 (0.028)	Tender right-sided neck mass with weight loss, hemoptysis, dyspnea, fever, night sweats, diarrhea (duration unspecified)	3 \times 4-cm mass in right submandibular area	Disseminated histoplasmosis; MAC; numerous dental caries
3/M/40	6 (0.006)	Enlarging anterior neck mass over 6 wk; productive cough with hemoptysis	3 \times 4-cm cervical mass with cervical adenopathy	HCV
4/M/36	74 (0.074)	3-wk history of fever and chills, night sweats, productive cough, and 24-lb (10.8-kg) weight loss	None	None
5/M/34	33 (0.033)	6-wk history of right-sided "furuncle" and neck mass that subsequently ruptured	Right-sided cervical adenopathy and fluctuant bubo	Thrush, HCV
6/M/32	19 (0.019)	2- to 3-mo history of bilateral neck masses with 2 to 3 wk of fever, chills, andodynophagia	Bilateral large cervical masses	HCV
7/M/59	102 (0.102)	2-wk history of enlarging nontender right-sided neck mass	Right-sided 8 \times 10-cm cervical neck mass	CLL
8/M/30	49 (0.049)	3-wk history of enlarging bilateral neck masses with fever and chills	9 \times 8-cm right-sided and 5 \times 5-cm left-sided hard, fixed, tender, tonsillar masses	Thrush
9/F/25	12 (0.012)	2-mo history of chronic draining right posterior neck mass and fever and chills	Right-sided posterior cervical draining abscess and left-sided 7 \times 5-cm tender cervical mass	HCV
10/M/34	52 (0.052)	1- to 2-mo history of enlarging left-sided neck mass with fevers, night sweats, and 25-lb (11.2-kg) weight loss	Left-sided 5 \times 2-cm fluctuant and right-sided 2 \times 2-cm cervical masses	None
11/M/28	24 (0.024)	Headache, fever and chills, cough, and nodular rash	Indurated pustular rash on torso and extremities	Thrush

CLL, chronic lymphocytic leukemia; HCV, hepatitis C virus; MAC, *Mycobacterium avium* complex.

The median temperature for the patients with cervical lymphadenitis was 37.9°C (range, 36°C-39.8°C). An elevated WBC count (10,500/ μ L [10.5×10^9 /L] or more) was seen in only 3 of the 9 patients with a neck mass, although in 1 patient (case 7), the elevated WBC count was due primarily to chronic lymphocytic leukemia. Similarly, a left shift (granulocytes, >78%) was noted in only 4 patients, only 1 of whom had an elevated WBC count (case 8). Seven patients had relative monocytosis (monocytes, 9% [0.09] or more; median, 11% [0.11]; range, 9.3%-31.0% [0.09-0.31]), and absolute monocytosis (monocytes, 945/ μ L [0.94×10^9 /L] or more) was present in 4 (median, 2,165/ μ L [2.16×10^9 /L]; range, 1,504-4,061/ μ L [1.50 - 4.06×10^9 /L]).

Diagnostic Features

Fifteen diagnostic procedures were performed (Table 2). Direct Gram stain was performed on 6 specimens, and gram-positive, beaded bacilli were identified on 4. Staining for acid-fast bacilli (AFB) with auramine stain was performed on 11 and AFB were seen on 4.

Cytologic Findings

Of 8 fine-needle aspirations (FNAs) performed, cytologic examination was done on 7 (Table 2). Suppurative inflammation with necrosis was seen in 4 and a mixed granulomatous-suppurative inflammatory response in 3 (Image 1 and Image 2).

Gram or Gram-Weigert stain was performed on 5 of the 8 FNA specimens, and branching, beaded, gram-positive bacilli were present in 2 (Image 3), although the bacilli were not seen by the original reviewing pathologist in 1 case (case 5). Similarly, while a Kinyoun stain was performed in 6 of the 9 cytology cases, the characteristic fuchsin-positive filamentous rods with short branches (Image 4) were present in only 3 preparations but had not been seen by the original reviewing pathologist in 1 of the cases (case 4). In 1 case, a modified Kinyoun stain demonstrated rare bacilli, which had not been detected on original review, while none were seen on the Kinyoun stain (case 8). Stainable bacilli were seen only in specimens that demonstrated either a suppurative or a neutrophil-predominant, mixed suppurative-granulomatous inflammatory infiltrate.

Histologic Findings

Histologic preparations were available for 5 cases (Table 2). All except 1 specimen showed a mixed suppurative-granulomatous response to the infection (Image 5). Three specimens showed well-formed granulomas with only isolated small microabscesses. Giant cells were seen in only 1 case. Two specimens demonstrated confluent granulomatous inflammation with focal abscesses (cases 5 and 9), and the skin biopsy in case 11 demonstrated dermal and

subcutaneous abscesses without granuloma formation. Brown-Hopps stain demonstrated rare gram-positive branching bacilli (Image 3, inset) in only 1 case (case 7), which had not been seen by the original reviewing pathologist. Ziehl-Neelsen staining was performed on all specimens. Bacilli were seen in 2 (Image 4, inset). In 1 case, the bacilli had not been observed by the original reviewing pathologist (case 11). Fite stain was performed on 3 specimens and was negative in all cases.

Treatment and Clinical Course

Of the 11 patients, the correct diagnosis was made initially for only 1 patient. Initial diagnoses are listed in Table 3. In most cases, initial therapy was ineffective.

M fortuitum infection was fatal in only 1 case (case 11). Meningitis developed in this patient after 2 months of treatment with trimethoprim-sulfamethoxazole combination treatment. This isolate was the only isolate resistant to sulfonamides of those tested (Table 4). Failure to note previous skin and bone marrow cultures that were positive for *M fortuitum* resulted in subsequent treatment with antituberculous medication for presumed tuberculous meningitis and led to death due to *M fortuitum* meningitis 2 weeks later.

Of the remaining 10 cases, long-term follow-up data were available for 8. After institution of appropriate therapy based on culture and subsequent susceptibility results, treatment led to resolution of disease in all cases. Available follow-up history showed no evidence of recurrence of infection a median of 24 months (range, 6-60 months) after institution of definitive therapy. In 5 cases, treatment of disease was facilitated by incision and drainage of the site of infection.

Discussion

M fortuitum infection in immunocompromised patients often manifests as disseminated disease with multiple skin lesions, may or may not have deep organ involvement, and can be characterized by waxing and waning of signs and symptoms.^{2,3} Case 11 in the present series illustrates that this type of disease manifestation also occurs in patients with AIDS. Pulmonary infection occurs more often in middle-aged women without underlying pulmonary disease rather than in immunocompromised patients.^{7,8} In contrast with the clinical course usually seen, case 4 in our series showed a course more similar to *Nocardia* infection with prolonged pneumonia leading to the development of cervical lymphadenitis and a brain abscess.

Cervical lymphadenitis was the most common initial sign of *M fortuitum* infection in our series and was found in 9 of 11 patients. In a 10th patient, a neck mass developed later in the clinical course. Before our series, only 17 cases

Table 2
Diagnostic Characteristics of *Mycobacterium fortuitum* Infections

Case No.	Procedure	Direct Gram Stain/ Fluorochrome AFB Stain	Cytologic Findings	Histologic Findings
1	FNA; right cervical lymph node	ND/Negative	Mixed granulomatous and suppurative inflammation (neutrophil predominant); Gram and Kinyoun stains, no organisms seen	—
2	FNA; right-sided cervical lymph node	ND/1+ AFB	Suppurative inflammation with necrosis; Gram and Kinyoun stains positive for branching rods	—
3	FNA; neck mass	ND/Negative	Mixed granulomatous and suppurative inflammation (granuloma predominant); Kinyoun: no organisms seen	—
4	BAL	ND/ND	Acute inflammation; Kinyoun stain positive for branching rods*	—
	Transbronchial biopsy	ND/ND	—	Mixed granulomatous and suppurative inflammation (granuloma predominant); Ziehl-Neelsen positive
	FNA; left-sided neck mass	Gram-positive bacilli/3+ AFB	Suppurative inflammation with necrosis; stains not performed	—
5	FNA; right-sided neck mass	ND/Negative	Suppurative inflammation with necrosis; Gram stain positive for branching rods* [†] ; Kinyoun, no organisms seen	—
	Biopsy; right-sided neck mass	ND/ND	—	Granulation tissue with poorly formed granulomas and microabscesses; Brown-Hopps, Ziehl-Neelsen, and Fite stains, no organisms seen
6	FNA; neck mass	Negative/negative	Mixed granulomatous and suppurative inflammation (neutrophil predominant); Kinyoun and GMS, rare branching rods; Gram and modified Kinyoun, no organisms seen	—
7	Biopsy; right tonsil and right neck mass	Gram-positive beaded bacilli/2+ AFB	—	Tonsil, noncaseating granulomas with giant cells and focal neutrophils; Brown-Hopps and Ziehl-Neelsen, no organisms seen Neck mass, large necrotizing granulomas with giant cells; Brown-Hopps, rare branching rods* [†] ; Ziehl-Neelsen and Fite stains, no organisms seen
8	FNA; neck mass	ND/2+ AFB	Suppurative inflammation with necrosis; modified Kinyoun, rare branching rods* [†] ; Kinyoun, Gram-Weigert, no organisms seen	—
9	Biopsy; right neck mass	Negative/negative	—	Confluent granulomatous inflammation without giant cells and focal microabscesses; Brown-Hopps, Ziehl-Neelsen, and Fite stains, no organisms seen
10	Left neck mass; aspirate for culture only	Gram-positive bacilli/negative	—	—
11	Skin biopsy of left thigh nodule	Gram-positive filamentous bacilli/negative	—	Dermal and subcutaneous microabscesses; Ziehl-Neelsen positive for branching rods* [†] ; Brown-Hopps, no organisms seen

AFB, acid-fast bacilli; BAL, bronchoalveolar lavage; FNA, fine-needle aspiration; GMS, Gomori methenamine silver; ND, not done.

* Organisms not identified on original pathologic examination.

of cervical lymphadenitis due to *M fortuitum* had been reported in the literature, 3 of which had occurred in patients with AIDS.⁴ Occurring late in the course of HIV infection (median CD4 cell count, 33/ μ L [0.033×10^9 /L]; range, 6-102/ μ L [0.006 - 0.102×10^9 /L]), *M fortuitum* cervical lymphadenitis manifests as a neck mass, enlarging over a period of weeks to months, and may be tender or nontender.

M fortuitum lymphadenitis has been associated with previous dental extraction in patients with AIDS and patients without AIDS.^{2,4} While no history of dental work was present in any of our cases, at least 2 showed evidence of severe dental caries. Abnormalities in laboratory test results are limited. Leukocytosis may or may not be present; however, relative monocytosis (median, 11% [0.11]; range, 9.3%-31%

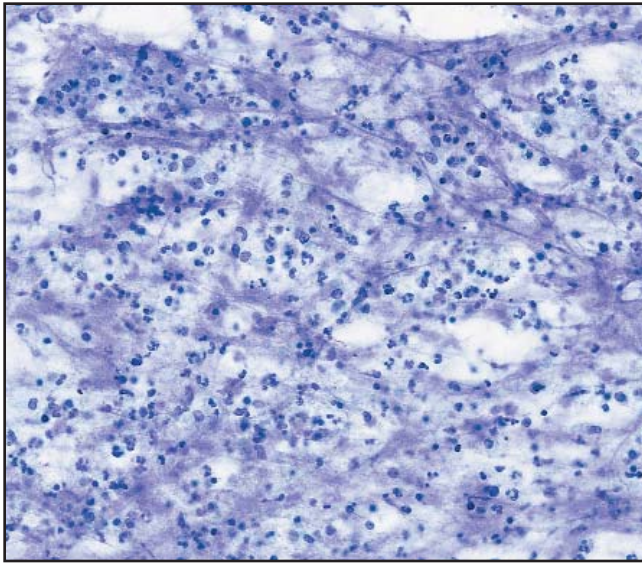


Image 1 (Case 6) Suppurative and necrotic inflammatory pattern in fine-needle aspiration specimen from neck mass (Papanicolaou, original magnification $\times 50$).

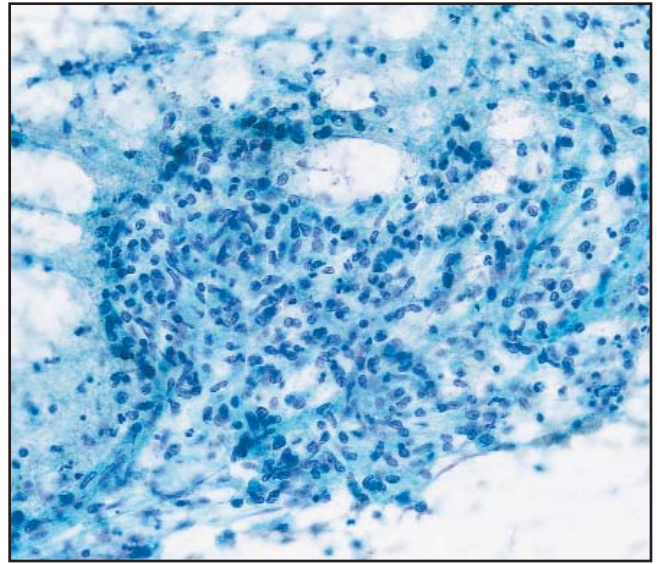


Image 2 (Case 3) Fine-needle aspiration specimen of cervical lymph node demonstrating predominantly granulomatous inflammation (Papanicolaou, original magnification $\times 50$).

[0.09-0.31]) or absolute monocytosis (median, $2,165/\mu\text{L}$ [$2.16 \times 10^9/\text{L}$]; range, $1,504\text{-}4,061/\mu\text{L}$ [$1.50\text{-}4.06 \times 10^9/\text{L}$]) were frequent in our series, present in 78% (7/9) and 44% (4/9), respectively.

The histologic response found in our series mirrored that seen in patients without AIDS with only slight modification.² A mixed suppurative-granulomatous response was seen in all 4 of the biopsied neck masses and 1 tonsil and in

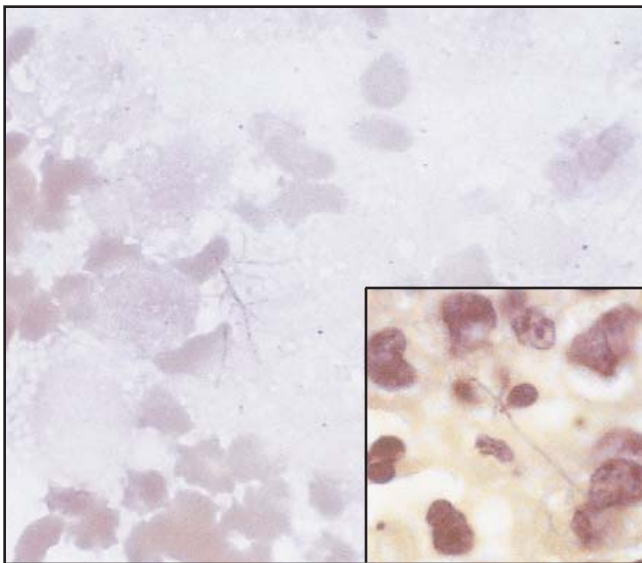


Image 3 (Case 2) Filamentous gram-positive bacillus with short branches revealed by fine-needle aspiration of neck mass (Gram, original magnification $\times 250$). Inset (Case 7), Gram-positive bacillus with short branches in lymph node granuloma (Brown-Hopps, original magnification $\times 250$).

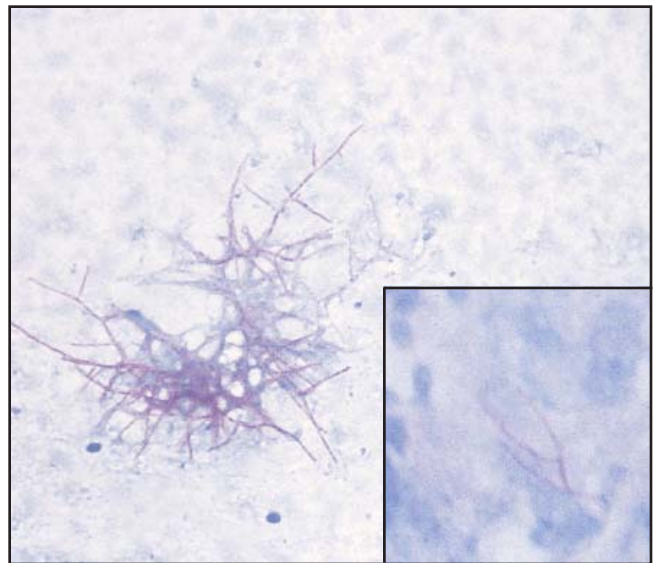


Image 4 (Case 4) Complex aggregate of acid-fast bacilli with short branches, characteristic of *Mycobacterium fortuitum*, in fine-needle aspiration specimen from neck mass (Kinyoun, original magnification $\times 50$). (Case 4) Inset, Acid-fast bacillus in transbronchial biopsy specimen. Large aggregates of branching bacilli seen in cytologic preparations were not seen in histologic preparations in this series (Ziehl-Neelsen, original magnification $\times 250$).

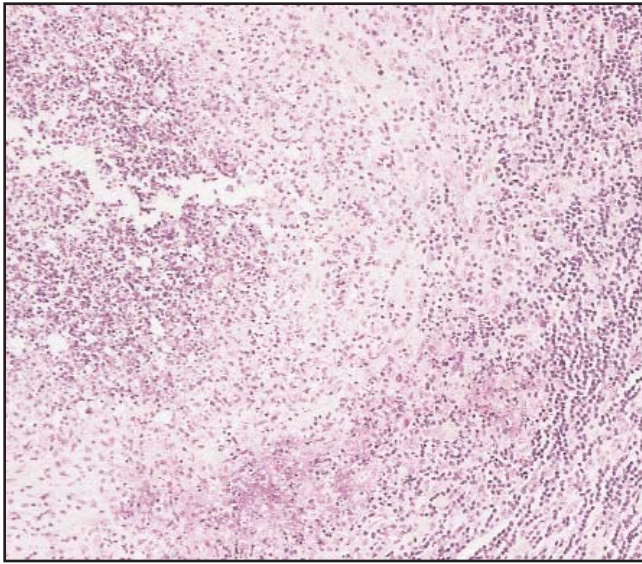


Image 5 (Case 7) Granuloma with central abscess from a cervical lymph node (H&E, original magnification $\times 50$).

3 of the 7 FNA specimens examined. Caseation was not present, and in contrast with findings in patients without AIDS, giant cells were seen in only 1 case. The large abscesses seen in many patients in the present series have not been described in patients without AIDS.

Detection of AFB in stained preparations from *M fortuitum* infections can be problematic. In many cases in this series, AFB were not identified or were rare in direct smears and cytologic and histologic specimens. Bacilli can be infrequent, and staining affinity is variable from isolate to isolate, with as few as 10% of bacilli on a smear being acid-fast.¹ In the present series, AFB were seen in 36% (4/11) of direct specimens stained with auramine, 43% (3/7) of cytologic specimens stained by the Kinyoun method, and 33% (2/6) of the histologic specimens stained with Ziehl-Neelsen stain. A modified acid-fast stain was performed on only 2 cytology specimens (modified Kinyoun), of which 1 was positive, and in 3 of the histology specimens (Fite), of which none were positive. The modified stain did not seem to add appreciably to sensitivity of detection. Gram stains fared slightly better in identifying organisms in direct specimens (66% [4/6]) and cytologic specimens (60% [3/5]) but were less sensitive in histologic specimens (20% [1/5]).

The scarcity of bacilli present in some preparations led to their being overlooked by the original reviewing pathologist in 43% (3/7) of cytology specimens and 33% (2/6) of histology specimens. Another problem is the potential confusion of *M fortuitum* with *Nocardia* species. The staining of *M fortuitum* by routine acid-fast stains, when staining occurs,

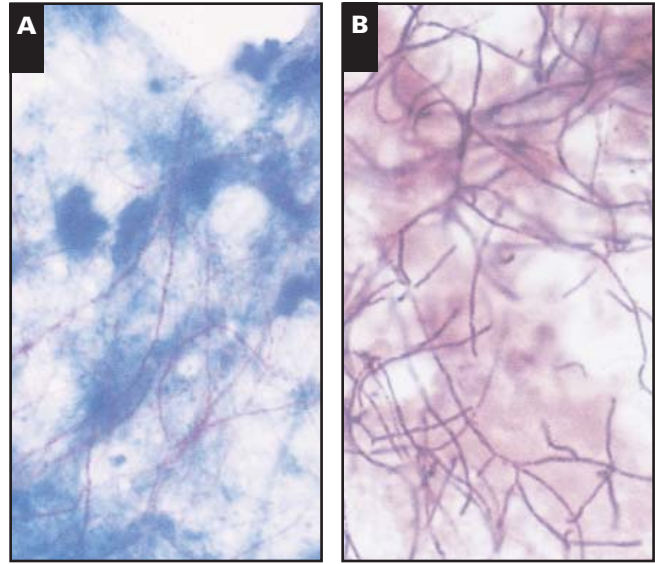


Image 6 Fine-needle aspiration specimen of *Nocardia asteroides* stained with modified Kinyoun stain (**A**) and Gram stain (**B**), demonstrating long, thin, branching filaments. Compare with Images 3 and 4 (original magnification $\times 250$).

and the morphologic features facilitate differentiation. *M fortuitum* characteristically has shorter, blunter branches than *Nocardia* species, and the branches more often extend at right angles from their point of origin (Image 4) **Image 6**. Differentiation may be more difficult in histologic specimens because the large, complex aggregates of bacilli seen in cytologic preparations generally are not present. When combined with the appropriate clinical manifestations, the morphologic characteristics of *M fortuitum* may permit a presumptive diagnosis, although morphologic overlap between *M fortuitum* and *Nocardia* species can occur, and culture confirmation is necessary.

Case 11 illustrates the importance of using in vitro susceptibility testing to guide therapy. Reporting of bacilli on a direct smear Gram stain as probably *Nocardia* species led to prolonged treatment of the patient with sulfamethoxazole-trimethoprim combination therapy, to which the *M fortuitum* isolate was resistant by in vitro testing. Although the sensitivity pattern of *M fortuitum* is fairly predictable, individual variation exists, and in vitro susceptibility testing is a necessary component of therapeutic evaluation in each case.⁷ While therapy has not been standardized, prolonged treatment (months) is necessary for most disseminated infections in patients without AIDS.³ Although experience is limited, cervical lymphadenitis due to *M fortuitum* in patients in the present study resolved with a combination of incision and drainage and a course of varying regimens of intravenous antibiotics followed by oral antibiotics. Similar outcomes were seen in the 2 cases reported by Butt.⁴

Table 3
Clinical Course of *Mycobacterium fortuitum* Infections in Patients With AIDS

Case No.	Initial Diagnosis	Initial Therapy/Clinical Course	Definitive Therapy	Follow-up
1	Lymphadenitis (NOS)	2-wk course of clindamycin unsuccessful	14-day course of IV amikacin and imipenem; then oral doxycycline	Lost to follow-up on discharge
2	<i>M fortuitum</i> adenitis	Decrease in lesion size during therapy	IV sulfamethoxazole-trimethoprim combination and cefuroxime; then oral doxycycline	Lost to follow-up after patient discharged against medical advice
3	Tuberculous scrofula	Recurrence 2.5 mo after initial treatment when taking medications for tuberculosis	Clarithromycin, cefotaxime, and doxycycline	No evidence of disease 2 and 6 mo after definitive therapy
4	<i>Nocardia</i> pneumonia	Returned 2 mo after initial treatment with worsening of pneumonia despite treatment with sulfamethoxazole-trimethoprim combination and cefuroxime; after 2 wk of sulfamethoxazole-trimethoprim combination and ceftiofloxacin, cervical adenitis and frontal lobe brain abscess developed	Amikacin, doxycycline, and I&D of brain abscess and neck mass, followed by oral azithromycin	Resolution of brain abscess shown by 2-mo follow-up computed tomography; no evidence of disease 2 y after definitive therapy
5	Lymphadenitis (NOS)	I&D followed by levofloxacin and clindamycin	Ofloxacin for unknown period	No evidence of disease 6 mo and 18 mo after therapy
6	<i>Nocardia</i> vs atypical mycobacterial lymphadenitis	Not documented	Treated with minocycline and dapsone for unknown period	No evidence of disease 12 mo and 54 mo later
7	Tuberculous scrofula	No improvement with I&D, anti-tuberculosis medications; regimen changed to clarithromycin, amikacin, and sulfamethoxazole-trimethoprim combination 1 mo after initial treatment with no improvement	I&D, amikacin, and ceftiofloxacin for 3 mo followed by ofloxacin and clarithromycin for 1 mo	No evidence of disease approximately 60 mo later
8	<i>Nocardia</i> lymphadenitis	Readmitted 1 wk after initial therapy for rapid increase in size of neck mass despite therapy with amikacin and ceftriaxone	I&D followed by amikacin, ofloxacin, and cefuroxime for unknown period	Resolution at 8 wk; no evidence of disease approximately 30 mo later
9	Lymphadenitis (NOS)	Admitted after failure of treatment with I&D and cephalexin; admitted second time after failure of treatment with an amoxicillin-clavulanate potassium combination, an ampicillin sodium-sulbactam sodium combination, and rifampin	I&D, followed by IV amikacin, clarithromycin, ceftiofloxacin for 14 d and then oral clarithromycin and cefuroxime for an unknown period	Died after 2 y with no evidence of <i>M fortuitum</i> at autopsy
10	Lymphadenitis (NOS)	Failed to resolve despite 2-wk course of clindamycin	I&D, with IV amikacin followed by 6 mo of treatment with cefuroxime and a trimethoprim-sulfamethoxazole combination	No evidence of disease at 10 mo
11	Disseminated <i>Nocardia</i> (favored) vs nontuberculous mycobacterial infection	Treated with sulfamethoxazole-trimethoprim combination; 2 mo after initial treatment returned with meningitis, which was treated with antituberculous medications; after some improvement, he was discharged from the hospital	—	Died of <i>M fortuitum</i> meningitis 2 wk after initiation of treatment with antituberculous medications

I&D, incision and drainage; IV, intravenous; NOS, not otherwise specified.

Table 4
Antibiotic Susceptibility Patterns of *Mycobacterium fortuitum* Isolates

Antibiotic	No. Susceptible/No. Tested
Amikacin	11/11
Ciprofloxacin	11/11
Clarithromycin	9/10
Doxycycline	10/11
Imipenem	10/11
Sulfamethoxazole	7/8
Ceftiofloxacin	7/11

M fortuitum infection is being recognized with increasing frequency in patients with AIDS. Ten cases were identified during a 5-year period at a university medical center serving a large AIDS population. Infection most

frequently manifests late in AIDS as a suppurative-granulomatous cervical lymphadenitis, although other manifestations such as disseminated disease, pulmonary infection, meningitis, and brain abscess may be seen. A paucity of organisms, staining variability with both Gram and acid-fast stains, and possible confusion with *Nocardia* species may make pathologic diagnosis difficult. Careful review of material at $\times 1,000$ often is necessary to identify organisms. Culture and in vitro antibiotic susceptibility testing are mandatory because of occasional variations in sensitivity patterns. Accurate identification of *M fortuitum* as the cause of infection in these cases is important, as appropriate therapy most often results in complete resolution of infection despite the severe immunosuppression of the patient.

From the Departments of ¹Pathology and ²Internal Medicine,
University of Texas Medical Branch, Galveston.

Address reprint requests to Dr Smith: Division of
Microbiology, Dept of Pathology, University of Texas Medical
Branch, 301 University Blvd, Galveston, TX 77555-074.

References

1. Brown TH. The rapidly growing mycobacteria: *Mycobacterium fortuitum* and *Mycobacterium chelonae*. *Infect Control*. 1985;6:283-288.
2. Wallace RJ, Swenson JM, Silcox VA, et al. Spectrum of disease due to rapidly growing mycobacteria. *Rev Infect Dis*. 1983;5:657-679.
3. Ingram CW, Tanner DC, Durack DT, et al. Disseminated infection with rapidly growing mycobacteria. *Clin Infect Dis*. 1993;16:463-471.
4. Butt A. Cervical adenitis due to *Mycobacterium fortuitum* in patients with acquired immune deficiency syndrome. *Am J Med Sci*. 1998;315:50-55.
5. Smith MB, Boyars MC, Woods GL. Fatal *Mycobacterium fortuitum* meningitis in a patient with AIDS. *Clin Infect Dis*. 1996;23:1327-1328.
6. Nolte FS, Metchok B. *Mycobacterium*. In: Murray PR, Baron EJ, Pfaller MA, et al, eds. *Manual of Clinical Microbiology*. 6th ed. Washington, DC: ASM Press; 1995:400-437.
7. Wallace RJ. Recent changes in taxonomy and disease manifestations of the rapidly growing mycobacteria. *Eur J Clin Microbiol Infect Dis*. 1994;13:953-960.
8. Griffith DE, Girard WM, Wallace RJ. Clinical features of pulmonary disease caused by rapidly growing mycobacteria. *Am Rev Respir Dis*. 1993;147:1271-1278.

First and Only FDA Cleared Digital Cytology System

Genius™ Cervical AI

Genius™ Review Station

Genius™ Digital Imager



Empower Your Genius With Ours

Make a Greater Impact on Cervical Cancer
with the Advanced Technology of the
Genius™ Digital Diagnostics System



Click or Scan
to discover more

ADS-04159-001 Rev 001 © 2024 Hologic, Inc. All rights reserved. Hologic, Genius, and associated logos are trademarks and/or registered trademarks of Hologic, Inc. and/or its subsidiaries in the United States and/or other countries. This information is intended for medical professionals in the U.S. and other markets and is not intended as a product solicitation or promotion where such activities are prohibited. Because Hologic materials are distributed through websites, podcasts and tradeshows, it is not always possible to control where such materials appear. For specific information on what products are available for sale in a particular country, please contact your Hologic representative or write to diagnostic.solutions@hologic.com.

genius™
DIGITAL DIAGNOSTICS