



The Percutaneous Trampoline Platysmaplasty: Technique and Experience With 105 Consecutive Patients

Aesthetic Surgery Journal
32(1) 11–24
© 2012 The American Society for
Aesthetic Plastic Surgery, Inc.
Reprints and permission:
[http://www.sagepub.com/
journalsPermissions.nav](http://www.sagepub.com/journalsPermissions.nav)
DOI: 10.1177/1090820X11429939
www.aestheticsurgeryjournal.com



Gregory P. Mueller, MD, FACS; Norman Leaf, MD, FACS; Sherrell J. Aston, MD, FACS; and Corbett W. Stone, BSME

Abstract

Background: Controversy persists regarding the optimal procedure to rejuvenate the aging neck. More invasive procedures carry increased risks of complications, whereas less invasive approaches may deliver marginal results. The challenge is selecting the appropriate procedure for delivering consistent, durable results meeting both the patient's and surgeon's expectations.

Objectives: The authors describe their trampoline platysmaplasty (TPP) approach, a percutaneous suture suspension necklift that constitutes a less invasive approach for neck rejuvenation.

Methods: A retrospective study was conducted of 105 consecutive patients who underwent TPP. Age, sex, procedure(s) performed, complications, and patient satisfaction were recorded. Cadaver studies were conducted to compare the tensile strength of the ligaments that anchor the TPP to the tensile strength of the sutures placed to approximate the medial platysma borders. In addition, the accuracy of light transillumination to determine depth of travel of the light-emitting diode (LED) lighted rod was evaluated.

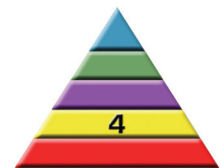Results: Patients underwent either TPP alone (18 women, 24 men) or TPP with a facelift (35 women, 28 men) between October 2007 and June 2009. The average age of the patients was 52 years, and average length of follow-up was 33 months. Patient satisfaction was high. Three early patients underwent immediate revision to improve results secondary to the suture matrix being too loose. Six additional patients had recurrent banding around one year postoperatively, but correction was achieved in all six by replacing the matrix with the help of the lighted rod. The results of the cadaver study revealed that the tensile strength of the retaining ligaments was statistically identical to the medial platysma borders, and the light transillumination feedback was accurate with regard to the depth of travel of the illuminated rod tip.

Conclusions: The TPP approach for neck rejuvenation is effective and durable in properly-selected patients. It works well as a stand-alone procedure and in conjunction with facelift procedures. It also offers younger patients a less-invasive option to improve neck contours inherited through genetics. After nearly three years of follow-up of the patients in this report, the results appear to be long-lasting.

Level of Evidence: 4.

Keywords

percutaneous necklift, short-scar facelift, platysmaplasty, minimally-invasive plastic surgery, facial rejuvenation, suture suspension, SMAS plication, mandibular retaining ligament, corset platysmaplasty



Accepted for publication August 23, 2011.

Patients who seek facial rejuvenation are often more concerned about physical changes in the neck than changes in the jawline or nasolabial folds. Controversy persists regarding the most effective means of restoring a youthful appearance to the neck because more invasive procedures carry increased risks of complications, whereas less invasive approaches may deliver marginal results. To address these challenges, we began performing necklifts via our percutaneous platysmaplasty approach in October 2007. With this technique, a nonabsorbable suture matrix is constructed in the subcutaneous space and positioned on the surface of the platysma muscle. The suture strands are introduced through several small punctures along the lateral jawline and underneath the chin, yielding a framework similar to

Dr. Mueller is in private practice in West Hollywood, California, and is the inventor of the iGuide Surgical Suture System. Dr. Leaf is an Associate Clinical Professor in the Division of Plastic and Reconstructive Surgery, UCLA School of Medicine, Los Angeles, California. Dr. Aston is a Professor of Plastic Surgery at New York University School of Medicine, New York, New York. Mr. Stone is an engineer in San Diego, California.

Corresponding Author:

Dr. Gregory P. Mueller, 9201 Sunset Boulevard, Suite 602, West Hollywood, CA 90069 USA.
E-mail: greg.mdgpm@gmail.com



Scan this code with your smartphone to see the operative video. Need help? Visit www.aestheticsurgeryjournal.com.

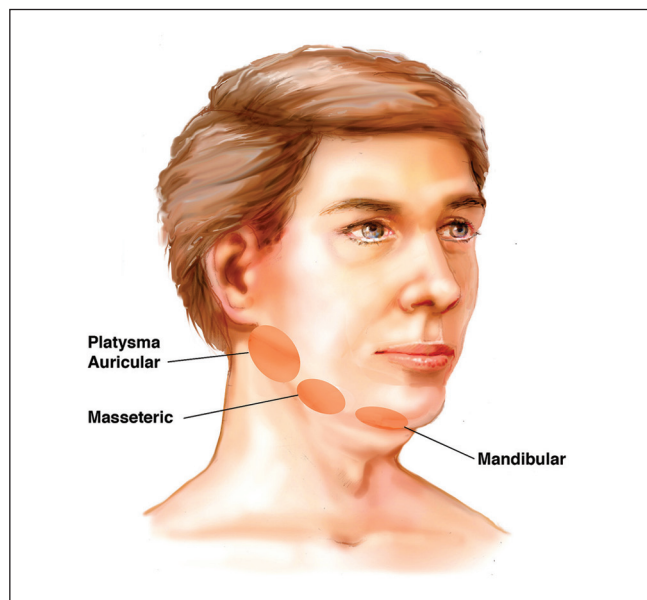


Figure 1. Highlighted areas indicate lateral retaining ligaments in the jawline.

a shoelace that functions like a trampoline. The retaining ligaments along the lateral aspect of the mandible provide the “anchoring” aspect of the trampoline platysmaplasty (TPP) matrix and include the platysma auricular ligaments,¹ the masseteric ligaments,² and the mandibular ligaments³ (Figure 1).

The method of delivering suture strands and anchoring them by passing the suture around the retaining ligaments along the lateral ramus of the mandible is accomplished with a specialized light-emitting diode (LED) instrument system (iGuide; Implicitcare, LLC, West Hollywood, California). This light-guided system was designed by two of the investigators in this series (GPM, CWS) and includes a marking tape, puncture device, dermal clearing device, LED light source, and two stainless steel rods with fiberoptic cores. The rods are connected by a 70-inch 4-0 braided polyester suture that attaches to the center of each rod. Placement of the suture matrix on the surface of the platysma muscle is critical to obtaining successful results with the TPP approach, and utilizing light transillumination from the tip of the rod with the attached suture allows the surgeon to accurately determine the depth and direction of travel, thereby enabling successful construction of the support system in the plane between the platysma muscle and overlying neck skin.

The technique of utilizing the retaining ligaments along the lateral jawline as anchors for suturing and the application of light transillumination to guide the building of this suture matrix were supported by the results of a fresh cadaver study conducted by two of the authors (GPM, SJA) in the anatomy laboratory at the University of

Maryland, State Anatomy Board in Baltimore, Maryland, in August 2009. Both the tensile strength of the retaining ligaments and the accuracy of LED light transillumination were evaluated. In this report, we describe the TPP procedure and review the results of 105 consecutive patients who underwent TPP necklifting with an average follow-up of 33 months.

METHODS

Patient Selection

A total of 105 consecutive patients (53 women, 52 men) underwent TPP necklifting with one of two surgeons (GPM or NL) between October 2007 and June 2009. All patients underwent preoperative evaluation by their operating surgeon, and patients were selected for inclusion if their neck anatomy was likely to show improvement with the less-invasive TPP technique alone or in combination with a short-scar facelift. Six anatomic variants contribute to a loss of neck contour: (1) loss of dermal elastic fiber tone with sagging of the skin, (2) ptosis of the soft tissues in the neck and chin, (3) banding of the platysma muscles at the anterior neck, (4) elimination of the anterior sternocleidomastoid border, (5) increased fat deposition, and (6) submandibular gland protrusion. Patients who had only fat deposition could be treated with liposuction alone and were therefore excluded from the study. Patients with large necks and excessive redundant neck skin were treated with traditional open techniques, so they were not included in this study. The indications for the short-scar facelift were the same as have been established previously in the literature; patients with midfacial aging and loss of neck contour were deemed candidates for the short-scar facelift and TPP.

Operative Technique

To begin the procedure, the patient was positioned on the operating table with the neck extended, allowing maximal exposure to the area. The skin of the face and neck was prepped and draped in a sterile fashion. For those patients undergoing a concurrent facelift, the entire face and neck were infiltrated with approximately 500 to 600 mL of a solution of lidocaine with epinephrine (1 L normal saline with 50 mL of 1% lidocaine and 1 mL of 1:1000 epinephrine). For those undergoing TPP without facelift (with or without liposuction), 300 to 400 mL of the same solution was infiltrated for the lateral ramus and entire neck region. With a #15 blade, a total of three 3-mm access sites for tunneling and liposuction were dissected. A midline submental puncture was made just posterior to the bony submentum. This avoids postoperative palpability of the knot securing the TPP, which can occur if the knot is located over the bone. In addition, right and left punctures were made at the anterior earlobe-facial junction. Neck undermining was undertaken with a 3-mm spatulated




Figure 2. A 3-mm spatulated cannula is applied to undermine the neck in the subdermal plane.

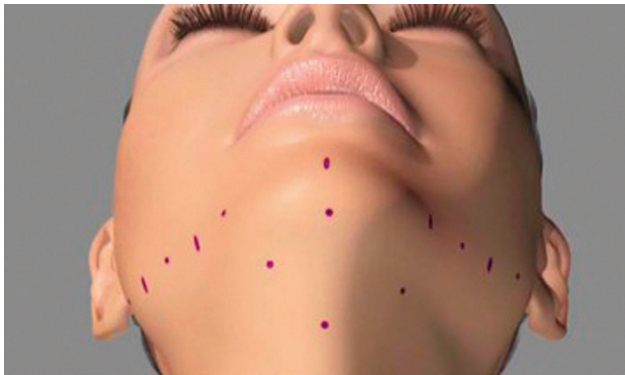

Figure 4. Two to three marks are made underneath the jawline between the cervicomental angle and the submental stab incision. These marks will be punctured and will function as “pivot points” (under chin) and anchor points (lateral ramus). Copyright 2011, MediVisuals, Inc. Reprinted with permission.

cannula (Figure 2) in every patient, in order to open the subdermal plane and expose the dermal ligaments. This maneuver is essential, as it exposes raw surfaces that will form scar tissue, allowing adherence of the neck skin to the underlying platysma muscle. In patients with excess fat in the neck, suction was applied to the cannula after undermining was completed.

In those patients undergoing a concurrent short-scar facelift, each surgeon utilized his preferred technique (imbrication, superficial musculoaponeurotic system [SMAS] flap, etc) to complete that portion of the procedure. Regardless of technique, it was essential to undermine the skin with a 3-mm spatulated cannula in the subdermal plane of the entire face and neck, including the lateral ramus, prior to elevating the skin. A 2- to 3-cm zone above the lower border of the mandible was marked on the skin, extending from the angle of the mandible anteriorly to the lateral mentum. The skin in this area was not separated from the underlying SMAS, thus preserving

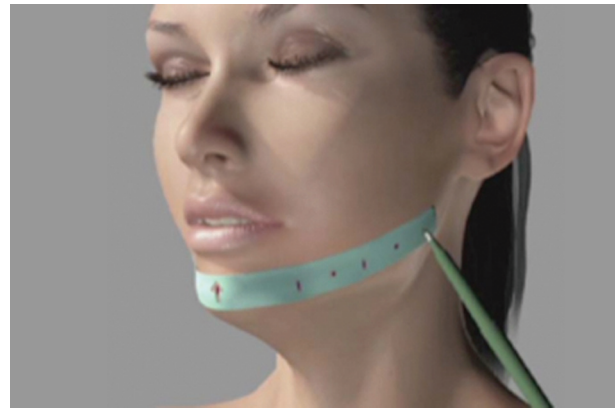

Figure 3. A sterile marking pen is applied to stencil the alternating lines and dots, with the most posterior mark located at the posterior border of the angle of the mandible. Usually, three to five marks are required on each side. Copyright 2011, MediVisuals, Inc. Reprinted with permission.

the dermal retaining ligaments. Upon completion of the upper facelift procedure, the incisions were closed in the usual manner.

The weaving of the TPP matrix was always the last step in our procedure for rejuvenation of the face and neck. The midline was marked and the marking tape was applied along the jawline. A sterile marking pen was used to stencil the alternating lines and dots, with the most posterior mark located at the posterior border of the angle of the mandible. Three to five marks were usually required on each side (Figure 3). The cervicomental angle was identified, and a mark was placed 1 cm anteriorly. Two to three additional marks were made underneath the jawline between the cervicomental angle and the submental stab incision. These marks were later punctured and functioned as “pivot points” for the straight rod as it passed underneath the curved surface of the chin. They were randomly placed to give the surgeon options as the rod was repeatedly passed underneath the jawline (Figure 4). The lancet was applied to puncture these anchor points along the lateral ramus and the pivot points underneath the chin. With each piercing, the lancet was rotated to the left and right to dilate each puncture as the skin was lifted upwards by grasping it between the thumb and index finger. Lifting the skin decreased the risk of injury to deeper structures (Figure 5). The clearing device was inserted and rotated two times clockwise in every puncture, with the curved tip located just deep to the dermis (Figure 6).

The illuminated stainless steel rod, which was attached to a 4-0 Teflon-coated braided polyester suture, was introduced at the cervicomental angle and advanced underneath the skin. Transillumination of light from the tip indicated the depth and direction of travel. The depth of travel was determined by the color and intensity of light. A bright yellow spot of light indicated the correct depth of travel, thus confirming that the tip was in the subcutaneous space. As the rod was passed underneath the skin, the

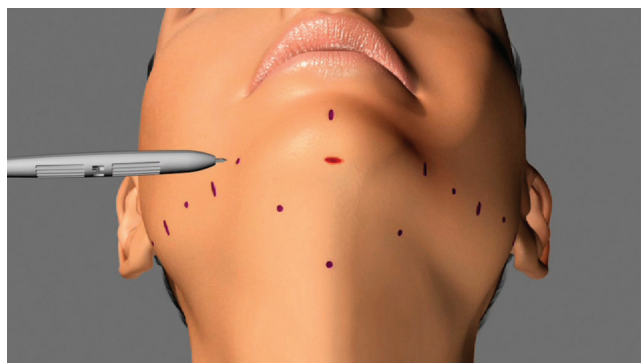


Figure 5. The lancet is used to pierce the skin, which is lifted upwards. Lifting the skin decreases the risk of injury to deeper structures. Copyright 2011, MediVisuals, Inc. Reprinted with permission.

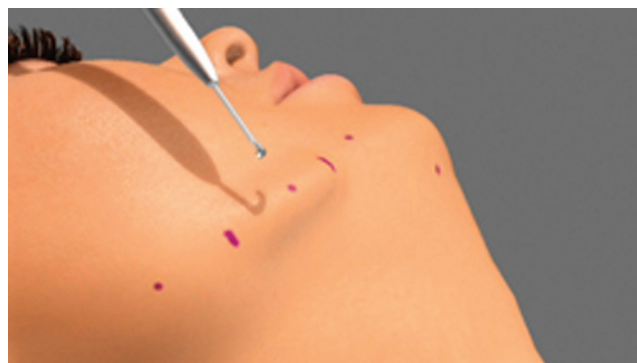


Figure 6. The dermal clearing device is inserted and rotated two times clockwise in every puncture, with the curved tip located just deep to the dermis. Copyright 2011, MediVisuals, Inc. Reprinted with permission.

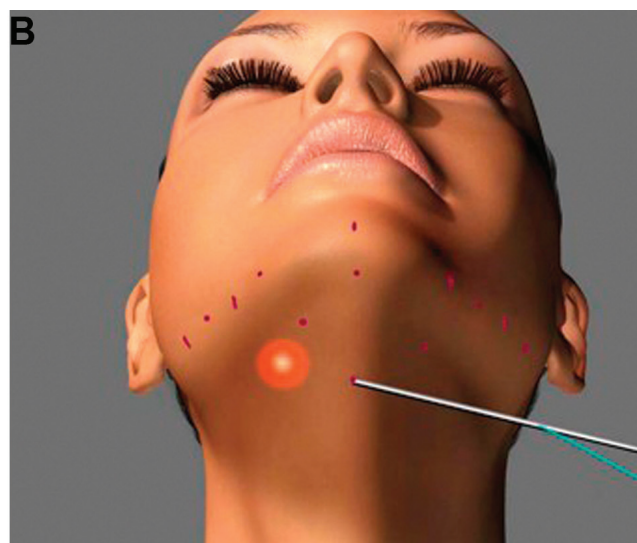
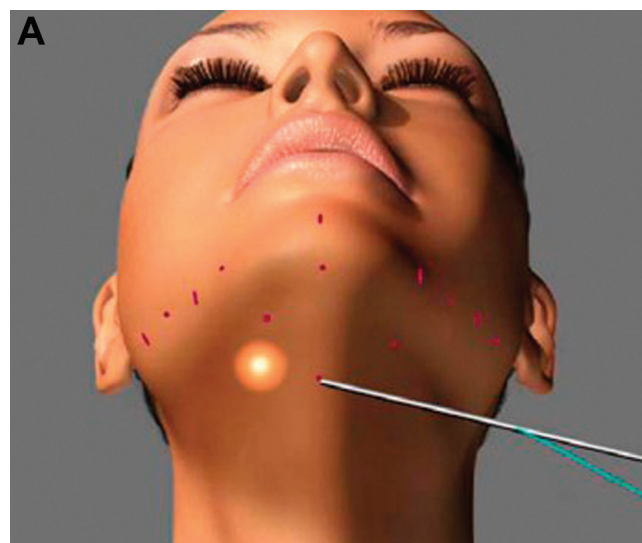


Figure 7. (A) A bright yellow spot of light indicates the correct depth of travel, thus confirming that the tip is in the subcutaneous space. (B) A dull red light indicates that the rod has passed deep to a segment of the platysma muscle. Copyright 2011, MediVisuals, Inc. Reprinted with permission.

surgeon observed the light; if it suddenly changed to dull red, this indicated that the rod had passed deep to a segment of the platysma muscle (Figure 7).

Visible tethering of the overlying skin and increased resistance confirmed the engagement of this first anchor point as the tip of the rod remaining in the subcutaneous space was advanced 1 to 2 cm toward the medial canthus and then rotated downward (Figure 8). The light handle was attached to the exposed portion of the rod prior to advancing the tip underneath the jawline to the next anchor point, which was marked with a vertical line on the left side of the mandible. These steps were repeated as the rod crisscrossed the undersurface of the jawline,

advancing toward the midline submental stab incision. With every pass, it was essential to pull on the suture, maintaining tension in the entire matrix. Upon reaching the anterior mentum, the rod was brought out through the incision and the suture was cut free from the rod. This same sequence was performed for the second strand of suture, which was weaved underneath the jawline using the dots (instead of the lines) as anchor points (Figure 9).

Gentle tension was applied to both suture ends as an assistant applied upward pressure to the area under the chin. This allowed adequate tightening of the matrix, which aided in optimizing results. The amount of tension required was determined by visualizing dimpling of the first two anterior

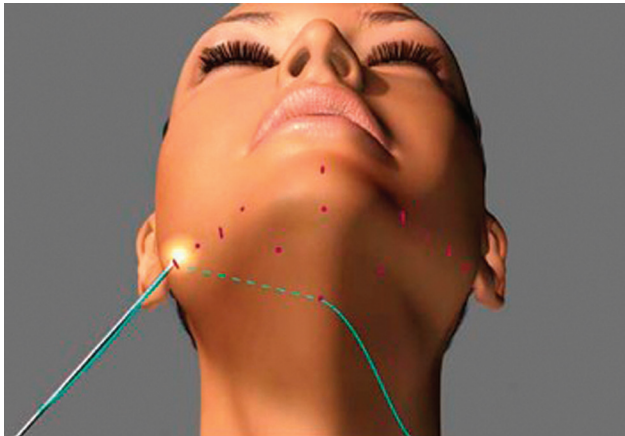


Figure 8. Encircling/engaging the ligaments. Copyright 2011, MediVisuals, Inc. Reprinted with permission.

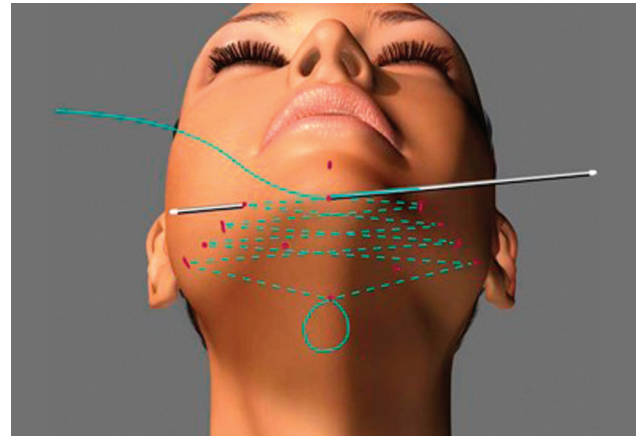


Figure 9. Completion of the matrix. Copyright 2011, MediVisuals, Inc. Reprinted with permission.



Figure 10. Tension on the matrix approximates skin and underlying muscle. The amount of tension required is determined by visualizing dimpling of the first two anterior pivot points. Copyright 2011, MediVisuals, Inc. Reprinted with permission.

pivot points, which is caused by suture tension on the dermal ligaments (Figure 10). Once achieved, the matrix was secured by tying the suture ends together in the usual fashion. As gentle traction was placed on the tied suture, the assistant cut the suture, allowing the knot to retract into the subcutaneous space. A chin strap was applied.

Postoperative Instructions

Patients were instructed to remove the chin strap on the first day but to continue wearing it while sleeping for a total of six days. Additional postoperative instructions included cold compresses applied as often as possible for the first three days during waking hours. TPP-only patients usually returned to normal activities in three to four days, whereas facelift patients usually required 10 to 14 days. Both groups typically experienced minor bruising that could be concealed with makeup. Most patients experienced limitations in opening the mouth widely and often observed visible dimpling at the anchor points with wide mouth-opening during the first postoperative month.

Cadaver Studies

In August 2009, two of the authors (GPM, SJA) conducted fresh cadaver studies at the anatomy lab of the University of Maryland, State Anatomy Board, to evaluate the tensile strength of the retaining ligaments and to confirm the accuracy of LED light transillumination.

Interrupted sutures were placed to approximate the platysma borders, as in a traditional platysmaplasty. Simultaneously, sutures were woven around the retaining ligaments along the jawline, which are involved in anchoring the TPP. Four anchor points on each side of the mandible were tested. Three suture ligations of the medial platysma borders were tested on each cadaver. With a calibrated tensile strength meter, force was applied to each suture attached to either the platysma muscle or the retaining ligaments until it completely severed the tissue. The average maximum tension required to completely pull the suture through the medial platysma borders was 9.282 lb, compared to the 11.144 lb required to rupture each retaining ligament anchor point. Evaluation of the data revealed that the strength of the retaining ligaments and the platysma muscle was statistically the same. This finding further supported the potential of the retaining ligaments to anchor the TPP suture matrix (Figure 11).

Confirmation of the accuracy of light transillumination was obtained by passing the illuminated rod underneath the skin of the face and neck. Observing the intensity and color of the light allowed the investigators to determine the position of the rod tip, which was then recorded. Both depth and direction of travel were assessed. With the rod left in position, an incision was made in the illuminated skin. Dissection was carried down to the level of the rod to confirm the depth of penetration and document the anatomical layers above and below the tip. Multiple passes were made with the rod at various depths of penetration. This study confirmed the accuracy of light to determine the depth and direction of travel (Figure 12).

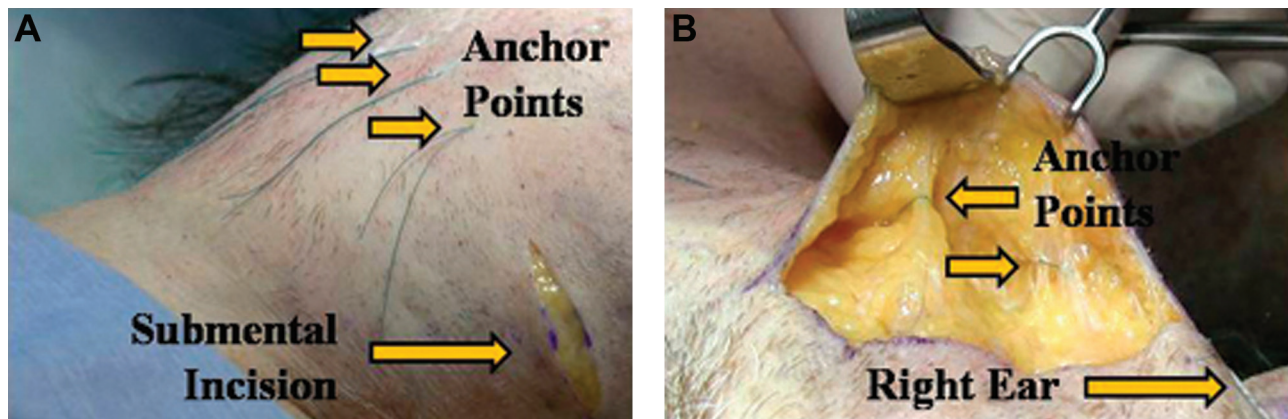


Figure 11. (A) In the cadaver study, anchor points are identified. (B) Encircling/engaging the ligaments is shown. With a calibrated tensile strength meter, force was applied to each suture that was attached to either the platysma muscle or the retaining ligaments until it completely severed the tissue. Evaluation of the data revealed that the strength of the retaining ligaments and the platysma muscle was statistically the same. This finding further supported the potential of the retaining ligaments to anchor the trampoline platysmaplasty suture matrix.

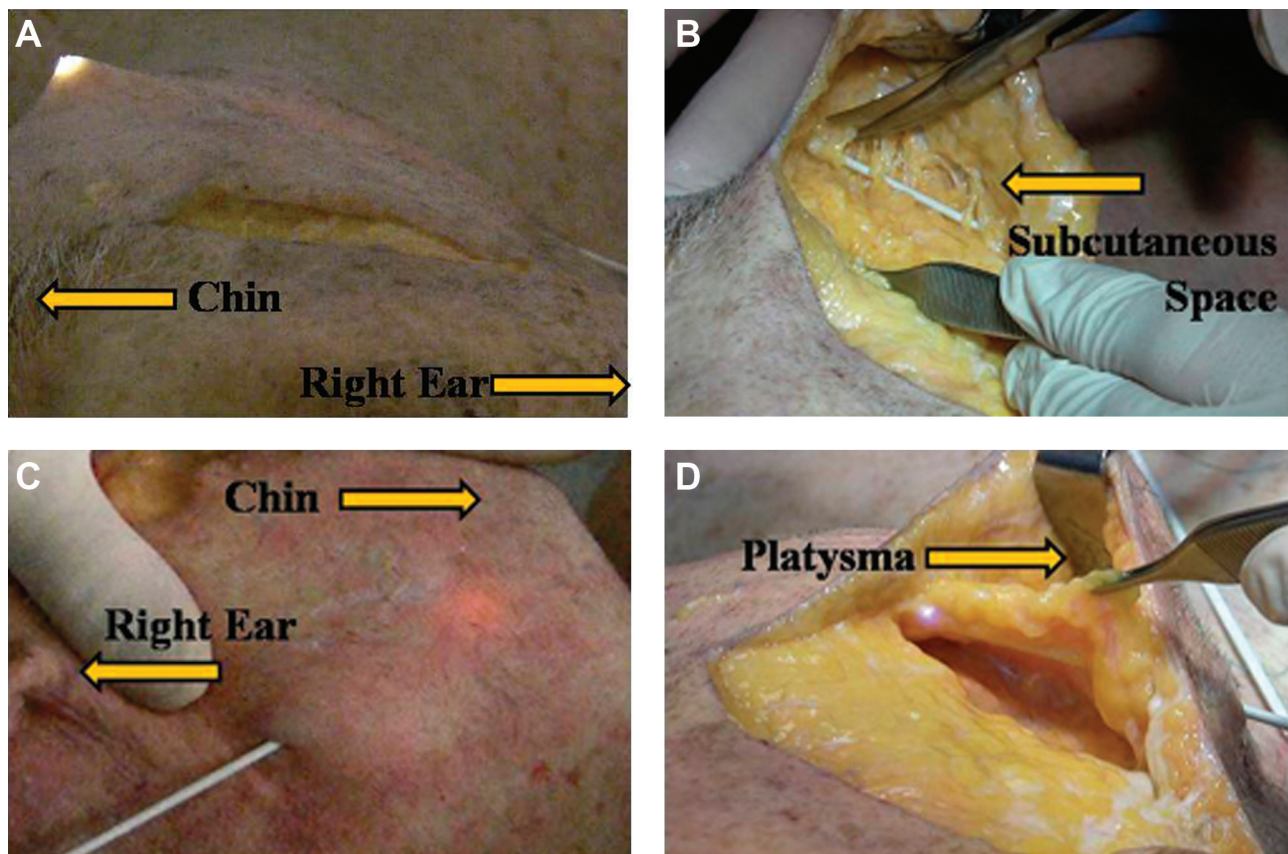


Figure 12. (A) In the cadaver study, observation of the intensity and color of the light was used to determine the position of the rod tip, which was then recorded. A bright yellow light indicated the subcutaneous space. (B) Dissection was carried down to the level of the rod to confirm the depth of penetration (subcutaneous space) and the anatomical layers that were above and below the tip. (C) A dull red light indicated penetration to the subplatysmal plane. (D) Dissection confirmed the depth of penetration (subplatysmal).

RESULTS

The average age of the patients in this series was 52 years (range, 23-80 years). Forty-two patients (18 women, 24 men) underwent TPP alone, and 63 (35 women, 28 men) underwent TPP with a facelift. The average length of follow-up was 33 months.

Overall patient satisfaction was high, as determined by the significant increase of patient referrals for the procedure. Three patients experienced minimal to no improvement after TPP. One of these patients subsequently underwent removal of the suture matrix through the submental incision; replacement of the TPP with the open approach produced an improved result. Another patient underwent percutaneous placement of a double-stranded neck-defining suture under local anesthesia, which resulted in improvement of his neck contours. The third patient, a 78-year-old woman, underwent a revision necklift to tighten the skin overlying the lower half of the neck by extending the facelift incisions posteriorly.

In addition, six patients presented with residual/recurrent platysma bands one year postoperatively. Replacing the matrix with the lighted rod resulted in proper placement of the suture on the surface of the platysma muscle, which yielded correction in all six patients. Prolonged dimpling occurred at the anchor points along the lateral ramus in four patients. Regular massage to the dimpled areas was recommended, and all patients had complete resolution; the longest time to resolution was six weeks. Two infections occurred, with one responding to antibiotics and the other requiring removal of the suture framework through a traditional submental incision. The latter patient had a methicillin-resistant *Staphylococcus aureus* (MRSA) infection documented with cultures. Removal of the suture framework resulted in quick resolution of the infection with no deformity of the neck region. Of note, one patient had a breakage of the suture during the procedure. The suture was easily removed, and a replacement suture was introduced with a successful outcome. There was one postoperative hematoma in a patient with hypertension. One patient experienced a marginal mandibular nerve paresis that resolved in six weeks. No permanent skin dimpling or contouring deformities have been noted.

Clinical results are shown in Figures 13 to Figures 16.

A video of the surgical procedure is available at <http://www.aestheticsurgeryjournal.com>. You may also use any smartphone to scan the code on the first page of this article to be taken directly to the video on www.YouTube.com.

DISCUSSION

Restoration of the youthful neck has evolved along a continuum of techniques over the past 30 years, ranging from minimalist to highly invasive. In 1974, Guerrerosantos et al⁴ described the “muscular lift in cervical rhytidoplasty,” in which platysma muscle flaps were developed and anchored posteriorly to the mastoid fascia. The introduction of liposuction by Illouz⁵ in 1980 offered a technique

for minimally-invasive defatting of the neck. Aston’s comprehensive description of the various deformities of the neck and the specific surgical maneuvers required to correct each of them was one of the first publications that highlighted the complexity of this region.⁶ It was clear that the neck needed to be treated to reverse the signs of aging, but none of the various approaches delivered consistent outcomes. A standard approach that involves the wide undermining of the submental area with plication of the medial bands became the most popular technique and is still in wide use today. The “corset platysmaplasty” described by Feldman in 1990 is an extension of the anterior band plication and involves creating “gussets” in the platysma to produce a sharply defined jawline.⁷ In addition, aggressive resection of ptotic submandibular glands has its supporters, despite the risks of bleeding, nerve injury, and dryness of the mouth.

The original design of the “open” TPP was similar to the suspension lifts reported by Guerrerosantos, Giampapa, and Ramirez⁸⁻¹⁷ (Figure 17). This approach involved construction of a shoelace-like support system placed underneath the jawline and anchored in the platysma muscle. In October 2007, the lead author (GPM) performed the first *percutaneous* platysmaplasty in conjunction with a facelift. By means of a probe with a 4-0 Teflon-coated polyester suture attached, the TPP matrix was constructed without opening the neck.

The TPP technique described here involves expanses of suture that bridge tissue, allowing the elevation and approximation of the subdermis and underlying muscle. In addition, the exposure of raw surfaces contributes to contraction of the dermis and adherence of the skin to the underlying muscle. The percutaneous TPP differs from conventional suspension lifts in that it is a low-tension dynamic support system anchored in multiple locations by the retaining ligaments along the lateral ramus. The matrix is essentially one continuous suture strand and, like a shoelace, it continually adjusts with movement. After nearly four years of follow-up in this series, it is apparent that the results are long-lasting in properly-selected patients. Overall, the open TPP has been performed by the authors for eight years (1999-2007) with consistent, durable results that are still apparent at this time, but these patients are not the subject of this study.

The success of the procedure is dependent on the ability to construct a support matrix just over the surface of the platysma muscle in the subcutaneous space. The early learning curve revealed the necessity of light guidance or direct visualization with an endoscope to precisely and consistently construct this support matrix. An accurate determination of the passage of the rod and suture could not always be achieved with palpation of the rod tip as it passed under the skin. The transillumination of light from the tip of the rod through the neck skin provides the surgeon with feedback regarding the depth of passage. Our cadaver studies support the accuracy of the light feedback system to determine the correct depth of travel in the appropriate plane.

Our experience with 105 consecutive patients treated with closed TPP has been positive, with consistently

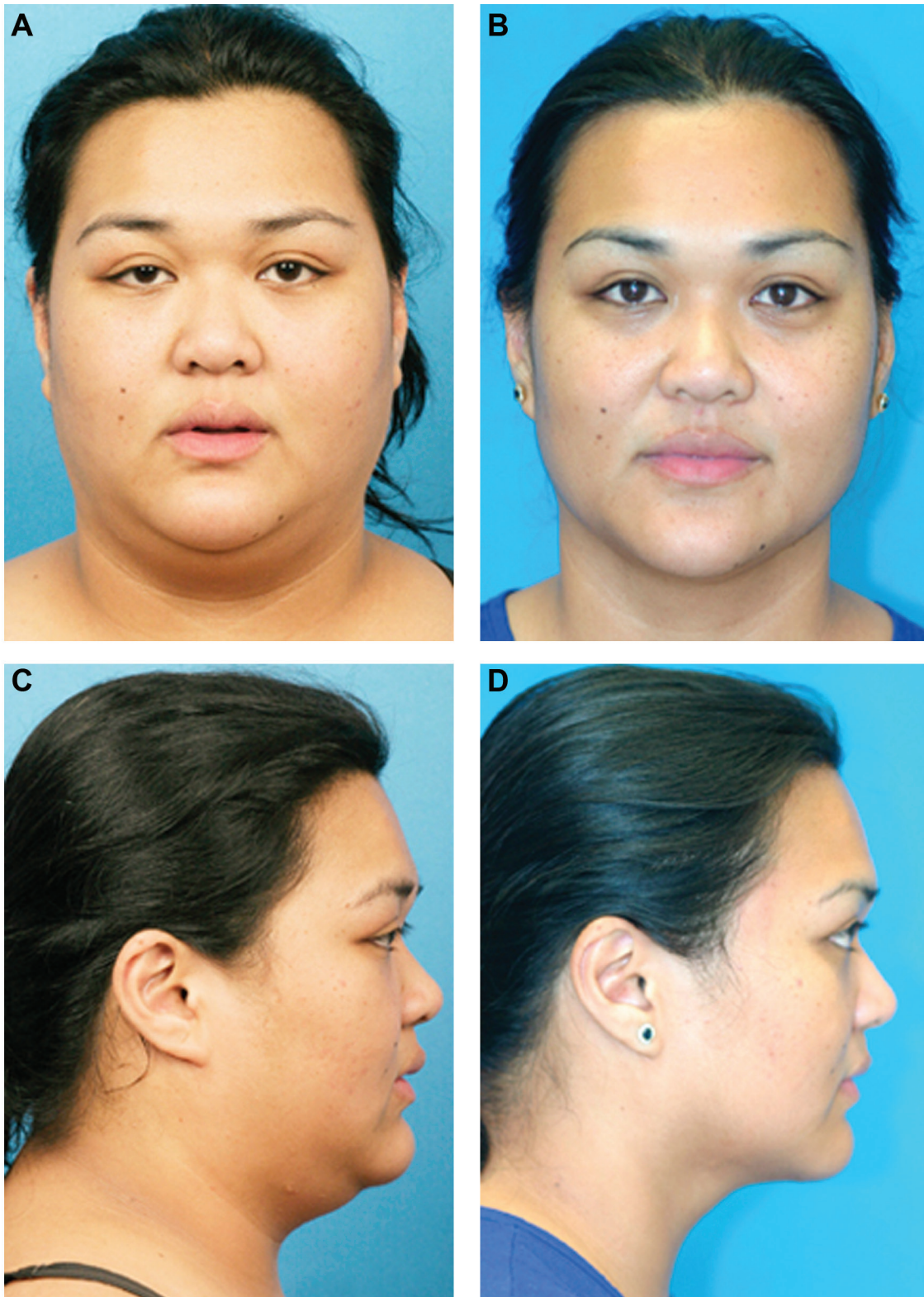

Figure 13. (A, C) This 29-year-old woman presented with platysmal banding on animation and fat deposition. (B, D) Thirty-eight months after undergoing neck liposuction and trampoline platysmaplasty. The patient lost approximately 20 lbs after the procedures through exercise and a reduction in caloric intake.

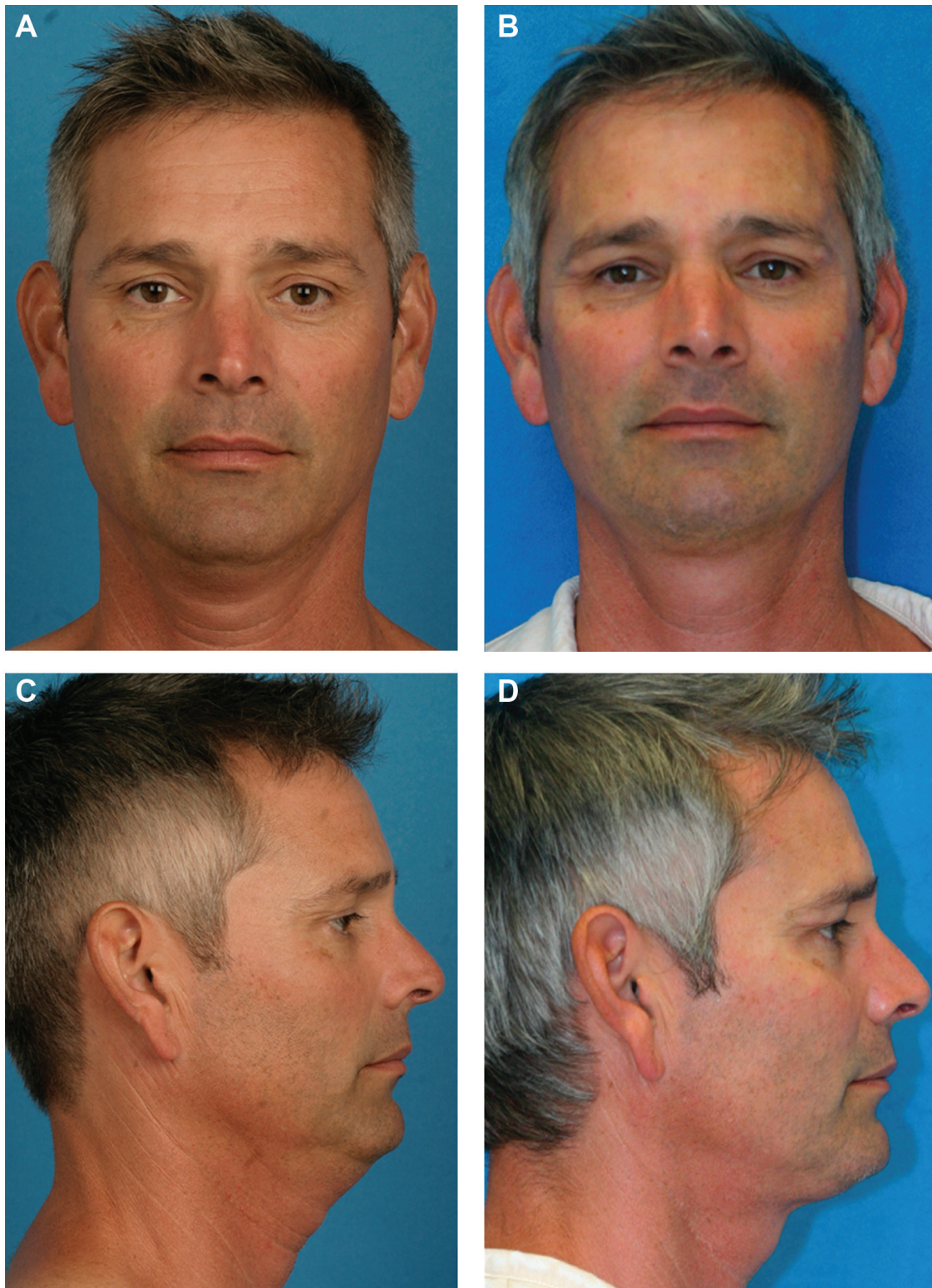

Figure 14. (A, C) This 42-year-old man presented with a genetically-inherited obtuse cervicomental angle and ptotic submandibular glands. (B, D) Thirty-one months after undergoing neck liposuction and trampoline platysmaplasty.

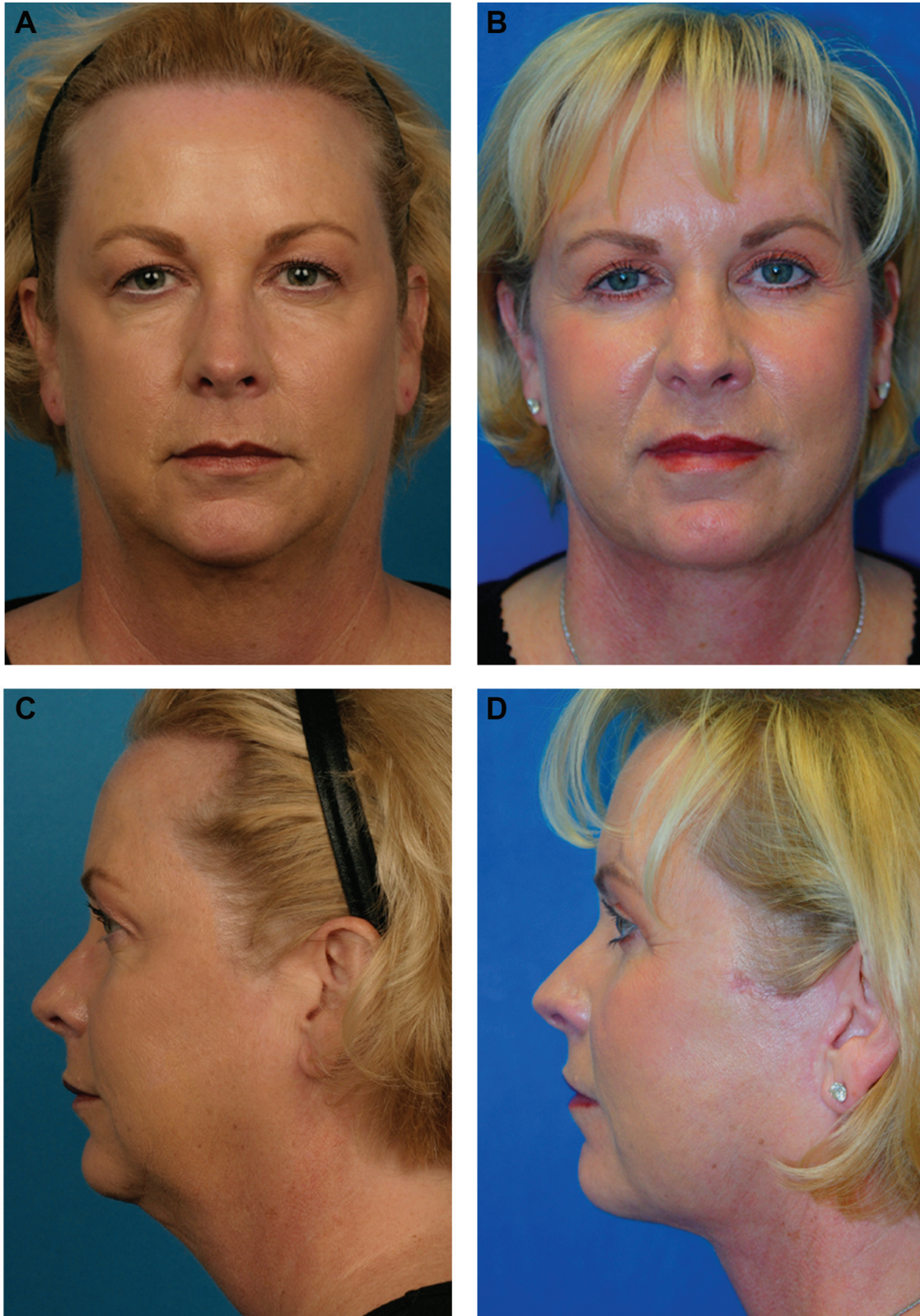

Figure 15. (A, C) This 53-year-old woman presented with an aging neck, platysmal bands, fat deposition, and skin laxity. (B, D) One year after undergoing a short-scar facelift, superficial musculoaponeurotic system plication, neck liposuction, four-lid blepharoplasty, and trampoline platysmaplasty.

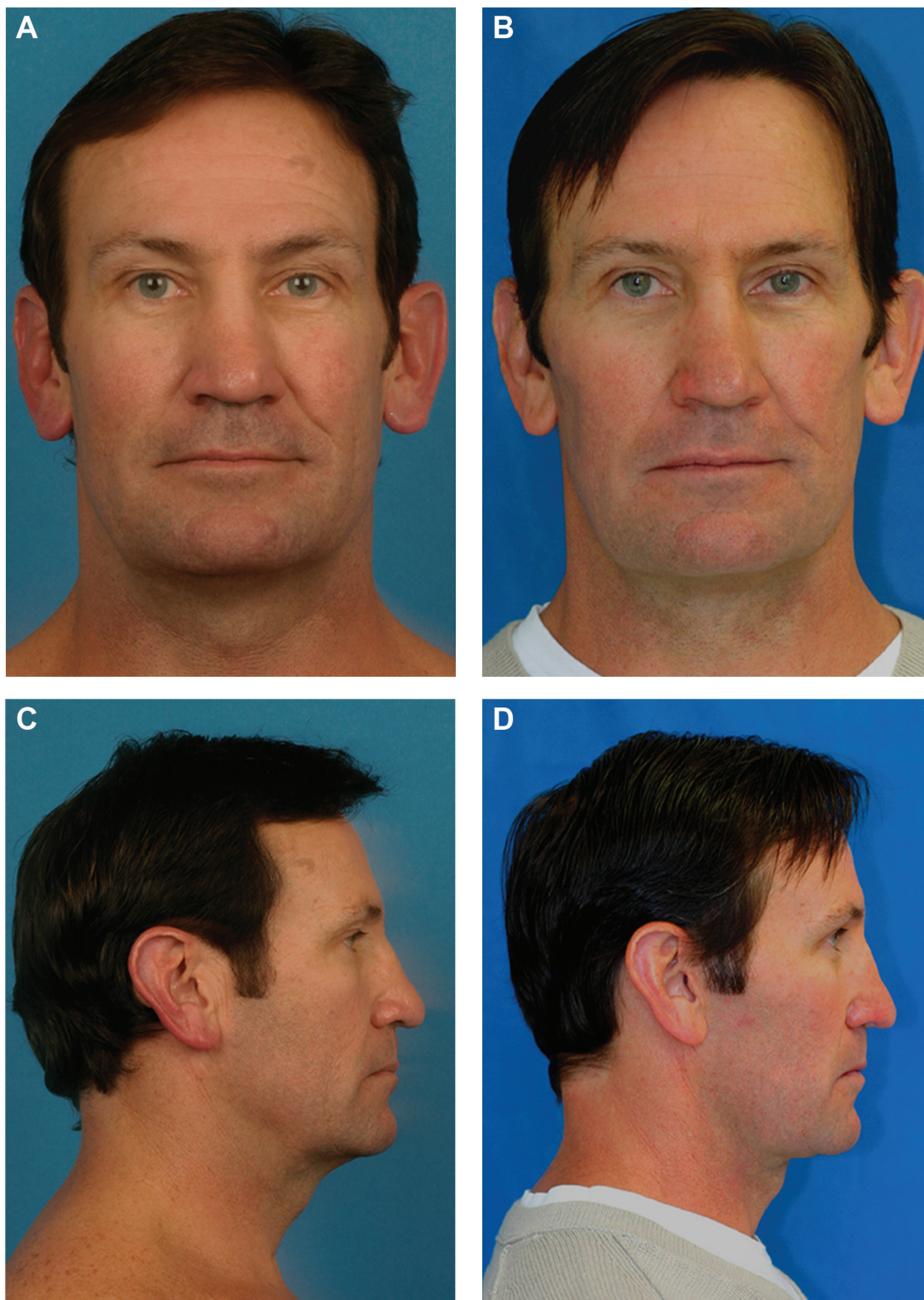

Figure 16. (A, C) This 46-year-old man presented with an aging neck, platysmal banding, and skin laxity. (B, D) Thirty-six months after undergoing a short-scar facelift, superficial musculoaponeurotic system plication, neck liposuction, and trampoline platysmaplasty.

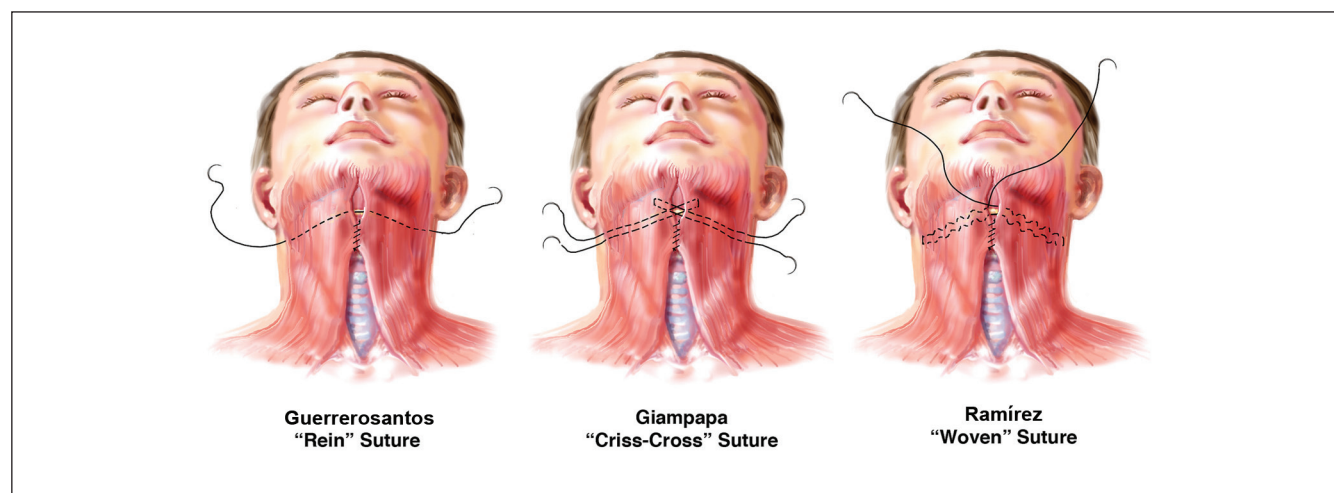


Figure 17. The original design of the open trampoline platysmaplasty was similar to the suspension lifts reported by Guerrerosantos, Giampapa, and Ramírez.

effective results and few complications. TPP is most commonly performed in conjunction with a facelift to rejuvenate the neck. Skin excision is necessary in patients who opt for a short-scar facelift. TPP can also be performed as a stand-alone procedure for those patients with early signs of aging and adequate skin elasticity or in young patients with genetically-inherited undesirable neck contours. It also serves as a bridge procedure for patients who have previously undergone more invasive facial rejuvenation operations and wish to improve or maintain their results less invasively. TPP may be performed as a stand-alone procedure, completely percutaneously, without skin excision.

Significant tension is required to obtain desired results. This is confirmed by obvious dimpling at the two anterior anchor points and tension lines underneath the chin. In most cases, the initial dimpling resolves in 24 to 48 hours and is secondary to the infiltrate and swelling caused by the procedure. However, as previously mentioned, some patients may experience dimpling upon extreme jaw flexion. This dimpling is far milder than what is seen at the conclusion of the procedure and typically resolves after the first month (Figure 18). Although patients rarely have a perfect result (as is true in most operations), those undergoing TPP in our hands have consistently experienced effective, long-lasting, natural-looking results with a short recovery period and reduced swelling and bruising.

In this report, liposuction of the neck was performed in the majority of cases to remove fat deposits, prior to performing TPP. The presence of fat deposits is determined during the preoperative patient examination by pinching the skin in several areas of the neck and comparing it to the skin on the clavicle. If the neck skin is thicker, liposuction is indicated. If not, then liposuction is unnecessary. Patients without evidence of platysma banding in repose or with flexion of the neck were treated with liposuction only and were not included in this study. Four patients

who had previously undergone aggressive fat removal in the neck with overresection were selected to undergo TPP alone, without liposuction. All four of these patients presented with soft tissue irregularities and platysma bands. TPP resulted in improvement in these patients, supporting its effectiveness as a stand-alone procedure.

The combination of liposuction to remove fat and TPP to smooth neck contours and conceal platysma banding under the jawline provided the best results both in facelift patients and those who underwent TPP alone. The synergy of the two procedures mirrors the outcomes achieved when combining liposuction or direct fat excision with traditional open-neck muscle tightening.

CONCLUSIONS

Successful rejuvenation and refinement of the neck continues to challenge surgeons. The goal of delivering consistently effective and natural-looking results is shared by all surgeons. Although TPP is similar to other techniques in that it involves placement of sutures to elevate and tighten the platysma muscle, its defining feature is the weaving of that suture material through the subcutaneous space using light transillumination to accurately assess the correct depth of passage, so that the support matrix is positioned between the platysma muscle and the skin. Anchor points located in the retaining ligaments along the lateral jawline allow the securing of the trampoline matrix and provide an upward vector of lift for the undersurface of the jawline. The matrix is dynamic, allowing the shifting of tension to the numerous anchor points because it is one continuous suture strand, similar to a shoelace. Results in our series of 105 consecutive patients with 33 months of follow-up have shown that TPP offers excellent results with proper patient selection. The exact duration of results with this procedure is yet to be determined. TPP is

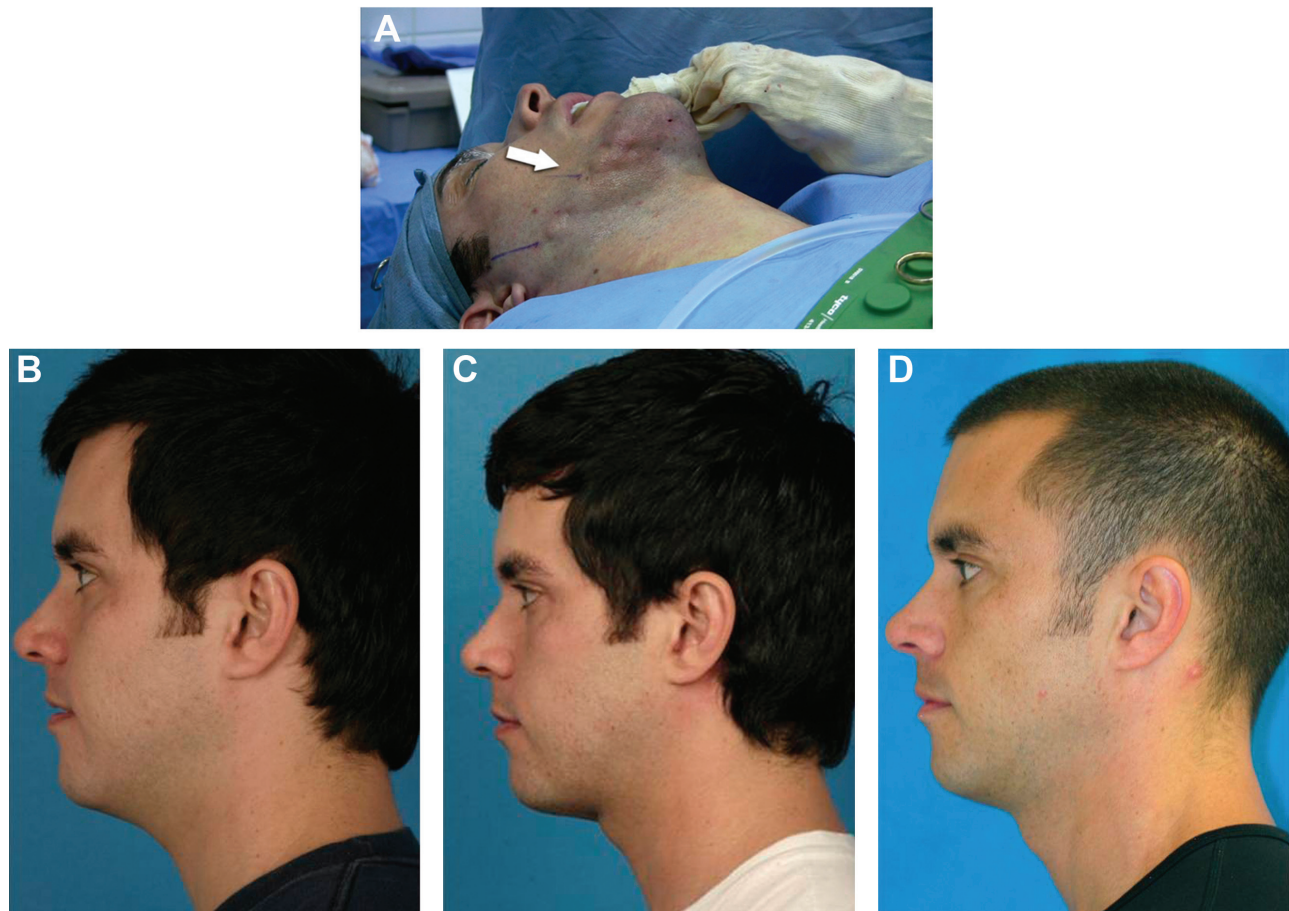

Figure 18. (A) A patient is shown immediately after undergoing neck liposuction and trampoline platysmaplasty (TPP). Note the visible dimpling and tethering at the conclusion of the procedures. (B) The patient in part A, a 34-year-old man, originally presented with a poorly defined neck contour and platysma banding on animation. (C) One day and (D) two years after TPP.

not seen as a replacement for traditional neck rejuvenation procedures, and it does not remove excess skin.

Disclosures

Dr. Gregory P. Mueller is the inventor of the iGuide Surgical Suture System manufactured by Implicitcare, LLC (West Hollywood, California) and has a financial interest in the company. Dr. Sherrell J. Aston was granted shares in Implicitcare, LLC in exchange for his consultation services. Corbett Stone was employed by Implicitcare, LLC from July 2009 to September 2010 and has been granted shares in Implicitcare, LLC for his consultation services. Dr. Norman Leaf does not have a financial interest in Implicitcare, LLC. Currently, the iGuide Surgical Suture System has general clearance for soft tissue approximation and elevation of subdermis and underlying muscle under the Food and Drug Administration (FDA) Premarket Notification K091061. Use of the iGuide Surgical Suture System to perform a necklift is considered an off-label use of the product. Implicitcare, LLC is seeking the additional indication specific for the necklift procedure.

Funding

The authors received no financial support for the research and authorship of this article.

REFERENCES

1. Furnas DW. The retaining ligaments of the cheek. *Plast Reconstr Surg* 1989;83:11-16.
2. Feldman JJ. Corset platysmaplasty. *Plast Reconstr Surg* 1990;85:333-343.
3. Khazanchi R, Aggarwal A, Johar M. Anatomy of aging face. *Indian J Plast Surg* 2007;40:223-229. Available at: <http://www.ijps.org>. Accessed August 30, 2009.
4. Guerrerrosantos J, Espaillet L, Morales F. Muscular lift in cervical rhytidoplasty. *Plast Reconstr Surg* 1974;54:127-131.
5. Illouz Y-G. Une nouvelle technique pour les lipodystrophies localizes. *La Revue de Chirurgie Esthetique de Lange Francaise* 1980;6:19-23.
6. Aston SJ. Platysma-SMAS cervicofacial rhytidoplasty. *Clin Plast Surg* 1983;10:507-520.

7. Mendelson B, Freeman W, Huggins R. Surgical anatomy of the lower face: the premasseter space, the jowl, and the labiomandibular fold. *Aesthetic Plast Surg* 2008;32:185-195.
8. Guerrerosantos J. The role of the platysma muscle in rhytidoplasty. *Clin Plast Surg* 1978;5:29-49.
9. Guerrerosantos J. Managing platysma bands in the aging neck. *Aesthetic Plast Surg* 2008;28:211-216.
10. Giampapa VC, Di Bernardo B. Neck recontouring with suture suspension and liposuction: an alternative for the early rhytidectomy candidate. *Aesthetic Plast Surg* 1995;19:217-223.
11. Giampapa VC, Bitzos I, Ramírez OM, et al. Long-term results of suture suspension platysmaplasty for neck rejuvenation: a 13-year follow-up evaluation. *Aesthetic Plast Surg* 2005;29:332-340.
12. Giampapa VC, Bitzos I, Ramírez OM, et al. Suture suspension platysmaplasty for neck rejuvenation revisited: technical fine points for improving outcomes. *Aesthetic Plast Surg* 2005;29:341-350.
13. Guerrerosantos J. Discussion: suture suspension platysmaplasty for neck rejuvenation revisited: technical fine points for improving outcomes. *Aesthetic Plast Surg* 2005;29:351-352.
14. Ramírez OM. Cervicoplasty: nonexcisional anterior approach. *Plast Reconstr Surg* 1997;99:1576-1585.
15. Ramírez OM. Cervicoplasty: nonexcisional anterior approach: a 10-year follow-up. *Plast Reconstr Surg* 2003;111:1342-1345.
16. McKinney P. Discussion: cervicoplasty: nonexcisional anterior approach: a 10-year follow-up. *Plast Reconstr Surg* 2003;111:1346-1347.
17. Ramírez OM. Cervicoplasty without skin excision. In: Shiffman MA, Mirrafati SJ, Lam SM, editors. *Simplified Facial Rejuvenation*. Berlin, Germany: Springer-Verlag; 2008. p. 614.