



The Extratemporal Facial Nerve and Its Branches: Analysis of 42 Hemifacial Dissections in Fresh Persian (Iranian) Cadavers

Aesthetic Surgery Journal
33(2) 201–208
© 2012 The American Society for
Aesthetic Plastic Surgery, Inc.
Reprints and permission:
[http://www.sagepub.com/
journalsPermissions.nav](http://www.sagepub.com/journalsPermissions.nav)
DOI: 10.1177/1090820X12473104
www.aestheticsurgeryjournal.com



Mohammad Reza Farahvash, MD; Aliasghar Yaghoobi, MD;
Benyamin Farahvash, BS; Yashar Farahvash, PharmD; and
Shahriyar Hadadi Abiyaneh, MD

Abstract

Background: The facial nerve controls facial muscles and expressions. Variability in branching patterns of the nerve creates variability in facial animation, which is evident in facial plastic surgery both between patients and ethnic groups and between sides of the face. Identifying relationships between the main trunk of the facial nerve and its network of branches to soft tissues/bony fixed points contributes to safer aesthetic and reconstructive techniques.

Objective: The authors evaluate facial nerve branches in Persian (Iranian) cadavers, propose classification of the extratemporal nerve, determine topography of the nerve using fixed facial points, and define a new fixed point.

Methods: Twenty-one cadavers were dissected, for a total of 42 hemifaces. Bicoronal and preauricular to submandibular incisions were made to deglove the face. Coded data were analyzed using a statistical program. The average of various quantitative and qualitative data points was analyzed. Averaged quantitative variables were compared between groups. The primary fixed index to specify the main trunk of the facial nerve was a point on a line from the upper edge of the tragus to the tip of the mastoid.

Results: The study confirmed the variable branching pattern of the extratemporal facial nerve. Temporal branches on the zygomatic arch numbered 1 to 3. Distance from the nearest branch to the tragus was 20.62 ± 3.84 mm on the right and 21.33 ± 3.10 mm on the left. The variability in distribution may explain different facial expressions among ethnic groups.

Conclusions: Research using cadavers may improve facial surgery procedures and clarify variability in the facial nerve branching patterns among different ethnic groups.

Keywords

facial nerve, subcutaneous facelift, SMAS plication, temporal nerve, marginal mandibular nerve, buccal nerve, zygomatic nerve, nerve injuries, SMAS, platysma, deep plane facelift

Accepted for publication June 22, 2012.

The facial nerve, which innervates the mimetic muscles that control facial expression, emerges from the stylomastoid foramen and traverses the parotid gland. The main trunk usually divides into 2 principal partitions: the “temporofacial” and “cervicofacial” portions. Facial expression is an exclusively controlled trait, and dysfunction of this nerve may lead to psychological and physical complications. Furthermore, the anatomy of the facial nerve is complicated and might vary among ethnic groups, which may explain the diverse facial expressions and animations among different groups.¹⁻³ To reduce injury to the facial nerve during facelifts, maxillofacial surgery, or radical neck dissection, plastic surgeons must proceed with careful anatomic dissection of the important facial nerve motor

Dr M. R. Farahvash is Associate Professor of Plastic Surgery and Dr Abiyaneh is Assistant Professor in the Department of Plastic Surgery, Imam General Hospital, Tehran University of Medical Sciences School of Medicine, Tehran, Iran. Dr Yaghoobi is Assistant Professor of Plastic Surgery in the Department of Plastic Surgery, Arak University of Medical Sciences School of Medicine, Arak, Iran. Mr B. Farahvash is a researcher and medical student in the Department of Dermatology at Boston University School of Medicine and Dr Y. Farahvash is a researcher and dental student at the Boston University School of Dental Medicine, Boston, Massachusetts, USA.

Corresponding Author:

Dr Mohammad Reza Farahvash, Tehran International Tower, Wing A, Apt. 1093, South Sheikhabahaei Ave, Tehran, Iran and 191 Saint Botolph Street, Apt. 2, Boston, MA, 02115, USA.
E-mail: rfarahvash@gmail.com

branches, taking anatomic variations into account. Detailed knowledge of facial nerve anatomy, including the variations among different ethnic groups, is essential to securing and distinguishing nerve branches as well as preventing iatrogenic injuries during surgery.⁴⁻⁶ Reliable, fixed landmarks in relation to this nerve and its branches are needed to predict the precise location of important structures, guarantee safe margins, prevent aesthetic and functional complications, and avert legal issues. Distinguishing the topography of the facial nerve could therefore help provide an accurate guide for predicting the precise location of this nerve.

Variations in facial nerve anatomy are well documented in the scientific literature. Davis et al⁷ described the branching patterns of the facial nerve and noted 6 patterns in 350 hemifacial dissections. The most common type (type III) had a single connection between the frontozygomatic and cervicofacial divisions, with a connecting loop between the zygomatic and buccal branches.⁷ Katz and Catalano⁸ made diagrams of the facial nerve after 100 parotidectomies, classifying them into 5 groups. In all cases, the main trunk was divided into a larger frontozygomatic and smaller cervicofacial section. On the basis of anatomic dissection of 10 fresh cadaveric hemifacial dissections, Tzafetta and Terzis⁹ demonstrated great variability in branching patterns of the facial nerve and the variations in which the facial nerve innervates mimetic musculature. Kim et al¹⁰ showed that the marginal mandibular branch of the facial nerve that exits the parotid gland was a single branch in 28% of cases, 2 branches in 52% of cases, 3 branches in 18% of cases, and 4 branches in 2% of cases. Wetmore,¹¹ Schmidt et al,¹² Correia and Zani,¹³ Gosain et al,¹⁴ and Furnas¹⁵ used facial landmarks for delineation of the facial nerve course. Furnas¹⁵ was the first to describe the fascial layers and their relationship to the frontal branch and its trajectory under the temporoparietal fascia. Pitanguy and Ramos¹⁶ substantiated this a year later. They acknowledged that the direction of the fascial branch was constant on a line starting 0.5 cm below the tragus and passing 1.5 cm above the lateral end of the eyebrow. Because of the superficial location and vulnerability of the frontal branch over the zygomatic arch,^{9,17} they recommended that, for standard rhytidectomy, the surgeon should remain at a subcutaneous level over the arch, while remaining superiorly deep in the temporoparietal fascia.⁹

The course of the temporal branch has also been described in detail in the literature.^{10,14,15,18-21} In 2008, Campero et al²² conducted a survey to determine the relationship between the temporal branch of the facial nerve and the zygomatic arch. The results suggested that the average distance from the temporal nerve to the tragus, crossing the zygomatic arch, was 18.65 mm. In 2010, Agarwal et al²³ showed that the temporal branches were consistently within the innominate fascia (the second layer, superficial to the first layer, over the zygomatic arch) overlying the zygomatic periosteum.²⁴ Trussler et al²⁵ conducted a study showing that the temporal branch of the facial nerve is protected by a deep layer of fascia called the

parotid temporal fascia, which is separate from the superficial musculoaponeurotic system (SMAS) as it traverses the zygomatic arch.²⁶ Miloro et al²⁷ showed that the distance from the most posterior temporal branch of the facial nerve to the most superior point of the external acoustic meatus was 2.12 ± 0.21 cm.

Al-Hayani,²⁸ performing an anatomic survey of the marginal mandibular branch of the facial nerve in 50 autopsy samples, demonstrated that it exhibited only a single branch in 32% of the samples, 2 branches in 40%, and 3 branches in 28%. The relationship between the nerve and the inferior margin of the mandibular body also differed: in 28% of samples, the nerve was above the inferior margin of the mandibular body; in 44% of samples, it was below; and in 28% of samples, the nerve and inferior margin of the mandibular body were parallel.²⁸

The prevalence of elective facial surgery has increased with improvement in surgical techniques and with the increased average human age. Unfortunately, the anatomy described in some of the classic references is usually discussed from a basic science perspective and rarely from a surgical point of view. Therefore, this report, and other observations like it, may lead to quantitative and qualitative improvements in procedures and outcomes for certain patients. We conducted this study to examine the facial nerve branches in Persian (Iranian) cadavers, propose classification of the extratemporal nerve, determine topography of the nerve using fixed facial points, and define a new fixed point.

METHODS

This was a topographic survey of the facial nerve and its branches on both sides of 21 fresh Persian (Iranian) cadavers, for a total of 42 hemifaces. The study was performed at the Medical Forensics Center of Tehran, Iran. Cadavers were selected in a simple nonrandom sequence. The cadavers in the sample were older than 18 years and were dissected no more than 24 hours after death. Compliance with moral and legal criteria from the Medical Forensic Institute was maintained while performing the dissections.

Prior to dissection, each cadaver's face was marked with an irregular hexagon. The selected points for marking out the hexagon were as follows: Point A = upper border of the tragus, Point B = lateral canthus, Point C = lateral oral commissure, Point D = angle of the mandible, Point F = the point in the middle of the line between Point D and the cross point between the inferior border of the mandible and the anterior facial artery, and Point G = tip of the mastoid process (Figures 1 and 2). The exact surface marking of Points A, B, C, D, G, and F helps to identify facial nerve branches before starting the operation. It also helps to avoid facial nerve branches injury. Point F is a newly defined point, which is in the middle of a line between Point D and the cross point of the facial artery with the inferior border of the mandible. The importance of Point F is that the marginal mandibular nerve is always above the inferior border of the mandible, anterior to Point F (Figure 1).

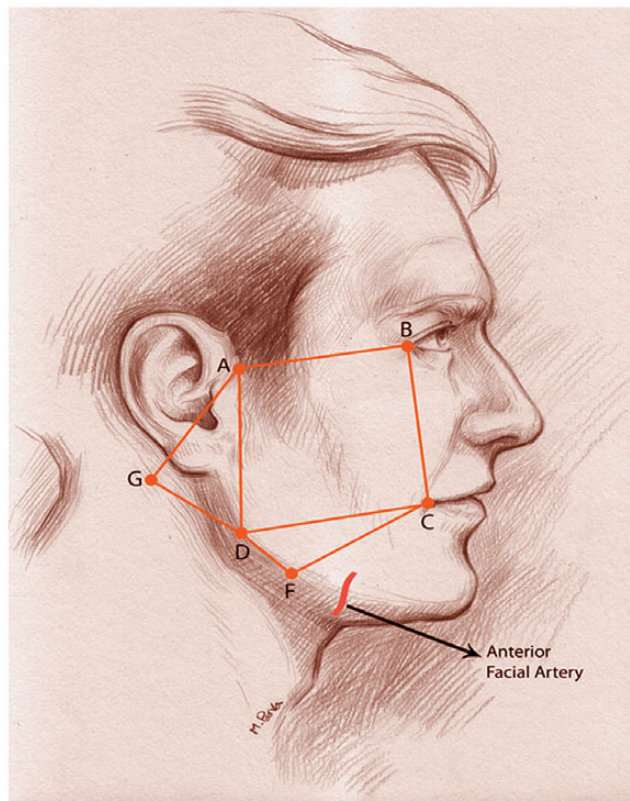


Figure 1. Hexagon ABCFDG, which was drawn on each hemiface prior to dissection. Point A is the upper border of the tragus, B is on the lateral canthus, C is on the lateral oral commissure, D is on the angle of the mandible, F is in the middle of the cross point of the facial artery with the inferior border of the mandible and point D, and G is on the mastoid process tip.

A bicorporeal incision was then made, curving along the preauricular line and continuing posteroinferiorly at the mastoid area to the posterior margin of the sternocleidomastoid muscle. After removal of the skin, dissection was started with exposure of the facial nerve trunk at its exit from the stylomastoid foramen. During dissection of the facial nerve branches, loupe magnification ($4.5\times$) was used and measurements were taken using a ruler and calipers (Table 1 and Table 2).

All coded data were imported into the computer and analyzed using the statistical program SPSS 16.0 (SPSS, Inc, an IBM Company, Chicago, Illinois).^{29,30} Analysis included the average of various quantitative inputs such as age and nerve distance, together with qualitative inputs such as sex, the number of nerve branches, and the nerve exit point. The averaged quantitative variables were compared between groups using a Student *t* test.

RESULTS

The mean \pm SD age of the dissected cadavers was 43.29 ± 18.24 years. Fourteen subjects were male (66.7%) and

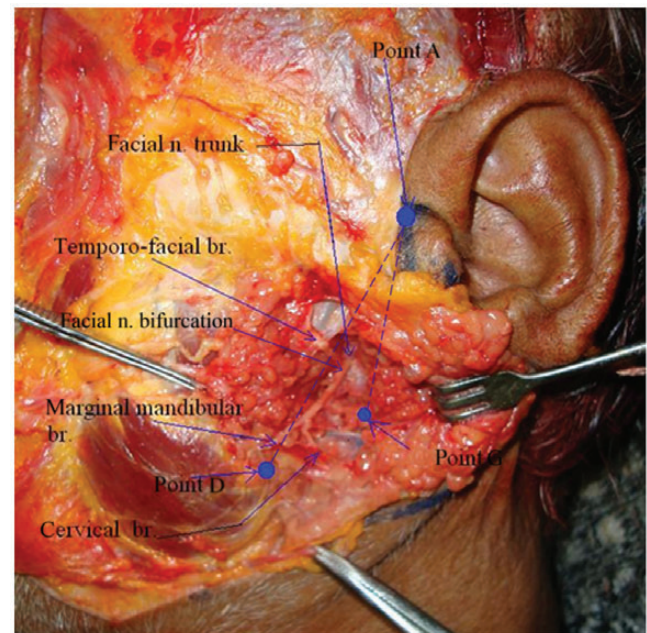


Figure 2. Left side of a cadaver face showing the distance between the facial nerve trunk, facial nerve bifurcation, and marginal mandibular nerve with point G, line A-D, and line A-G.

7 were female (33.3%). The mean \pm SD distance between the facial nerve trunk on the right side of the face and Point G on the A-G line was 11.81 ± 2.01 mm; on the left side, this distance was 11.62 ± 1.93 mm (Tables 1 and 2). The mean \pm SD distance between the facial nerve bifurcation and the AD line was 1.57 ± 2.59 mm on the right side and 1.67 ± 2.47 mm on the left side, whereas the mean \pm SD distance between the marginal mandibular branch of the facial nerve and the A-D line at the level of the mastoid tip was 2.29 ± 2.28 mm on the right side and 2.71 ± 2.72 mm on the left. These anatomic features are shown in Figure 2.

The number of temporal branches of the facial nerve on the zygomatic arch on the right side was 1 in a single cadaver (4.8%), 2 in 10 of the cadavers (47.6%), and 3 in the remaining 10 cadavers (47.6%). On the left side, it was 1 in a single case (4.8%), 2 in 8 of the cadavers (38.1%), and 3 in the 12 remaining cadavers (57.1%). The distance of the nearest temporal branch to the tragus at Point A was 20.62 ± 3.84 mm on the right side and 21.33 ± 3.10 mm on the left (Tables 1 and 2). In all cadavers, the main temporal branch was bigger than the frontal branch of the superficial temporal artery and ran parallel to this branch, ending at the posterior surface of the frontalis muscle (Figure 3). On the right side, the main temporal branch was the first branch in 7 cadavers (33.3%), the second branch in 13 cadavers (61.9%), and the third branch in 1 cadaver (4.8%). On the left side, it was the first branch in 7 cadavers (33.3%) and the second branch in 14 cadavers (66.7%). Regardless of whether this branch was the first, second, or third branch from point A, the distance of the nearest branch to point A was more than 2 cm in each

Table 1. Facial Nerve Parameters on the Right Sides

	Mean, mm \pm SD			P Value
	Total	Male	Female	
Distance between facial nerve and Point G on AG line	11.81 \pm 2.01	12.43 \pm 1.95	10.57 \pm 1.61	.043
AB distance	72.76 \pm 7.30	75.43 \pm 7.02	67.43 \pm 4.57	.014
Distance of first frontal branch to Point A	20.62 \pm 3.84	20.86 \pm 2.65	20.14 \pm 5.78	.699
Distance of second frontal branch to Point A	28.05 \pm 5.10	29.23 \pm 4.10	25.85 \pm 6.33	.164
Distance of third frontal branch to Point A	35.00 \pm 4.98	35.50 \pm 5.64	34.25 \pm 4.50	.722
Distance between facial nerve bifurcation and line AD	1.57 \pm 2.59	1.64 \pm 3.00	1.43 \pm 1.71	.864
Distance between marginal mandibular nerve and Point F	7.64 \pm 3.77	8.29 \pm 3.53	7.00 \pm 3.83	.454
Distance between marginal mandibular nerve and line AD at the mastoid level	2.29 \pm 2.28	2.43 \pm 2.34	2.00 \pm 2.30	.696

Point A, upper border of the tragus; Point B, lateral canthus; Point C, lateral oral commissure; Point D, angle of the mandible; Point F, the point in the middle of the line between Point D and the cross point between the inferior border of the mandible and the anterior facial artery; Point G, tip of the mastoid process. The *P* value represents male vs female.

Table 2. Facial Nerve Parameters on the Left Side

	Mean, mm \pm SD			P Value
	Total	Male	Female	
Distance between facial nerve and Point G on AG line	11.62 \pm 1.93	11.93 \pm 1.97	11.00 \pm 1.82	.312
AB distance	73.24 \pm 6.97	75.64 \pm 6.84	68.43 \pm 4.46	.021
Distance of first frontal branch to Point A	21.33 \pm 3.10	21.79 \pm 2.96	20.43 \pm 3.40	.358
Distance of second frontal branch to Point A	27.6 \pm 3.84	28.64 \pm 4.03	26.14 \pm 3.18	.206
Distance of third frontal branch to Point A	35.67 \pm 3.55	35.88 \pm 4.01	35.25 \pm 2.87	.789
Distance between facial nerve bifurcation and line AD	1.67 \pm 2.47	1.71 \pm 2.73	1.57 \pm 2.07	.905
Distance between marginal mandibular nerve and Point F	8.28 \pm 3.76	8.43 \pm 3.63	8.14 \pm 3.02	.860
Distance between marginal mandibular nerve and line AD at mastoid level	2.71 \pm 2.72	3.14 \pm 2.85	1.86 \pm 2.41	.320

Point A, upper border of the tragus; Point B, lateral canthus; Point C, lateral oral commissure; Point D, angle of the mandible; Point F, the point in the middle of the line between Point D and the cross point between the inferior border of the mandible and the anterior facial artery; Point G, tip of the mastoid process. The *P* value represents male vs female.

case.

On the right side over the zygomatic arch, 1 fascial layer lay beneath the temporal branch in 5 cadavers (23.8%) and 2 fascial layers in 16 cadavers (76.2%). On the left side, there was 1 fascial layer in 4 cadavers (19%) and 2 fascial layers in 17 cadavers (81%). In all cadavers, the temporal branches were deep to the SMAS and superficial temporal fascia as they crossed the zygomatic arch both at left and right sides. Only 1 zygomatic-buccal branch exited the anterior border of the parotid gland above the parotid duct and then arborized on the right side in 2 cadavers (9.5%) and on the left side in 1 cadaver (4.8%). On the right side, 3 zygomatic-buccal branches crossed line B-C and were bordered by the quadrangle formed by lines A, B, C, and D in 4 cadavers (19.0%); 4

branches crossed line B-C in 4 additional cadavers (19.0%); 5 branches crossed line B-C in 7 cadavers (33.3%); 6 branches crossed line B-C in 2 cadavers (9.5%); and 7 branches crossed line B-C in 4 cadavers (19.0%). On the left side, 3 branches crossed line B-C in 5 cadavers (23.8%), 4 branches crossed line B-C in 5 cadavers (23.8%), 5 branches crossed line B-C in 5 cadavers (23.8%), 6 branches crossed line B-C in 4 cadavers (19.0%), and 7 branches crossed line B-C in 2 cadavers (9.5%) (Figure 4).

The mean \pm SD distance between the marginal mandibular nerve and the inferior border of the mandible at Point F was 3.33 \pm 3.77 mm on the right and 2.81 \pm 3.76 mm on the left. On the right side, the marginal mandibular nerve exited from the inferior border of the parotid gland as an

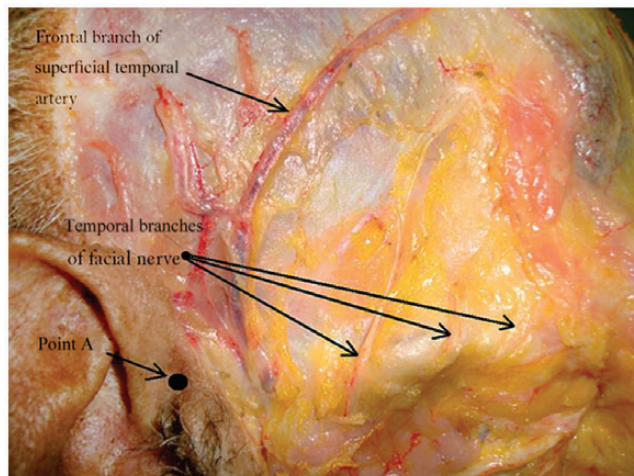


Figure 3. Commonly, there are 3 temporal branches on the zygomatic arch. The main branch runs parallel to the superficial temporal artery. In this figure, it is closer to Point A.

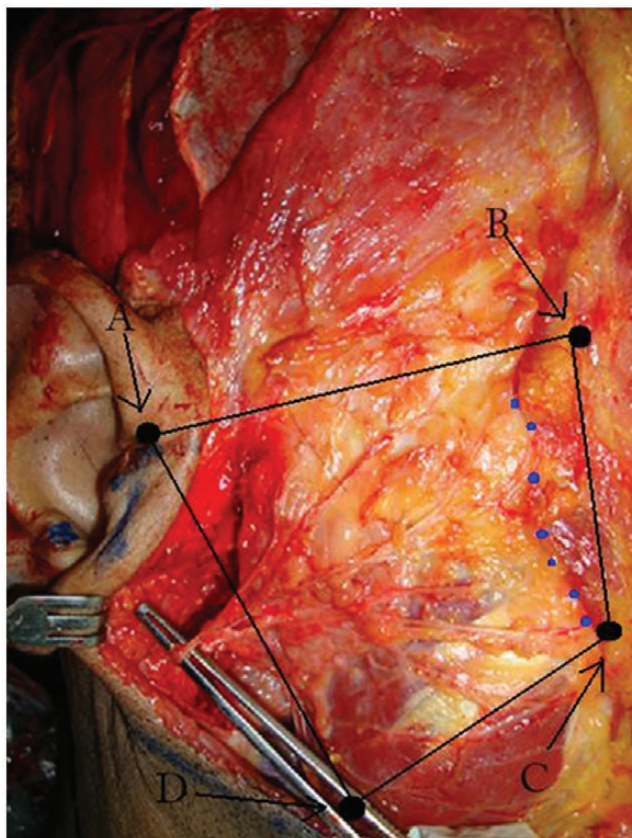


Figure 4. Seven zygomatic-buccal branches crossing line B-C (blue dots). All branches are bordered by quadrangle ABCD.

independent branch in 14 cadavers (66.7%) but was common with the buccal branches in 5 cadavers (23.8%) and common with the cervical branch in 2 cadavers (9.5%). On the left side, this nerve was independent in 16 cadavers (76.2%), was common with the buccal branches in 2

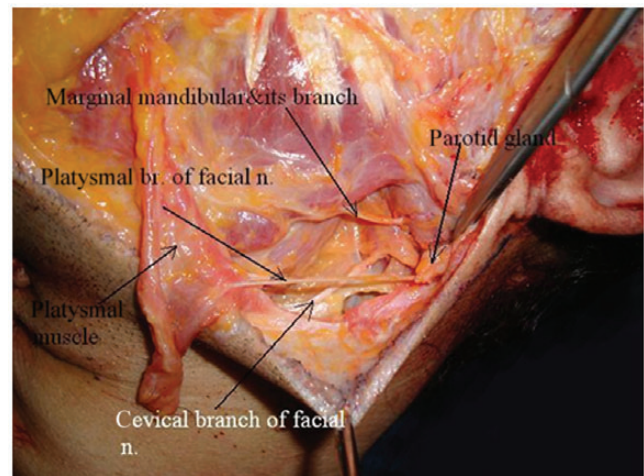


Figure 5. The platysmal branch from the marginal mandibular nerve above the mandibular angle innervates the platysma muscle. The marginal mandibular nerve on the left side of the face of this cadaver exits from the inferior border of the parotid as an independent branch.

cadavers (9.5%), and was common with the cervical branch in 3 cadavers (14.3%). On the right side, a branch from the marginal mandibular nerve above or at the level of the mandibular angle (Point D) innervated the platysma muscle in 7 cadavers (33.3%), and the cervical branch innervated the platysma muscle in 2 cadavers (9.5%). On the left side, these findings were the same.

When exiting from the lower parotid border, the marginal mandibular ramus had 1 branch. However, this branch was also common with the buccal (16.5%) and cervical branches (12%). These findings were the same in all cadavers and on both sides. Two of the 42 marginal mandibular nerves dissected from the 21 cadavers in this study featured more than 1 branch, but only a single main branch innervated the muscles below the lip in more than 90% of the cadavers ($n = 40$). Posterior to Point F, the mandibular ramus seemed to pass above the inferior border of the mandible when the distance was negative and passed below the inferior border of the mandible when the distance was positive. Anterior to Point F, 100% of the branches of the marginal mandibular nerve that innervate the depressor muscles of the lower lip seemed to be above the inferior border of the mandible.

The marginal mandibular branch, the cervical branch, or the cervicomandibular branch innervated the platysma muscle at the level of or above the mandibular angle in more than 40% of the 21 cadavers (Figure 5). Unlike the buccal branches, this branch critically passed the parotid fascia and was then superficialized. Hence, this region requires special care during dissection (Figures 2 and 5).

DISCUSSION

The results of our study on Persian (Iranian) cadavers confirm the variable branching pattern of the extratemporal facial nerve. This variability may help explain the different

facial expressions that appear among individual ethnic groups. The facial nerve branches that innervate mimetic muscles in individuals of Iranian descent may differ from those in individuals from Northern Europe. To our knowledge, this is the first time that an anatomical researcher has published a hypothesis to try to explain this difference. We have observed in many countries that different ethnic groups exhibit different types of smiling and facial animation. The animation muscles (especially the frontalis, corrugators, and platysma muscles) are not active when people speak Farsi (the Iranian language), but these muscles are very active when people speak English and certain other European languages. This may explain the fact that procedures such as frontal lifts and platysma muscle-weakening corrections are rarely performed on Iranian individuals. Additional study, including investigation of facial nerve branches of other ethnic groups, is necessary to prove this theory.

The average number of temporal branches is 3,^{12-15,21,31-34} and the number of temporal branches in the current study was between 1 and 3. As the temporal branch coursed the zygomatic arch, it was located under a fascial plane deep to the SMAS. This fascial plane is a continuation of the superficial fascia. In the current study, 1 dissectible anatomic layer lay under the temporal branch and the zygomatic arch periosteum in approximately 23.8% of the cadavers, and 2 anatomic layers lay under this area in 76.2% of cadavers. The deeper fascial layer was clearly dissectible and continuous with the deep temporalis fascia. The second layer, which was superficial to the first layer, is the innominate fascia, a fibrofatty layer deep to the SMAS. Agarwal et al²³ have shown in an evaluation of histologic cross sections that the frontal branches are consistently located within the innominate fascia overlying the zygomatic periosteum.

In their 2010 study, Trussler and colleagues²⁵ showed that the frontal branch of the facial nerve is protected by a deep layer of fascia (the parotid temporal fascia), which is separate from the SMAS as it traverses the zygomatic arch. Division of the SMAS above the arch in a high-SMAS facelift is safe using the technique described in that study.²⁵ In 3 of the 42 sides dissected in the current study (7%), only 1 branch exited from the parotid anterior border, which was above the parotid duct in all cases. More than one branch extended from this border, which emphasizes the need to pay careful attention to any dissection that occurs above the duct. These different branches have been reported by previous observations.^{32,34}

The facial nerve and the salivary duct lie in the same plane between the superficial and the deep lobe of the parotid gland. A periductal nerve plexus runs adjacent to the parotid (Stensen) duct and often crosses it. The existence of a high percentage of periductal branches suggests that surgeons should be cautious in this area and that this area should be considered a landmark for distinguishing the plane of the nerve.^{26,35} Baker and Conley²⁴ observed that the cervical division of the extratemporal facial nerve had 3 to

5 branches: 1 buccal, 3 mandibular, and 1 cervical. In 15% of patients in their study, there was a connection between buccal and mandibular branches. Lineweaver and colleagues³⁶ have also demonstrated interconnections between the buccal and marginal mandibular branches, seen in up to 88% of cadavers in their study. The dissections in the current study showed that the marginal mandibular nerve most commonly exited from the inferior border of the parotid gland as an independent branch (66.7%). The most appropriate index to specify the main trunk of the facial nerve just before bifurcation was the distance from the facial nerve to the tip of the mastoid (Point G) on the A-G line (11.8 ± 2.11 mm on the right side and 11.62 ± 1.93 mm on the left side; Figures 1 and 2).

Many authors^{10,28,36} have reported a high percentage of 2- and 3-branched marginal mandibular nerves. In this study, only 2 of the 42 marginal mandibular nerves featured more than 1 branch. In our opinion, in the majority of cases where 2 or 3 branches are reported, the branches are, in fact, buccal branches that have separated.

Saylam et al,³⁷ Erbil et al,³⁸ and May³⁹ have studied the topography of the facial nerve, its branches, and the relationships among these branches. On the basis of these studies, some authors have presented classifications for the facial nerve ramification. In the current study performed with Persian cadavers, a single mandibular branch was seen in 95.7% of cadavers, and 2 or more major branches were seen only in 4.7%. In 2010, Tzafetta and Terzis⁷ showed a single marginal mandibular branch in only 21% of cadavers in their study and 2 or more major branches in 79% of their cadavers. This difference may explain the minimal animation of the lower lip and neck among Persian individuals.

On the basis of our observations in this study regarding the branching patterns of the facial nerve, we propose the following classification system for facial nerve arborization in Iranian individuals, paying particular attention to the relationship between the marginal mandibular branch and buccal branches. Our classification system defines type I as the classic type reported in traditional anatomy books (Figure 6). Type II features buccal branches that are mainly arborized from the marginal mandibular nerve (Figure 7). In type III (the sweeper type), the buccal, zygomatic, and temporal branches are all arborized directly from the main trunk just after leaving the cervicomandibular branch (Figure 8). In type IV, which surprisingly constituted more than 40% of our cadavers, there is an area devoid of motor branches between the most inferior buccal branch and the marginal mandibular branch, and the buccal branches are arborized from the temporozygomaticobuccal branch (Figure 9). In type IV cadavers in our study, we did not see communication with the cervicomandibular branch. Of importance, a safe zone for dissection was apparent in type IV cases, situated between the lowest buccal branch and the marginal mandibular branch. This safe zone could be identified preoperatively by electroneurodiagnosis.

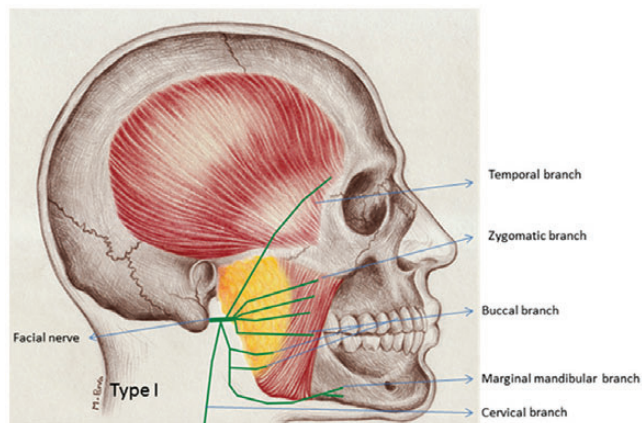


Figure 6. Type I: classic type reported in traditional anatomy books.

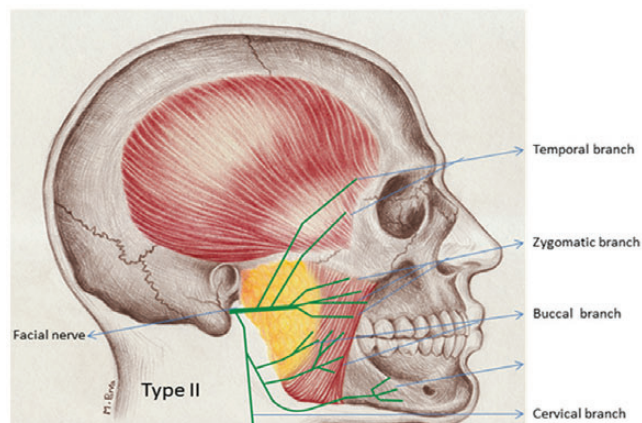


Figure 7. Type II: buccal branches are mainly arborized from the marginal mandibular branch.

CONCLUSIONS

On the basis of our findings from 42 hemifacial anatomic dissections in fresh Persian (Iranian) cadavers, which demonstrated the incredible variability of facial nerve branching patterns, we proposed a new classification of the facial nerves for Iranian patients. We defined a new fixed Point F, the point in the middle of the line between Point D (angle of the mandible) and the cross point between the inferior border of the mandible and the anterior facial artery, and measured the distance of the marginal mandibular nerve to this point. The predissection hexagon described in this article can help plastic surgeons recognize the facial nerve trunk and its branches before surgical dissection, which will prevent injury to this nerve. In addition, we defined the larger temporal nerve branch and calculated its distance to Point A, the upper border of the tragus. This study was the first research of this type to be performed in Western Asia. Overall, our results should serve as an effective surgical guide. Future studies are warranted to identify additional variability in branching patterns of the facial nerve among

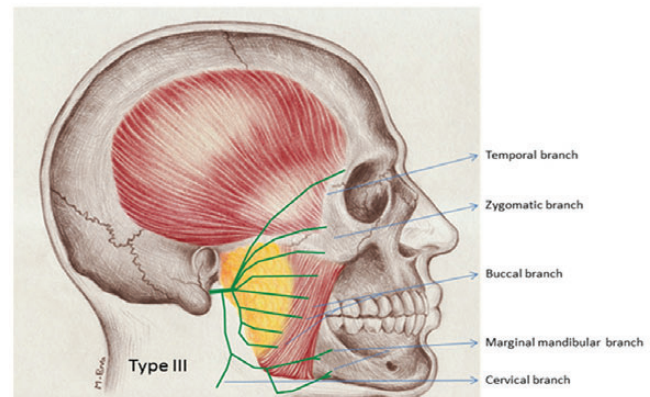


Figure 8. Type III (sweeper type): the buccal, zygomatic, and temporal branches are all arborized directly from the main trunk just after leaving the cervicomandibular branch.

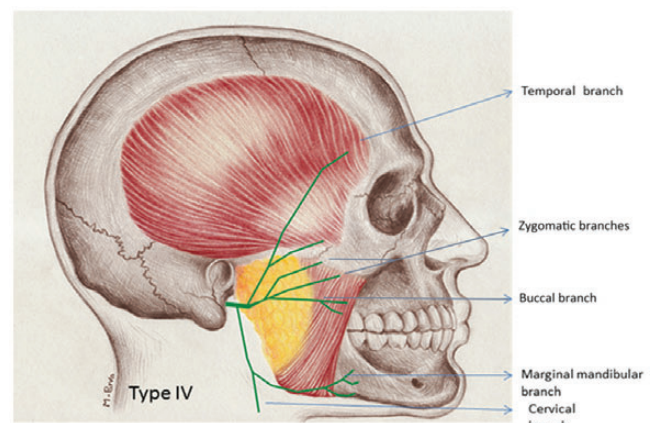


Figure 9. Type IV: the buccal branches are arborized from the temporozygomaticobuccal branch. There is an area between the lowest buccal branch and the marginal mandibular nerve that is devoid of motor branches.

different ethnic groups, which may account for the significant variations noted in facial animation patterns among these groups.

Disclosures

The authors declared no potential conflicts of interest with respect to the research, authorship, and publication of this article.

Funding

The authors received no financial support for the research, authorship, or publication of this article.

REFERENCES

1. Ekman, P. Universal and cultural differences in facial expressions of emotions. In Cole JK, ed. *Nebraska*

- Symposium on Motivation*. Lincoln: University of Nebraska Press; 1972: 207-283.
2. Marsh AA, Elfenbein HA, Ambady N. Nonverbal "accents": Cultural differences in facial expressions of emotion. *Psychol Sci*. 2003;14:373-376.
 3. Matsumoto D, Ekman P. Japanese and caucasians facial expressions of emotion (JACFEE) and neutral faces (JAC-NeuF). Slides. 1988; San Francisco, CA: San Francisco State University.
 4. Carpenter MB. *Human Neuroanatomy*. 7th ed. Baltimore, MD: Williams & Wilkins; 1976.
 5. Meining JH. *Human Anatomy*. 2nd ed. Pretoria, South Africa: van Schaik Akademies; 1997:220-222.
 6. Freilinger G, Gruber H, Happak W, Pechmann U. Surgical anatomy of the mimic muscle system and the facial nerve: importance for reconstructive and aesthetic surgery. *Plast Reconstr Surg*. 1987;80:686-690.
 7. Davis RA, Anson BJ, Budinger JM, Kurth LR. Surgical anatomy of the facial nerve and parotid gland based upon a study of 350 cervicofacial halves. *Surg Gynecol Obstet*. 1956;102:385-412.
 8. Katz AD, Catalano P. The clinical significance of the various anastomotic branches of the facial nerve: report of 100 patients. *Arch Otolaryngol Head Neck Surg*. 1987;113:959-962.
 9. Tzafetta K, Terzis JK. Essays on the facial nerve, part I: microanatomy. *Plast Reconstr Surg*. 2010;125:879-889.
 10. Kim DI, Nam SH, Nam YS, Lee KS, Chung RH, Han SH. The marginal mandibular branch of the facial nerve in Koreans. *Clin Anat*. 2009;22:207-214.
 11. Wetmore SJ. Surgical landmarks for the facial nerve. *Otolaryngol Clin North Am*. 1991;24:505-530.
 12. Schmidt BL, Pogrel MA, Hakim-Faal Z. The course of the temporal branch of the facial nerve in the periorbital region. *J Oral Maxillofac Surg*. 2001;59:178-184.
 13. Correia PC, Zani R. Surgical anatomy of the facial nerve, as related to ancillary operations in rhytidoplasty. *Plast Reconstr Surg*. 1973;52:549-552.
 14. Gosain AK, Sewall SR, Yousif NJ. The temporal branch of the facial nerve: how reliably can we predict its path? *Plast Reconstr Surg*. 1997;99:1224-1233.
 15. Furnas DW. Landmarks for the trunk and temporofacial division of the facial nerve. *Br J Surg*. 1965;52:694-696.
 16. Pitanguy I, Ramos AS. The frontal branch of the facial nerve: the importance of its variations in face lifting. *Plast Reconstr Surg*. 1966;38:352-356.
 17. Hochberg J, Kaufman H, Ardenghy M. Saving the frontal branch during a low fronto-orbital approach. *Aesthetic Plast Surg*. 1995;19:161-163.
 18. Robbins TH. The protection of the frontal branch of the facial nerve in face-lift surgery. *Br J Plast Surg*. 1981;34:95-99.
 19. Lettieri S. Frontal branch of the facial nerve: galeal temporal relationship. *Aesthetic Surg J*. 2008;28:143-146.
 20. Ishikawa Y. An anatomical study on the distribution of the temporal branch of the facial nerve. *J Craniomaxillofac Surg*. 1990;18:287-292.
 21. Stuzin JM, Wagstrom L, Kawamoto HK, Wolfe SA. Anatomy of the frontal branch of the facial nerve: the significance of the temporal fat pad. *Plast Reconstr Surg*. 1989;83:265-271.
 22. Campero A, Socolovsky M, Martins C, Yasuda A, Torino R, Rhoton AL. Facial-zygomatic triangle: a relationship between the extracranial portion of facial nerve and the zygomatic arch. *Acta Neurochir (Wien)*. 2008;150:273-278, discussion 278.
 23. Agarwal CA, Mendenhall SD III, Foreman KB, Owsley JQ. The course of the frontal branch of the facial nerve in relation to fascial planes: an anatomic study. *Plast Reconstr Surg*. 2010;125:532-537.
 24. Baker DC, Conley J. Avoiding facial nerve injuries in rhytidectomy. *Plast Reconstr Surg*. 1979;64:781-795.
 25. Trussler AP, Stephan P, Hatfield D, Schaverien M, Meade R, Barton E. The frontal branch of the facial nerve across the zygomatic anatomical relevance of the high-SMAS technique. *Plast Reconstr Surg*. 2010;125:1221-1229.
 26. Kitamura T, Togawa K. Surgery of Stensen's duct. *Arch Otolaryngol*. 1971;93:189-193.
 27. Miloro M, Redlinger S, Pennington DM, Kolodge T. In situ location of the temporal branch of the facial nerve. *J Oral Maxillofac Surg*. 2007;65:2466-2469.
 28. Al-Hayani A. Anatomical localisation of the marginal mandibular branch of the facial nerve. *Folia Morphol (Warsz)*. 2007;66:307-313.
 29. Llesvesque R. *SPSS Programming and Data Management: A Guide for SPSS and SAS Users*. 4th ed. Chicago, IL: SPSS, Inc; 2006.
 30. Argyrous G. *Statistics for Research: With a Guide to SPSS*. 2nd ed. London: Sage; 2005.
 31. Fatah MF. Innervation and functional reconstruction of the forehead. *Br J Plast Surg*. 1991;44:351-358.
 32. Salas E, Ziyal IM, Bejjani GK, Sekhar LN. Anatomy of the frontotemporal branch of the facial nerve and indications for interfascial dissection. *Neurosurgery*. 1998;43:563-568.
 33. Saylam C, Ucerler H, Orhan M, Ozek C. Anatomic guides to precisely localize the zygomatic branches of the facial nerve. *J Craniofac Surg*. 2006;17:50-53.
 34. Ammirati M, Spallone A, Ma J, Cheatham M, Becker D. An anatomical study of the temporal branch of the facial nerve. *Neurosurgery*. 1993;33:1038-1044.
 35. Kitamura T, Togawa K, Tsukamoto K, Naito J. Extratemporal facial nerve surgery. *Arch Otolaryngol*. 1972;95:369-375.
 36. Lineweaver W, Rhoton A, Habal MB. Microsurgical anatomy of the facial nerve. *J Craniofac Surg*. 1997;8:6-10.
 37. Saylam C, Ucerler H, Orhan M, Ozek C. Anatomic landmarks of the buccal branches of the facial nerve. *Surg Radiol Anat*. 2006;28:462-467.
 38. Erbil KM, Uz A, Hayran M, Mas N, Senan S, Tuncel M. The relationship of the parotid duct to the buccal and zygomatic branches of the facial nerve: an anatomical study with parameters of clinical interest. *Folia Morphol (Warsz)*. 2007;66(2):109-114.
 39. May M. Facial nerve anatomy and common branching patterns. In: *The Facial Nerve*. New York, NY: Thieme; 1986:P55.