

Interpretation of Gram Stains for the Nonmicrobiologist

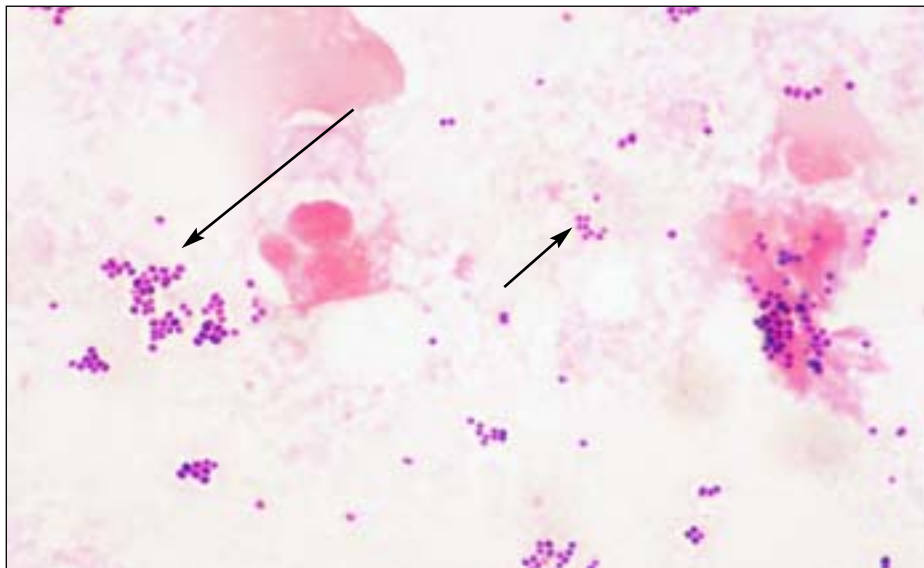
Joan Barenfanger, MD, MMB, ABMM, and Cheryl A. Drake, SM(ASCP)

From the Department of Laboratory Medicine, Memorial Medical Center, Springfield, IL

- ▶ Guidelines for the interpretation of Gram stains
- ▶ Normal flora in respiratory secretions
- ▶ Normal flora in the female genital tract
- ▶ Presumptive identification of microorganisms from Gram stain
- ▶ Correlation of findings

Laboratories everywhere are being asked to do more with less. To enable the laboratory to offer increased services over an expanded period of time, many technologists with little experience in microbiology are now asked to perform and read Gram stains. Interpretation of Gram stains is notoriously difficult for nonmicrobiologists because such interpretation requires multiple observations and the judgment that comes with years of experience. This article offers objective criteria for interpreting the most commonly encountered Gram-stained specimens.

An adequate examination of a Gram-stained smear includes observing numerous representative fields. The fields containing neutrophils yield the most useful information. A minimum of 1 minute should be spent examining a smear; after that, judgment is needed. Obviously, a smear from the cerebrospinal fluid (CSF) with neutrophils deserves more time than an acellular smear. Similarly, more time should be spent on a specimen that was obtained



[11a] Staphylococci: gram-positive cocci in the tetrads (short arrow) and clusters (long arrow) as well as the nonspecific singles and pairs.

by an invasive technique than on one that was easy to obtain.

Generally, only 1 morphotype (bacteria with a certain Gram stain and shape, eg, gram-negative bacilli) is seen in a sterile site. For instance, only gram-negative diplococci are expected in a patient's CSF, not gram-negative diplococci as well as gram-positive cocci. If both of these morphotypes are seen, most likely the problem is over- or underdecolorization.

The problem with decolorization must also be considered when the shape

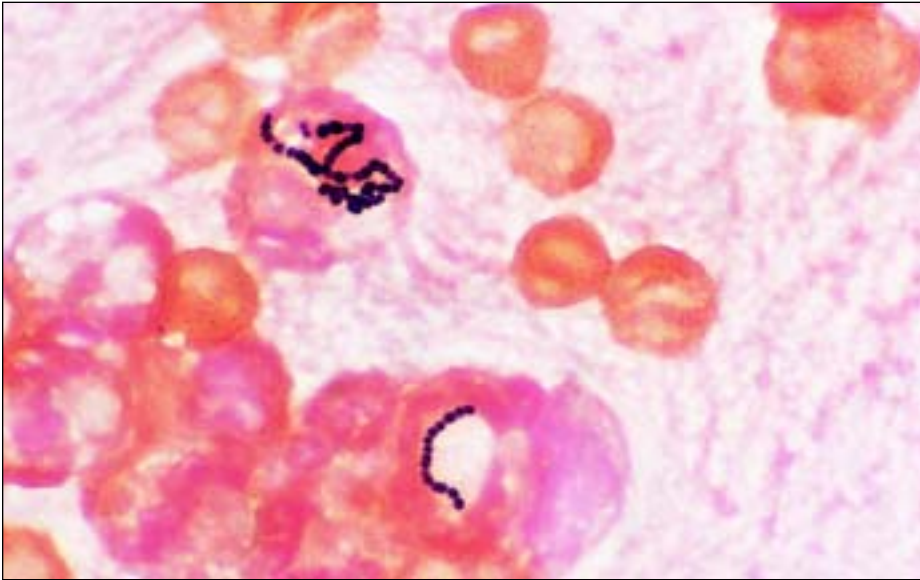
of the organism does not “fit” the Gram stain. Please refer to Images 1a through 1j for Gram stains of characteristic morphotypes (all images $\times 100$ oil except G and J). For instance, gram-positive cocci seen in tetrads and clusters or in long chains are highly characteristic of staphylococci and streptococci, respectively [T1] [11a] [11b], but may appear gram-negative because of overdecoloration. Similarly, classic gram-positive diplococci are lancet-shaped or pointed at the outside ends [T1] [11c]. If gram-positive diplococci flattened at the out-

Presumptive Identification Based on Gram Stain and Morphologic Features

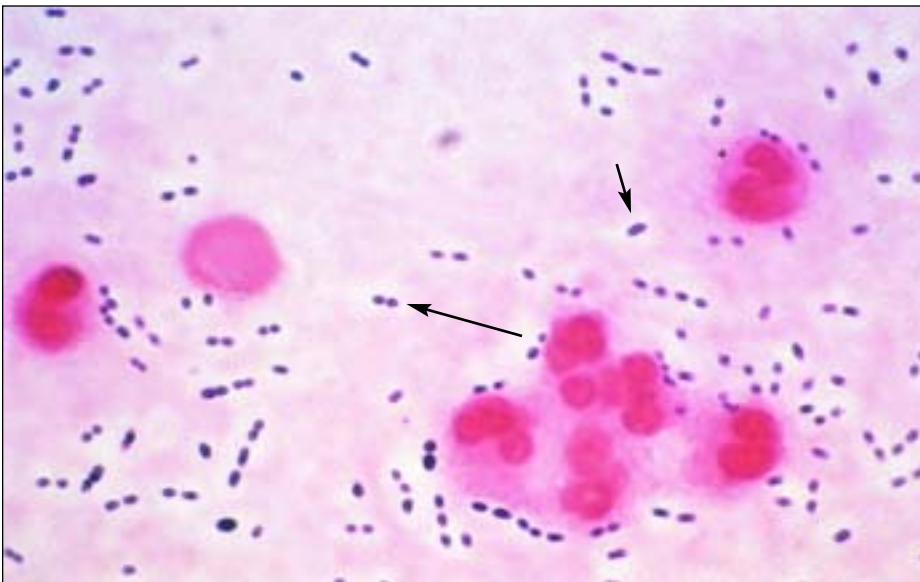
T1

Gram Stain Findings	Presumptive Identification	Most Likely Site(s)/Comment
Gram-positive cocci in clusters or tetrads	Staphylococci	Any site including GI and respiratory tract, skin, blood, and urine
Gram-positive cocci in long chains (>5 cocci)	Streptococci (all groups, including <i>Streptococcus viridans</i>) and enterococci	Any site including GI and respiratory tract, skin, blood, and urine
Gram-positive diplococci and chains; occasionally with a capsule	<i>Streptococcus pneumoniae</i>	Any site, especially respiratory, blood, and CSF; the gram-positive diplococci differ from the gram-negative diplococci in that the former are pointed at the ends, or lancet shaped, unlike the latter, which are flat or biscuit or kidney-bean shaped
Gram-positive cocci in singles, pairs, and short chains	Staphylococci or streptococci	Any site including GI and respiratory tract, skin, blood, and urine
Gram-positive bacilli		
	Lactobacilli	Lactobacilli are generally long, slender, large gram-positive bacilli but may be more variable or may be chains or spirals or short and coccobacillary forms; they are seen as normal flora in respiratory and genital sites but rarely cause infection
	Diphtheroids	Diphtheroids are usually small, pleomorphic gram-positive bacilli often in club-shaped or angular arrangements (V and L shapes or "Chinese lettering"); they are often seen as normal flora but rarely cause infection
	<i>Clostridium</i> organisms	<i>Clostridium</i> organisms are large, box-car-shaped bacilli that may contain spores and may decolorize easily, appearing to be gram-negative; the finding of gram-positive bacilli with spores in a wound without the presence of neutrophils is highly suggestive of <i>Clostridium</i> organisms because these organisms have enzymes that lyse WBCs, thus making the smear appear acellular; <i>Clostridium</i> organisms may be present in wounds, especially with other organisms
	<i>Listeria</i> organisms	<i>Listeria</i> are generally small and regular gram-positive bacilli that are seen mostly in CSF
Gram-positive coccobacilli	—	Rarely seen clinically
Gram-negative cocci	—	Rarely seen clinically unless in the presence of gram-negative diplococci, in which case the gram-negative cocci should not be specifically reported
Gram-negative coccobacilli	<i>Haemophilus influenzae</i> , <i>Gardnerella vaginalis</i>	<i>H influenzae</i> : respiratory tract or CSF <i>G vaginalis</i> : genital secretions
Gram-negative diplococci	<i>Neisseria</i> organisms, <i>Moraxella</i> organisms	<i>Neisseria gonorrhoeae</i> : genital and joint (sexually transmitted disease) <i>Neisseria meningitidis</i> : CSF and respiratory secretions <i>Moraxella</i> organisms: respiratory tract The gram-negative diplococci differ from the gram-positive diplococci in that the former are flat or biscuit or kidney-bean shaped, unlike the latter, which are pointed at the ends or lancet shaped
Gram-negative rods (bacilli)	<i>Pseudomonas aeruginosa</i> , enterics including <i>Escherichia coli</i> , and anaerobes such as <i>Bacteroides</i> organisms	Any site including GI and respiratory tract, skin, blood, and urine

CSF, cerebrospinal fluid; GI, gastrointestinal.



[11b] Streptococci: gram-positive cocci in long (>5 cocci) chains. Note the intracellular location.



[11c] *Streptococcus pneumoniae*: gram-positive lancet-shaped (pointed ends) diplococci (long arrow). The capsule (short arrow) is visible as a halo around the bacteria, providing another clue that this is *S pneumoniae*.

imens [11d]. Interestingly, when these same organisms are grown in the laboratory and then stained, they are strongly gram-positive. Alternatively, there are rare instances of classically gram-negative organisms such as *Moraxella* and *Acinetobacter* species that tend to retain the crystal violet stain and appear to be gram-positive. Use of the term gram-variable should be restricted to cases in which the laboratorian really cannot determine whether the organism is gram-positive or gram-negative.

Occasionally, debris and artifacts mimic organisms. To avoid this problem, bacteria should not be reported automatically unless more than 1 is seen. For instance, if only 1 gram-positive coccus or even a pair of cocci is seen after examining numerous fields, one should consider: (1) not reporting this result, (2) obtaining consultation with another technologist before reporting, or (3) reporting “possible” or “probable” bacteria.

Normal Flora in Respiratory Secretions

Unless clearly associated with neutrophils or seen intracellularly, the various organisms of normal flora need not necessarily be reported individually. In fact, doing so may be confusing and misleading to the clinician who may interpret these organisms as potential pathogens simply because “the laboratory reported it.” However, if any single morphotype (even one that is considered normal flora) is closely associated with neutrophils, its presence should be reported, and if this morphotype is intracellular, its intracellular location should also be noted in the report.

There are 2 main clues that an organism is truly intracellular and not merely lying on top of a neutrophil (RT Thompson, oral communication, Evanston Hospital, Evanston, IL). First, the organisms may be concentrated within a neutrophil because phagocytosis is an active process. Second, the organisms may be seen displacing something in the cytoplasm, usually the nucleus or a vacuole. In addition, unless

side ends are seen, the smear might be underdecolorized because generally gram-negative diplococci are kidney-bean or biscuit shaped with flattened ends [T1] [11e].

Interpretation of Gram stains should be based only on areas of the smear that take up the Gram stain properly. Even in a well-performed stain, a thick smear may contain areas that are underdecolorized or overdecolorized. Purple precipitate is often present in an area of

underdecolorization, and the nuclei of neutrophils are purple. Examining an area of underdecolorization may result in the interpretation of gram-negative bacteria as gram-positive.

The term “gram variable” refers to organisms that take up the positive (crystal violet) stain variably. Frequently, organisms such as *Clostridium* species will be gram-variable or even appear frankly gram-negative on smears made directly from patient spec-

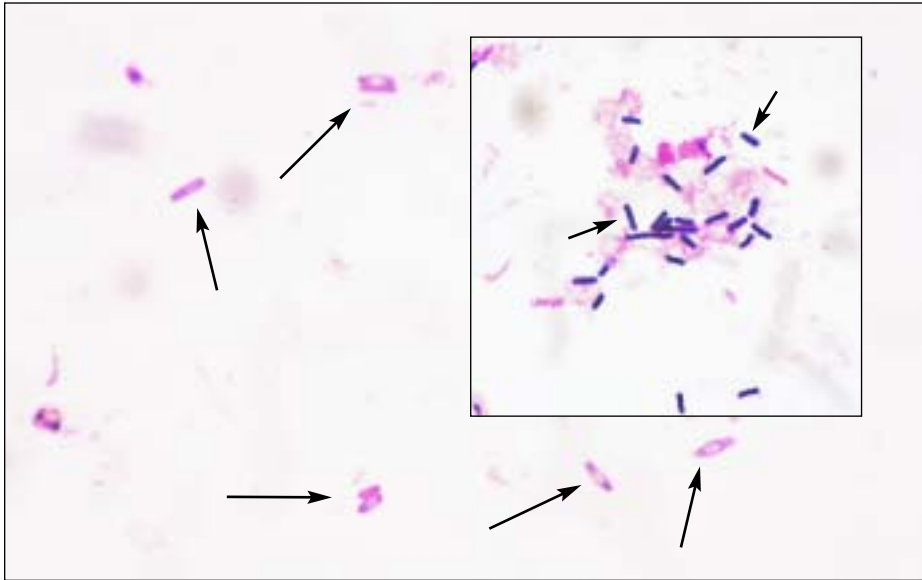
Morphotypes Expected From Common Sites*

Site	Gram Stain/Organism Expected	Comment
CSF	Gram-negative diplococci (<i>Neisseria</i> organisms); gram-negative coccobacilli (<i>Haemophilus</i> organisms); gram-positive cocci (in long chains and diplococci, streptococci; in clusters and tetrads, staphylococci); gram-positive rods (<i>Listeria</i> organisms)	In a sterile site, expect only 1 morphotype; <i>Staphylococcus epidermidis</i> is generally expected if the CSF is from a shunt (here this organism is usually not a contaminant); streptococci and <i>Listeria</i> organisms are expected in infants and in elderly people
Joint	Gram-positive cocci (in tetrads or clusters, staphylococci; in long chains and diplococci, streptococci); gram-negative diplococci (<i>Neisseria</i> organisms); gram-negative coccobacilli (<i>Haemophilus</i> organisms); gram-negative rods (enterics such as <i>Escherichia coli</i>)	In a sterile site, expect only 1 morphotype; staphylococci are the most common organisms in this site; <i>Neisseria</i> organisms would be expected only in a sexually active patient
Blood†	Gram-positive cocci (especially in clusters and tetrads, staphylococci; in long chains, streptococci and enterococci; diplococci, <i>Streptococcus pneumoniae</i>); gram-negative coccobacilli (<i>Haemophilus</i>); gram-negative rods (<i>Pseudomonas aeruginosa</i> , "enterics" including <i>Escherichia coli</i> , and anaerobes such as <i>Bacteroides</i> organisms); gram-positive bacilli (<i>Clostridium</i> or <i>Listeria</i> or diphtheroids)	In a sterile site, expect only 1 morphotype
Respiratory	Gram-positive cocci (especially diplococci, <i>S pneumoniae</i>; in chains, streptococci; in clusters and tetrads, staphylococci); gram-negative diplococci (<i>Moraxella</i> organisms); gram-negative coccobacilli (<i>Haemophilus</i> organisms); gram-negative rods (pseudomonads and enterics such as <i>E coli</i>); gram-positive bacilli (lactobacilli and diphtheroids, almost never clinically significant); large gram-positive oval forms with budding/hyphae (yeasts)	Normal oral flora include: gram-positive cocci, gram-positive bacilli, gram-negative diplococci, gram-negative coccobacilli, gram-negative bacilli, and even yeasts; gram-negative bacilli are frequent causes of hospital-acquired pneumonia
Wound/abscess	Gram-positive cocci (especially in clusters and tetrads, staphylococci; in long chains, streptococci and enterococci); gram-negative rods (<i>Pseudomonas aeruginosa</i> , enterics including <i>E coli</i> , and anaerobes such as <i>Bacteroides</i> organisms); gram-positive bacilli (<i>Clostridium</i> organisms and diphtheroids)	More than 1 morphotype may be present
Urine	Gram-negative rods (pseudomonads and enterics such as <i>E coli</i>); gram-positive cocci (especially in long chains, streptococci and enterococci; in clusters and tetrads, staphylococci); large gram-positive oval forms with budding/hyphae (yeasts)	—
Genital	Gram-negative diplococci (<i>Neisseria</i> organisms) gram-negative coccobacilli (<i>Gardnerella</i> organisms); gram-negative rods (enterics such as <i>E coli</i> and pseudomonads); gram-positive cocci (especially in long chains, enterococci and streptococci; in clusters and tetrads, staphylococci); gram-positive bacilli (lactobacilli, which almost never cause disease); large gram-positive (or variable) oval forms with budding/hyphae (yeasts)	Normal female flora include: gram-positive cocci, gram-positive bacilli, and gram-negative bacilli; <i>Neisseria</i> organisms would be expected in a sexually active or sexually abused patient; gram-negative diplococci are diagnostically significant for gonococcal infection only in a urethral smear from a man; women may have saprophytic gram-negative diplococci in the genital tract; bacterial vaginosis characteristically has: (1) an absence of inflammatory cells; (2) a decreased number of gram-positive lactobacilli morphotypes; (3) an excess number of pleomorphic gram-negative bacilli, curved rods, and coccobacilli; and (4) clue cells

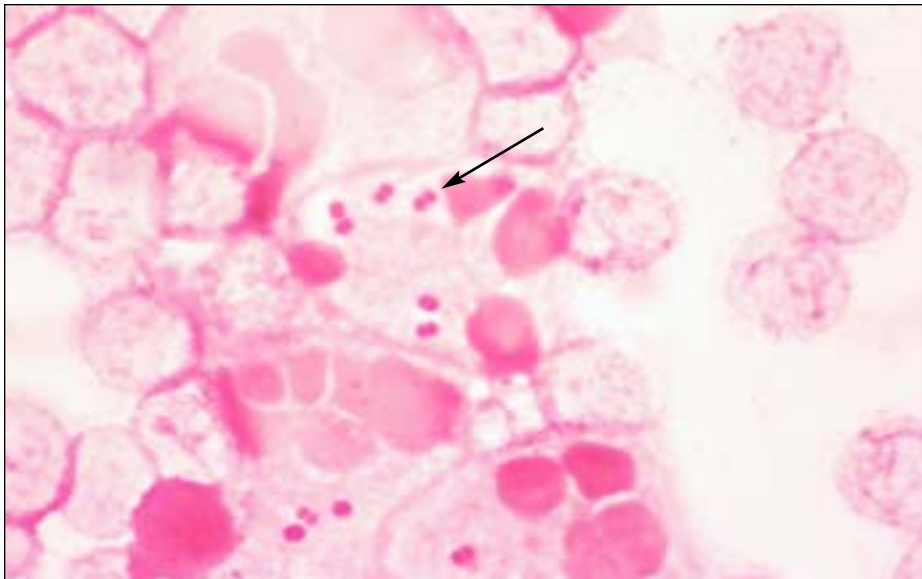
CSF, cerebrospinal fluid.

*In nonsterile sites, the common potential pathogens are in **boldface**.

†Unlike the other specimen types, blood is not examined directly for organisms. This row describes what is to be expected from blood that has been cultured previously.



[11d] Clostridium species: gram-variable bacilli with spores (long arrows). Note the lack of neutrophils, which were most likely lysed by the enzymes of the bacteria. The inset shows the Gram stain of the same organism grown in the laboratory. Note that most of the bacilli are taking up the Gram stain (short arrows), making them easy to interpret as gram-positive bacilli.



[11e] Moraxella/Neisseria species: gram-negative diplococci with kidney-bean or biscuit-shaped ends (arrow). Note the intracellular location.

part of this screen, a search for neutrophils should be made on low power [11]. Generally, in a nonsterile specimen such as sputum, the only bacteria that are of interest are found closely associated with neutrophils.

There is one exception to lumping the morphotypes of normal flora in sputum specimens rather than reporting them individually. Sometimes organisms that are present in normal flora are also important causes of community-acquired pneumonia (eg, *Streptococcus pneumoniae*, *Moraxella catarrhalis*, and *Haemophilus influenzae*) or nosocomial pneumonia (eg, gram-negative bacilli). The specific morphotypes of normal flora should be reported: (1) if the bacteria are seen in moderate numbers and are associated with neutrophils; (2) if they are seen intracellularly; or (3) if more than 2 to 3 yeasts are seen, in which case they should be specifically reported.

For instance, morphotypes of *M catarrhalis* (gram-negative diplococci) are considered normal flora [T1] [T2] [11e]. If they predominate and are seen with neutrophils or (more significantly) are seen intracellularly within neutrophils, the report should specifically note the presence of the gram-negative diplococci, quantitate them, and note their intracellular location. Noting in the report an intracellular location of an organism alerts the clinician that this organism is causing infection rather than simply colonizing the patient. [T2] indicates the common potential pathogens by specimen type.

Normal Flora in the Female Genital Tract

A wide variety of bacterial flora is found normally in the female genital tract, including gram-positive cocci in singles, pairs, chains, clusters, and tetrads, gram-positive bacilli that appear slender (lactobacilli), pleomorphic (diphtheroids) or large box-car shaped (*Clostridium* organisms), gram-negative bacilli, gram-negative pleomorphic bacilli, gram-negative coccobacilli, and even a few yeasts. Although some saprophytic *Neisseria* species or organisms that look like *Neisseria*

the infection is polymicrobial, only 1 morphotype will be seen intracellularly.

The morphotypes of normal oral flora seen in respiratory specimens are gram-positive cocci, gram-positive bacilli, gram-negative diplococci, gram-negative coccobacilli, gram-negative bacilli, and even a very few yeasts [T2]. With the exceptions described in the following paragraph, these organisms can be considered and reported as “bacteria consistent with

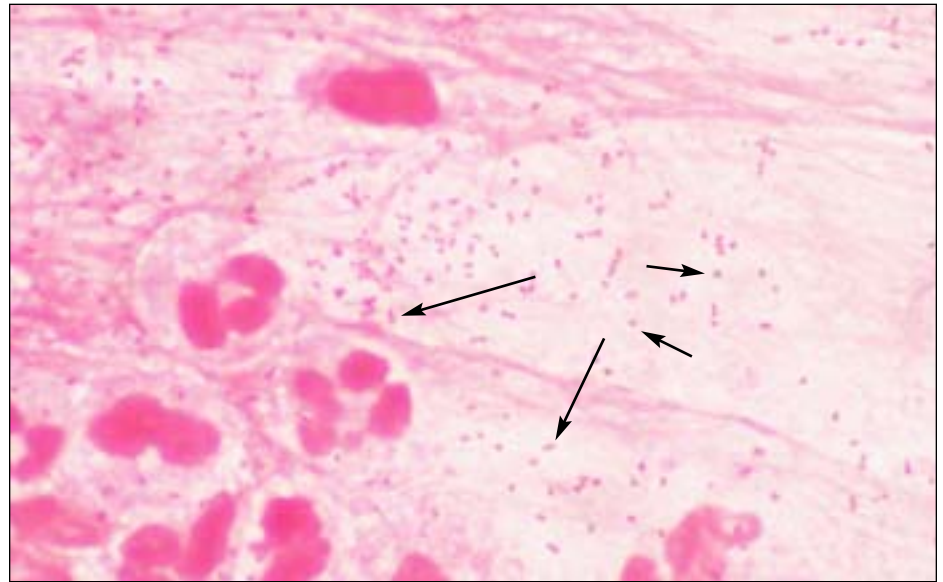
normal oral flora.” Some specimens, notably sputum specimens, can contain anaerobes as part of normal flora. Caution should be used in reporting large gram-positive rods and/or fusiform gram-negative rods. These may be included as part of the “bacteria consistent with normal oral flora.” All sputum specimens should be screened by Gram stain for acceptability before routine culturing. This process is well reviewed elsewhere.¹⁻⁴ As

gonorrhoeae on Gram stain and yeasts are occasionally seen in the genital tract, they should be reported because they share morphotypic characteristics with the common genital pathogens, *N gonorrhoeae* and *Candida* organisms.⁵⁻⁸ If extracellular organisms resembling the morphotypes of *N gonorrhoeae* are seen, the microscopist should continue examining the slide for intracellular gram-negative diplococci, which have more diagnostic significance.

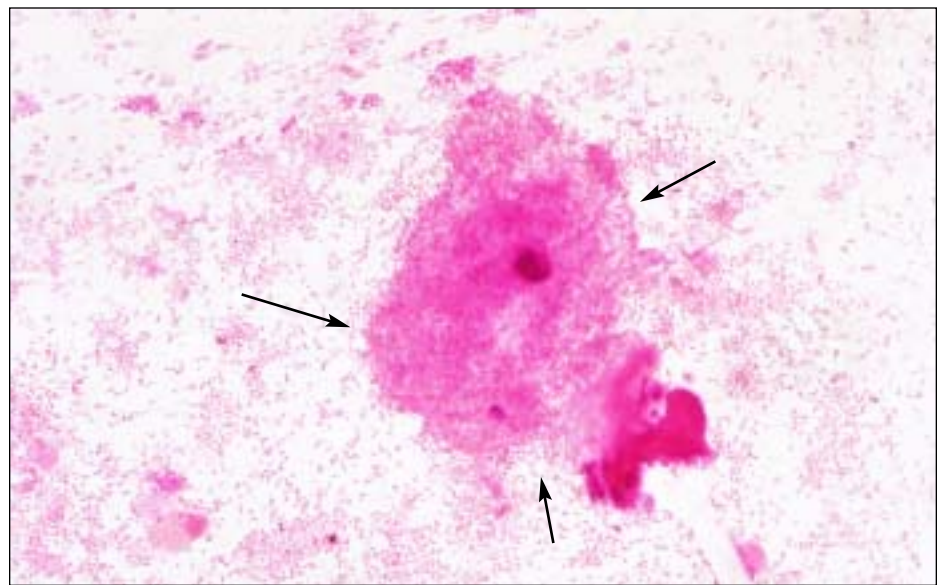
The predominance of slender gram-positive bacilli (which are most likely lactobacilli) is normal. The Gram stain is an important component in making the clinical diagnosis of bacterial vaginosis. The Gram stain in a patient with bacterial vaginosis has the following characteristics: (1) an absence of inflammatory cells; (2) a decreased number of gram-positive lactobacilli morphotypes; (3) an excess number of pleomorphic gram-negative bacilli, curved rods, and coccobacilli; and (4) clue cells [I1g].^{9,10} Clue cells are squamous epithelial cells the borders of which are obscured by bacteria, classically by gram-negative coccobacilli, the morphotype characteristic of *Gardnerella vaginalis* [T1].

Presumptive Identification

Given a specific site and the presence of a characteristic organism, an educated guess can be made about its identity. Presumptive identification is not necessary or even expected in a report of a Gram stain. However, as part of self-imposed quality assurance, it is wise to consider presumptive identification when interpreting a Gram stain. While examining a smear from a specific site, the laboratorian should ask: "Is what I am seeing expected? Are these gram-negative coccobacilli suggestive of *H influenzae* [T1] [I1f] expected from a wound?" According to [T1] and [T2], this is an unexpected finding. In that case, reexamining the smear to verify the presence of gram-negative coccobacilli or consultation with another technologist would improve confidence in the report and its quality, even if gram-negative coccobacilli are indeed present in the



[I1f] *Haemophilus* species: gram-negative coccobacilli. Some forms appear coccoid (short arrows), others more rod-like (long arrows).

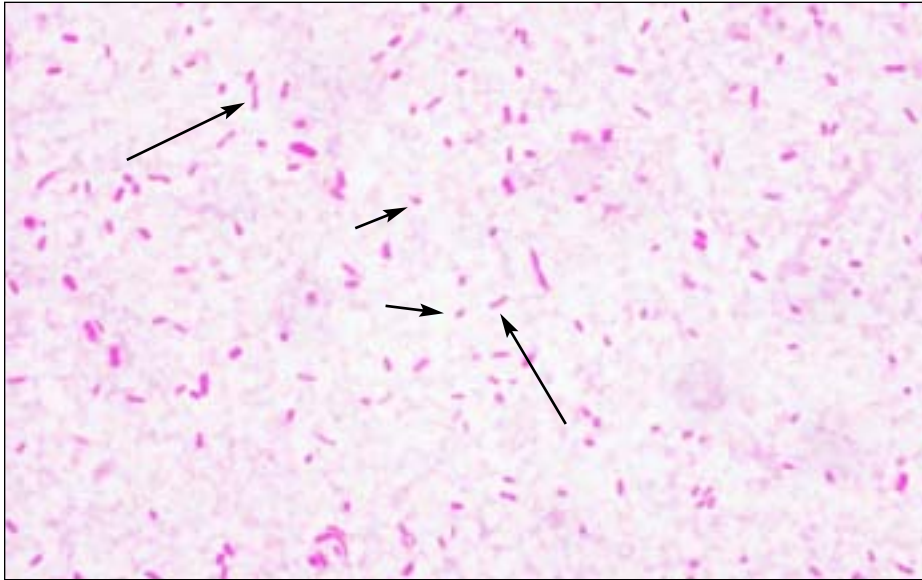


[I1g] Clue cell: Squamous epithelial cell with borders (arrows) obscured by gram-negative coccobacilli, most likely *Gardnerella* species (x40). Note the predominance of gram-negative bacteria and the absence of both inflammatory cells and the morphotypes of normal flora, eg, gram-positive bacilli.

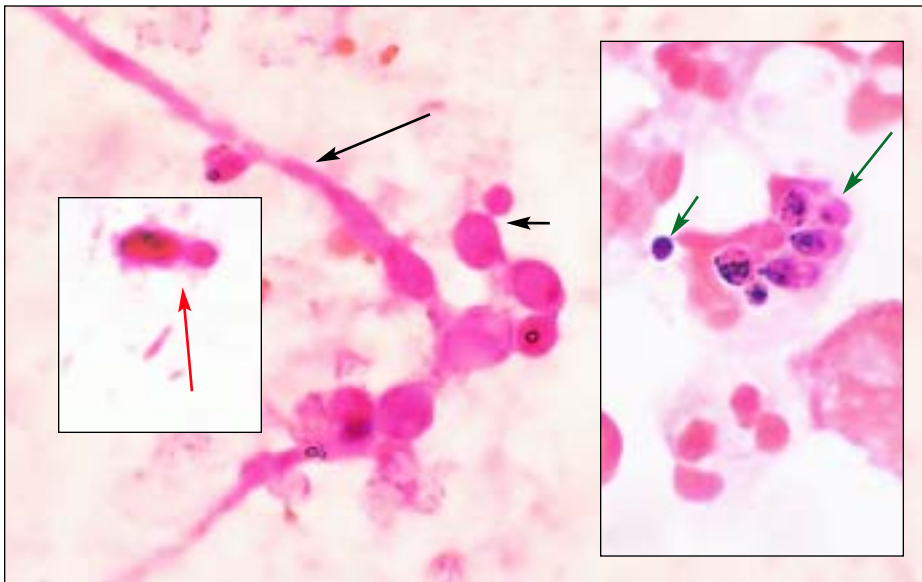
wound. (In fact, wounds can be caused by other less common bacteria not covered in this article).

As another example, a sputum specimen with many lancet-shaped gram-positive diplococci with a surrounding capsule will most likely grow *S pneumoniae* [T1] [I1c]. Finding many neutrophils associated with these bacteria makes the likelihood even

higher. Similarly, the presence of gram-negative diplococci in a CSF specimen suggests *Neisseria meningitidis*, not *N gonorrhoeae* or *M catarrhalis*, all of which may look identical to each other on Gram stain [T1] [I1e]. *Neisseria gonorrhoeae* would be expected in genital secretions (or even a joint fluid), and *M catarrhalis* would be expected in respiratory secretions [T1] [T2].



[I1h] *Enterobacteriaceae* species and pseudomonads: gram-negative rods. *Enterobacteriaceae* organisms are often larger rods (long arrows); smaller rods (short arrows) are suggestive of pseudomonads.



[I1i] Yeasts: gram-positive and gram-negative (or gram-variable) large budding yeasts (short black arrow) and pseudohyphal forms (long black arrow), which are mostly decolorized. Left inset, Note the size of the budding yeast (red arrow) compared with the gram-negative bacteria below. Right inset, A gram-positive extracellular yeast (long green arrow) and intracellular yeasts (short green arrow).

differentiation. Similarly, although *Enterobacteriaceae* organisms are often larger than pseudomonads, this is not a characteristic sufficiently reliable for differentiation [I1h].

Although not seen commonly, *Clostridium* organisms in Gram stains are included here because of their clinical importance. If gram-positive (or gram-variable) bacilli contain spores, *Clostridium* or *Bacillus* species are likely [T1] [I1d]. Although *Clostridium* organisms are classically gram-positive bacilli that may or may not contain spores, in our experience they often stain gram-negative in clinical specimens. Because some *Clostridium* organisms have enzymes that lyse the host's cells, they are often seen in smears without neutrophils.

Although the Gram stain is used for detection and differentiation of bacteria, other microorganisms, most frequently yeasts and fungi, can be seen on a Gram-stained smear. Like *Clostridium* organisms, yeasts can appear gram-positive or gram-negative [I1i]. Yeasts are generally at least 10 to 20 times the size of bacteria [I1i], so differentiation from bacteria is not a problem. However, yeasts are the size of crystal violet precipitate, which is occasionally present. This large purple structure can even appear to be budding. Crystal violet precipitate can be differentiated from yeasts because (1) the precipitate may be present in an area with several other purple artifacts of various size and shape, (2) the precipitate has a homogenous deep-purple color while the yeast is often mottled, and (3) the precipitate may be perfectly round while *Candida* species, the yeast most commonly encountered, are generally oval.

Correlation of Findings

[T1] contains information on which species the common morphotypes most likely represent, and [T2] contains information on which site is expected for a given morphotype. Correlating information from both of these tables will help the laboratorian better interpret the Gram-stained smear. For instance, if gram-negative diplococci are seen in a

If the gram-positive cocci are arranged in clusters or in tetrads, staphylococci are most likely present [T1] [I1a]. If long chains (>5 cocci) of gram-positive cocci are present, streptococci are most likely [T1] [I1b]. Further, if there are pairs of cocci that are pointed at the outside ends, *S pneumoniae*

is likely [T1] [I1c]. Frequently, gram-positive cocci occur only in singles, pairs, and short chains, preventing reliable differentiation between staphylococci and streptococci (or enterococci). Although staphylococci are often larger than streptococci, this is not a characteristic reliable enough for

joint fluid specimen, the expected species represented by this finding is *N gonorrhoeae*. However, if this specimen were from a 70-year-old woman (who would be unlikely to have a sexually transmitted disease), one may want to reconsider. Are the bacteria really gram-negative diplococci, or are they decolorized gram-positive cocci? A more extensive examination of the slide may reveal gram-positive cocci in clusters or tetrads, indicating the presence of *Staphylococcus aureus*, a more likely joint pathogen in an elderly patient. Other sources of help in interpreting, and competency testing for, Gram-stained specimens include both compact disks and color atlases.^{11,12}

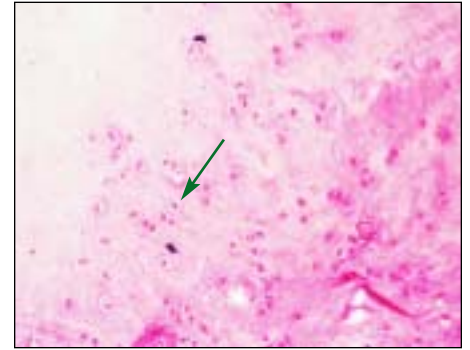
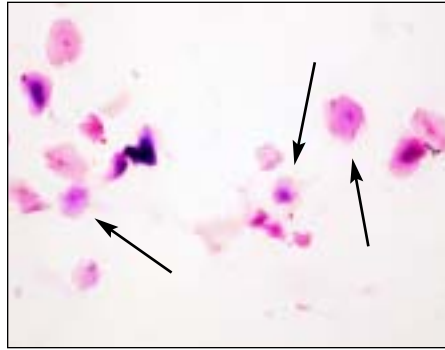
Summary

If the laboratorian's interpretation is not consistent with the guidelines presented in [T1] [T2], the interpretation should be reconsidered or consultation should be sought. Possibly over- or underdecolorization has occurred. Although these guidelines give objective criteria for interpreting the most commonly encountered Gram stains, there will be exceptions. The quality of the reports and confidence in the reports will improve if consultation with another technologist occurs before reporting such findings.

Acknowledgment

This article was part of a project supported by the Memorial Medical Foundation, Springfield, IL.

1. Wilson ML. Clinically relevant, cost effective clinical microbiology. *Am J Clin Pathol*. 1997;107:154-167.



[11] Left, A sputum specimen that should be rejected. Note the numerous squamous epithelial cells (black arrows) and the absence of neutrophils. Right, Acceptable sputum specimen. Note the numerous neutrophils (green arrow) and the absence of squamous epithelial cells ($\times 10$).

- Infections in the lower respiratory tract. In: Forbes BD, Sahn D, Weissfeld A. *Bailey and Scott's Diagnostic Microbiology*. 10th ed. St Louis, MO: Mosby; 1998:318.
- Reisner BS, Woods GL, Thomson RB, et al. Specimen processing. In: Murray PR, ed. *Manual of Clinical Microbiology*. 7th ed. Washington DC: ASM Press; 1999:72.
- Introduction to microbiology, part I: the role of the microbiology laboratory in the diagnosis of infectious diseases: guidelines to practice and management. In: Koneman EW, Allen SD, Janda WM, et al, eds. *Diagnostic Microbiology*. 5th ed. New York, NY: Lippincott; 1997:83.
- Neisseria* species and *Moraxella catarrhalis*. In: Koneman EW, Allen SD, Janda WM, et al, eds. *Diagnostic Microbiology*. 5th ed. New York, NY: Lippincott; 1997:519.
- Neisseria* and *Moraxella catarrhalis*. In: Forbes BD, Sahn D, Weissfeld A. *Bailey and Scott's Diagnostic Microbiology*. 10th ed. St Louis, MO: Mosby; 1998:599.
- Knapp JS, Totten PA, Mulks MH, et al. Characterization of *Neisseria cinerea*, a nonpathogenic species isolated on Morton-Lewis medium selected for pathogenic *Neisseria* spp. *J Clin Microbiol*. 1984;19:63-67.
- Dossett JH, Appelbaum PC, Knapp JS, et al. Proctitis associated with *Neisseria cinerea* misidentified as *Neisseria gonorrhoeae* in a child. *J Clin Microbiol*. 1985;21:575-577.
- Nugent RP, Krohn MA, Hillier SL. Reliability of diagnosing bacterial vaginosis is improved by a standardized method of Gram stain interpretation. *J Clin Microbiol*. 1991;29:297-301.
- Spiegel CA, Amsel R, Eschenbach DA, et al. Diagnosis of bacterial vaginosis by direct Gram stain of vaginal fluid. *J Clin Microbiol*. 1983;18:170-177.
- Marler LM, Siders JA, Allen SD. *Direct Smear Atlas*. New York, NY: Lippincott Williams and Wilkins; 1998.
- Cookson BT, Orkand AM, Curtis J, et al. *Gram-Stain Tutor* [CD-ROM, version 2.0]. Seattle, WA: University of Washington; 1999.

Suggested Reading

McClelland R. Gram's stain: the key to microbiology. *Med Lab Observer*. 2001;33:20-28.

InterNetConnect

Loyola University Medical Center's Gram stain page:
<www.lumen.luc.edu/lumen/DeptWebs/microbio/med/gram/gram-stn.htm>

First and Only FDA Cleared Digital Cytology System

Genius™ Cervical AI

Genius™ Review Station

Genius™ Digital Imager



Empower Your Genius With Ours

Make a Greater Impact on Cervical Cancer
with the Advanced Technology of the
Genius™ Digital Diagnostics System



Click or Scan
to discover more

ADS-04159-001 Rev 001 © 2024 Hologic, Inc. All rights reserved. Hologic, Genius, and associated logos are trademarks and/or registered trademarks of Hologic, Inc. and/or its subsidiaries in the United States and/or other countries. This information is intended for medical professionals in the U.S. and other markets and is not intended as a product solicitation or promotion where such activities are prohibited. Because Hologic materials are distributed through websites, podcasts and tradeshows, it is not always possible to control where such materials appear. For specific information on what products are available for sale in a particular country, please contact your Hologic representative or write to diagnostic.solutions@hologic.com.

genius™
DIGITAL DIAGNOSTICS