

# Olfactory Testing Informs the Decision Process to Obtain Advanced Neuroimaging in Traumatic Brain Injury

LTC Robert Shih, MC, USA\*†; Col Michael Xydakis, USAF, MC\*†

**ABSTRACT** The purpose of this article is to examine the usefulness of olfactory testing as a tool for the evaluation or stratification of traumatic brain injury (TBI) patients. Olfactory dysfunction is more likely to be overlooked by both the patient and the provider, especially in the acute setting, in contrast to deficits in other senses like vision or hearing. This is a retrospective clinical analysis (case series) of eight active duty service members referred to ear, nose, and throat clinic at Walter Reed National Military Medical Center during a 2-yr period between March 2014 and March 2016 for subspecialist evaluation of suspected olfactory impairment after an exposure to closed head trauma. Advanced neuroimaging revealed evidence of frontal lobe injury in all eight patients, which was subtle and subcentimeter in half of the cases, best demonstrated with high-resolution imaging in the coronal plane. In this article, we discuss the correlation between olfactory dysfunction and brain pathology in both TBI and non-TBI settings. We then provide our recommendation for an orbit magnetic resonance imaging (MRI) to evaluate the inferior frontal lobes and olfactory bulbs in patients with unexplained anosmia.

## INTRODUCTION

Traumatic brain injury (TBI) is a broad and heterogeneous category of neurologic disease, which is defined by a temporary or permanent brain dysfunction as the result of an external force. It can present with a wide array of physical, cognitive, behavioral symptoms and can have a wide range of outcomes from complete recovery to severe disability. Clinical management of TBI patients is dependent on having accurate noninvasive tools that can stratify them into different prognostic or treatment categories. For example, head computed tomography (CT) is a fast and widely available tool, which is effective in the acute setting for detecting neurosurgical emergencies, such as hemorrhage, herniation, and hydrocephalus, as well as bony fractures or metallic shrapnel. In a review of the effectiveness of seven neuroimaging modalities for the detection of TBI, the two most useful tools were brain magnetic resonance imaging (MRI) and transcranial Doppler, within specific clinical settings.<sup>1</sup>

The purpose of this article is to examine the usefulness of olfactory testing as a tool for the evaluation or stratification of TBI patients. Olfactory dysfunction is more likely to be overlooked by both the patient and the provider, especially in the acute setting, in contrast to deficits in other senses like vision or

hearing. Nevertheless, it is not an uncommon phenomenon, with estimates of complete loss of smell function (anosmia) in 5–10% and partial loss of smell function (hyposmia) in 30–40% of TBI patients, with the possibility of distorted smells (dysosmia) or phantom smells (phantosmia) in the subacute period.<sup>2</sup> Although nasal airway obstruction or shearing of the olfactory nerves at the cribriform plate can theoretically cause a conductive or sensorineural post-traumatic anosmia, most TBI patients show no evidence of sinonasal or anterior skull base fractures on CT; therefore, a more likely mechanism is central injury to the olfactory bulbs, tracts, or cortex of the brain, which can be confirmed with advanced neuroimaging.<sup>3</sup>

## METHODS

This is a retrospective clinical analysis of eight active duty service members referred to ear, nose, and throat (ENT) clinic at Walter Reed National Military Medical Center (WRNMMC) during a 2-yr period between March 2014 and March 2016 for evaluation of suspected olfactory impairment after a history of closed head trauma. The service members were evaluated by an otolaryngologist who subspecializes in smell and taste disorders. In addition to a standard history and physical examination, including nasal cavity examination, olfactory testing was performed using a commercially available set of felt-tip pens containing liquid odorants: Sniffin' Sticks (Burghart Messtechnik, Wedel, Germany). Available neuroimaging was reviewed by the otolaryngologist in conjunction with a neuroradiologist.

## RESULTS

Case 1 is a 45-yr-old active duty sailor who was referred for evaluation of suspected hyposmia 11 mo after a severe closed head injury (motorcycle accident), including facial fractures and subdural hematomas. His sense of taste and smell were previously normal and now significantly impaired with loss of

\*Department of Radiology, Walter Reed National Military Medical Center, 8901 Wisconsin Avenue, Bethesda, MD 20889.

†Air Force Research Lab, Wright-Patterson Air Force Base, OH 45433.

The identification of specific products or scientific instrumentation does not constitute endorsement or implied endorsement on the part of the authors, DoD, or any component agency. The views expressed in this presentation are those of the authors and do not reflect the official policy of the Department of the Army/Navy/Air Force, Department of Defense, or U.S. Government.

doi: 10.1093/milmed/usx178

Published by Oxford University Press on behalf of Association of Military Surgeons of the United States 2018. This work is written by (a) US Government employee(s) and is in the public domain in the US.

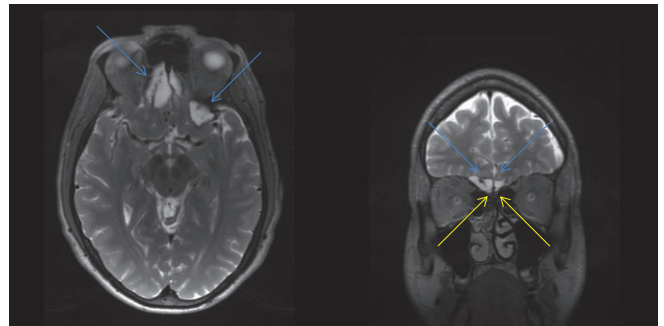
appetite, for example, “things taste generic to me... a filet mignon tastes the same as a corn dog.” He also reported new phantosmia, that is, phantom smells or olfactory hallucinations. Formal testing revealed normal taste with severe hyposmia: 4/4 taste strips, 6/12 Sniffin’ Sticks, 22/40 University of Pennsylvania Smell Identification Test (UPSIT), and unable to smell natural gas or smoke odors. His brain/orbit MRI revealed subcentimeter encephalomalacia/gliosis at the inferior surface of the left frontal lobe, consistent with mild sequela from previous contusion (Fig. 1).

Case 2 is a 31-yr-old active duty sailor who was referred for evaluation of suspected anosmia, after a severe mountain biking accident 6 yr earlier, during which he was traveling 20 miles/h and was thrown over the handlebars. He presented to an outside hospital with headache, transient confusion, and blood in his left external auditory canal. There is outside documentation of left subdural hematoma, bilateral frontal lobe contusions, and left temporal bone fracture. His taste and appetite are normal; his sense of smell was previously normal. Formal testing revealed anosmia by quantitative olfactometry: 4/4 taste strips, 2/12 Sniffin’ Sticks, and 11/40 UPSIT, but he was able to identify some odors at suprathreshold concentration (e.g., licorice, coffee, and bubble gum). His brain MRI revealed encephalomalacia or gliosis at the inferior surface of both frontal lobes, chronic sequela of known contusions (Fig. 2).

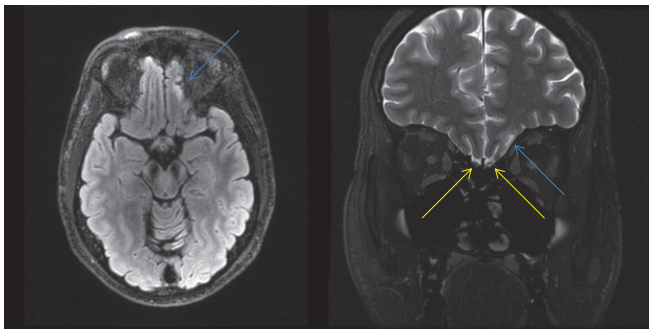
Case 3 is a 32-yr-old active duty sailor referred for evaluation of suspected hyposmia. He had been exposed to multiple mild traumatic brain injuries related to “fighting, automobile accident, striking the butt of a rifle to his forehead, explosions, etc.,” with altered sensorium immediately following several of these episodes. He has no loss of appetite or weight loss but does describe infrequent phantosmia and some memory or word-finding difficulties. Formal testing revealed more of a central olfactory processing disorder,

with preserved ability to detect or discriminate odors, but impaired ability to identify or name odors: 4/4 taste strips and 8/12 Sniffin’ Sticks with somewhat indecisive responses. His brain MRI revealed subcentimeter encephalomalacia (i.e., chronic gliosis) at the inferior surface of the left frontal lobe, consistent with mild sequela from a previously undiagnosed contusion (Fig. 3).

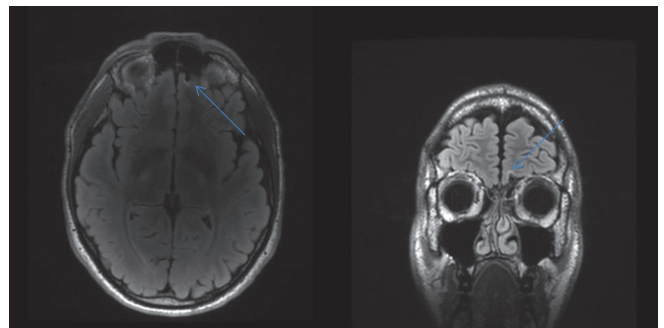
Case 4 is a 39-yr-old active duty sailor who was referred for evaluation of suspected anosmia after a 1-yr deployment in Afghanistan, now unable to smell isopropyl alcohol or povidone-iodine during his post-deployment health reassessment. Formal testing in ENT clinic confirmed anosmia: 4/4 taste strips, 1/16 Sniffin’ Sticks (identified garlic), and 0/16 on both discrimination and threshold. Because the patient could not remember any specific episodes of head trauma, but did describe a few severe upper respiratory infections while in theater, the initial clinical impression was post-viral anosmia. An orbit MRI was ordered to evaluate his nasal



**FIGURE 2.** A 31-yr-old active duty sailor with anosmia after a mountain biking accident. Axial and coronal reformat images from high-resolution three dimensions weighted (3D T2) brain magnetic resonance imaging (MRI) reveal encephalomalacia/gliosis at the inferior surface of both frontal lobes (blue), consistent with chronic sequela from previous contusions. This size of contusion would be easier to detect on head computed tomography and certainly brain MRI, especially around time of peak edema. Olfactory bulbs are normal (yellow).



**FIGURE 1.** A 45-yr-old active duty sailor with severe hyposmia affecting taste and appetite after a motorcycle accident. Axial weighted fluid-attenuated inversion recovery (T2/FLAIR) image from his brain magnetic resonance imaging (MRI) (left) and coronal T2 FLAIR scans image from his orbit MRI (right) reveal subcentimeter encephalomalacia/gliosis at the inferior surface of the left frontal lobe (blue), consistent with mild sequela from previous contusion. This size of contusion would be occult on a head computed tomography (CT) and could be missed on a brain MRI, without dedicated attention to the inferior frontal lobes. Olfactory bulbs are normal (yellow).



**FIGURE 3.** A 32-yr-old active duty sailor with history of multiple mild traumatic brain injuries and hyposmia with impaired ability to identify or name odors. Axial and coronal reformat images from high-resolution three-dimensional weighted fluid-attenuated inversion recovery brain magnetic resonance imaging reveal subcentimeter encephalomalacia/gliosis at the inferior surface of the left frontal lobe (blue), consistent with mild sequela from a previously undiagnosed contusion. Olfactory bulbs are normal posteriorly (not shown).

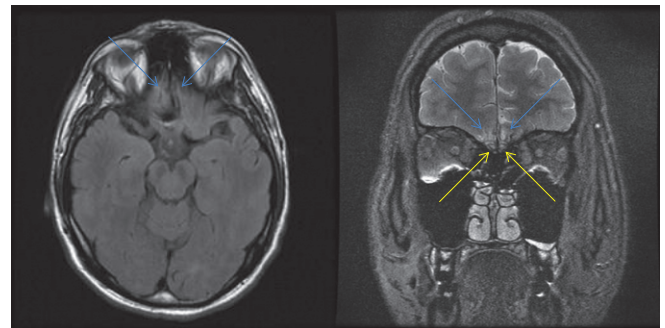
cavity and anterior skull base, which revealed subcentimeter gliosis at the inferior surface of both frontal lobes and at the right olfactory bulb, consistent with mild sequelae from previous traumatic contusions, despite a lack of a known episode of head trauma (Fig. 4).

Case 5 is a 28-yr-old active duty marine who was referred for evaluation of persistent anosmia with ageusia (loss of taste), following a closed head injury 3 mo earlier. He was performing maintenance on US Marine Corp Variant of the Osprey aircraft when he fell 12–15 ft off a ladder and struck his head on the tarmac. He had confused memories of the event and may have experienced a few seconds loss of consciousness. He was transported to a local emergency room where head CT revealed a nondisplaced occipital fracture. A few days later, a repeat head CT after an episode of vomiting revealed a left inferior frontal lobe contusion, which was now visible because of increased edema and swelling. Given the small size, it was observed without neurosurgical intervention. A few months later, he had persistent loss of smell and taste with recurrent phantosmia, described as a foul smell x 4–5 h. Formal testing confirmed anosmia: 4/4 taste strips (normal taste), 8/16 Sniffin' Sticks (but with tenuous and uncertain responses), and 1–2/16 on threshold testing. His brain/orbit MRI revealed subcentimeter encephalomalacia/gliosis at the inferior surface of both frontal lobes (gyrus rectus) and at the bilateral olfactory bulbs, representing chronic sequelae of traumatic contusions from a known closed head injury 3 mo earlier (Fig. 5).

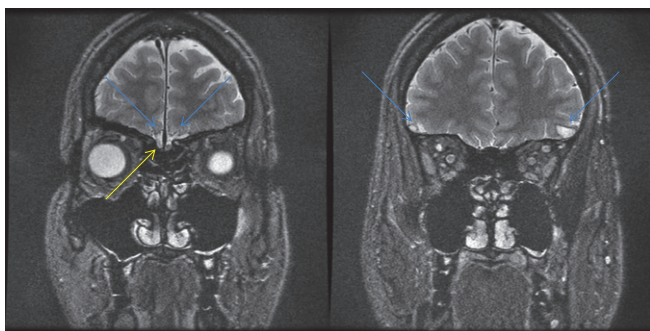
Case 6 is a 31-yr-old active duty marine who was referred for evaluation of persistent anosmia after severe trauma 5 yr earlier when a tow truck shackle struck him in the head. According to the outside records, he sustained a left posterior skull fracture, subdural hematoma, subarachnoid hemorrhage, and frontotemporal hemorrhagic contusions, then underwent left-sided craniotomy. Five years later, he complains of daily migraine headaches and no sense of smell since the injury. His

neuropsychological evaluation revealed impairment of information-processing speed, verbal learning, and memory/executive function. Olfactory/gustatory testing revealed normal taste with anosmia: 4/4 taste strips, 1–2/16 Sniffin' Sticks, and 0/16 on threshold testing. His brain/orbit MRI revealed obvious encephalomalacia/gliosis at the inferior and lateral surface of bilateral frontal and temporal lobes, representing chronic sequela of traumatic contusions from a known closed head injury, with damaged olfactory bulbs (Fig. 6).

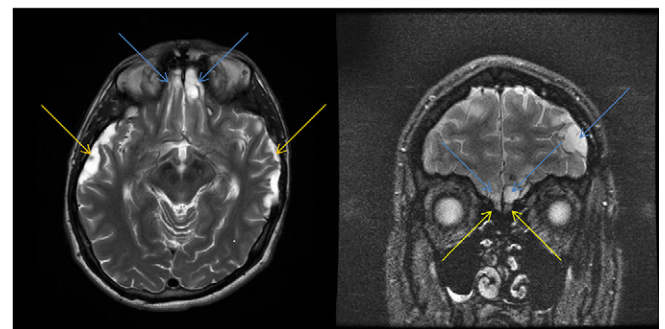
Case 7 is a 23-yr-old active duty sailor referred by another otolaryngologist for evaluation of suspected olfactory impairment after trauma 7 mo earlier. The patient first noticed a loss of smell and taste about 1 mo after his all-terrain vehicle accident (he was traveling downhill at 50 km/h when the brakes failed and he collided with a wall). Other symptoms



**FIGURE 5.** A 28-yr-old active duty marine with persistent anosmia, after falling 12–15 ft from a ladder, while performing maintenance on multi-mission vertical aircraft –22 Osprey aircraft. It is very difficult to visualize the subcentimeter encephalomalacia or gliosis at the inferior surface of both frontal lobes (gyrus rectus) on axial weighted fluid-attenuated inversion recovery (T2 FLAIR) images from a standard brain MRI (left). It is much easier to see this finding on higher resolution coronally oriented T2 FLAIR scan images from a standard orbit MRI (blue), which also reveals central hyperintense gliosis with peripheral hypointense hemosiderin staining at the chronically damaged olfactory bulbs on both sides (yellow).



**FIGURE 4.** A 39-yr-old active duty sailor with diagnosis of anosmia after a 1-yr deployment in Afghanistan. Orbit magnetic resonance imaging was ordered to evaluate the soft tissues in the region of the nasal cavity and anterior skull base. Coronal weighted fluid-attenuated inversion recovery scan images at the ocular globes (left) and optic nerves (right) reveal subcentimeter encephalomalacia/gliosis at the inferior surface of left > right frontal lobes (blue) and at the right olfactory bulb (yellow). These findings are consistent with mild sequelae from previous contusions, despite a lack of a known episode of head trauma.



**FIGURE 6.** A 31-yr-old active duty marine with chronic headaches and anosmia following a severe traumatic brain injury 5 yr earlier (tow truck shackle to the head). Axial weighted (T2) image from his brain magnetic resonance imaging (MRI) (left) reveals obvious encephalomalacia or gliosis at the lateral surface of the temporal lobes (orange) and the inferior surface of the frontal lobes (blue). Coronal T2 fluid-attenuated inversion recovery scan image from his orbit MRI (right) confirms post-traumatic encephalomalacia at the surface of left > right frontal lobes (blue) and reveals chronic injury to the bilateral olfactory bulbs, which demonstrate poorly defined margins and heterogeneous signal on both sides (yellow).



include daily phantosmia, described as a chemical smell lasting a few seconds, plus loss of appetite and weight, which has subsequently recovered. Formal testing revealed normal taste and hyposmia: 4/4 taste strips, 11–12/16 Sniffin' Sticks, and 0/16 on threshold testing. Although the patient was not able to undergo MRI, he received a positron emission tomography (PET)/CT as part of a traumatic brain injury research protocol, which revealed focal hypometabolism/hypoattenuation at the inferior surface of the right frontal lobe, consistent with chronic sequela from previous contusion (Fig. 7).

Case 8 is a 22-yr-old active duty marine referred for olfactory evaluation 2 mo after a fall of approximately 6 ft from his top bunk bed in the barracks, which resulted in skull fractures, brain contusions, and subdural hematoma. He was observed without neurosurgical intervention. Two months later, he has persistent symptoms of headaches, insomnia, and personality changes ("I get mad and frustrated easily"). He was not aware of any olfactory impairment, until he was evaluated and referred by neurology a few weeks ago. Formal testing revealed normal taste and complete anosmia: 4/4 taste strips, 0/16 Sniffin' Sticks, and 0/16 on threshold testing. An orbit MRI revealed obvious encephalomalacia/gliosis at the inferior surface of the right > left frontal lobes, which also affected the right > left olfactory bulbs, consistent with chronic sequela from known traumatic history and brain contusions (Fig. 8).

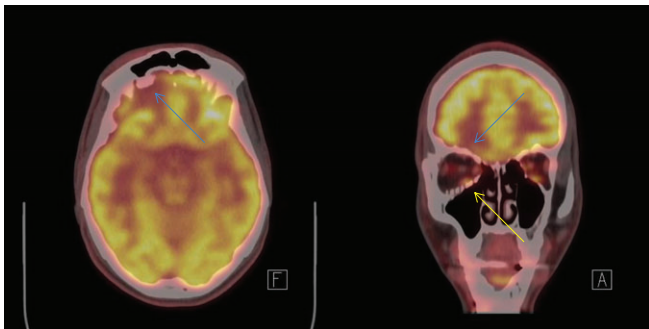
## DISCUSSION

This is a retrospective clinical analysis of eight active duty service members referred to ENT clinic at WRNMMC during a 2-yr period for evaluation of suspected olfactory impairment after a history of closed head trauma. All eight patients demonstrated hyposmia or anosmia on Sniffin' Sticks olfactory function testing. All eight patients also showed evidence of frontal lobe injury on advanced neuroimaging. In four patients, there was obvious post-traumatic encephalomalacia from previous contusions

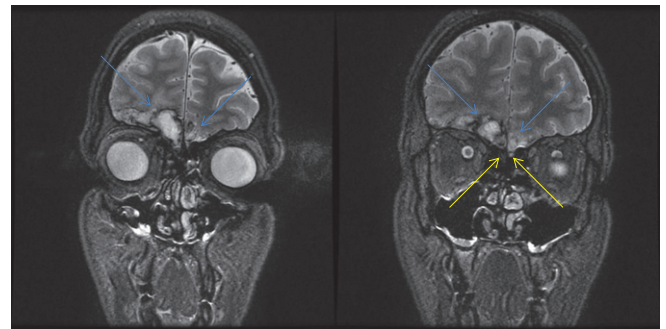
at the inferior surface of the frontal lobes (Figs 2, 6–8), also involving the anterolateral surface of the temporal lobes (not shown). In four patients, there was more subtle and subcentimeter gliosis at the inferior surface of the frontal lobes, not likely to be detectable by CT, not involving the temporal lobes, best depicted on high-resolution coronal T2 images from brain or orbit MRI (Figs 1, 3–5). In four patients, there was evidence of additional injury to the olfactory bulbs (Figs 4–6, 8).

This correlation between post-traumatic anosmia and abnormal neuroimaging has been described in other articles. A case series of 25 patients with post-traumatic olfactory dysfunction referred to the Smell and Taste Center at the University of Pennsylvania found MRI lesions of the olfactory bulbs/tracts in 88%, the inferior frontal lobes in 60%, and the anterior temporal lobes in 32%.<sup>4</sup> A study of 62 patients admitted to the Traumatic Brain Injury Program at McGill University Health Centre, Montreal General Hospital, during a 6-mo period found an association between lesions in the inferior frontal lobes (orbitofrontal cortex) and lower odor identification scores ( $p < 0.001$ ) plus an association between lower odor identification scores and worse performance on cognitive or executive function tests ( $p < 0.01$ ).<sup>5</sup> Another study of 231 blast-injured US combat troops who were evacuated from operations in Afghanistan or Iraq detected olfactory impairment in none of the patients with normal neuroimaging and in 35% of those with abnormal neuroimaging, which most commonly showed injury to the frontal > temporal lobes.<sup>6</sup>

This connection between olfactory dysfunction and fronto-temporal lobe pathology has also been described in other neurodegenerative diseases. For example, formal olfactory testing using a 40-item (UPSIT) was a better biomarker than verbal episodic memory at predicting cognitive decline to Alzheimer dementia in 757 cognitively intact subjects followed over 4 yr.<sup>7</sup> Odor identification testing has also been shown to predict the



**FIGURE 7.** A 23-yr-old active duty sailor with chronic hyposmia following a severe all-terrain vehicle accident 7 mo earlier. Axial (left) and coronal (right) fused images from a brain positron emission tomography/computed tomography (CT) reveal focal hypometabolism at the inferior surface of the right frontal lobe (blue), consistent with gliosis or encephalomalacia, as chronic sequela from previous traumatic contusion. There was also subtle hypoattenuation on the unfused head CT images (patient not able to undergo MRI). The patient sustained multiple right-sided facial fractures during his collision and had a surgical repair with metallic mesh at his right orbital floor blowout fracture (yellow).

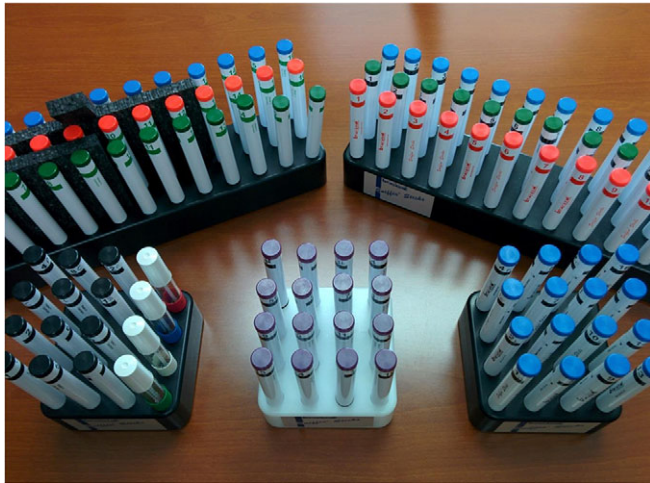

**FIGURE 8.** A 22-yr-old active duty marine with complete anosmia after falling from a bunk bed 2 mo earlier. He did not know he had lost his sense of smell, until diagnosed by a neurologist, and has concerns about his career goal of becoming a fireman (he could not detect natural gas or smoke odors on formal testing). Coronal weighted fluid-attenuated inversion recovery scan images from an orbit magnetic resonance imaging at the level of the ocular globes (left) and optic nerves (right) reveal post-traumatic encephalomalacia at the inferior surface of the right > left frontal lobes (blue), chronic sequela from previous contusions. There is also chronic damage of the right > left olfactory bulbs (yellow).

development of Parkinson disease or dementia with Lewy bodies in subjects with idiopathic REM sleep behavior disorder.<sup>8</sup> There is evidence of olfactory dysfunction in multiple sclerosis, which differs in character between the acute neuroinflammatory and chronic neurodegenerative stages, chronic stroke patients, chronic alcoholism, sleep deprivation, and aging (anosmia was a higher predictor of 5-yr mortality than cancer, heart disease, or emphysema).<sup>9–15</sup> Our sense of smell is a window to the health of our frontotemporal lobes.

Olfactory function testing should be considered in all patients with suspected neurologic disease, including TBI. In a 2014 systematic review of the current literature on traumatic brain injury and olfaction, the authors come to the following conclusion: “The results of this review confirm that post-TBI olfactory dysfunction is common. If persistent, it represents the loss of an important sensory function with potential functional consequences as eloquently outlined in the qualitative study cited immediately above [for example: effects on taste/appetite, personal safety/hygiene, interpersonal relationships]. Remarkably, many individuals who suffer this complication appear to be unaware of it. Finally, its presence seems to signal an increased likelihood of adverse cognitive and other neuropsychiatric and functional outcomes. The implications of these findings are worth considering at the extremes of TBI severity.”<sup>16</sup>

The most commonly used olfactory tests are the 40-item “scratch and sniff” UPSIT, which tests odor identification and requires approximately 25 min, versus the pen-based Sniffin’ Sticks (Fig. 9), which tests odor threshold and discrimination



**FIGURE 9.** Sniffin’ Sticks (Burghart Messtechnik, Wedel, Germany). The black, purple, and blue pens at the bottom are used to test olfactory identification, where either 12 (black) or 16 (purple or blue) familiar odorants are presented, along with four multiple choice answers for each pen. The white tubes contain taste strips (sweet, sour, salty, and bitter). The 48 pens in the upper left are used to test olfactory discrimination, where for each of 16 triplets, the task is to identify which pen is different from the other two. The 48 pens in the upper right are used to test olfactory thresholds, where for each of 16 triplets, the task is to identify the pen containing varying concentrations of normal butanol alcohol (*n*-butanol) (the other two contain solvent only, without *n*-butanol).

as well as identification, requiring approximately 25–45 min for the complete examination.<sup>17, 18</sup> UPSIT (Sensonics International, Haddon Heights, NJ, USA) was developed by Richard Doty, director of the University of Pennsylvania Smell and Taste Center. It comprises four booklets with 10 odors each and costs approximately \$20–30 per use; there is an abbreviated 12-item version called B-SIT (Brief Smell Identification Test). A complete set of Sniffin’ Sticks (“Extended Test”) costs approximately \$1,000, whereas an abbreviated subset for odor identification only (“Screening 12”) costs approximately \$200; these are reusable with a shelf life of 12 mo. Imaging equipment is considerably less portable and more expensive; a new CT scanner costs approximately \$500 K to \$1 M, whereas a new MRI scanner costs approximately \$1.5 M to \$3 M. For this reason, relatively accessible inexpensive olfactory testing kits may be useful in the field and at forward-deployed aid stations.

A diagnosis of post-traumatic anosmia should be accompanied by patient counseling on methods to reduce risk from fire/smoke, food spoilage, and gas leaks. It also informs the decision process to obtain advanced neuroimaging for detecting frontal lobe injury, especially if previous imaging has been unremarkable (e.g., “normal” head CT). A multicenter observational study of mild TBI, which accounts for 75% of all TBI, found that 27% of patients with a normal admission head CT had an abnormal early brain MRI and that abnormal MRI findings were associated with a poorer Extended Glasgow Outcome Scale at the 3-mo follow-up.<sup>19</sup> In addition to obtaining an MRI, a diagnosis of post-traumatic anosmia should focus the radiologist’s attention on the olfactory bulbs and inferior frontal lobes, which are best evaluated with high-resolution coronal images. Because a standard brain MRI may not include this capability and often consists of a sagittal T1 sequence with axial T2 sequences, we recommend including an orbit MRI.

An orbit MRI is a widely available protocol and is the simplest method to ensure high-resolution coronal images of the olfactory bulbs and inferior frontal lobes. It is our recommendation for the workup of unexplained anosmia in both TBI and non-TBI patients. In order to evaluate the optic nerves (approximately 3 mm in diameter) and cavernous sinuses, an orbit MRI will also provide high-resolution coronal images of the nasal cavity, anterior skull base, olfactory bulbs and tracts (approximately 3 mm in size as well),<sup>20</sup> inferior frontal lobes, and anterior temporal lobes. Even when a brain MRI protocol does include coronal sequences, or coronal reformats of 3D sequences, an orbit MRI protocol still usually provides better spatial resolution because of a smaller more-focused field-of-view (e.g., 18 cm versus 24 cm).

Finally, it should be noted that this is a case series without controls, based on referrals to a subspecialist at a tertiary care center, with associated inherent weaknesses. For example, this study can establish neither the frequency of neuroimaging findings in patients with abnormal olfactory function (positive predictive value), nor absence of similar findings in patients

with normal olfactory function (negative predictive value). It is intended to share findings that may interest military providers who encounter patients with TBI and/or anosmia.

## CONCLUSIONS

Olfactory testing is a useful but underutilized tool for evaluation of closed head trauma patients, as well as many other neurologic conditions. This should be of particular interest to the military population, whose demographics and duties confer a higher risk of concussion and TBI relative to the civilian population. Severe olfactory impairment in TBI patients is highly correlated with imaging findings of traumatic contusion, particularly to the frontal lobes, both in our case series and in the reported literature. Because these contusions may be subtle or subcentimeter (occult on head CT), the clinical detection of unexplained anosmia or severe hyposmia is an indication for advanced neuroimaging, which should include high-resolution imaging in the coronal plane (e.g., orbit MRI). Early detection of brain injury is crucial because therapeutic and rehabilitative intervention can be helpful in maximizing positive outcomes.

## PRESENTATIONS

Presented as a poster at the 2016 Military Health System Research Symposium, Kissimmee, FL (abstract number: MHSRS-16-0013).

## REFERENCES

1. Amyot F, Arciniegas DB, Brazaitis MP, et al: A review of the effectiveness of neuroimaging modalities for the detection of traumatic brain injury. *J Neurotrauma* 2015; 32(22): 1693–721.
2. Wise JB, Moonis G, Mirza N: Magnetic resonance imaging findings in the evaluation of traumatic anosmia. *Ann Otol Rhinol Laryngol* 2006; 115(2): 24–7.
3. Wu AP, Davidson T: Posttraumatic anosmia secondary to central nervous system injury. *Am J Rhinol* 2008; 22(6): 606–7.
4. Yousem DM, Geckle RJ, Bilker WB, McKeown DA, Doty RL: Posttraumatic olfactory dysfunction: MR and clinical evaluation. *AJNR Am J Neuroradiol* 1996; 17(6): 1171–9.
5. de Guise E, Alturki AY, Laguë-Beauvais M, et al: Olfactory and executive dysfunctions following orbito-basal lesions in traumatic brain injury. *Brain Inj* 2015; 29(6): 730–8.
6. Xydakis MS, Mulligan LP, Smith AB, Olsen CH, Lyon DM, Belluscio L: Olfactory impairment and traumatic brain injury in blast-injured combat troops: a cohort study. *Neurology* 2015; 84(15): 1559–67.
7. Devanand DP, Lee S, Manly J, et al: Olfactory deficits predict cognitive decline and Alzheimer dementia in an urban community. *Neurology* 2015; 84(2): 182–9.
8. Mahlknecht P, Iranzo A, Högl B, et al: Olfactory dysfunction predicts early transition to a Lewy body disease in idiopathic RBD. *Neurology* 2015; 84(7): 654–8.
9. Lutterotti A, Vedovello M, Reindl M, et al: Olfactory threshold is impaired in early, active multiple sclerosis. *Mult Scler* 2011; 17(8): 964–9.
10. Rolet A, Magnin E, Millot JL, et al: Olfactory dysfunction in multiple sclerosis: evidence of a decrease in different aspects of olfactory function. *Eur Neurol* 2013; 69(3): 166–70.
11. Wehling E, Naess H, Wollschlaeger D, et al: Olfactory dysfunction in chronic stroke patients. *BMC Neurol* 2015; 15: 199.
12. Rupp CI, Fleischhacker WW, Drexler A, Hausmann A, Hinterhuber H, Kurz M: Executive function and memory in relation to olfactory deficits in alcohol-dependent patients. *Alcohol Clin Exp Res* 2006; 30(8): 1355–62.
13. Killgore WD, McBride SA: Odor identification accuracy declines following 24 h of sleep deprivation. *J Sleep Res* 2006; 15(2): 111–6.
14. Murphy C, Schubert CR, Cruickshanks KJ, Klein BE, Klein R, Nondahl DM: Prevalence of olfactory impairment in older adults. *JAMA* 2002; 288(18): 2307–12.
15. Pinto JM, Wroblewski KE, Kern DW, Schumm LP, McClintock MK: Olfactory dysfunction predicts 5-year mortality in older adults. *PLoS One* 2014; 9(10): e107541.
16. Schofield PW, Moore TM, Gardner A: Traumatic brain injury and olfaction: a systematic review. *Front Neurol* 2014; 5: 5.
17. Callahan CD, Hinkebein JH: Assessment of anosmia after traumatic brain injury: performance characteristics of the University of Pennsylvania Smell Identification Test. *J Head Trauma Rehabil* 2002; 17(3): 251–6.
18. Wolfensberger M, Schnieper I, Welge-Lüssen A: Sniffin' Sticks: a new olfactory test battery. *Acta Otolaryngol* 2000; 120(2): 303–6.
19. Yuh EL, Mukherjee P, Lingsma HF, et al: Magnetic resonance imaging improves 3-month outcome prediction in mild traumatic brain injury. *Ann Neurol* 2013; 73(2): 224–35.
20. Suzuki M, Takashima T, Kadoya M, Takahashi S, Miyayama S, Taira S: MR imaging of olfactory bulbs and tracts. *AJNR Am J Neuroradiol* 1989; 10(5): 955–7.