

Exceptional Cases

An extreme and life-threatening case of recurrent D-lactate encephalopathy

Nay Htye¹, Luke White¹, Gagangeet Sandhu², James Jones² and Ira Meisels³

¹Department of Medicine, St Luke's-Roosevelt Hospital Center, Columbia University College of Physicians and Surgeons, New York, NY, USA, ²Division of Nephrology, Department of Medicine, St Luke's-Roosevelt Hospital Center, Columbia University College of Physicians and Surgeons, New York, NY, USA and ³Division of Nephrology, Department of Medicine, St Luke's-Roosevelt Hospital Center, Columbia University College of Physicians and Surgeons, New York, NY, USA

Correspondence and offprint requests to: Luke White; E-mail: luke@kesil.com

Abstract

D-lactic acidosis has been reported in patients after a variety of gastrointestinal surgeries, particularly jejunoileal bypass. An insufficient length of small intestine to metabolize ingested carbohydrates leads to an abnormal carbohydrate load in the colon. These carbohydrates are metabolized by colonic anaerobes (especially *Lactobacillus* species) into the dextrorotary isomer of lactate. Unlike its levorotary counterpart, D-lactate has neurotoxic effects and patients suffering from a significant D-lactate burden may suffer encephalopathic symptoms. These symptoms are usually mild and self-limiting in patients with normal renal function. We present here a case of D-lactic acidosis in a patient with end-stage renal disease who developed recurrent and life-threatening respiratory failure due to severe D-lactic acid encephalopathy. To our knowledge, no previously reported case has been sufficiently severe to necessitate endotracheal intubation and mechanical ventilation. An array of treatments including hemodialysis effected a prompt reversal of sensorium to baseline. We describe the potential treatments for D-lactic acidosis, which can be viewed as a paradigm of substrate, catalyst and pathologic product and review reports of their relative efficacy.

Keywords: encephalopathy; anaerobes; d-lactate; lactic acidosis

Case presentation and initial laboratory data

A 60-year-old male presented to the emergency department (ED) after being referred by his primary physician for ataxic gait and slurred speech. He had suffered several similar episodes over the course of 5 months. At baseline, he was fully lucid and ambulatory. Notably, 8 months before presentation he had been admitted for an intestinal volvulus that necessitated the removal of 419 cm [165 inches] of diffusely necrotic jejunum and ileum. After discharge, he had resumed a normal diet. He also suffered

from end-stage renal disease and received hemodialysis three times weekly for 3.5 h/session.

The several episodes of ataxia and slurred speech had resolved seemingly spontaneously prior to this latest episode. His symptoms, which he had noticed the night before admission, progressed throughout the night and into the next day.

On presentation, the patient's blood pressure was 140/86 mmHg, heart rate 86 beats/min, respiratory rate 23 breaths/min and pulse oximetry 99% on room air. Lung auscultation was clear. His initial neurologic exam revealed mild slurring of speech and gait imbalance but no other deficits. Initial laboratory data is noted in Table 1. Computed tomography of the head showed microvascular disease but no infarct or bleed.

Six hours after initially being triaged in the ED, the patient's consciousness deteriorated and he was noted to be obtunded, with no response to voice and minimal response to deep painful stimulus. His respirations decreased to 10 breaths/min. An arterial blood gas and chemistry drawn at the time revealed a combined respiratory and metabolic acidosis (Table 1). He was intubated for hypercarbic respiratory failure and admitted to the intensive care unit. In light of his history of jejunoileal resection, acidemia and normal L-lactate levels, a serum D-lactate level (Mayo Labs, Rochester, MN) was ordered (Table 1).

After intubation, the patient remained unresponsive even after normalization of Pco₂ on the ABG; no sedation was administered. He received hemodialysis and during dialysis became more responsive. After his usual 3.5 h of dialysis, he was fully responsive, able to follow commands and to write legibly. Shortly afterward, he was extubated. He was counseled on carbohydrate restriction and discharged on a course of metronidazole for colonic bacterial overgrowth.

Diagnosis

D-Lactic acid associated severe metabolic encephalopathy with associated respiratory failure.

Table 1. Summary of pertinent laboratory results^a

Summary of laboratory results	
WBC	4.8 × 10 ⁹ /L [4.8 K/ μ L]
Hemoglobin	125 g/L [12.5 g/dL]
Hematocrit	0.41 [40.1%]
Platelet	82 × 10 ⁹ /L [82 K/ μ L]
Sodium, serum	152 mmol/L [152 mEq/L]
Potassium, serum	5 mmol/L [5 mEq/L]
Chloride, serum	115 mmol/L [115 mEq/L]
Bicarbonate, serum	16 mmol/L [16 mEq/L]
Anion gap	26
Urea nitrogen, serum	3.21 mmol/L [9 mg/dL]
Creatinine	512.72 μ mol/L [5.8 mg/dL]
Calcium	2.13 mmol/L [8.5 mg/dL]
Protein, total	66 g/L [6.6 g/dL]
Albumin	30 g/L [3 g/dL]
Alkaline phosphatase	1.04 μ kat/L [62 U/L]
Aspartate aminotransferase	0.57 μ kat/L [34 U/L]
Alanine aminotransferase	0.18 μ kat/L [11 U/L]
Acetone	Negative
D-lactate	12.57 mmol/L
Lactic acid	0.9 mmol/L
Serum osmolality	333 mmol/kg [333 mOsm/Kg]
Ammonia	29 μ mol/L
ABG	ABG 7.02 (pH)/59.9 (PCO ₂)/ 96.7 (PaO ₂)/15 (HCO ₃)
Toxicology screen (urine)	
Methadone	Negative
Opiates	Negative
Cocaine	Negative
Barbiturates	Negative
Benzodiazepines	Negative
Toxicology screen (blood)	
Alcohol	
Salicylate	Not Detected
INR	1.4
Prothrombin time	16.9 s

^aConversion factors for SI units (wherever applicable) and laboratory range: serum creatinine (in mg/dL to μ mol/L, $\times 88.4$; laboratory range 0.7–1.4 mg/dL), serum urea nitrogen (in mg/dL to mmol/L, $\times 0.357$; laboratory range 7–18 mg/dL), C3 complement (in mg/dL to g/L, $\times 0.01$; laboratory range 90–180 mg/dL), C4 complement (in mg/dL to g/L, $\times 0.01$; laboratory range 16–47 mg/dL), hemoglobin (in g/dL to g/L, $\times 10$; laboratory range 13.5–17.5 g/dL), protein (total) (in g/dL to g/L, $\times 10$; laboratory range 6.3–8.2 g/dL) and albumin (in g/dL to g/L, $\times 10$; laboratory range 3.5–5.5 g/dL). The normal value for D-lactate is < 5 mmol/L. ANA, antinuclear antibody; RBC, red blood cells; Ab, antibody; INR, International Normalized Ratio.

Clinical follow-up

Despite these measures, he presented to the ED after 15 days with identical symptoms. The patient's family noted that the night prior he had eaten a meal heavy in simple carbohydrates. He was again intubated and improved rapidly after dialysis. In consultation with an infectious disease specialist, amoxicillin/clauvanate was added to his regimen of metronidazole. His family was also educated on the signs of worsening encephalopathy and encouraged to call us directly if they noticed these.

He was admitted a third time for identical symptoms; we were aware of his imminent arrival after being called by his family. Intubation was avoided through immediate intravenous bicarbonate administration, noninvasive positive pressure support ventilation and emergent dialysis, all of which were readied while he was en route to the ED.

Discussion

The dextrorotary isomer of lactate was identified as the causative agent of encephalopathy in short gut syndrome in 1979 by Oh *et al.* [1]. Since then, < 50 cases have been thoroughly described in the published literature. The neurologic symptoms described in D-lactic acidosis consistently include gait disturbances, slurred speech, hallucinations and, rarely, obtundation [1,2]. To our knowledge, however, no previously reported case has been sufficiently severe to necessitate endotracheal intubation and mechanical ventilation.

Our patient, whose serum D-lactate concentration on his first admission is among the highest reported, suffered progressive and catastrophic respiratory collapse due to obtundation from D-lactate accumulation. This extreme manifestation of D-lactate neurotoxicity led to hypopnea and hypercarbic respiratory failure, which in conjunction with his pre-existing end-stage renal disease triggered a life-threatening double acidosis with no endogenous means of compensation.

Notably, his symptoms were most severe immediately prior to his dialysis sessions; his most profound obtundation occurred in the mornings prior to scheduled dialysis and followed large meals of carbohydrates the night before. Neurologic improvement was evident within 30 min after beginning dialysis and after 3.5-h sessions of dialysis, he returned fully to baseline.

His recurrent episodes of encephalopathy necessitated multiple management strategies. Emergently, bicarbonate and ventilatory support were employed to combat the immediate dangers of his extreme acidosis. Antibiotics were employed both emergently on admission and as an outpatient to reduce and chronically suppress the overgrowth of colonic anaerobes. Hemodialysis was performed to both correct acidosis and remove D-lactate. Dietary modifications were attempted to limit the amount of carbohydrates available for metabolism to D-lactate.

This spectrum of treatments is notable in that it encompasses the full range of known therapies for D-lactate neurotoxicity, which as a consequence of its rarity necessarily suffers from principally anecdotal treatment guidelines. We will review the range of attempted therapies, their rationale and their reported efficacy and recommend a comprehensive strategy for management of the condition.

D-lactic acidosis is a pathologic process involving a substrate (carbohydrates), catalyst (terminal gut anaerobes, most importantly *Lactobacillus spp.*) and product (D-lactate) (Figure 1). In addition to D-lactate's symptomatic effects, its acidic property contributes to a positive feedback loop promoting the growth of *Lactobacillus* in the gut lumen. This positive feedback can contribute to potentially fatal neurologic impairment given sufficient substrate and the absence of adequate excretion. Targeted reduction of any of these elements should lead to a subsequent mitigation of symptoms as D-lactate levels are reduced.

Substrate reduction or carbohydrate restriction

Carbohydrates are absorbed almost completely by an intact small intestine. The amount available to colonic anaerobes, which are the principal producers of D-lactate,

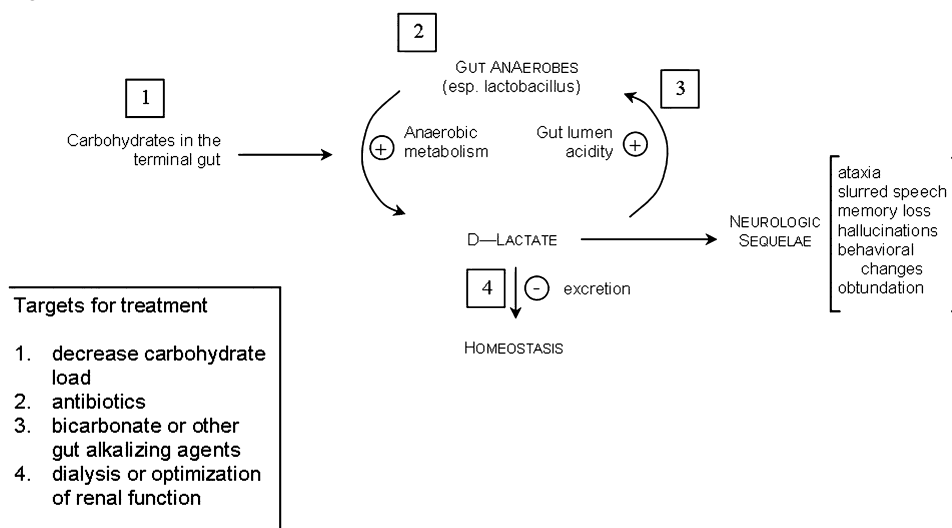


Fig. 1. The pathogenesis of D-lactic acidosis involves a substrate (carbohydrates), catalyst (terminal gut anaerobes, most importantly *Lactobacillus spp.*) and product (D-lactate). In addition to D-lactate's symptomatic effects, its acidic property contributes to a positive feedback loop promoting the growth of *Lactobacillus* in the gut lumen. Targeted reduction of any of these elements should lead to a subsequent mitigation of symptoms as D-lactate levels are reduced.

is sufficiently small that detectable levels of D-lactate are not found in healthy individuals [2]. D-lactate neurotoxicity has occasionally been diagnosed by reproducing symptoms with a carbohydrate challenge [3]. Given the frequent transience of symptoms and reports of particularly severe symptoms following high-carbohydrate meals, carbohydrate intake can be regarded as a rate-limiting factor in the development of D-lactate neurotoxicity. In fact, some anecdotal reports point to a positive feedback loop in which accumulation of D-lactate accompanies increased carbohydrate craving, as was reported by Carr *et al.* [4] and in our own case.

Clearly the most effective means of eliminating a product is to eliminate its substrate, and indeed, one strategy in treatment has been complete cessation of oral intake when D-lactate toxicity is suspected. Many attempts have been made to limit carbohydrate intake, with mixed success [3] and failure [5]. The dilemma of carbohydrate restriction in short-gut syndrome is that a carbohydrate-predominant diet is often recommended after jejunioileal resection [6]. The difficulty of maintaining adequate caloric intake with an extremely limited amount of carbohydrates, as is the case in ketogenic diets, is well established. While a reversion from oral intake to total parenteral nutrition has been attempted [7] and will prevent D-lactate buildup by eliminating carbohydrate exposure to the colonic lumen and its resident anaerobes, the high rate of infection and diminished quality of life would seem to argue against this method except in the most severe and refractory of cases.

Catalyst reduction with antimicrobial therapy

Normal colonic floras are largely benign; the incidence of systemic infection from gut anaerobes is low and sepsis due to *Lactobacillus* is exceedingly rare. D-lactic acidosis is no exception: the pathologic culprit is not the bacterium, but its byproduct. Though several D-lactate producing anaerobes are present in the colon, abnormally large carbohydrate delivery to the colon preferentially selects for *Lactobacillus spp.* as the accumulation of D-lactic acid creates an acidic gut milieu in which *Lactobacillus* rapidly becomes the dominant organism.

Antimicrobial therapy in D-lactic acidosis must be targeted toward reduction of colonic anaerobes and in particular *Lactobacillus*. The ideal antibiotic regimen will have poor oral absorption (so as to maximize intraluminal concentrations) and broadly target the principal D-lactate producing anaerobes. The most commonly employed agents used have been neomycin, oral vancomycin and metronidazole. Each has been used frequently over the last 30 years with varying success. Additionally, we used amoxicillin/clauvanate due to its poor oral absorption and excellent spectrum against *Lactobacillus*.

No single agent, however, has met with consistent success and recurrence of symptoms has been reported with all these therapies, including our own strategy of chronic suppression with metronidazole and amoxicillin/clauvanate. This is likely due to multiple factors, including incomplete eradication, multiple D-lactate generating species, and resistance patterns that shift faster than the treatment standards for this rare condition are updated. An example is the continued use of neomycin in D-lactate toxicity on the precedent of prior reports despite its relative inferiority to newer antibiotics.

Bongaerts *et al.* have provided the most comprehensive investigation into the causative organisms and their relative susceptibilities. They found that neomycin selected for *Lactobacillus acidophilus* while eradicating *Lactobacillus fermentum*, the other principal D-lactate producing species, while oral vancomycin did the opposite [8]. While the efficacy of antibiotics in general has not yet been convincingly demonstrated, it is likely that any effective regimen will involve multiple agents.

Bicarbonate may be best regarded as an antimicrobial in the treatment of D-Lactate toxicity: gut alkalization may

in severe disease mitigate the competitive advantage *Lactobacillus* gains against less acid-tolerant competitors through intraluminal D-lactate production. There is scant evidence to support this in clinical practice, though, and the treating physician must keep in mind that the symptoms of D-lactate toxicity may be principally due to the molecule itself rather than the associated acidity.

Product elimination

D-lactate toxicity remains a relatively rare phenomenon in proportion to the large number of patients with gut dysfunction, largely due to its efficient renal excretion. Oh *et al.* demonstrated that in healthy men continuously infused with a D-lactate solution excretion rates ranged between 61 and 100% [9]. Though toxicity can occur in the context of normal renal function as production overwhelms excretory capacity, the most pronouncedly symptomatic cases (including our own) seem to correlate with renal dysfunction. A 1993 case report describes a case of chronic D-lactate encephalopathy occurring in a patient with short-gut syndrome and end-stage renal disease [10]. Over the course of 15 weeks of tracking D-lactate level and neurologic symptoms, they discovered that 4 h of continuous dialysis significantly but incompletely removed D-lactate and that an increase in total weekly dialysis time led to a reduction of symptomatic episodes.

Our own experience correlated with this, as our patient suffered his most pronounced symptoms immediately preceding his scheduled dialysis day. The diagnosis was delayed due to the transience and varying severity of his initial symptoms, which in retrospect was likely due to the complex interaction between variable production and fixed windows of excretion. There may be a role for the treatment of D-lactate toxicity through dialysis. Our case, which we believe to be the most symptomatically extreme in published literature, suggests that this level of severity may only manifest in patients already on dialysis. This small subset of patients may require longer or more frequent dialysis, especially in the case of patients on a conventional three-sessions-per-week schedule that necessitates 72 h without dialysis during part of the week.

Conclusion

D-lactate neurotoxicity remains relatively rare, with fewer than 50 cases reported since its first description. Its rarity

makes a clear understanding of treatments all the more essential as it can progress rapidly, as it did in our patient, and become a life-threatening process.

Some evidence points to the possibility that D-lactate acidosis may be more prevalent than presently assumed. Despite the fact that it has, in adults, been almost exclusively reported following small bowel surgery, a study of randomly selected hospital inpatients found that 2.8% had measurable levels of D-lactate and 40% of these had no history of gastrointestinal surgery or disease. A markedly high proportion of inpatient delirium remains idiopathic. Evidence that D-lacticemia may be underdiagnosed and D-lactate's pleiomorphic neurotoxic effects suggest that patients with idiopathic neurologic changes may benefit from measurement of D-lactate levels, particularly if their presentation is in the context of renal compromise or gut dysfunction. While the treatment regimen that best balances symptomatic control and quality of life remains unclear, it will likely continue to involve a multifaceted approach.

Conflict of interest statement. None declared.

References

1. Oh MS *et al.* D-lactic acidosis in a man with the short bowel syndrome. *N Engl J Med* 1979; 301: 249–252
2. Petersen C. D-lactic acidosis. *Nutr Clin Pract* 2005; 20: 634–645
3. Narula R, El Shafei A, Ramaiah D, Schmitz P. D-lactic acidosis 23 years after jejunio-ileal bypass. *Am J Kidney Dis* 2000 Aug; 36(2): E9
4. Carr DB, Shih VE, Richter JM *et al.* Encephalopathy following jejunioileostomy. *JAMA* 1982; 247: 1127
5. Khurshheed J. Short bowel syndrome: A nutritional and medical approach. *CMAJ* 2002; 166: 1297–1302
6. Karton M, Rettmer RL, Lipkin EW. Effect of parenteral nutrition and enteral feeding on D-lactic acidosis in a patient with short bowel. *JPEN J parenter Enteral Nutr* 1987; 11: 586–589
7. Bongaerts GP *et al.* Role of bacteria in the pathogenesis of short bowel syndrome-associated D-lactic acidemia. *Microb Pathog* 1997; 22: 285–293
8. Oh MS *et al.* Metabolic utilization and renal handling of D-lactate in men. *Metabolism* 1985; 34: 621–625
9. Hingorani AD *et al.* Successful treatment of acute D-lactate encephalopathy by haemodialysis. *Nephrol Dial Transplant* 1993; 8: 1283–1285
10. Thurn JR, Pierpont GL, Ludvigsen CW *et al.* D-lactate encephalopathy. *Am J Med* 1985; 79: 717–721

Received for publication: 8.12.10; Accepted in revised form: 20.12.10