

Corticosteroid therapy in Riedel's thyroiditis

B Vaidya, PE Harris, P Barrett, P Kendall-Taylor

Summary

We report a case of Riedel's thyroiditis presenting with a systemic illness, life-threatening stridor and a stony hard goitre. Diagnosis was confirmed by open thyroid biopsy. Treatment with corticosteroid resulted in a dramatic improvement. A possible autoimmune mechanism in the pathogenesis of Riedel's thyroiditis is discussed.

Keywords: Riedel's thyroiditis, tracheal compression, corticosteroid, autoimmune disease

Riedel's thyroiditis is a chronic inflammatory lesion of the thyroid gland characterised by dense and invasive fibrosis involving the gland and its surrounding tissue. This condition is very rare. Only 37 cases were found on review of histology of 57 000 thyroidectomies, an incidence of 0.06%.¹ Patients classically present with a stony hard thyroid mass which tends to be adherent to the surrounding tissues, making clinical distinction from malignancy very difficult. Not infrequently, they have compressive symptoms including dyspnoea, stridor, a feeling of suffocation, dysphagia and hoarseness. Thyroid function is usually in the euthyroid range, but may be hypothyroid if the disease is extensive, involving the whole gland. Erythrocyte sedimentation rate (ESR) is generally elevated. Thyroid antibodies are found in 67% of cases.² Histologic features of this disorder include complete destruction of involved thyroid tissue with absence of normal lobulation, lack of granulomatous reaction, cellular exudation, extension of fibrosis beyond the thyroid into the adjacent structures such as nerves, blood vessels, fat and skeletal muscles and occlusive phlebitis.^{3,4} We present a patient with a life-threatening tracheal compression due to Riedel's thyroiditis who made a dramatic improvement with corticosteroid therapy.

Case report

A 50-year-old woman initially presented in December 1992 with primary hypothyroidism and goitre. There was no family history of thyroid or other autoimmune disorders. She was treated with thyroxine replacement therapy. Four months later, she developed a systemic illness with malaise, tiredness, sore-throat and pyrexia. She also complained of breathlessness, hoarseness and increase in goitre size. Examination demonstrated a very large, diffuse, rock hard, fixed goitre. The

trachea was not palpable and there was no lymphadenopathy. She was clinically euthyroid.

Investigations revealed haemoglobin 10.1 g/dl, normochromic, normocytic, white cells $12.7 \times 10^9/l$ (neutrophils $11.4 \times 10^9/l$), platelets $1045 \times 10^9/l$, ESR 120 mm/h, and C-reactive protein 241 mg/l (normal range 0–12). Renal function, calcium and phosphate were normal. Liver function tests showed alkaline phosphatase 320 IU/l (29–111), α -glutamyl transferase 244 IU/l (<40), alanine transaminase 19 IU/l (3–41) and albumin 27 g/l (38–48). Thyroid function was normal on thyroxine 200 μ g daily. Septic screen, hepatitis screen, viral serology, chest X-ray, ultrasonography of abdomen and myeloma screen were normal. Bone marrow aspiration showed a reactive picture. Thyroid microsomal (1:12 800), thyroglobulin (1:3200) and gastric parietal cell antibodies were positive, but Rh factor, antinuclear, smooth muscle, antimitochondrial and reticulin antibodies were negative. Thyroid ultrasonography revealed diffuse enlargement of both lobes and isthmus with an inhomogenous hypo-echogenicity. Tracheal compression was demonstrated on X-ray of the thoracic inlet. Fine needle aspiration of thyroid was inconclusive showing organising haematoma only. Technetium scan of the thyroid demonstrated no uptake.

The patient underwent open thyroid biopsy. The thyroid was found to be indurated, infiltrating the surrounding tissues, and was not resectable. Histology of the biopsy was consistent with Riedel's thyroiditis (figure 1). This demonstrated dense fibrous tissue infiltration replacing the normal thyroid parenchyma within which focally degenerate striated muscle fibres and adipocytes were noted. There was a prominent mixed cellular exudation (lymphocytes 55%, neutrophils 33%, macrophages/monocytes 12%). The predominant lymphocyte type was T-cell marker positive (CD3 and UHL-1), although there were scattered B cells (CD79a and L26) primarily in the follicular centres. There was a slight predominance of CD8+ over CD4+ lymphocytes (CD8+ cells 28%, and CD4+ cells 23%). There was no evidence of malignancy.

Following biopsy, her condition continued to deteriorate rapidly with increasing breathlessness, stridor and dysphagia. Peak flow was reduced to 150 l/min. Her FEV₁ was 1.8 l, FVC 3.5 l and FEV₁/FVC was 54%. In view of the severity of her distressing symptoms, the possible need for tracheostomy was assessed. This was considered to be technically difficult.

Royal Victoria
Infirmary, Newcastle
upon Tyne,
NE1 4LP, UK
Department of
Medicine (Endocrinology)
B Vaidya
PE Harris
P Kendall-Taylor
Department of
Pathology
P Barrett

Correspondence to
B Vaidya, Department of
Medicine, North Tees
General Hospital,
Stockton-on-Tees,
TS19 8PE, UK

Accepted 1 May 1997

Figure 1 Histology showing (A) thyroid parenchyma replaced by dense fibrous tissue, and (B) mixed cellular infiltration (H&E stain)

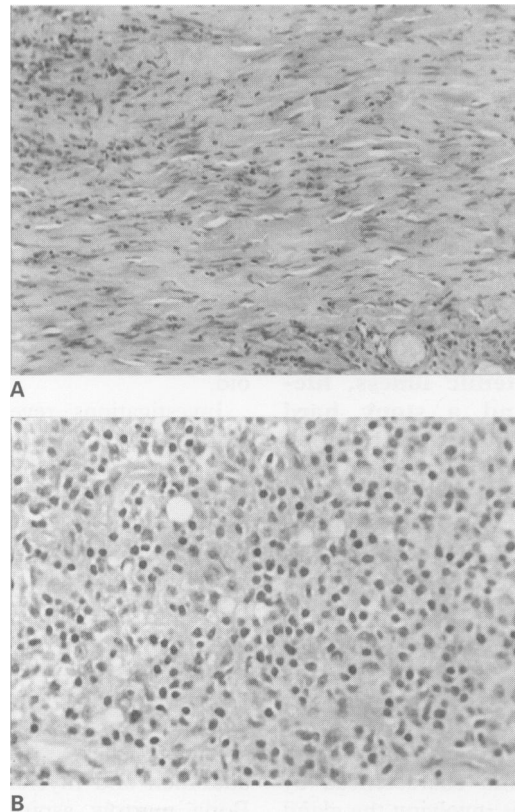
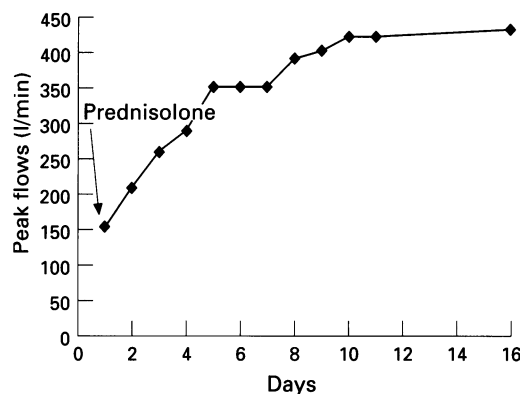


Figure 2 Improvement in peak flows following corticosteroid therapy



Treatment was commenced with prednisolone 80 mg/daily. A dramatic improvement in her symptoms was evident within 24 hours. Over the ensuing days, there was continued improvement in her symptoms, in the size and consistency of goitre, and peak flows (figure 2). Haemoglobin, ESR, C-reactive protein and liver function tests normalised within two weeks of initiation of prednisolone. Follow-up thoracic inlet X-ray showed that the trachea was uncompromised. The dose of prednisolone was gradually reduced. At present, she is maintained on prednisolone 5 mg and thyroxine 150 μ g daily. There is no evidence of recurrence, ESR remains suppressed, thyroid gland not palpable, and recent ultrasonography demonstrated atrophy of the thyroid gland.

Discussion

The aetiology of Riedel's thyroiditis is unknown. There has been considerable discussion in the past as to whether it is a variant of

Summary points

- the early use of high dose steroids in Riedel's thyroiditis can be life-saving, and may avoid hazardous surgery and invasive procedures like tracheostomy
- Riedel's thyroiditis diagnosed postoperatively should also be treated with steroids to prevent progression or recurrence
- high titres of thyroid autoantibodies, marked lymphocytic infiltration and dramatic response to steroids in this case support the hypothesis that Riedel's thyroiditis may be a T-cell mediated autoimmune disease

Hashimoto's thyroiditis. They are now considered to be separate clinico-pathological entities. There is a well documented association between Riedel's thyroiditis and retroperitoneal and mediastinal fibrosis, orbital pseudotumour and fibrosis in other organs. This suggests that these fibrotic processes might be different manifestations of the same disease, sometimes termed 'idiopathic multifocal fibrosclerosis'.⁵ There are occasional reports of coexistence of Riedel's thyroiditis with other autoimmune disorders such as Addison's disease, insulin-dependent diabetes, pernicious anaemia, Graves' disease and Hashimoto's thyroiditis. In addition, the presence of mononuclear cell infiltrate within the fibrotic process and the presence of thyroid autoantibodies in a significant number of patients, as in our case, suggest a possible autoimmune mechanism in the pathogenesis of Riedel's thyroiditis.⁶

Surgery has been the recommended treatment for Riedel's thyroiditis, mainly to release the trachea from compression and to obtain a biopsy in order to exclude malignancy. Due to the very hard consistency and invasion of the surrounding tissues with obliteration of surgical planes and landmarks, surgery is often very difficult and is potentially hazardous in this condition. In addition, recurrence after surgery is well recognised.^{7,8} Although there have been no controlled trials of steroid therapy in Riedel's thyroiditis, there are some anecdotal reports suggesting that steroids may be of benefit in this condition.^{2,6,8-11} Some patients seem to have obtained a long-term benefit even after steroid withdrawal,^{2,9} while others relapsed when steroids were stopped^{9,10} and in some cases no significant improvement was noted, possibly due to longer duration of the fibrosis.^{4,10} Steroids are considered to be more effective if given early in the disease. Rarely, spontaneous regression can occur in Riedel's thyroiditis.¹² In our case, there was a dramatic improvement of the compressive symptoms with the high dose of prednisolone, avoiding tracheostomy. The associated systemic disturbances and abnormal liver function tests noted at the presentation also improved with treatment. The goitre regressed to atrophy of a small maintenance dose of prednisolone.

We are grateful to Dr P Tanner for referring this patient.

- 1 Hay ID. Thyroiditis: a clinical update. *Mayo Clin Proc* 1985; **60**: 836–43.
- 2 Schwaegerle SM, Bauer TW, Esselstyn CB. Riedel's thyroiditis. *Am J Clin Pathol* 1988; **90**: 715–22.
- 3 Woolner LB, McConahey WM, Beahrs OH. Invasive fibrous thyroiditis (Riedel's struma). *J Clin Endocrinol Metab* 1957; **17**: 201–20.
- 4 Meijer S, Hausman R. Occlusive phlebitis, a diagnostic feature in Riedel's thyroiditis. *Virchows Arch A Pathol Anat Histol* 1978; **377**: 339–49.
- 5 DeLange WE, Freling NJM, Molenaar WM, Doorenbos H. Invasive fibrous thyroiditis (Riedel's struma): a manifestation of multifocal fibrosclerosis? *Q J Med* 1989; **268**: 709–17.
- 6 Heufelder AE, Hay ID. Evidence for autoimmune mechanisms in the evolution of invasive fibrous thyroiditis (Riedel's struma). *Clin Invest* 1994; **72**: 788–93.
- 7 Nielsen HK. Multifocal idiopathic fibrosclerosis. *Acta Med Scand* 1980; **208**: 119–23.
- 8 Zimmermann-Belsing T, Feldt-Rasmussen U. Riedel's thyroiditis: an autoimmune or primary fibrotic disease? *J Intern Med* 1994; **235**: 271–4.
- 9 Katsikas D, Shorthouse AJ, Taylor S. Riedel's thyroiditis. *Br J Surg* 1976; **63**: 929–31.
- 10 Thomson JA, Jackson IMD, Duguid WP. The effect of steroid therapy on Riedel's thyroiditis. *Scot Med J* 1968; **13**: 13–6.
- 11 Kelly WF, Mashiter K, Taylor S, Joplin GF. Riedel's thyroiditis leading to severe but reversible pituitary failure. *Postgrad Med J* 1979; **55**: 194–8.
- 12 Hartemann P, Leclere J, Mizrahi R, Zannetti A, Genton P, Parache RM. A case of regressive Riedel's thyroiditis. *Ann Endocrinol* 1979; **40**: 65–6.

Ocular purpura in a swimmer

Nigel I Jowett, Sheena G Jowett

Summary

Swimming goggles are increasingly being worn by children during swimming lessons to protect their eyes, although reports of ocular damage associated with their use is becoming more common. We describe a new injury, 'purpura gogglorum', caused by overtight application of faulty goggles. Whilst no permanent harm to the eyes resulted in this case, other swimmers have sustained more serious ocular damage, including loss of sight, from goggle-associated injury.

Keywords: goggles, swimming, ocular damage

Swimming goggles are often worn by children during swimming lessons because ocular symptoms are common without them. Whilst adenoviral-induced conjunctivitis (pharyngoconjunctival fever) and other organisms are usually inhibited by adequate chlorination of the water, high chlorine and ammonia concentrations frequently lead to watering, stinging or swelling of the eyes. We previously viewed these goggles as being harmless swimming accessories, but worrying reports of goggle-associated ocular trauma have been

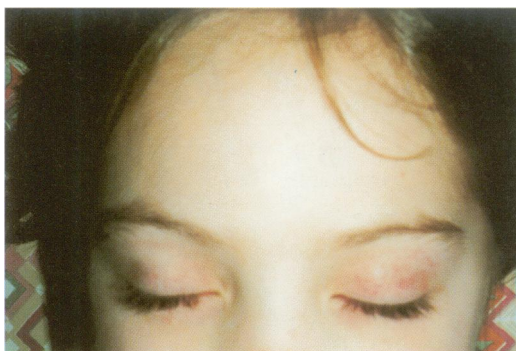accumulating, and we describe a further, hitherto unreported injury.

Case report

Our healthy seven-year-old daughter presented to us following her weekly swimming lesson with an extensive purpuric rash over her left eyelid (figure). The right eyelid was only mildly affected, but the eye itself was reddened and sore. The cause of these eye signs was not clear initially, until she later requested a new pair of swimming goggles. Apparently, the right eye-piece had started to leak during the lesson, filling with water and causing irritation to the eye. To stop the leak, she tightened the head band incrementally, pulling the goggles away from her face to empty out the eye piece. In doing so, not only had the pressure on the orbital soft tissues increased, but each time the goggles had been pulled away from the eye, a negative pressure had been induced by the normally functioning seal on the left side, producing suction petechiae. The effect was not so marked on the right side because of the faulty seal. The left eyelid subsequently became oedematous, but responded to treatment with a cold compress, the petechiae and the swelling resolving over 24 h without sequelae.

Discussion

We were alarmed to find many previous reports of significant eye injuries associated with the use of swimming goggles (box 1). Serious ocular injury has resulted when the eye pieces having been pulled away from the face to clean the lenses, slipped and recoiled into the unprotected eye.¹ Contact dermatitis from the neoprene cushion seals seems to be a common cause of red and oedematous eyes,^{2,3} and baggy, oedematous eyelids may result from excess pressure from stiff frames on the medial part of the upper lid.⁴ An acute corneal



Figure

Treffgarne,
Pembrokeshire,
Wales, UK
NI Jowett
SG Jowett

Correspondence to Dr NI Jowett, Withybush General Hospital, Haverfordwest, Pembrokeshire SA61 2PZ, Wales, UK

Accepted 20 March 1997