

Psoas Abscess: Imaging Diagnosis of A Rare Entity

Aniruddha Kulkarni¹, Mubashshera Aafreen², Shubhangi Shetkar³, Md Ashfaque Tinmaswala⁴

¹Professor and HOD, Department Of Radiology, Tapadiya Diagnostic Centre Aurangabad India.

^{2,4}Resident, Department Of Radiology, Tapadiya Diagnostic Centre Aurangabad India.

³Consultant Radiologist, Department Of Radiology, Tapadiya Diagnostic Centre Aurangabad India.

Received: February 2018

Accepted: February 2018

Copyright: © the author(s), publisher. It is an open-access article distributed under the terms of the Creative Commons Attribution Non-Commercial License, which permits unrestricted non-commercial use, distribution, and reproduction in any medium, provided the original work is properly cited.

ABSTRACT

Psoas abscess (PA) is a rare infection which may present as pus collection in the ilio-psoas muscle compartment. Mynter et al described this entity for the first time in 1881. Its incidence is so rare that less than 15 patients are diagnosed every year in whole world. It is not only a rare infection but also it is an under diagnosed entity because of its non-specific and vague symptomatology. These abscesses are many times under-diagnosed despite availability of improved diagnostic modalities. The diagnosis require a high index of suspicion specially in patients of diabetes, patients on immunosuppressants, individuals receiving chemotherapy and patients with acquired immunodeficiency syndrome. The Psoas abscesses are divided into primary and secondary PA on the basis of the etiology. The exact etiology of primary Psoas abscess is not known but it is thought to be secondary to hematogenous spread. The secondary Psoas abscess is thought to be secondary to spread of infection from the adjacent sites like from pott's spine or secondary to urinary tract infection, post spine-surgery, in patients with mycotic aneurysms, individuals with endocarditis and pyogenic osteomyelitis etc. The common organisms involved in PA include S.Aureaus, E.Coli, Bacteroids, M.Tuberculosis, Enterococcus and peptostreptococcus. Patients may present with the classical triad of Pain, Fever and Limp. A timely diagnosis and immediate and aggressive treatment is essential as these abscesses carry a very high mortality if not treated in time. The imaging techniques which may be used for the diagnosis include Ultrasound Imaging, Computerised Tomography and Magnetic Resonance Imaging. Plain Radiographs are usually unremarkable. The fact that Psoas muscle abscess are located in the retrofascial space rather than in the retroperitoneal space makes its diagnosis difficult on ultrasound examination and approximately 40% of the times the diagnosis of Psoas abscess is missed on ultrasonography. Diagnosis by CT and MRI is relatively easy and almost all cases can be diagnosed on the basis of CT or MRI. Unenhanced CT may show presence of abscess within the Psoas muscle. A CT-Scan with oral and IV contrast may be needed in some cases of Psoas abscess where the abscess is suspected to be secondary. CT may also help in CT Guided drainage of abscess which may have diagnostic (culture and sensitivity) and therapeutic implications. MRI may provide better visualization of abscess than CT scan moreover MRI can simultaneously rule out other causes of low back pain. In some advanced centers gallium-67 scanning is being used for the diagnosis of Psoas abscess but its routine use is not feasible in developing countries like that of India. We are reporting here a case of Psoas abscess in 25 year old female who were sent for referred to us for CT abdomen. She had a history of fever, right flank pain, nausea and referred pain to groin. We diagnosed her to be having Psoas Abscess on the basis of imaging findings. Patient received appropriate treatment in the form of drainage of abscess and proper antibiotics after which he improved drastically. This case report emphasizes the importance of early imaging diagnosis and institution of appropriate treatment.

Keywords: Psoas Abscess, Immunosuppression, Imaging Diagnosis, Prompt Treatment.

INTRODUCTION

Psoas abscess (PA) is defined as collection of pus in Psoas compartment. The infection may reach this compartment either from contagious infective focus or from hematogenous spread. Mynter was the first person to describe this pathology in 1818.^[1] It may present with non-specific symptoms like back pain,

pyrexia of unknown origin, abdominal pain and urinary complaints. It is more commonly seen in elderly patients, individuals with diabetes mellitus, HIV and individuals receiving long term steroid therapy. The common organisms responsible for Psoas abscess include Staphylococcus aureus, E.Coli, Bacteroids sp., Mycobacterium tuberculosis and Streptococci.^[2] Very few cases of Psoas abscess have been reported in literature not only because it's rare but also because of difficulty in arriving at a diagnosis due to non-specific symptomatology of Psoas abscess. The incidence of Psoas abscess is estimated to be approximately 12 cases per year in the world, although this incidence is having an upward trend due to increased availability of

Name & Address of Corresponding Author

Dr. Mubashshera Aafreen
Resident,
Department Of Radiology,
Tapadiya Diagnostic Centre
Aurangabad
India.

imaging techniques like Computerised tomography (CT Scan) and Magnetic Resonance Imaging (MRI).^[3] Psoas abscess is divided into primary and secondary on the basis of whether they are due to a bacteremia distant to ilio-psoas muscle (primary Psoas abscess) or because of a direct spread of infection to the ilio-psoas muscle by contiguity from an adjacent structure like sigmoid colon, appendix, jejunum, ureters, kidneys, pancreas and spine (secondary Psoas abscess). The fact that Psoas muscle is rich in blood supply makes it predisposed to hematogenous spread from other sites of infection. In earlier days tuberculosis was one of the common causes of secondary Psoas abscess but with widespread use of antitubercular drugs the incidence of tubercular Psoas abscess has reduced and now the Psoas abscess is usually caused by pyogenic organisms.^[4]

Imaging of Psoas abscess is an important part of management of the patients. Proper imaging can help in early diagnosis of the patients which is essential because PA may prove fatal if not diagnosed in time and treated properly with appropriate antibiotics. Ultrasound is the most easily available diagnostic tool for the diagnosis of Psoas abscess. It is relatively inexpensive and free of ionizing radiation but it is highly operator dependant and only 60% cases of Psoas abscess can be diagnosed on ultrasound. Another problem with ultrasound imaging is that the retroperitoneal space can be very difficult to visualize in obese patients and many a times is obscured by presence of bowel gases. Cross sectional imaging like Computed Tomography may be used to overcome these problems and is considered "gold standard" for the diagnosis of Psoas abscess. Some authors recommend MRI because of its ability to visualize the abscess wall and surrounding structures without intravenous contrast medium thus avoiding potential side effects of intravenous contrast. Moreover MRI allows better discrimination of soft tissues giving it a distinct advantage over CT scan. The disadvantages with MRI includes the fact that it can't be done in claustrophobic patients, individuals with pacemakers, cochlear implants or aneurysmal clips.^[5]

We present here a case of 25 year female who had been referred for CT abdomen with history of fever, left flank pain, nausea and referred pain to groin. she was diagnosed to be having Psoas Abscess on the basis of imaging findings. Patient received appropriate treatment in the form of drainage of abscess and proper antibiotics after which he improved drastically. This case report emphasizes the importance of early imaging diagnosis and institution of appropriate treatment.

CASE REPORT

A 25-year-old female was referred to us for imaging with complaints of 2-weeks' history of non specific

abdominal and right groin pain. Patient gave history of painful and restricted movements of right hip and was also having a history of fever since 8-10 days without any other apparent cause of fever. Lab investigations showed a raised C-reactive protein and mild leukocytosis. Reading of clinical notes showed that there was tenderness in left lower quadrant of abdomen. Initially Ultrasonography was done which showed hydronephrosis on right side and presence of heterogeneous lesion with internal echoes in right ilio-psoas compartment.

A diagnosis of Right Psoas abscess was considered and CT abdomen was done to confirm the diagnosis. Several axial sections of whole abdomen were studied with negative oral and non-ionic IV contrast using the spiral mode on a 64 slice CT scanner. Computed tomography (Axial Images) showed bulky right psoas as compared to left. A thick walled peripherally enhancing necrotic collection involving right psoas muscle was seen.

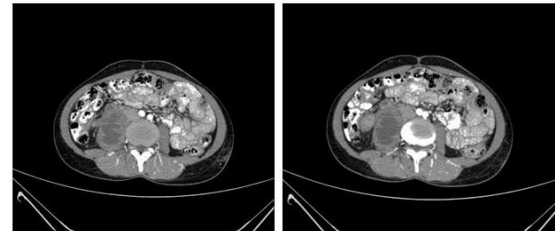


Figure 1: Contrast enhanced axial CT sections showing bulky right psoas as compared to left. A thick walled peripherally enhancing necrotic collection involving right psoas muscle is seen. Features are s/o right psoas abscess.

On coronal CT abscess was seen extending from L2 to L5 vertebrae closely abutting right pelviureteric junction and proximal ureter. These findings confirmed diagnosis of right psoas abscess.

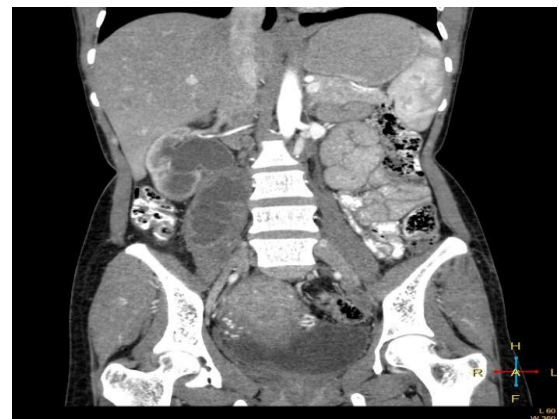

Figure 2: Contrast enhanced coronal CT section showing extent of abscess involvement. The abscess is seen extending from L2-L5 and closely abutting right PUJ and proximal ureter.

Based Upon these findings a diagnosis of right psoas abscess was made. Follow up of the patient was done and it was found that the patient underwent

drainage of the psoas abscess and received intravenous antibiotics on the basis of culture and sensitivity report for 2 weeks. The patient became afebrile in 1 week. The IV antibiotics were stopped and oral antibiotics were started after 2 weeks and were continued up to 6 weeks. The symptoms resolved and the pain, restricted movements and deformity in the hip disappeared several days after beginning of antibiotic therapy.

DISCUSSION

The ilio-psoas compartment is an extraperitoneal compartment containing ilio-psoas and iliacus muscles. The Psoas major is a long fusiform muscle on the side of the lumbar region of the vertebral column and lesser pelvis. Its origin is from the lateral borders of T12 to the L5 vertebrae. The muscle passes downward across the brim of the lesser pelvis and passes beneath the inguinal ligament in front of the capsule of the hip joint and inserted into the lesser trochanter of the femur. The Psoas muscle lies in close proximity to organs such as the sigmoid colon, appendix, jejunum, ureters, abdominal aorta, kidneys, pancreas and spine. Hence infections in any of these structures can spread to the ilio-psoas muscle. Another mechanism of spread of infection to Psoas muscle is by hematogenous spread which is facilitated by relatively rich blood supply to ilio-psoas.^[6]

In 1881 Mynter described this entity for the first time and named it acute psoitis. Its incidence is very rare ranging from 10-12 cases per year worldwide making it one of the rare diagnoses to be made. It may present with non specific symptoms including but not limited to non-specific abdominal or flank pain, pain while walking, limping, urinary complaints, fever, malaise, weight loss and anorexia. A high index of suspicion is needed to make a proper diagnosis. The non-specific tests like a raised white cell count, raised C-reactive protein, and raised erythrocyte sedimentation rate may be the first sign of Psoas abscess. Blood cultures may be positive for the offending organism. Initial radiological investigations may include plain radiograph of the kidney ureters bladder or IVU. The definitive diagnosis can be made with the help of ultrasound, computed tomography and magnetic resonance imaging.^[7]

Ultrasound may show heterogeneously hypoechoic collection with multiple foci of gas around the Psoas muscle in retrofascial space. There may be associated enlargement of affected Psoas muscle. As already mentioned though ultrasound is quick to perform, widely available and relatively affordable it lacks sensitivity and is highly dependent upon the operator.^[8]

Computed tomography is the investigation of choice for the diagnosis of Psoas abscess. The sensitivity of computed tomography for the diagnosis of Psoas

abscess is nearly 100%. On CT Psoas abscess may present as enlargement of the ilio-psoas muscle by a hypodense lesion. It typically shows rim enhancement in post contrast images. Lenchik et al conducted a retrospective study to differentiate neoplastic, inflammatory, and hemorrhagic conditions of the ilio-psoas compartment. They reviewed CT scans of 44 patients who had abnormalities of the ilio-psoas compartment. Final diagnoses were established by surgical biopsy, percutaneous biopsy or clinical evidence. Diagnoses were correlated with CT features to determine findings that could be used to differentiate the three abnormalities. These included enlargement of the ilio-psoas muscles; extent, margination, and attenuation of the lesion; presence of gas, calcification, bone destruction, fat infiltration, and fascial disruption; and associated fluid or adenopathy. They concluded that a low-attenuation lesion was the most reliable CT feature of ilio-psoas abscess.^[9]

MRI imaging is a very useful investigation for the diagnosis of Psoas abscess. Its use is limited by its cost, its relative contraindications in some patients and limited availability. MR imaging may show areas of high signal intensity at non-enhanced T2-weighted images. Moreover MRI can diagnose other causes of back pain and it can show the abscess wall and surrounding structures in a better fashion without the need for intravenous contrast.^[10]

Once the diagnosis is confirmed by imaging the management is pretty straightforward and consist of drainage of abscess and starting appropriate antibiotics on the basis of culture and sensitivity reports. In the past, open drainage of the abscess through an iliac crest incision was often been done but current standard of care is percutaneous CT-guided drainage of the abscess which is less invasive, has less chances of complications and is associated with decreased morbidity.

CONCLUSION

Psoas abscess is a very rare occurrence. Only 10- 12 cases per year are diagnosed around the world making it one of the rarest imaging diagnoses. If not diagnosed early and treated properly it can prove fatal in majority of the cases. We reported this case to emphasize the importance of early imaging diagnosis of this rare entity.

REFERENCES

1. Mynter H. Acute psoitis. Buffalo Med Surg J. 1881;21:202–210.
2. Ricci MA, Rose FB, Meyer KK. Pyogenic psoas abscess: worldwide variations in aetiology. World J Surg. 1986;10(5):834–43.
3. Takada T, Terada K, Kajiwarra H, Ohira Y. Limitations of using imaging diagnosis for psoas abscess in its early stage. Intern Med. 2015;54(20):2589-93.

4. Harrigan RA, Kauffman FH, Love MB. Tuberculous psoas abscess. *J Emerg Med.* 1995 Jul-Aug;13(4):493-8.
5. Stern JJ, Stoopack PM. Magnetic resonance imaging in the diagnosis of a psoas abscess. *J Comput Tomogr.* 1988 Jan;12(1):79-80.
6. Sajko S, Stuber K. Psoas Major: a case report and review of its anatomy, biomechanics, and clinical implications. *The Journal of the Canadian Chiropractic Association.* 2009;53(4):311-318.
7. Chern CH, Hu SC, Kao WF, Tsai J, Yen D, Lee CH. Psoas abscess: making an early diagnosis in the ED. *Am J Emerg Med.* 1997 Jan;15(1):83-8.
8. Usehal A, Essodegui F, Abdelouafi A, Kadiri R. [Ultrasonography in the diagnosis and treatment of psoas abscess. Apropos of a study with 30 patients]. *J Radiol.* 1994 Nov;75(11):629-34.
9. Hoffer FA, Shamberger RC, Teele RL. Ilio-psoas abscess: diagnosis and management. *Pediatr Radiol.* 1987;17(1):23-7.
10. Lee JK, Glazer HS. Psoas muscle disorders: MR imaging. *Radiology.* 1986 Sep;160(3):683-7.

How to cite this article: Kulkarni A, Aafreen M, Shetkar S, Tinmaswala MA. Psoas Abscess: Imaging Diagnosis of A Rare Entity. *Ann. Int. Med. Den. Res.* 2018; 4(2):RD22-RD25.

Source of Support: Nil, **Conflict of Interest:** None declared