

## Intestinal geotrichosis in a German shepherd

Ya-Jane LEE<sup>1,4</sup>, Wei-Li HSU<sup>2</sup>, Chin-Fu LIN<sup>3</sup>, Shao-Wei LEE<sup>4</sup>, Feng-Pang CHENG<sup>1,4,\*</sup>

<sup>1</sup>Department of Veterinary Medicine, College of Veterinary Medicine, National Chung-Hsing University 250 Kuo-Kuang Rd 402 Taichung City - TAIWAN

<sup>2</sup>Graduate Institute of Microbiology and Public Health, College of Veterinary Medicine, National Chung-Hsing University 250 Kuo-Kuang Rd 402 Taichung City - TAIWAN

<sup>3</sup>Division of Microbiology, Department of Medical Laboratory, Taichung Veterans General Hospital, Taichung - TAIWAN

<sup>4</sup>Veterinary Medical Teaching Hospital, College of Veterinary Medicine, National Chung-Hsing University 250 Kuo-Kuang Rd 402 Taichung City - TAIWAN

Received: 17.09.2009

**Abstract:** A 4-year-old sexually intact male German shepherd with a 3-month history of chronic watery diarrhea was referred to the Veterinary Medical Teaching Hospital. Dehydration and serum biochemistry revealed hypoalbuminemia, and fecal material contained a large quantity of round arthroconidia that were microscopically observed. A specimen was submitted for fungal culture and yielded a white to cream-colored subsurface colony. Microorganisms derived from the colony exhibited chains of smooth, septate hyaline hyphae that were producing 1-celled arthroconidia. *Geotrichum candidum* was thus identified. Colonoscopic features included erythema, edema, and loss of the usual fine vascular pattern, with granularity of the mucosa of the descending colon. Treatment consisted of oral administration of ketoconazole and metronidazole for 3 weeks, while oral prednisolone was tapered after 1 week of therapy. The dog's feces gradually softened after the first treatment. Fecal smear examination revealed no trace of the yeast-like microbes 7 days after treatment was administered, and 2 weeks post-treatment the dog passed well-formed stools and had regained its normal body weight. The previously observed clinical signs did not reoccur, even after oral medication was withdrawn.

**Key words:** Geotrichosis, diarrhea, dog, fungus

### Introduction

*Geotrichum candidum* is a ubiquitous saprophytic fungus of soil and decaying organic wastes. In animals and humans it can be isolated as part of the resident microflora or a pathogen (1), or as an opportunistic pathogen capable of causing diseases in immunocompromised hosts. Such infections are referred to as geotrichosis (1,2). Only a few cases of

geotrichosis involving pulmonary (1,3), cutaneous (2), and oral sites (4) have been documented in dogs. Isolation of *G. candidum* from the feces of clinically normal animals is possible (1). Nevertheless, canine intestinal geotrichosis has not been reported to date. The present case report describes the clinical findings and treatment of a German shepherd diagnosed with intestinal geotrichosis.

\* E-mail: fpcheng@dragon.nchu.edu.tw

### Case history

A 4-year-old sexually intact, annually vaccinated male German shepherd with a 3-month history of chronic watery diarrhea was treated with antibiotics and anti-diarrheal agents at several local clinics. Treatments administered before the dog was referred to the Veterinary Medical Teaching Hospital, National Chung-Hsing University, did not result in complete remission. The dog maintained a good appetite during the therapy period. Physical examination revealed the patient was bright, alert, and responsive; however, the dog exhibited weight loss, emaciation, and dehydration. Abnormal serum biochemical values included low albumin level (1.99 IU/L; normal: 2.3-4.3 IU/L), slightly elevated AST (51.8 IU/L; normal: 0-40 IU/L), LDH (157 IU/L; normal: <100 IU/L), and CK (198 IU/L; normal: 8-60 IU/L), and a high potassium concentration (5.26 mmol/L; normal: 2.7-5.0 mmol/L). Fecal material was microscopically observed to contain a large quantity of round arthroconidia (Figure 1). A specimen was submitted for fungal culture and yielded a white to cream-colored subsurface colony on Sabouraud agar at 25-28 °C. Microorganisms derived from the colony exhibited chains of smooth, septate hyaline hyphae that were producing 1-celled arthroconidia (Figure 2). *Geotrichum candidum* was thus identified based on its definitive morphological characters. Additionally, *Proteus vulgaris* was isolated via fecal mycobacterial culture under anaerobic conditions. Colonoscopic features included erythema, edema, and loss of the

usual fine vascular pattern, with granularity of the mucosa of the descending column (Figure 3).

As a result, the patient was diagnosed with inflammatory bowel disease (IBD) caused by intestinal geotrichosis. Ketoconazole (20 mg/kg) and metronidazole (25 mg/kg) were orally administered for a period of 3 weeks, while oral prednisolone (2 mg/kg for the first 3 days and 1 mg/kg for the following 4 days) was tapered after 1 week of therapy. Well-cooked rice combined with Hill's i/d was as the dog's regular diet. His feces gradually changed from watery to mushy, and tended to be softly formed after the first treatment. Fecal smear examination 7 days after treatment revealed no trace of yeast-like microbes; thereafter, the dog regained its normal body

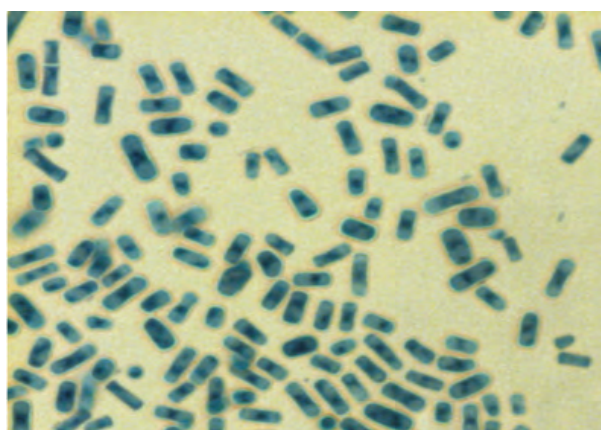


Figure 2. *Geotrichum candidum* isolated from feces showing characteristic rectangular arthrospores as demonstrated by lactophenol cotton blue staining ( $\times 400$ ).

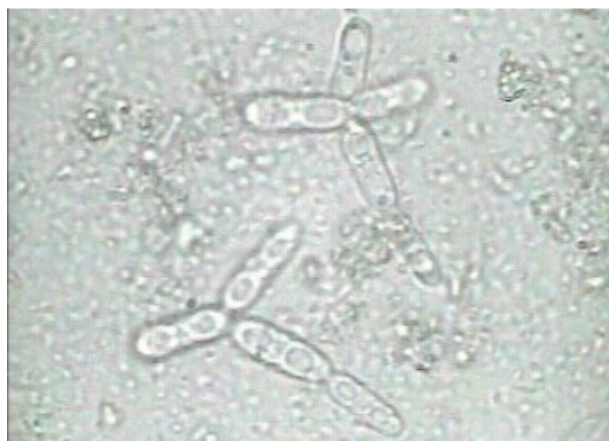

Figure 1. Photomicrograph represented unicellular hyaline arthroconidia in fecal material ( $\times 400$ ).

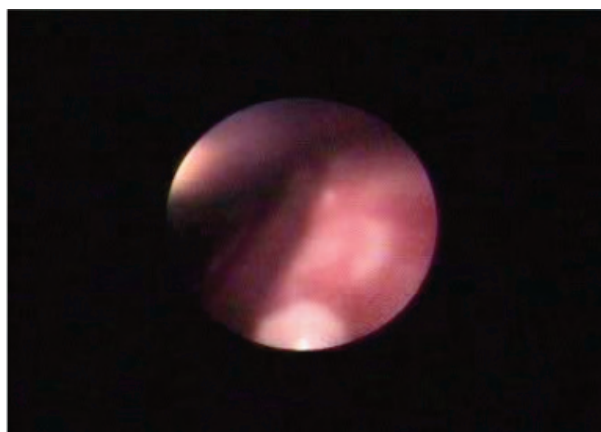


Figure 3. Mucosal erythema, granularity and edema of colon seen by the enteroendoscopy.

weight and 2 weeks post-treatment passed well-formed stools. The previous clinical signs did not reoccur, even after oral medication was withdrawn.

## Results and discussion

Human geotrichosis is often associated with immunodeficiency due to viral infection, chemotherapy, or leukemia, and can also occur secondary to other infections (5,6). Under such circumstances systemic dissemination is possible. Historically, the presented patient did not receive any chemotherapy or immunosuppressive medication. Additionally, the dog's annual vaccination record was sound. Blood work revealed the level of leukocytes was normal, indicative of non-inflammatory infection. Diarrhea was the sole clinical sign, suggesting the involvement of the intestinal tract. These findings indicated that the immunocompetent dog might have been suffering from intestinal geotrichosis due to other reasons. In addition, the dog had received long-term antibiotics therapy. Under such circumstances, the growth of organisms, such as enterobacteriaceae and lactobacilli, was inhibited, promoting the fungal proliferation (7). Based on the fact that the medicines previously used to treat the dog did not contain any type of steroid that would interfere with its immune response and *G. candidum* was discovered before we administered short-term steroid treatment, we think intestinal movement may have been interrupted by anti-diarrheal agents that enabled *Geotrichum* to become an opportunistic pathogen. We propose that improper use of medicine could have been the cause, at least in part, for the massive proliferation of *G. candidum*.

According to the dog's medical records and endoscopic findings, IBD was considered the primary illness; however, it was unlikely, as the previous use of prednisolone did not relieve the symptoms, and, furthermore, withdrawal of steroid treatment did not exacerbate the dog's condition. In contrast, the remission of clinical signs was associated with the removal of *Geotrichum candidum*, a sign of good responsiveness to anti-fungal medication. Based on the evidence at hand, abnormal fungal proliferation was the major factor that deteriorated the dog's normal intestinal barrier and caused an invasive infection.

Nystatine given as an oral suspension effectively treated gorillas with watery diarrhea associated with isolation of *G. candidum* from fecal wet mounts (8). Successful treatment with amphotericin B and voriconazole in humans has been reported (9). Nevertheless, disseminated geotrichosis in dogs was reported to be not curable (1,3). The present case report is the first to describe canine intestinal geotrichosis successfully cured using ketoconazole. The favorable outcome of the presented case indicates that ketoconazole treatment may be useful in similar cases.

## Acknowledgements

We thank Professor Min-Liang Wong (Department of Veterinary Medicine, National Chung-Hsing University, Taichung, Taiwan) for carefully reviewing the manuscript.

## References

1. Rhyan, J.C., Stackhouse, L.L., Davis, E.G.: Disseminated geotrichosis in two dogs. *J. Am. Vet. Med. Assoc.*, 1990; 197: 358-360.
2. Reppas, G.P., Snoeck, T.D.: Cutaneous geotrichosis in a dog. *Aust. Vet. J.*, 1999; 77: 567-569.
3. Lincoln, S.D., Adcock, J.L.: Disseminated geotrichosis in a dog. *Vet. Pathol.*, 1968; 5: 282-289.
4. Pal, M.: Role of *Geotrichum candidum* in canine oral ulcers. *Rev. Iberoam. Micol.*, 2005; 22: 183.
5. Girmenia, C., Pagano, L., Martino, B., D'Antonio, D., Fanci, R., Specchia, G., Melillo, L., Buelli, M., Pizzarelli, G., Venditti, M., Martino, P.: Invasive infections caused by *Trichosporon* species and *Geotrichum capitatum* in patients with hematological malignancies: a retrospective multicenter study from Italy and review of the literature. *J. Clin. Microbiol.*, 2005; 43: 1818-1828.
6. Mahapatra, A.: Coinfection of *Cryptosporidium* and *Geotrichum* in a case of AIDS. *Indian. J. Pathol. Microbiol.*, 2005; 48: 25-27.

7. Chretien, J.H., Garagusi, V.F.: Current management of fungal enteritis. *Med. Clin. North Am.*, 1982; 66: 675-687.
8. Dolensek, E.P., Napolitano, R.L., Kazimiroff, J.: Gastrointestinal geotrichosis in six adult gorillas. *J. Am. Vet. Med. Assoc.*, 1977; 171: 975-976.
9. Sfakianakis, A., Krasagakis, K., Stefanidou, M., Maraki, S., Koutsopoulos, A., Kofteridis, D., Samonis, G., Tosca, A.: Invasive cutaneous infection with *Geotrichum candidum*: sequential treatment with amphotericin B and voriconazole. *Med. Mycol.*, 2007; 45: 81-84.