



Restorative Dentistry

Principles of cavity preparation class I

LEC.5

performed

by

Dr : Rusul Al Saray

Cavity preparation : is the mechanical alteration of a defective or injured tooth in order to placement of restorative materials, re-establish normal form and function & esthetic corrections

Conventional preparations : preparation for amalgam, cast metal that require specific wall form, depth and marginal forms because of the properties of the restorative materials

Modified preparation : for composite restorations may require only the removal of the defect without specific uniform depths, wall designs, retentive features or , marginal forms

Objectives of Cavity preparation

- 1- Remove all defects and provide necessary protection to the pulp
- 2- Extend the restoration as conservatively as possible
- 3- Form the tooth preparation so that under force of mastication, the tooth or the restoration or both will not fracture and the restoration will not be displaced
- 4- Allow for the esthetic and functional placement of a restorative material

G.V. Black's Approach to Cavity Preparation

1. Outline form
2. Resistance form
3. Retention form
4. Convenience form
5. Removal of remaining caries
6. Finish enamel walls
7. Clean cavity preparation

Tooth preparation walls

Internal wall : is the prepared surface that does not extend to the external tooth surface

External wall : is the prepared surface that extend to the external tooth surface & take the name of the tooth surface (aspect) that the wall is adjacent to it.

Axial wall : the axial wall is the internal wall parallel to the long axis of the tooth

Pulpal wall (Floor) :is the internal wall that is perpendicular to the long axis of the tooth and occlosal to the pulp

The floor (seat) (pulp and gingival floors) : is the prepared wall that is horizontal and perpendicular to the occlosal forces. The prepared to provide stabilizing seats for the restorations & distributing the stresses

Enamel wall : is that portion of a prepared external wall consisting of enamel

Dentinal wall : is that portion of a prepared external wall consisting of dentin

Tooth Preparation Angle

The junction of two or more prepared surface is referred to as angle

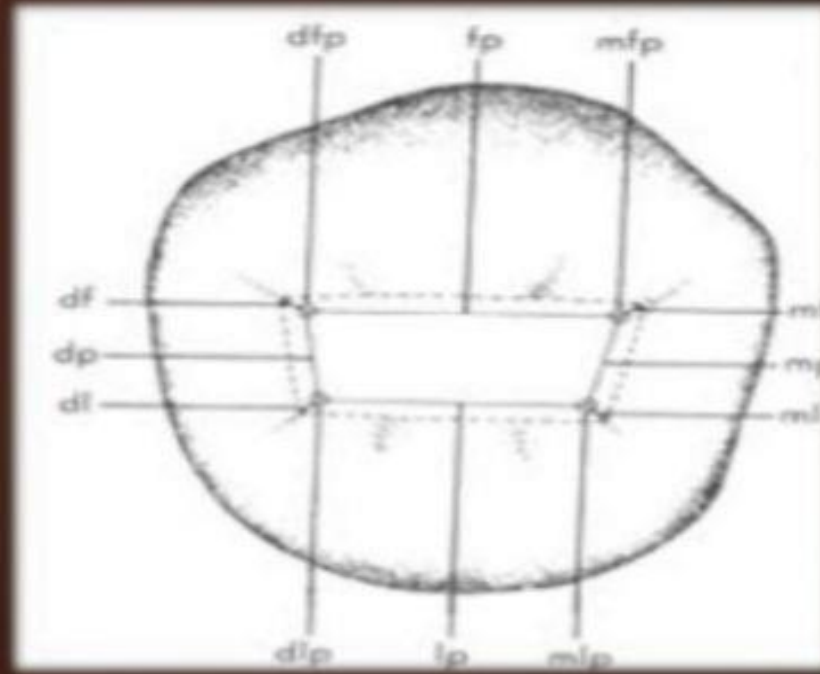
Line angle : is the junction of two surfaces of different orientation

-internal line angle : is the line angle whose apex points into the tooth

-External line angle : is the line angle whose apex points away from the tooth

Point angle : its junction of three surfaces of different orientation

- 1) Mesio buccal
- 2) Mesio lingual
- 3) Disto buccal
- 4) Disto lingual
- 5) Mesio pulpal
- 6) Disto pulpal
- 7) Bucco pulpal
- 8) Linguo pulpal



Guidebook on preclinical conservative dentistry by K.S.Karthikeyn page no38,39

11

CLASS I PREPARATION:

WALL = 5

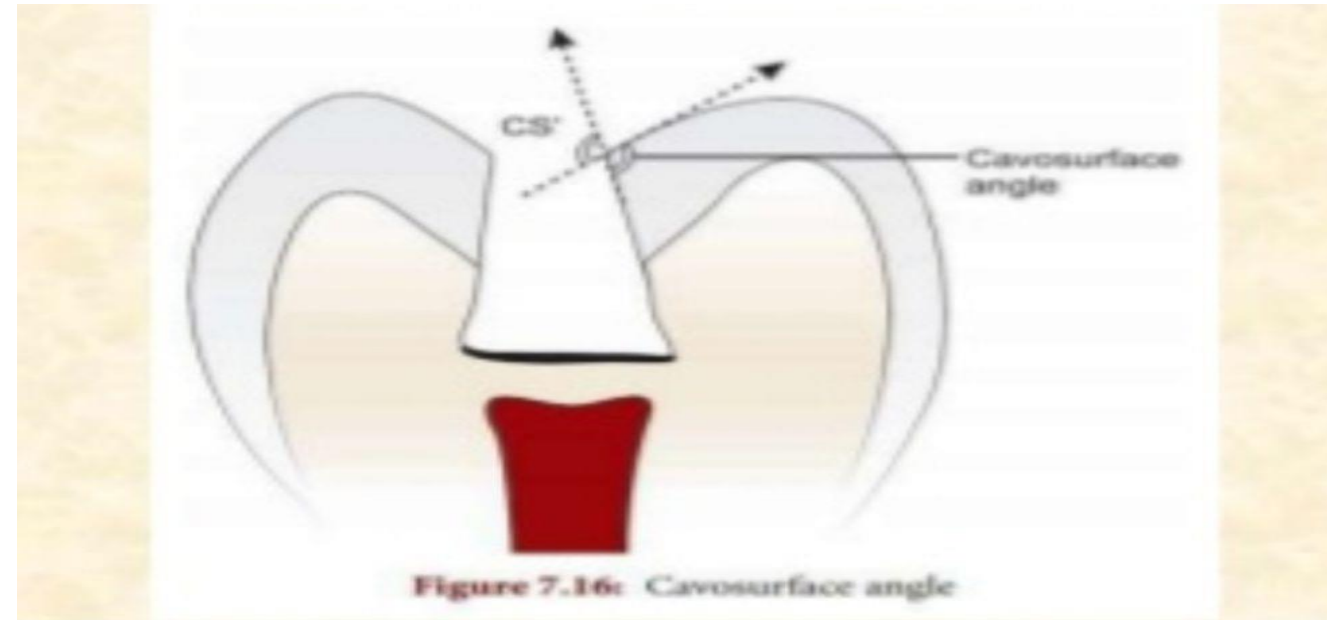
LINE ANGLE = 8

POINT ANGLE = 4

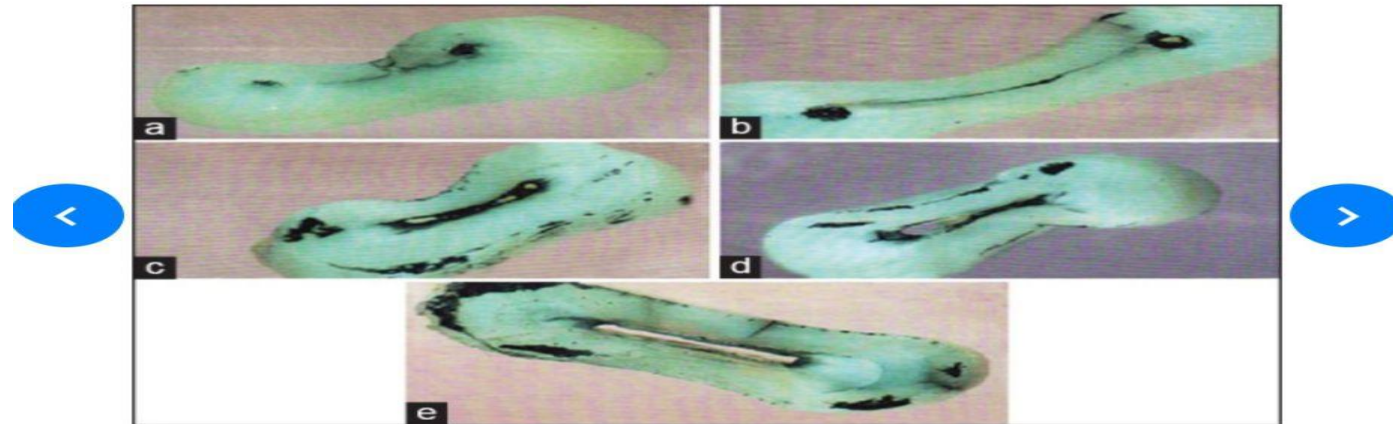
Cavosurface Angle, Cavosurface Margin & Isthmus :

-**Cavosurface angle** : is the angle of tooth structure formed by the junction of a prepared wall and the external surface of the tooth

-**Cavosurface margin** : it's the junction between the wall of the cavity and the surface of the tooth



-**Isthmus** : it is the portion of the compound and complex cavities that joining the two portion



Isthmus classifications described by Hsu and Kim:
Type I (a), type II (b), type III (c), type IV (d), type V (e)

RESISTANCE FORM

Resistance form is the design given to a cavity preparation to help prevent fracture of the restorative material and the tooth.

Resistance form is obtained by giving the cavity "box form". The factors that contribute to



Enamel Margin Strength

One of the important principle in cavity preparation is the concept of the strongest enamel margin , this margin has two significant features :

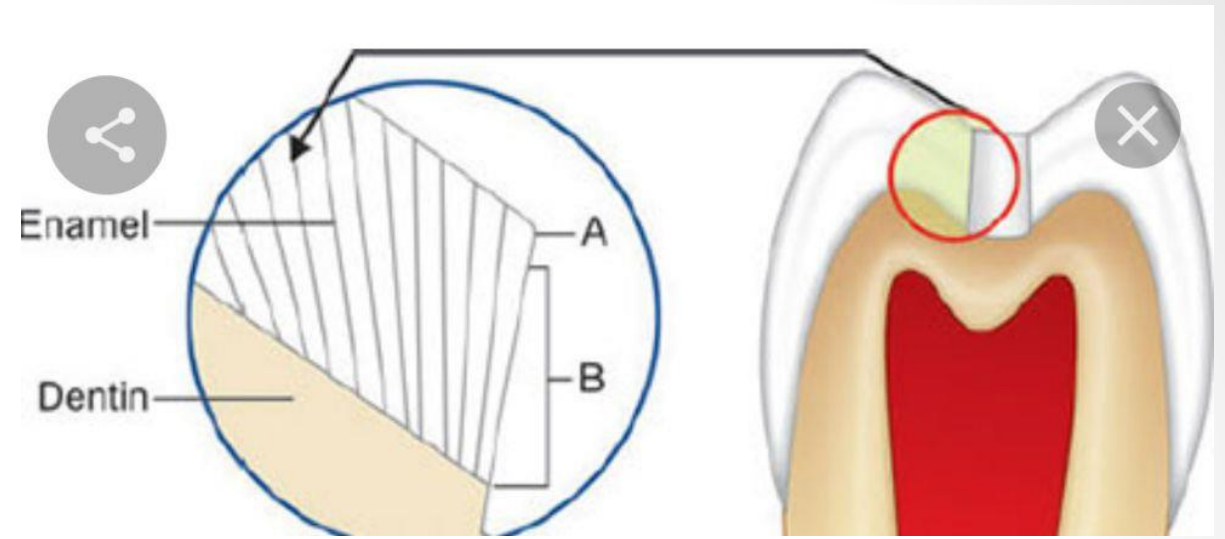
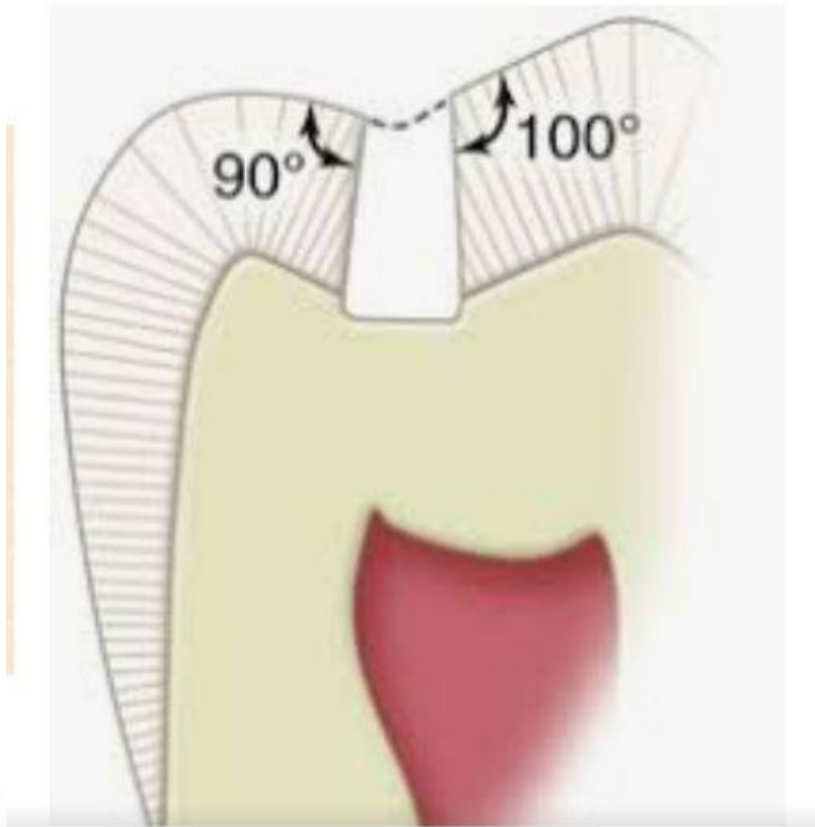1- it is formed by full –length enamel rods whose inner ends are on sound dentine

2- Enamel rods are line on the preparation side by shorter rods (outer rods) are cut off but the inner end are on sound dentine because the enamel rods are perpendicular to the enamel surface

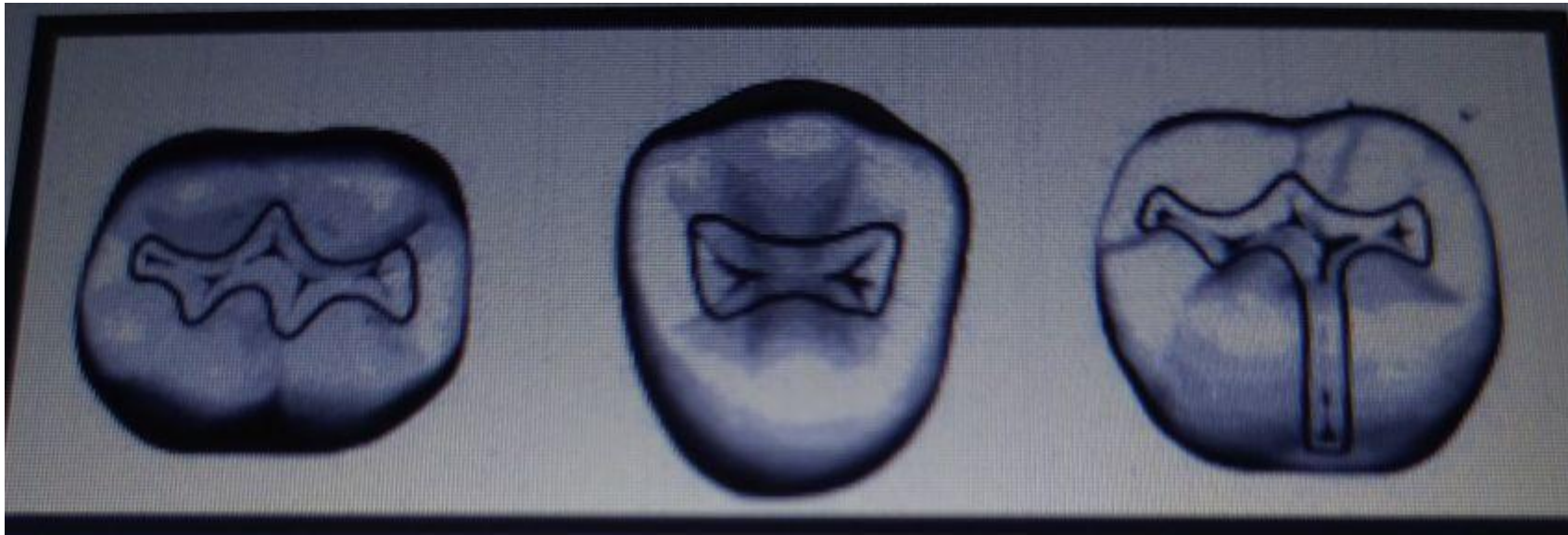
A- An enamel margin composed of full –length rods that are on sound dentin but are not lined by shorter rods also on sound dentin is termed strong . This margin results in a 90-degree cavosurface angle

B- An enamel margin composed of rods that do not rest on sound dentin is termed unsupported , this weak enamel margin either has cavosurface angle less than 90 degree or has no dentinal support

C- The strongest enamel margine results in a cavosurface angle greater than 90 degree



Retention is obtained by: 1- Flat pulpal floor
2- Dove tail
3- Convergence of buccal and lingual wall at 5 degree



Class I cavity of buccal pit of lower first molars

The lower first molar has three cusps buccally: mesiobuccal , distobuccal and distal cusp and have a buccal groove between the mesiobuccal and distobuccal cusps and has a buccal pit which is susceptible to caries , the buccal pit has a triangular shape, due to inclination of mesiobuccal and distobuccal cusps towards the buccal groove, so we should be conservative in our cavity preparation and make triangular outline form, the buccal pit located at the center of the triangle.

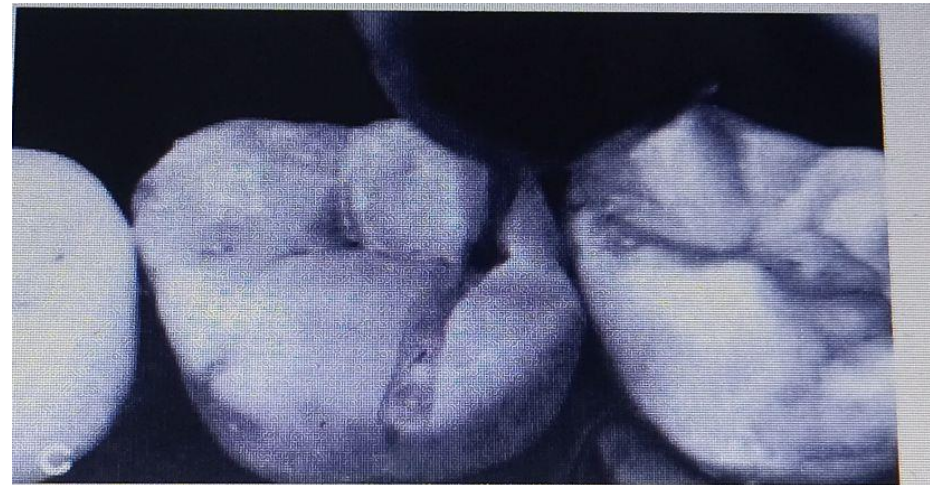Class I cavity of palatal pit of upper incisors

- There is a non coalesced pit in the palatal surface of the upper incisors , incisal to the cingulum with two small grooves radiated. The caries in this area attack this pit with the two grooves , so the cavity has triangular shape, the pit is located at the apex of triangle

Class I cavity of upper molars

The upper molars has oblique ridge from the distobuccal cusp to the mesiolingual cusp. The ridge is smooth , has a good bulk of enamel, so it is highly resistance to dental caries, we should preserve this ridge and do two separate class I cavities one mesially and other distally. (but if this oblique ridge is evolved with caries , we should included in our cavity and do one class I cavity , also if the width of the oblique ridge is very small 0.5 mm or less , it could not withstand the force of mastication so we should included in our cavity preparation).

- **Distal cavity (Distal to the oblique ridge) :** Distally there is a groove which is extend from the occlusal surface to the palatal surface and end by non coalesced pit., so caries almost extend along this groove , and our cavity preparation should be extend palatally , (applying all the principles of the cavity preparation) the entrance by small round bur than using fissure bur perpendicular to the occlusal surface to make 5 outline form extend the bur palatally at the same depth (1.5) and include the carious groove , then when the cavity is opened to the palatal surface ,



Steps of cavity preparation and restoration of class I amalgam

- 1- Administer appropriate anesthesia and place the rubber dam
- 2- Using a round bur in the high speed turbine, penetrate into the tooth parallel it in the long axis in the central pit region or in the most affected pit and fissure and extend into all susceptible fissure and pit to the depth 0,25- 0.5 mm in dentin in permanent teeth

- 3- Extend buccal and lingual grooves approximately equal to the width of the round bur and create a dovetail
- 4- Near the marginal ridges, angle the bur slightly to prepare parallel walls to avoid the undermined marginal ridges . Mesial and distal walls should be vertical in minimal preparation and slightly flared in maximum preparation
- 5- Remove all carious dentine by using a large round bur handpiece or sharp spoon excavator
- 6- smooth the enamel walls and refine the final outline form with 330 carbide bur
- 7- Rinse and dry preparation and inspect for : caries removal, sharp cavosurface margin, and removal of all unsupported enamel enamel with hand instruments as necessary

Common errors with Class I preparation

- 1- preparation not including all susceptible fissure
- 2- too deep or too shallow cavity preparation
- 3-Excessive flare of the cavosurface margins
- 4- Undermining the marginal ridge
- 5- Deep carving exposing margins of the preparation

**THANK
YOU**



Lec 6

Dr : Rusul Al Saray

Class II Cavity Preparation for Amalgam

Definition :

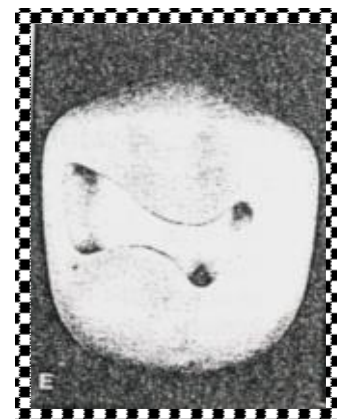
- They are smooth surface lesion that occur at the proximal surfaces of molars and premolars
- Proximal caries may be needed to x-ray for detection

These lesions are characterized by :

- 1- it is difficult to be detected until it will be considerable size
- 2- Bite-wing radiographic film is helpful for correct diagnosis
- 3- a conical spread in both enamel and dentin :
 - In enamel : cone base at the outer surface and the a apex toward the ADJ
 - In dentin : cone base at the ADJ and the apex toward the pulp
- Class II could be :
 - 1- simple mesial or distal cavity
 - 2- compound (included 2 surfaces) as mesio-occlusal or disto-occlusal
 - 3- complex (included 3 surfaces) _ as mesio-occlusal-distal

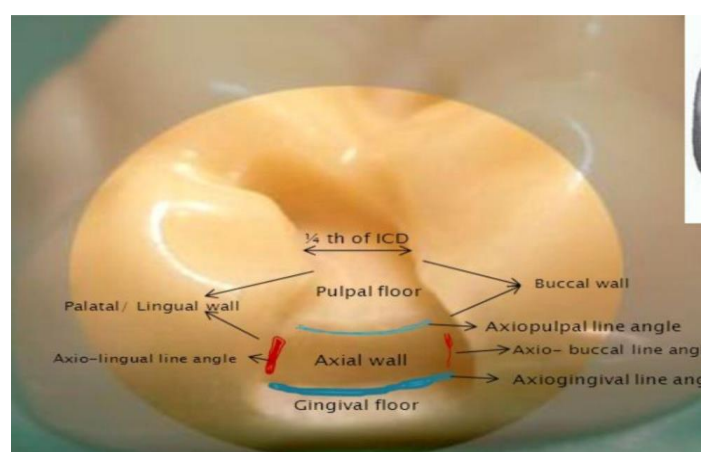
Steps of Class II cavity preparation

- First, we do class I cavity preparation on the occlusal surface applying all Black's principles of cavity preparation, because it gives vision and proximity to reach caries in the proximal contact area. Usually caries occur in the contact area, because of difficulty to clean this area by dental brush, this leads to food accumulation, and development of caries.
- One of the most important point in class II cavity is that we should not hit the adjacent tooth by rotary bur, since the proximal surface of the adjacent tooth is intact and smooth, so any cut will produce a rough surface and this facilitate food and bacterial accumulation which will cause caries to the sound tooth. To avoid this :

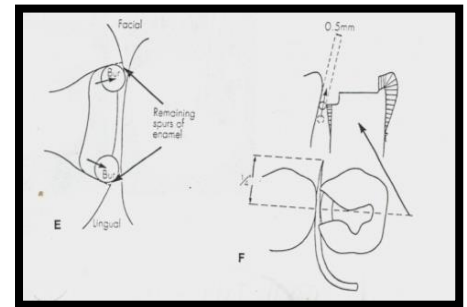


A-

- Placing a matrix band between the two adjacent teeth, place the fissure bur at the same depth of class I cavity and continue cutting towards the proximal marginal ridge until reach the end of the tooth. (the opening has the same width of the bur and same depth of class I)



- Placing the fissure bur perpendicular to the occlusal surface, and ascend gingivally to create a step and reach caries in the proximal contact area, continue cutting to remove caries and extend the base of the box just beyond the proximal contact area (0.5 mm below the contact area) so the margin of the restoration will be in cleansable area.

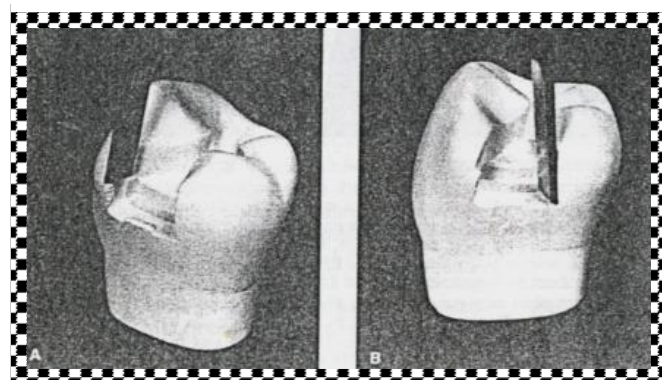
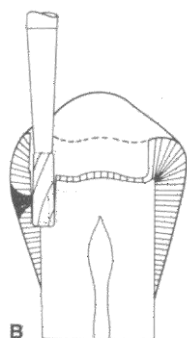


- Move the fissure bur buccolingually until the buccal wall and lingual wall will be free from the contact area to be in cleansable area.
- The contact should be opened 0.5 mm gingivally, buccally and lingually (palatally), the tip of the probe should pass freely between the two teeth.

Or

B-

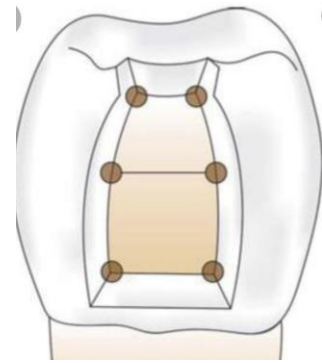
- Place the fissure bur at the same depth of class I cavity and continue cutting towards the proximal marginal ridge leaving a thin shell of marginal ridge, after that move the bur occlusogingival creating a step beyond the contact point, then move the bur buccolingually, remove the thin shell by a chisel or hatchet. Finish enamel walls by chisel or hatchet to remove any undermined enamel, and free the contact gingivally, buccally and lingually.



- At the end we will have a proximal box with the following walls:
 - axial wall: parallel with long axis of the tooth.
 - gingival seat : perpendicular to the ling axis of the tooth.
 - buccal wall
 - lingual (palatal wall)

and has the following line angles

- Axiogingival line angle
- Axiobuccal line angle
- Axiolingual (palatal) line angle
- Axiopulpal line angle



- + Line angles 11
- + Point angles 6
- + Walls 6 (facial, lingual , gingival ,pulpal Axial , distal &mesial)

1- Outline form in Class II cavity preparation

It depends on :

- 1- Extent of carious lesion proximally
- 2- location and extent of the contact area
- 3- convexity of the proximal surfaces :

More convex the proximal surface = wider the embrasures and the smaller the dimension of the contact area. So, decrease of required extension of the cavity preparation outline.

Modifying factors affecting outline form:

A- Masticatory load :

The greater the masticatory load, should be extent of the cavity preparation to reduce the surface area of the restoration subject to high loading

B- localized cariogenic factors :

Tooth position , partial denture attachment)indicates greater extent of the cavity into self-cleansable area

C- Esthetics :

Esthetics can modify the outline form by minimizing the facial extent of the cavity, especially in the mesio-facial margins of premolars and first molars

D- Tooth position :

Malaligment and rotation of teeth can be impeded or facilitate the access to proximal lesions and accordingly modify the outline form

External outline

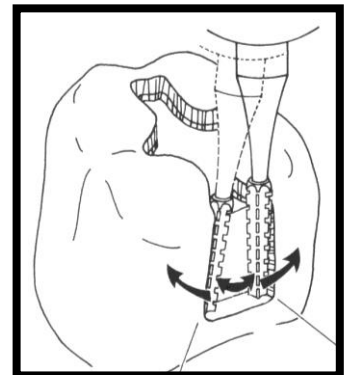
- Bucco and lingo-proximal margins are extended to include caries and to break contact with the adjacent tooth to provide convenience form
- Gingival floor is extended to include caries and break contact with adjacent tooth gingivally

Internal outline

- Axial wall should :
Be placed into dentin approximately 0.5 mm from DEJ
Follow curvature of DEJ bucco-lingually and occluso-lingually
- Proximal walls direction
Buccal and lingual walls of proximal box are parallel to the enamel rods direction and perpendicular to the tangent of the tooth surface
- Gingival floor
Parallels the enamel rod directions ; often cervically inclined, and kept parallel to the pulpal floor

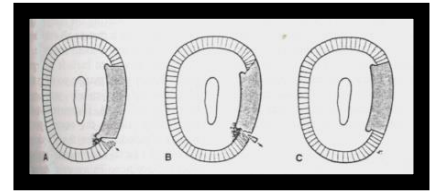
2- Retention form

1. In addition to the convergence of the buccal and lingual walls of the occlusal class I cavity, and the dovetail. We do convergence of the buccal and lingual walls of the box occlusally.
2. dislodgement of the restoration.
3. Retentive grooves: using a small fissure bur to make a retentive grooves on axiobuccal and axiolingual line angles, they should be placed in dentine because its resiliency.



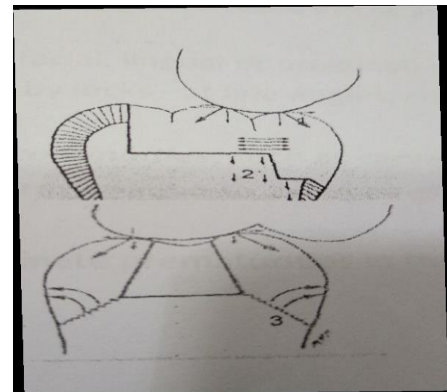
3- Resistance form

1. width of the cavity 1/4 of intercusp distance.
2. cavosurface line angle ($90^{\circ} - 110^{\circ}$).
3. Axio-pulpal line angle is beveled. To eliminate stress concentration on the restoration.
4. Gingival cavosurface line angle is beveled. To remove the unsupported enamel.
5. rounded internal line angles.
6. Removal of the unsupported enamel.



During centric and excursive movement of the mandible, different stresses applied on both the tooth and restoration :

- 1- Tensile stresses : at the isthmus portion of the restoration
- 2- compressive stresses : in the remaining tooth structure, apical to restoration
- 3- shear stresses at the junction of the surrounding tooth structure and corresponding floor with a tendency toward fracture
 - Amalgam is least resistance to tensile stress and most resistant to compressive stress
 - Tooth structure is least resistant to shear stress particularly when interrupted by a cavity preparation



Isthmus portion

Definition :

- The narrowest connection between the occlusal and proximal portions of class II cavity preparation (it is most suitable area for fracture)
- Cavity width at the isthmus portion should be kept as narrow as possible (1/4- 1/3intercuspal distance)
- The labial and lingual walls should approach the proximal tooth surface at 90 degrees (Butt joint)

The outline of the isthmus portion should allow :

- 1- Removal of all carious enamel and dentin
- 2- placing the margins at self-cleaning areas
- 3- Freeing of proximal contact area
- 4- conservation of tooth structure (1/4 intercuspal distance)

The isthmus out line shapes may be :

- **Straight:** in case of open contact
- **Uniform :** in case of normal sized contact area (narrow contact and broad embrasures)
- **Reverse curve:** in case of wide contact area and narrow embrasures (undermined of enamel), so the reverse curve is performed to achieve the Butt-joint margin and to conserve facial cusp structure

✚ When developing the mesiofacial wall perpendicular to the enamel rod direction (Butt-joint) for :

- 1- Achieved strong enamel margin
 - 2- Conserving the facial cusp structure
 - 3- Prevent metal (amalgam)display
 - 5- Allow easy application of the matrix and band
- N.B : in lingual side, the reverse curve usually is minimal because the embrasure form is large.

Steps of tooth preparation in premolar with mesial caries

- 1- local anesthesia and application of rubber dam to prevent contamination in case of pulp exposure
- 2- occlusal step same as class I starting from the aspect
- 3- proximal box preparation
 - A- Visualize the desire final location of the facial and lingual walls of the proximal box or proximal outline form relative to contact area
 - B- position of the bur over the exposed DEJ and then allow the end of the bur to cut a proximal gingivally (0.5-0.6 mm into dentin &0.2-0.3mm into enamel)
 - C- pressure is directed gingivally and lightly toward the mesial surface to keep the bur against the proximal enamel, while the bur is moved facially and lingually along DEJ then extend gingivally just beyond the caries or the proximal contact area
 - D- The amount of buccal and lingual extension depend on the amount of caries and the contact. If the caries is minimal, the extension should allow for a 0.5 mm clearance from the adjacent tooth
- 4- Removal of the weakened enamel by spoon excavator or by the bur & removal of undermined enamel by enamel hatchet to establish the proper direction to the mesolingual and mesiofacial wall and gingival floor (90-100 degree)

5 -Removal of remaining caries :

- ✚ infected carious dentin in the axial wall is removed by the suitable sized round bur or spoon excavators
- ✚ the pulpal depth of the axiofacial, axiolingual and axiokingival line angles should be never be altered because of the presence of caries in the axial wall central of these line angle

6- Finishing the external walls : the preparation walls and margins should not have unsupported enamel, then use GM trimmer to establish cavosurface bevel or (20degree) at the gingival margin in the enamel & cleaning and inspection of the cavity

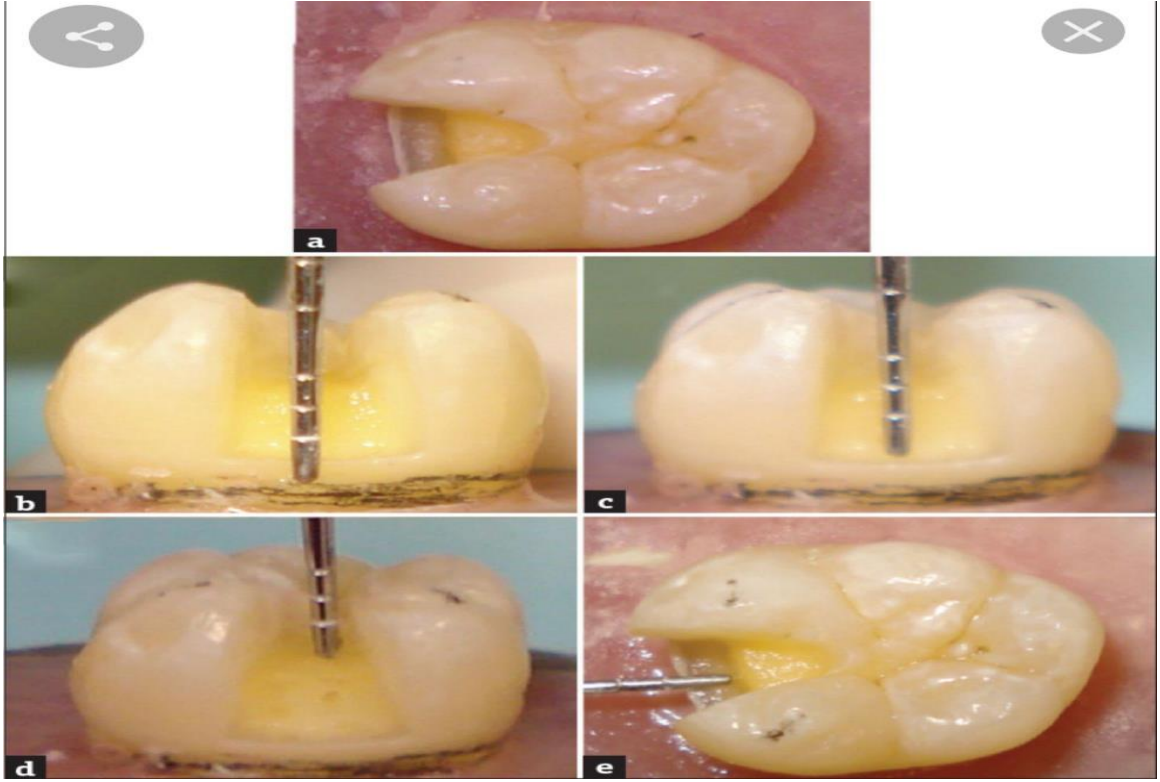
❖ **Cavosurface bevel is not indicated if :**

- When gingival margin is positioned gingival to the CEJ.
- Tooth preparation for amalgam, ideally there should be a 90 degree cavosurface angle (maximum of 100 degrees) at the proximal margin

4-Convenience form:

Achieved by:

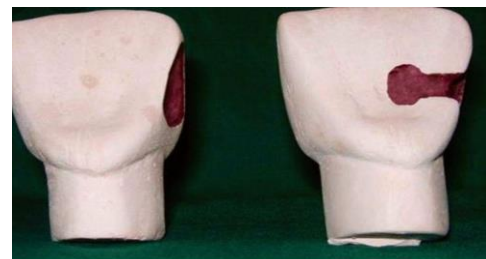- Cutting an occlusal cavity as this will improve the accessibility
- Accentuation of cavity walls and margins
- Freeing og the contact
- Selecting suitable size instruments





CLASS III CAVITY PREPARATION FOR AMAGLAM

Class III cavity is prepared when the caries occur at the proximal surface of all anterior teeth. All class III cavity should be filled with tooth colored restorative material (composite resin) except the distal surface of maxillary canine, it is better to be filled with amalgam, because the distal surface of the maxillary canine is the contact between anterior teeth and posterior teeth, and usually there is a mesial shifting of the posterior teeth, so there will be continuous force at the distal surface of the maxillary canine, if it is filled with composite, this cause wear of composite with time and decrease the mesiodistal width of canine, so it is better to fill it with amalgam because of higher wear resistance of amalgam compared with composite.



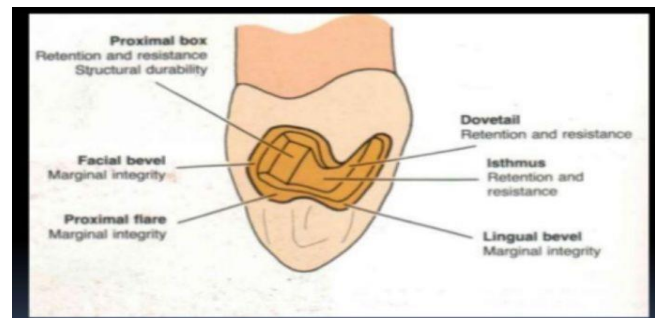
Contraindications :

Class III amalgam restoration are contraindication esthetically important area because most of patients object to metal restorations that are visible especially the proximal surface of incisors and the mesial surface of canines

Advantages :

- 1- Amalgam restorations are stronger than other Class III direct restorations
- 2- They are generally easier to place
- 3- Less expensive to the patient
- 4- Amalgam restorations are usually easier to finish and polish without damage to adjacent surface

- ✚ Caries usually occur at the contact area of upper canine, the access to the cavity is from the lingual surface, never do access to the cavity from the labial surface because of esthetic purposes, only if the caries is extended to the labial surface, we can make access from the labial surface



- ✚ Placing the bur on the distal marginal ridge at the contact area and do entry, then use the fissure bur moving it gingivally and labially and incisally creating the outline form removing all caries lesion.

- ✚ The contact with the adjacent tooth should be opened to be in a cleansable area.



The gingival wall should be perpendicular to the long axis of the tooth, the axial wall should be parallel to the long axis of the tooth, to have good vision and good access to the cavity (convenience form).



Remove any unsupported enamel.



Cavosurface line angle (90-100).

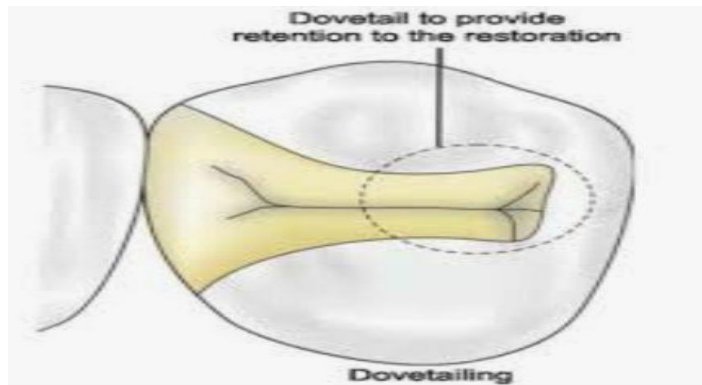
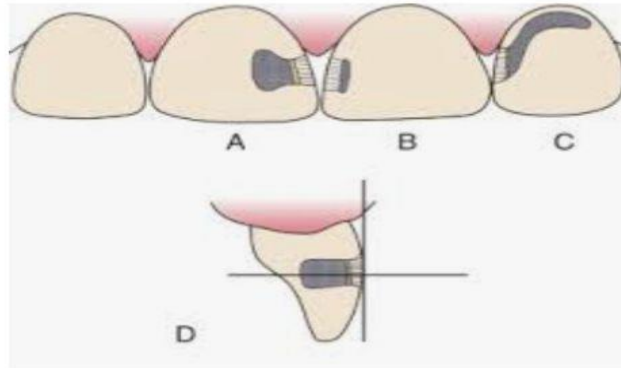
Retention form

- Flat gingival wall and should be perpendicular to the long axis of the tooth.
- Lingual access area should be minimal.
- Lingual inclination of the incisal third of the labial wall
- Labial and lingual walls are parallel as much as possible to prevent displacement of the filling material.
- Retention grooves axioincisally and axiogingivally.
- Dovetail on the lingual surface.

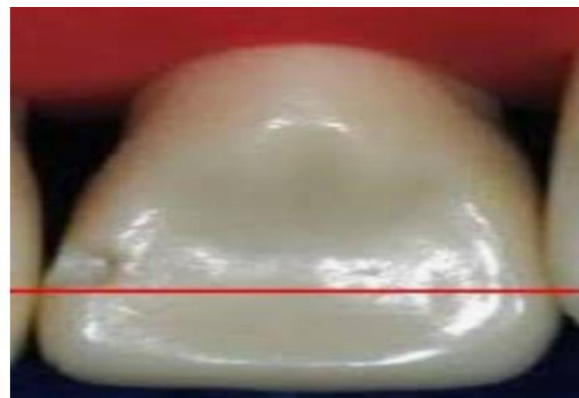
If we have extensive caries and large class III cavity and previous retentive means is not enough, so we do dovetail on the lingual surface of maxillary canine as following :

1- the lingual dovetail should be conservative not extending beyond the mesio-distal midpoint of the lingual surface; this varies according to the extent of the proximal caries.

2- the axial depth of the dovetail should approximate 1mm



A- carious tooth



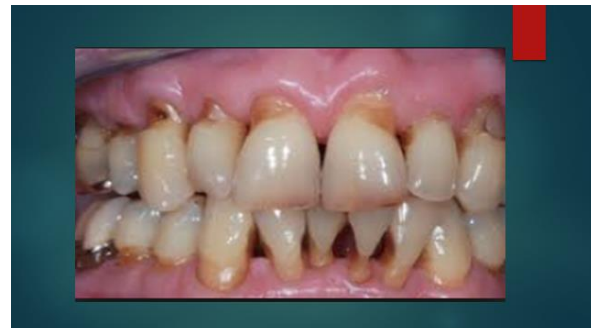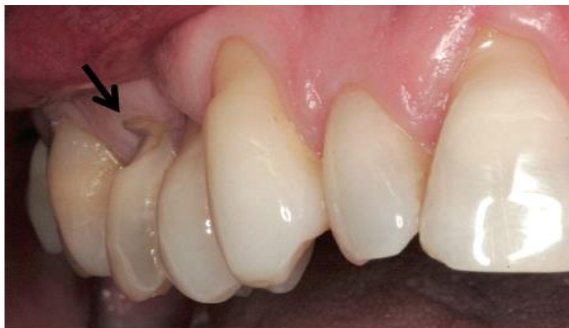B-Simple caries

CLASS V CAVITY PREPARATION FOR AMAGLAM

Indications

The selection of amalgam as a restorative material for class V cavity should involve the following considerations:

- 1- **Caries:** When the caries rate is high, the amalgam is chosen over more expensive filling materials.
- 2- **Erosion or abrasion, or both:** Erosion: tooth loss at the cervical area due to non-bacterial acid attack. Abrasion: tooth loss at the cervical area of the tooth due to abrasive slurry between two surfaces (mechanical action) e.g: tooth brush – dentifrice abrasion. In both cases there is no caries if we prepare a class V cavity it is better to be filled by amalgam, because of high abrasive resistance of amalgam.



Erosion

3- Sensitive areas at, or apical to, the cement enamel junction :

Because of gingival recession or periodontal surgery or both the cementum may be extremely sensitive, when the method of desensitizing the area is failed, so a class v cavity preparation is necessary.

4- Esthetics: Class V cavity for all anterior teeth should be filled by tooth colored restorative materials, because the metallic color of amalgam does not match the color of tooth. While for posterior, it is less visible, usually, the class V amalgam fillings at the buccal surface of mandibular premolar and molar are not visible; whereas those at maxillary premolars and first molar are more visible. .

5- Abutment teeth for removable partial dentures: Amalgam is chosen over a tooth colored restorative material when placed on abutment teeth for partial dentures because it is better to be contoured and less wear will occur as a clasps move on the restoration.

6- Economics: The patient's economic situation may influence the selection of restorative materials such that the amalgam may be chosen over more expensive materials.

Isolation:

Moisture in the form of saliva, gingival sulcus fluid or gingival hemorrhage must be excluded during caries removal, cementation, and filling procedure because: 1- It may contaminate the pulp during caries removal especially with pulp exposure. 2- Negatively affect the physical properties of the cement and filling material. So isolation is important during class V cavity preparation because sometimes the caries may extend subgingivally and should extend the margin of the restoration subgingivally, so we do isolation to protect the gingiva and provide access while eliminating seepage of secular fluid into the cavity preparation or restorative material.

Isolation done by:

1- Cotton roll 2- Retraction cord 3- Rubber dam

- Outline form :

Using round bur to start entry to the cavity, the direction of the bur should be perpendicular to the buccal (or palatal) surface of the tooth, then using the fissure bur to do the outline form, just remove the caries and the margins should be in sound tooth structure, there is no need to "extension for prevention" the shape of class V cavity is trapezoidal in shape or could be kidney shaped to be more conservative.

- **Resistance form** : Depth of the cavity is 1.5 mm : the axial wall of the cavity should not be flat, if we do so will not have even depth of the cavity because of convexity of tooth structure, so the axial wall should be slightly convex.

- Cavosurface line angle (90-100). - Rounded internal line angles -
Removal of unsupported enamel

Mesial and distal walls should be slightly diverge

- Occlusal and gingival walls should be perpendicular to the long axis of the tooth and parallel to each other, any convergence of these walls will create unsupported enamel.

• **Retention form**

I- Retention mean in class V cavity is made by making retention grooves or retention holes. This depend on the size of cavity , in small conservative cavity , retention holes is made , while in large class V cavity , retention grooves are necessary.

II- In case of more extensive class V cavity we may need to (pins) as extra retention.

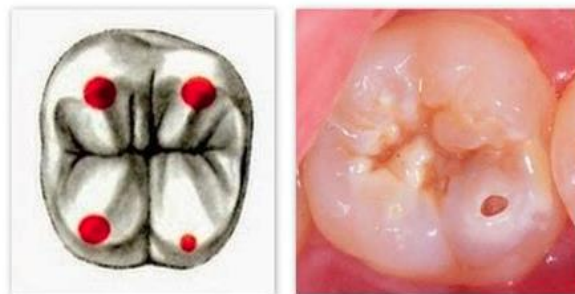
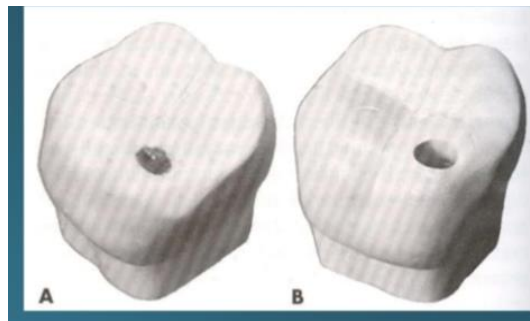
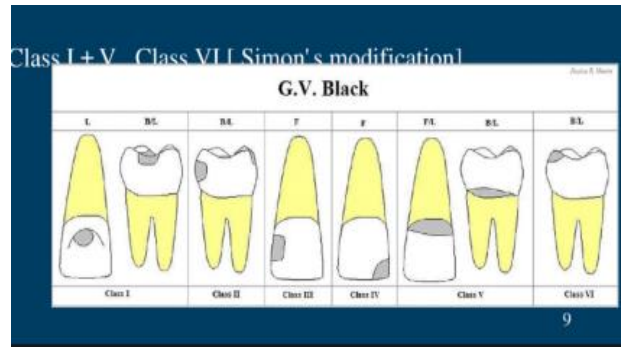
Position of the retentive means: Best position is axioocclusal and axiokingival line angles.

Method of placement :

1- Retention holes: using a small round bur (no. 1/4) and make two holes at axioocclusal line angle and two holes at axiokingival line angle.

2- Retention grooves: using a small round bur (no. 1/4) making two holes at axioocclusal line angle then connecting between them by small round bur or by small fissure bur, holding the bur in oblique direction. Same thing is done on axiokingival line angle.

Class IV cavity preparation



Class VI Lesions

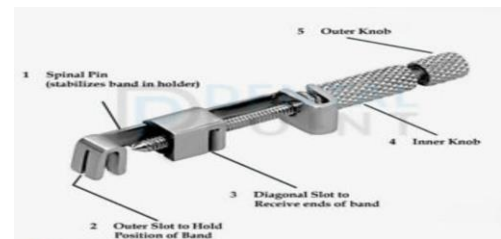
Matrix band and retainer:

- The function of the matrix band:

- 1- To retain the amalgam in the cavity during condensation.
- 2- To permit close adaptation of the amalgam to cervical and axial margins.
- 3- To help to restore the contact area and external contour of the crown.

Matrices are of 3 types:

1)-The band encircles the tooth and is secured by a retainer (universal matrix) indicated when we have 3 surfaces (MOD)



2 -surfaces class II. Positioned from buccal. Band has different shapes: straight, curved, and contoured. The chief advantage of this type is that it can be firmly adapted to the tooth.



2) The band encircles $\frac{3}{4}$ (three- quarters) of the crown and is retained by retainer no.1 into the free embrasure. Indicated when the contact points are so tight that it is difficult to place the other types.

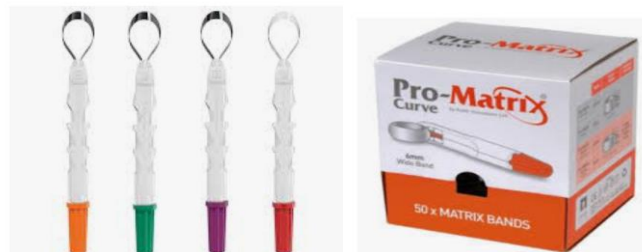

3) In the third type only a matrix band is used without a retainer. Indicated in badly broken teeth, patient with gagging reflex.

A- Sectional bands



B- Disposable bands



The band should be:-

- 1- Strong, smooth, establishes proper anatomical contour.
- 2- Restoration of correct proximal contact relation.
- 3- Easy for insertion and removal.

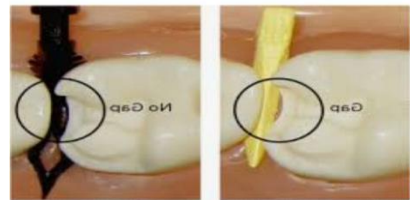
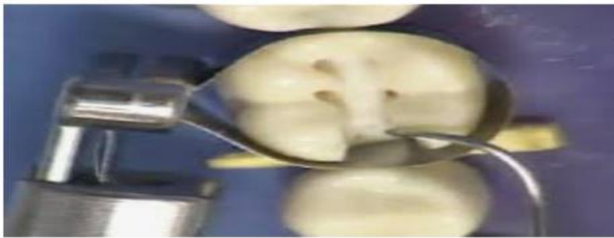
Wedge

Objectives:-

- 1) To hold the band tightly against the gingival margin of restoration (excess contour of the cervical area)
- 2) To prevent over hang amalgam.
- 3) To provide sufficient separation of the teeth to compensate for thickness of the band material. the effective force of the wedge is horizontally directed to the cervical edge of the band, so when the wedge is forcefully driven into place resulting in separation of the approximate teeth, such temporary tooth movement will make up for the thickness of the matrix band material.

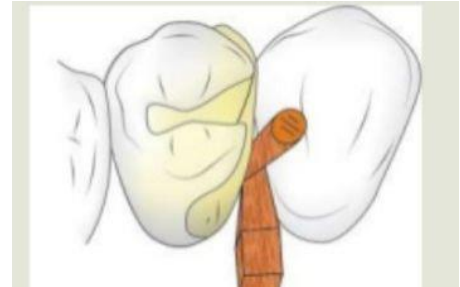


-The wedge should be positioned as near as to the gingival margin (just beneath to the gingival margin). If the wedge positioned: *Occlusal to gingival margin, the band will be pressed into the preparation creating an abnormal concavity. *As far as apical to margin, the band will not be held tightly against the gingival margin result in gingival excess (over hang).



-If the wedge significantly apical of the gingival margin, a second smaller wedge placed on the first one to wedge adequately the matrix against the margin (in case of recession of inter proximal tissue level).

- Occasionally a double- wedging is permitted if access allows, securing the matrix when the proximal box is wide facio-lingually. One from lingual side and the second from facial embrasure.



-The wedge is either triangular or round. The triangular can be modified (by knife) to conform the approximating tooth contours. It's recommended for the deep gingival margin, because the base of the wedge will more readily engage enough tooth gingival to the margin without causing excessive soft tissue displacement. The round is preferred with conservative proximal boxes because its wedging action is more occlusal (near the gingival margin) without impinging the soft tissue. Before inserting the amalgam, A final check should be made for the following points:

- 1) Is the matrix system stable (by wedge...)
- 2) Does it fit the cervical margin? It should not possible to insert a probe between the cervical margin and the band.
- 3) Is the height of the band sufficient (1-2 mm above the adjacent tooth, any attempt to remove the band before the reduction of the marginal ridge to its approximate height by contouring its outer incline is an invitation to marginal ridge fracture.
- 4) Is the cavity clean and dry? *Contamination with saliva increases leakage of the restoration. Zinc- containing amalgam expands excessively if contaminated by moisture when they are condensed. Zinc react with water to produce hydrogen gas. The hydrogen gas causes the amalgam restoration to expand, seeming to push out of the preparation.

Liners and Bases

Definition:

Its intermediate material placed between the restoration and dentine /pulp ; that have protection or isolation and therapeutically action on the pulp

Liners: these are material that are applied in a thin layers (< 0.5 mm) under restoration . Used primarily to achieve a physical barrier to bacteria and their products and /or to provide a therapeutic effect, such as anti-bacterial or pulpal sedative effect. Liners are usually applied only to dentin cavity walls that are near the pulp.

Bases (cement bases 1-2 mm):

-These material have significant strength properties to be applied in relatively thick layers usually 1-2 mm, Material are used to provide thermal protection for the pulp and to supplement mechanical support for the restoration by distributing local stresses from the restoration across the underlying dentin surface.

-This mechanical support provides resistance against disruption of thin dentin over the pulp during amalgam condensation procedures or cementation procedures. Some base materials are irritating to the pulp before the setting reaction has completed, such a base may be used in conjunction with a liner.

The properties of an ideal lining material:

- 1) It should be easy to supply.
- 2) The strength should be enough to withstand the condensation forces.
- 3) It should not irritate the pulp or interfere with the setting reaction of the restoration.
- 4) Radioopaque.
- 5) It should have a bacteriostatic effect, must have adequate working time and well adapted to the cavity walls.
- 6) Has pharmacological action or sedation effect
- 7) Reduce thermal conductivity of the restoration.

Indications of cavity bases and liners :

- 1- Chemical protection : Against some ingredients of restorations that may be noxious to the dentin-pulp organ, such as residual monomers of composite, acidic components of zinc phosphate cement and metallic ions of amalgam.
- 2- the sealing ability and thermal and electric insulation that previods the sealing functions of the lost enamel
- 3- in deep cavities base and liners are used to decrease the amount of permanent restorations needed to overcome there problems such as : the case with thermal properties of metallic restorations and the high dimensional instability of resin restorations
- 4- Mechanical protection by straightening of the cavity walls without removal of sound vital dentin tissue
- 5- In extremely deep cavities may also necessitate pulp medication to stimulate dentine formation from undifferentiated mesenchymal cells
- 6- To camouflage the brownish discoloration of dentin under esthetic restorations

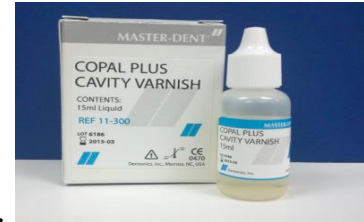Types and classsifications of base and liner materials

Solution : is completely dissolve compound (salt &water)

Suspension : is incompletely dissolve compound (sand &water)

A- Liners

Varnish sealer: It is a natural gum or a synthetic resin dissolved in a solvent such as chloroform, alcohol, acetone



Indications

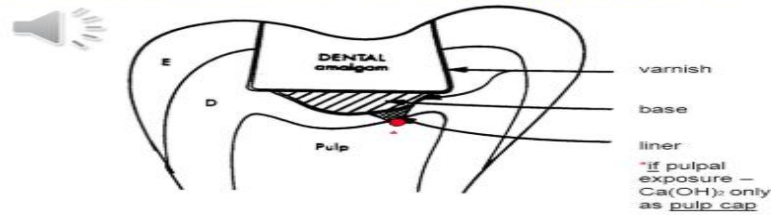
- : 1) Varnish is frequently sealing dentil tubules under amalgam restoration because they reduce significantly the leakage around the margins and walls of the restoration.
- 2) Used as barrier against the passage of irritants from cements or other restorative materials and to reduce the sensitivity of freshly cut dentin.
- 3) Is not thick enough to provide thermal insulation.

Contraindications

- 1- Under adhesive resin composite as it prevent the mechanical inter locking & react with it
- 2- Under GIC as it eliminates adhesive potential & decrease fluoride release
- 3- in very deep cavities as it causes pulpal irritation from it solvent (acetone)

Manipulation: Usually applied by means of a small round piece of cotton according to the size of the cavity, we paint the entire cavity preparation. A minimum of 2 thin films should be applied, as the initial layer dries it leaves small pinholes and the second coating fills in the voids and produces a more continuous coating.

Varnish, Liner, & Base Application



Calcium hydroxide: Has long been used as a base liner under restorative material. $\text{Ca}(\text{OH})_2$ is supplied either as a suspension type or as a paste system, one paste contains calcium hydroxide(catalyst) while the other contains salicylate(base).

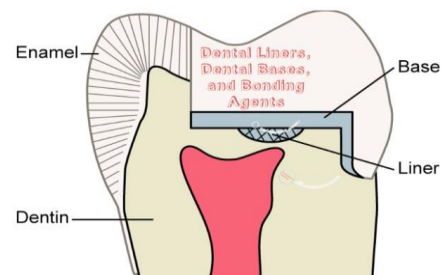
Uses: 1) They are recommended materials for direct pulp capping where the pulp exposure or indirect pulp capping where there's $\frac{1}{2}$ mm of dentin remains till pulp exposure

2) As base/ or liner under other dental restorative materials.

Types :

A- Hard setting (chemical cure) : $\text{Ca}(\text{OH})_2$

B- Light cure : $\text{Ca}(\text{OH})_2$



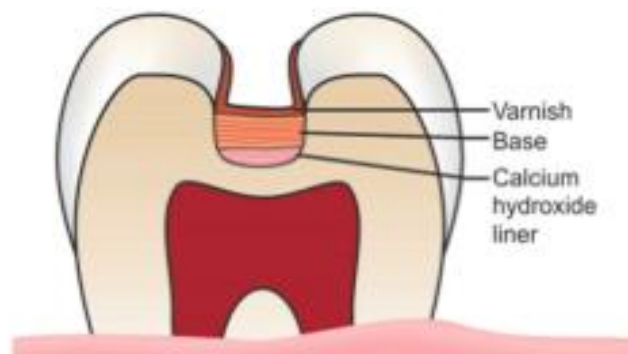
C- Low viscosity zinc oxide eugenol

D- Resin modified GI

Properties:

- 1) It has ability to stimulate reparative dentin formation with direct pulpal contact.
- 2) Serve as a protective barrier between tooth tissues and acid containing cements and restorative materials since it has high PH.
- 3) Has antibacterial action that reduces the inflammatory effects of bacteria on the pulp.
- 4) Conventional calcium hydroxide liners have demonstrated poor physical properties (high solubility, have low values of tensile and compression strength). Visible light- activated calcium hydroxide overcome most of these deficiencies.

Manipulation: Equal lengths of the different colored pastes are dispensed on a paper pad and then mixed to a uniform color with ball- point instrument; the setting time is 2-3 min. mixing time 10 sec. at room temperature. The setting reaction of $\text{Ca}(\text{OH})_2$ is accelerated by water, the moisture present in dentin is sufficient to cause the material to set within seconds of application on the dentin surface.



Zinc oxid eugenol

Form & composition : powder (zinc oxide) with liquid)(eugenol)

Function & indications

- 1- palliative and sedative effect on the pulp
- 2- Used in moderately deep cavities
- 3- Reinforced ZOE can be used as a base material

Contraindication

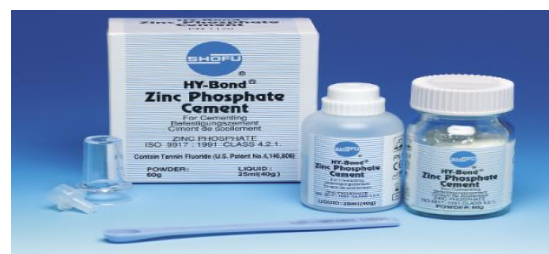- In very deep cavities as eugenol is irritant material
- With resin composite as it interfere with it setting reaction
- With glass ionomer as it prevents bonding with tooth structure

Zinc-phosphate cement (ZPC): ZPC is supplied as a powder and liquid.

- ✚ Powder: consist of zinc oxide chiefly with additions of magnesium oxide and silicon dioxide, and other minor ingredients.
- ✚ Liquid: consists of a water solution of phosphoric acid.

Properties:

- 1) Strong and has a low solubility compared to other cements.
- 2) Because the mixed cement has a low PH until it has set, ZPC is irritating to the pulp.
- 3) ZPC sets to a hard brittle material. It can withstand amalgam condensation forces and support the overlying amalgam restoration.



Indications

- 1- For luting inlays, crowns, bridges, orthodontic bands. ZPC has a long working time compared to other luting cements [1-1 1/2 min].
- 2- Used as a base material. It is acidic and the pulp may need to be protected with a liner or a varnish.
- 3- Also ZPC indicated for replacement of lost dentin.

Contraindications

- 1- Cannot be used as a liner due its acidity
- 2- When remaining dentin bridge is <0.5 mm

Mixing:

-ZPC is dispensed as scoops of powder and drops of liquid, the No. of drops and scoops of powder required are found in the directions provided by the manufacturer.

-A cement spatula and glass slab is used. The reaction is very exothermic, the heat of the reaction accelerates the setting rate so it is important to dissipate this heat by:

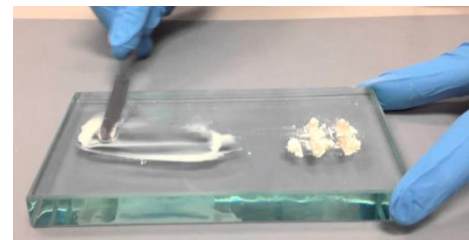
- A large portion of a cooled mixing slab (21C) must be used during mixing (cooling obtained by placing the slab under cool water or in a refrigerator). - The powder must be added in small increments.
- The mixing time must extend to 1 1/2 to 2 minutes.

- The powder is dispensed on the middle area of the slab and divided into small equal parts; the liquid is dispensed with an eyedropper on the other area of the slab. The mixing is started by adding the 1.st small increment of the powder into the liquid and continuously speculated, then the 2.nd part of the powder incorporated and so on. A primary consistency is usually attended at the end of 11

-6/2 min. Advantages of incorporating small increments of powder over a large area of the slab are: dissipating the heat of reaction, permit a greater quality of powder and smoother mix as well as longer working time and less acidity.



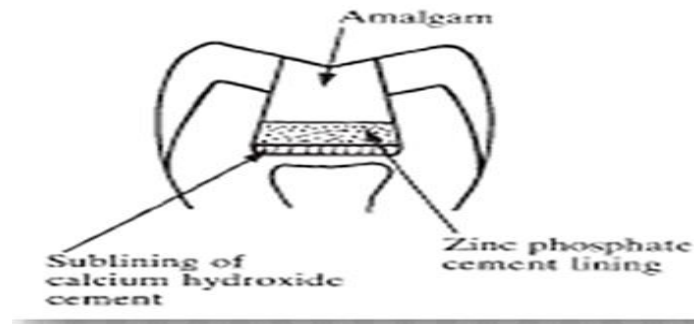
- ZPC is mixed to the proper consistency depending on the clinical use. The mix is thinner (lower P/L ratio) when used for luting, and thicker consistency (higher P/Lratio) used as a base.



- Insertion: a small quantity of cement is picked up on the point of a rightangled probe (lightly rolled into a ball with fingers) replaced on the floor of the cavity. Then it's tapped with an instrument, covered with powder of cement to prevent the cement from sticking to the instrument. The cement then shaped with instrument such as Ash. For class II the cement is pressed against the axial wall, pulpal floor and the axiopulpal line angle



- Any trimming with bur should be delayed until complete setting of the cement to avoid dislodgment and should be carried out with sharp bur and low speed and minimum pressure. The same technique applied to class V cavities.



Zinc polycarboxylate cement

Form & composition : powder (zinc oxide)& liquid (polyacrylic acid)

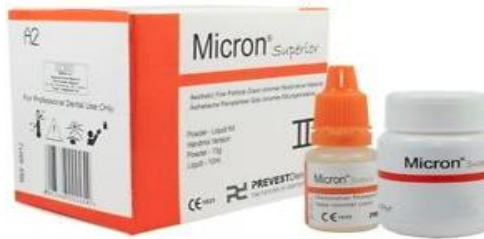Properties:

- Bond chemically to tooth structure ,so it decreases microleakage
- Provided minimal irritation to the pulp as it :
 - A- Its PH rises rapidly to 3.4 after two minutes of mixing
 - B- polyacrylic acid is weaker than poly phosphoric acid
 - C- Polyacrylic acid has low diffuse mobility into dentin due to large molecular size
- Compatible with all restorative material except ZOE & Varnish

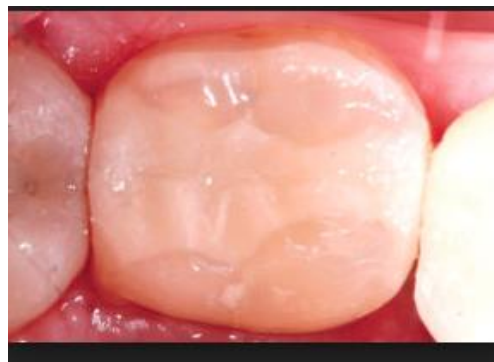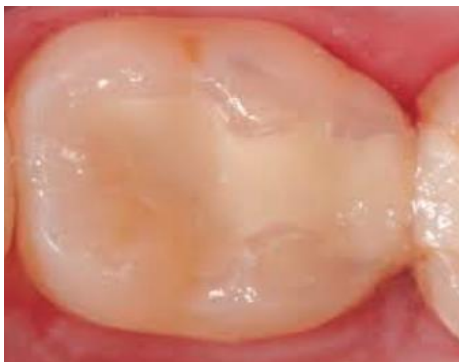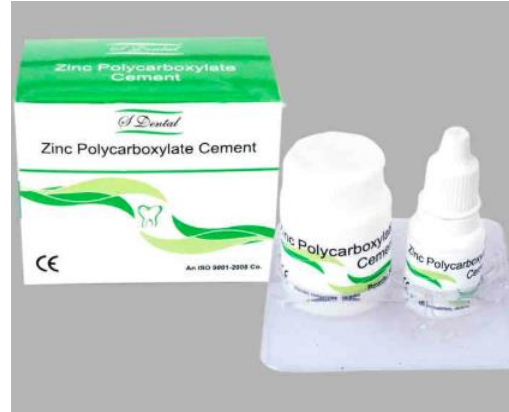Indication : Under any restorative material as a luting cement

PREVEST LABORATORIO

Micron superior



**Glass Ionomer
restorative material A2**



Conventional GI

Form :

- Powder : calcium aluminum fluoro silicate
- Liquid : poly carboxylic acid
- Reaction :
 - A- Only acid base reactions ,only chemical
 - B-As acid attacks particles, and release of calcium and aluminum ions to give polycarboxylate salt to give bulk to cement
 - C-Silica reacts with water to give hydrogen to coat the unreacted particles
 - D-As it is acid containing, it can be used in conditioning the tooth surface (etching) :
- Very low acid effect enough to make etching not demineralization
- This acid has mild acidity cause just etching, then acidic effect will be buffered by action of calcium ions in the tooth structure

Resin modified glass ionomer cement(RMGIC)

Form & composition : powder (fluoro-alumino- silicate glass)&liquid (polyacrylic acid), so it combines between light curing polymerization and then the acid base reaction

Proprieties

- ✚ Excellent sealing ability due to chemical bonding to tooth
- ✚ Anti-cariogenic effect due to fluoride release
- ✚ Biocompatible with tooth & restoration
- ✚ Excellent material to be used as dentin substitute
- ✚ Give thermal, chemical &mechanical protection

Indication :

1`- base under composite in sandwich technique to combine the benefit of adhesion and fluoride release of GI with high esthetic of composite resin &decrease the cavity depth

2- liner, base , luting cement as well as restoration material

lec 14

Operative Dentistry

Complete crown restoration

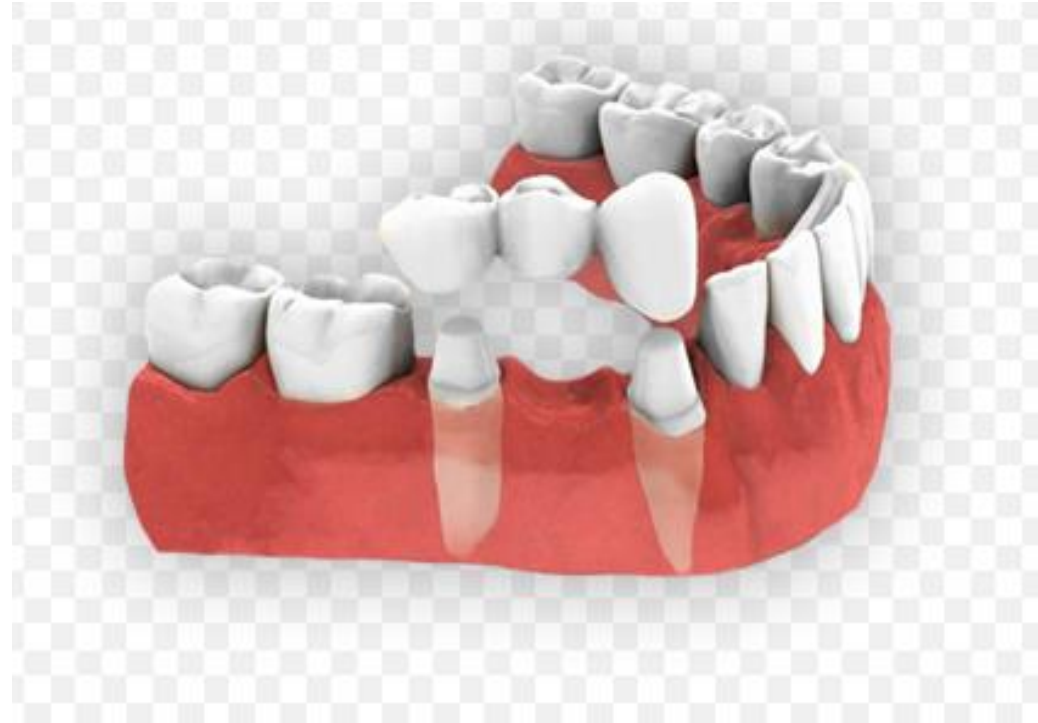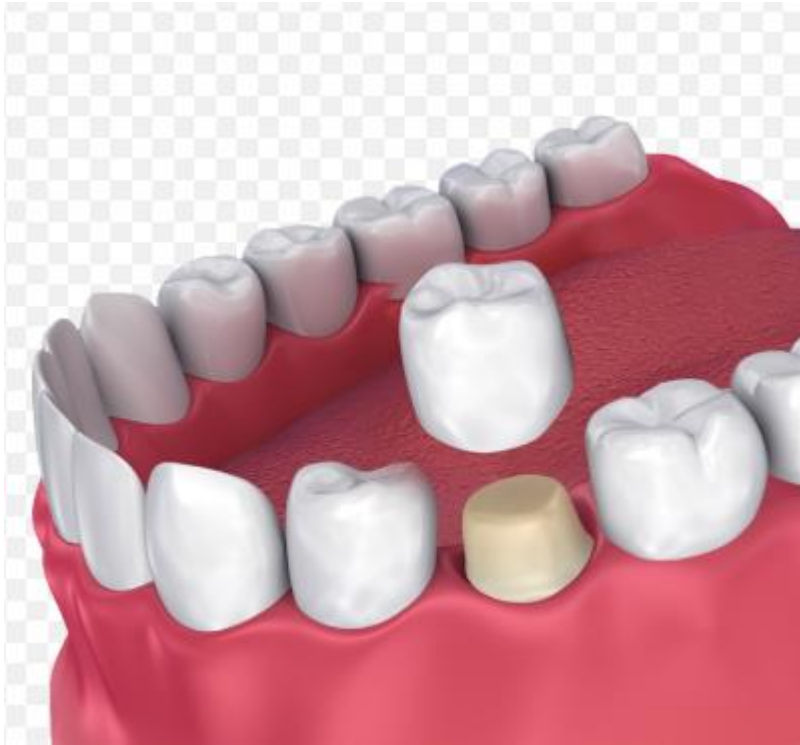by

Dr. Rusul Al-Saray

Introduction to fixed prosthodontics

- ▶ **Prosthodontics**: is the dental specialty concerned with the making of artificial replacements for missing parts of the mouth and jaw.
- ▶ **Fixed prosthodontics(crown and bridge)**:
 - ▶ its is branch of dental science that deals with restoration of damaged teeth with artificial crown and replacing the missing natural teeth by dental prosthesis permanently cemented in place .
- ▶ **Fixed prosthodontics includes**:
 - ▶ 1-inlays 2-onlays 3-veneers 4-crowns 5-
fixed partial dentures

Crown: its is fixed extra-coronal artificial restoration of the coronal portion of natural tooth, restore morphology, contour and function of the tooth and should protect the remaining tooth structure.




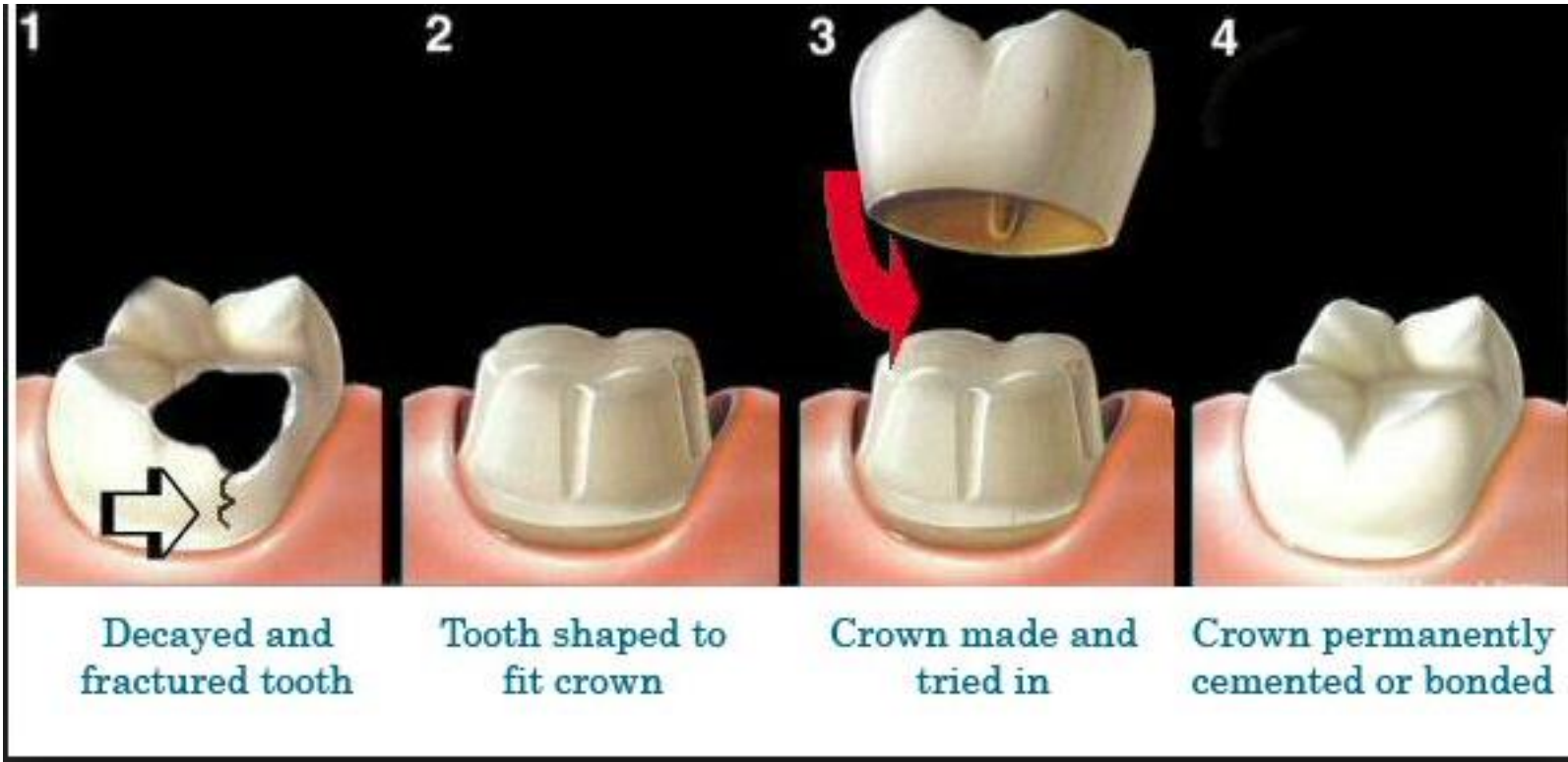
Types of crowns(classification):

1 –according to coverage area

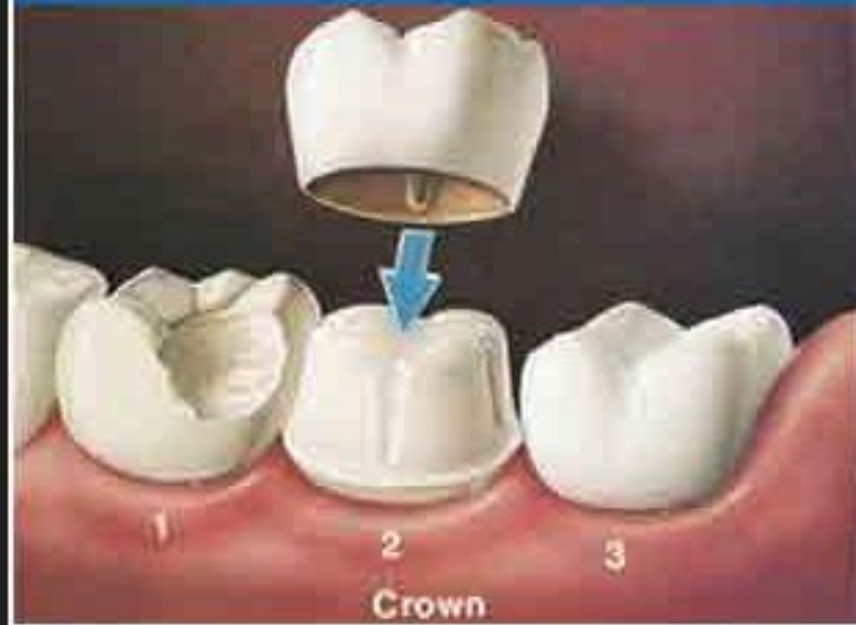
- ▶ **1- complete crowns** :it is the crown that covers all the coronal portion of the tooth such as full metal crown, porcelain fused to metal and all ceramic crown.
- ▶ **2- partial crown**: that covers part of the coronal portion of the tooth such as $\frac{3}{4}$ crown .
- ▶ **3- complete replacement**: replaces the natural crown entirely. Such as post crown.

2– according to the materials used in fabrication

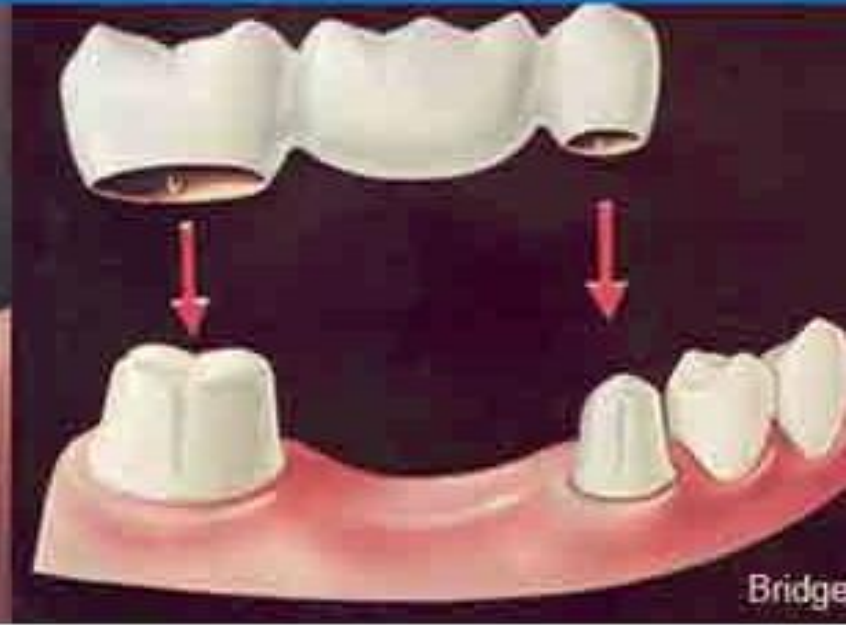
- ▶ **1– metal crown** : made from gold alloy such as full metal crown
 - ▶ **2–non–metal crown**: made from acrylic resin, zirconium or jacket crown
 - ▶ **3–combination of them**: porcelain fused to metal
- 



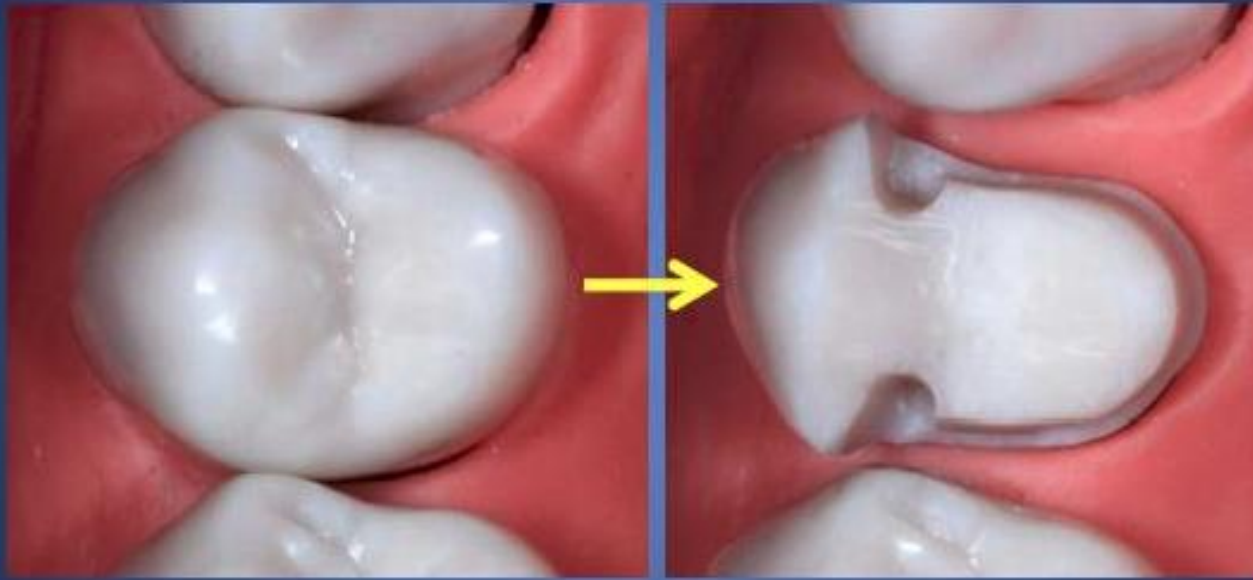
CROWN



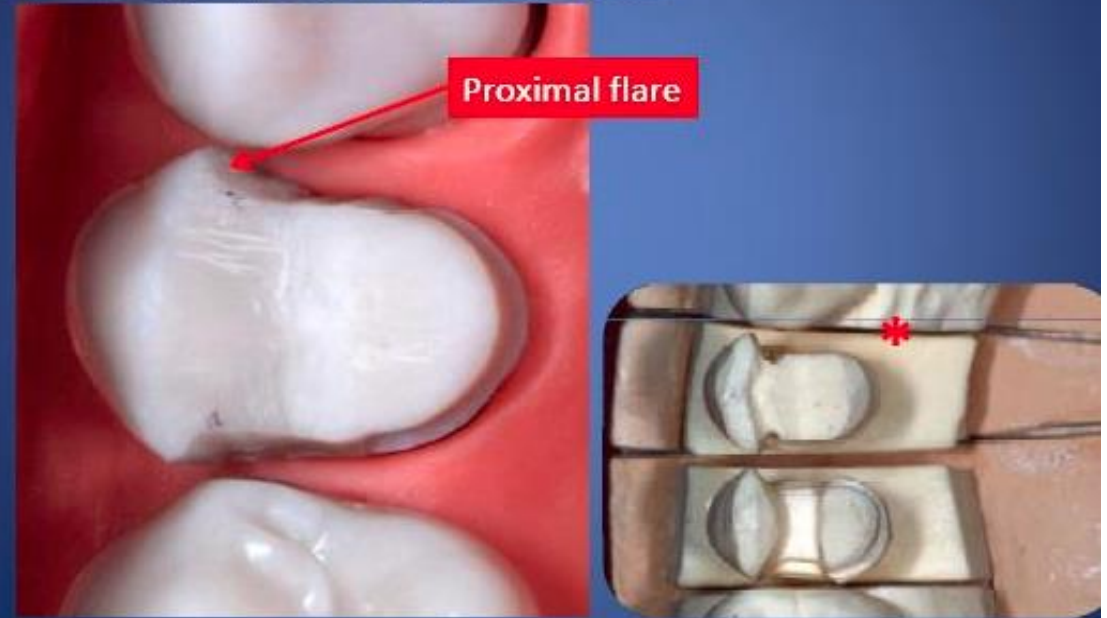BRIDGE

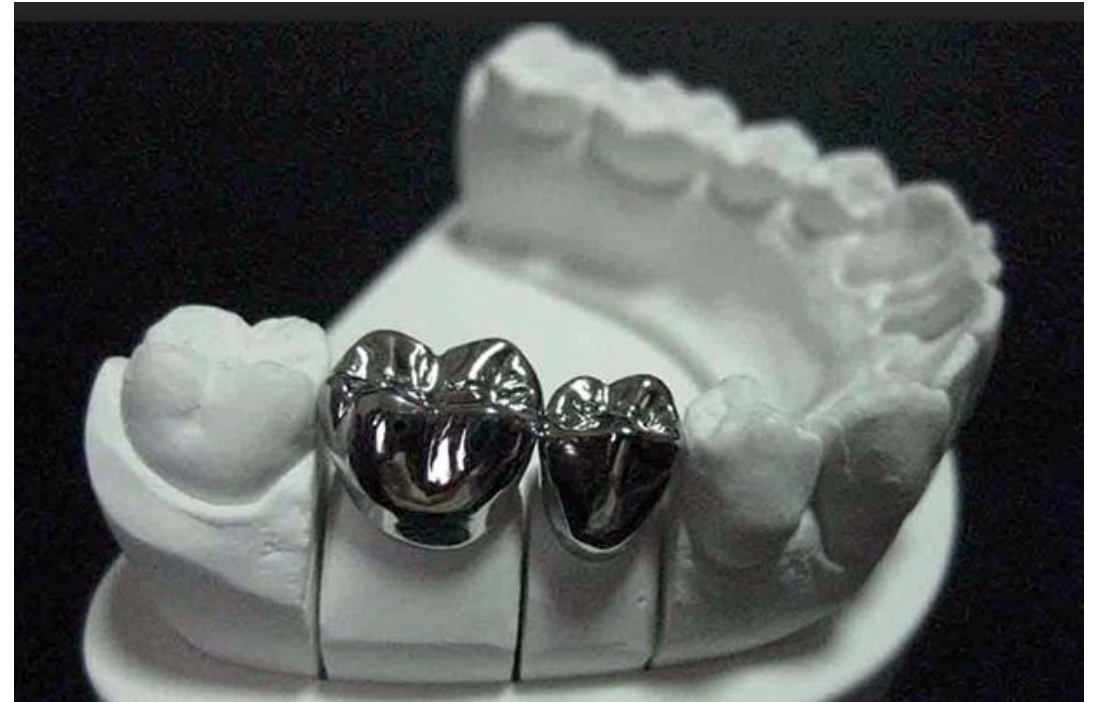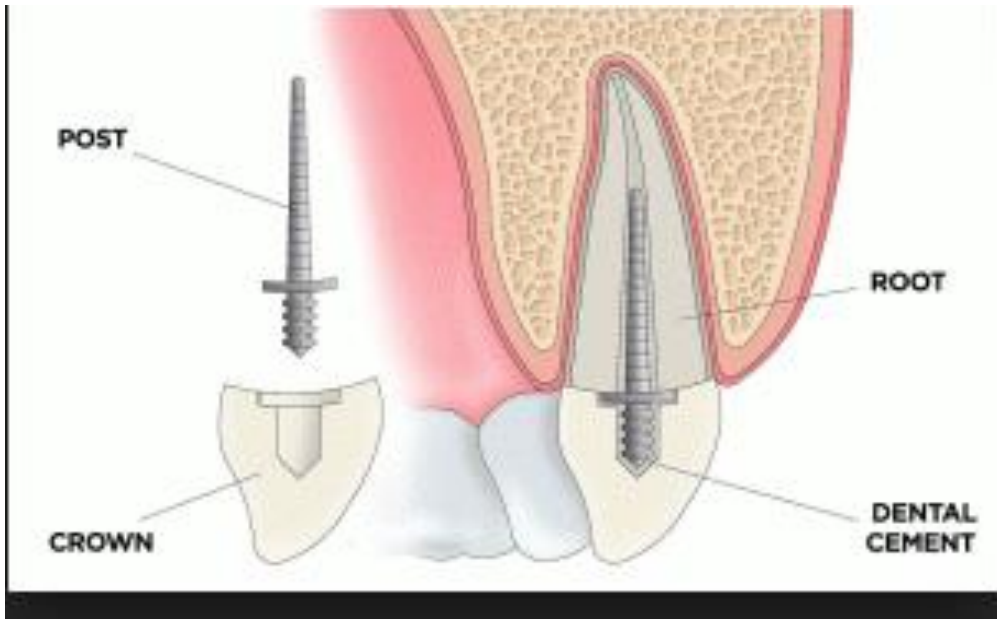


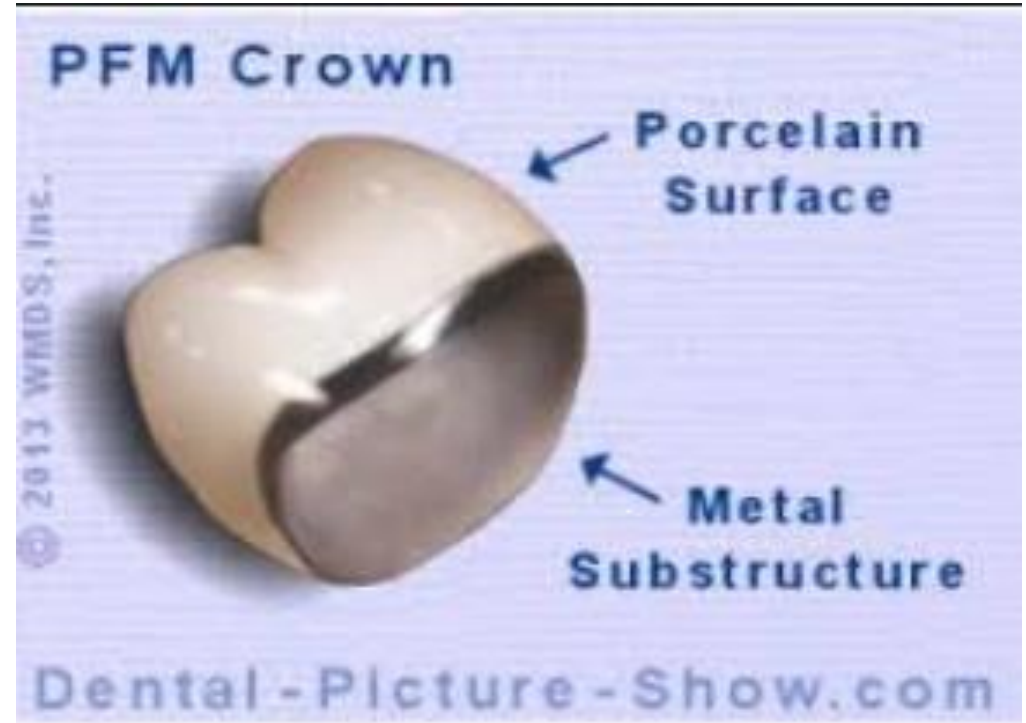¾ Preparation stages

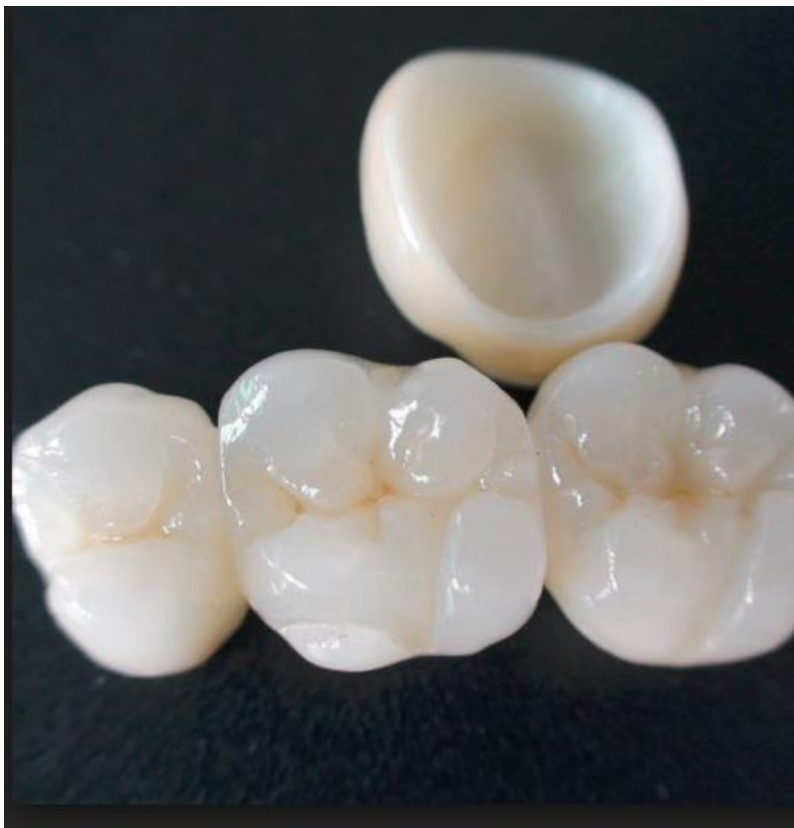

Torpedo bur and for Technician to cut the die*
Use needlepoint to develop proximal flares




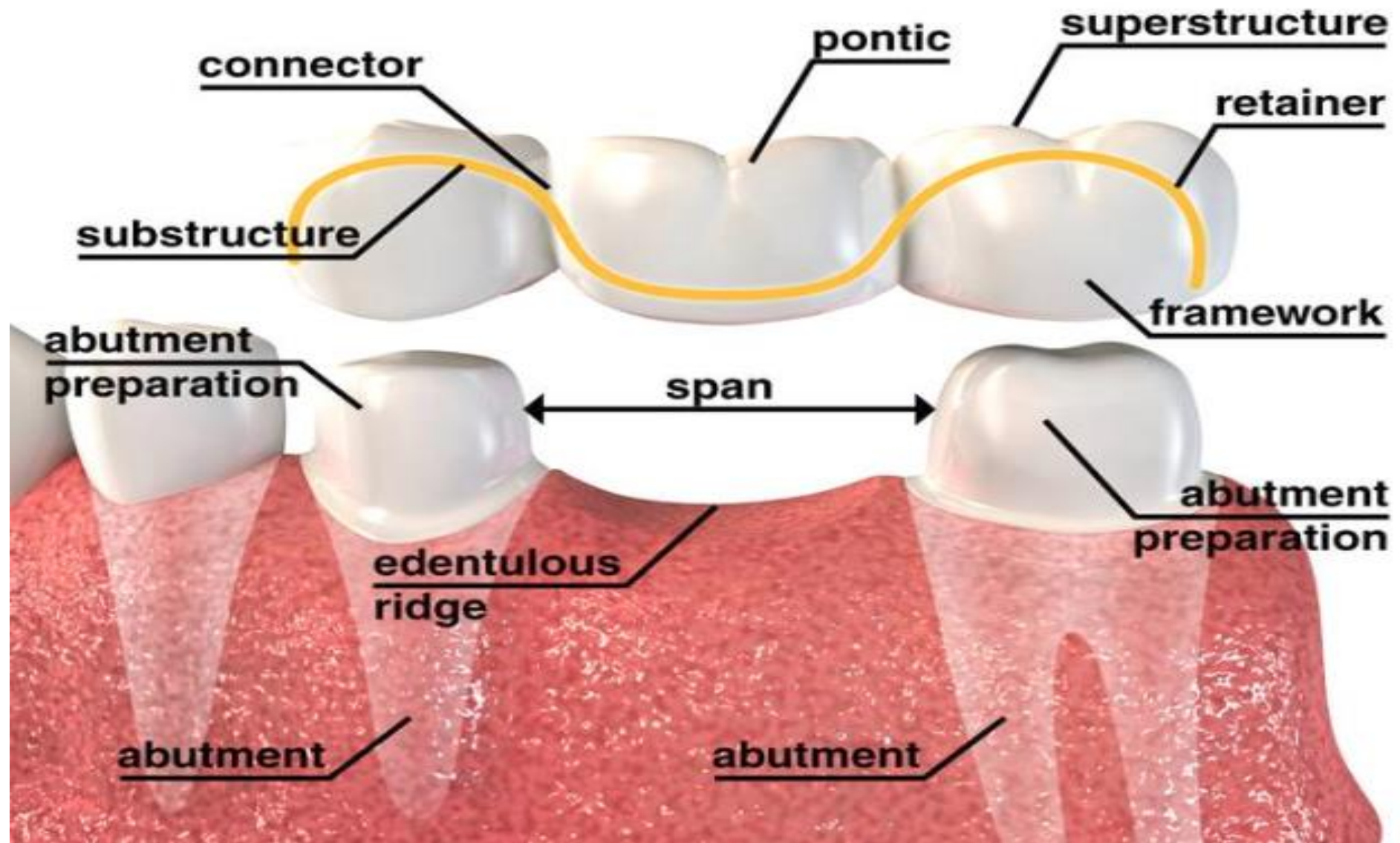






Bridge:


- ▶ It is fixed dental prosthesis which replaces and restores the function and esthetic of one or more missing natural teeth and cant removed by patient .
 - ▶ **Components of bridge:**
 - ▶ **1- retainer:** part that seats over abutment
 - ▶ **2- pontic:** its suspended member of fixed partial denture that replaces the missing tooth or teeth.
 - ▶ **3- connector:** that joins the individual components of the bridge together(retainer and pontic).
- 



Purposes of crown construction

- ▶ 1-to restore the grossly damaged tooth ,fracture tooth
- ▶ 2- to restore the masticatory function and speech
- ▶ 3-to restore the esthetic
- ▶ 4- to maintain the periodontal health by recontouring the occlusion
- ▶ 5-to alter the occlusion (occlusal relationship) as a part of occlusal reconstruction to solve occlusal problems.

Steps in construction of cast restorations

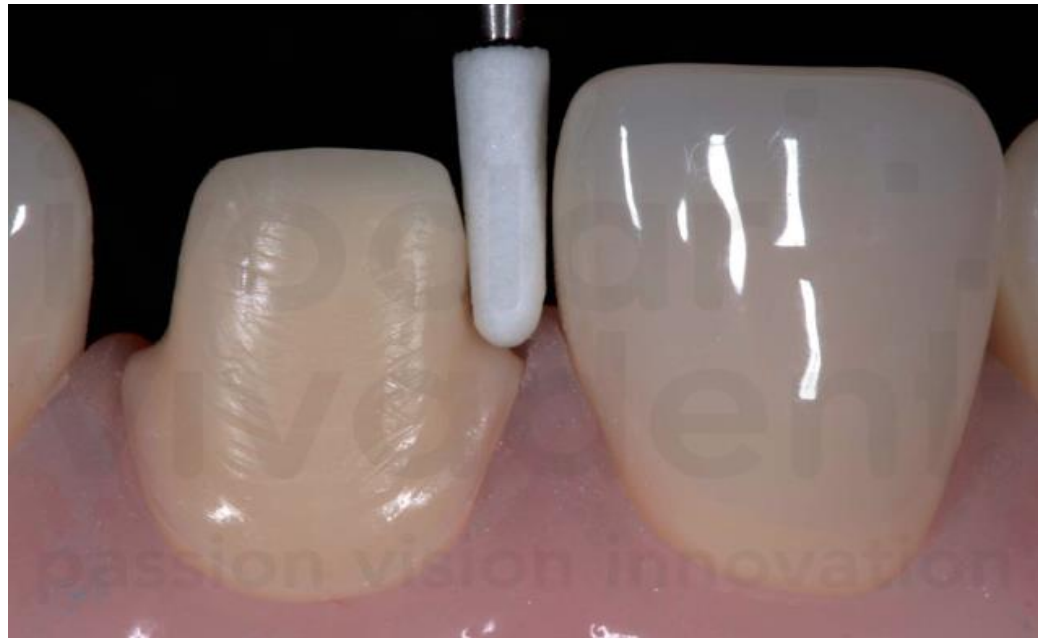- ▶ 1- Diagnosis
 - ▶ 2-tooth preparation
 - ▶ 3- final impression
 - ▶ 4-temporary restoration
 - ▶ 5-construction of working model
 - ▶ 6-waxing
 - ▶ 7-investing
 - ▶ 8- wax elimination
 - ▶ 9- casting
 - ▶ 10-cleaning and finishing
 - ▶ 11- try in and cementation
- 

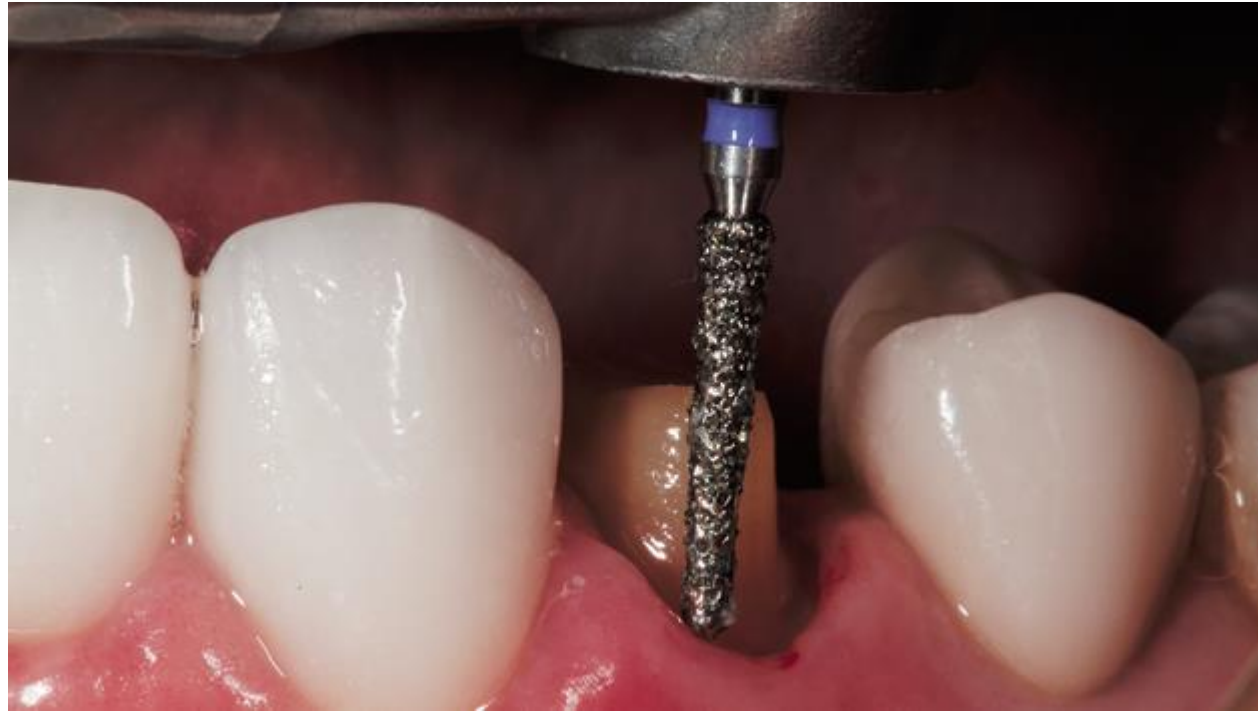Diagnosis:

- ▶ A) periodontal examination:
- ▶ Proper oral hygiene to ensure no plaque accumulation
- ▶ B) dental examination: which includes:
- ▶ **Visual examination**: we should examine the occlusion of the patient...crowding or spacing ..rotation of teeth .
- ▶ : shape and number of roots ,the condition
- ▶ **Radiographic examination** of surrounding structures and bone support..(crown/root ratio).....1:2


Tooth preparation

- ▶ Its is the cutting that is carried out on the tooth during crown construction procedure .
- ▶ **Finishing line** : is line that separates between the prepared and un prepared tooth portion.





Disadvantages of crowns

- ▶ 1- heat generation during the cutting procedure of teeth ...water coolant must be used
 - ▶ 2- over preparation can cause pulp irritation or pulp exposure which lead to dead of the pulp.
 - ▶ 3- periodontal problems: food impaction with subsequent gingivitis and periodontal pocket formation.
- 



RESTORATIVE DENTISTRY

lecture 1

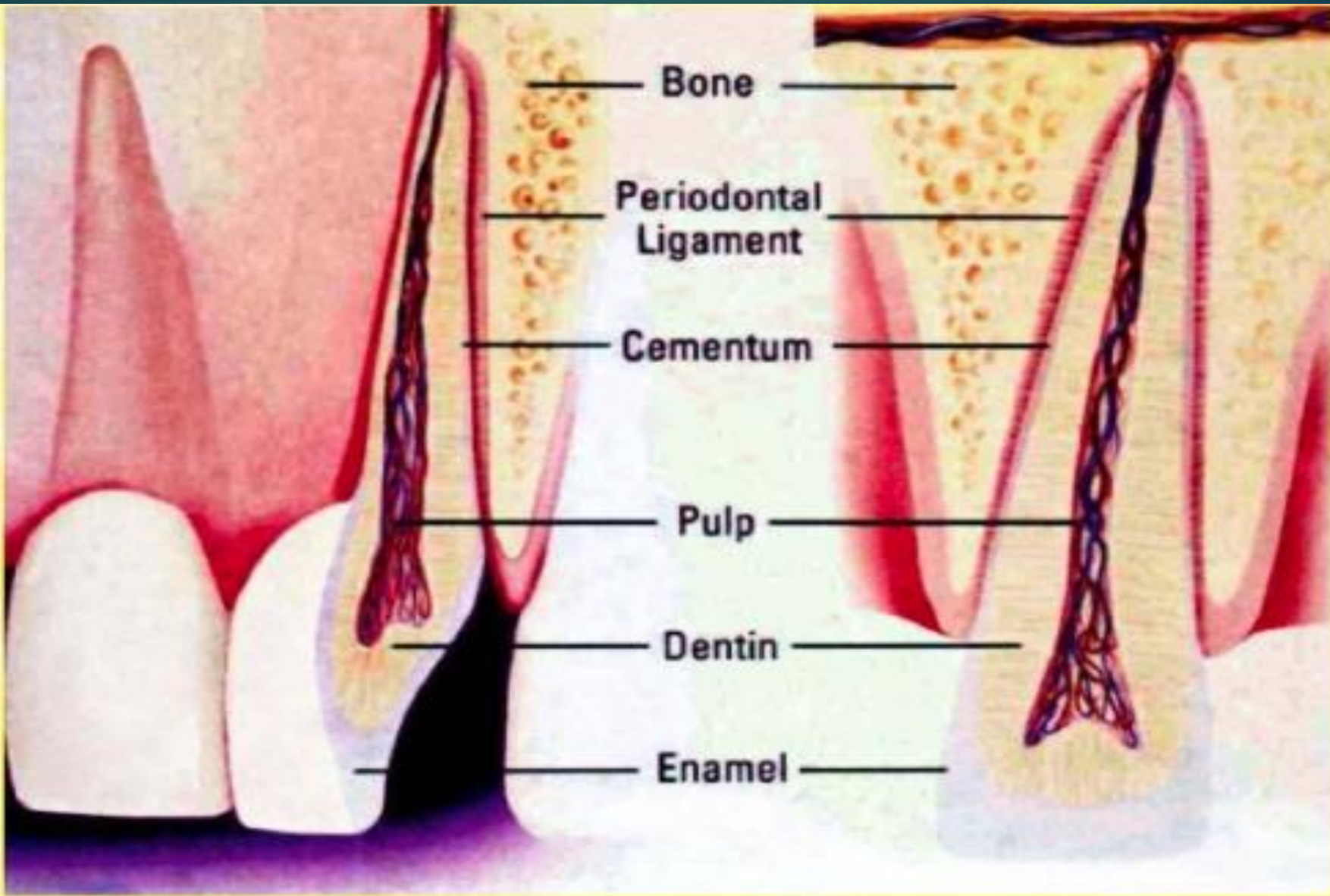
performed by

Dr : Rusul Al Saray

Introduction to
Operative Dentistry
Part I

Definition:

Operative Dentistry is the art and science of the **prevention**, **diagnosis** and **treatment** of defects in the enamel and dentin of individual teeth.



Bone

Periodontal
Ligament

Cementum

Pulp

Dentin

Enamel

Objective of operative dentistry:

1- Diagnosis

- proper diagnosis of lesion for planning the treatment
- Determination of nature, location, extent & severity of disease

2- prevention :

Its included procedures of preventions before the appearance of any sign and symptom of disease

3- Interception

Procedure done after the appearance of any signs and symptoms (dental caries)to prevent the extension of the lesion

4- preservation

Preservation of what has remained (tooth structure or pulp) along with an effort to restore what has been lost

5- Restorations

The restoration must be adequate to restore the form, function and esthetic of the tooth structure

6- Maintenance

After restoration is done, it must be maintained for longer useful service

Indications :

- 1- Treatment of carious lesion
- 2- Treatment of non carious lesion
- 3- Treatment of discolored or fracture tooth
- 4- Esthetic enhancement
- 5- Repair or replacement of old restorations

Cariious tooth defects (Dental caries)

Dental caries it's an infectious disease caused by specific types of bacteria (microorganisms) that causes fermentation to carbohydrate leading to acid release byproduct that causes dissolution and destruction in the hard tooth surfase

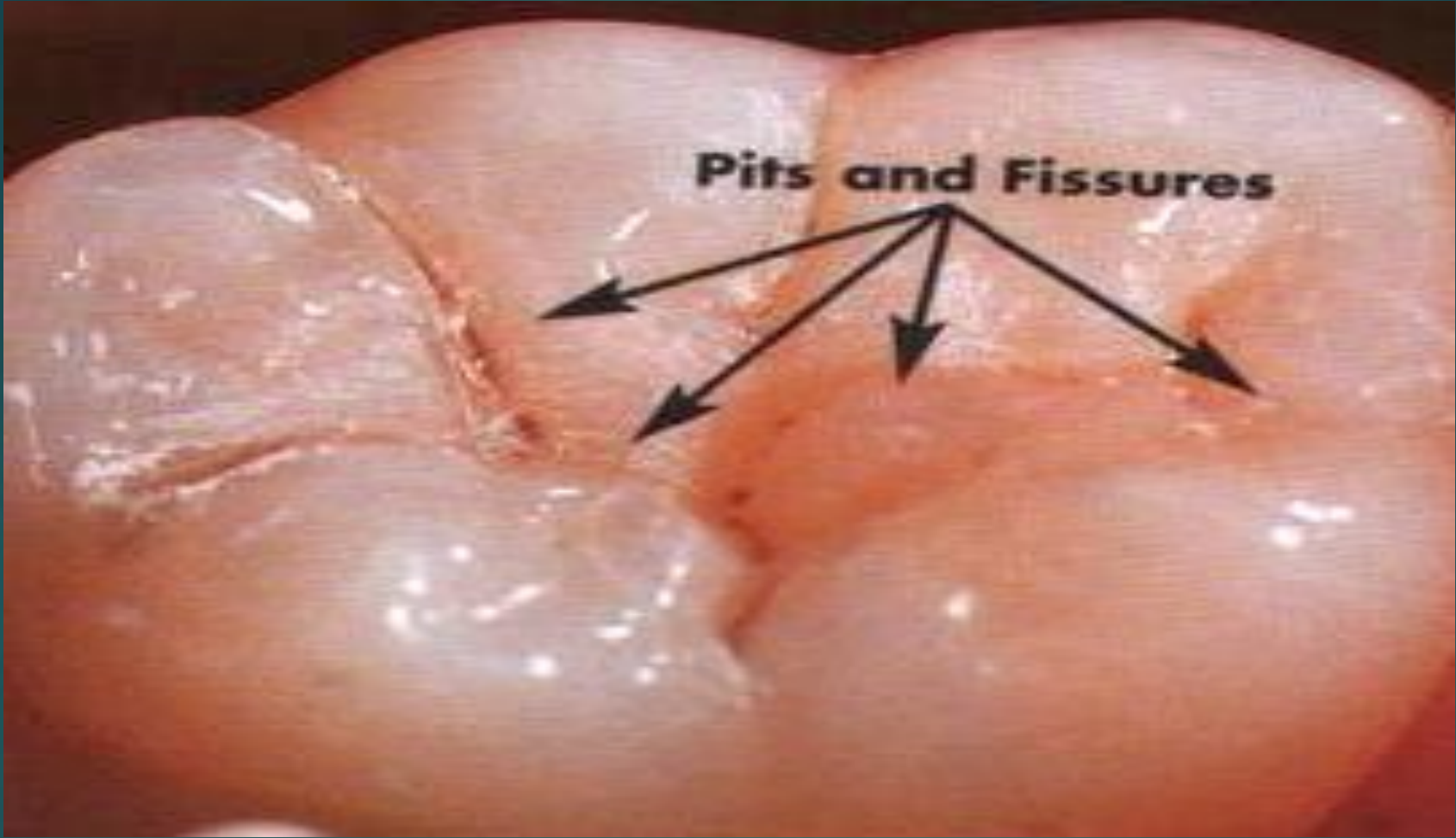
[bacteria +carbohydrate +tooth structure = caries]

Morphology types of caries

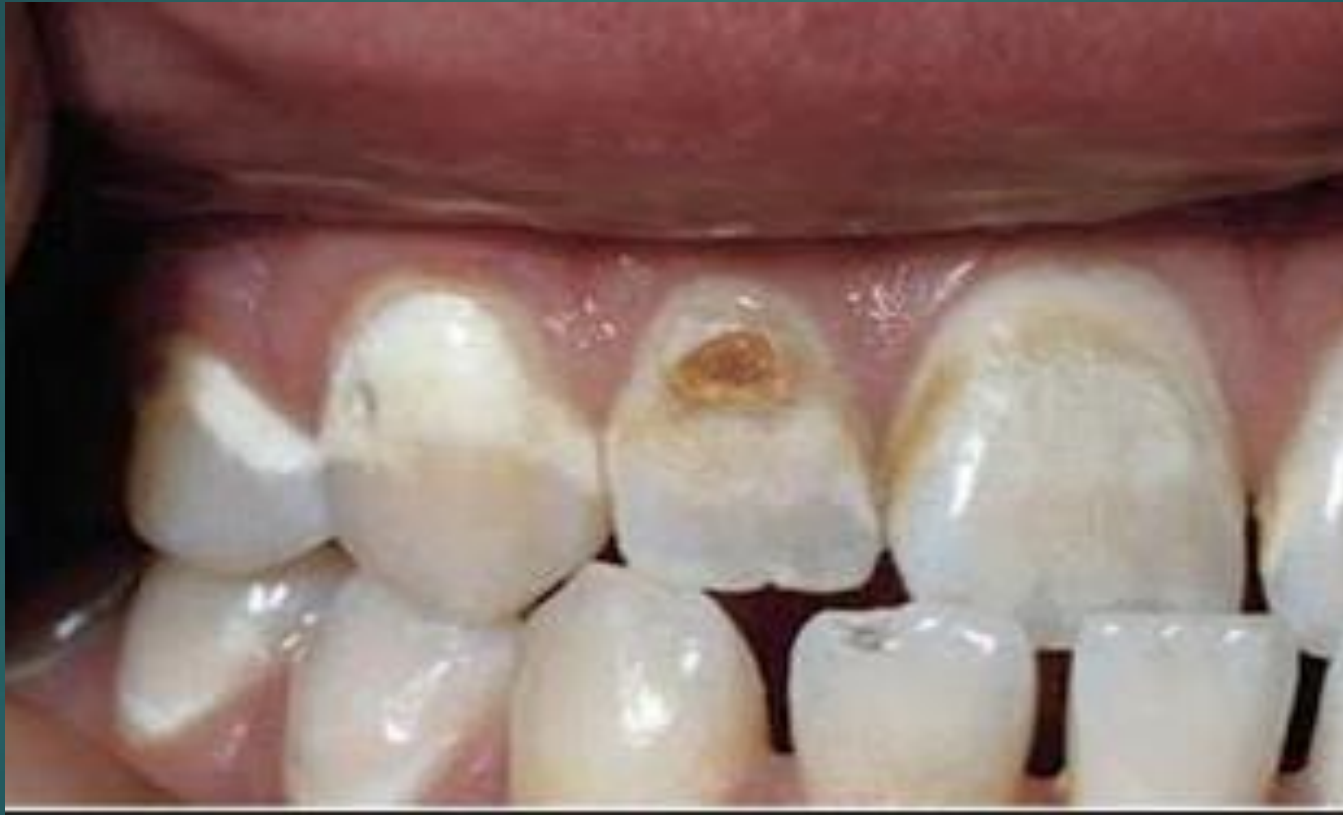1- Pits and Fissures carious lesions ▶

2- Smooth surfaces carious lesions ▶

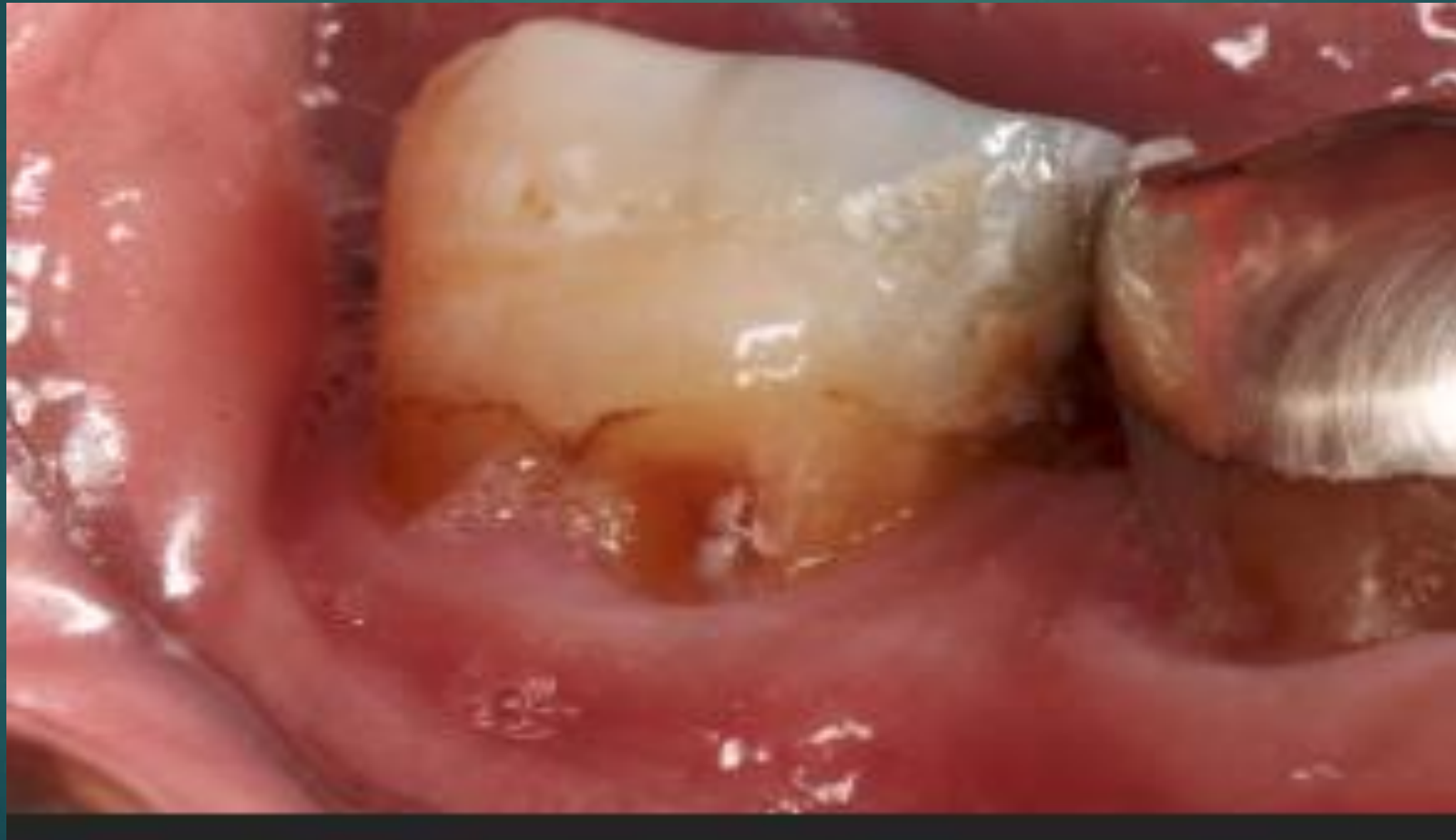3- Root surface carious lesions ▶



Smooth surface caries



Root caries



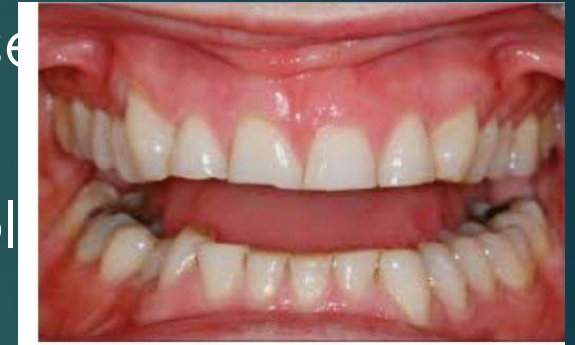Non carious defect

-it's the loss of the tooth structure, but due to non- bacterial cause. Its may be : attrition, abrasion or erosion ▶

A-Attrition (Occlusal or incisal) ▶

-is the loss of tooth structure (flattening of the occlusal or incisal surfaces due to mechanical wear between opposing teeth , increased para-functional

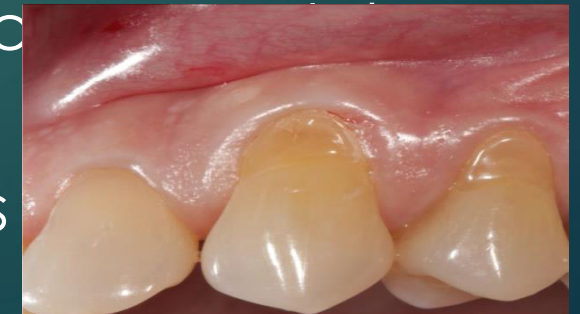habits as bruxism and clenching (young age)&by aging (old)



B- Abrasion : (cervical or incisal)

Is the loss of tooth structure due to mechanical cause resulting from forces of friction bet the teeth and foreign / external objects which occur (incisal),

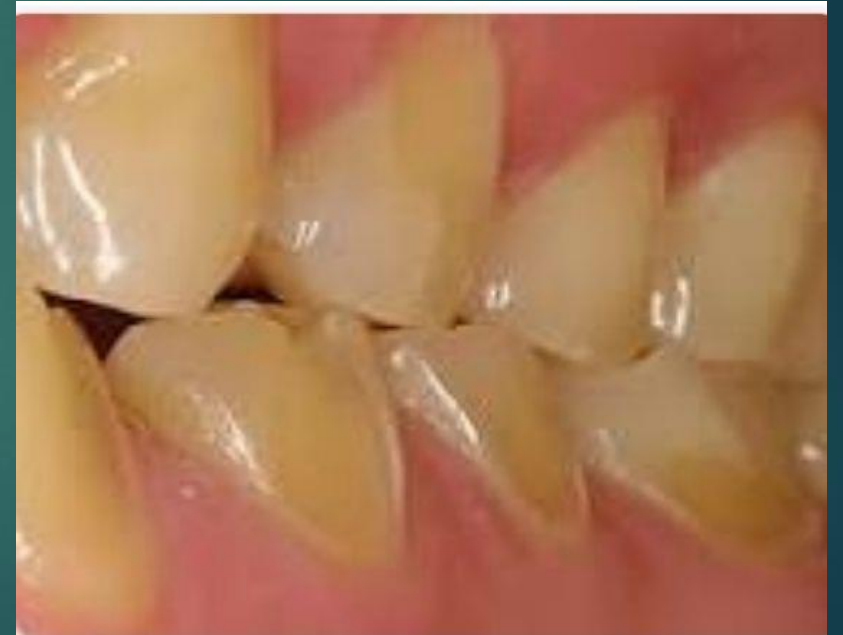Like wrong brushing technique , pipe smoking , tailor . Tools



C- Erosion : Is a chemo-mechanical tooth structure loss due to a chemical agent as acids which may be :

Internal source : like stomach acid vomiting - affecting the lingual surface of maxillary anterior teeth mainly

- External source : like acid & soda drinkers administration as lemon sucking



3- Fracture teeth:

Loss of tooth structure as a result of trauma or due to heavy occlusal forces

4- **discolored teeth** : its due to stains that may be ::

- Extrinsic: food , smoking
- Intrinsic: tetracycline stains

5- Esthetic enhancement

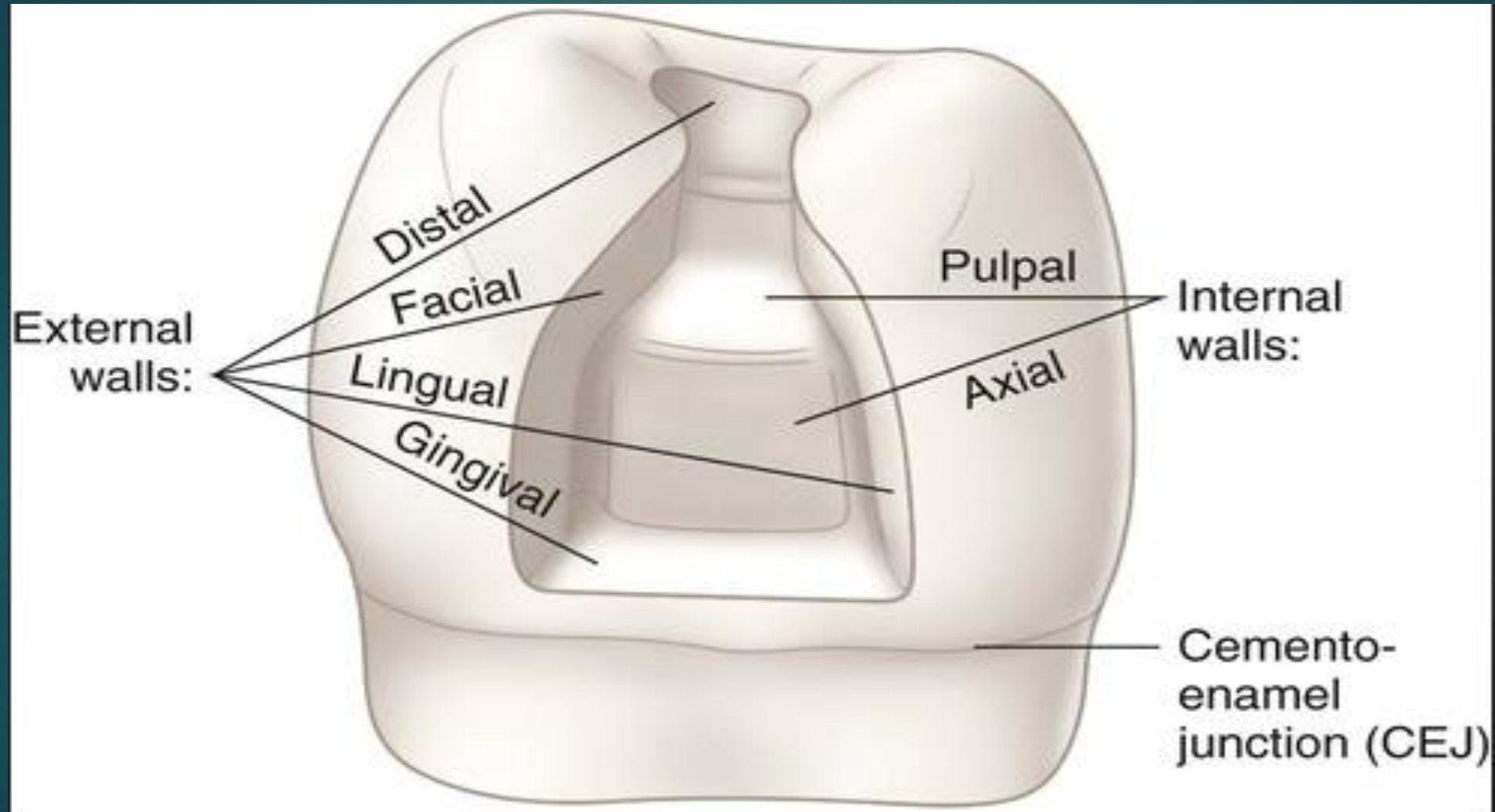
Diastema closure : the space between the teeth that may affect the appearance of the patient

- slight discoloration that needs to bleaching

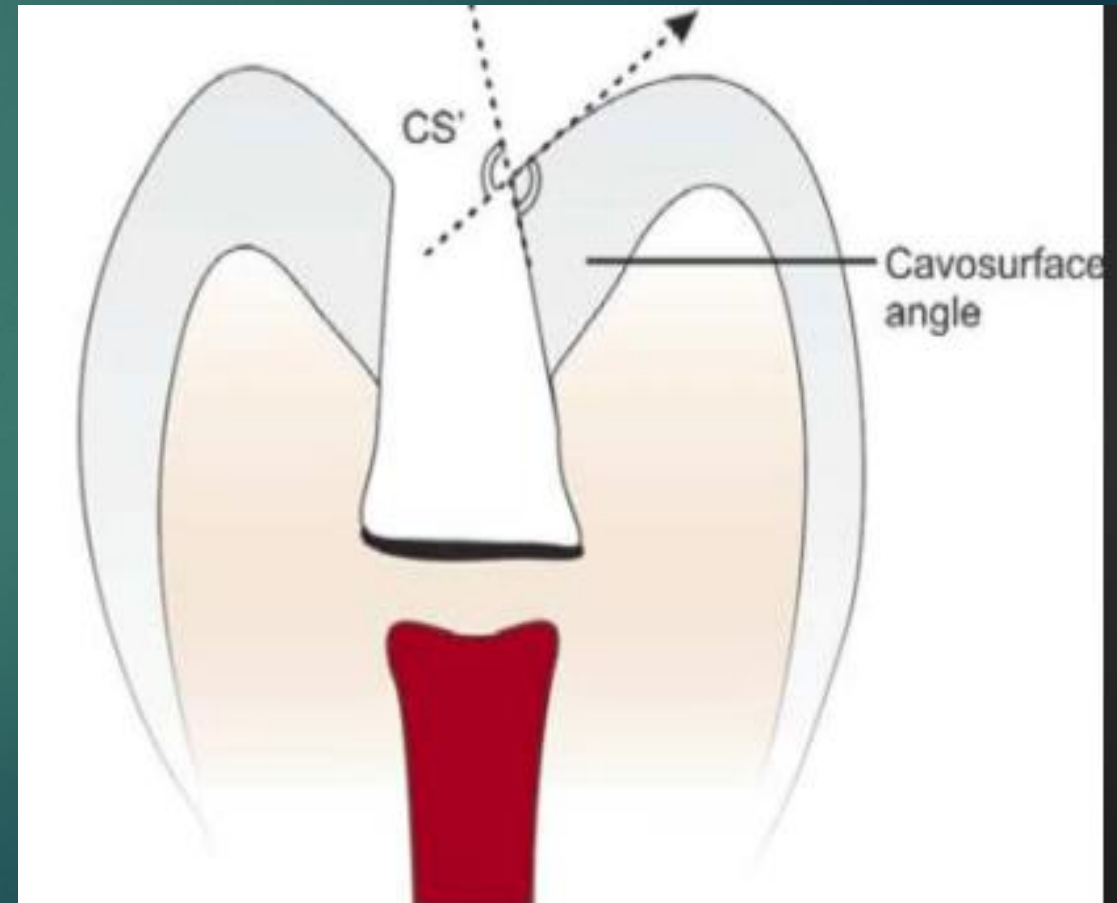
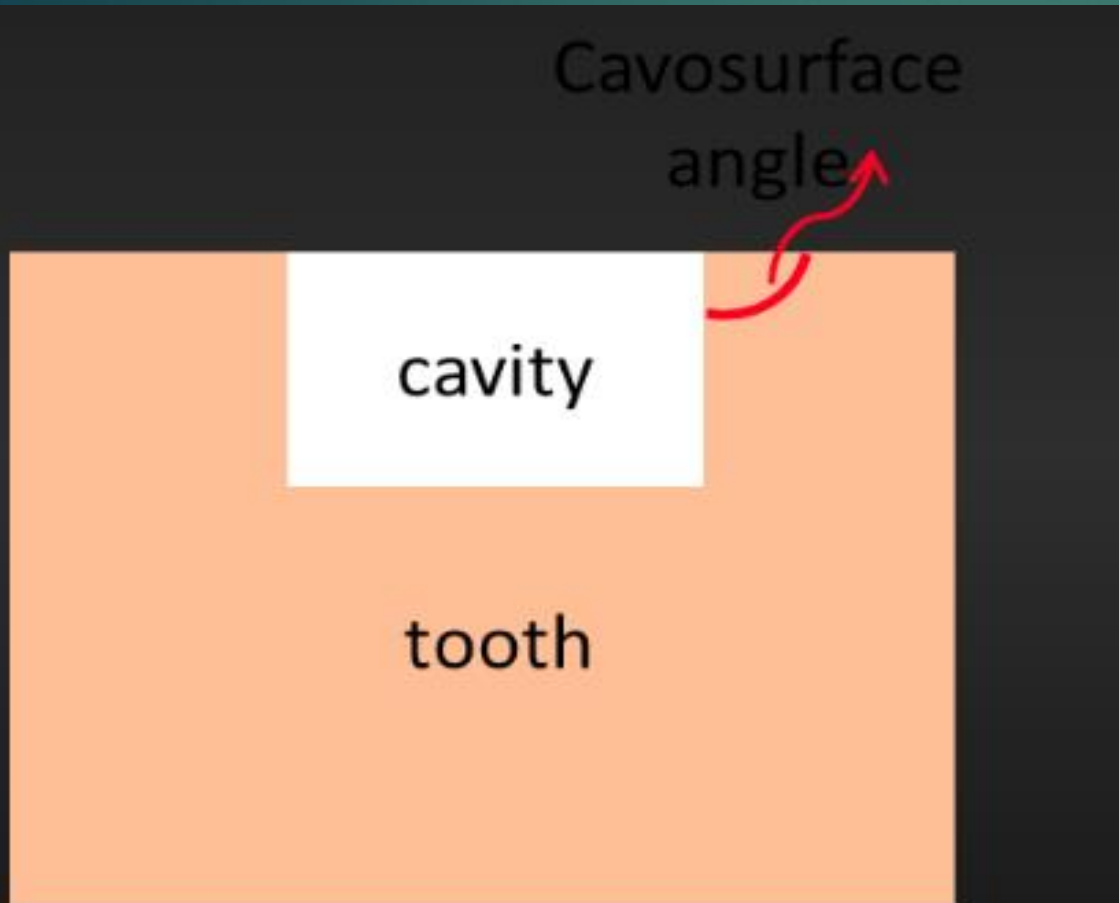
Tooth preparation classify :

- 1- **simple** if tooth preparation only one tooth surface. ▶
- 2- **compound** if tooth preparation two surfaces are involved. ▶
- 3- **complex** if tooth preparation involved three or more surfaces. ▶

Tooth preparation walls



Cavosurface angle: is the angle of tooth structure by junction of a prepared wall and external surface of the tooth

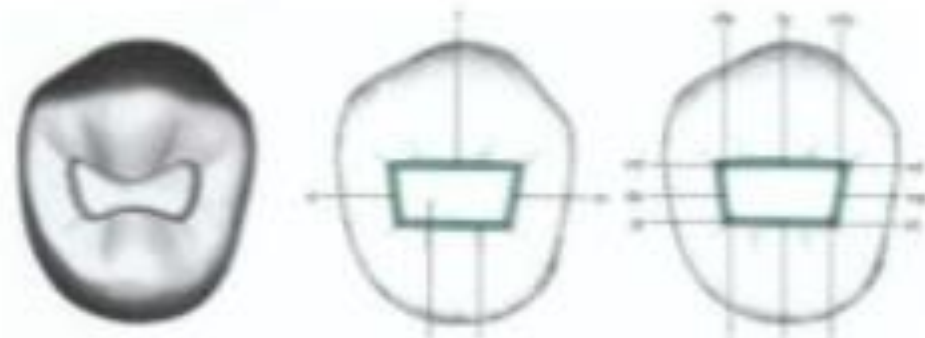

> G V Black's classification

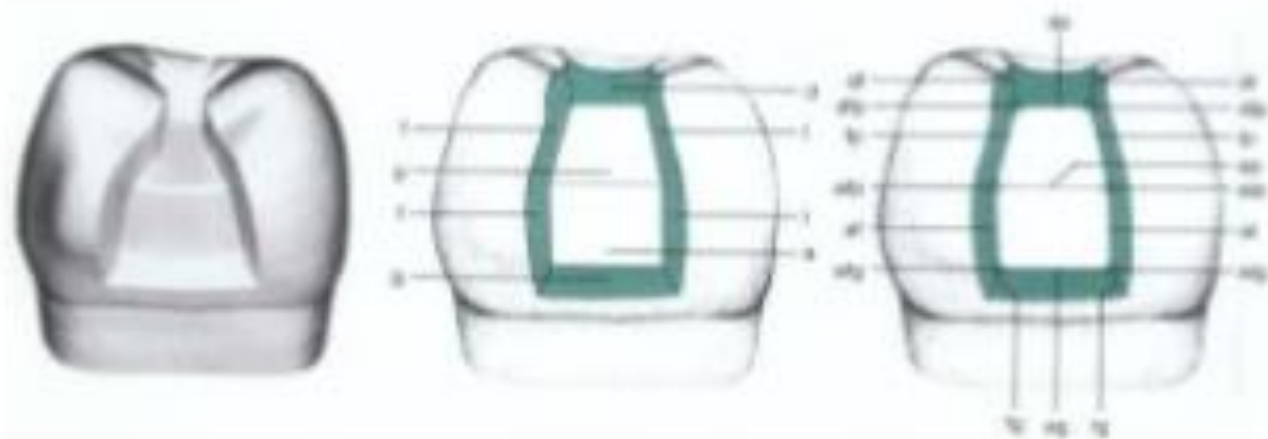
Class I lesions : All pit-and-fissure restorations are Class I, and they are assigned to three groups, as follows.

They usually have three locations:

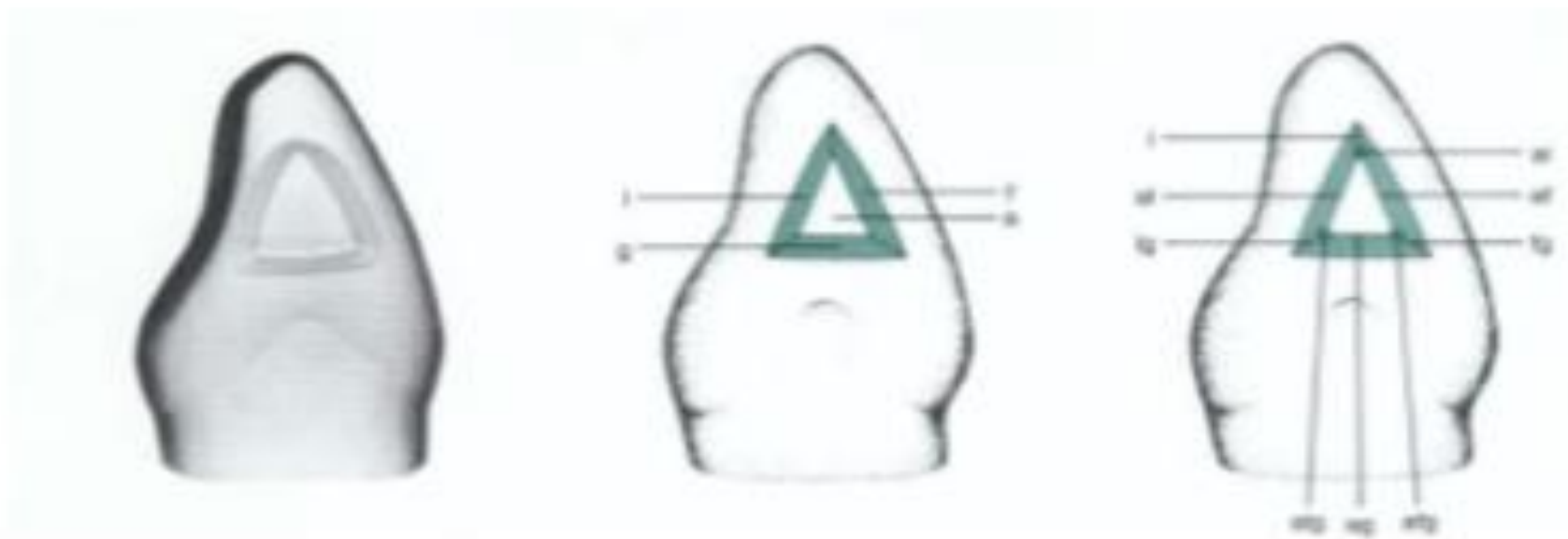
- the occlusal surfaces of molars and premolars
- the occlusal two thirds of the buccal and lingual surfaces of molars and
- the lingual surfaces of anterior teeth.



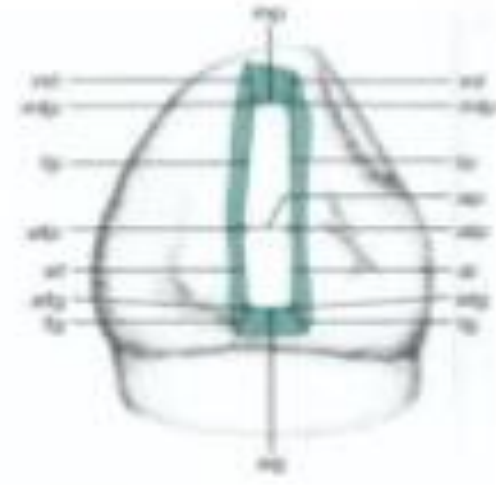
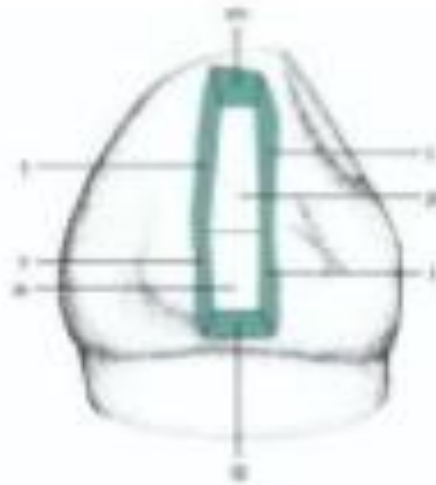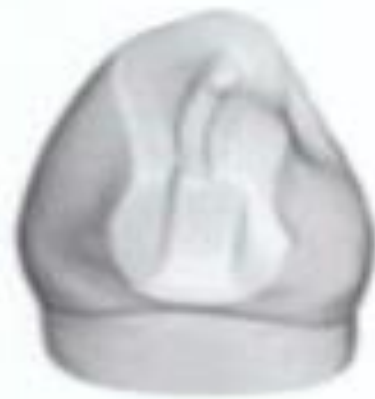Class II Lesions: Restorations on the proximal surfaces of posterior teeth are Class II.



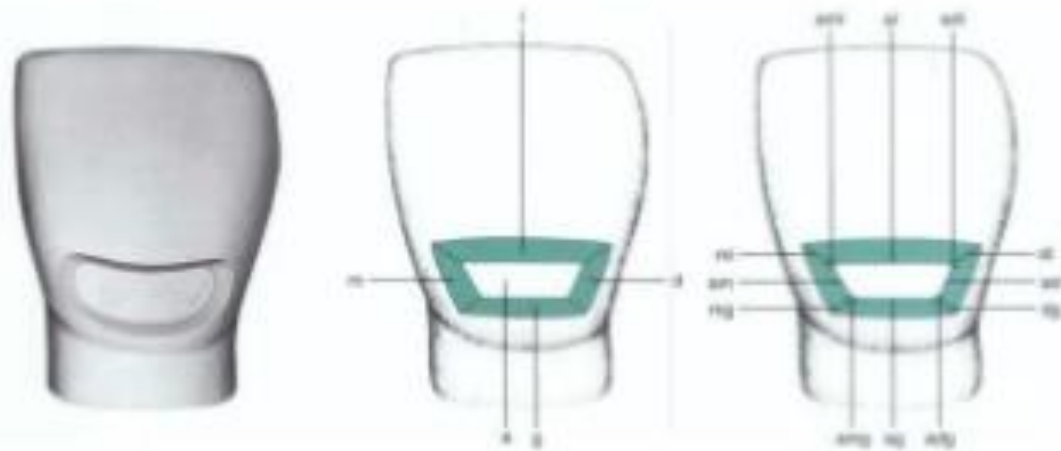Class III lesions : are found on proximal surfaces of anterior teeth that do not involve or necessitate removal of the incisal angle.



Class IV: Class IV Restorations. Restorations on the proximal surfaces of anterior teeth that do involve the incisal edge are Class IV.

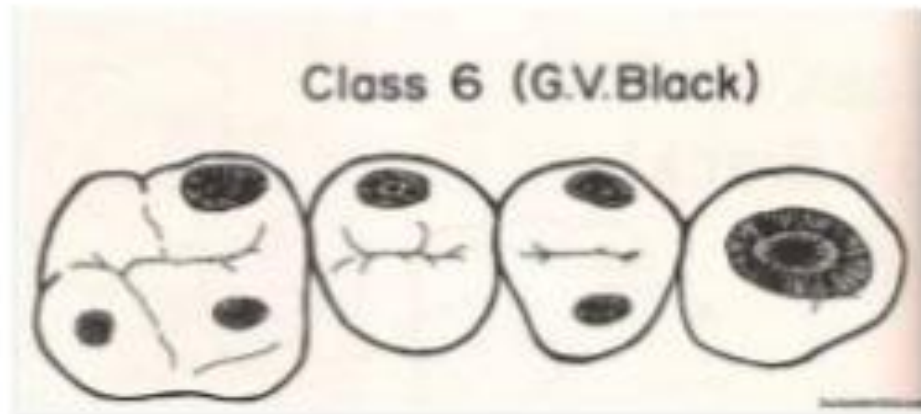


Class V Restorations: Restorations on the gingival third of the facial or lingual surfaces of all teeth (except pit-and-fissure lesions) are Class V.



Class VI Restorations: Restorations on the incisal edge of anterior teeth or the occlusal cusp heights of posterior teeth are Class VI.

They usually start in a traumatic or a formative defect.



**THANK
YOU**



Restorative dentistry

INSTRUMENTS AND EQUIPMENT FOR TOOTH PREPARATION (HAND INSTRUMENTS)

LEC.2

PERFORMED BY

DR : RUSUL AL SARAY

Classification of instruments

-Classification given by GV Black

-this classification is based according to use of use of the instrument

A- Hand instrument

-cutting(chisel, excavators& others)

-Non cutting (diagnostic , restorative material applicators)

B- Rotary instruments

- Power cutting handpiece

- Rotary cutting instruments

Instrument design:

Most hand instruments, regardless of use composed of three parts: □


A- Blade: is the working end of the instrument, has many sizes and designs depending on the function, it is connected to the handle by the shank. For the non cutting instrument the part corresponding to the blade is called the nib. The end of the nib or working surface is termed as the face. Some instruments have a blade on both ends of the handle and are known as double – ended instruments. □

B- Shank: connects the handle to blade, it is normally rounded, smooth and tapered; The shank may be straight or angled. Angulation of instrument is provided for access, view and stability (keep the blade edge within 1-2 mm to the long axis of the instruments).

c- Handle or shaft: Handle is used to hold the instrument. It can be small, medium or large, □ smooth or serrated for better grasping and developing pressure. They are commonly eight –sided to facilitate control


Instrument shank angles:

- connect the handle to the working end
- they are normally smooth, round and tapered
- shanks often have one or more bends (angulation) to avoid twisting or slippage of instrument when force is applied (balance and sharpness)



Cutting instrument bevel

- ☉ ☐ Most hand cutting instruments have on the end of the blade a single bevel that forms the primary cutting edge. Two additional edges, called secondary cutting edges, extend from the primary edge to the length of the blade. Bi-beveled instruments, such as ordinary hatchets, have two bevels that form the cutting edge.



Instrument name

- □ Black classified all instruments by name to describe instruments for their easier identification similar to biological classification. Naming of an instrument generally moves from 4 to 1.
- 1- function (e.g., scaler, excavator)
- 2- manner of use (e.g., hand condenser)
- 3- design of the working end (e.g., spoon excavator, sickle scaler) 4- shape of the shank (e.g., mon-angle, bin-angle, contra-angle) Exploring Ins


Cutting instruments:

- □ Instruments that are used to cut hard or soft tissues of the mouth, they include:
- **1- Excavators:** Excavators are used for removal of caries shaping of the internal parts of the cavity (dentine). They are subdivided into the following:
- **(A)- Ordinary hatchet excavator**
- -Single ended
- - used in scraping action for sharpening line angle
- - the blade is bedeviled



□ (B)- Hoe excavator:

- This type of instrument is used for planning tooth preparation walls and forming line angles. It is commonly used in Class III and V preparations with a pull motion .
- (C) Angle forms
 - Cutting edge makes different angles with the long axis of the instrument other than a right angle
 - - all are used also in shaving the hard tooth structure
line angle refinement



D- Spoon excavators

- Right or left -
- Cutting edge is rounded

Removal of soft carious dentine(remaining caries)

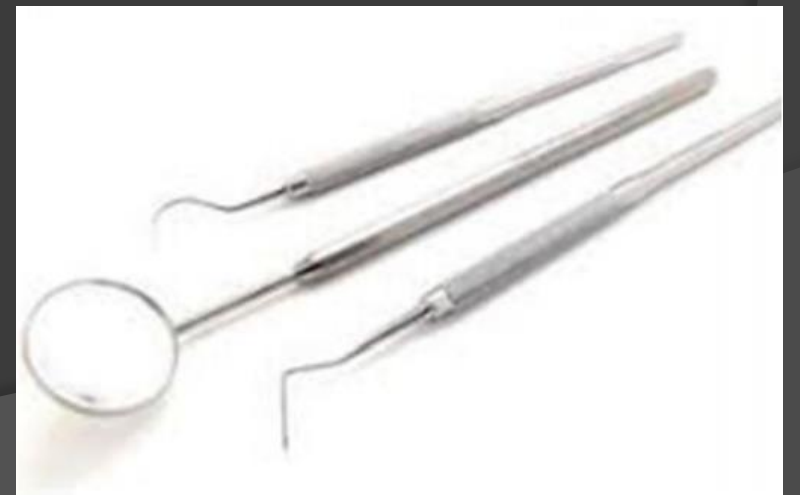Discoid spoon excavators : circular in shape (disk like)

Cleoid spoon excavators : Claw like & use as carving instrument



Exploring Instruments

1. Dental Mirrors: Dental mirror is used as supplement to improve vision during working
2. Dental Explorer used to explore tissue defects like caries detection. Either straight, sickle (curved), angled (interproximal) in shape



Chisels

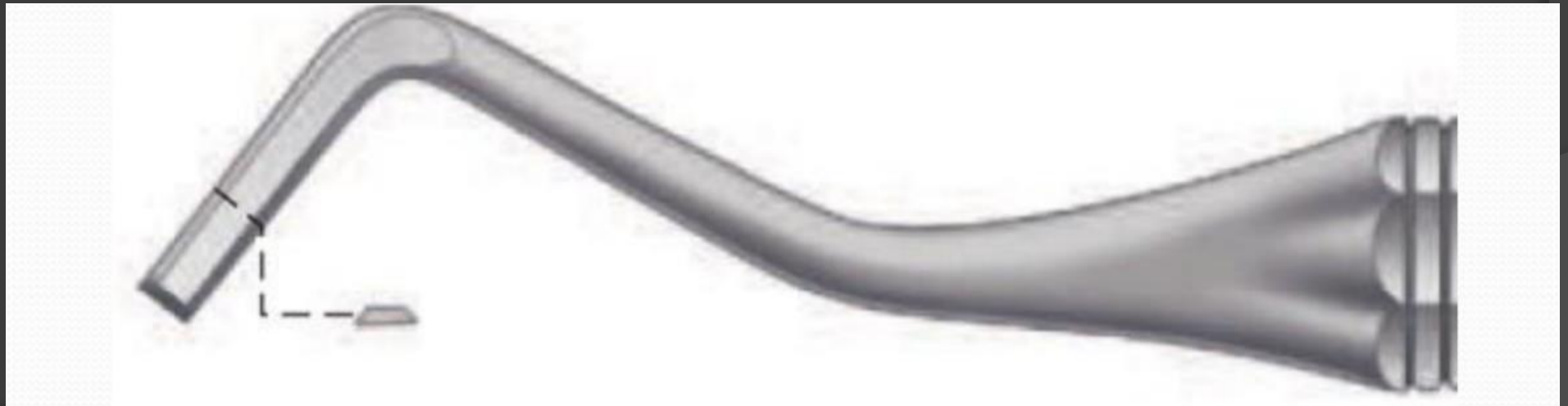
are intended primarily for cutting enamel and may be grouped as follows:

(A)- Straight, slightly curved, or bin-angle:

- A straight chisel which is mainly used for cutting enamel
- Has a straight shank & blade
 - The bevel is on one side
 - The cutting edge is at 90 degree angle to the handle

(B)- Enamel hatchet

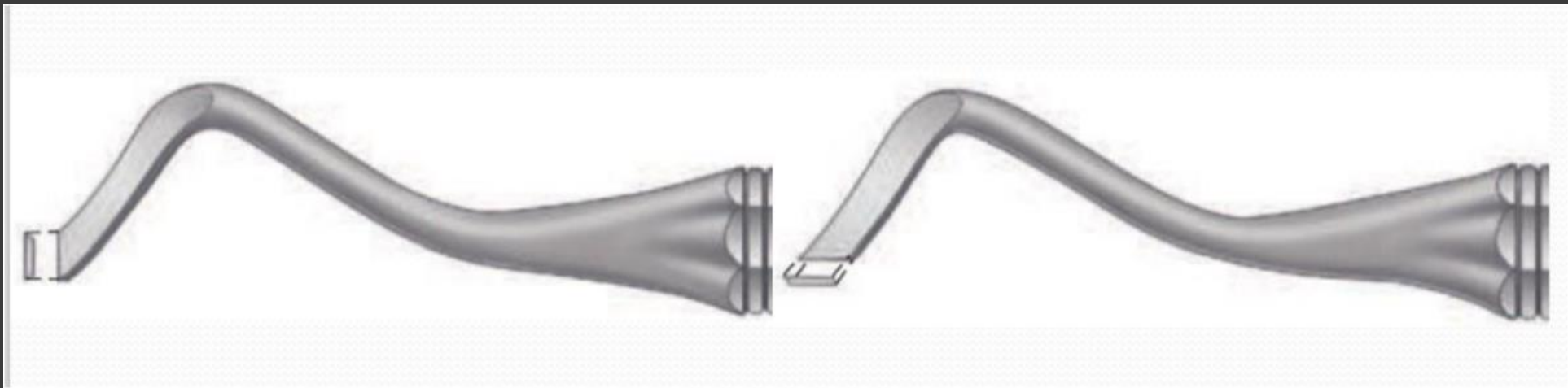- ⦿ : □ It is a chisel similar in design to the ordinary hatchet except that the blade is larger, heavier, and is beveled on only one side. It is used for cutting enamel and comes as (right or left)types for use on opposite sides of the cavity.



C)- Gingival margin trimmer

- ④ □- Mesial or distal & used in beveling the gingival enamel margins
- ④ -unlike hatchet it has a curved blade with a cutting edge makes an angle with the blade

④




Restorative Instruments

- ① 1. Cement Spatulas □ On the basis of size, cement spatula can be classified into two types
- ② A. Large cement spatula: Mixing of luting cements.
- ③ B. Small cement spatula: Mixing of liner. □ Cement spatula also can be classified on the basis of thickness rigid and flexible. Their use depends on viscosity of cement and personal preference.



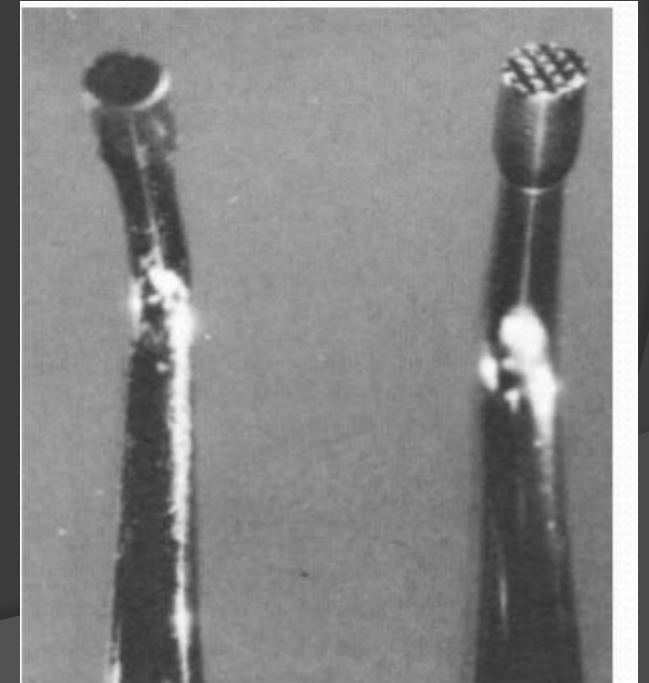
- 2. Ash □ Ash 6 : adaptation of cement against the axial wall and finish carving of amalgam.



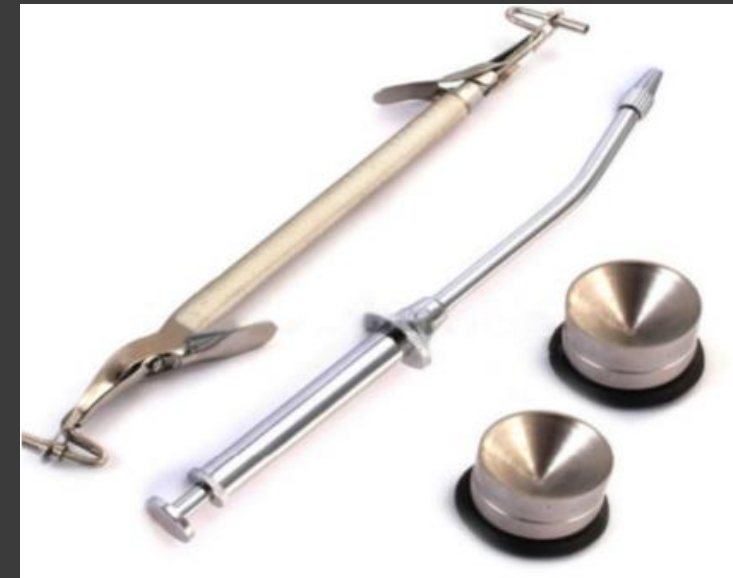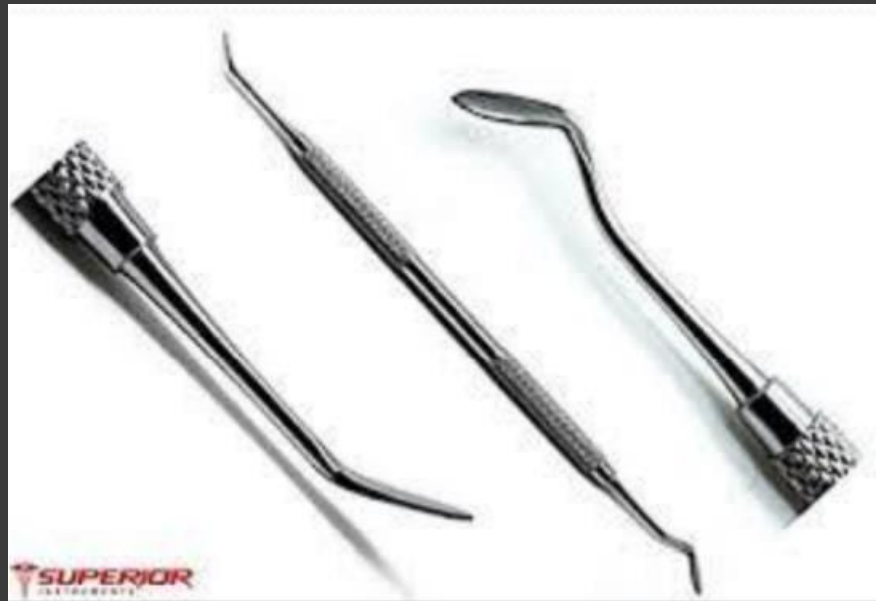- Ash 49: adapt the cement in the cavity and finish carving of amalgam, sometimes used to condense some of the filling materials.



- 3. Condensers □ Used to condense amalgam in the prepared cavity. So they called condensers or pluggers. The head has different sizes and shapes, and could be either smooth or serrated.



- ③ 3. Amalgam carriers □ Used to carry amalgam from the container to the prepared cavity.
- ④ 4. Carving instruments used to shape and form tooth anatomy from a restorations

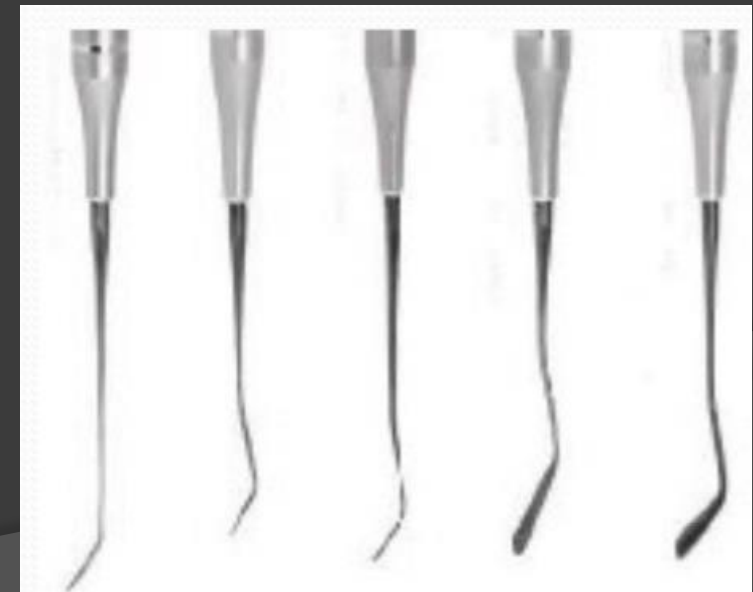
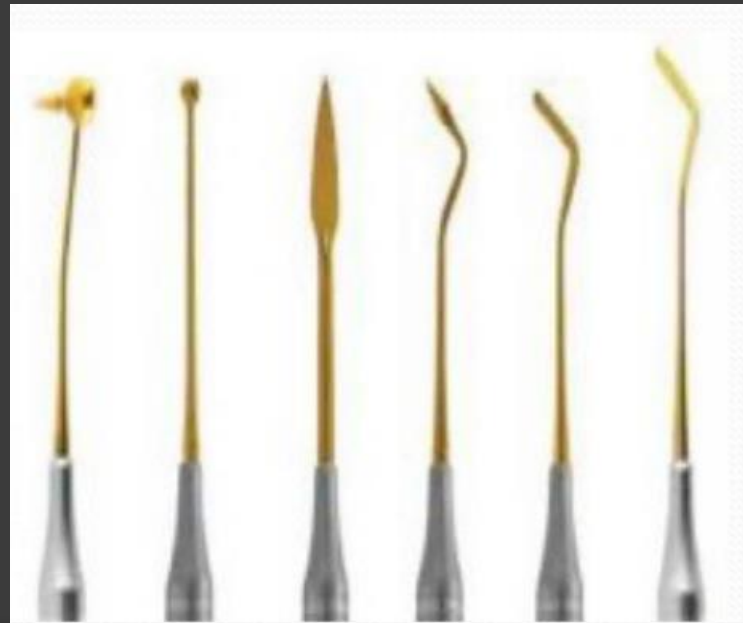
- 5. Burnishers Has a round heads. Usually double ended, with different sizes. Usually used to polish and burnish the surfaces of the restoration (amalgam), contour the matrix band in class II cavity preparation and stretch the margin of cast gold restoration.



6. Composite instruments

- Special Non sticking hand instruments of different shapes and sizes used to manipulate and sculpt dental composite



**THANK
YOU**

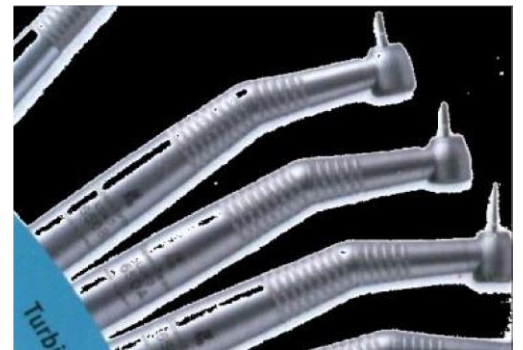

Powered cutting equipment Lec.3

DR.Rusul Al Saray

Handpiece:

- Is a device for holding rotary instruments, transmitting power (Source of power is motor or



air) to them, and for positioning them intraorally. Handpieces and associated cutting and polishing instruments developed as two basic types, straight and angle

Rotary speed ranges

- Three speed ranges are generally recognized measured in revolutions per minute (rpm)

1- Low speed or slow speeds: (below 12,000 rpm.) Used for tooth cleaning, caries excavation, and finishing and polishing procedures. At low speeds, tactile sensation is a better and there is generally less chance for overheating cut surfaces

2- Medium or intermediate speeds: (12,000 – 200,000 rpm).

3- High or ultra-high speeds: (above 200,000 rpm). Used for tooth preparation and removing old restorations.

Rotary Cutting Instruments

- The individual instruments intended for use with dental handpieces are manufactured in hundreds of sizes, shapes, and types. Each instrument consists of three parts: shank, neck, and head



Materials of dental burs

- **1- Stainless Steel:** introduced in 1891 , perform well cutting human **dentin** at low speeds, but dull rapidly at high speed or when cutting enamel. Once dulled,

reduced cutting effectiveness creates increased heat and vibration.

- 2- Carbide burs: usually tungsten carbide, they are introduced in 1947, replaced steel burs for cavity preparation, carbide is much harder than steel and less subjected to wear during cutting. But they are **brittle**, so they will fracture when subjected to sudden blow or shock.

3- Diamond burs: Introduced in 1942, they belong to “**abrasive instruments**” are based on small particles of a hard substance held in a matrix of softer material. Cutting occurs at a large number of points where individual hard particles protrude from the matrix. Diamond instrument have long life and great effectiveness in cutting enamel and dentin.



Shapes and sizes

1- Round Burs: Spherical in shape, with different sizes ($1/4 = 0.5$ mm, $1/2 = 0.6$ mm , $1 = 0.8$ mm, $2 = 1.0$ mm, $3 = 1.2$ mm, $4 = 1.4$ mm ...etc) .

Large round burs with slow speed used for caries removal

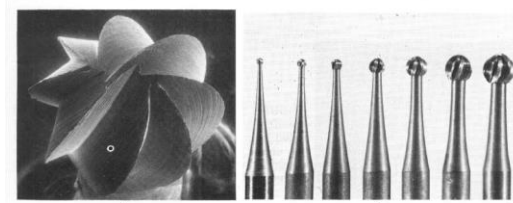


FIGURE 3-7. Round burs, A, Note the blades, which enable the bur to cut with its end. B, Round burs range in size from No. 1/2, 1, 2, 4, 6, 8, 10 (left to right).

which cannot be removed by spoon excavator. Small round burs used for entry into the tooth and for preparation of retentive pinholes and grooves.

2- Elliptical Burs (Pear shaped):

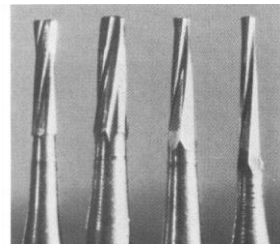
Elliptical or elongated round burs have become popular as a result of a trend toward conservative cavity design. Characterized by round corners with a reverse taper. They produce a



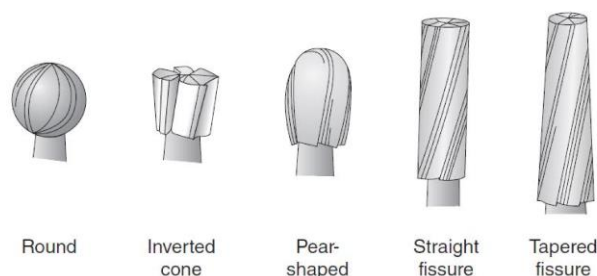
conservative cavity preparation with rounded internal corners and a minimum removal of tooth structure.

- 3- **Straight fissure burs**: Elongated cylinder, cut enamel and dentin well at high speed, establishing outline form and have advantage of leaving smooth cut surface. Numerical code: (56 = 0.8 mm, 57= 1.0 mm, 58 = 1.2 mm, 59 = 1.4 mm.....).

- 4- **Tapered fissure burs**: Tapered cone with the small end of the cone directed away from the shank. Used for inlay and crown preparation, where freedom of the undercut is essential. Numerical code: (700 = 1.0 mm, 701 = 1.2 , 702= 1.6 mm, 703= 2.1mm)



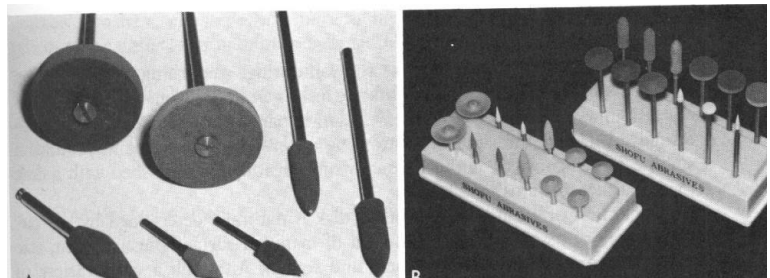
- 5- **Inverted cone bur**: Tapered cone with the apex of the cone directed toward the bur shank. The head length is about the same as the diameter. Used for providing undercut in cavity



preparation and flattening of the pulpal and gingival walls.
Numerical code: (33 1/2 = 0.6 mm, 34= 0.8 mm, 35 = 1.0 mm.....

Rotary finishing and polishing instruments

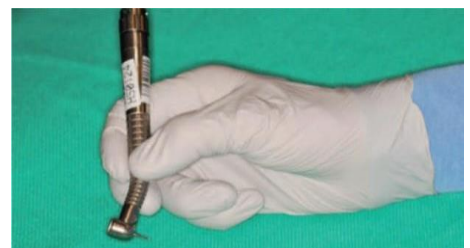- ☰ Used for finishing and polishing of filling material and tooth surface, they have different sizes and shapes and colors Examples: Silicon carbide (Carborundum) , Diamond stones, Aluminum oxide discs, silicon rubber wheel and points, brushes and rubber cups.



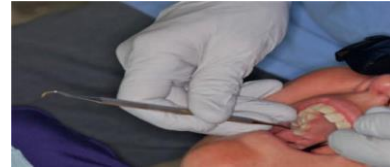
Control of operative instruments

1- The Modified pen grasp:

- Similar :Holding a pen but the instruments supported by the tip (not the joint of the middle finger)
- Holding : between the thumb, middle and index fingers
- Rest : by tips of the rings and little fingers on a nearby tooth on same arch



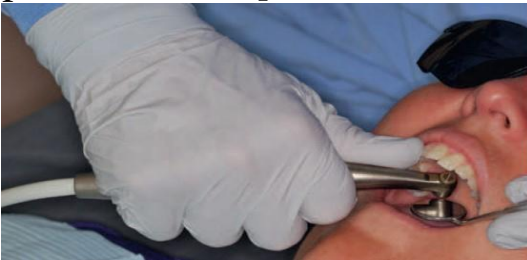- Palm : facing away from the operator
- Function : Finishing the enamel walls



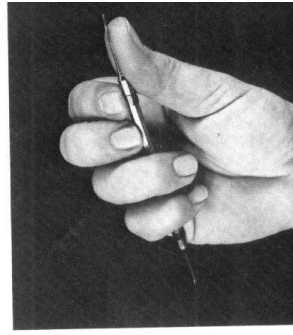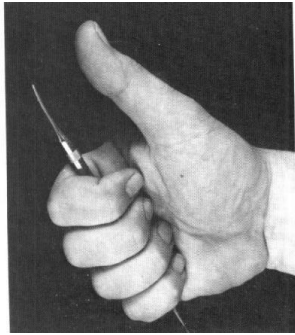
- 2-Inverted pen grasp:** The same as pen modified grasp ,
- Palm** : the action of the instrument is up and toward the operator .
 - Function** : lingual surfaces of anterior teeth

3-Palm and thumb grasp:

- Similar** : Holding a knife while removing the skin of an apple .
 - Holding** : all the four fingers, while the thumb is free
 - Rest** : Tip of the thumb on the nearby tooth of the same arch
 - Palm** : Facing the instruments
 - Function** : limit use
- used mainly in the upper arch ,
proximal and palatal surface of max. ant.



Occlusal & buccal surfaces of max. posterior



4-Modified palm and thumb grasp:

- **Similar & Holding** as Palm and Thumb grasp
- **Rest** : Thumb is rested on the tooth being prepared
- **Palm** : facing the instrument
- **Function** as the Palm & Thumb grasp.



Lec9

Operative Dentistry
Clinical Procedures of Amalgam

Performed

by

Dr. Rusul Alsaray

Dental Amalgam

Introduction

- Dental amalgam is an alloy made by mixing mercury with a silver tin alloy. Dental amalgam alloy is a silver tin alloy to which varying amount of copper and small amount of zinc has been added.
- According to **Skinner's**, amalgam is a special type of alloy in which one of its constituent is mercury. In dentistry, it is common to use the term amalgam to mean dental amalgam.

Advantages


- Ease of use, Easy to manipulate
- Relatively inexpensive
- Excellent wear resistance
- Restoration is completed within one sitting without requiring much chair side time.
- Well condensed and triturated amalgam has good compressive strength.



Advantages

- Sealing ability improves with age by formation of corrosion products at tooth amalgam interface.
- Relatively not technique sensitive.
- Bonded amalgams have “bordering benefits”.
 - Less microleakage
 - Slightly increased strength of remaining tooth structure.
 - Minimal postoperative sensitivity.

Disadvantages

- Unnatural appearance (non esthetic)
- Tarnish and corrosion
- Metallic taste and galvanic shock
- Discoloration of tooth structure
- Lack of chemical or mechanical adhesion to the tooth structure.
- Mercury toxicity
- Promotes plaque adhesion
- Delayed expansion
- Weakens tooth structure (unless bonded).

Composition of dental amalgam

Powder: the alloy powder composed of :

1- silver : 40-70%

Gives strength

High expansion of the restoration

2- Tin 20-30%

Increase affinity for mercury

speed of amalgamation

Increase the flow of the amalgam



3- COPPER : 15-30% high copper

5% or less low copper alloys.....lead to

Reduce corrosion of the restoration

Minimize the flow

Increase setting expansion

4- Zinc : 1-2%



Acts as a scavenger for oxides formed during manufacturing

Help the process of amalgamation

Alloy particles

Irregular shape of particles called **lath-cut** alloy ▶

Spherical shape called **spherical** alloy ▶

Lath cut and spherical called **Admixed** ▶

Amalgamation

It is the process of reaction between the mercury and amalgam alloy

The amalgamation reaction consists of two phenomena which include solution and crystallization

The amalgam alloy is intimately mixed with liquid Hg to wet the surface of the particles and this crystallization growth leading to hard amalgam .

Properties of dental amalgam

1- compressive strength

Highly compressive strength for high copper alloy and low for low copper alloys...because amalgam is brittle material therefore sudden application or excessive force tend to fracture .

2- **tensile strength** : strong in compressive but weaker in tensile and shear strength

3- **Creep** : is permanent deformation under static loads...

Highly copper alloys have low creep



4- Dimensional changes : the amalgam undergo shrinkage at the first time after setting (first 20 mins) and after this period the expansion occur and the dimension become constant with in 24 hours

5- corrosion : it is progressive destruction of the metal by chemical or electrochemical reaction with its environments, Excessive corrosion can lead to increase porosity and reduce the marginal integrity.

Amalgam capsules



Amalgam mixing or triturating



Old design



New design

1- under-mixed : appear dull and crumbly which are lower strength and poorer corrosion ►

2- normal mixing: appear shiny and separated in one mass from the capsule ►

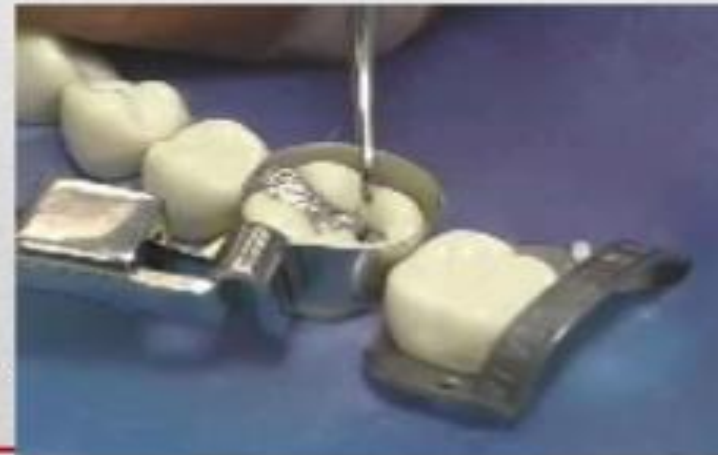3- overmixed : appear soupy and tend to stick to inside the capsule which result low compressive strength and high creep. ►

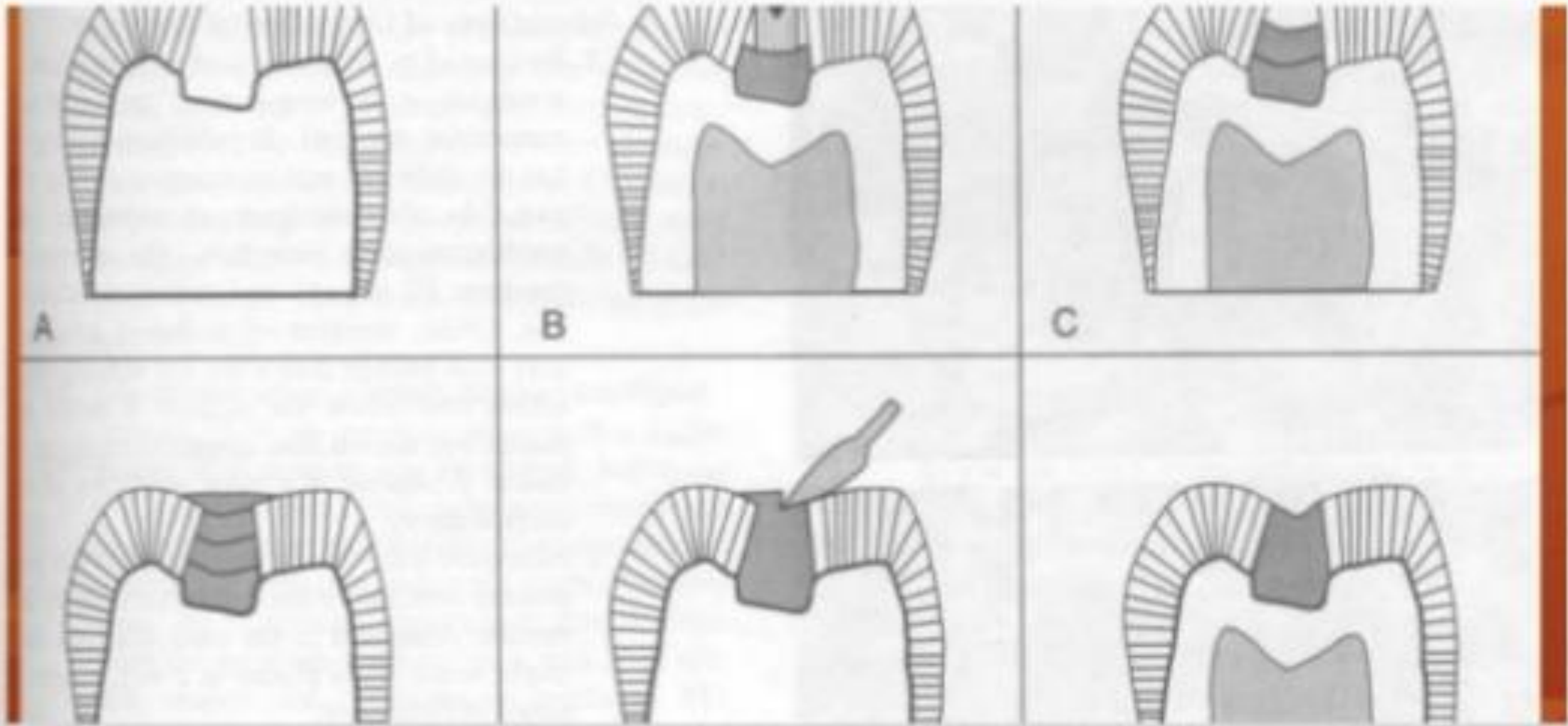
Hand condensation

- Once the increment of amalgam is inserted into the cavity preparation it should be condensed with pressure to avoid voids and to adapt the material to the walls, the condenser point is forced into the amalgam mass under hand pressure.
- Condensation is started at the center and then condenser point is stepped little by little towards the cavity wall.
- After condensation of the each increment excess mercury should left over the first increment so that it can bond with the next increment.
- The procedure of adding an increment,condensing it,adding another increment and so forth is continued until the cavity is overfilled.
- In case the cavity is large well condensed amalgam restoration can be achieved when the mix has proper consistency.

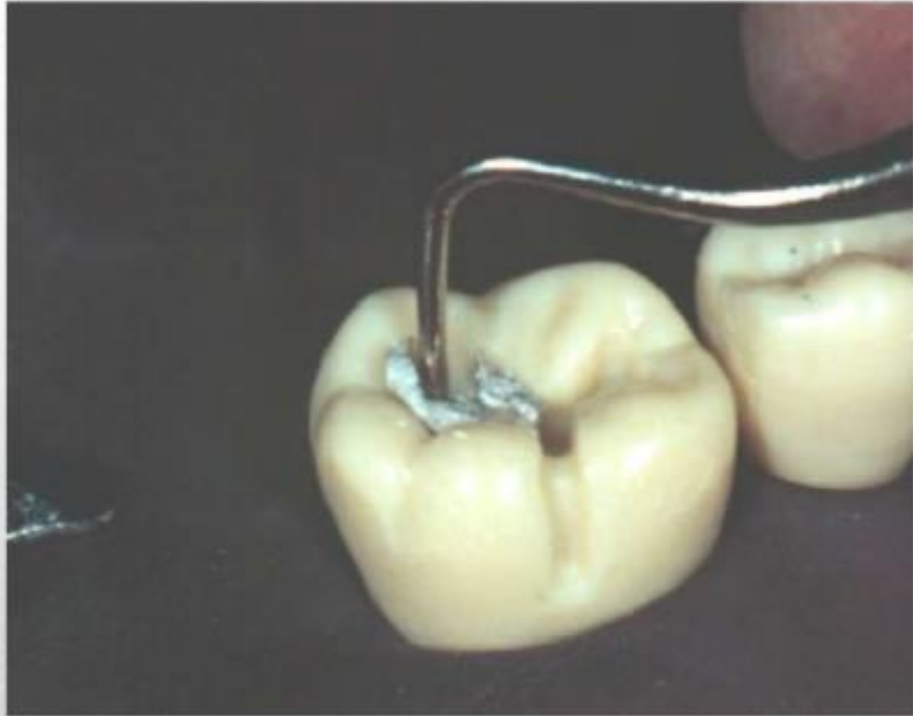


Hand condenser

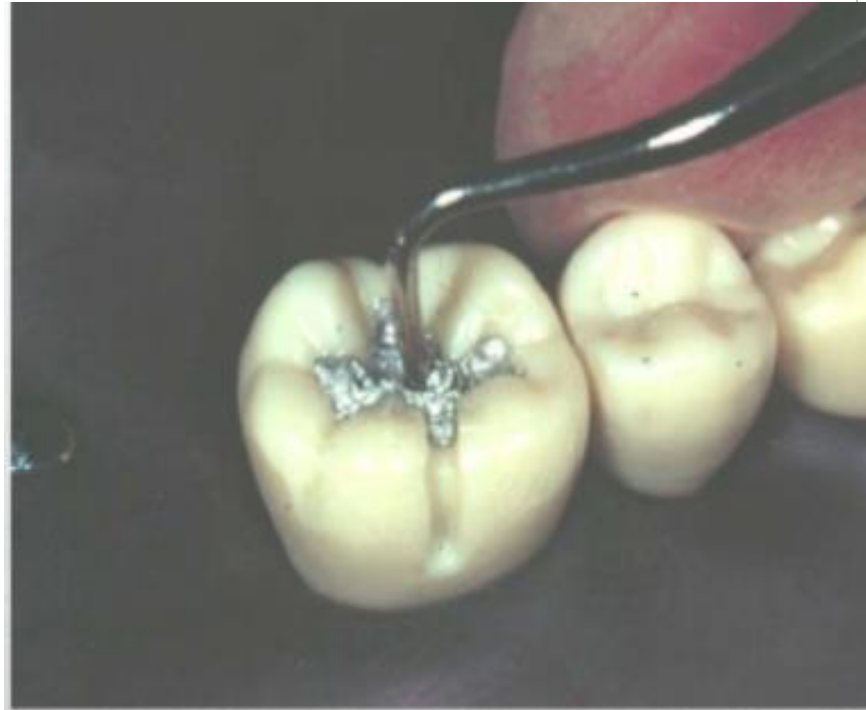



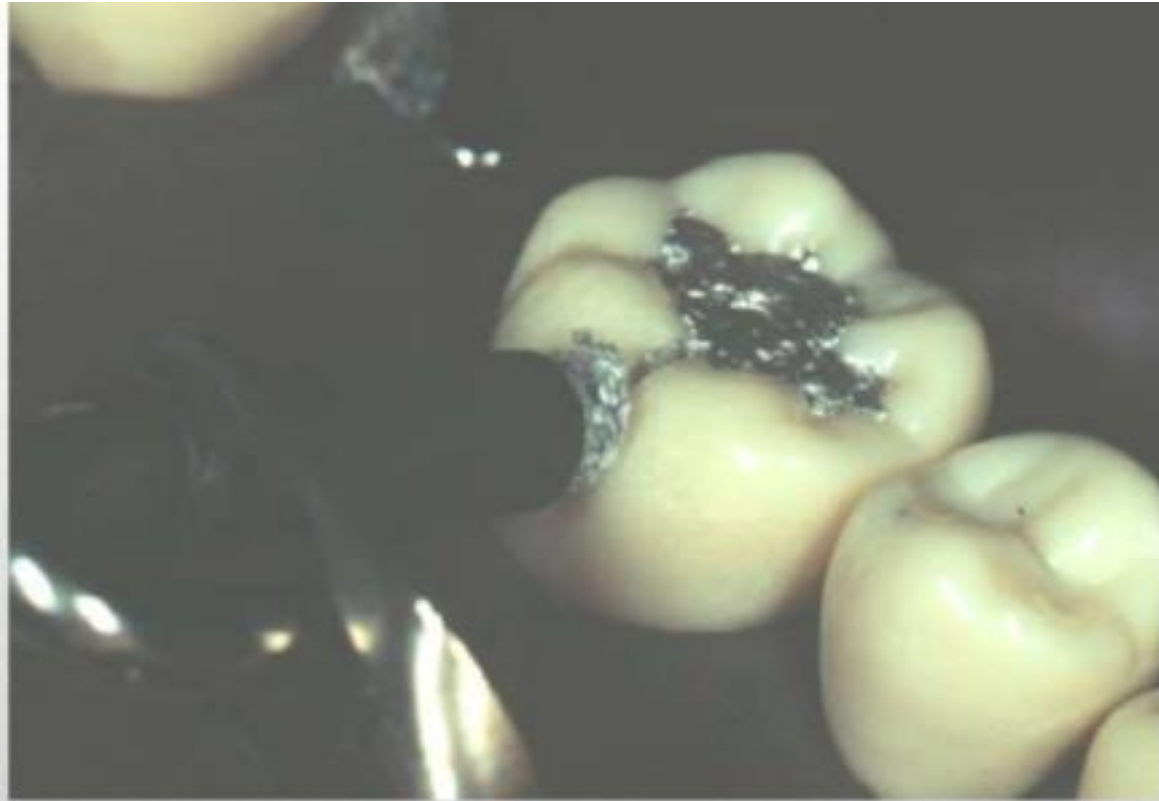Condensation of amalgam



Start with the smallest condenser



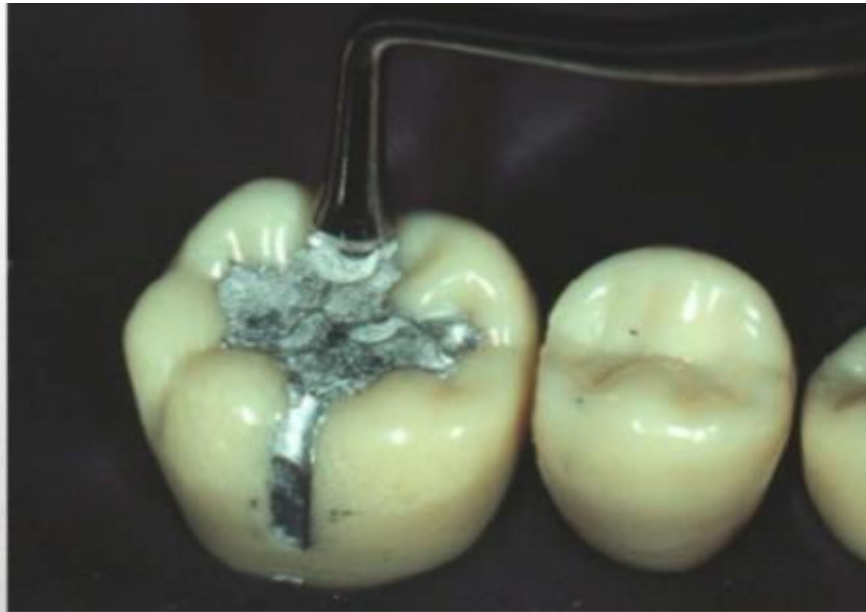
Step condenser over mass



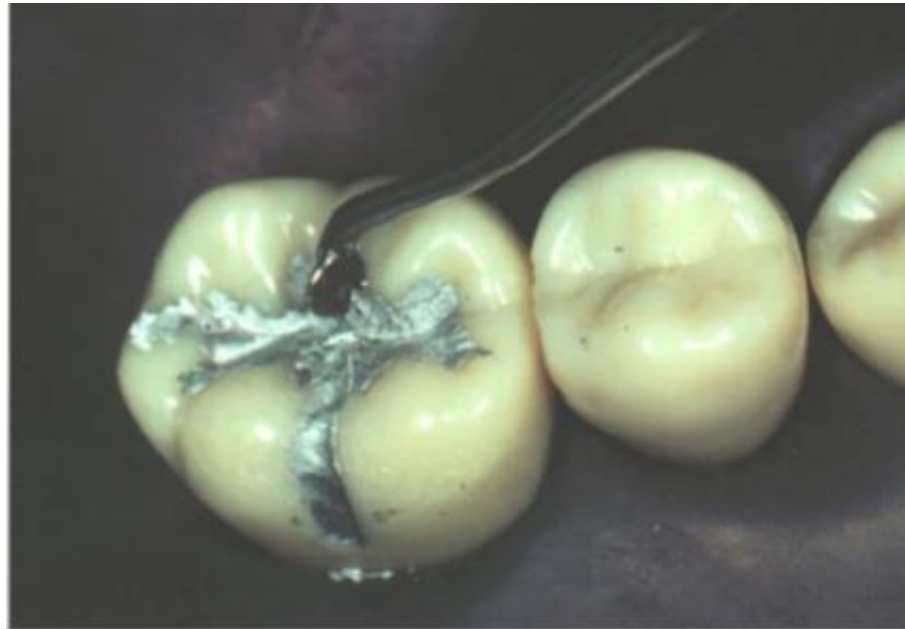Continue adding increment

Carving and finishing

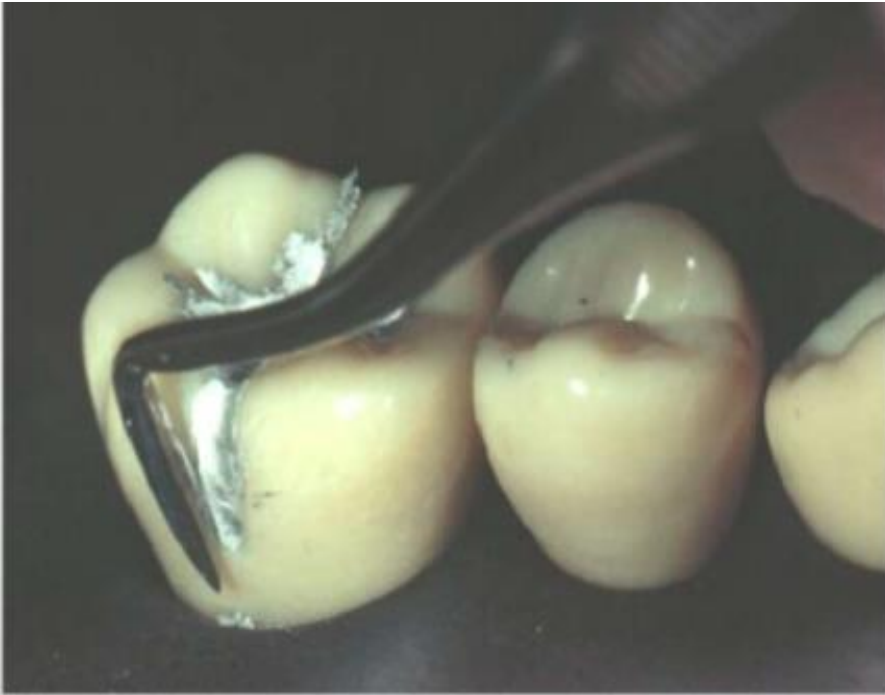- After amalgam is condensed in cavity it is carved to reproduce the proper tooth anatomy. It should be started when the amalgam is hard enough to offer resistance to the carving.
- Burnishing of the occlusal anatomy can be accomplished with the help of the ball burnisher. A rigid flat-bladed instrument is best used on the smooth surfaces. Final smoothing can be done with the help of moist cotton or with the help of prophylaxis paste. While polishing temp should not raise beyond 60-degree.
- Final finish should be done after the amalgam is fully set, it should be delayed for at least 24 hr. and a wet prophylaxis paste should be used .



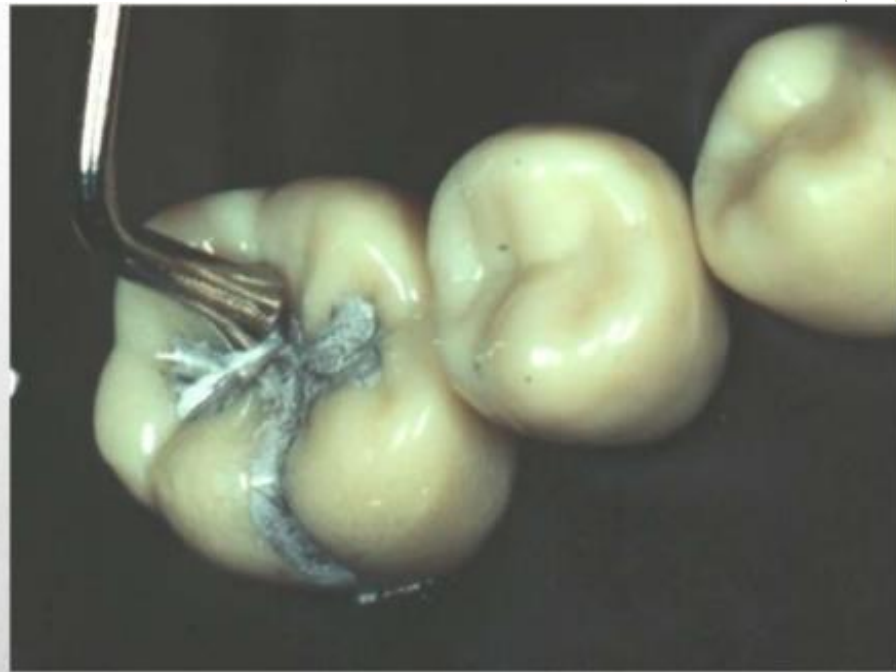
Create initial grooves



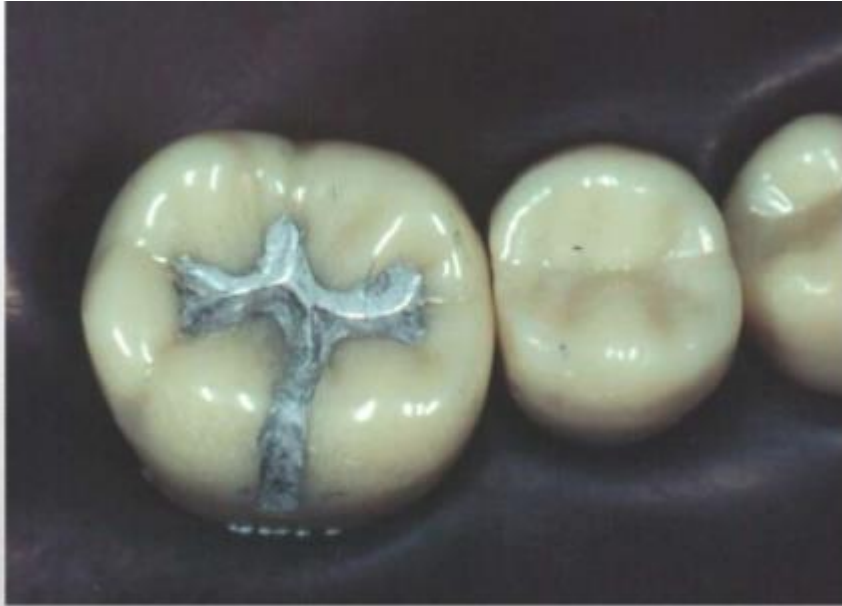Carve to margin



Remove flash

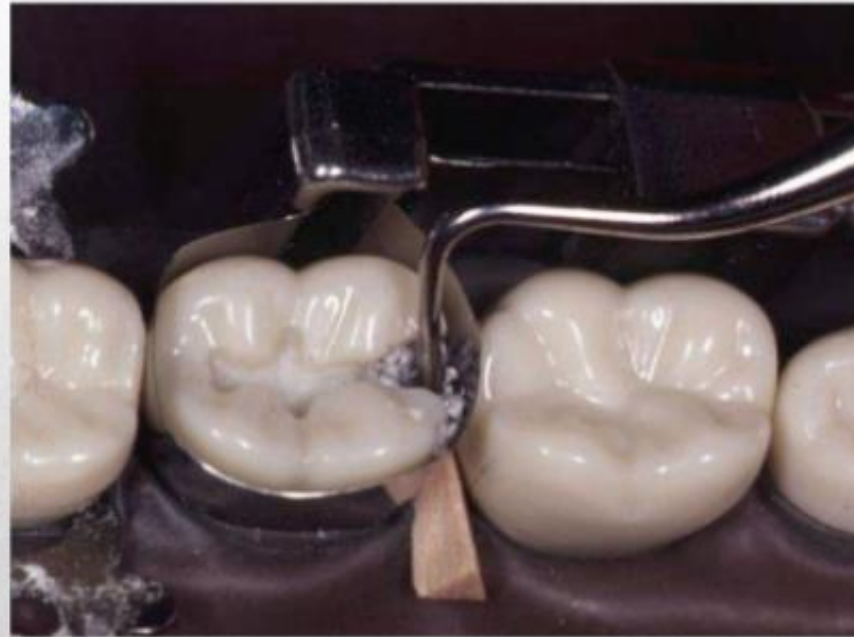

Final shape and burnishing

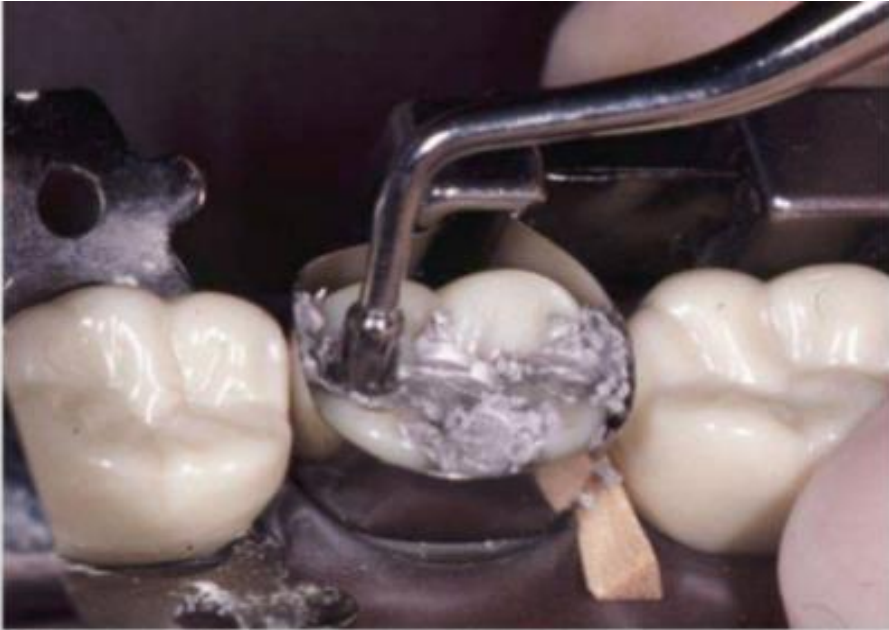

Completed restoration

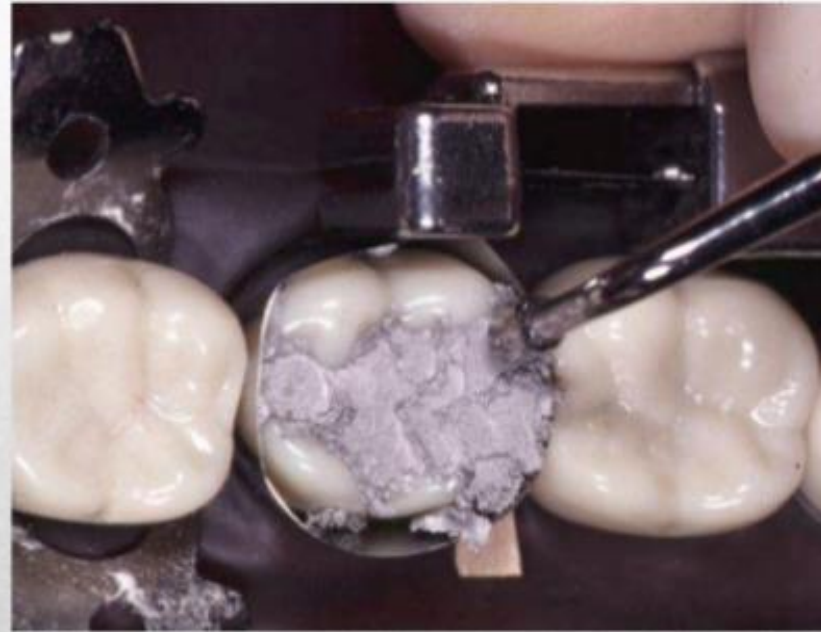
Class II restoration



Initial Condensation



Overpacking



Marginal Ridge Condensation

Complex amalgam restorations

Definition: -

Complex posterior restorations are used to replace any missing structure of teeth that have fractured, have severe caries involvement or have existing restorative material

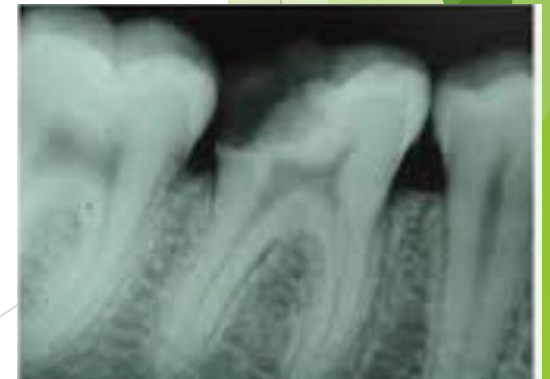
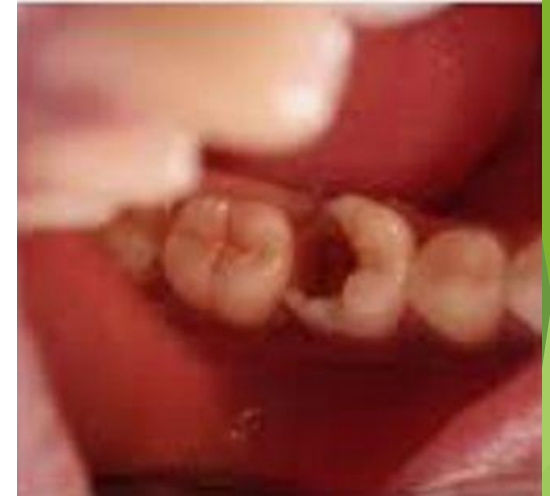These restorations usually involve the replacement of one or more missing cusps and require additional means of retention

Indications :

1- Definitive final restorations : if there is insufficient tooth structure, this can be managed by :

A-Usually indirect restoration to avoid fracture under mastication's

-B Complex amalgam restoration where additional retention features are used



2- foundation restoration : can be used under full coverage crowns on abutment teeth ,foundation may be amalgam , composite RMGI

3- Control restoration : used in questionable teeth that may need endodontic treatment , crown lengthening or has questionable periodontal prognosis to protect the pulp from fluid , bacteria & facilitates of control of plaque & caries with provided some resistance against tooth fracture

4- interim restoration :in case of occlusal rehabilitation (teeth wear &occlusal plane discrepancy)

Contraindication

1- the patient with significant occlusal problems

2- patient whose tooth cannot be restored properly with direct restoration because of anatomic or functional considerations or both

3- Esthetic

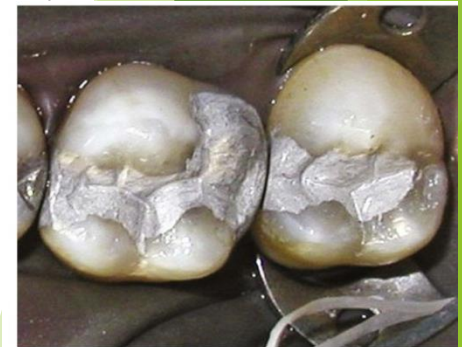

FIG. 16-1 Mesio-occluso-distolingual (MODL) complex amalgam tooth No. 3.

Pin Retained Amalgam Restoration

Definition:

Any restoration requiring the placement of one or more pins in dentin to provide a adequate resistance and retention forms

Advantage :

- 1- Greater retention than restoration relying only on bonding or undercut
- 2- important adjunct in restoration of teeth with extensive caries or fracture

Disadvantage

- 1- Nay create craze line or fractures and internal stress in dentin
- 2- Risk of perforation into pulp or external tooth surface
- 3- Decrease resistance of amalgam to tensile force



Thread Mate System : is mostly wide used self-threading pin

Types : gold plated stainless steel pins or Titanium

They are versatile (wide range of sizes , color coded & greater retention

pin size

Minuta	0.38mm	pink	Provided good retention in posterior teeth
Minikin	0.48mm	Red	Usually selected to reduce the risk of dentin crazing & perforation
minim	0.61mm	Silver	Used as a backup in case of pin lacks retention
Regular	0.78mm	Gold	Rarely used because a significant amount of stress and crazing or cracking in the tooth (enamel & dentin)

Pin design

-for each of four sizes of pins , several designs are available :

1- link series : recommended because of their versatility, self aligning ability and retentiveness

2- link plus

3- two-in-one

4- standard

5- self- shearing

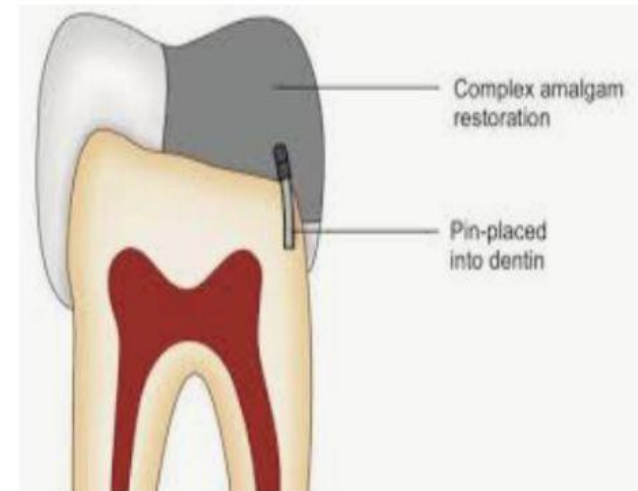
The self- shearing pin & self shearing two-in-one pin sometimes may be fail to reach the bottom of pinhole, whereas 93% of link series and link plus & two in –one pins can extended to optimal depth of 2 mm



Number of pins

Several factors must be considered when deciding how many pins are required:

- 1- the amount of missing tooth structure
- 2- the amount of dentin available to receive the pin safely
- 3- the amount of retention required
- 4- the size of pin
- 5- As the number of pins increases according to :
 - (i) The crazing of dentin and the potential for fracture increase
 - (ii) the amount of available dentin between the pins decrease
 - (iii) The strength of amalgam restorations decrease



Principles of pin location

- 1- Knowledge of normal pulp anatomy and external tooth contours
- 2- A current radiograph of the tooth
- 3- A periodontal probe
- 4- The patient's age

The following principles of the pin placement are recommended :

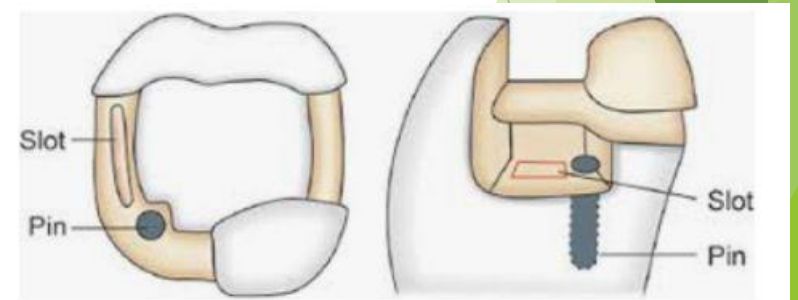
- 1- occlusal clearance should be sufficient to provide 2mm of amalgam over the pin
- 2- placement of the pin is ideal in the area where is the greatest bulk of amalgam would present to minimize the weakening effect of the pins
- 3- the pinhole should be no closer than 0.5-1mm to the DEJ or no closer than 1-1.5mm to the external surface of the tooth , whichever distance is greater
- 4-the pinhole should be parallel to the adjacent external surface of the tooth

5- A minimum of 0.5mm clearance is necessary around the circumference of the pin for a adequate condensation of amalgam

6- the pinhole must be placed on a flat dentinal floor

7- the minimal inter-pin distance is 3mm for the Minikin pin and 5mm for the Minim pin

8- whenever three or more pinholes are placed, they should be located at different vertical levels on the tooth

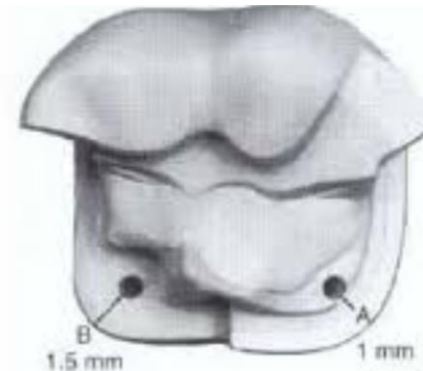


Pinholes preparation and insertion

- 1- when the pinhole locations has been determined , round bur is first used to proper a hole approximately one half of the bur at each location
- 2- A twist drill should be used for preparing pinholes with contra-angle handpiece rotating at a very low speed (300-500 rpm)
- 3- the optimal depth of the pinhole into the dentin is 2mm.

Two instruments are available for the insertion of threaded pins :

- (i) Conventional latch –type contra-angle handpiece
- (ii) TMS hand wrenches



Pinhole position. A, Position relative to DEJ.
B, Position relative to external tooth surface.

Failure of Pin –retained Restorations

The failure of pin may be occur in different location :

- A- within the restoration (restoration fracture)
- B- At the interfere between the pin and the restorative material
- C- within the pin (pin fracture)
- D- At the interfere between the pin and the dentin
- E- Within dentin (dentin fracture)