
Difficult Problems in Thyroid Surgery

The successful diagnosis and treatment of thyroid disease is based on a thorough understanding of the normal anatomic and physiologic features of the thyroid gland. This is especially true for patients who require surgical intervention for thyroid disease. Like all operative procedures, thyroidectomy has the potential for complications, but this risk can be minimized. To achieve this goal, knowledge of the thyroid anatomic and physiologic features is needed to apply the indications for thyroid operations, to provide adequate preoperative assessment, to choose the most suitable anesthetic, and to perform a technically precise operation. With proper training and experience, the risks of thyroidectomy can be eliminated for most patients and reduced in all patients.

Historic Aspects

Until just over 100 years ago, thyroid operations were undertaken under very primitive conditions and with great trepidation because they had little chance of success. The first credible accounts of thyroid operations come from the School of Salerno in Italy in the writings of Roger Frugardi that were published in approximately 1170.¹ These operations had many complications and were often fatal. In 1718, Lorenz Heister of Altdorf and Helmstadt, Germany, wrote an account that differed little from that of Frugardi.¹ William S. Halsted in his extensive review entitled “The Operative Story of Goiter,” which was published in 1920, could trace only 8 reports of operative intervention for goiter between 1596 (the year of the first report) and 1800. In 1846 Liston, who had performed 5 thyroid operations, wrote that there was a grave risk of death from hemorrhage and that it was “a proceeding by no means to be thought of.” In 1848 Johann Dieffenbach of Berlin stated that it was “one of the most thankless, and most perilous undertakings.” The outcome of thyroid surgery was so poor that the French Academy of Medicine banned its practice in 1850.¹

In 1871, Green reported 3 of the first successful thyroidectomies in

America. He summarized the surgical opinion at that time by stating, “It is and always will be exceedingly rare that any such interference is warrantable; *never*, for the relief of deformity or discomfort merely; *only*, to save life.”^{2,3}

A revolution in operations and surgical technique occurred during the latter half of the 19th century, and this had a major impact on the development of thyroid operations. A thorough understanding of the thyroid’s anatomic and pathologic features became key to decreasing morbidity during thyroidectomy. This (along with the introduction of anesthesia in 1846, antiseptics in 1867, and general improvements in surgical technique and instrumentation) was crucial for the development of safe thyroid procedures.¹⁻³

Thyroid operations owe their development to specific contributions from some of the greatest surgeons of the 19th century. Theodor Billroth who held the Chair of Surgery in Zurich from 1861 to 1867 performed 59 operations for goiter and rigorously reviewed his results. Forty percent of his patients died, including 7 patients who died of sepsis. Because of these results, he practically abandoned thyroid operations until 1877 when antiseptic techniques were widely adopted. After moving to Vienna, Billroth reported performing 16 thyroidectomies, including 12 lobectomies and 4 total thyroidectomies. All 16 of his patients survived. These results encouraged Billroth to operate on the thyroid more often and to attempt more difficult procedures. Anton Wolfler, Billroth’s assistant, recognized the risk of injury to the recurrent laryngeal nerves during thyroidectomy and developed techniques to protect the nerve while performing thyroidectomies in laboratory animals.¹

Theodor Kocher, Billroth’s junior by 12 years, was appointed the Chair of Surgery in Berne Switzerland in 1872. He identified “cachexia strumipriva” or what is now recognized as myxedema in 30 of 100 of his patients who had undergone total or near total thyroidectomy. In 1883 Kocher advocated lobectomy rather than total thyroidectomy to avoid this complication. Kocher provided many contributions to thyroid operation, including the use of the transverse collar incision, separation of the strap muscles, mobilization of the thyroid lobe after ligation of the lateral veins, and meticulous hemostasis. These are the basic techniques of thyroid operation that are still used today.³ Recognition of his contributions in this field culminated in 1909 when Kocher was awarded the Nobel Prize in Medicine.²

William S. Halsted, Professor of Surgery at Johns Hopkins University, refined the techniques of his contemporaries and contributed some of his own unique innovations to thyroid surgery. Halsted studied and, in 1907,

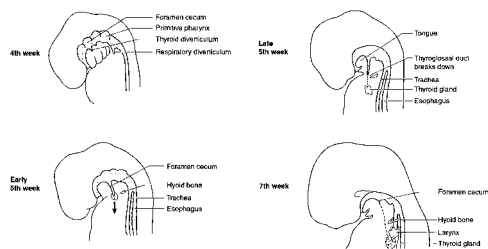


FIG 1. The thyroid develops from the foramen cecum and migrates inferiorly. During week 5 of life, the thyroglossal duct is fragmented. By week 7, the thyroid gland has migrated to its final resting position.

described the surgical anatomy and blood supply to the parathyroid glands.¹ He advocated partial resection rather than total lobectomy to protect the parathyroid glands and the recurrent laryngeal nerves. He also avoided lateral ligation of the inferior thyroid artery to prevent ischemia of the parathyroid glands.¹ Although much has been learned about the physiologic and pharmacologic aspects of the thyroid gland during the 20th century, the basic surgical techniques for thyroidectomy were developed by these pioneering surgeons. It is their contributions that have made thyroid operation in experienced hands safe and effective.

Embryologic Development

During fetal development, the primordium of the thyroid gland first appears in the late fourth week of gestation as a solid mass of endoderm. It develops at the apex of the foramen cecum on the floor of the pharynx at the level of the first pharyngeal pouch. Evagination of this thickening forms a bilobed diverticulum that will later become the thyroid gland. The thyroid primordium descends through the tissues of the neck at the end of the thyroglossal duct. The thyroglossal duct can remain as a vestigial connection between the thyroid gland and the foramen cecum. During the end of the fifth week of development, the thyroglossal duct is fragmented and loses its lumen. By the seventh week, the thyroid gland, now consisting of lateral lobes connected by the isthmus, continues its descent to its final position, inferior to the cricoid cartilage (Fig. 1).^{4,5}

Understanding the embryogenesis of the thyroid is the first step in anticipating the more common anatomic variations that may be encountered during neck operations. Several developmental types of anomalies can occur with the thyroid. Occasionally during embryogenesis, a portion of the duct persists that results in the formation of a thyroglossal duct cyst.

TABLE 1. Symptoms commonly associated with thyroglossal duct cysts

| |
|----------------------------------|
| Painless midline mass |
| Midline mass fluctuating in size |
| Dysphagia |
| Infected fistula |
| Mid-neck tenderness |
| Cough |

TABLE 2. Differential diagnosis for a midline neck mass

| |
|-------------------------------|
| Thyroglossal duct cyst |
| Dermoid cyst |
| Pyramidal lobe of the thyroid |
| Thyroid adenoma |
| Thyroid carcinoma |
| Goiter |
| Aberrant thyroid tissue |
| Branchial cleft cyst |
| Lipoma |
| Lymphadenopathy |
| Hemangioma |
| Lymphangioma |
| Sebaceous cyst |
| Teratoma |
| Tuberculosis |
| Salivary gland tumor |

Either the lack of, or an abnormal descent of, the gland may result in ectopic tissue and accessory thyroid nodules, whereas developmental failure of part of the gland may result in thyroid hemigenesis.^{6,7}

Thyroglossal Duct Cyst

Thyroglossal duct cysts result from the persistence and cystic expansion of the remnants of the thyroglossal duct, which normally obliterates during the fifth week of gestation. Because of the distinct embryologic basis for their formation, thyroglossal duct cysts usually have a classic appearance. An asymptomatic, slow-growing, mobile, palpable midline neck mass that moves with deglutition is typical. Other symptoms may include a mass that fluctuates in size, dysphagia, mid-neck tenderness, an infected persistently draining sinus, and/or cough (Table 1).^{8,9} Although congenital thyroid anomalies account for most midline neck masses, clinicians must consider other possible causes for masses in this location to diagnose and treat them correctly (Table 2). Dermoid cysts are the

second most common type of midline neck cyst and can be confused as a thyroglossal duct cyst. Although surgical treatment for a dermoid cyst is recommended, much less dissection is required to ensure complete removal than for a thyroglossal duct cyst.¹⁰

Thyroglossal duct remnants may manifest at any age, although more than one half of the patients are seen before age 20.^{6,11}

Male and female patients are affected equally. Approximately 1% of thyroglossal duct cysts undergo neoplastic change, with most tumors (85%) being papillary adenocarcinoma. Squamous cell, anaplastic, and Hürthle cell carcinoma have also been reported in thyroglossal duct cysts.⁸ Most thyroglossal duct cysts (61%) are located between the hyoid bone and thyroid cartilage, with the remaining cysts being intralingual, suprahyoid, and suprasternal. Ultrasonography or scintigraphy may be used to exclude ectopic thyroid tissue within the cyst. Ultrasound scanning can also be used to identify a solid midline neck mass, such as a Delphian node. Surgical excision of the cyst is the usual treatment, unless it contains the patient's only functioning thyroid tissue.⁶

Walter Sistrunk from the Mayo Clinic described the now classic surgical treatment for a thyroglossal duct cyst. The "Sistrunk operation" consists of en bloc removal of the cyst and central hyoidectomy so that the tract can be excised up to the foramen cecum. Sistrunk emphasized the need to isolate the suprahyoid portion of the duct because "... the tract usually passes through the hyoid bone"¹²

Ectopic Thyroid Tissue

Ectopic thyroid tissue has been found mainly in midline locations. Approximately 90% of ectopic thyroid tissue occurs at the base of the tongue.¹³ Williams and colleagues¹⁴ reported that ectopic thyroid tissue occurred between the foramen cecum and the thyroid, with a prevalence of 0.17 per 1000 autopsy specimens in adults. Rare locations in which ectopic thyroid tissue has been reported to occur include the gallbladder, porta hepatis, duodenal wall, fallopian tubes, and vagina.^{13,15-18} The normal embryologic descent of the thyroid explains its occurrence along the thyroglossal duct tract. However, ectopic tissue outside of this vestige is difficult to explain. Several theories have been proposed for ectopic tissue in the mediastinum, such as over descent of thyroglossal duct remnants. For subdiaphragmatic locations, a possible dual differentiation from a common totipotential endodermal precursor cell of the gut that allows the development of these germ cells into thyroid tissue has been suggested.¹⁵ However, given the rarity of the occurrence of ectopic

TABLE 3. Prevalence of thyroid hemiagenesis

| First Author | Date | No. of cases | Total population | Ratio |
|--------------|------|--------------|------------------|--------|
| Autopsies | | | | |
| Ehlers | 1886 | 15 | 300 | 1:20 |
| Marshall | 1895 | 1 | 60 | 1:60 |
| Harada | 1972 | 0 | 1007 | 0 |
| Surgery | | | | |
| Stierlin | 1912 | 5 | 7000 | 1:350 |
| Mayo Clinic | 1935 | 5 | 45,367 | 1:9073 |
| Spencer | 1949 | 1 | 1000 | 1:1000 |
| Heimann | 1967 | 5 | 7000 | 1:350 |
| Makiuchi | 1971 | 5 | 3026 | 1:605 |
| Harado | 1972 | 7 | 12,456 | 1:1779 |
| Imaging | | | | |
| Andrew | 1968 | 7 | 708 | 1:101 |
| Hamburger | 1970 | 4 | 7000 | 1:1750 |
| Maganini | 1977 | 1 | 1700 | 1:1700 |
| Friedman | 1979 | 6 | 12,000 | 1:2000 |
| Mariani | 1980 | 13 | 14,660 | 1:1128 |
| Saadi | 1981 | 18 | 30,000 | 1:1667 |
| Melnick | 1981 | 3 | 1000 | 1:333 |
| Bergami | 1995 | 2 | 2000 | 1:1000 |

Adapted from Mikosch P, Gallowitsch HJ, Kresnik E, Molnar M, Gomez I, Lind P. Thyroid hemiagenesis in an endemic goiter area diagnosed by ultrasonography: report of sixteen patients. *Thyroid* 1999;9:1075-84.

thyroid tissue, the possibility of metastatic thyroid carcinoma must be considered whenever this condition is encountered.

Thyroid Hemiagenesis

Thyroid hemiagenesis was first reported by Handfield-Jones in Britain in 1866.^{19,20} Marshall described the first patient in the United States with this rare congenital anomaly in 1895.²⁰ Mikosch and colleagues²⁰ reviewed the world literature, which consisted of 256 patients, in 1999. The true prevalence of this anomaly is difficult to determine because most cases are found coincidentally when other thyroid diseases or neck problems are being evaluated. However, hemiagenesis is a very rare congenital anomaly.^{21,22} Information from autopsy, operation, and imaging studies varies considerably, with the prevalence ranging from 1:20 to 1:9073 patients (Table 3).²⁰ Thyroid hemiagenesis occurs more frequently in female patients than male patients, with a ratio of 3:1. Because hemiagenesis is most often diagnosed coincident with the occurrence of other thyroid conditions, this ratio may be based on a bias because of the female predominance in most thyroid disorders.²⁰ Usually the left lobe is involved (absent in approximately 68%-80% of the patients).²³

Several different theories have been proposed to explain how abnormal development of the thyroid gland leads to hemiagenesis. Hamburger and Hamburger²⁴ reported in 1970 that frequently the right lobe is relatively larger than the left lobe. Therefore, thyroid hemiagenesis could represent the extreme of this asymmetry, which is caused by a marked imbalance in the differential growth of the bilobed thyroid during embryologic development.²⁴

Thyroid hemiagenesis appears to have a genetic component to its occurrence because there are reports of this rare disorder occurring in monozygotic twins, in sisters, and with other thyroid malformations within a single family.²⁰ Given that thyroid hemiagenesis frequently occurs in association with other pathologic conditions (including primary hypothyroidism, hyperthyroidism, adenocarcinoma, and thyroiditis), a complex disturbance of the embryologic development of the thyroid gland and other neck structures may account for its pathogenesis.^{19,20} A conclusive explanation for the occurrence of thyroid hemiagenesis has not been established thus far.²⁰ Scintigraphy will show uptake only in the contralateral lobe, but ultrasound scanning is needed to prove the absence of any thyroid tissue in the involved side of the neck. The clinical importance of thyroid hemiagenesis is that mild to moderate enlargement of the contralateral lobe may be compensatory hypertrophy and not pathologic. Contralateral lobectomy is likely to remove all of the patient's functioning thyroid tissue and should be avoided unless the patient is symptomatic or has a risk of cancer.

Anatomic Features: Surgical Aspects

Aside from the various thyroid anomalies that occur, there are several anatomic considerations that the surgeon must take into account when performing thyroid operations. The surgeon must be familiar with the normal anatomy of the neck and the anatomic course and position of the laryngeal nerves and the location and blood supply of the parathyroid glands.

The thyroid gland normally lies adjacent to the thyroid cartilage and anterolateral to the larynx and trachea (Fig 2). The gland weighs approximately 15 to 25 g and consists of 2 lateral lobes joined anteriorly by the isthmus.²⁵ The isthmus is approximately 1.25 cm in transverse and vertical dimensions and generally overlies the second and third tracheal rings.² The 2 lateral lobes of the gland are approximately 5 cm long and 2 to 3 cm in transverse and posterior dimensions.² Each lateral lobe of the thyroid gland is bordered posteromedially by the trachea and esophagus, posterolaterally by the carotid sheath, and anterolaterally by the sterno-

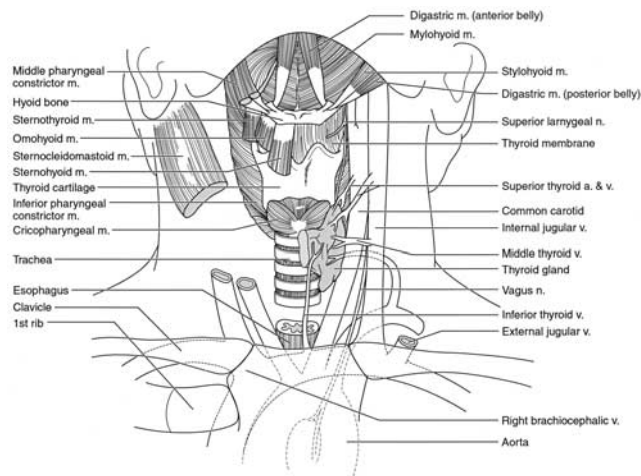


FIG 2. Anatomic position of the thyroid gland.

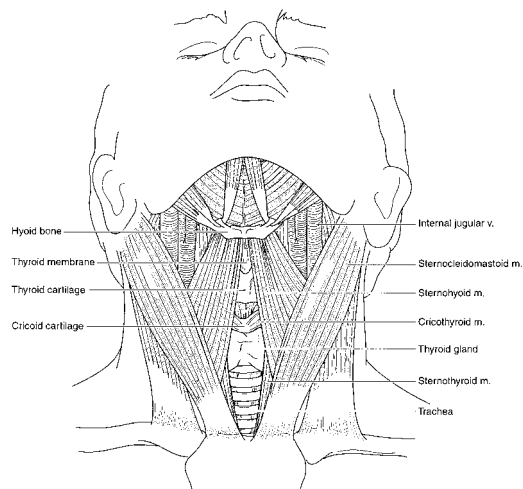


FIG 3. The thyroid gland is bordered posteromedially by the trachea and esophagus, laterally by the carotid sheath, and anteriorly by the strap muscles.

cleidomastoid and strap muscles (the sternohyoid, sternothyroid, and omohyoid muscles; Fig 3). The sternohyoid muscles act because of their insertion on the thyroid cartilage as a barrier that prevents upward extension of the superior pole as the thyroid gland enlarges. The strap muscles are innervated by the ansa cervicalis. The ansa is formed from the

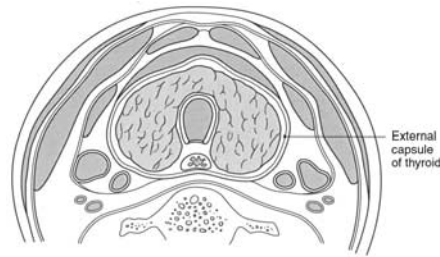


FIG 4. The thyroid gland is invested by a thin layer of connective tissue that is developed from the pretracheal fascia, which serves as a capsule.

descendens hypoglossi, which is composed of C₁ fibers, and the descendens cervicalis, which is composed of C₂ and C₃ fibers. A pyramidal lobe is present in approximately one half of all adults. This lobe extends for a variable distance up toward the hyoid bone and is more commonly found to the left of the isthmus.²

The thyroid gland is invested by a thin layer of connective tissue that is derived from pretracheal fascia, which serves as a capsule (Fig 4). This fascia forms the anterior suspensory ligament of the thyroid above the isthmus. Posteromedially, it is usually condensed and attached firmly to the first few tracheal rings and cricoid cartilage. This posteromedial suspensory ligament is called the *ligament of Berry* and is anatomically important because of its location relative to the recurrent laryngeal nerve (Fig 5). The recurrent laryngeal nerve passes deep to the ligament on its course to the larynx. A branch of the inferior thyroid artery often crosses the ligament. If not carefully ligated, bleeding from this vessel can be troublesome. Indiscriminate clamping to control bleeding from this branch or from the vessels in the vicinity of the ligament can cause recurrent laryngeal nerve injury. Slow, careful bloodless dissection is required in this area so that the recurrent laryngeal nerve can be seen and protected.

The thyroid is a very vascular organ that is supplied by 4 main arteries: 2 superior thyroid arteries and 2 inferior thyroid arteries (Fig 6). The superior thyroid arteries are usually the first branch off the external carotid arteries, just above the bifurcation of the common carotid arteries. These arteries give origin to the superior laryngeal arteries and then descend medially on the surface of the inferior pharyngeal constrictor muscles to divide into anterior and posterior branches on the anteromedial surface of the upper pole of each lobe of the thyroid.²⁵ The superior

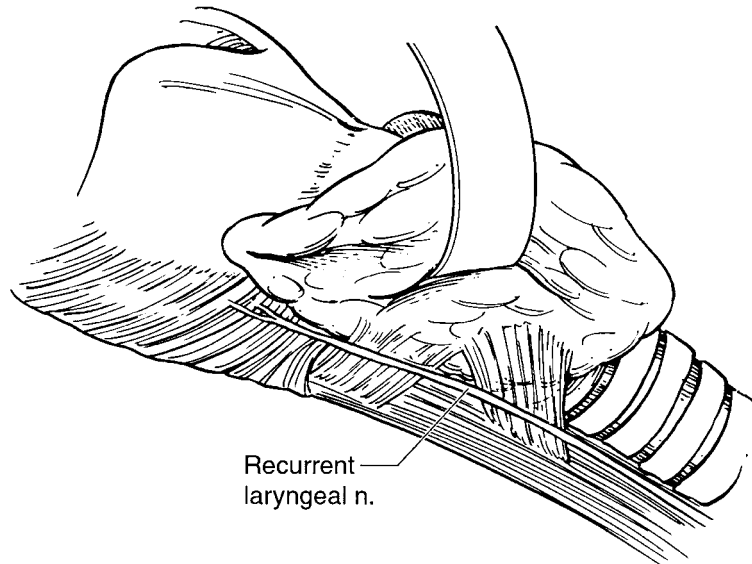


FIG 5. Posteromedial condensation of the pretracheal fascia and its relationship to the recurrent laryngeal nerves.

thyroid artery is anatomically closely related to the external branch of the superior laryngeal nerve (Fig 7).

The inferior thyroid arteries generally arise from the thyrocervical trunks just distal to their origin from the subclavian arteries. They run behind the carotid sheathes to the level of the cricoid cartilage and then pass downward and medial to reach the middle portion of each thyroid lobe. Each artery usually trifurcates into an inferior, posterior, and internal branch before entering the thyroid gland.² The relationship of the inferior thyroid artery to the recurrent laryngeal nerve is surgically important. The course of the inferior thyroid artery relative to the inferior laryngeal nerve is variable; it may pass over, under, or between the branches of the nerve in its course to the larynx (Fig 8). The inferior thyroid artery also provides the main blood supply to both the superior and inferior parathyroid glands in most individuals.

Thyroid ima arteries may arise from either the innominate artery or the aorta and enter the lower surface of the isthmus.² Rarely, thyroid ima vessels may replace an absent inferior thyroid artery to supply the inferior pole of the gland. The frequency of the occurrence of thyroid ima vessels has been overemphasized, especially because there is little, if any, danger associated with their ligation and transection. These vessels can cause

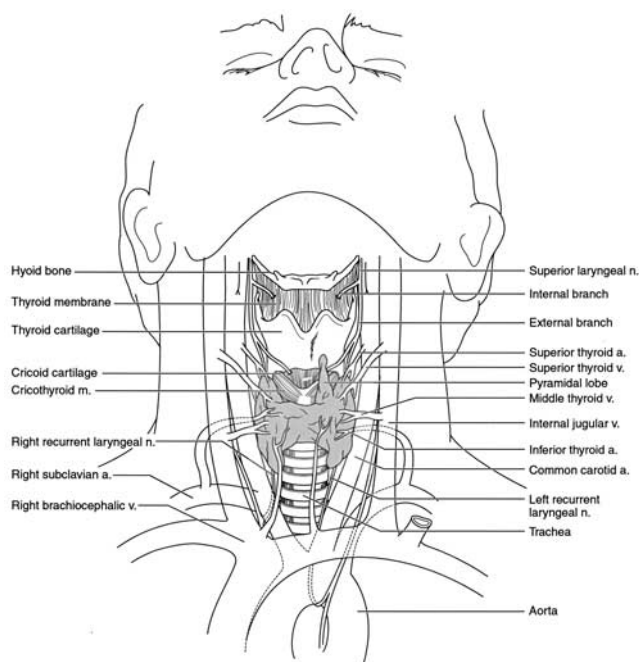


FIG 6. Arterial supply of the thyroid gland.

problems if they are torn and retract into the mediastinum when large goiters are resected, especially those large goiters that are substernal. The resulting hemorrhage can be difficult to control through the cervical incision.

The venous drainage of the thyroid gland is more variable than the arterial supply but is mainly through 3 pairs of veins. The superior thyroid veins run just anterior and lateral to the superior thyroid arteries and empty into the internal jugular veins. The middle thyroid veins drain directly into the internal jugular veins and, when present, must be divided and ligated when medial mobilization of the thyroid gland is performed. The inferior thyroid veins drain the lower aspect of each lobe. Several trunks may be present that can form a plexus. They drain directly into the innominate or internal jugular veins.²⁶ These veins are thin walled but can dilate up to several times their normal size as the gland enlarges, especially in hyperthyroidism. They can cause substantial hemorrhage if they are torn or not carefully ligated during thyroidectomy. Follicular carcinomas can spread directly into and through these veins to the internal jugular or innominate veins. Distal control of the jugular and/or innominate vein is then necessary if hemorrhage or tumor embolus is to be

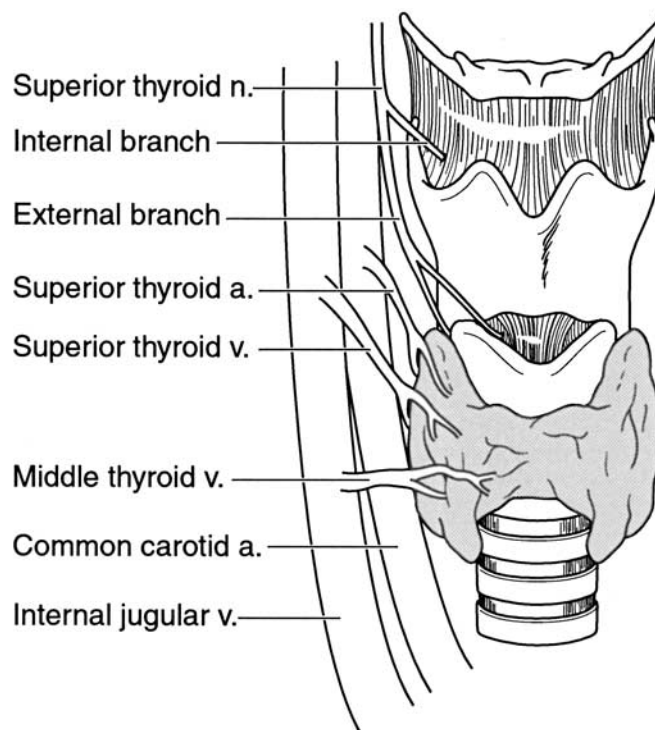


FIG 7. Close anatomic relationship of the external branch of the superior laryngeal nerve and the superior thyroid artery.

avoided during thyroidectomy when direct tumor growth into these veins has occurred.

The lymphatic drainage of the thyroid gland is important in the surgical treatment of thyroid carcinomas. The thyroid gland is richly endowed with lymphatic channels, and its lymphatic fluid may drain in many directions. The extensive lymphatic drainage from the thyroid flows to regional lymph nodes that are subgrouped according to location. The central compartment of the neck, which includes the lymphatic and soft tissues around the esophagus, is delineated inferiorly by the innominate vein, superiorly by the hyoid bone, laterally by the carotid sheaths, and dorsally by the prevertebral fascia. The central compartment contains pretracheal and paratracheal lymph nodes that drain the thyroid bed. These are termed level VI lymph nodes. Level I or the submandibular and submental groups of lymph nodes are included in the central compartment in some classifications. These level I lymph nodes are not usually

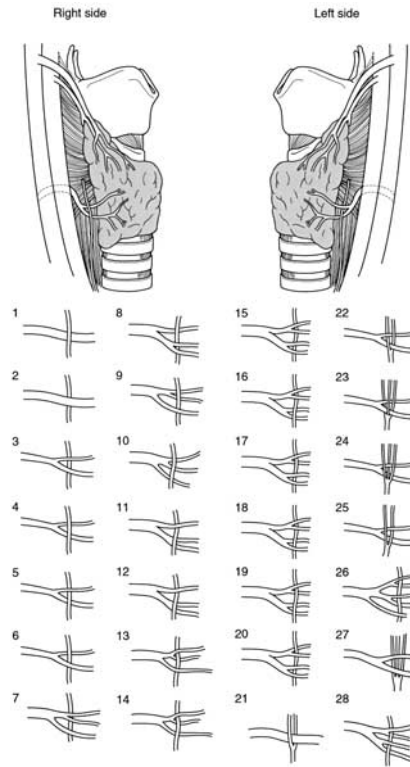


FIG 8. The relationship of the inferior thyroid artery relative to the inferior laryngeal nerve. The inferior laryngeal nerve can course under or over the main inferior thyroid artery or any of its branches as shown in the lower portion of the figure.

involved with thyroid cancer and are not removed with a central neck dissection unless clinically enlarged (Fig 9).

The lateral compartment is subdivided into an anterior and posterior compartment by the posterior border of the sternocleidomastoid muscle. This compartment is delineated superiorly by the hypoglossal nerve and inferiorly by the subclavian vein and includes the area between the carotid sheath, sternocleidomastoid muscle, and the trapezius muscle. The anterior compartment is divided cranially to caudally into the superior jugular lymph nodes (level II), midjugular lymph nodes (level III), and inferior jugular lymph nodes (level IV). Lymph nodes in the posterior triangle (level V) are bounded by the medial border of the trapezius muscle, the posterior border of the sternocleidomastoid muscle, and the subclavian vein. These lymph nodes are uncommonly involved with

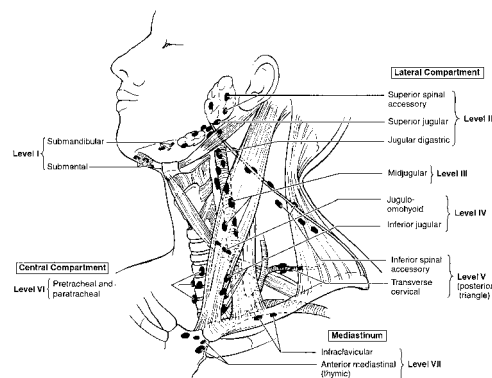


FIG 9. The extensive lymphatic drainage of the thyroid gland.

thyroid cancer but should be removed if they are enlarged. Level VII lymph nodes encompass the mediastinal lymphatic tissue, which consists of the infraclavicular and anterior mediastinal or thymic lymph nodes.^{27,28} These lower cervical and upper mediastinal lymph nodes can almost always be removed through a cervical incision. Median sternotomy is rarely necessary and is indicated only when the involved lymph nodes cannot be removed safely through a cervical incision.

Lymph node metastases from differentiated thyroid cancer occur in more than 70% of patients when a systematic neck dissection is performed.^{29,30} Noguchi and colleagues³¹ suggest that the pattern of nodal metastases in early thyroid carcinomas is directed downward and laterally toward the lower neck and the mediastinum. In advanced stages of disease, tumor metastases obstruct the lymphatic channels, and nodal spread begins to follow an upward direction toward the deep upper cervical nodes.³¹ Nodal metastases usually occur first in the ipsilateral neck. Tumor involvement can alter lymphatic flow, and metastases to the contralateral neck are not uncommon as the disease becomes more advanced.

Although the number and position of the parathyroid glands may vary, there are typically 4 glands in close association with the posterolateral borders of the thyroid lobes. Variations in parathyroid anatomy are generally caused by differences in their patterns of embryogenesis. The superior glands are most often found on the posterior surface of the upper thyroid lobe, near the site where the recurrent laryngeal nerve enters the larynx. The inferior glands are generally more anterior and lie close to the inferior pole of the thyroid gland. The principal blood supply of both the superior and inferior parathyroid glands is derived from the

inferior thyroid artery. However, the parathyroid glands may also receive their blood supply from the thyroid ima arteries or from the anastomoses of vessels that supply the larynx, trachea, and esophagus. In 20% of patients, the superior thyroid artery will supply the superior parathyroid gland.² Each parathyroid gland generally has a single-end arterial supply. If the main trunk of the inferior thyroid artery is ligated during thyroidectomy, the viability of the parathyroid glands will be compromised. To preserve the blood supply to the parathyroid glands, the branches of the inferior thyroid arteries should be ligated beyond and medial to the vessels that supply them. If this cannot be accomplished, parathyroid autotransplantation should be performed.

The fascial planes of the neck are important because they form natural lines of cleavage through which the tissues may be separated. The deep fascia of the neck is made up of 3 layers: investing, pretracheal, and prevertebral fascia. The investing or superficial layer of the deep cervical fascia is located between the superficial fascia and the muscular layer. The pretracheal fascia lies anterior to the trachea and extends inferiorly from the thyroid cartilage and the arch of the cricoid cartilage. It lies deep to the infrahyoid muscles and splits to enclose the thyroid gland, trachea, and esophagus and laterally blends with the carotid sheath. Within the pretracheal fascia, the thyroid gland can be found investing the trachea anteriorly and laterally. The esophagus, which lies between the posterior aspect of trachea and anterior aspect of the vertebrae, is bounded laterally by the common carotid artery and the vagus nerve. Although the esophagus is primarily a midline structure, its course at this level of the neck deviates slightly to the left. The prevertebral fascia surrounds the prevertebral muscles of the vertebral column. It is also continuous with the deep fascia that covers the floor of the anterior and posterior triangle of the neck.³²

Recurrent Laryngeal Nerve

Routine identification of the recurrent laryngeal nerve during thyroidectomy greatly decreases the risk of nerve injury. An awareness of the potential course of the nerve is crucial for identifying it safely and exposing it atraumatically during the operation. The reported incidence of recurrent laryngeal nerve palsy varies from 0% to 14%.³³ Several factors influence the likelihood of injury to the nerve, including the underlying disease (ie, goiter vs malignancy), the extent of resection, and the experience of the surgeon. Iatrogenic injury to one nerve may be asymptomatic but often results in patient morbidity from hoarseness and reduced vocal range. Bilateral nerve injury results in complete voice loss,

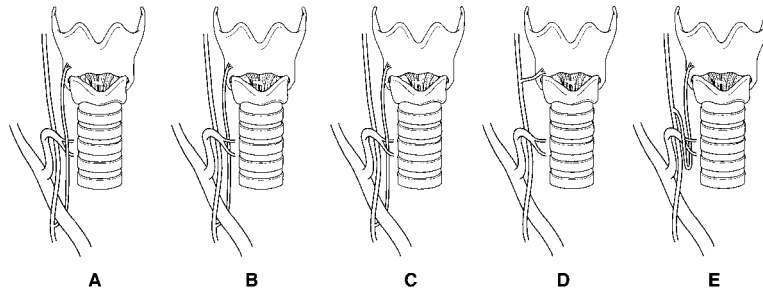


FIG 10. The course of the recurrent laryngeal nerve. **A, B,** and **C,** Common variations; **D,** nonrecurrent nerve; **E,** recurrent nerve around the inferior thyroid artery. (From Skandalakis JE, Droulias C, Harlaftis N, Tzinas S, Gray SW, Akin JT. The recurrent laryngeal nerve. *Am Surg* 1976;42:629-34.)

with or without major respiratory distress. If the vocal cords are fixed in the midline, the patient will have stridor and respiratory distress that will require tracheostomy. If the vocal cords are lax, respiratory difficulties may not occur until the cords become tense and fibrosed.³⁴

Surgeons who perform thyroidectomy must have a clear and complete understanding of the gross anatomic features of the recurrent laryngeal nerve. As the main trunk of the recurrent laryngeal nerve emerges from the superior thoracic inlet, it lies in a triangle bounded medially by the trachea and esophagus and laterally by the common carotid artery and internal jugular vein. The right recurrent laryngeal nerve has a somewhat more oblique course from lateral to medial in the central neck, whereas the left recurrent laryngeal nerve has a more vertical course along the tracheoesophageal groove. Skandalakis and colleagues³⁴ examined the course of the recurrent laryngeal nerve in 62 male and 40 female cadavers. Their findings are summarized in Fig 10. Before its entrance into the larynx, the recurrent laryngeal nerve will often branch, with a reported incidence that ranges from 1% to 73%.³⁵ Katz and Nemiroff,³⁵ in a study of 719 patients, found that 63% of the nerves bifurcated extralaryngeally and that if 1 side bifurcates, more than 39% of patients will have bilateral bifurcation. This extralaryngeal branching is extremely important from the surgical point of view. If this branching is not recognized, recurrent laryngeal nerve branches may be injured easily. For this reason, the importance of identifying the main trunk of the nerve before its point of possible division cannot be over-emphasized.

The relationship of the recurrent laryngeal nerve and branches of the inferior thyroid artery have also been studied carefully. Reed³⁶ identified the recurrent laryngeal nerve posterior to the inferior thyroid artery in

most patients on both the right (47.7%) and left sides (54.9%). Similar results were reported by Skandalakis and colleagues.³⁴ Sturiniolo and colleagues³⁷ found the recurrent laryngeal nerve behind the trunk of the inferior thyroid artery in 30.5% of their patients on the right and in 36.7% on the left. Likewise, they reported the respective configuration of the inferior thyroid artery to the recurrent laryngeal nerve overlapped on both sides in only 51.2% of their patients. Both nerves ran in front of the trunk of the artery in 23.4% of patients, among the branches in 12.6% of patients, behind the trunk in 6.3% of patients, in front of branches in 6.7% of patients, and behind the branches of the artery in 1.2% of cases. In the remaining 48.8% patients, the relationship between the 2 sides was completely different. The main point to remember is that the surgeon cannot rely on the recurrent laryngeal nerve being posterior to the inferior thyroid artery and must be wary of the presence of a more anterior nerve to avoid inadvertent injury.

The tubercle of Zuckerkandl is a thickening of thyroid tissue that is located at the most posterolateral edge of the thyroid gland (Fig 11). In 1904, Zuckerkandl described this anatomic landmark.³⁸ The importance of Zuckerkandl's tubercle lies in its close anatomic relationship with the recurrent laryngeal nerve and the parathyroid glands. Normally, the recurrent laryngeal nerve will course posterior and lateral to the thyroid lobe. The tubercle of Zuckerkandl can extend sufficiently posterior to end up behind the nerve. In other words, as the thyroid tissue enlarges in a Zuckerkandl tubercle, the recurrent laryngeal nerve can be elevated out of the posterior neck and end up in an anterior position, where it is at great risk of injury unless the anatomic distortion is recognized. Likewise, the superior and inferior parathyroid glands can be elevated to a more anterior position by this posterolateral extension of thyroid tissue and be at greater risk of inadvertent removal or devascularization in the setting of a prominent or enlarged tubercle of Zuckerkandl.^{38,39} Extreme care and technical precision must be used when this area of the thyroid gland is mobilized because of the possible injury that may occur to the recurrent laryngeal nerve and parathyroid glands.

Despite the fact that both the ligament of Berry and the point of entrance of the nerve into the larynx are relatively fixed, the relationship of the recurrent nerve with the ligament of Berry is somewhat inconstant. This has been attributed to differences in the size of the suspensory ligament and/or variations in the course of the recurrent nerve in the tracheoesophageal groove.⁴⁰ During thyroidectomy, the recurrent laryngeal nerve is at great risk during the ligation of this ligament.^{41,42} Therefore, the

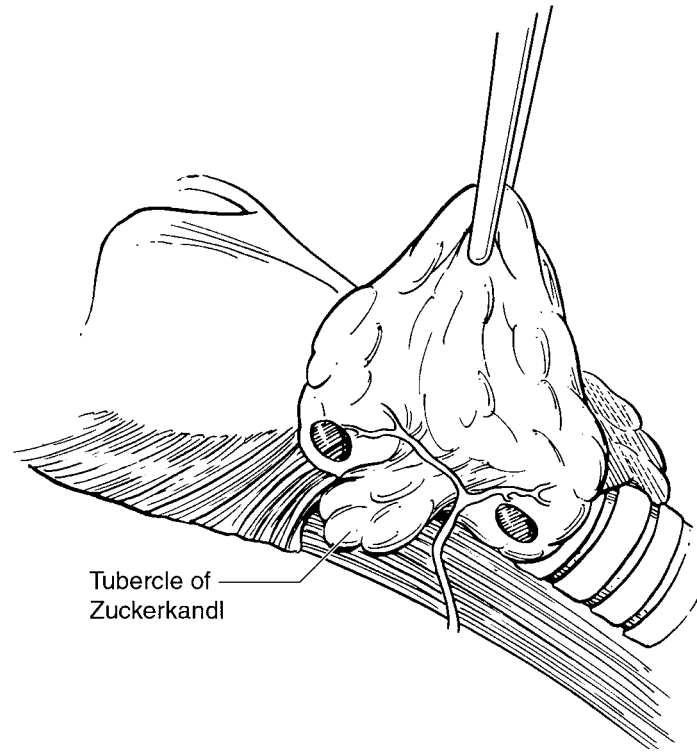


FIG 11. The tubercle of Zuckerkandl lies at the most posterolateral edge of the thyroid gland. The importance lies in its close anatomic relationship with the recurrent laryngeal nerve and the parathyroid glands.

suspensory ligament of Berry should be ligated only after the nerve has been visualized directly.

Superior Laryngeal Nerve

The superior laryngeal nerve originates from the vagus nerve just outside the jugular foramen of the skull. It passes inferior and medial to the carotid arteries and divides at the level of the hyoid bone. The larger internal laryngeal nerve provides sensory branches to the mucosa of the larynx. The smaller external laryngeal nerve provides motor innervation to the cricothyroid muscle, which regulates the tension of the vocal cords and is extremely important in providing a normal voice.⁴³⁻⁴⁵ If this nerve is damaged, the ability to project the voice may be lost. In 1930 a world-renowned opera singer's career was terminated because of injury to the superior laryngeal nerve after a thyroidectomy for benign disease.

Because of this, the external branch has been called the “the nerve of Amalita Galli Curci.”⁴⁵ Unilateral injury to the nerve results in a flaccid ipsilateral vocal cord that bulges on expiration and retracts on inspiration. This will change the timber of the voice and markedly diminish the capacity to project any loudness. Bilateral injury can result in a hoarse, monotonous voice that fatigues easily.^{43,46}

Because of its superior location, the internal branch of the superior laryngeal nerve is rarely subject to injury during thyroidectomy. However, it may be placed in jeopardy when an enlarged superior pole of the thyroid gland extends above the upper border of the thyroid cartilage. A high mass ligation of the superior thyroid artery and vein can then transect or damage this nerve. When the internal laryngeal nerve is injured, sensation to the upper one half of the larynx will be impaired.⁴⁷ This loss of sensation may cause swallowing difficulties that result in choking and aspiration pneumonitis.⁴³

The external branch of the superior laryngeal nerve runs in close proximity to the superior thyroid artery and is therefore vulnerable when the vessels of the superior pole are ligated, even when this pole is not enlarged. Various operative strategies have been proposed to avoid injury to the external superior laryngeal nerve. Some authors advocate routine identification of the nerve.⁴⁸ Others advocate skeletonizing the superior pole vessels while being careful not to dissect the nerve from the fibers of the pharyngeal constrictor muscles.³ In 50 cadaveric specimens, Lennquist and colleagues⁴⁶ showed that 20% of external superior laryngeal nerves run through the fibers of the pharyngeal constrictor muscle, which necessitates intramuscular dissection for nerve identification. Therefore, routine identification of the external branch of the superior laryngeal nerve would mean dissection into the well-vascularized pharyngeal constrictor muscles in one fifth of the patients; this would cause an increased risk of bleeding and added scarring. Twenty-three percent of the nerves identifiable without intramuscular dissection run partly lateral to the superior thyroid artery and its branches, a location that may result in definite injury without careful dissection. The nerve is put at risk for paresis by blind clamping of vessels and imprudent use of electrocautery. Rarely, even caudal retraction of the upper pole to divide and ligate the superior thyroid vessels may cause transient paresis.⁴⁵ One may minimize the potential risk to the nerve by dividing the individual branches of the superior thyroid vessels as they enter the thyroid capsule.

Nonrecurrent Laryngeal Nerve

Although a nonrecurrent laryngeal nerve is a rare finding, failure to recognize it can lead to inadvertent injury with serious repercussions.⁴⁹ A nonrecurrent laryngeal nerve was first described more than 150 years ago. This variant has a reported incidence of 0.3% to 0.8%,⁵⁰ and it occurs on the left side much less commonly, with a reported incidence of 0.04%.⁴⁹

The presence of nonrecurrent laryngeal nerves can be explained by anomalous embryologic development of the arterial system. In the normal embryo, the right and left recurrent inferior laryngeal nerves supply the sixth branchial arches. They pass beneath the sixth aortic arch and ascend to the larynx as the heart descends. On the right side, the recurrent nerve moves up as the fifth and sixth arches involute and disappear. It then lies beneath the fourth arch, which forms a part of the subclavian artery. The distal portion of the sixth arch persists on the left to form the ductus arteriosus, which prevents upward movement of the left recurrent nerve.⁵⁰

An anomalous origin of the right subclavian artery from a point distal to the left subclavian artery may occur. This results when the right fourth aortic arch and the proximal right dorsal aorta are obliterated. The right recurrent inferior laryngeal nerve is then free to move upward as it comes directly off the main vagal trunk and forms a nonrecurrent laryngeal nerve.⁵⁰ For a left nonrecurrent laryngeal nerve to occur, there must be situs inversus, and the ligamentum arteriosus must occur on the right side.⁴³ This vascular anomaly is very unusual, which explains the rare occurrence of a left-sided nonrecurrent laryngeal nerve.

When a nonrecurrent inferior laryngeal nerve occurs, the ipsilateral recurrent inferior nerve is usually absent. However, coexistence of both recurrent and nonrecurrent inferior laryngeal nerves has been described.^{31,32} The observation of an unusually thin recurrent nerve should remind the surgeon of the possibility of a nonrecurrent nerve.

Surgical Technique

Whether a total thyroidectomy or lobectomy is performed, the key to success is an organized methodic approach with adequate exposure. There are 4 key steps to the performance of a thyroidectomy: (1) exposure of the thyroid gland within the central neck, (2) takedown of the upper pole vessels, while protecting the superior laryngeal nerve, (3) mobilization and dissection of the lateral lobe with preservation and protection of the recurrent laryngeal nerve and parathyroid glands, and (4) closure with meticulous hemostasis.

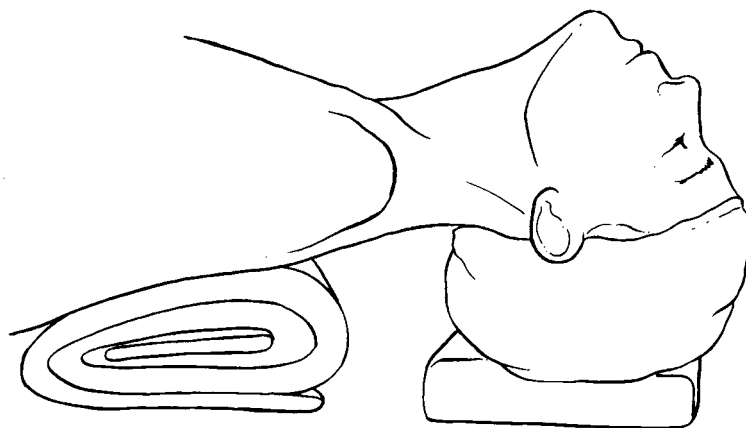


FIG 12. The patient is placed supine with a soft roll placed beneath the shoulders with adequate support underneath the head.

Thyroid Gland Exposure

Although local anesthesia and cervical block have been used for thyroidectomy, our preference is general anesthesia. Many patients will have tracheal deviation and/or compression of the trachea as the result of the mass effect from an enlarged thyroid. These can cause airway problems that can challenge the anesthesiologist who must intubate the patient. An awake or fiberoptic intubation may be necessary to secure a difficult airway before anesthetizing the patient. The airway can also be lost to laryngeal edema or spasm that may occur when the attempt is made to intubate these patients. Although an inability to obtain an airway is rare with experienced anesthesiologists, the surgeon must be available and ready to provide one by means of an emergency tracheostomy, cricothyroidotomy, or needle tracheotomy if the patient is not being oxygenated.

After the induction of general anesthesia, the patient is placed supine with a roll of soft towels placed transversely beneath the shoulders to allow the head and neck to fall back and be extended (Fig 12). Care must be taken not to over-extend the neck and to provide adequate support underneath the head. Spinal cord traction and compression can occur if there is excessive extension and inadequate support. This can lead to major and permanent neurologic deficits, which include quadriplegia. The operating table is placed in a chaise lounge position with the head of the patient elevated approximately 10 to 15 degrees. This allows for improved exposure and increases venous return to reduce venous engorgement. The patient's hands and arms are placed at the side. Using mild

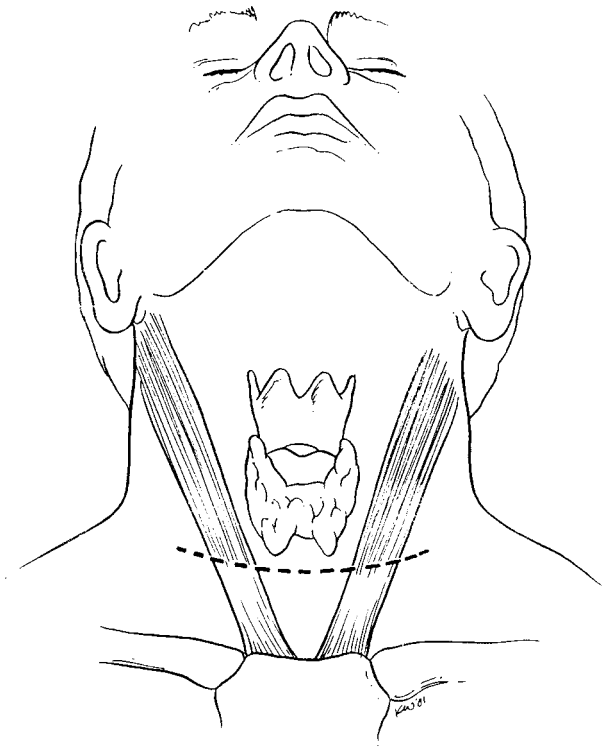


FIG 13. A cervical skin incision is made 1 to 2 cm above the suprasternal notch in the natural skin crease of the neck.

traction by means of a towel hooked around each wrist with the ends tucked under and behind the buttocks and hips of the patient, the shoulders are pulled inferiorly. This maneuver will hold the upper extremities in position and avoid any pressure injury to peripheral nerves. Care must be taken to avoid excessive traction or having the patient's body weight on the arms. Special padding may be needed for the elbows to avoid peripheral nerve injury.

A skin incision is made approximately 1 to 2 cm above the suprasternal notch. Ideally, this will be made in 1 of the natural skin creases of the neck. The level of the incision is important for good cosmesis (Fig 13). If the incision is placed too high, it may be noticeable when normal clothing is worn; if it is too low, exposure may be compromised. To assure proper position and symmetry, the line of incision should be measured and marked, with the sternal notch, thyroid cartilage, and mandibular notch as

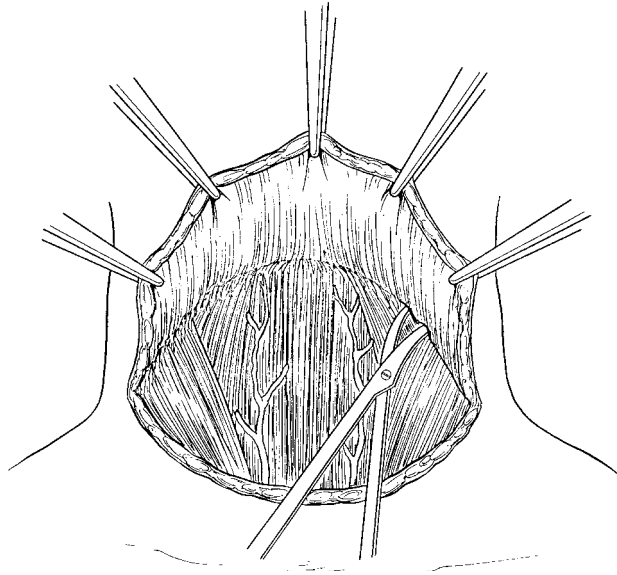


FIG 14. Subplatysmal flaps are raised to the sternal notch and clavicle inferiorly and the thyroid notch superiorly and onto the sternocleidomastoid muscles laterally.

points to identify the midline of the neck. The incision is then made in a lower neck skin crease with its midpoint centered on this line. The incision extends for an equal distance from 2.5 to 7 cm on each side of the midline, depending on the size and position of the thyroid to be removed and the patient's body habitus. The incision is carried down through the platysma muscle. Subplatysmal flaps are raised to the thyroid notch superiorly, onto the sternocleidomastoid muscle laterally, and to the sternal notch and clavicle inferiorly (Fig 14). Care must be taken not to make the flaps too thin or to make an inadvertent through-and-through button-hole cut in the skin because it will cause cosmetically unacceptable scarring. Patients with long thin necks are especially at risk for this complication at the superior aspect of the flap.

The gland is exposed by separating the strap muscles in the midline. This can be facilitated by starting the incision lower in the neck, where the midline is more obvious because the strap muscles tend to diverge from one another there (Fig 15). The strap muscles are retracted laterally to expose the entire anterior surface of the gland (Fig 16). The goal is to mobilize the strap muscles from the sternum and clavicle up to the upper extent of the superior pole of the gland at or above the insertion on the thyroid cartilage. Usually, these muscles separate quite readily from the

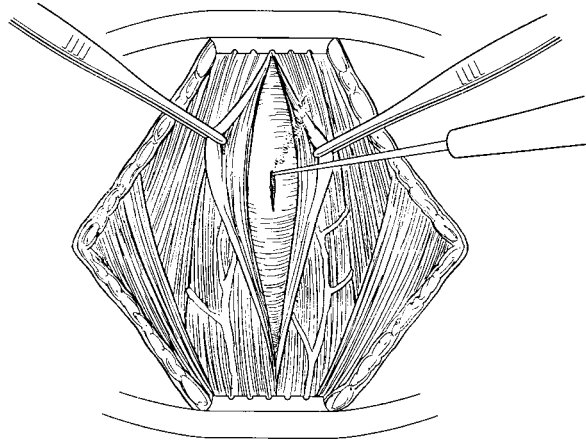


FIG 15. Exposure of the gland is achieved as the strap muscles in the midline are separated.

underlying thyroid. However, if there has been inflammation (such as with thyroiditis) or if there has been previous operation or hemorrhage from a needle biopsy, sharp dissection may be required to separate the muscles from the thyroid lobe. If the gland is so large that retracting the strap muscles does not provide adequate exposure, the muscles can be divided. It is important to preserve the innervation to the strap muscles at the lateral border of the sternothyroid when these muscles are divided. The ansa cervicalis innervates all 4 strap muscles. The strap muscles can usually be approximated, without difficulty, when the neck wound is closed if they have been divided and an enlarged lobe has been removed. If a patient has thyroid cancer, the surgeon should not hesitate to resect the overlying strap muscles if there is any question that they are involved or so close to the tumor that there would be an inadequate margin.

Dissection of Upper Pole and Superior Laryngeal Nerve

Upper pole mobilization requires division of the superior thyroid artery and vein. The difficulties with this maneuver are the risk of injury to the superior laryngeal nerve, which lies in close proximity to the vessels, and the risk of bleeding if the artery or vein retract superiorly out of view without being ligated securely (Fig 17). For this reason, adequate exposure is crucial for safe dissection, which can occur only if the superior pole is visualized clearly. Downward traction on the gland by the assistant is helpful, especially when dealing with large glands. If

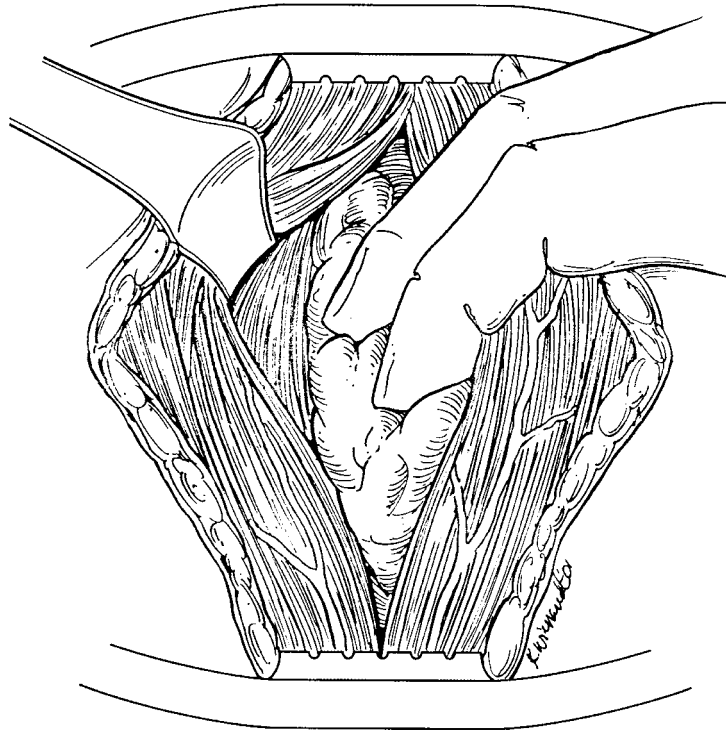


FIG 16. The strap muscles are retracted laterally to expose the gland.

separation and lateral retraction of the strap muscles does not provide sufficient visualization, the muscle overlying the superior pole should be cut until it is exposed clearly. Care must be taken not to lacerate or tear the underlying subcapsular veins, which can result in troublesome bleeding when a cut is made through this muscle.

There are 2 main approaches to protect the superior laryngeal nerve. First, the medial and lateral borders of the superior pole are mobilized. Lateral retraction of the strap muscles and the carotid sheath and medial retraction of the thyroid will allow blunt dissection of the largely avascular investing fascia to expose the lateral aspect of the superior pole. The upper pole is then retracted laterally while the cricothyroid muscles and larynx are pushed medially. The intent is to pull the upper pole out and away from the course of the superior laryngeal nerve. There is often 1 or more blood vessels that pass transversely through this plane of dissection that must be ligated and divided to free the medial aspect of the superior pole. Then the upper pole pedicle itself is mobilized. This is

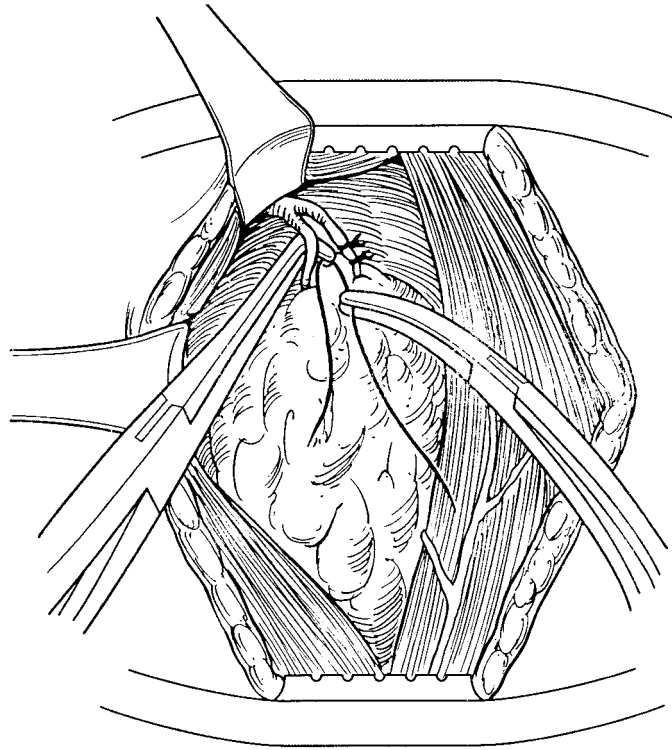


FIG 17. Upper pole mobilization with the division of the superior thyroid artery and vein.

achieved by dividing the individual branches of the superior thyroid vessels as low as possible as they enter the thyroid capsule. This lessens the potential for injury to the nerves at risk because it minimizes the problem of the proximity of the vessels to the nerve. When taking down the superior pole, any tissue that has a vertical orientation that can be pushed medially away from the upper pole tissue should be pushed away to avoid injury to the superior laryngeal nerve. A second technique, which we do not generally recommend, involves leaving a protective cuff of thyroid tissue at the upper pole. This can be satisfactory for the treatment of thyrotoxicosis or multinodular goiter. However, it is inadequate for the treatment of carcinomas. We believe there is a greater risk of bleeding from this cuff of thyroid tissue than if the vessels are ligated individually as they enter the thyroid capsule. We do not find it necessary to use this method even when dealing with large goiters.

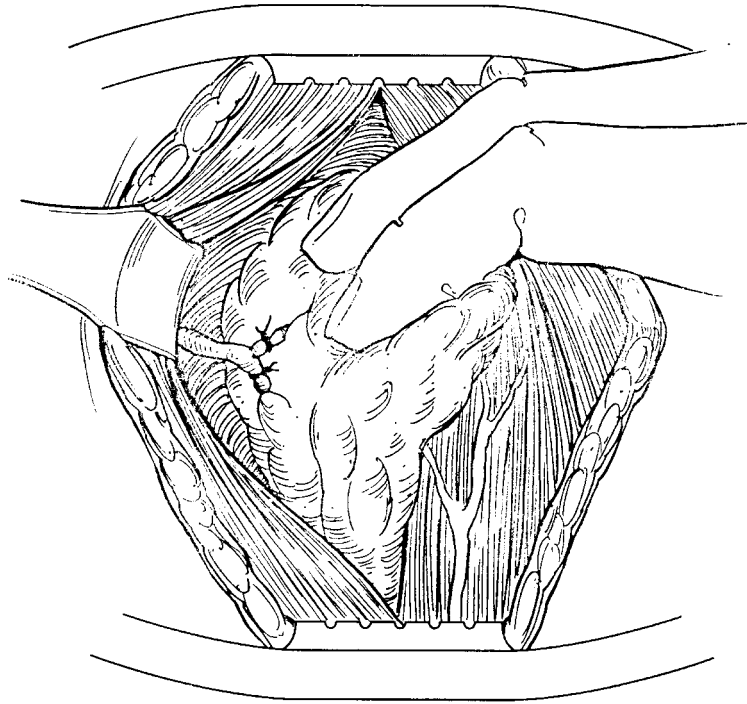


FIG 18. Lateral lobe dissection with retraction of the gland medially and ligation of the middle thyroid vein close to the gland.

Dissection of the Lateral Lobe

The lateral lobe of the thyroid is retracted medially. The lateral space between the thyroid and the carotid sheath is opened until the prevertebral fascia is encountered. The middle thyroid vein may be encountered at this time. This vein is fairly inconstant and may be absent or consist of several branches.²⁶ It should be ligated and divided as close as possible to its entry into the gland (Fig 18). The dissection for actual mobilization of the lobe should be right on the capsule, to avoid injury to the parathyroid glands and the recurrent laryngeal nerve. For malignancies that are locally invasive, the dissection should be extended as far away from the gland as necessary to resect it completely. The lobe is then rotated out of the neck with gentle traction. When the strap muscles and carotid sheath are retracted laterally, care must be taken not to occlude the carotid or to break off any atherosclerotic plaque by prolonged or forceful use of retractors.

When the thyroid gland is retracted medially and elevated out of the

wound, the capsule can be dissected and separated from the investing areolar tissue. The vessels are clamped as they penetrate the capsule and then are divided and individually ligated, progressing in a posterior direction as the operation moves superiorly along the lateral border of the gland. This method generally allows for visualization of the recurrent laryngeal nerve and the inferior thyroid artery. The surgeon must be cautious when approaching the inferior thyroid artery and remember that the nerve can be anterior to it. Any linear structure that is passing obliquely from inferior laterally to superior medially must be considered a possible recurrent laryngeal nerve until the true nerve has been identified confidently. In other words, nothing passing along the possible course of the nerve should be divided and ligated until the surgeon is absolutely certain it is not the recurrent laryngeal nerve. The recurrent laryngeal nerve can usually be identified in the region of the ligament of Berry if it has not already been visualized. During this mobilization process, the superior and inferior parathyroid glands are identified. The dissection continues medially, with care taken not to disturb the nerve while preserving the anterior branches to the parathyroid glands once they are identified. The surgeon should not dissect lateral or deep to the nerve. The thyroid should be elevated off the nerve and rotated medially away from it. Any pressure or traction on the nerve should be avoided. Nerve stimulators have been used to help identify the recurrent nerve and avoid its injury. We do not use such an instrument because we think a thorough understanding of the anatomic course of the nerve and adequate exposure and meticulous technique are much more reliable means of protecting the nerve. A nerve stimulator can give the surgeon a false sense of security and put the nerve at greater risk of injury.

When a subtotal resection is performed, the parathyroid glands may not need to be mobilized away from the remaining thyroid gland. In this situation, the cut edges of the thyroid gland should be ligated securely with a suture ligature to prevent bleeding from the vascular parenchyma. Care must be taken not to pass the needle too deeply, which can inadvertently damage the blood supply to the parathyroid glands or catch the recurrent nerve. When total thyroidectomy is performed, the parathyroid glands must be freed from the thyroid gland with their vascular pedicle intact. If their blood supply is lost, the ischemic parathyroid gland will necrose. When the blood supply to the gland has been injured or is questionable, it should be biopsied to confirm it is parathyroid and to see if it is still vascularized. If it is ischemic and does not bleed when biopsied, it should be autotransplanted. A nonviable gland should be removed and placed into cool saline solution. After frozen section

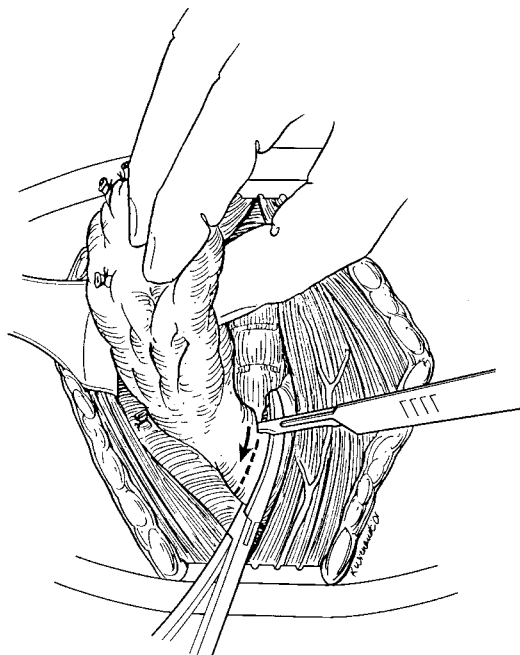
confirmation that it is parathyroid, it should be minced into small 1-mm fragments and reimplanted into the ipsilateral sternocleidomastoid muscle as soon as the operation permits. The site of the transplant is marked with permanent sutures or clips.

The isthmus and pyramidal lobes are freed from their attachments to the trachea. There is usually a relatively avascular plane in the midline between the posterior aspect of the isthmus and the trachea. Any vessels can be controlled by cautery or ligation. Extreme care must be exercised when the isthmus is removed from the underlying pretracheal fascia, to avoid puncture of the trachea. If a puncture or laceration of the trachea occurs, it should be repaired with absorbable sutures, which will not serve as a nidus for future respiratory infection. Care must be taken to avoid the endotracheal tube with the sutures.

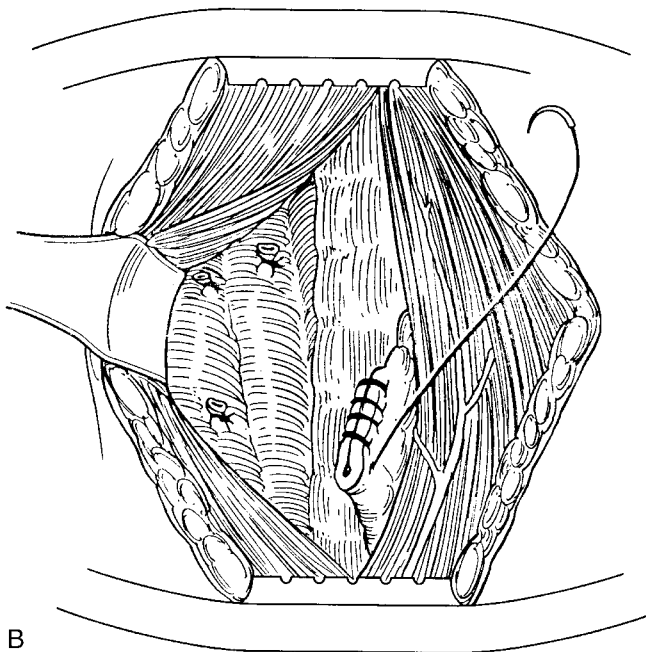
The pyramidal lobe must be located and removed completely. This lobe may only be a small thread as it enters the isthmus but can spread out like a tennis racket as it courses superiorly. If it is missed, it can hypertrophy after the operation and result in a cosmetically unsightly midline neck mass. If only a lobectomy is being performed, the isthmus and pyramidal lobe should be removed to free the anterior surface of the trachea so that the risk of future airway compression by recurrence of disease is minimized. The cut edge of the contralateral lobe must be controlled because of its propensity for hemorrhage. We suture ligate this raw edge to decrease the risk of bleeding (Fig 19).

Closure

Hemostasis is assessed when the patient is placed in a Trendelenburg position to allow for venous engorgement. This maneuver increases cervical venous pressure and stresses possible bleeding points that may otherwise be overlooked. Once meticulous hemostasis is achieved by suture ligation and electrocautery, closure of the wound is accomplished by reapproximating the strap muscles in the midline (Fig 20). It is important to cover the trachea by closing the strap muscles because this prevents the skin from scarring down to it. If there is fixation of the dermis to the trachea, the skin will not move with swallowing and will be cosmetically unappealing. If the strap muscles were transected to obtain better exposure, they should be reapproximated before the midline closure. This can be facilitated by flexing the patient's head forward to bring the cut edges together. The platysma muscle is then reapproximated. A cosmetically desirable skin closure can be achieved with either an absorbable subcuticular suture or nonabsorbable interrupted sutures



A



B

FIG 19. For a lobectomy, the isthmus and pyramidal lobe should be removed to free the anterior surface of the trachea (A) and the cut edge of the contralateral lobe should be ligated (B).

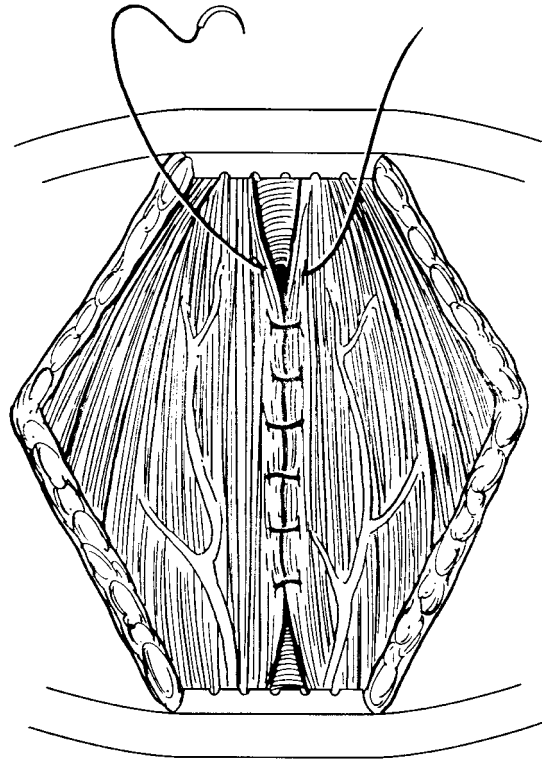


FIG 20. Reapproximation of the strap muscles.

TABLE 4. Major complications of thyroidectomy

| |
|----------------------------------|
| Hemorrhage |
| Airway obstruction |
| Recurrent laryngeal nerve injury |
| Hypoparathyroidism |
| Thyroid crisis |

that are removed within 2 to 3 days to prevent any “railroad tracking.” The use of drains is controversial; we rarely use them.

Complications of Thyroid Surgery

A thorough knowledge of the potential complications of thyroidectomy is essential for the thyroid surgeon. A discussion of the importance of these complications should stress the measures to avoid them. The major complications of thyroidectomy include postoperative hemorrhage, air-

way obstruction, recurrent laryngeal nerve injury, hypoparathyroidism, and, in hyperthyroid patients who are inadequately prepared for surgery, thyroid crisis (Table 4).

Postoperative Hemorrhage and Airway Compromise

Bleeding into the deep cervical space after a thyroidectomy can result in a life-threatening compromise to the airway. A hematoma in this space can cause tracheal compression, laryngeal edema, and respiratory compromise.⁵¹ Postoperative bleeding within this compartment usually occurs within the first 4 hours after the procedure and requires urgent attention.^{52,53} If acute respiratory distress occurs from a hematoma in the deep cervical space, the neck incision should be opened at the bedside, and the hematoma should be evacuated. If this does not relieve the respiratory distress, an emergency tracheostomy should be performed if the airway cannot be secured by immediate passage of an endotracheal tube. The patient should be returned to the operating room as soon as possible for wound exploration and ligation of any offending vessel(s). Alternatively, an endotracheal tube can be placed if the patient is not in acute life-threatening respiratory distress. The patient can then be brought back to the operating room urgently for exploratory procedures under sterile conditions.^{52,53} The most important issue is to gain an adequate airway; there should be no hesitation to perform a tracheostomy.

Respiratory obstruction from laryngeal edema usually occurs within 12 hours of operation. Laryngeal edema may occur from a hematoma in the thyroid bed or from trauma after endotracheal intubation.⁵¹ Tracheostomy is frequently required in patients with postoperative hemorrhage because of the resulting laryngeal edema, especially when there has been a delay in diagnosis. Bilateral recurrent laryngeal nerve injury can result in respiratory obstruction, with the vocal cords held together in a midline position.⁵² Fortunately, these problems are rare, with only 1% to 2% of patients who require reoperation to control hemorrhage and approximately 0.1% to 0.3% of patients who require tracheostomy.⁴⁵

Recurrent Laryngeal Nerve Injury

Paralysis of the recurrent laryngeal nerve is the most common complication after thyroid operation.⁵⁴ Permanent injury to the recurrent laryngeal nerve should occur in fewer than 1% of the patients who undergo thyroidectomy.⁴⁵ Recurrent laryngeal nerve injury reportedly ranges from 0.5% to 3% after thyroidectomy for cancer.⁵³ The rate of recurrent laryngeal nerve injury during reoperations is significantly higher compared with that after initial operations, with an incidence ranging

from 1% to 24%.⁵⁵ Although it is controversial whether the course of the recurrent laryngeal nerve must be identified during a thyroidectomy, most reports show a significantly lower rate of temporary and permanent nerve injury when the nerve is identified.⁵⁴

The symptoms of recurrent laryngeal nerve palsy depend on the completeness of the nerve injury and the presence of associated injury to the superior laryngeal nerves and the contralateral recurrent laryngeal nerve. With isolated unilateral nerve injury, if the position of the paralyzed vocal cord is midline and compensation by the contralateral cord is effective, the damage may not be recognized until some point later, when weakness or change in the voice becomes apparent. If bilateral recurrent laryngeal nerve injury occurs, the main effect is often on the competency of the airway, and the voice may remain surprisingly close to normal. If bilateral nerve injury manifests with stridor on extubation, the diagnosis is obvious, and the patient must be treated with reintubation or tracheostomy. However, the manifestation can be delayed if the vocal cords are in a persistently abducted position after operation because of the splinting effect of the endotracheal tube. These patients can then be diagnosed late with dyspnea and stridor.

If there are no acute respiratory issues and the patient's speech is acceptable, only supportive measures (such as keeping the oropharynx humidified) may be necessary. The passage of time will allow for likely nerve recovery, especially if it was visualized at the operation. This may occur up to 1 year after operation. However, surgical approaches may be necessary in patients with a persistently incompetent glottis and dyspnea or stridor because of vocal cord paralysis.

A flaccid vocal cord can be injected with Teflon paste or silicon. Both can permanently tighten the cord and improve phonation. Hydron gel (Gelfoam, Ethicon, Somerville, NJ), which causes semipermanent tightening because it is absorbed slowly, can be used to check the probable results of Teflon or silicon injection or to improve phonation early after operation in patients in whom the likelihood of nerve recovery is high. Vocal cord injection improves both the volume and the tone of speech. The material is injected in the vocal process anterior and lateral to the margin of the fold. Sufficient material is injected to swell the cord to midline and restore phonation.⁵⁶

A thyroplasty that medializes the paralyzed cord can be performed. The indications for a thyroplasty are unilateral or bilateral vocal fold paralysis or paresis, incomplete glottic closure, and vocal fold bowing.^{57,58} There are various ways to perform this procedure. Netterville and colleagues⁵⁸ described a technique in which an implant that was fashioned from a

silicone rubber block is placed in a window that had been created in the thyroid cartilage approximately 8 mm posterior to the anterior commissure and 3 mm superior to the inferior border of cartilage that serves to medialize the cords. Reinnervation techniques have been attempted, with variable results. Because reinnervation of the paralyzed laryngeal muscles takes at least 3 months, vocal cord injection is recommended to improve the speech during the interim.⁵⁶

The first clinical report of laryngeal reinnervation is generally attributed to Horsley in 1909, who repaired a severed recurrent laryngeal nerve.⁵⁹ Several case reports have described improved vocal fold mobility after reinnervation.^{60,61} However, mobility is not always restored after reinnervation.⁶² If a nerve is transected, both ends should be freshened and reapproximated in a tension-free manner with the use of fine sutures and loupes or an operating microscope for magnification. If too large a nerve segment is missing to allow a tension free anastomosis, a nerve graft can be used. The ansa cervicalis is generally the most frequently used donor nerve. The ansa's branch to the lower portion of the sternothyroid muscle is identified and dissected toward its muscular termination inferiorly. A nerve stimulator can be used to help identify the ansa but is usually not required. A sufficient length of nerve is harvested to allow for a tension-free anastomosis between the ends of the nerve graft and the recurrent laryngeal nerve. The microneural anastomosis is performed under an operating microscope with 10-0 nylon sutures.⁶³

With bilateral nerve injury, the main concern is to provide an adequate airway. Generally, a tracheostomy is required in this situation. Recovery of nerve function can take as long as 6 to 12 months. If there is no improvement after this period, a permanent tracheostomy tube with a speaking valve is an option. In another operation, 1 vocal fold can be moved laterally to restore an adequate airway. This alters the voice and results in abnormal speech. A compromise must be made between a reasonably acceptable voice and a patent airway.⁵⁶

Hypoparathyroidism

The incidence of parathyroid gland injury is related to the extent of the operation and to the experience of the surgeon. The incidence of permanent hypoparathyroidism after total thyroidectomy ranges from 0.7% to 4% (Table 5).⁶⁴⁻⁶⁷ Postoperative hypoparathyroidism may result from the inadvertent removal of the parathyroid glands with the thyroid. More commonly, it is caused by devascularization of the parathyroid glands during the ligation of the blood supply to the thyroid gland. Because most parathyroid glands derive their blood supply from the

TABLE 5. Reported postoperative incidence of permanent hypoparathyroidism

| Series | Year | No. of patients | Incidence (%) |
|-----------------------------------|------|-----------------|---------------|
| Jacobs et al ⁴⁸ | 1983 | 213 | 2.8 |
| Swartz and Friedman ⁶⁴ | 1987 | 183 | 3.3 |
| Tovi et al ⁶⁵ | 1989 | 100 | 4.0 |
| Hamming et al ⁶⁶ | 1989 | 148 | 4.0 |
| Al-Suliman et al ⁵⁵ | 1997 | 935 | 0.7 |

inferior thyroid artery, ligation of the branches of this artery close to the thyroid capsule is essential. These vessels are delicate and can be injured by blind suctioning in the operative field or by careless efforts to control bleeding by imprecise clamping or suturing of tissue.⁶⁸ The operative field should be kept dry by blotting with a sterile gauze so that the parathyroids can be identified and their vascular supply preserved.

The incidence of hypoparathyroidism can be diminished substantially by the use of parathyroid autotransplantation. Glands that do not have an obvious intact blood supply should be incised to see whether they bleed. If they do not bleed, a small portion should be sent for frozen section to confirm that it is parathyroid tissue before autotransplantation. After a lobe is removed or especially after a total thyroidectomy is performed, the specimen should be inspected to be sure that there are no possible parathyroid glands on the thyroid. If any are found, they should be separated from the specimen, and a small portion of the glands should be sent for frozen section confirmation. The remaining tissue should be placed in cold saline solution. If it does prove to be parathyroid tissue, it should be autotransplanted as soon as possible to the ipsilateral sternocleidomastoid muscle, as described earlier. Some surgeons routinely autotransplant 1 parathyroid gland when performing total thyroidectomy, but this is not our practice. We use autotransplantation liberally whenever there is a question about the vascular integrity of a gland but feel it is best to preserve the glands in situ whenever possible.

After the operation, serum calcium, magnesium, and phosphorus levels should be measured. Hypocalcemia after thyroidectomy is usually temporary, with reported incidences ranging from 1% to 50%. However, most experienced surgeons report an incidence of 2% or less.⁴⁵ The diagnosis of hypocalcemia should be based on ionized calcium levels if there is any question about the patient's circulating total protein and albumin status. Mild postoperative hypocalcemia can generally be treated with oral calcium supplementation. Symptomatic hypocalcemia (manifested by tingling in the hands and feet, circumoral paresthesia, and Chvostek's or

Trousseau's signs) requires more aggressive treatment, and intravenous calcium may be necessary. If the patient experiences spontaneous twitching or carpal pedal spasms, blood should be drawn for serum calcium and phosphorous determination, and calcium gluconate should be administered intravenously until the symptoms abate. Usually, several ampoules of calcium gluconate are required when patients experience symptomatic hypocalcemia. If the patient has a low serum calcium level and a high serum phosphorous level, hypoparathyroidism is present, and vitamin D treatment with calcitriol should be used in addition to calcium supplementation. If hypocalcemia is due to "bone hunger," the serum phosphorous level will also be low.

Thyrotoxic Crisis

Thyrotoxic crisis or thyroid storm is a condition that is characterized by severe symptoms of hyperthyroidism (including tachycardia, mental obtundation, mania, delirium, stupor, coma, nausea, vomiting, diarrhea, and high fever). It occurs in hyperthyroid patients and with Graves' disease who are prepared inadequately for operation.^{45,53} This is a clinical diagnosis for which any delay in recognition and treatment can be potentially life-threatening.

The patient in thyroid storm should be monitored in an intensive care unit. The treatment includes eliminating the initiating factor, administering oxygen, using a cooling blanket, and administering appropriate intravenous medications. Propylthiouracil, which inhibits the peripheral conversion of T_4 to T_3 and prevents intraglandular hormone storage, should be administered immediately. Iodine is also administered because it blocks the release of preformed thyroid hormone from the thyroid gland. Dexamethasone acts synergistically with propylthiouracil and iodine to prevent the conversion of T_4 to T_3 . Intravenous beta blockers are used to slow the heart rate and blunt many of the cardiovascular effects of hyperthyroidism.⁵³ Propranolol and other beta-adrenergic agents are used for symptomatic relief. These agents block the symptoms of tachycardia, diaphoresis, and anxiety but do not control the underlying hyperthyroidism.

Substernal Goiter

Most substernal goiters are an extension of a cervical goiter. Substernal goiter may be defined as any thyroid enlargement that expands into the mediastinum. Seventy-five percent to 90% of goiters that extend into the mediastinum are located anterior to the recurrent laryngeal nerves and the major vessels. Although most goiters are located anterior to these

structures, it is important not to exclude the possibility of an anteriorly lying recurrent nerve before dissection.⁶⁸ Approximately 10% to 15% of all intrathoracic goiters occur in the posterior mediastinum. These tend to develop from the posterolateral aspects of the thyroid gland. Goiters that descend into the posterior mediastinum can travel behind the carotid sheath and the recurrent laryngeal nerve and inferior thyroid vessels.⁶⁹ They usually descend on the right, posterior to the great vessels, because they take the path of least resistance and grow away from the aortic arch and its branches.⁷⁰ Intrathoracic goiters that arise from the left lobe of the cervical thyroid may descend to the right because of the presence of the left common carotid and subclavian arteries and the left innominate vein.^{68,70}

Various criteria have been used to classify goiters with mediastinal extension. Substernal includes those goiters in which just a portion extends into the mediastinum. Partial intrathoracic goiters include those goiters in which more than 50% of the gland extends into the mediastinum. Complete intrathoracic goiters do not possess a cervical component.^{71,72} Substernal goiters should be differentiated from aberrant goiters. The term *aberrant* is generally reserved for mediastinal goiters that do not have any connection to the cervical gland and do not receive a cervical blood supply.⁷¹

Extension of a cervical goiter into the mediastinum is attributed to the increasing weight of the thyroid gland, negative intrathoracic pressure, respiratory movements, and shortness of the neck.^{68,69} The absence of an anatomic structure that anchors the thyroid between the lower neck and the inlet to the thoracic cavity is thought to augment migration.⁶⁸ These extensions of a cervical goiter tend to follow the fascial planes through the thoracic inlet, following the path of least resistance.⁷⁰

Several large series of patients who underwent thyroidectomy have reported that the incidence of substernal goiter varies from as low as 1% to more than 21%.⁷¹ Lahey and Swinton⁷³ reviewed 5131 thyroidectomies and found a 21% incidence. At the other extreme, Wakeley and Mulvany⁷⁴ reported that 20 of their 1200 patients who underwent thyroidectomy had substernal goiters, a 1.7% incidence. The incidence of substernal goiter in several large series of thyroidectomies is summarized in Table 6.⁷³⁻⁷⁶ Obviously, the frequency in a given series will vary according to how the entity is defined, to the particular geography and patient population that is involved, and to other factors, such as referral patterns.

Substernal goiters are most common in patients in the fifth decade of life. However, patients as young as 15 years and as old as 90 years have

TABLE 6. Reported incidence of substernal goiters in patients who have undergone thyroidectomy

| Series | No. of thyroidectomies | No. of substernal goiters | Incidence (%) |
|-----------------------------------|------------------------|---------------------------|---------------|
| Lahey and Swinton ⁷³ | 5131 | 1086 | 21 |
| Wakeley and Mulvany ⁷⁴ | 1200 | 20 | 1.7 |
| Pemberton ⁷⁵ | 4006 | 542 | 13.5 |
| Reeve ⁷⁶ | 2000 | 173 | 8.6 |

been reported.⁷¹ Women predominate, with the female:male ratio typically being 3 or 4:1.⁷⁷⁻⁷⁹ Symptoms and signs may arise from compression of the structures located within the confines of the bony thoracic inlet. These structures include the trachea, esophagus, and vasculature. The most common symptoms that are associated with substernal goiter include a cervical mass (65%), dysphagia (36%), and dyspnea (32%).⁸⁰ Patients may also have stridor, hoarseness, cough, and wheezing.⁷¹ Vadasz and Kotsis⁸¹ noted that, of their 175 patients with intrathoracic goiters, 6% had laryngeal nerve palsy. A rare neurologic presentation that can occur with intrathoracic goiter is Horner's syndrome (meiosis, anhidrosis, and ptosis).⁷⁰

In 1921, Pemberton described the positional nature of these symptoms.⁷⁵ The Pemberton maneuver involves "elevating both arms until they touch the sides of the head"; if a substernal goiter is present, "after a minute or so, congestion of the face, some cyanosis, and lastly distress become apparent."^{71,82} Certain patients will complain of dyspnea, stridor, or flushing only when they are supine or when their arms are raised above their heads or when the neck is extended. These symptoms result from increased pressure in the thoracic inlet and impaired venous return from the head and neck.

Whenever a substernal goiter is diagnosed (by symptoms, palpation, or chest radiograph), it is prudent to consider obtaining pulmonary function studies and a computed tomography (CT) scan of the mediastinum. The CT scan is an important diagnostic tool for the assessment of the extent of a substernal goiter, its relationship to other mediastinal structures, and any anatomic distortion it is causing. The CT scan can show tracheal deviation and/or compression that will help to plan both the intubation and the operation. The pulmonary function studies can document obstructive airway disease and serve as a baseline to measure improvement after thyroidectomy. Long-standing multinodular goiters generally respond poorly to thyroid hormone suppression.⁸³ It is difficult and expensive to follow the effects of suppressive therapy with substernal goiters because CT scanning must be performed to assess the size of the gland accurately.

We usually advise resection because of this difficulty and because of the potential abrupt and treacherous onset of symptoms. Once any symptom or sign of compression by the substernal component of the goiter occurs, operation is indicated and may need to be performed emergently. Substernal glands should not be biopsied with a needle because any bleeding could cause airway compression and respiratory distress.

Endotracheal intubation with a rigid tube is the favored approach for anesthesia. Most anteriorly placed substernal goiters can be approached through the standard cervical incision by a combination of gentle upward traction along with digital pressure once the lobe has been fully mobilized in the neck. To make the most of the cervical approach, it is important to mobilize the subplatysmal flaps sufficiently inferior to get as much exposure as possible. The strap muscles should be separated all the way down to the sternal notch. We still begin the operation by taking down the superior pole and ligating the superior thyroid artery and vein. Most substernal goiters receive their blood supply from cervical thyroid vessels and generally maintain some connection to the thyroid gland in the neck. By ligating as much blood supply to the gland as possible, there will be some shrinkage of its size because a substantial part of its volume will be blood. Because much, if not all, of the blood supply to the gland will be cervical in origin, progressive ligation of these vessels will allow its mobilization as the gland is pulled superiorly. Care must be taken not to rupture the thyroid capsule because this will cause bleeding and will make it more difficult to pull the remaining gland out of the mediastinum.

Excessively vigorous attempts to deliver the goiter with a cervical approach alone can result in heavy blood loss in some patients.^{78,84} Ehrenhaft and Buckwalter⁸⁴ pointed out the increased risk of uncontrollable hemorrhage, injury to the recurrent laryngeal nerves, and incomplete removal of the goiter through a strictly cervical approach. They favored sternotomy for anterior goiters and a right lateral thoracotomy for posterior goiters. Gourin and colleagues⁷⁸ described their use of a partial upper sternotomy in addition to their standard cervical collar incision. All patients were initially approached with a generous collar incision. When it became obvious that the goiter could not be safely delivered through the thoracic inlet, the mediastinum was entered by extending the incision in the shape of a "T" caudally so that the sternum can be split vertically. Although most authors generally recommend a cervical approach today, there are certain circumstances (such as a very large substernal goiter or carcinoma in a substernal goiter) in which a sternotomy is a safer and necessary alternative. During extraction, the goiter may wedge in the

narrow thoracic inlet between the bony structures and the trachea. This can cause complete respiratory obstruction. This can also necessitate a sternotomy to release the gland and relieve the respiratory distress.

Piecemeal removal or morcellation of substernal goiters has been described.⁷² This can lead to serious hemorrhage, especially in those goiters with substantial vascularity. If uncontrollable bleeding in the chest occurs, a sternotomy must be performed to access the responsible vessels. Another problem with morcellation is the possibility of occult malignancy.⁷⁸ This piecemeal approach violates the principle of an en bloc resection in cancer operations and may eliminate a chance for cure.

The Very Large Goiter

The cause of goiter remains unclear. One hypothesis suggests that persistent stimulation by thyroid-stimulating hormone (TSH) or other extrinsic or intrinsic factors results in a sustained increase in thyroid mass. There is a hereditary predisposition for goiter. Microscopically, this increase in mass is due to the abnormal growth of follicular cells. Because of the inadequate production of thyroid hormone in iodine deficiency, TSH is increased, which results in goitrous enlargement.

There is no general agreement about the amount of thyroid tissue required for a goiter to be considered large or very large. The World Health Organization initially classified large goiters as goiters that could be identified from a distance, are grossly disfiguring, and could cause symptoms because of their size.⁸⁵ Goiters that weigh more than 80 g after excision have been deemed large.⁸⁶ More recently, thyroid glands that weigh more than 100 g or measure more than 100 mL in volume have been called large or very large.^{55,87-91} Alternatively, enlargement as small as 2.5 times the size of the normal thyroid gland has been used as a criterion for classification as large.⁸⁹

There is no relationship between the size of nodular goiters and their function. Very large goiters pose more problems with their physical rather than their functional aspects. Approximately 80% of patients with multinodular goiters are euthyroid.⁹² Similarly, there is no relationship between circulating thyroid hormone levels and thyroid size in patients with Graves' disease.⁹³

Very large goiters will often cause compressive symptoms. Compression from benign thyroid disease can be caused by nodular colloid goiter or thyroiditis, but thyroiditis is associated with a greater likelihood of compression.⁹⁴ In addition to malignancy, large retrosternal nodular goiters are most likely to manifest with respiratory obstruction.⁹⁵ Complications from a compromised respiratory tract are common and poten-

tially lethal.^{86,96} Simple tracheal compression may result in dyspnea and inspiratory stridor.^{91,97} A choking sensation, often aggravated when lying recumbent, is another symptom of tracheal compression.^{94,98} Large goiters can cause tracheal displacement, infiltration, and tracheomalacia.⁸⁶ Because the growth of the goiter can progress slowly and allow patients to compensate, substantial tracheal compression may be asymptomatic or at least unnoticed.⁹⁴ Therefore, airway symptoms and signs with large goiters can manifest late. There are instances in which acute tracheal occlusion may require urgent intubation or tracheostomy.^{94,95} With the onset of respiratory symptoms, the occurrence of acute airway occlusion may be sudden and unpredictable.⁹⁴ The development of concurrent upper respiratory infection can exacerbate symptomatic compressive goiters and cause respiratory arrest.

As a goiter enlarges, it can compress or stretch the recurrent laryngeal nerve. Altered nerve function may lead to further respiratory difficulties.^{86,95,96} Dysphagia caused by esophageal compression can occur.^{68,81,94,98-100} Less commonly, the superior vena cava syndrome with elevated central venous pressure as the result of local compression of this vein may be a symptom.^{91,93,101,102} Facial edema, distended upper body veins, and collateralization of the venous system have been described with large retrosternal goiters that cause the superior vena cava syndrome.¹⁰²

Unusual manifestations of large goiters have included superior sagittal sinus thrombosis. It has been postulated that very large goiters cause stasis of the venous return from the central nervous system. This, plus a hypercoagulable state that is associated with thyrotoxicosis, seems to be responsible for the thrombosis.¹⁰³ A “steal” syndrome from the cerebrovascular system has also been described.¹⁰⁴ Infectious processes such as pneumonia, which presumably is caused by aspiration or inability to clear the tracheobronchial tree with coughing, can develop. Local infection, in the form of an infected cyst within a multinodular goiter, has also been described.¹⁰⁵ Horner’s syndrome (meiosis, ptosis, and exophthalmos) has occurred in patients with cervical sympathetic chain compression.¹⁰¹ Ectopic thyroid tissue may also manifest as a very large goiter. A very large lingual goiter may require emergency tracheostomy.¹⁰⁶ These different manifestations may occur in various combinations.¹⁰¹

Plain radiographs may be used to assess the airway of patients with very large thyroid glands. Chest radiographs can identify tracheal displacement or narrowing and substernal goiters.^{86,95} Neck radiographs have been recommended as part of the initial evaluation because of their potential to identify tracheal deviation that can be a potential harbinger of tracheal

compression.⁹⁴ CT scans of the neck and chest are useful in the evaluation of compressive symptoms by clarifying the findings on chest radiographs and identifying involvement of other structures with greater detail.^{86,97} Ultrasonography is suitable for goiters that are confined to the neck, but it cannot image substernal extension because of bony interference. Magnetic resonance imaging (MRI) has been advocated for more detailed delineation of intrathoracic extensions of the large goiters, but it probably does not add information that is not already available on a good quality CT scan.^{91,107} Esophagrams can identify areas of esophageal narrowing or displacement if there are any symptoms of dysphagia.⁸⁶ Venocavograms are used to evaluate compressive symptoms that are consistent with a superior vena cava syndrome.⁹⁵ Other imaging studies (such as thyroid scintigraphy) can be used to evaluate the size and function of an enlarged thyroid gland.

Pulmonary function tests and flow volume loops may be used to determine the extent of obstruction and the possible need for urgent thyroidectomy.⁸⁶ They are recommended for patients with a large goiter who complain of any potential compressive symptoms.¹⁰⁷ Flow volume loop findings, in conjunction with chest radiographs, have a high rate of detecting upper airway obstruction from goiters.⁹⁸ Nygaard and colleagues¹⁰⁸ have demonstrated that flow volume loops are superior to radiographs of the trachea in the detection of upper airway obstruction.

Radioiodine therapy has been used as an alternative to surgical therapy for large goiters. It is an attractive therapeutic option when operation is a relatively high risk or is not an option.^{90,107} Radioactive iodine can exacerbate compressive symptoms by causing edema and swelling in the gland.^{90,107} When there is marked narrowing of the trachea, edema prophylaxis with glucocorticoids has been recommended.¹⁰⁷ Concern about high absorption of radiation, particularly with very large goiters, is another reason for its limited use and for the recommendation that it be limited to elderly patients.⁹⁰

When elderly patients with large compressive multinodular goiters have been treated with radioiodine therapy, decreased gland size has been documented by imaging studies or physical examination. Although reductions are reported, they range only from 30% to 40% after 1 year.^{90,91,107} Some continued reductions have been noted when patients have been followed for longer periods.⁹¹ Bonnema and colleagues¹⁰⁷ have demonstrated that, as the size of the goiter increases, the effect of radioiodine therapy is attenuated. In other words, there is a negative correlation between the size of the gland and its reduction after radioactive iodine treatment. Size reductions, when they occur, correlate with

improvements in symptoms and the radiographic findings of tracheal compression.^{90,91,107} However, there are studies that have shown little, if any, benefit.

Several studies regarding hyperthyroidism have demonstrated that radioactive iodine therapy reduces goiter size, with some regimens having more dramatic effects than others. Success rates are usually defined as remission of hyperthyroidism rather than a decrease in size per se and have ranged from 25% to 50% in larger goiters.^{91,109,110} Lower success rates with radioiodine treatment typically occur with large goiters.^{109,111} Confounding factors, such as the concomitant use of antithyroid medications, may be responsible for some of the failures of radioactive iodine.^{110,111} The reduction in thyroid volume after treatment with iodine has been shown to be a good predictor of decreased function in Graves' disease that is associated with large goiters. The volume before radioactive iodine treatment has not been as predictive.¹¹⁰ Peters and colleagues⁹³ showed that a marked decrease in gland size (71%) depended on the dose of radioactive iodine that was absorbed by the thyroid tissue.⁹³ These results were not reproducible at a fixed higher dose in a study reported by Sabri and colleagues,¹¹⁰ but some of these patients had been using antithyroid medications.

TSH suppression therapy with exogenous thyroid hormone can be used instead of radioiodine therapy or operation. Accelerated bone loss and cardiac arrhythmias can result from excessive TSH suppression therapy, especially in the elderly population with very large goiters.¹⁰⁷ TSH suppression therapy for large compressive goiters is frequently not possible because the serum TSH of these patients is often already below the normal range.⁹¹

Radiation thyroiditis can be an early complication of radioiodine treatment. It can worsen symptoms of compression and thyrotoxicosis. However, it typically manifests with only mild symptoms that are short lived. The frequency of clinically relevant manifestations that require corticosteroid therapy has been reported to range from 0% to 2%.^{91,108}

Although it is thought to be rare, autoimmune hyperthyroidism occurs in patients who are treated with radioactive iodine therapy for large multinodular goiter at a slightly higher frequency than expected (3/80 patients).^{90,91} Hypothyroidism after treatment is somewhat difficult to assess because of the frequency of thyroid hormone replacement therapy.⁹⁰ However, the overall incidence of hypothyroidism ranges between 20% and 30% at 1 to 5 years after treatment.^{90,91,107,108} The development of thyroid cancer after radioactive iodine therapy is an important concern. No higher risk of cancer development has been found in patients who

were treated with radioiodine for large nontoxic goiters compared with those patients who were treated for small goiters.⁹¹

Surgical resection is the treatment of choice for very large goiters that are either toxic or nontoxic, especially if compressive symptoms are present.^{90,91,93,94,97,107,112,113} Surgical treatment of very large goiters also provides tissue for pathologic diagnosis and removes possible malignancy.⁹¹ With Graves' disease and a large goiter, operation has been advocated because of the potential improvement in ophthalmopathy.¹¹⁴ Operative therapy for large toxic multinodular goiters rapidly reverses hyperthyroidism and obviates any concern about compression.⁹² Removal of the abnormally enlarged gland that is causing thyrotoxicosis from either toxic multinodular goiter or Graves' disease is the most rapid and effective means to control hyperthyroidism.¹¹³

Treatment of a potentially compromised airway supercedes any other concerns before the operation. With severe respiratory embarrassment, intubation or tracheostomy may be required immediately. Recent evidence has shown that intubation has been accomplished without much difficulty in patients with very large goiters, even in the presence of acute respiratory distress.^{86,115} Fiberoptic intubation and/or awake intubation are often required in patients with large goiters.^{86,97,115}

Indirect laryngoscopy has been advocated to assess the larynx and vocal cords before operation and to identify patients at high risk for postoperative complications.⁹⁶ Other surgeons have used preoperative direct laryngoscopy to assess the position of the larynx and vocal cord function.⁸⁶ Regardless of the method of laryngeal visualization, identification of a unilaterally paralyzed recurrent laryngeal nerve will make the surgeon be appropriately more cautious when near the contralateral recurrent laryngeal nerve.⁹⁵

During the operation, there are several challenges in the surgical resection of a very large goiter. In 1988, Melliere and colleagues⁹⁵ discussed 3 of the challenges that are encountered with the removal of large goiters that are causing respiratory compression: achieving adequate hemostasis before delivering the gland, preventing injury to the external branch of the superior laryngeal nerve, and preserving the blood supply to the superior parathyroid gland while delivering a voluminous gland.⁹⁵ Without adequate hemostasis, there is real risk of injury to the recurrent laryngeal nerve. Careful identification, minimal manipulation, and preservation of the recurrent laryngeal nerve during operation is imperative, particularly when vocal cord paresis is identified on the contralateral side.⁸⁶ Retrospective analysis has demonstrated that removal of large

goiters does not necessarily increase the risk of recurrent laryngeal nerve injury compared with the removal of small goiters.⁵⁵

The external branch of the superior laryngeal nerve should also be approached with great caution. In a nonrandomized prospective review, Cernea and colleagues⁸⁷ confirmed that the position of the external branch of the superior laryngeal nerve was at high risk of injury in more than one half of patients with large goiters. The risk was greatest with the enlargement of the superior pole of the gland because of the intimate relationship of the external branch of the superior laryngeal nerve and the superior thyroid vessels.⁸⁷ The average goiter size in this study was 10 cm in largest dimension, and the average weight was 471 g.

Surgical morbidity and mortality rates that are associated with large goiters are higher than with smaller glands.²⁶ Respiratory complications are related directly to the presence of compressive symptoms and signs. In addition to hemorrhage and recurrent laryngeal nerve injury, which are associated with all thyroidectomies, tracheomalacia and laryngeal edema are special considerations with very large goiters. If there is any concern about an airway abnormality after thyroidectomy, fiberoptic endoscopy is indicated if the patient's condition is stable.^{97,114}

Tracheomalacia occurs when the cartilaginous rings and supportive tissue of the trachea are weakened or destroyed. This results in a compromised airway after the thyroid gland, which has been providing external support to the trachea, is removed. This complication is rare but can follow the removal of large compressive goiters.^{26,94,96,114} Large goiters may predispose the trachea to this condition by simple mass effect, but the chronicity of the compression is also important.⁹⁶ When a very large goiter is removed and tracheomalacia is encountered, several options are available to address this complication. Geelhoed¹¹⁶ proposed 3 options: tracheopexy, tracheostomy, and tracheoplasty (Table 7). Usually, prolonged intubation (ranging from 12 hours to more than 48 hours after the operation) is sufficient to treat most patients who have tracheomalacia.⁹⁷

Laryngeal edema has also been ascribed to a lack of supportive tissue after the removal of large compressive goiters.⁹⁶ This condition occurs more frequently than does tracheomalacia.^{95,26} Postoperative stridor is most likely due to laryngeal edema or laryngospasm.⁹⁷ Difficult or traumatic intubation, which sometimes occurs with large goiters, may contribute to these laryngeal problems.⁹⁶ Steroid therapy can be used in conjunction with prolonged intubation to decrease laryngeal edema.^{95,96} A tracheostomy may be needed in these situations to maintain a secure airway.⁹⁶

TABLE 7. Proposed options for treatment of tracheomalacia

| |
|--|
| Tracheostomy |
| Airway diversion: cervical or mediastinal tracheostomy |
| Tracheopexy |
| Stenting |
| Prolonged intubation |
| Intrinsic support |
| Strutting |
| Aortic adventitial suspension |
| Supportive thyroid remnants |
| Subtotal thyroidectomy |
| Staged resection |
| Extrinsic prosthetic support |
| Tracheal neo-rings |
| Tracheal support grafts |
| Tracheal mesh sheathing |
| Tracheoplasty |
| Resection of tracheomalacia segment |
| Length of segment that is possible without anastomosis tension |
| Position of tracheostomy (mediastinal?) |
| Auxiliary support from blood supply grafting or prosthesis |
| Future possibility of tracheal replacement |

Adapted from Geelhoed GW. Tracheomalacia from compressing goiter: management after thyroidectomy. *Surgery* 1988;104:1100-8. With permission.

The intraoperative decision to place a tracheostomy has centered on the unresectability of a thyroid malignancy or bilateral recurrent laryngeal nerve resection during excision of extensive malignant disease.⁹⁵ Tracheomalacia is also a strong indication for a tracheostomy.^{86,96} Abdel Rahim and colleagues⁹⁶ demonstrated, in a retrospective study of large goiters that were causing respiratory symptoms, that 13% of their patients required a tracheostomy, 5 due to tracheomalacia and 2 due to laryngeal edema. The presence of a goiter for more than 5 years, progressive stridor, retrosternal extension, marked tracheal deviation detected radiologically, tracheal compression, and difficulty with preoperative intubation were significant risk factors for the need for tracheostomy.⁹⁶ Some surgeons advocate tracheostomy when there is clinical evidence of tracheal collapse with spontaneous inspiration and expiration. This condition can be confirmed by bronchoscopy if it was not detected at the time of thyroidectomy.⁸⁶ Other investigators advocate emergent tracheostomy for respiratory distress. However, if a postoperative diagnosis of tracheomalacia is confirmed by laryngoscopy, simple reintubation for a brief period of time, typically 24 to 48 hours, may be sufficient treatment.^{68,97}

Temporary vocal cord paralysis occurs after the resection of large goiters with greater frequency as compared with smaller goiters.⁵⁵

Al-Suliman and colleagues⁵⁵ showed that the incidence of wound hematomas and temporary hypocalcemia occurred with similar frequency after resection of a large goiter compared with resection of a smaller goiter. Permanent hypocalcemia, on the other hand, occurs with greater frequency in large goiters.⁵⁵ A very uncommon complication of thyroidectomy for a very large goiter is an arteriovenous fistula from the right thyrocervical trunk to the right jugular vein. This complication was described after a total thyroidectomy for a large goiter in a survivor of the Chernobyl nuclear accident.¹¹⁷

Invasion of Adjacent Structures by The Abnormal Thyroid Gland

The surgical treatment of thyroid lesions that invade adjacent structures is controversial, but removing as much abnormal tissue as possible and maintaining the functional integrity of the neck structures are basic principles.^{118,119} Direct invasion of surrounding local tissues occurs in 0.9% to 22% of patients with thyroid carcinoma. Most of these lesions are well-differentiated cancers,^{118,120-126} even though undifferentiated carcinomas have a greater tendency for invading local structures.¹²⁷ Local invasion is 1 of the most important prognostic signs for survival in patients with thyroid cancer.^{121,128} Less well-differentiated carcinomas that invade the aerodigestive tract have a statistically lower rate of survival¹²⁹ than differentiated thyroid carcinomas.¹³⁰ Recurrent thyroid cancer constitutes a large proportion of patients with local tumor invasion.^{126,131-138} Breaux and Guillaumondegui¹¹⁸ found that patients with local recurrence, extensive nodal disease or distant metastases, and undifferentiated cancers were more likely to have local invasion. Differentiated and medullary thyroid cancers with known extrathyroidal growth (pT4) or lymph node involvement (pN1) have an increased risk of both respiratory tract and digestive tract invasion when compared with lower stage primary tumors (pT1-pT3) or those tumors without nodal involvement (pN0).¹³⁹ Invasion of more than 4 adjacent structures of the neck has been shown to be uniformly lethal.¹¹⁸

Although surgical treatment for locally invasive undifferentiated thyroid carcinomas (such as anaplastic carcinomas) is frequently only palliative, improved survival rates or cure can occur with differentiated carcinomas.^{118,121,140} Unlike for other malignancies, an adequate resection for most thyroid carcinomas is achieved if the margins are negative.^{124,141} The extent of thyroidectomy has been guided by the extent of the disease process.¹⁴² Resection of the sternocleidomastoid muscle, strap muscles, internal jugular vein, common carotid artery, recurrent laryngeal

TABLE 8. Staging system for tracheal invasion by thyroid carcinoma

| Stage | Description |
|-------|--|
| 1 | Confined to substance of thyroid gland |
| 2 | Extends through the capsule of the thyroid gland and abuts the external perichondrium but does not erode cartilage or invade between cartilaginous plates |
| 3 | Invades between the rings of cartilage or destroys cartilage |
| 4 | Extends through the cartilage or between the cartilaginous plates into the lamina propria of the tracheal mucosa but does not elevate or invade the epithelium |
| 5 | Extends through the entire thickness, expands the trachea mucosa, and is visible through a bronchoscope as a nodule or ulcerated mass |

From Shin DH, Mark EJ, Suen HC, Grillo HC. Pathologic staging of papillary carcinoma of the thyroid with airway invasion based on the anatomic manner of extension to the trachea: a clinicopathologic study based on 22 patients who underwent thyroidectomy and airway resection. *Hum Pathol* 1993;24:866-70. With permission.

nerve, vagus nerve, phrenic nerve, and esophagus may be required as part of surgical therapy.¹²⁸ Variability in the involvement of these and other structures is responsible for the absence of a uniform procedure to remove the tumor burden. The possibility of an extended life expectancy and the difficulty of predicting the growth rate of the thyroid carcinoma make the determination of the extent of resection difficult.^{121,130,138} The improved efficacy of postoperative radioactive iodine adjuvant therapy with lesser tumor burden also affects surgical decision-making when eradicating locally invasive thyroid cancer.^{121,140}

Invasion of the Respiratory Tract

The respiratory tract is the most common site of invasion by thyroid malignancy. This can range from outer cartilaginous invasion to frank intraluminal ingrowth. It can involve the upper airway at multiple levels.¹²⁰ Histologically, thyroid carcinomas that invade the aerodigestive system are often poorly differentiated.¹³³ Laryngeal invasion can occur by direct extension of thyroid carcinoma through either the tracheal or cricoid cartilage or by posterior extension around the thyroid cartilage into the piriform sinus.¹²⁴ Tracheal invasion occurs by direct ingrowth of the primary tumor or by secondary ingrowth of an involved lymph node.^{124,139} Pharyngeal invasion occurs in a similar manner.¹²⁴ Invasion of the larynx and trachea by thyroid cancer decreases the survival rate.¹⁴³ Shin and colleagues¹⁴⁴ have proposed a staging system for tracheal invasion (Table 8). This classification has been used for retrospective analysis of airway invasion by thyroid carcinoma, but its value as a prognostic tool or guide for surgical treatment has not been defined

clearly.^{119,145} Even in the presence of distant metastases, resection is recommended often because of the mortality rate that is associated with local disease and the need for primary tumor resection for the effectiveness of other adjuvant therapy.¹⁴⁶

Local disease can be directly responsible for death in some patients with advanced thyroid cancer.^{127,147,148} Respiratory tract involvement contributes to the relatively high mortality rate that is associated with invasive thyroid cancer.¹²⁷ Ultimately, patients with laryngeal and/or tracheal invasion will die from intraluminal hemorrhage or respiratory failure.^{127-129,133-135,142,143,145,149,150} Luminal obstruction is the most likely cause of respiratory distress.¹⁵¹ Luminal obstruction usually is due to a combination of vocal cord paralysis, extrinsic compression, and the presence of an intraluminal mass.^{121,140} More than 80% of patients are reported to have active local disease at the time of death from all types of thyroid cancer.¹²⁷

Thyroid carcinoma that invades the respiratory tract is more common in men and in older patients.^{119,142} Patients with invasion of the larynx or trachea can have respiratory difficulty, dyspnea, or stridor.^{121,126-129,131-135,140,142,146,151-154} Stridor will often first manifest with increased physical activity. When stridor is present, it will eventually lead to frank dyspnea, air hunger, or the sensation of choking.^{125,127,128,140} Otodynia is a rare manifestation.^{124,126} A concomitant neck mass is usually present.^{119,121,127,128,155} Some thyroid malignancies can be masked within a multinodular goiter.^{156,157} The presence of a large, bulky, or fixed mass along with frank dyspnea heralds the onset of imminent respiratory distress.^{131,133,134,141,151} A fixed mass with a history of previous thyroid carcinoma indicates recurrence.¹⁴¹ Bleeding into the trachea that results in hemoptysis can be a sign of thyroid cancer with airway invasion.^{121,123-128,132,138,150-153} Its occurrence after thyroid operation often indicates recurrence.¹³⁵ Hoarseness, sore throat, cough, voice changes, and pneumonia are other respiratory symptoms that are associated with intraluminal invasion.^{121,126,127,130,133,134,140,151-153} Some patients can remain asymptomatic until the disease is quite advanced.^{119,133-135,150} Benign disease that causes extrinsic compression or that occurs ectopically within the lumen may cause respiratory symptoms and should be considered.¹²¹

In addition to the patient's history, a thorough physical examination will allow the clinician to suspect airway invasion. Usually a palpable neck mass or nodule that has recently enlarged will be present.^{121,133,134,153} The mass will often be hard and displace or be fixed to the surrounding tissue. Plain radiographs of the neck and chest may show an abnormal

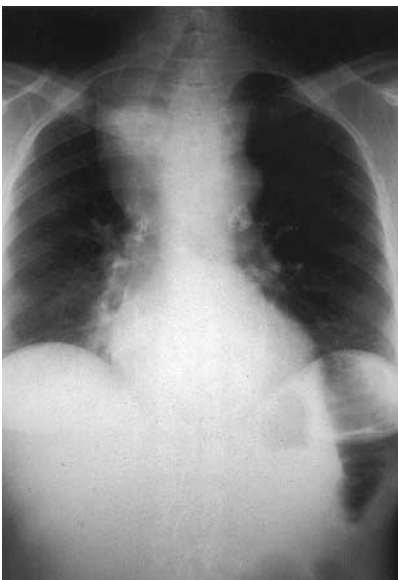

FIG 21. Chest radiograph demonstrates characteristic narrowing that is associated with tracheal invasion by tumor.

shadow that displaces, compromises, or narrows the trachea (Fig 21).^{121,131-135} Ultrasound scanning is not extremely useful for the evaluation of intraluminal invasion, although it can define potential nodal involvement and lateral and posterior extension of the primary tumor.¹²⁴ CT scanning can determine the presence and delineate the extent of cartilaginous and intraluminal invasion (Fig 22).^{122,128,152} It can also identify structures that are not involved by the carcinoma.¹⁵³ CT scanning is a reliable tool to evaluate the thyroid gland and the tumor, identify tissue planes and vascular structures, provide images of the trachea at different levels, and determine the extent of any stenosis.^{122,135} However, CT scanning can underestimate airway involvement by not characterizing thyroid and cricoid cartilage invasion.¹⁴⁹ MRI has been recommended for the evaluation of the extent of tumor invasion but usually does not provide additional information beyond what is already available from CT scanning.^{122,133,134} MRI identification of cancer around the airway is not a reliable predictor of invasion.¹⁵⁸ Laryngoscopy and bronchoscopy can be used to diagnose intraluminal invasion and can identify areas of erosion or bleeding.^{121,125,128,135,143} They can also be used to evaluate the mobility of the vocal cords, which may influence the surgical approach.¹⁴⁰ Laryngoscopy or bronchoscopy is strongly recommended

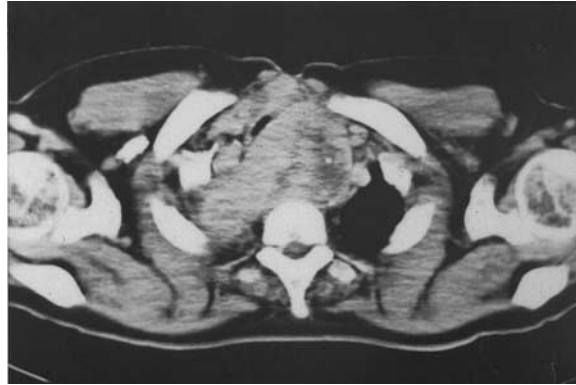

FIG 22. Neck CT demonstrates invasion of the trachea and other adjacent neck structures by direct invasion.

whenever tracheal invasion is suspected.^{133,140} Radioactive iodine scintigraphy can identify metastatic disease but cannot define tracheal compromise.¹²⁵

Preoperative needle biopsy has been recommended by many surgeons. However, the presence of a large invasive lesion warrants resection, so biopsy usually does not add anything to the treatment.¹³¹ Both core and fine-needle biopsy can result in hemorrhage or swelling in the tumor that can precipitate acute respiratory compromise; therefore, they are best avoided. Intraoperative biopsy with frozen sections to confirm invasion histologically can be used in guiding a more extensive resection.^{128,135}

Operative treatment of locally invasive thyroid cancer ranges from shave excision to extended tracheal and laryngeal resections. The long relative survival rate with thyroid cancer and the lack of necessity for wide margins during surgical resection are factors that affect the extent of operation.^{133,134,141} Whenever possible, gross tumor should not be left behind, except when the medical condition of the patient cannot tolerate the resection and the risks of morbidity are greater than the potential benefits of the resection. A patient's unwillingness to proceed with an extensive procedure is another reason to leave behind gross tumor or not operate at all.^{119,141,145,151} Less conventional procedures (such as bronchoscopic excision or debulking operations) have all met with poor results.^{132,133}

Shave Excision. A shave excision removes gross disease from the neck structures (eg, larynx and trachea) without resecting them. This technique can be used when tumor around the trachea is tightly adherent or tumor

infiltration is limited to the perichondrium.^{119,125,136,142,154,156} Its advantage is the avoidance of the morbidity of a more extended resection.¹⁴³ Shave excision has resulted in survival rates that are similar to those for extended resection in several studies.^{123,143,145} Rare reports of no recurrence after shave excision have further supported its use under certain circumstances.¹⁴² Shave excision, which does not leave behind any gross disease, has been recommended in place of a complete en bloc resection when there are concerns about an increased risk of morbidity and death.¹⁴³ A central neck dissection may be needed along with shave excision to remove all gross tumor.¹¹⁹

The main argument against shave excision of an involved segment of tracheal cartilage is the potentially high rate of recurrence.^{122,133,134,150} In several retrospective analyses, complete tumor excision (including resection and reconstruction of the airway) was associated with improved survival rates compared with shave excision.^{133,134,146,150} A cumulative review of studies that compared shave excision with complete resection procedures showed a 38% and 24% recurrence rate, respectively.¹⁴⁶ The use of adjuvant therapy with either radioactive iodine or external beam irradiation after shave excision has not decreased high rates of recurrence.^{133,134,150} Park and colleagues¹⁵⁰ reported that only 4 of 16 patients with papillary or follicular thyroid carcinoma did not have local recurrence after shave excision. The major site of failure was in the central neck, so the macroscopic impression of an adequate resection most likely underestimates the extent of disease.¹²⁶ Studies that show comparable survival rates with complete en bloc resection are flawed by nonrandomization of patients. Consequently, the stage of disease may have been more advanced in patients with total resection compared with those with shave excision. In addition, shave excision without the use of frozen sections for margin evaluation actually may have removed the entire tumor and constitute a total resection.¹⁴⁶

Partial Laryngeal or Partial Tracheal (Tracheal Window) Resection. Impending airway obstruction from laryngeal invasion can be an indication for laryngectomy with well-differentiated tumors.¹¹⁸ A total laryngectomy is usually not needed; a full-thickness window resection often suffices. Subglottic or paraglottic invasion may be an indication for partial laryngectomy.^{119,141,143,146,151} Resection of a portion of the thyroid cartilage may not affect the subglottic airway.¹⁴¹ Superficial invasion of the outer tracheal cartilage without frank intraluminal involvement can be an indication for partial laryngeal resection.¹⁴¹

It is not uncommon to encounter cricoid cartilage involvement in addition to thyroid cartilage involvement. Treatment of the cricoid

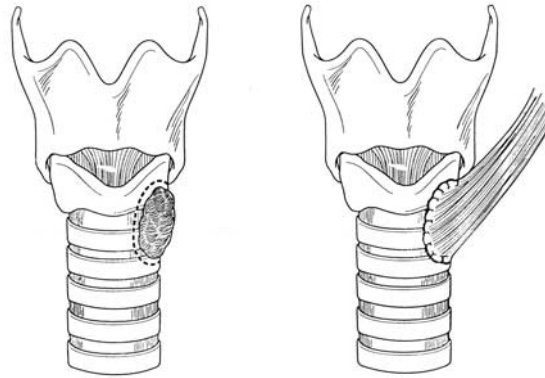


FIG 23. Cricoid cartilage resection with muscular flap reconstruction.

cartilage during partial laryngectomy merits special consideration. Twenty-five percent to 33% of the anterolateral cricoid cartilage may be resected with a subglottic laryngectomy without reconstruction.^{122,123,141} Similarly, removal of 30% or less of the cricoid ring will allow maintenance of a normal caliber airway with appropriate reconstruction.¹⁴³ Cartilage grafts may be used for reconstruction of defects of one third or less of the circumference of the cricoid cartilage.^{124,159} Caution over too extensive a resection of the cricoid cartilage is necessary because of a concern about recurrent laryngeal nerve injury. Friedman and colleagues^{122,141} proposed several parameters for partial resection of both the cricoid cartilage and the tracheal rings when the tumor invades into the cartilage, but not through it. Defects of 15% to 35% and 35% to 75% of the cricoid cartilage circumference warrant myocutaneous flap closure without and with a stent, respectively (Fig 23). Other forms of reconstruction, including Marlex mesh closure (Bard, Billerica, Mass) have had limited success.^{130,140}

The treatment principles for invasion that involve the first tracheal ring are similar to those treatment principles for cricoid cartilage involvement. Cartilaginous involvement, even without intraluminal spread, is a sufficient indication to perform a partial tracheal resection.¹⁴¹ Window resection can be used for intraluminal invasion by thyroid carcinoma through the anterior or lateral walls of the trachea. Some lesions that involve less than 30% of the tracheal circumference can be resected and reconstructed primarily without a flap for reinforcement (Fig 24).¹²² Some surgeons have resected one half of the circumference of a few tracheal rings without using a flap to buttress their primary repair.¹¹⁹

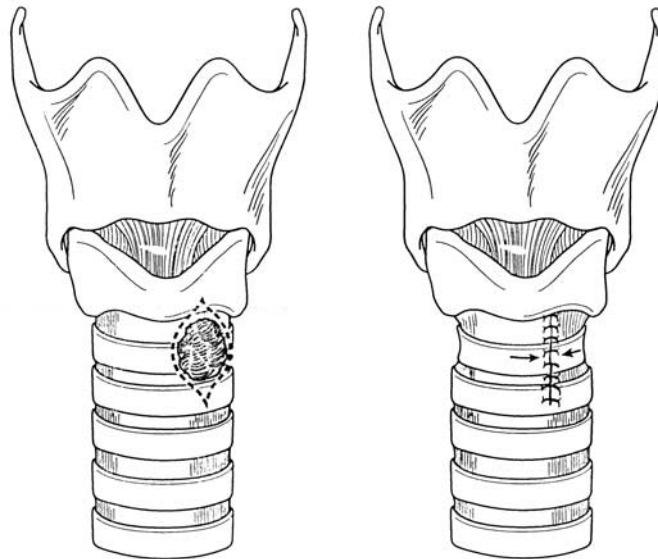


FIG 24. Tracheal resection repaired primarily.

When a thyroid tumor and a portion of trachea are removed en bloc, the defect can be closed with a flap of the overlying strap muscle, sternocleidomastoid muscle, pectoralis major muscle, or clavicular periosteum (Fig 25).^{119,122} Tracheal defects as small as 2 cm in size may require sternocleidomastoid advancement flap closure.¹³² The lack of rigidity in the flap with changes in the intraluminal pressure is a potential problem with this type of closure. Flap necrosis, air leak, and tracheal fistulas with the local vasculature are potential problems with partial resection and flap closure.¹²⁵ Because local recurrence is common with invasive thyroid carcinomas, damage to the local musculature and surrounding tissues from previous surgical procedures and radiation may decrease the chance for successful graft or flap reconstruction.^{125,141} A tracheostomy tube with subsequent removal 4 to 5 days after the operation can be sufficient for small anterior midline areas of invasion that require partial tracheal resection.¹¹⁹ Defects of more than 30% of the airway circumference, but less than 6 cm in length, may require both flap closure and a tracheal stent. Defects larger than 6 cm mandate a “T” tube stent (Fig 26).¹⁴⁶ Occasionally, lateral wall defects can be repaired, when necessary, with cartilage grafts.¹³⁶

When tracheal resection leaves a defect of more than one third of the circumference, tracheal fenestration can be an alternative reparative

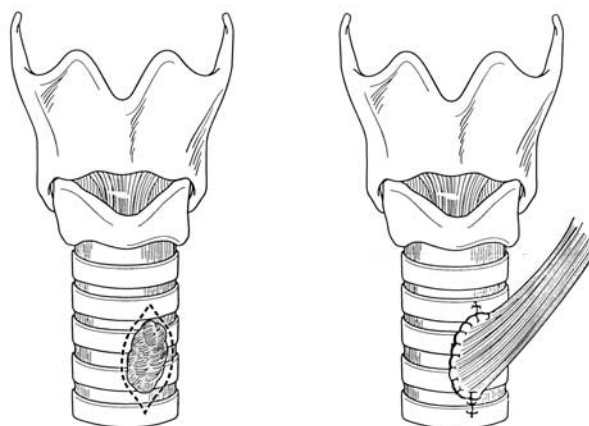


FIG 25. Tracheal resection with muscular flap reconstruction.

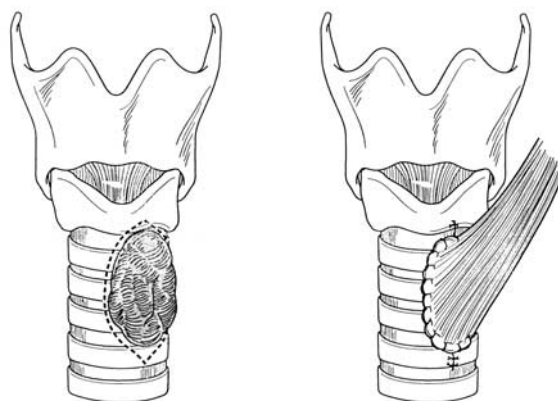


FIG 26. Tracheal resection of more than 6 cm in length that requires stent placement.

procedure.¹⁵⁹ The creation of a short-term tracheostomy followed by delayed closure with autografted cartilage and a skin flap can avoid the complication of tracheal narrowing after primary repair. The defect also may be too large to be reconstructed with a muscle flap without any skeletal support. The staged procedure can be less complex than circumferential resection followed by a primary anastomosis.¹⁵⁹ Recently, a free graft from conchal cartilage of the auricle has been described with moderate success in 4 of 5 patients. This technique has been proposed as a simpler, less invasive, and more cost-effective alternative compared with other forms of tracheoplasty.¹⁵⁹

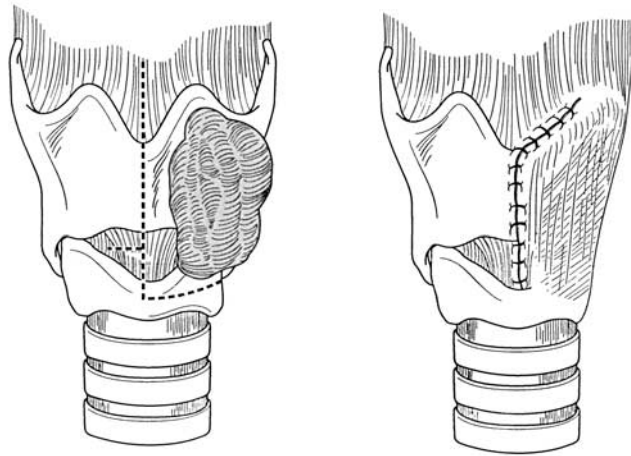


FIG 27. Vertical hemilaryngectomy.

Vertical Hemilaryngectomy. With extensive unilateral involvement, a vertical hemilaryngectomy can be attempted to save as much of the larynx as possible (Fig 27).¹²² Hemilaryngectomy preserves speech and swallowing, if complete excision of the tumor is achieved.^{119,124} Extensive reconstruction of the resected portion of the larynx is typically not required, except for muscular or myocutaneous flap closure.¹¹⁹ Both partial laryngectomy and vertical hemilaryngectomy have been used in patients with Hürthle and follicular cell carcinoma to prevent speech, swallowing, and asphyxiation difficulties.¹⁵¹

Circumferential Tracheal Resection with Primary Anastomosis. Circumferential tracheal resection with primary anastomosis is performed for more advanced disease.^{128,133-136,141,156,160} The concern that a more limited resection will leave behind residual tumor because of submucosal spread is the reason that circumferential sleeve resection followed by an end-to-end anastomosis has been advocated.¹⁶¹ Circular resection with primary anastomosis for deep tracheal invasion has been associated with a decreased rate of both local and distant recurrence, compared with simple removal of the involved thyroid gland that leaves macroscopically known residual disease.¹⁴⁵

Thyrotacheal and cricotracheal anastomoses have been used when the tracheal involvement is high.¹³⁶ A thyrotacheal anastomosis after extensive resection is the preferred treatment for extensive cricoid or tracheal involvement, which is defined as more than 60% of the circumference or when there is extensive subglottic involvement that requires resection of

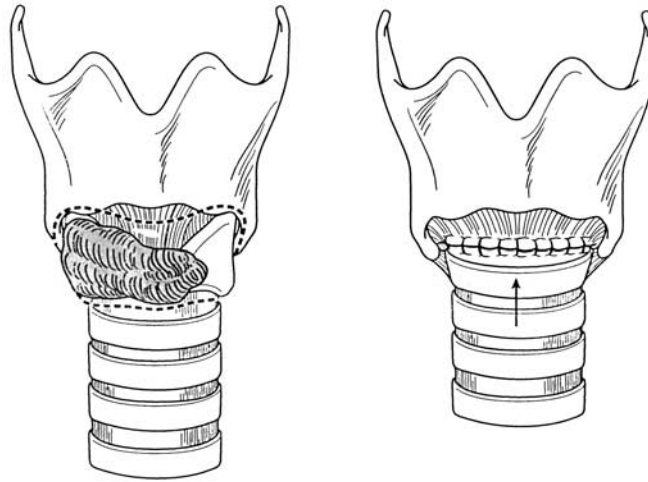


FIG 28. Thyrotracheal anastomosis after circumferential resection of extensive cricoid or tracheal thyroid cancer.

the entire anterior arch of the cricoid cartilage (Fig 28).^{122,141} This procedure may improve the survival rate with these advanced tumors.^{128,135} Division of the recurrent laryngeal nerves and loss of the circumferential cartilaginous support are 2 problems that are associated with resection of the cricoid cartilage before thyrotracheal anastomosis.¹⁶⁰ Given the difficulties with a thyrotracheal anastomosis, a cricotracheal anastomosis may be used in certain circumstances. With a cricotracheal anastomosis, an oblique incision from the inferior border of the thyroid cartilage anteriorly to the inferior margin of the cricoid plate posteriorly below the exposed recurrent laryngeal nerves is required.¹⁶⁰ Transection of the airway superior to the posterior margin may be accomplished by removal of a rim of cricoid cartilage subjacent to the posterior and lateral aspects of the submucosa (Fig 29).¹⁶⁰

Tracheal resection and primary anastomosis are used when other more limited resections are impossible and less than 5 to 6 cm of the trachea is involved (Fig 30).^{143,151} Guidelines for the performance of this procedure have included tracheal invasion of more than 60% of the circumference and involvement of 4 or fewer tracheal rings or less than 2.5 cm in tracheal length.^{122,125,151} Actually, up to 6 tracheal rings can be resected safely and still have a tension-free anastomosis.¹⁵⁶ Other authorities have recommended that age, body habitus, and number of involved tracheal rings (6 or 7) should be considered when a circumferential or sleeve

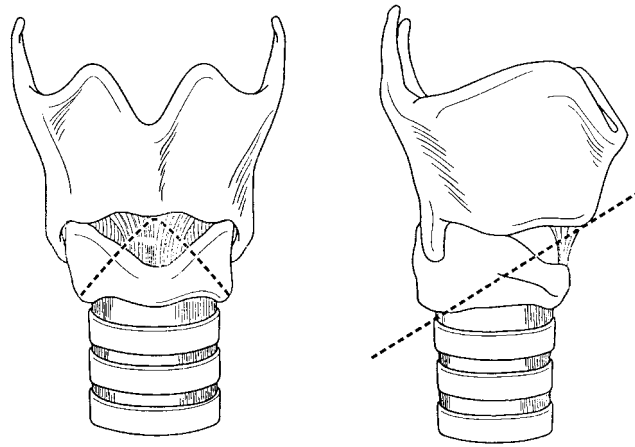


FIG 29. Line of resection for cricoid cartilage resection before a cricotracheal anastomosis.

resection with a primary anastomosis is performed.¹¹⁹ An omental flap can be used to assist healing of the end-to-end anastomosis after a circular resection.¹³³

Melliere and colleagues¹⁵⁶ performed resections of up to 4 tracheal rings using a release of the caudad trachea to create a tension-free primary anastomosis. Mobilization of the distal trachea is accomplished by dissection anteriorly and laterally with preservation of the posterior vasculature until the tracheal bifurcation is reached. Resection of more than 6 tracheal rings may require both mediastinal mobilization along the anterior surface of the trachea to the carina and a laryngeal release to achieve the end-to-end anastomosis.^{128,135} A suprahyoid release can also be used to decrease tension on a primary end-to-end anastomosis of defects of approximately 6 to 7 cm. This release is achieved by transecting the suprahyoid muscles from the superior surface of the hyoid bone.¹²⁵ A median sternotomy may be needed for mediastinal release of the distal trachea.¹²⁵ Finally, the patient's head may be placed in the flexed position while on a ventilator to minimize the tension on the anastomosis.^{125,156} Complications from this mobilization include anastomotic stenosis, difficulty with swallowing, wound infection, and suture failure.^{128,135} Tearing of the fascia at certain points along the trachea and violation of the tracheal blood supply during tracheal mobilization can be responsible for these complications.¹²⁵

Perioperative morbidity is reportedly higher with circumferential resections than with partial or window resections and includes laryngeal and

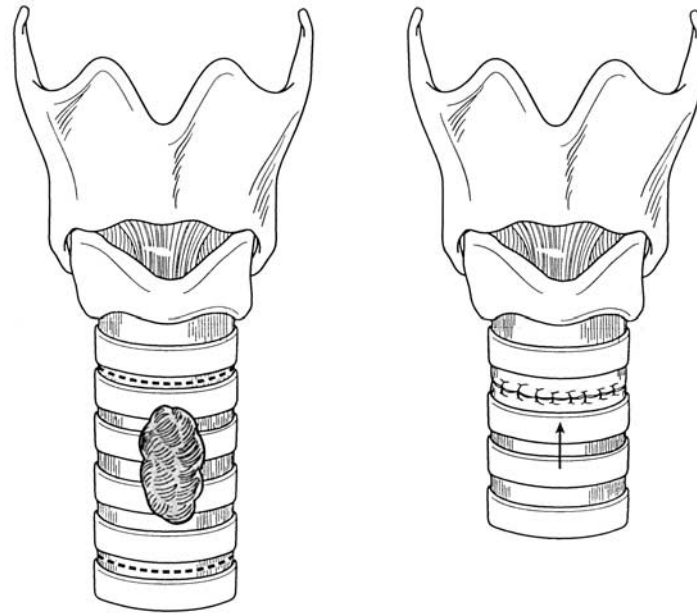


FIG 30. Circumferential tracheal resection with primary anastomosis.

anastomotic stenosis.¹²⁵ The tracheal anastomosis is also a high-risk site for recurrent laryngeal nerve injury.¹²² Laryngeal stenosis occurs independent of whether the patient has undergone a partial cricoid cartilage resection.¹³⁵

A variant of circumferential sleeve resection has been described by Musholt and colleagues¹²⁵ In a subset of patients with unilateral laryngotracheal invasion and a contralateral intact recurrent laryngeal nerve, they performed a laryngotracheal “step” resection (Fig 31). With this procedure a partial full-thickness laryngectomy or hemilaryngectomy are performed along with a tracheal incision on the contralateral side below the cricoid cartilage. The ipsilateral tracheal wall inferior to the excised larynx is resected to complement the laryngeal defect in a “step”-shape fashion.¹²⁵ Interrupted sutures are used for this anastomosis, which is additionally protected with a muscle flap.¹²⁵ This technique has been associated with a longer recurrence-free survival rate when compared with a partial or window resection. It also is associated with lower postoperative morbidity and greater stability.¹²⁵

Although most authorities consider circular resection and primary anastomosis to be the treatment of choice for any intraluminal tracheal

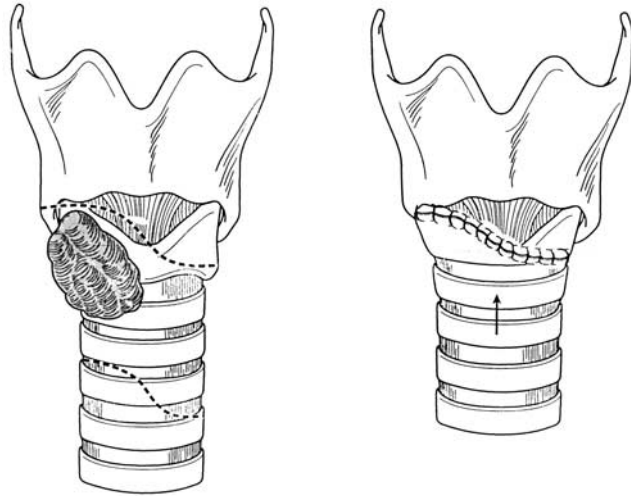


FIG 31. Laryngotracheal "step" resection as a variant of the circumferential resection.

invasion, there are other alternatives.¹³⁶ The trough method, in which a sleeve resection is repaired in 2 stages has been described for situations in which the intervening length between the 2 ends for anastomosis may be too long for primary repair.^{136,140} The posterior wall of the trachea is repaired primarily after the resection, and the anterolateral wall is left open with a tracheostomy tube in place. This defect is then reconstructed during a second-stage procedure with a local skin flap.¹³⁶

Total Laryngopharyngectomy or Total Laryngectomy. Historically, patients with airway invasion were treated with a total laryngectomy.¹⁴¹ Today, total laryngopharyngectomy is performed when thyroid carcinoma invades along the posterior margin of the trachea, precluding preservation of any laryngeal function (Fig 32).^{119,143,152} The lack of cartilage in the posterior larynx allows malignancy easy access to its lumen. The indications for total laryngopharyngectomy or laryngectomy include massive or extensive invasion of the thyroid cartilage, extensive paraglottic, subglottic or piriform sinus invasion, and more than 50% destruction of the cricoid cartilage.^{122,141,149} McCaffrey and Lipton¹²⁴ state that a total laryngectomy should be considered when more than one third of the cricoid cartilage circumference is involved. The poor blood supply to the cartilage, which limits the efficacy of adjuvant therapy, is another reason for total laryngectomy with carcinomas invading more than 50% of the thyroid or cricoid cartilage.¹³⁶ Total laryngectomy can palliate the symptomatic patient, but prolonged survival rates have not

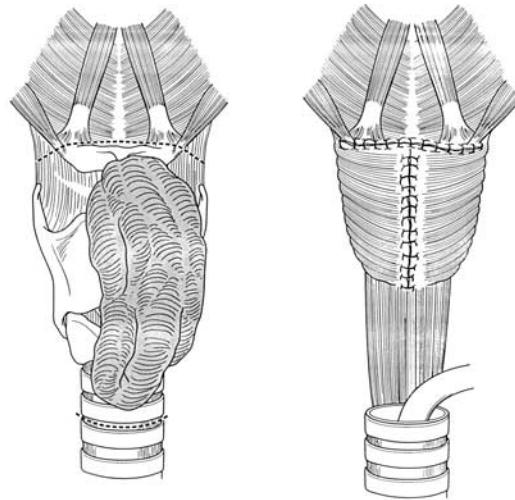


FIG 32. Posterior progression of advanced thyroid carcinoma around the trachea precludes preservation and mandates total laryngectomy.

been demonstrated with this procedure.^{118,126,137} Grillo and colleagues¹³³ advocate refraining from a total laryngectomy, even in the presence of positive margins because of the loss of function. However, they do support its use when there is no possible laryngeal salvage. Additional support for this radical operation is based on a decreased incidence of death by airway obstruction or hemorrhage.^{122,123,138} The relatively long life span with some thyroid carcinomas, even with distant metastases, is the reason for radical resection for palliation.^{122,123}

Intubation, Tracheostomy, and Nonoperative Treatment. Difficult intubation at the time of induction can occur with advanced local disease.^{128,135} Direct fiberoptic intubation is often required, and needle catheter intubation or tracheostomy may be necessary. Routine placement of a tracheostomy under local anesthesia below the area of involvement followed by conversion to general anesthesia once an airway is secured can be performed as an alternative to intubation.¹³⁵ Tracheostomy should be considered for severe preoperative stridor, tracheal displacement, or compression or when resection is impossible because of extensive disease.^{121,122,131,136-138,141,146} Intraoperative findings consistent with tracheomalacia, laryngeal edema, or bleeding are also indications for tracheostomy.¹³¹ Airway protection is enhanced by tracheostomy placement distal to the area of the intraluminal invasion and subsequent resection.^{128,131,135} Elective tracheostomy is not performed routinely

because of the risk of complications from this procedure and the technical difficulties brought on by the extensive tumor involvement.^{136,150}

Lymphoma that invades the trachea does not require operation and is best treated by radiation and chemotherapy.^{118,121,124,131,140} Some authorities have suggested that attempted resection is not indicated for anaplastic carcinoma, but this is disputed because of rare reports of 5-year survivors after operation.^{138,156} Spindle and giant cell carcinomas may also be treated nonoperatively because of their poor outcome.¹¹⁸ Tracheostomy may be slightly easier if the tumor must be cut through because of the relative avascularity of some of these neoplasms.¹³¹

Invasion of the Nervous System

The recurrent laryngeal nerve is commonly involved^{118,123,124,126,133,134,139,142,150} by direct extension of either the primary invasive thyroid cancer or a metastatic lymph node.¹²⁴ Recurrent laryngeal nerve involvement occurs more frequently than respiratory tract invasion.^{123,150} Both benign and malignant diseases can involve the recurrent laryngeal nerve. Nonmalignant disease such as Reidel's thyroiditis, Hashimoto's thyroiditis, and Graves' disease can compress the recurrent laryngeal nerve and cause paralysis.^{162,163} Invasion of the recurrent laryngeal nerve by papillary, follicular, and medullary thyroid carcinoma is frequently associated with invasion of other adjacent structures, including the larynx, trachea, and esophagus.¹³⁹ Medullary thyroid cancer also is associated with invasion of the vagus nerves.¹³⁹ The impact of recurrent laryngeal nerve invasion on survival is unclear; some reports show a decrease, and other reports show no adverse effects.^{119,123,162,164}

Dysphonia is usually the initial symptom of vocal cord paralysis because of recurrent laryngeal nerve invasion.¹²³ Hoarseness or stridor may be due to recurrent laryngeal nerve or airway invasion.^{124,152} The finding of a thyroid nodule with ipsilateral vocal cord paralysis should raise the specter of malignancy until proved otherwise.¹⁶²

When recurrent laryngeal nerve paralysis is present, it is prudent to image the neck with CT scanning or MRI to estimate the size and extent of the thyroid enlargement.¹⁶³ The evaluation is similar to that for assessment of respiratory tract invasion.¹²⁴ Direct or indirect laryngoscopy is useful for assessment of the patient's symptoms and for assistance with intraoperative decisions to sacrifice a unilaterally involved recurrent laryngeal nerve.¹³¹ If a functioning recurrent laryngeal nerve is present, every reasonable effort should be made to preserve it. Concern over leaving behind microscopic disease should not preclude shave dissection

of the tumor away from the nerve. Conversely, an inordinate effort to preserve a nonfunctioning recurrent laryngeal nerve is inappropriate.^{119,123,124} Falk and McCaffrey¹⁶² re-examined the report by McCaffrey and colleagues¹²³ and identified 24 patients with papillary carcinoma with recurrent laryngeal nerve involvement that was either isolated or associated with adjacent muscle invasion from a total of 262 patients with advanced disease. Complete tumor excision that included resection of the recurrent laryngeal nerve in 17 patients (of whom 5 patients had vocal cord paralysis) was not associated with any increase in survival rate compared with the 7 patients who had incomplete excision. Based on this finding, they recommended preservation of a functioning recurrent laryngeal nerve, followed by radioactive iodine and TSH suppression with thyroxine to eliminate or to control any residual disease from invasive papillary cancer. The incidence of infiltration of the recurrent laryngeal nerve that met the inclusion criteria was low with follicular and medullary carcinomas, so extrapolations from the papillary carcinoma data were made. Because follicular carcinomas are typically responsive to radioactive iodine therapy and TSH suppression, incomplete resection was recommended. Although this adjuvant therapy is not efficacious for patients with medullary cancers, the authors advised a more conservative approach because of their relatively long survival rate. The same recommendation was not made for refractory anaplastic carcinoma.¹⁶² Nishida and colleagues¹⁶⁴ evaluated the prognosis of patients with recurrent laryngeal nerve invasion with intact preoperative vocal cord movement and found that preservation of the recurrent laryngeal nerve in well-differentiated thyroid cancers did not increase local or regional recurrence or result in a poorer prognosis. Few data are available regarding invasion of the recurrent laryngeal nerve by anaplastic carcinoma. Falk and McCaffrey¹⁶² suggested that, because of the aggressive nature of medullary and anaplastic carcinomas, resection of the involved and invariably paralyzed recurrent laryngeal nerve was beneficial to improve an already poor prognosis. External beam radiation with recurrent laryngeal nerve preservation is another alternative for medullary carcinoma even though proof of benefit is lacking.¹⁶² Shave excision from the recurrent laryngeal nerve has been associated with disease-free survival of more than 4 years.¹⁴²

With preoperative vocal cord paralysis, medialization of the involved vocal cord may be performed to improve phonation, if the contralateral vocal cord is not paralyzed from either the operation or the disease process.¹³⁶ This is probably best performed at a separate time from the thyroid operation. A tracheostomy is required after operation after

bilateral recurrent laryngeal nerve resection or bilateral recurrent laryngeal nerve nonfunction.¹¹⁹

Recurrent laryngeal nerve paralysis from invasive lymphoma can be treated by a partial resection to clarify the diagnosis followed by postoperative chemotherapy and radiation therapy, with a likely expectation for return of nerve function.¹⁶² Compromised nerve function is not always associated with invasive thyroid cancer, and the surgeon should not proceed with radical resection without obtaining a histologic diagnosis of malignancy.¹⁶²

Invasion of the phrenic, vagus, spinal accessory, and hypoglossal nerves and the sympathetic chain by differentiated thyroid carcinoma can occur^{142,145,165} but is much less frequent than isolated recurrent laryngeal nerve involvement. Involvement of these nerves is usually associated with invasion of other structures. With the limited available data, the preferred treatment of isolated invasion of these nerves has not been determined. When thyroid carcinoma has infiltrated these nerves, they are usually resected.¹⁵⁶

Invasion of the Digestive Tract

Invasion of the digestive tract by thyroid carcinoma is almost as common as invasion of the respiratory tract. Pharyngeal invasion usually occurs after laryngeal invasion, and esophageal invasion usually occurs after tracheal invasion. It is not uncommon for patients to have symptoms of both respiratory and digestive tract invasion.¹²⁴ The pharynx and esophagus can be invaded by the primary tumor or by metastatic lymph nodes.^{123,124,139} Invasion tends to penetrate the muscular layer with relative sparing of the mucosa and submucosa.¹²³ Typically, a well-differentiated thyroid carcinoma will invade only the outer muscular layer.^{119,123,124}

Dysphagia is a frequent manifestation of locally invasive thyroid carcinoma.^{125-127,153} It may be due to transmitted pressure from the mass anteriorly or from direct extension of the carcinoma into the esophagus. Aspiration from esophageal obstruction may account for some respiratory symptoms.¹²⁷ Inanition from esophageal obstruction by the invasive tumor can contribute to mortality rates.¹²⁷ Esophageal invasion with concomitant deep or superficial tracheal invasion is a poor prognostic finding.¹⁴⁵ Several studies have shown that patients with esophageal invasion have significantly poorer survival rates.¹²³

Imaging modalities, such as CT or MRI, can detect possible esophageal invasion. A barium esophagram may reveal an eccentric mass effect, irregular luminal narrowing, a nodular or serrated esophageal contour, an

ulceration, or an obstruction in the upper esophagus.^{119,166} Esophagoscopy may also detect invasion and offers a method to biopsy the lesion if there is intraluminal involvement.^{125,130}

Surgical treatment consists of resection with clear margins. Shave excision is an option and frequently is performed simultaneously with a shave excision from the respiratory tract.^{124,156} A small portion of the lateral pharyngeal wall can be excised for limited involvement.¹⁷⁰ With intraluminal invasion, resection of the piriform sinus with a lateral pharyngotomy is a method that maintains laryngeal and pharyngeal function.¹²⁴ For esophageal involvement of only the muscular layer, no repair or simple suture repair is all that is required, if an intact submucosal layer can be maintained.^{119,128,133,134,156} A large endoesophageal tube can facilitate this type of resection.¹⁵⁶ Full-thickness invasion may require partial resection and immediate suture repair.¹⁵³ Moderately sized intraluminal defects after resection can be reconstructed with myocutaneous or myofascial flaps. Larger and circumferential defects can require a jejunal free flap or gastroplasty.^{119,130,140} Colonic interposition grafts after an esophagectomy are an alternative.¹³³ Circumferential resection with primary anastomosis has not been described for esophageal invasion by thyroid carcinoma because of the fixed anatomic position and blood supply to the esophagus. Leakage and abscess are complications that are associated with primary repair of the esophageal defect that was created by the resection.¹⁵³ Esophageal dilatation has been described for esophageal strictures as the result of thyroid carcinoma involvement.¹⁵⁴

Invasion of the Vascular and Lymphatic Systems

Arterial, venous, and lymphatic invasion occur even less frequently. Their rare occurrence has precluded any formal study of the appropriate treatment.^{157,167} Extrathyroidal vascular invasion is associated with a 40% incidence of distant metastases from papillary thyroid cancer and is a significant predictor of distant spread. Intrathyroidal vascular invasion of smaller vessels is not only associated with distant metastasis but also with local, distant, and more aggressive recurrence.¹⁶⁷ Unfortunately, intraluminal tumor involvement is detected often at autopsy.^{165,168}

Venous invasion occurs more often than arterial invasion.¹⁶⁹ The pathophysiologic features of tumor thrombus propagation are related to the deposition of fibrin on the invading tumor cells. This fibrin serves as the matrix for further growth.¹⁷⁰ The superior vena cava syndrome is the most common clinical manifestation of intraluminal extension of thyroid carcinoma.¹⁷⁰ Nevertheless, this syndrome is more commonly associated with external compression of the superior vena cava than with either

external invasion or intraluminal extension of thyroid cancer.^{157,165,168,169} Clinically, the superior vena cava syndrome manifests with upper extremity and head and neck edema with dilated neck veins, chest wall collateralization, restriction of movement, and severe dyspnea.^{157,170} Typically, follicular carcinomas grow into veins and extend intraluminally as a tumor thrombus.¹⁶⁸ Direct invasion of the internal jugular vein is reported to be as high as 13%.¹¹⁸ Extension from the cervical veins through the superior vena cava to the cardiac chambers remains a possibility with these lesions and may be associated with dyspnea or generalized venous stasis. Sudden death from a resultant pulmonary embolism may occur.^{169,170} In rare circumstances, the tumor thrombus may extend from the superior vena cava to the right atrial chamber.¹⁵⁷ Jugular vein involvement is also associated with tracheal invasion.^{123,145,150,155,157,165,170}

Imaging by contrast-enhanced CT scanning or phlebography can be used to detect and evaluate vascular invasion.^{157,165,169,170} Distended veins with enhancing walls, low attenuating intraluminal filling defects, and adjacent soft tissue swelling are CT findings with a tumor thrombus.¹⁶⁹ Angiography is used to evaluate the full extent of vascular invasion.^{128,129,133} The disadvantage of all these imaging studies is the use of iodine-rich contrast that hinders and delays the postoperative use of therapeutic radioactive iodine.¹⁵⁷

Invasion of the superior vena cava should no longer be a contraindication for operation,^{155,168} even in the face of massive intraluminal involvement. Before 1978, aggressive surgical intervention for thyroid carcinoma that invaded the central veins was not performed.¹⁵⁷ Instead, radiation therapy was the mainstay for this problem.¹⁷⁰ Now, radioactive iodine therapy may be used as adjuvant therapy after operative removal of the tumor thrombus.¹⁵⁵ Because of the risks of tumor embolism and obstruction of the tricuspid valve, an operation should be performed.^{168,169} Aggressive surgical intervention also has been advocated to reduce the incidence of further metastases.¹⁵⁵ Removal of the tumor thrombus can be achieved through either a midline partial sternotomy or right parasternal thoracotomy. These approaches allow for excellent exposure to control the vena cava during subsequent manipulation and to perform any necessary mediastinal dissection. These incisions can be used in conjunction with a cervical collar incision.¹⁷⁰ A longitudinal cavotomy may be used to remove the tumor thrombus in the superior vena cava. A small portion of the vena cava may require resection to excise tumor adherent to the venous wall.¹⁵⁷ Resection of the larger tributaries of the superior vena cava or the superior vena cava itself may be followed

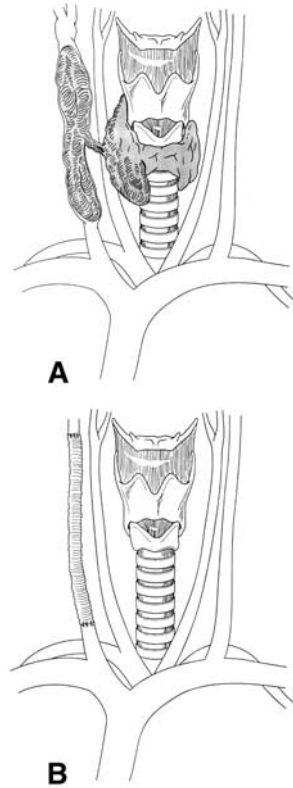


FIG 33. A, Extension of thyroid tumor as a thrombus; **B**, reconstitution of internal jugular vein with prosthetic graft.

with reconstitution with autogenous or prosthetic grafts. Polytetrafluoroethylene (PTFE; W.L. Gore & Associates Inc, Newark, Del) is commonly used (Fig 33).¹⁶⁸⁻¹⁷⁰ Restoration of continuity should be performed at the time of the initial vascular resection because of the probable difficulties with scar tissue during a reoperation.¹⁶⁵ Cardiopulmonary bypass should be available at operation if there is great vessel invasion because of possible cardiac chamber emboli or involvement.^{157,168-170} Tumor in the right ventricle that cannot be moved manually into the superior vena cava is an indication for cardiopulmonary bypass. Catheter embolectomy has also been used to remove the tumor thrombus.¹⁵⁷ Successful tumor thrombectomy combined with definitive therapy for the primary malignancy has been performed for extensions of the tumor to the internal jugular, subclavian, and innominate veins and superior vena cava.^{155,165,168}

Involved internal jugular veins have been resected segmentally without any postoperative complications or deaths.¹⁶⁵ Experience with bilateral jugular venous invasion is very limited. Thomas and colleagues¹⁶⁹ reported a patient with rare bilateral internal jugular vein invasion by follicular thyroid carcinoma. This patient collapsed and died suddenly after the CT scan. The surgical treatment of bilateral jugular vein involvement can be either staged or not. With staged treatment, a unilateral resection and reconstruction preferably with autogenous prosthesis is performed initially. After at least 1 month, the contralateral side is then resected and reconstructed in a similar manner.¹⁷¹ The 1-month delay allows for sufficient collateral flow to develop on the reconstructed side to avoid complications of facial edema and increased intracranial pressure. The graft will inevitably thrombose, but collateralization around this site will occur by the time the second operation is performed.^{171,172} With a single-stage procedure, bilateral resection followed by anastomosis between the distal end of the internal jugular vein to the proximal end of the ipsilateral external jugular vein can achieve excellent results.¹⁷¹

Carotid artery invasion is associated with a poor prognosis.^{153,158,173} Treatment of carotid artery invasion has included ligation and resection of the involved portion.^{122,136,158} Before operation, balloon catheter occlusion of the affected vessel can be performed.¹⁷⁴ Subclavian artery invasion has also been treated by ligation and resection.¹³³ Both carotid and subclavian artery invasion can be treated by shave excision.^{126,153} Omental flaps have been used to protect arterial structures from erosion and subsequent invasion by thyroid carcinomas that could not be resected completely.^{133,134}

The extent of lymph node involvement dictates whether a modified or conventional lymph node dissection is required.¹⁴⁰ Extensive lymph node involvement may require an en bloc dissection that includes the internal jugular vein.¹²⁸ Modified radical neck dissection has been included as part of the definitive operative resection, in addition to total thyroidectomy.^{119,128,133,137,150} With lateral compartment nodal involvement, extension of the cervical collar incision laterally and cranially is recommended.¹²⁵ Median sternotomy can be necessary as part of the modified radical neck dissection to remove lymph nodes that extend down into the mediastinum.^{128,135}

Invasion of the Musculature

The strap muscles and sternocleidomastoid muscles are frequent sites of tumor invasion because of their proximity to the thyroid gland.^{123,142,145,150} Muscular invasion reportedly occurs in 70% of

tumors that also invade the trachea.¹⁴⁵ Isolated spread to the strap muscles is not associated with a worse survival rate.^{123,124,142} Isolated local invasion by papillary thyroid cancer into the strap muscles can be treated by a straightforward resection of the involved tissue.^{123,155} Invasion of the sternocleidomastoid muscle that occurs simultaneously with deep or superficial invasion of the trachea is a poor prognostic factor for survival.¹⁴⁵ Local muscular invasion in recurrent or metastatic papillary carcinoma is associated with a significantly higher rate of distant metastasis and ultimately death.¹⁷⁵

Adjuvant Therapy

Well-differentiated thyroid carcinoma invasion of adjacent structures requires adjuvant therapy.¹²² Iodine-131, external beam radiation, brachytherapy, and thyroid hormone suppression are used alone or in combination.^{119,120,123,137,141,150,152} External beam radiation and chemotherapy have been used concomitantly with mixed results.^{153,156} Iodine-131 and external beam radiation are used frequently after shave excision.^{119,150} Adequate surgical resection of the primary and other gross tumor with only a small amount of residual disease is the optimal setting in which radioactive iodine treatment is beneficial.¹¹⁸ Melliere and colleagues¹⁵⁶ used radioactive iodine, external beam therapy, or both in 45 patients with papillary, follicular, or anaplastic carcinoma. With either postoperative radioactive iodine or external beam irradiation after shave excision, 20% of patients had either local recurrence or distant metastasis. Among 6 patients who were treated with extensive surgical resection followed by radioactive iodine and/or external beam irradiation, there were no deaths related to recurrent thyroid cancer until 6 years after the operation, when a local recurrence developed in 1 patient. Interestingly, this patient did not undergo external beam irradiation and was only treated with radioactive iodine. Based on this experience, the authors recommended both radioactive iodine and external beam irradiation after a total thyroidectomy for patients with evidence of invasion.¹⁵⁶ Iodine-131 therapy is not as effective with extensive invasion into the trachea, presumably because of the decreased blood supply to the cartilage. External beam radiotherapy alone is useful when there is an Iodine-131-resistant tumor with residual gross or microscopic disease or after shave excision of local invasion of the recurrent laryngeal nerve.^{119,152,153,156} Other than for these indications, the value of external beam radiotherapy has yet to be demonstrated clearly.¹¹⁹ Chemotherapy for anaplastic carcinomas in conjunction with either operation or other adjuvant therapy has not conclusively prolonged survival rates.^{153,156} The limitations or failure of

adjuvant therapy may merit consideration of a repeat and more complete resection.¹³⁷

Reoperations

The general indications for a thyroid reoperation include recurrent thyroid cancer, occurrence of cancer in the thyroid remnant after an operation for benign disease, symptomatic recurrent nodular or multinodular goiter, and recurrent thyrotoxicosis.^{176,177}

Thyroid reoperations are associated with a higher complication rate than are primary operations.^{177,178} Central neck reoperations are technically more challenging for a variety of reasons. The presence of sutures and clips from previous operations and scarring and fibrosis of the tissue planes makes dissection tedious and difficult. The complications that are reported to occur most often include hypoparathyroidism and injury to the recurrent laryngeal nerve. Transient recurrent laryngeal nerve injury has been reported to occur in 1.5% to 5% of patients, and permanent recurrent laryngeal nerve injury has been reported to occur in 2% to 6% of patients in thyroid reoperations.^{176,178-180} Transient hypoparathyroidism is reported to have an incidence of 3% to 15%, and permanent hypoparathyroidism is reported to have an incidence of 0% to 3.5%.¹⁷⁶ This low incidence of permanent hypoparathyroidism has been attributed to improved operative technique aimed at the preservation of the vascular pedicle to the parathyroid glands and to the use of parathyroid autotransplantation.¹⁷⁶

Avoidance of injury to the recurrent laryngeal nerve can be achieved by identifying the nerve early in the operation, keeping it visualized throughout the dissection, avoiding any unnecessary stretch and devascularization of it, and only using electrocautery away from the nerve in a discriminate and careful manner.

Moley and colleagues¹⁸¹ describe 3 operative approaches to identify the nerve in reoperations. These include a lateral or “back door” approach, a low anterior approach, and an approach in which the recurrent laryngeal nerve is identified by dissection between the superior pole of the thyroid and the larynx. In the lateral approach, the anterior border of the sternocleidomastoid muscle is mobilized and retracted laterally. In doing so, the sternohyoid and sternothyroid muscles are exposed. The lateral border of the sternothyroid muscle is mobilized off the carotid artery and jugular vein and reflected medially. Gentle lateral traction on the carotid artery is used to expose the paratracheal soft tissue inferolateral to the inferior pole of the thyroid. On the right, the recurrent laryngeal nerve lies posterior to the carotid artery. On the left side, the recurrent laryngeal

nerve is located more medial but is still exposed with lateral retraction of the left carotid artery. In the low anterior approach, the strap muscles are separated down to the sternal notch and reflected laterally. Dissection is carried down to the paratracheal regions. The right or left recurrent laryngeal nerves can be identified in the fat and nodal tissue as they come out from behind the ipsilateral carotid artery.

Finally, dissection between the superior pole of the thyroid and larynx can be used for reoperations in which some residual thyroid is intact. The recurrent laryngeal nerve is identified as it enters the larynx with dissection in the avascular plane between the larynx and the superior pole of the thyroid gland. This is accomplished by gently retracting the superior pole laterally with careful dissection along the larynx to the laryngotracheal groove, where the recurrent laryngeal nerve often branches.

Any of these 3 approaches can be used if the surgeon is familiar with them. The choice is made according to which best avoids the scarring from the previous operations and provides uninvolved access to virgin tissue planes.

REFERENCES

1. Welbourn RB. The thyroid. In: Welbourn RB, editor. The history of endocrine surgery. New York: Praeger; 1990: p. 9-82.
2. Bliss RD, Gauger PG, Delbridge LW. Surgeon's approach to the thyroid gland: surgical anatomy and the importance of technique. *World J Surg* 2000;24:891-7.
3. Thompson NW, Olsen WR, Hoffman GL. The continuing development of the technique of thyroidectomy. *Surgery* 1973;6:913-27.
4. Gray SW, Skandalakis JE, Akin JT. Embryological considerations of thyroid surgery: developmental anatomy of the thyroid, parathyroids and the recurrent laryngeal nerve. *Am Surg* 1976;42:621-8.
5. Larsen W. Human embryology. Churchill Livingstone Inc; New York: 1993.
6. Tsang SK, Maher J. Thyroid hemiagenesis accompanying a thyroglossal duct cyst: a case report. *Clin Nucl Med* 1998;23:229-32.
7. Shaha AR, Gujarati R. Thyroid hemiagenesis. *J Surg Oncol* 1997;65:137-40.
8. Organ GM, Organ CH. Thyroid gland and surgery of the thyroglossal duct: exercise in applied embryology. *World J Surg* 2000;24:886-90.
9. Josephson GD, Spencer WR, Josephson JS. Thyroglossal duct cyst: the New York eye and ear infirmary experience and a literature review. *Ear Nose Throat J* 1989;77:642-51.
10. Athow AC, Fagg NL, Drake DP. Management of thyroglossal cysts in children. *Br J Surg* 1989;76:811-4.
11. North JH, Foley AM, Hamill RL. Intrathyroid cysts of thyroglossal duct origin. *Am Surg* 1998;64:886-8.
12. Sistrunk WE. The surgical treatment of cysts of the thyroglossal tract. *Ann Surg* 1920;71:121-2.

13. Jamshidi M, Kasirye O, Smith J. Ectopic thyroid nodular goiter presenting as a porta hepatis mass. *Am Surg* 1998;64:305-6.
14. Williams ED, Toyn CE, Harach HR. The ultimobranchial gland and congenital thyroid abnormalities in man. *J Pathol* 1989;159:135-41.
15. Curtis LE, Sheahan DG. Heterotopic tissues in gallbladder. *Arch Pathol* 1969;88:677-83.
16. Takahashi T, Ishikura H, Kato H, Tanabe T, Yashiki T. Ectopic thyroid follicles in the submucosa of the duodenum. *Virchows Arch A* 1991;418:547-50.
17. Hoda SA, Huvos AG. Struma salpingis associated with struma ovarii. *Am J Surg Pathol* 1993;17:1187-9.
18. Kurman RJ, Prabha C. Thyroid and parathyroid glands in the vaginal wall: report of a case. *Am J Clin Pathol* 1973;59:503-7.
19. Bando Y, Nagai Y, Ushiogi Y, Toya D, Tanaka N, Fujisawa M. Development of Grave's hyperthyroidism from primary hypothyroidism in a case of thyroid hemiagenesis. *Thyroid* 1999;9:183-7.
20. Mikosch P, Gallowitsch HJ, Kresnik E, Molnar M, Gomez I, Lind P. Thyroid hemiagenesis in an endemic goiter area diagnosed by ultrasonography: report of sixteen patients. *Thyroid* 1999;9:1075-84.
21. DeRemigis P, D'Angelo M, Bonaduce S, DiGiandomenico V, Sensi S. Comparison of ultrasonic scanning and scintiscanning in the evaluation of thyroid hemiagenesis. *J Clin Ultrasound* 1985;13:561-3.
22. McHenry CR, Walfish PG, Rosen IB, Lawrence AM, Paloyan E. Congenital thyroid hemiagenesis. *Am Surg* 1995;61:634-9.
23. Melnick JC, Stemkowski PE. Thyroid hemiagenesis (hockey stick sign): a review of the world literature and report of four cases. *J Clin Endocrinol Metab* 1981;52:247-51.
24. Hamburger JI, Hamburger SW. Thyroid hemiagenesis. *Arch Surg* 1970;100:319-20.
25. Henry JF. Surgical anatomy and embryology of the thyroid and parathyroid glands and recurrent and external laryngeal nerves. In: Clark OH, Quan-Yang D, eds. *The textbook of endocrine surgery*. Philadelphia: Saunders; 1997: p. 8-14.
26. Studley JGN, Lynn J. Surgical anatomy of the thyroid gland and the technique of thyroidectomy. In: Lynn J, Bloom SR, editors. *Surgical endocrinology*. Jordan Hill, Oxford: Butterworth-Heinemann; 1993: p. 231-9.
27. Moley JF, DeBenedetti MK. Patterns of nodal metastases in palpable medullary thyroid carcinoma: recommendations for extent of node dissection. *Ann Surg* 1999;229:880-8.
28. Chouke KS, Whitehead RW, Parker AE. Is there a closed lymphatic system connecting thyroid and thymus glands? *Surg Gynecol Obstet* 1932;54:856.
29. Attie JN, Khafif RA, Steckler RM. Elective neck dissection in papillary carcinoma of the thyroid. *Am J Surg* 1971;122:464-71.
30. Frazell EL, Foote FW. Papillary thyroid carcinoma: pathological findings in cases with and without clinical evidence of cervical node involvement. *Cancer* 1955;8:1164-6.
31. Noguchi S, Noguchi A, Murakami N. Papillary carcinoma of the thyroid: developing patterns of metastasis. *Cancer* 1970;26:1053-60.
32. Moore KL. *Clinically oriented anatomy*. 3rd ed. Baltimore: Williams and Wilkins; 1992: p. 816-25.

33. Wagner HE, Seiler C. Recurrent laryngeal nerve palsy after thyroid gland surgery. *Br J Surg* 1994;81:226-8.
34. Skandalakis JE, Droulias C, Harlaftis N, Tzinas S, Gray SW, Akin JT. The recurrent laryngeal nerve. *Am Surg* 1976;42:629-34.
35. Katz AD, Nermiroff P. Anastomoses and bifurcations of the recurrent laryngeal nerve-report of 1177 nerves visualized. *Am Surg* 1993;59:188-90.
36. Reed AF. The relations of the inferior laryngeal nerve to the inferior thyroid artery. *Anat Rec* 1943;85:17-23.
37. Sturniolo G, D'Alia C, Tonate A, Gagliano E, Taranto F, Lo Schiavo MG. The recurrent laryngeal nerve related to thyroid surgery. *Am J Surg* 1999;177:485-8.
38. Hisham AN, Aina EN. Zuckerkindl's tubercle of the thyroid gland in association with pressure symptoms: A coincidence or consequence? *Aust NZ J Surg* 2000;70:251-3.
39. Pelizzo MR, Tonaito A, Gemo G. Zuckerkindl's tuberculum: an arrow pointing to the recurrent laryngeal nerve (constant anatomical landmark). *J Am Coll Surg* 1998;187:333-6.
40. Lekacos NL, Tzaardis PJ, Sfikakis PG, Patoulis SD, Restos SD. Course of the recurrent laryngeal nerve relative to the inferior thyroid and the suspensory ligament of berry. *Int Surg* 1992;77:287-8.
41. Lahey FH, Hoover WB. Injuries to the recurrent laryngeal nerve in thyroid operations. *Ann Surg* 1938;108:548-51.
42. Riddel V. Thyroidectomy: prevention of bilateral recurrent nerve palsy. *Br J Surg* 1970;57:1-42.
43. Droulias C, Tzinas S, Harlaftis N, Akin JT, Gray SW, Skandalakis JE. The superior laryngeal nerve. *Am Surg* 1976;42:635-8.
44. Durham CF, Harrison TS. The surgical anatomy of the superior laryngeal nerve. *Surg Gynecol Obstet* 1964;118:38-44.
45. Reeve T, Thompson NW. Complications of thyroid surgery: how to avoid them, how to manage them, and observation on their possible effect on the whole patient. *World J Surg* 2000;24:971-5.
46. Lennquist S, Cahlin C, Smeds S. The superior laryngeal nerve in thyroid surgery. *Surgery* 1987;102:999-1006.
47. Clader DN, Luter PW, Daniels BT. A photographic study of the superior and inferior thyroid arteries. *Am Surg* 1957;23:609-18.
48. Jacobs JK, Aland JW, Ballinger JF. Total thyroidectomy. *Ann Surg* 1983;197:542-9.
49. Henry JF, Audiffret J, Denizot A, Plan M. The nonrecurrent inferior laryngeal nerve: review of 33 cases, including two on the left side. *Surgery* 1988;104:977-84.
50. Sanders G, Uyeda RY, Karlan MS. Nonrecurrent inferior laryngeal nerves and their association with a recurrent branch. *Am J Surg* 1983;146:501-3.
51. Wade JSH. Thyroidectomy. *Br J of Hospital Med* 1978;10:456-68.
52. Sanders LE, Rossi RL, Cady B. Surgical complication and their management. In: Cady B, Rossi RL, editors. *Surgery of the thyroid and parathyroid glands*, 3rd ed. Philadelphia: Saunders; 1991: p. 326-36.
53. Kahky MP, Weber S. Complications of surgery of the thyroid gland and parathyroid glands. *Surg Clin North Am* 1993;73:307-21.
54. Jatzko GR, Lisborg PH, Muller MG, Wette VM. Recurrent nerve palsy after thyroid

- operations-principal nerve identification and a literature review. *Surgery* 1994;115:139-44.
55. Al-Suliman NN, Rytto NF, Qvist N, Blichert-Toft M, Graversen HP. Experience in a specialist thyroid surgery unit: a demographic study, surgical complications, and outcome. *Eur J Surg* 1997;163:13-20.
 56. Chessman A, Holden H. Management of the damaged recurrent laryngeal nerve following thyroid surgery. In: Lynn J, Bloom SR, editors. *Surgical endocrinology*. Jordan Hill, Oxford: Butterworth-Heinemann; 1993: p. 324-9.
 57. Koufman JA. Laryngoplasty for vocal cord medialization: an alternative to Teflon. *Laryngoscope* 1986;96:726-31.
 58. Netterville JL, Stone RE, Luken ES, Civantos FJ, Ossoff RH. Silastic medialization and arytenoid adduction: the Vanderbilt experience. a review of 116 phonosurgical procedures. *Ann Otol Rhinol Laryngol* 1993;102:413-24.
 59. Horsley JS. Suture of the recurrent laryngeal nerve with report of a case. *Trans South Surg Gynecol Assoc* 1909;22:161-7.
 60. Frazier CH, Mosser WB. Treatment of recurrent laryngeal nerve paralysis by nerve anastomosis. *Surg Gynecol Obstet* 1926;43:134-9.
 61. Lahey FH. Suture of the recurrent laryngeal nerve for bilateral abductor paralysis. *Ann Surg* 1927;87:481-4.
 62. Hoover WB. Surgical procedures for the relief of symptoms of paralysis of the recurrent laryngeal nerves. *Surg Clin North Am* 1953;33:879-85.
 63. Crumley RL, Izdebski K, McMicken B. Nerve transfer versus Teflon injection for vocal cord paralysis: a comparison. *Laryngoscope* 1988;98:1200-4.
 64. Schwartz AE, Friedman EW. Preservation of the parathyroid gland in total thyroidectomy. *Surg Gynecol Obstet* 1987;165:327-31.
 65. Tovi F, Noyek AM, Chapnik JS, Freeman JL. Safety of total thyroidectomy: review of 100 consecutive cases. *Laryngoscope* 1989;99:1233-7.
 66. Hamming JF, Van De Velde CJH, Goslings BM, et al. Prognosis and morbidity after total thyroidectomy for papillary, follicular and medullary thyroid cancer. *Eur J Cancer Clin Oncol* 1989;25:1317-23.
 67. Shaha A, Jaffe B. Complications of thyroid surgery performed by residents. *Surgery* 1988;104:1109-14.
 68. Newman E, Shaha AR. Substernal goiter. *J Surg Oncol* 1995;60:207-12.
 69. Mack E. Management of patients with substernal goiters. *Endocrine Surg* 1995;75:377-93.
 70. Buckley JA, Stark P. Intrathoracic mediastinal thyroid goiter: imaging manifestation. *Am J Rad* 1999;173:471-5.
 71. Katlic MR, Wang C, Grillo HC. Substernal goiter. *Ann Thorac Surg* 1985;39:391-9.
 72. Dedivitis RA, Guimaraes AV, Machado PC, Suehara AN, Noda E. Surgical treatment of the substernal goiter. *Int Surg* 1999;84:190-2.
 73. Lahey FH, Swinton NW. Intrathoracic goiter. *Surg Gynecol Obstet* 1934;59:627-37.
 74. Wakeley CG, Mulvany JH. Intrathoracic goiter. *Surg Gynecol Obstet* 1940;70:702-10.
 75. Pemberton J. Surgery of substernal and intrathoracic goiters. *Arch Surg* 1921;2:1-20.
 76. Reeve TS. Intrathoracic goiter: investigation and management. *Proceedings of the*

- First Asian Congress on Thoracic and Cardiovascular Surgery; 1972; Manila, The Philippines. p. 78-82.
77. Georgiadis N, Katsas A, Leoutsakos B. Substernal goiter. *Int Surg* 1970;54:116-21.
 78. Gourin A, Garzon AA, Karlson KE. The cervicomediastinal approach to intrathoracic goiter. *Surgery* 1971;69:651-4.
 79. DeAndrade MA. A review of 128 cases of posterior mediastinal goiter. *World J Surg* 1977;1:789-97.
 80. Sand ME, Laws BL, McElvein RB. Substernal and intrathoracic goiter. *Am Surg* 1983;49:196-201.
 81. Vadasz P, Kotsis L. Surgical aspect of 175 mediastinal goiter. *Eur J Cardiothorac Surg* 1998;14:393-7.
 82. Pemberton HS. Sign of submerged goiter [letter]. *Lancet* 1946;251:509.
 83. Lindem MD, Clark JH. Indications for surgery in thyroiditis. *Am J Surg* 1969;118:829-31.
 84. Ehrenhaft JL, Buckwalter JA. Mediastinal tumors of thyroid origin. *Arch Surg* 1955;71:347-56.
 85. Perez C, Scrimshaw NS, Munoz AJ. Technique of endemic goitre surveys. In: Clements FW, editor. *Endemic goitre*. Geneva: World Health Organization; 1960. p. 369-83.
 86. McHenry CR, Piotrowski JJ. Thyroidectomy in patients with marked thyroid enlargement: airway management, morbidity, and outcome. *Am Surg* 1994;0:588-91.
 87. Cernea CR, Nishi S, Hojaij FC. Identification of the external branch of the superior laryngeal nerve (ebsln) in large goiters. *Am J Otolaryngol* 1995;16:307-11.
 88. Dietlein M, Lauterbach KW, Schicha H. Treatment of toxic nodular goiters: comparative costing of radioiodine therapy and surgery. *Exp Clin Endocrinol Diabetes* 1998;106:S66-70.
 89. Glaser NS, Styne DM. Predictors of early remission of hyperthyroidism in children. *J Clin Endocrinol Metab* 1997;82:1719-26.
 90. Huysmans DAKC, De Haas MM, Van Den Broek WJM, et al. Magnetic resonance imaging for volume estimation of large multinodular goitres: a comparison with scintigraphy. *Br J Radiol* 1994;67:519-23.
 91. Huysmans DAKC, Hermus RMM, Barentsz JO, Corstens FHM, Kloppenbork PWC. Radioiodine for nontoxic multinodular goiter. *Thyroid* 1997;7:235-9.
 92. Hurley DL, Gharib H. Evaluation and management of multinodular goiter. *Otolaryngol Clin North Am* 1996;29:527-40.
 93. Peters H, Fischer C, Bogner U, Reiners C, Schleusener H. Reduction in thyroid volume after radioiodine therapy of graves' hyperthyroidism: results of a prospective, randomized, multicentre study. *Eur J Clin Invest* 1996;26:59-63.
 94. Alfonso A, Christoudias G, Amaruddin Q, Herbsman H, Gardner B. Tracheal or esophageal compression due to benign thyroid disease. *Am J Surg* 1981;142:350-4.
 95. Melliere D, Saada F, Etienne G, Becquemin JP, Bonnet F. Goiter with severe respiratory compromise: evaluation and treatment. *Surgery* 1988;103:367-73.
 96. Abdel Rahim AA, Ahmed ME, Hassan MA. Respiratory complications after thyroidectomy and the need for tracheostomy in patients with a large goitre. *Br J Surg* 1999;86:88-90.
 97. Martin-Hirsch DP, Lannigan FJ. The management of benign thyroid goitre causing tracheo-oesophageal embarrassment. *J Laryngol Otol* 1995;105:892-4.

98. Raftos JR, Ethell AT. Goitre causing acute respiratory arrest. *Aust NZ J Surg* 1996;66:331-2.
99. Kaya S, Tastepe I, Kaptanoglu M, Yukset M, Topeu S, Cetin G. Management of intrathoracic goiter. *Scand J Thorac Cardiovasc Surg* 1994;28:85-9.
100. Singh B, Lucent FE, Shaha AR. Substernal goiter: a clinical review. *Am J Otolaryngol* 1994;15:409-16.
101. Cegniz K, Aykin A, Demirci A, Diren B. Intrathoracic goiter with hyperthyroidism, tracheal compression, superior vena cava syndrome, and Horner's syndrome. *Chest* 1990;97:1005-6.
102. Jansen T, Romiti R, Messer G, Stucker M, Altmeyer P. Superior vena cava syndrome presenting as persistent erythematous oedema of the face. *Clin Exp Dermatol* 2000;25:198-200.
103. Siegart CEH, Smelt AHM, de Bruin TWA. Superior sagittal sinus thrombosis and thyrotoxicosis: possible association in two cases. *Stroke* 1995;26:496-7.
104. Gassideux P, Minette P, Trigaux JP, et al. Cerebrovascular circulation "steal" syndrome secondary to voluminous retrotracheal goiter. *Int Surg* 1986;71:107-9.
105. Hsu CY, Kao CH, Wang SJ. Multinodular goiter with a huge infected cyst. *Clin Nucl Med* 1994;19:455-6.
106. Lee CC, Chen CY, Chen FH, Lee GW, Hsiao HS, Zimmerman RA. Imaging of huge lingual thyroid gland with goitre. *Neuroradiology* 1998;40:335-7.
107. Bonnema SJ, Bertelsen H, Mortensen J, et al. The feasibility of high dose iodine¹³¹ treatment as an alternative to surgery in patients with a very large goiter: effect on thyroid function and size and pulmonary function. *J Clin Endocrinol Metab* 1999;84:3636-41.
108. Nygaard B, Hegedus L, Gervil M, Hjalgrim H, Soe-Jensen P, Hansen JM. Radioiodine treatment of multinodular non-toxic goitre. *Br Med J* 1993;307:828-32.
109. De Bruin TWA, Croon CDL, de Klerk JMH, van Isselt JW. Standardized radioiodine therapy in Graves' disease: the persistent effect of thyroid weight and radioiodine uptake on outcome. *J Intern Med* 1994;236:507-13.
110. Sabri O, Zimny M, Schreckenberger M, Reinartz P, Ostwald E, Buell U. Radioiodine therapy in graves disease: patients with large diffuse goiters treated with or without carbimazole at the time of radioiodine therapy. *Thyroid* 1999;9: 1181-8.
111. Marcocci C, Giancchetti D, Masinin I, et al. A reappraisal of the role of methimazole and other factors on the efficacy and outcome of radioiodine therapy of Graves' hyperthyroidism. *J Endocrinol Invest* 1990;236:507-13.
112. Patwardhan NA, Moront M, Rao S, Rossi S, Braverman LE. Surgery still has a role in Graves' hyperthyroidism. *Surgery* 1993;114:1108-13.
113. Younes N, Robinson B, Delbridge L. The aetiology, investigation and management of surgical disorders of the thyroid gland. *Aust NZ J Surg* 1996;66:481-90.
114. Tallstedt L, Lundell G, Topping O. Occurrence of ophthalmopathy after treatment for Graves' hyperthyroidism. *N Engl J Med* 1992;326:1733-8.
115. Shaha AR, Burnett C, Alfonso A, Jaffe BM. Goiters and airway problems. *Am J Surg* 1989;158:378-81.
116. Geelhoed GW. Tracheomalacia from compressing goiter: management after thyroidectomy. *Surgery* 1988;104:1100-8.

117. Jensovsky J, Markova H, Bohutova J. Unusual complication of total thyroidectomy: arteriovenous fistula. *Thyroid* 2000;10:359-61.
118. Breaux EP, Guillaumondegui OM. Treatment of locally invasive carcinoma of the thyroid: how radical. *Am J Surg* 1980;140:514-7.
119. Gillenwater AM, Goeppert H. Surgical management of laryngotracheal and esophageal involvement by locally advanced thyroid cancer. *Semin Surg Oncol* 1999;16:19-29.
120. Batsakis JG. Laryngeal involvement by thyroid disease. *Ann Otol Rhinol Laryngol* 1987;96:718-9.
121. Djalilian M, Beahrs OH, Decine KD, Weiland LH, DeSanto LW. Intraluminal involvement of the larynx and trachea by thyroid cancer. *Am J Surg* 1974;128:500-4.
122. Friedman M. Surgical management of thyroid carcinoma with laryngotracheal invasion. *Otolaryngol Clin North Am* 1990;23:495-507.
123. McCaffrey TV, Bergstrahl EJ, Hay ID. Locally invasive papillary thyroid carcinoma: 1940-1990. *Head Neck* 1994;15:165-72.
124. McCaffrey TV, Lipton RJ. Thyroid carcinoma invading the upper digestive system. *Laryngoscope* 1990;100:824-30.
125. Musholt TJ, Musholt PB, Behrend M, Raab R, Scheumann GF, Klempnauer J. Invasive differentiated thyroid carcinoma: tracheal resection and reconstruction procedures in the hands of the endocrine surgeon. *Surgery* 1999;126:1078-87.
126. Tovi F, Golstein J. Locally aggressive differentiated thyroid carcinoma. *J Surg Oncol* 1985;29:99-104.
127. Silliphant WM, Klinck GH, Levitin MS. Thyroid carcinoma and death: a clinicopathological study of 193 autopsies. *Cancer* 1964;17:513-8.
128. Nakao K, Miyata M, Izukura M, Monden Y, Maeda M, Kawashima Y. Radical operation for thyroid carcinoma invading the trachea. *Arch Surg* 1984;119:1046-9.
129. Tsumori T, Nakao K, Miyata M, et al. Clinicopathologic study of thyroid carcinoma infiltrating the trachea. *Cancer* 1985;56:2843-8.
130. Ballantyne AJ. Resections of the upper aerodigestive tract for locally invasive thyroid cancer. *Am J Surg* 1994;168:636-9.
131. Cady B. Management of tracheal obstruction from thyroid diseases. *World J Surg* 1982;6:696-701.
132. Calcaterra TC, Maceri DR. Aerodigestive dysfunction secondary to thyroid tumors. *Laryngoscope* 1981;91:701-7.
133. Grillo HC, Suen HC, Mathisen DJ, Wain JC. Resection management of thyroid carcinoma invading the airway. *Ann Thorac Surg* 1992;54:3-10.
134. Grillo HC, Zannini P. Resection management of airway invasion by thyroid carcinoma. *Ann Thorac Surg* 1986;42:287-98.
135. Ishihara T, Yamazaki S, Kobayashi K, et al. Resection of the trachea infiltrated by thyroid carcinoma. *Ann Surg* 1992;195:496-500.
136. Kim KH, Sung MW, Chang KH, Kang BS. Therapeutic dilemmas in the management of thyroid cancer with laryngotracheal involvement. *Otolaryngol Head Neck Surg* 2000;122:763-7.
137. Lipton RJ, McCaffrey TV, van Heerden JA. Surgical treatment of invasion of the upper aerodigestive tract by well-differentiated thyroid carcinoma. *Am J Surg* 1987;154:363-6.

138. Segal K, Abraham A, Levy R. Carcinomas of the thyroid gland invading larynx and trachea. *Clin Otolaryngol* 1984;9:21-5.
139. Machens A, Hinze R, Lautenschlager C, Thomusch O, Dralle H. Thyroid carcinoma invading the cervicovisceral axis: routes of invasion and clinical implications. *Surgery* 2001;129:23-8.
140. Lawson W, Som MP, Biller HF. Papillary adenocarcinoma of the thyroid invading the upper air passages. *Ann Otol Rhinol Laryngol* 1977;86:751-5.
141. Friedman M, Shelton VK, Skolnik EM. Laryngotracheal invasion by thyroid carcinoma. *Ann Otol Rhinol Laryngol* 1982;91:363-9.
142. Cody HS, Shah JP. Locally invasive, well-differentiated thyroid carcinoma: 22 years' experience at Memorial Sloan-Kettering Cancer Center. *Am J Surg* 1981;142:480-3.
143. Czaja JM, McCaffrey TV. The surgical management of laryngotracheal invasion by well-differentiated papillary thyroid carcinoma. *Arch Otolaryngol Head Neck Surg* 1997;123:484-90.
144. Shin DH, Mark EJ, Suen HC, Grillo HC. Pathologic staging of papillary carcinoma of the thyroid with airway invasion based on the anatomic manner of extension to the trachea: a clinicopathologic study based on 22 patients who underwent thyroidectomy and airway resection. *Hum Pathol* 1993;24:866-70.
145. Nishida T, Nakao K, Hamaji M. Differentiated thyroid carcinoma with airway invasion: indication for tracheal resection based on the extent of cancer invasion. *J Thorac Cardiovasc Surg* 1997;114:84-92.
146. Friedman M, Danielzadeh JA, Caldarelli DD. Treatment of patients with carcinoma of the thyroid invading the airway. *Arch Otolaryngol Head Neck Surg* 1994;120:1377-81.
147. McConahey WM, Hay ID, Woolner LB, van Heerden JA, Taylor WF. Papillary thyroid cancer treated at the Mayo Clinic, 1946 through 1970: initial manifestations, pathologic findings, therapy, and outcome. *Mayo Clin Proc* 1986;61:978-96.
148. Tollefson H, DeCosse J, Hutter R. Papillary carcinoma of the thyroid: a clinical and pathological study of 70 fatal cases. *Cancer* 1964;17:1035-44.
149. Donnelly MJ, Timon CI, McShane DP. The role of total laryngectomy in the management of intraluminal upper airway invasion by well-differentiated thyroid carcinoma. *Ear Nose Throat J* 1994;73:659-62.
150. Park CS, Suh KW, Min JS. Cartilage-saving procedure for the control of tracheal cartilage invasion by thyroid carcinoma. *Head Neck* 1993;15:289-91.
151. Talpos GB. Tracheal and laryngeal resections for differentiated thyroid cancer. *Am Surg* 1999;65:754-60.
152. Donnelly MJ, Considine N, McShane DP. Upper airway invasion by well-differentiated thyroid carcinoma. *J Laryngol Otol* 1993;107:752-4.
153. Fujimoto Y, Obara T, Ito Y. Aggressive surgical approach for locally invasive papillary carcinoma of the thyroid in patients over forty-five years of age. *Surgery* 1986;100:1098-106.
154. Grossman TW, Wilson JF, Toohill RJ. Delayed aerodigestive tract complications following combined therapy for thyroid cancer. *Ann Otol Rhinol Laryngol* 1985;94:505-8.
155. Lalak NJ, Campbell PR. Infiltrating papillary carcinoma of the thyroid with macroscopic extension into the internal jugular vein. *Otolaryngol Head Neck Surg* 1997;117:S238-30.

156. Mellièrè DJM, Yahia NEB, Becquemin JJP, Lange F, Boulahdour H. Thyroid carcinoma with tracheal or esophageal involvement: Limited or maximal surgery? *Surgery* 1993;113:166-72.
157. Niederle B, Hausmaninger C, Kretschmer G, et al. Intraatrial extension of thyroid cancer: technique and results of a radical surgical approach. *Surgery* 1990;108:951-7.
158. Takashima S, Takayama F, Wang Q, et al. Differentiated thyroid carcinomas: prediction of tumor invasion with MR imaging. *Acta Radiol* 2000;41:377-83.
159. Sugenoïa A, Matsuo K, Asanuma K, et al. *Head Neck* 1995;17:339-42.
160. Pearson FG, Cooper JD, Nelems JM. Primary tracheal anastomosis after resection of cricoid cartilage with preservation of the recurrent laryngeal nerves. *J Thorac Cardiovasc Surg* 1975;70:806-16.
161. Ozaki O, Sugino K, Mimura T, Ito K. Surgery for patients with thyroid carcinoma invading the trachea: circumferential sleeve resection followed by end-to-end anastomosis. *Surgery* 1995;117:268-71.
162. Falk SA, McCaffrey TV. Management of the recurrent laryngeal nerve in suspected and proven thyroid cancer. *Otolaryngol Head Neck Surg* 1995;113:42-8.
163. Hogg RP, Kuo MJ, Olliff J, Das Gupta AR. Invasion of the recurrent laryngeal nerve by adenoid cystic carcinoma: an unusual cause of true vocal fold paralysis. *J Laryngol Otol* 1999;113:260-2.
164. Nishida T, Nakao K, Hamaji M, Kamiike W, Kurozumi K, Matsuda H. Preservation of recurrent laryngeal nerve invaded by differentiated thyroid cancer. *Ann Surg* 1997;226:85-91.
165. Onaran Y, Terzioglu T, Oguz H, Kapran Y, Tezelman S. Great cervical vein invasion of thyroid carcinoma. *Thyroid* 1998;8:59-61.
166. Cooney BS, Levine MS, Schnall MD. Metastatic thyroid carcinoma presenting as an expansile intraluminal esophageal mass. *Abdom Imaging* 1995;20:20-2.
167. Gardner RE, Tuttle RM, Burman KD, et al. Prognostic importance of vascular invasion in papillary thyroid carcinoma. *Arch Otolaryngol Head Neck Surg* 2000;126:309-12.
168. Perez D, Brown L. Follicular carcinoma of the thyroid appearing as an intraluminal superior vena cava tumor. *Arch Surg* 1984;119:323-6.
169. Thomas S, Sawhney S, Kapur BML. Case report: bilateral massive internal jugular vein thrombosis in carcinoma of the thyroid: CT evaluation. *Clin Radiol* 1991;43:433-4.
170. Thompson NW, Brown J, Orringer M, Sisson J, Nishiyama R. Follicular carcinoma of the thyroid with massive angioinvasion: extension of tumor thrombus to the heart. *Surgery* 1978;83:451-7.
171. Takaeichi N, Ezaki H, Nishiki M, et al. Bilateral resection and reconstruction of internal jugular vein for thyroid carcinoma. *Jpn J Surg* 1984;14:465-71.
172. Gius JA, Grier DH. Venous adaptation following bilateral radical neck dissection with excision of the jugular vein. *Surgery* 1950;28:305-21.
173. Ishihara T, Kobayashi K, Kikuchi K, Kato R, Kawamura M, Ito K. Surgical treatment of advanced thyroid carcinoma invading the trachea. *J Thorac Cardiovasc Surg* 1991;102:717-20.
174. Yousem DM, Hatabu H, Hurst R, et al. Carotid artery invasion by head and neck masses: prediction with MR imaging. *Radiology* 1995;195:715-20.
175. Yamashita H, Noguchi S, Murakami N, Kawamoto H, Watanabe S. Extracapsular

- invasion of lymph node metastasis is an indicator of distant metastasis and poor prognosis in patients with thyroid papillary carcinoma. *Cancer* 1997;80:2268-72.
176. Chao TC, Jeng LB, Lin JD, Chen MF. Reoperative thyroid surgery. *World J Surg* 1997;21:644-7.
 177. Wilson DB, Staren ED, Prinz RA. Thyroid reoperations: indications and risks. *Am Surg* 1998;64:674-8.
 178. Seiler CA, Glaser C, Wagner HE. Thyroid gland surgery in an endemic region. *World J Surg* 1996;20:593-7.
 179. Eroglu A, Berberoglu U, Buruk F, Yildirim E. Completion thyroidectomy for differentiated thyroid carcinoma. *J Surg Oncol* 1995;59:261-7.
 180. Reeve TS, Delbridge L, Brady P, Crummer P, Smyth C. Secondary thyroidectomy: a twenty-year experience. *World J Surg* 1988;12:449-53.
 181. Moley JF, Lairmore TC, Doherty GM, Brunt M, DeBenedetti MK. Preservation of the recurrent laryngeal nerves in thyroid and parathyroid reoperations. *Surgery* 1999;126:673-7.