

**The State Medical and Pharmaceutical University “Nicolae Testemitanu”
Republic of Moldova**

**Department of
Human Anatomy**

**The functional Anatomy
of the Cranial nerves**

Lecturer Globa Lilian

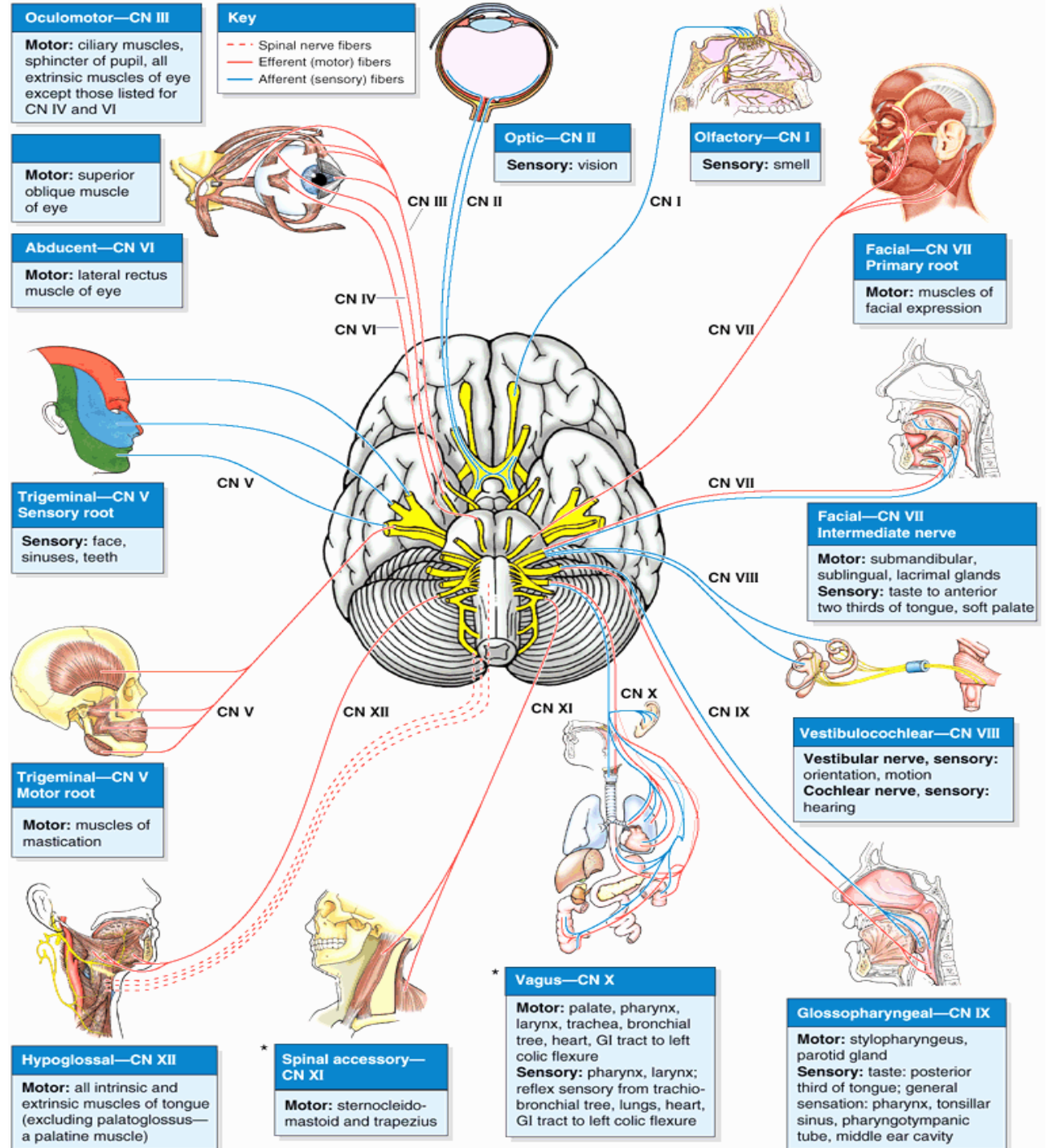
Cranial nerves

Like spinal nerves, **cranial nerves** are bundles of sensory or motor fibers that innervate muscles or glands; carry impulses from sensory receptors, or show a combination of these fiber types.

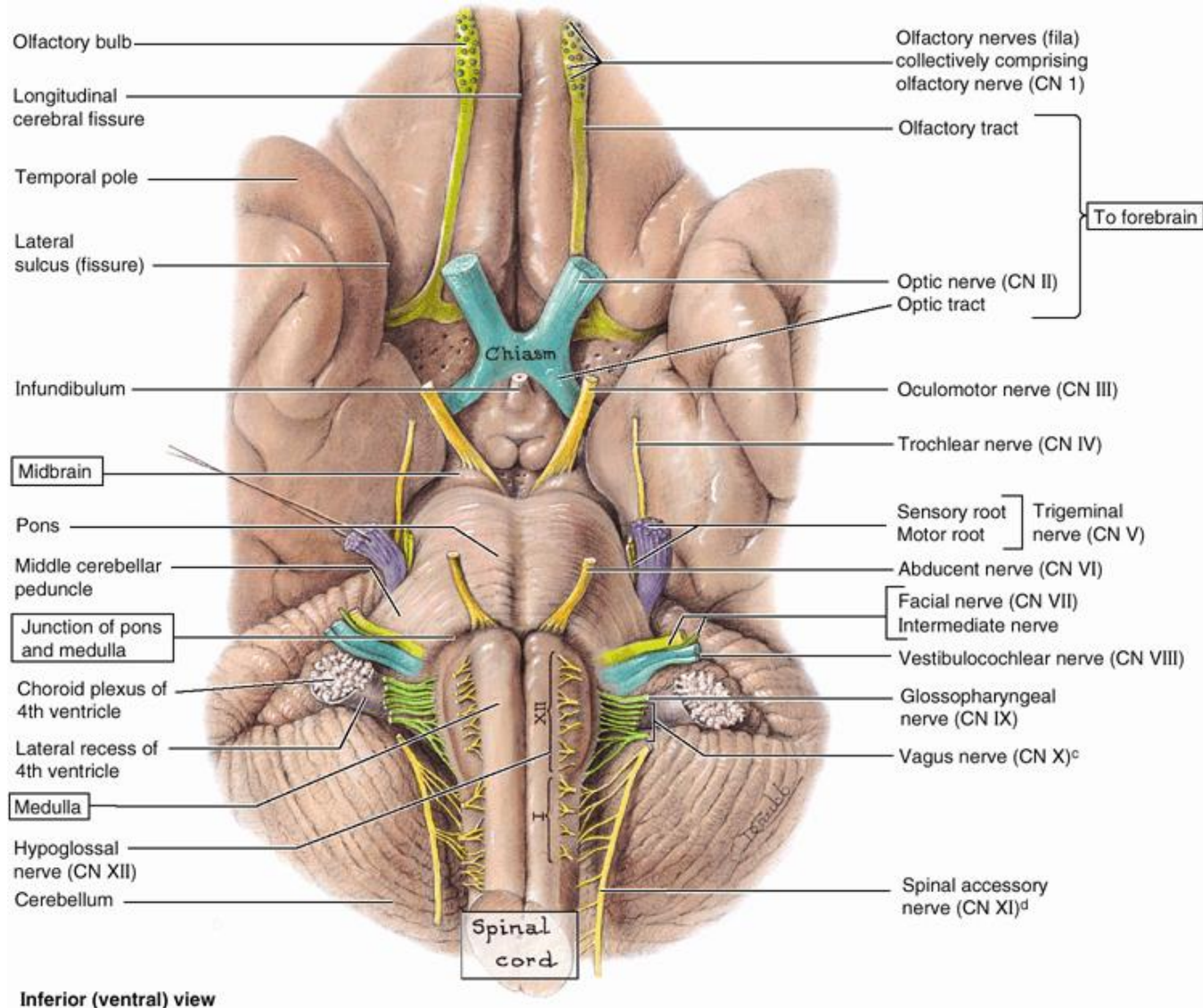
They are called **cranial nerves** because they emerge through foramina or fissures in the cranium and are covered by tubular sheaths derived from the cranial meninges.

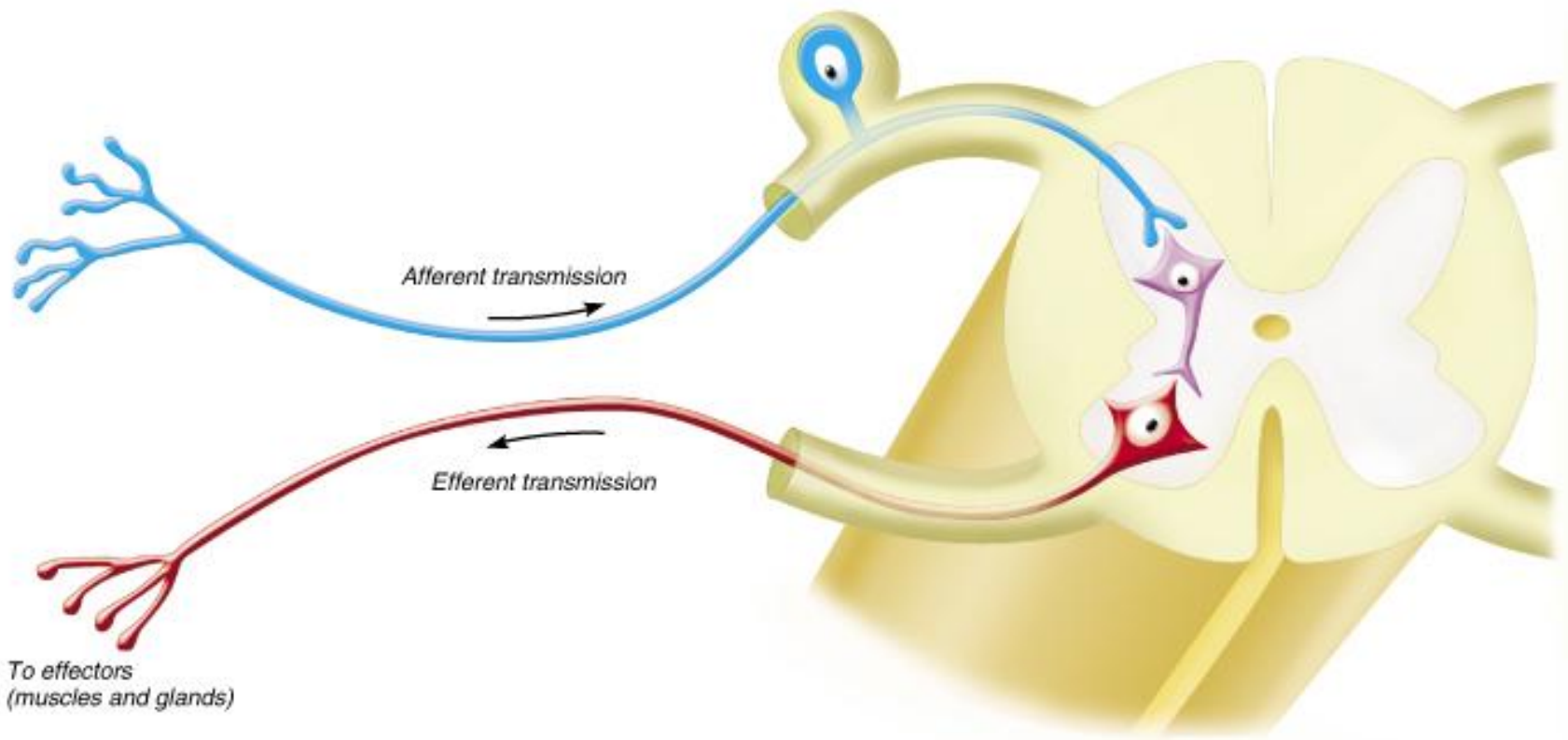
There are **twelve** pairs of cranial nerves, which are numbered I to XII, from rostral to caudal, according to their attachment to the brain and penetration of the cranial dura. Their names reflect their general distribution or function.

Cranial nerves



Cranial nerves

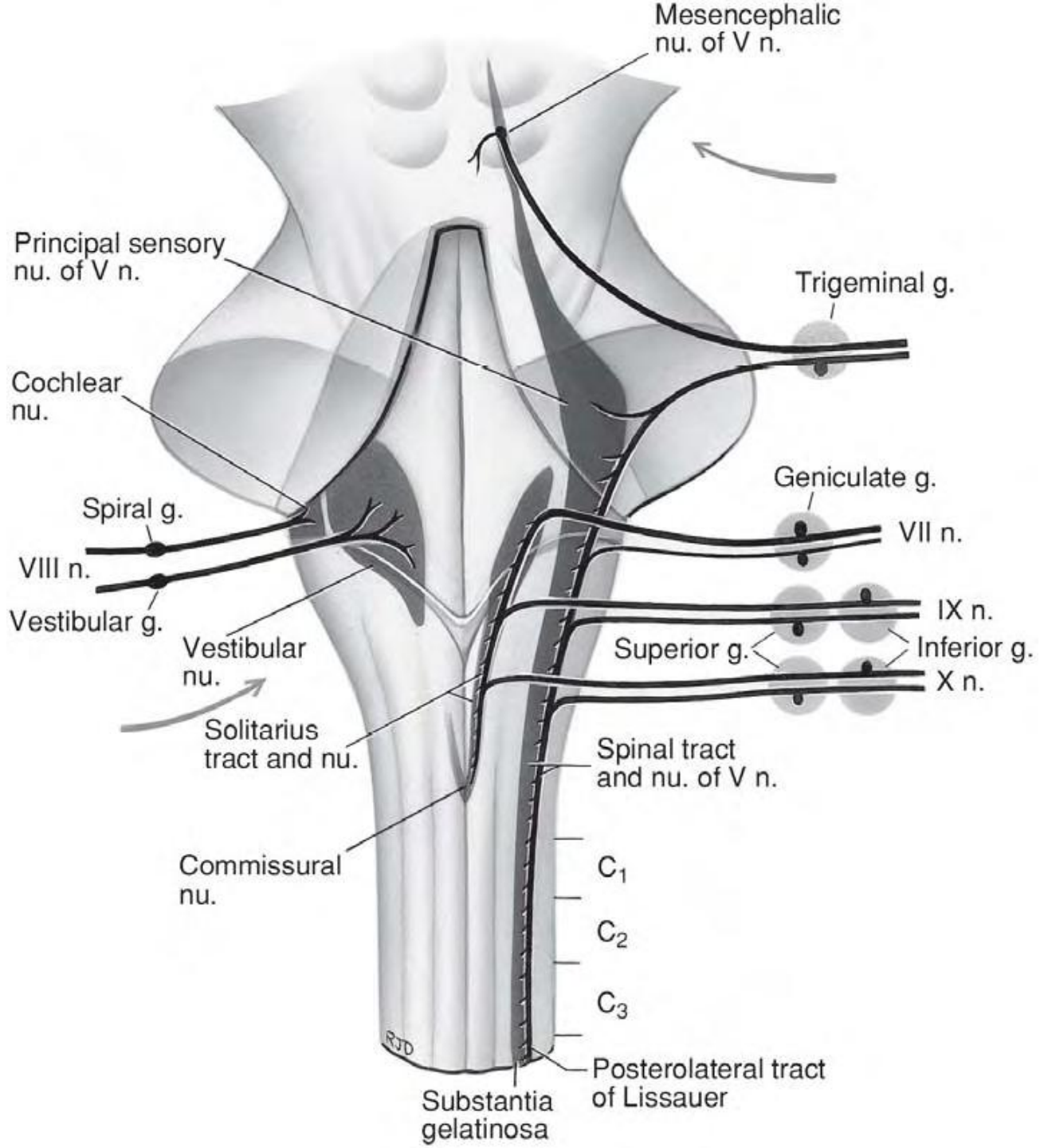


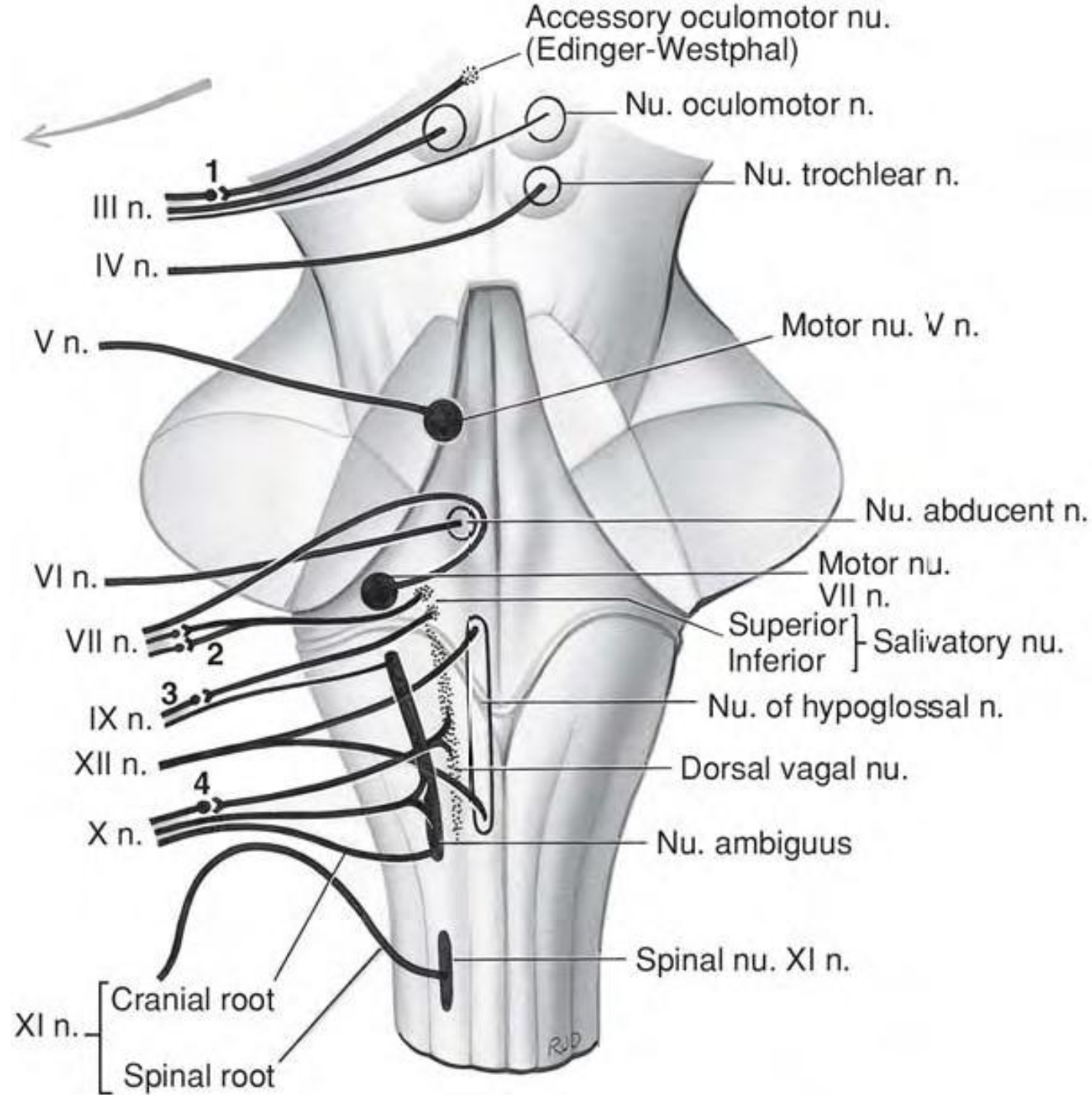


Afferent transmission

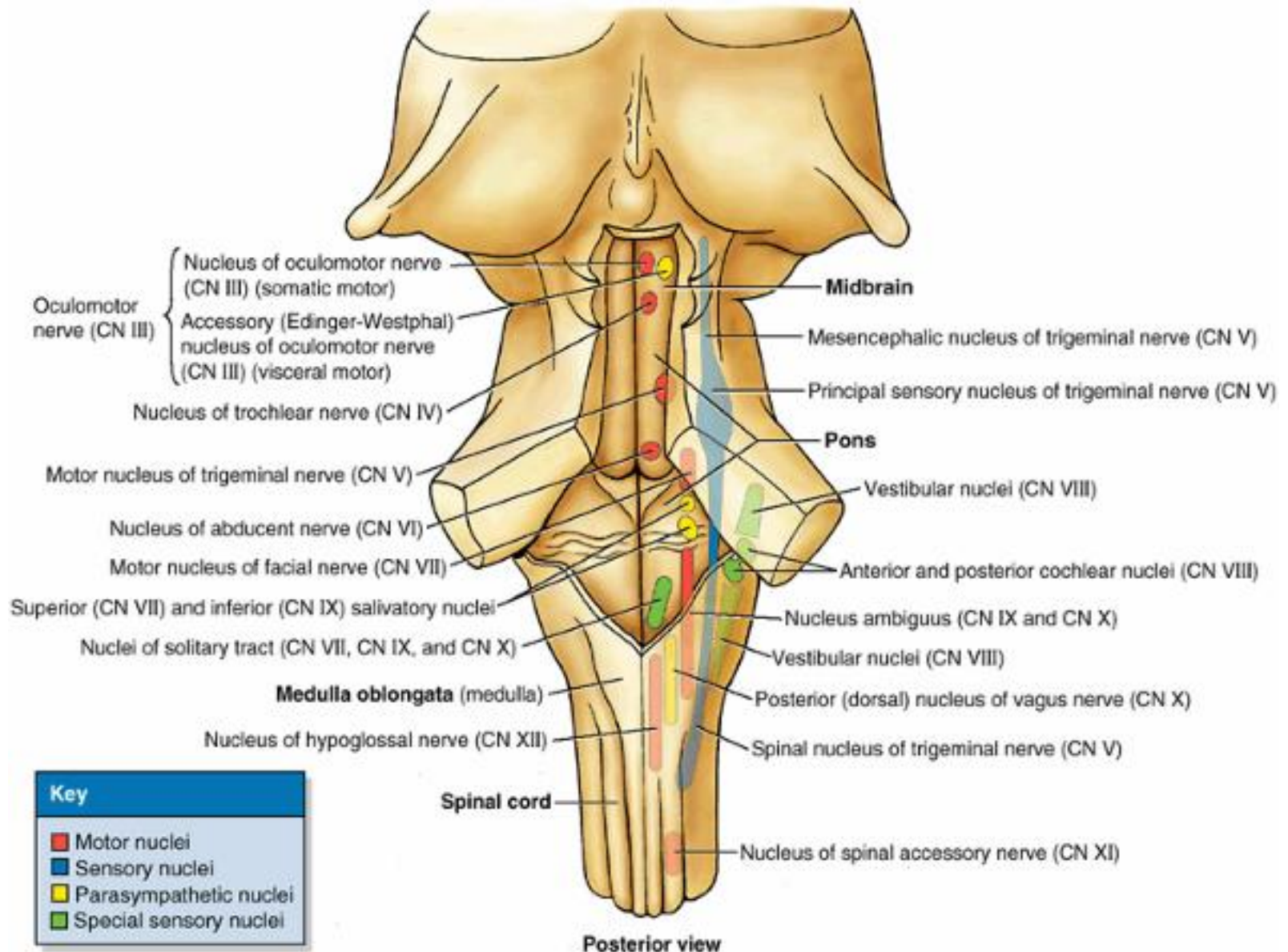
Efferent transmission

*To effectors
(muscles and glands)*





Cranial nerves



Fibers of Cranial nerves

The cranial nerves have the same **general functional** components as occur in spinal nerves:

- General somatic afferent (GSA),
- General visceral afferent (GVA),

- General somatic efferent (GSE), and
- General visceral efferent (GVE).

In addition, many cranial nerves have **special components**:

- Special somatic afferent (SSA),
- Special visceral afferent (SVA), and

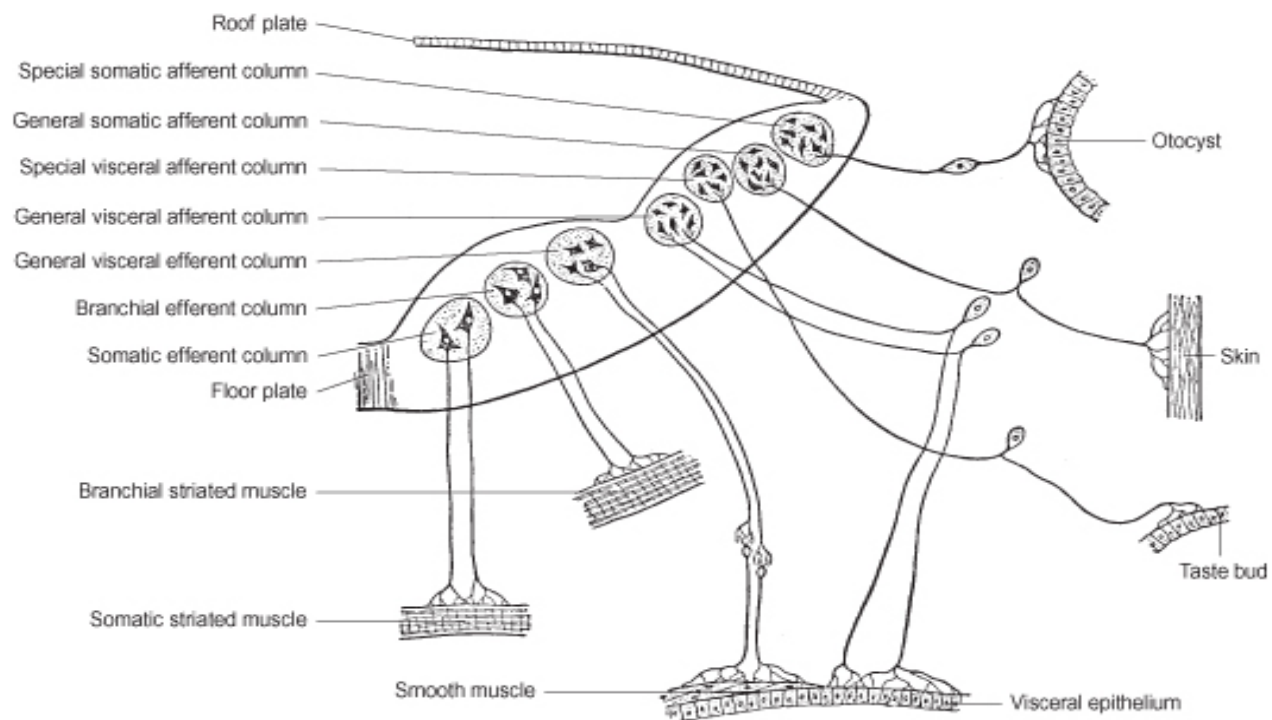
- Special visceral (branchial) efferent (SVE).

The terms :

- **Somatic** refers to head, body wall, and extremities;
- **Visceral** refers to viscera;

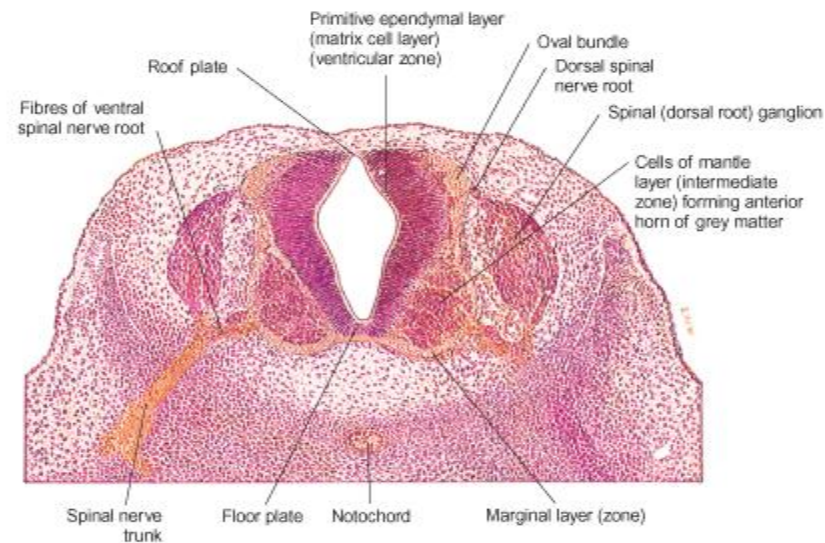
- **Afferent** refers to sensory (input);
- **Efferent** refers to motor (output);

- **General** refers to wide areas of the head and body;
- **Special** refers to the specialized functions of olfaction (smell), gustation (taste), vision, audition, equilibrium (vestibular system), and
- **Branchiomic** (gill arch) muscles.



© Elsevier Ltd 2005. Standing: Gray's Anatomy 39e - www.graysanatomyonline.com

Figure 14.20 Transverse section through the developing hindbrain of a human embryo 10.5 mm long, to show the relative positions of the columns of grey matter from which the nuclei associated with the different varieties of nerve components are derived. Postganglionic neurones are associated with the general visceral efferent column, bipolar neurones are associated with the otocyst and unipolar afferent neurones are associated with the other alar lamina columns.



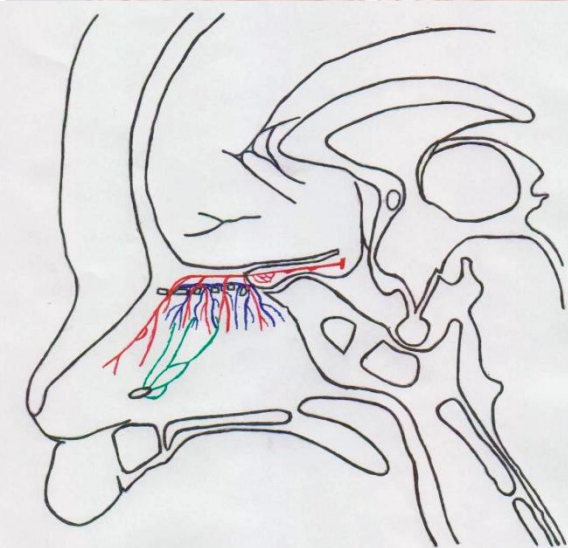
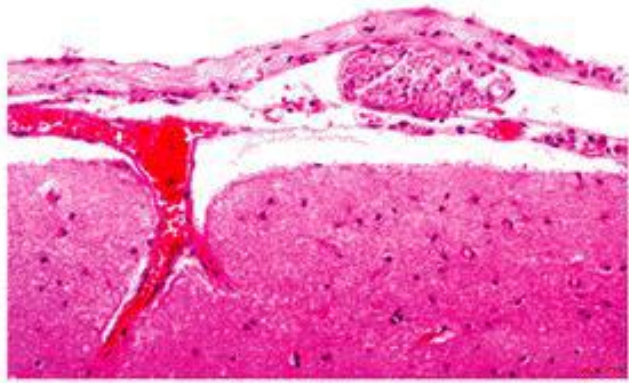
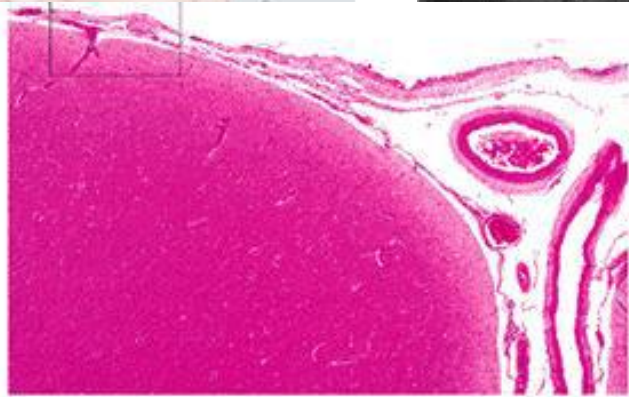
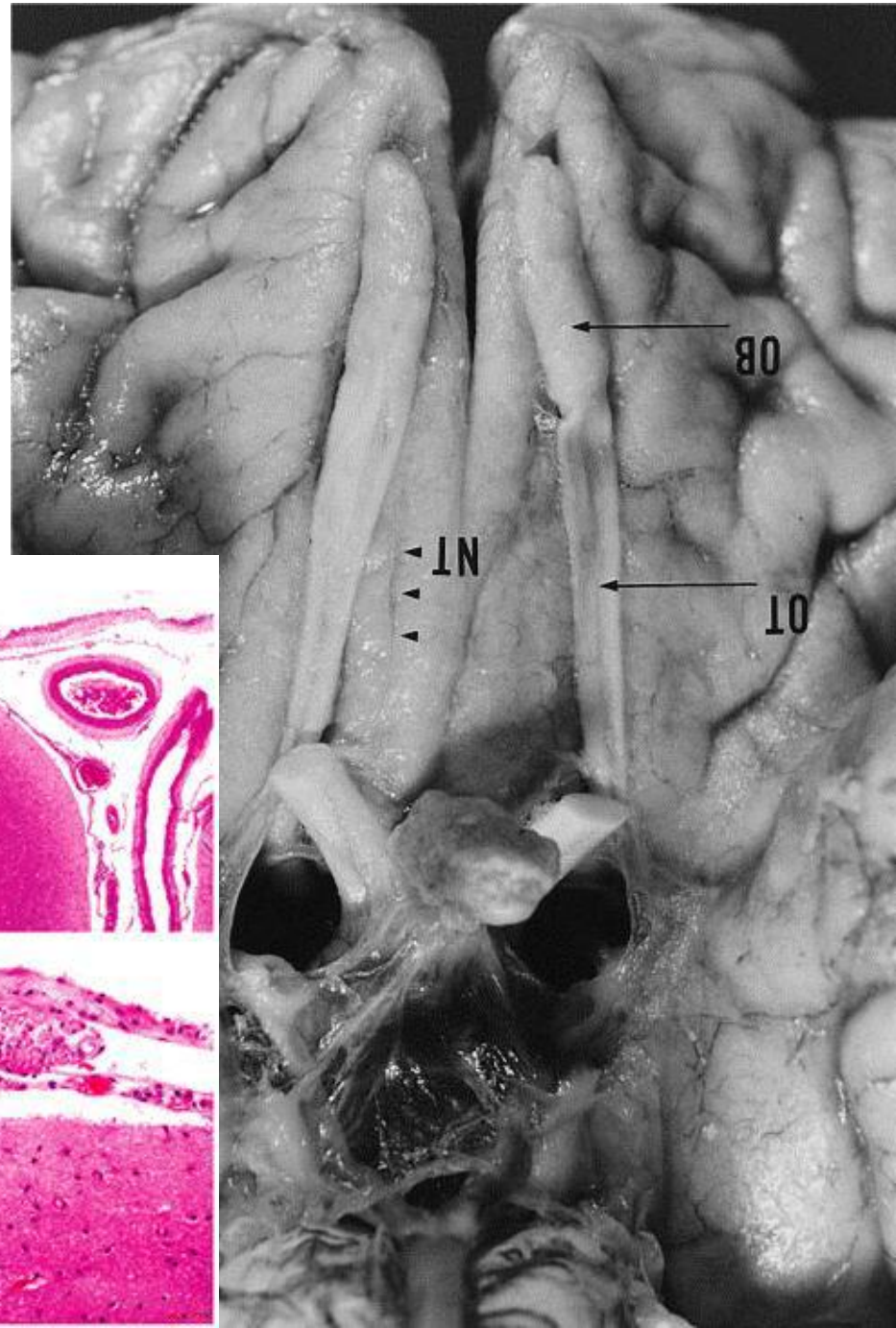
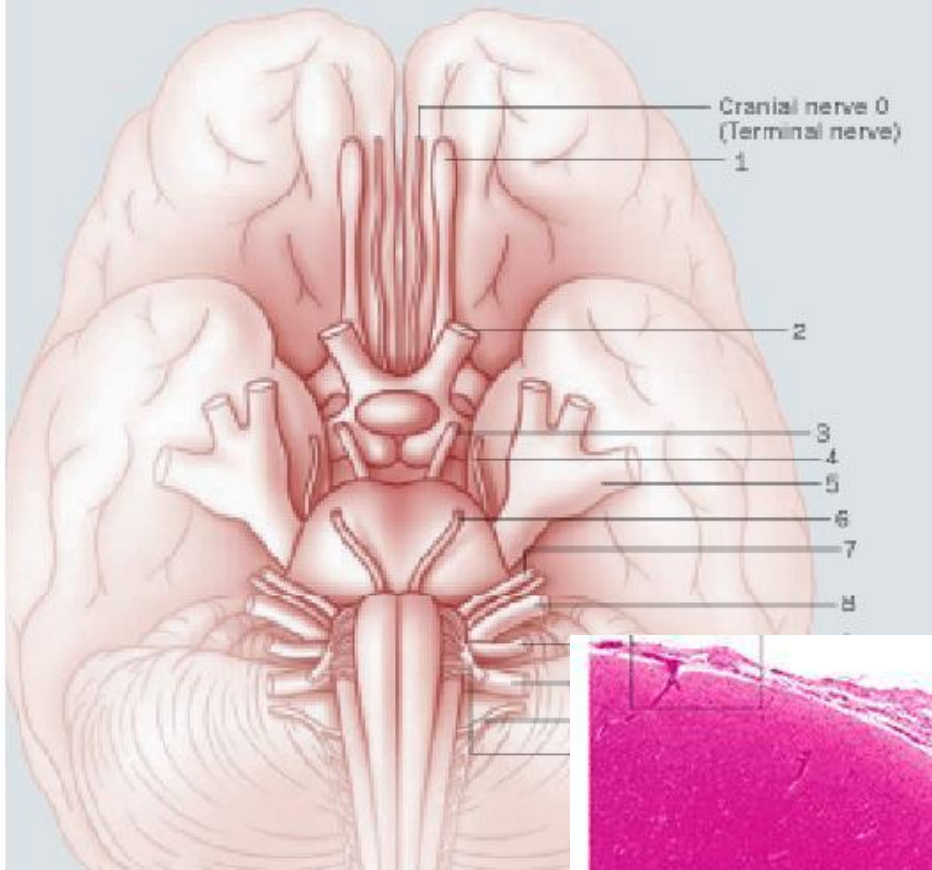
<i>Name</i>	<i>Components</i>	<i>Functions (major)</i>
I. Olfactory nerve	Special visceral afferent	Smell
II. Optic nerve	Special somatic afferent	Vision
III. Oculomotor nerve ^a	General somatic efferent	Movement of eyes
	General visceral efferent (parasympathetic)	Pupillary constriction and accommodation
IV. Trochlear nerve ^a	General somatic efferent	Movements of eyes
V. Trigeminal nerve	Special visceral efferent	Muscles of mastication and eardrum tension
	General somatic afferent	General sensations from anterior half of head including face, nose, mouth, and meninges
VI. Abducent nerve ^a	General somatic efferent	Movements of eyes
VII. Facial nerve ^b	Special visceral efferent	Muscles of facial expression and tension on ear bones
	General visceral efferent (parasympathetic)	Lacrimation and salivation
VIII. Vestibulocochlear nerve	Special visceral afferent	Taste
	General visceral afferent	Visceral sensory
IX. Glossopharyngeal nerve ^b	Special somatic afferent	Hearing and equilibrium
	Special viscera] efferent	Swallowing movements
X. Vagus nerve ^b and cranial root of XI	General visceral efferent (parasympathetic)	Salivation
	Special visceral afferent	Taste
	General visceral afferent	Visceral sensory
	Special visceral efferent	Swallowing movements and laryngeal control
XI. Spinal accessory nerve (spinal root)	General visceral efferent (parasympathetic)	Parasympathetics to thoracic and abdominal viscera
	Special visceral afferent	Taste
XII. Hypoglossal nerve ^a	General visceral afferent	Visceral sensory
	Special visceral efferent	Movements of shoulder and head

^a In addition, there are GSA fibers for proprioception from the muscles of the eye (III, IV, VI) and tongue (XII).

^b In addition, there are GSA fibers for cutaneous sense from just behind the external ear (VII, IX, and X).

The nervus terminalis

- **The nervus terminalis** (NT; terminal nerve) was clearly identified as an additional cranial nerve in humans more than a century ago, remains mostly undescribed in modern anatomy textbooks.
- The nerve is referred to as the nervus terminalis because in species initially examined its fibers were seen entering the brain in the region of the **lamina terminalis**.
- It has also been referred to as cranial nerve 0.
- This nerve is very distinct in human fetuses and infants but also has been repeatedly identified in adult human brains.
- The NT fibers are unmyelinated and emanate from ganglia. The fibers pass through the cribriform plate medial to those of the olfactory nerve fila.
- The fibers end in the nasal mucosa and probably arise from autonomic/neuromodulatory as well as sensory neurons.
- The NT has been demonstrated to release luteinizing-releasing luteinizing hormone and is therefore thought to play a role in reproductive behavior.



Cranial nerves

Olfactory Nerve (CN I)

Function: Special sensory (**special** visceral afferent) that is, the special sense of smell.

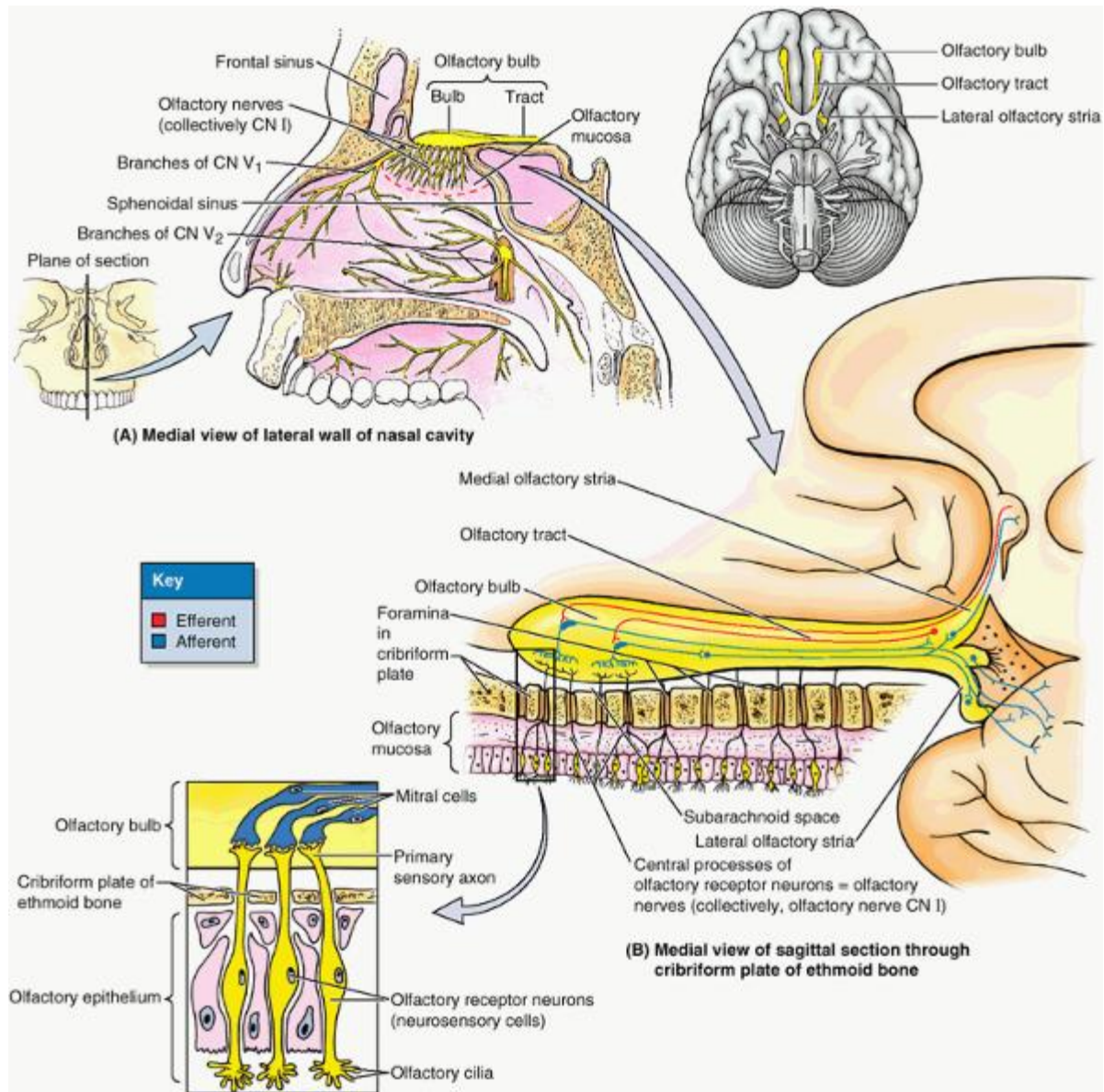
Olfaction is the sensation of odors that results from the detection of odorous substances aerosolized in the environment .

The cell bodies of olfactory **receptor neurons** are located in the olfactory organ (the olfactory part of the nasal mucosa or olfactory area), which is located in the roof of the nasal cavity and along the nasal septum and medial wall of the superior nasal concha.

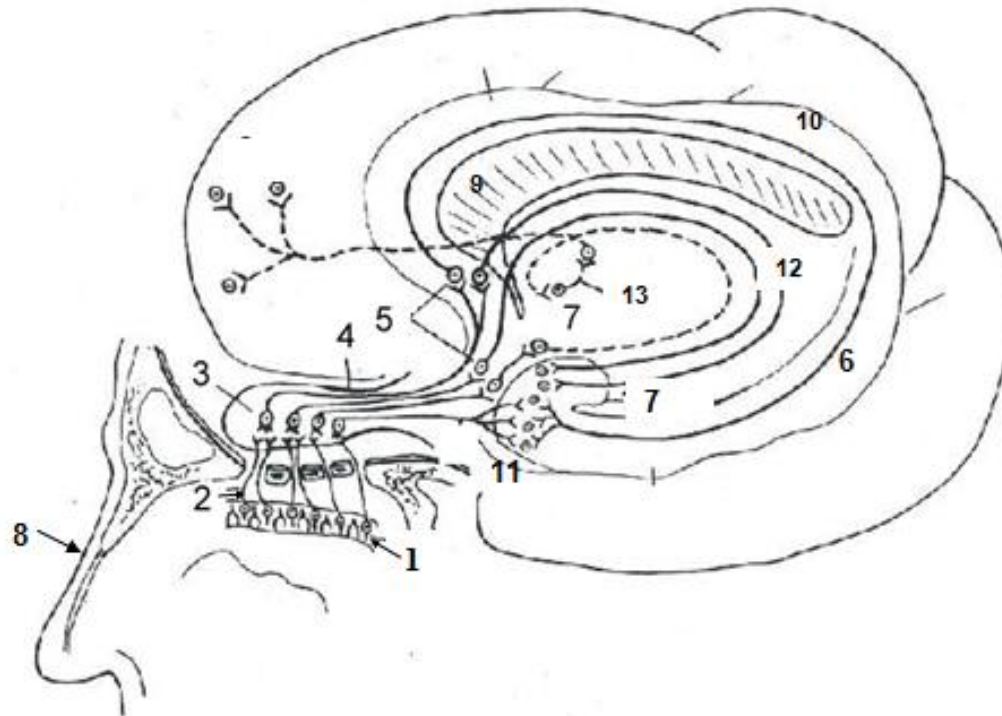
Olfactory receptor neurons are both receptors and conductors. The **apical surfaces** of the neurons possess fine olfactory cilia, bathed by a film of watery mucus secreted by the olfactory glands of the epithelium.

The cilia are stimulated by molecules of an odiferous gas dissolved in the fluid.

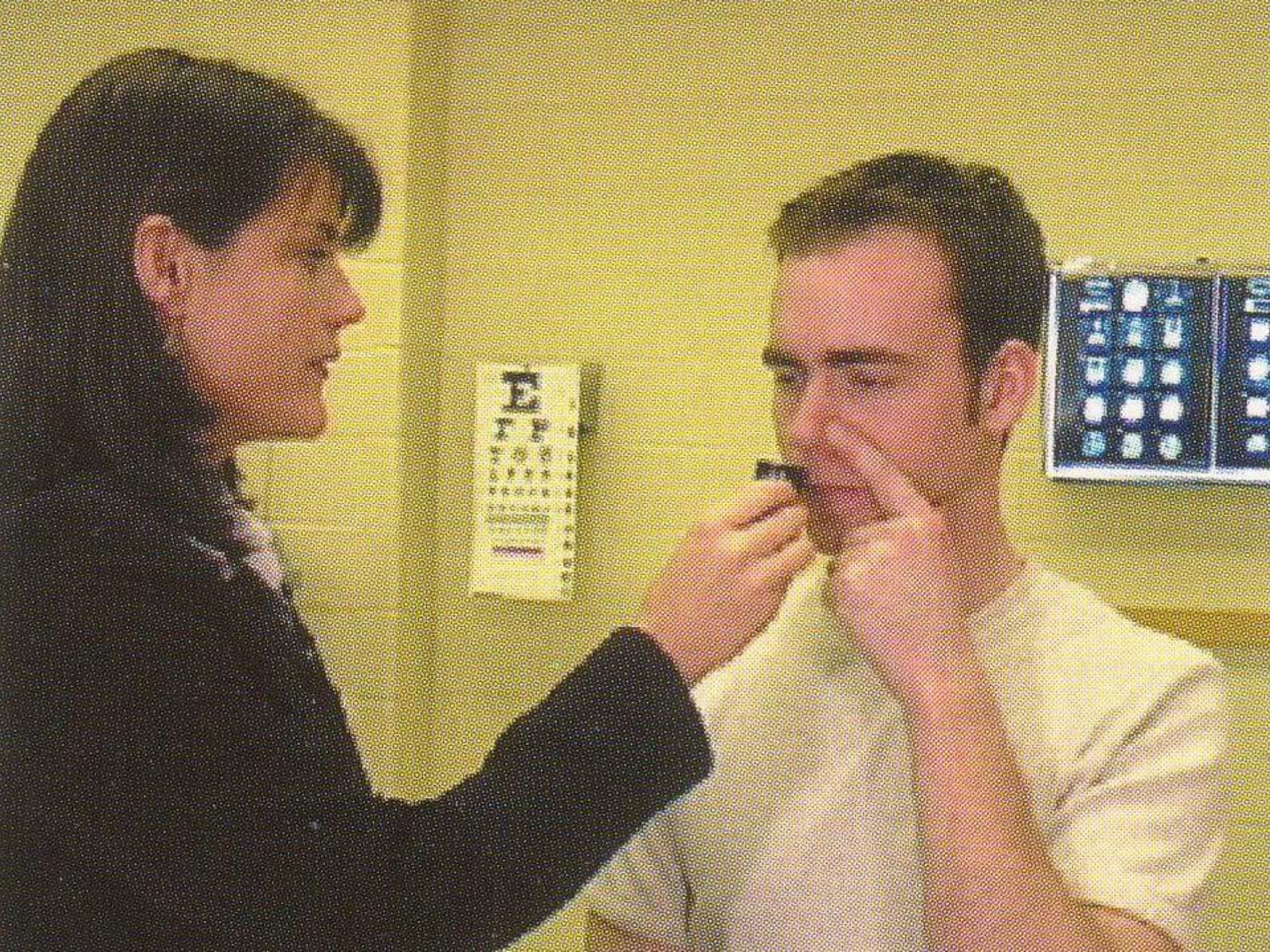Cranial nerves



Conducting pathways of the olfactory analyzer



- 1 – neuronum I (cellulae bipolares neurosensoriales);
- 2 – filae olfactoriae;
- 3 – neuronum II (cellulae mitrales bulbi olfactorii);
- 4 – tractus olfactorius;
- 5 – neuronum III (trigonum olfactorium, substantia perforata anterior, septum pellucidum);
- 6 – gyrus parahippocampalis;
- 7 – uncus, corpus amygdaloideum et area subcallosa;
- 8 – nasus externus;
- 9 – corpus callosum;
- 10 – gyrus cinguli;
- 11 – gyrus dentatus;
- 12 – fornix;
- 13 – thalamus.



Cranial nerves

Optic Nerve (CN II)

Function: Special sensory (special somatic afferent) that is, the special sense of **vision**.

The optic nerves (CN II) develop in a completely **different** manner from the other cranial nerves.

The structures involved in receiving and transmitting optical stimuli (the optical fibers and neural retina, together with the pigmented epithelium of the eyeball) develop as evaginations of the **diencephalon**.

The optic nerves are paired, anterior extensions of the forebrain (diencephalon) and are, therefore, actually CNS fiber tracts formed by axons of retinal ganglion cells.

In other words, they are third-order neurons, with their cell bodies located in the retina.

The nerve passes posteromedially in the orbit, exiting through the optic canal to enter the middle cranial fossa, where it forms the optic chiasm. Here, fibers from the nasal (**medial**) half of each retina decussate in the chiasm and join uncrossed fibers from the temporal (**lateral**) half of the retina to form the optic tract.

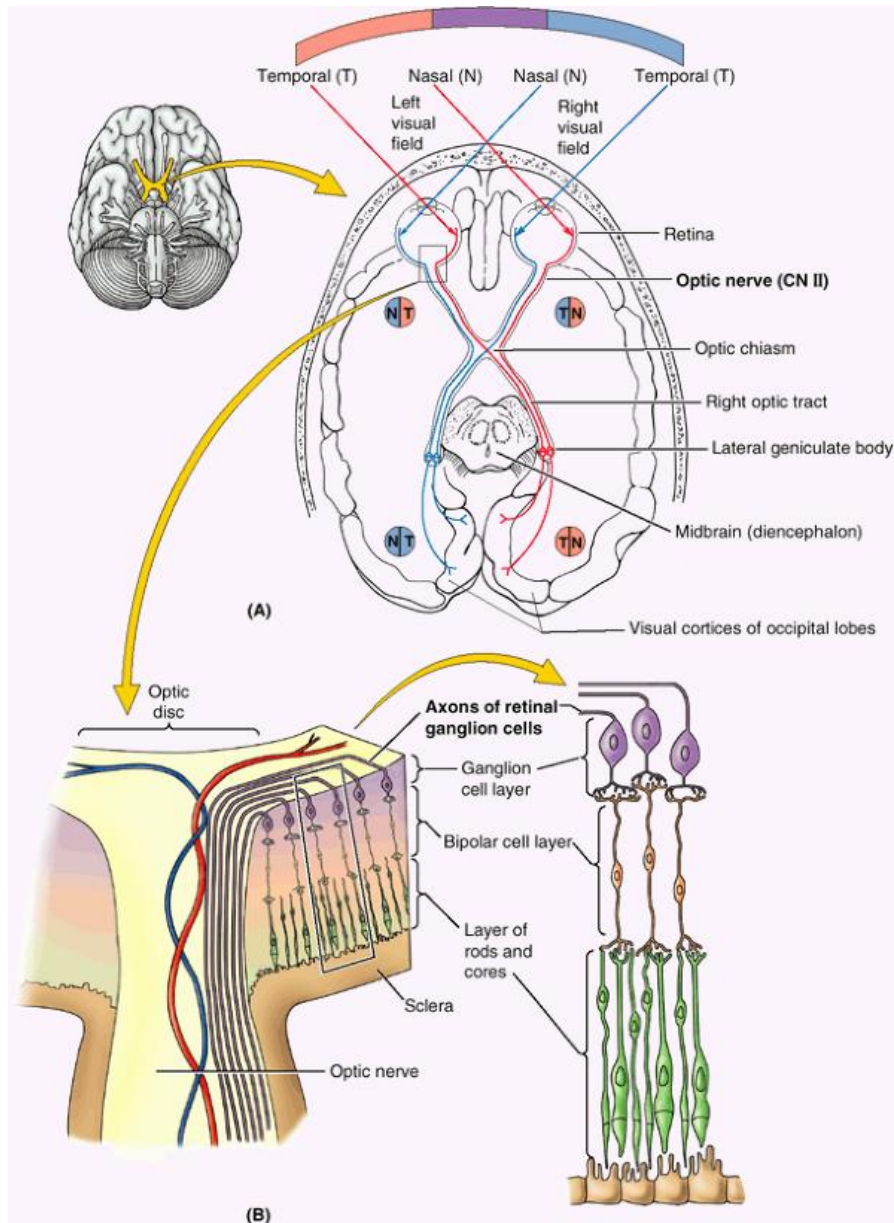
The partial crossing of optic nerve fibers in the chiasm is a requirement for binocular vision, allowing depth-of-field perception (three-dimensional vision).

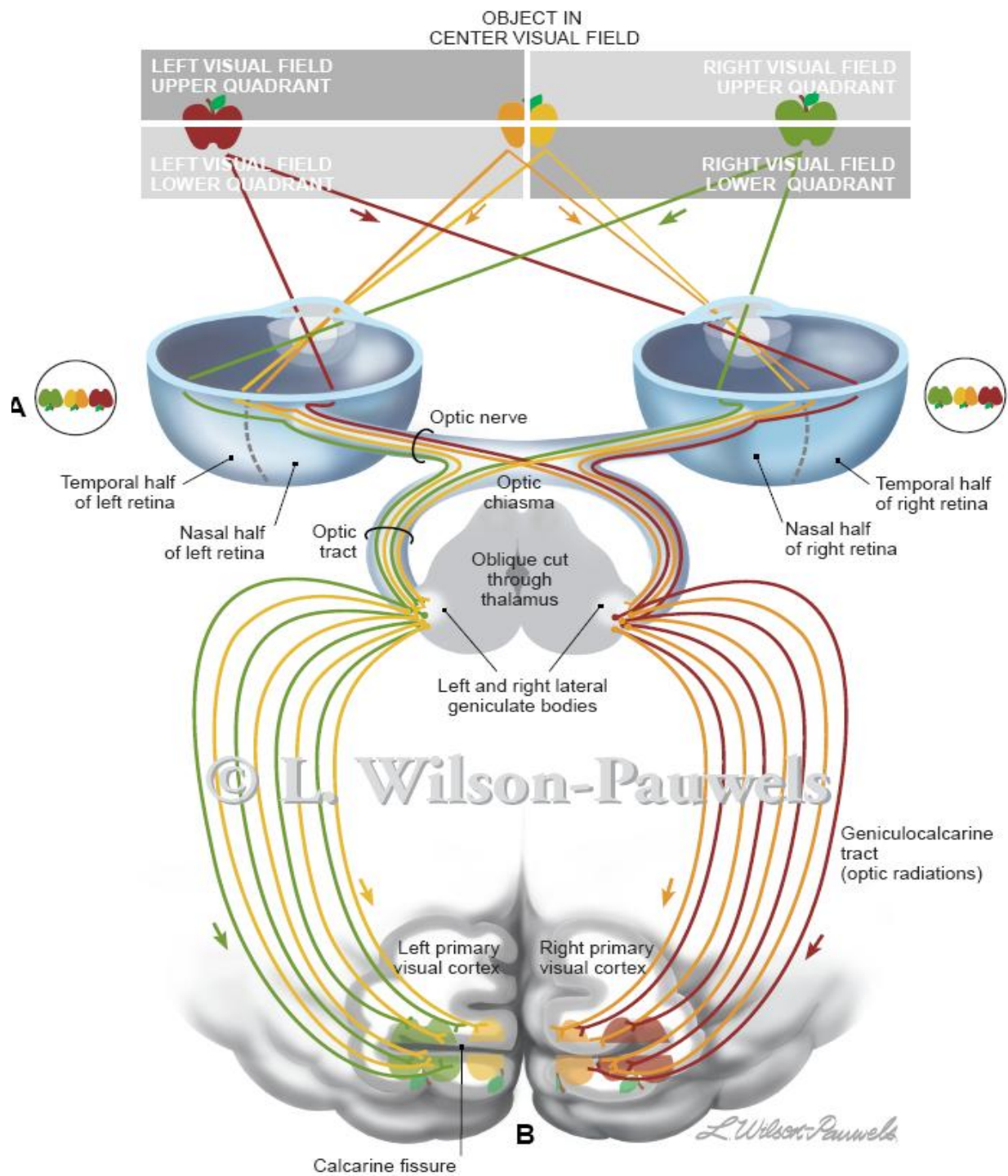
Thus fibers from the right halves of both retinas form the left optic tract.

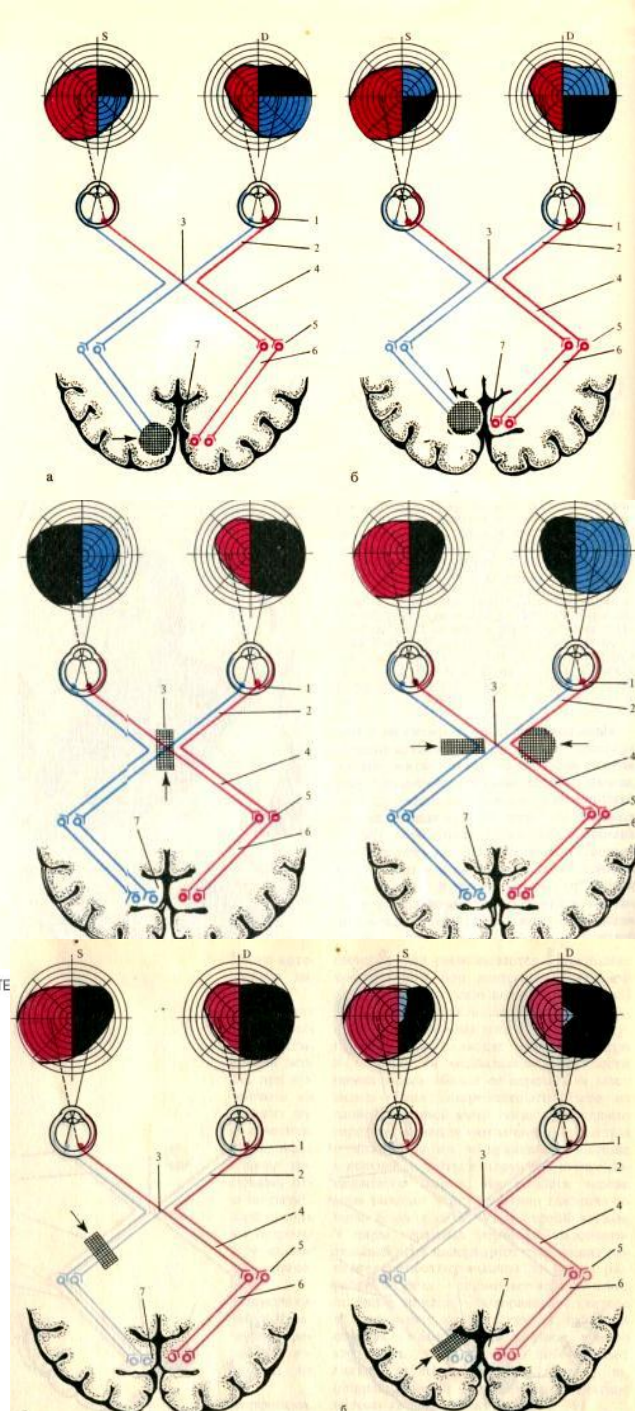
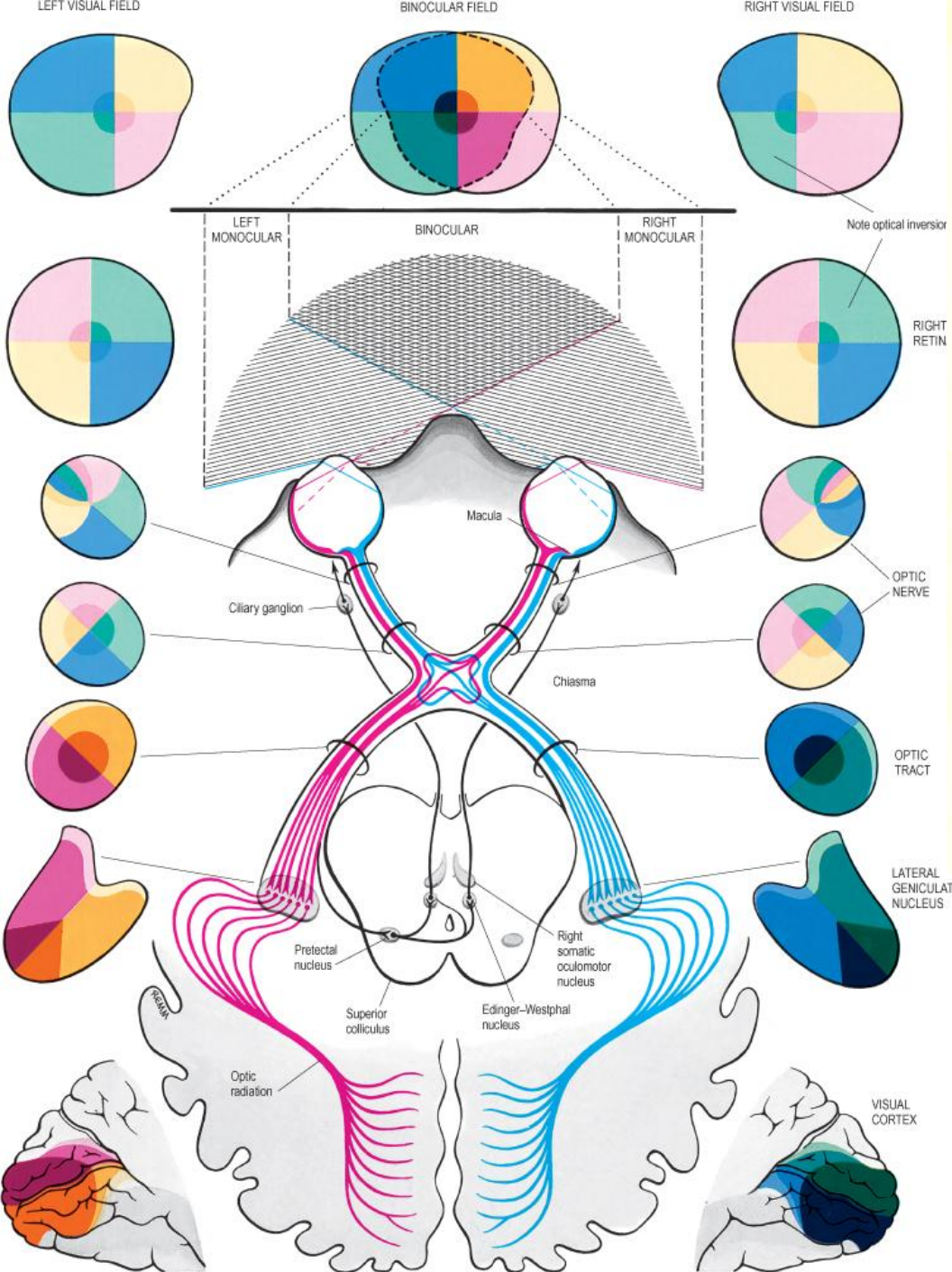
The decussation of nerve fibers in the chiasm results in the right optic tract conveying impulses from the left visual field and vice versa.

The visual field is what is seen by a person who has both eyes wide open and who is looking straight ahead. Most fibers in the optic tracts terminate in **the lateral geniculate bodies** of the thalamus. From these nuclei, axons are relayed to the visual cortices of **the occipital lobes** of the brain.

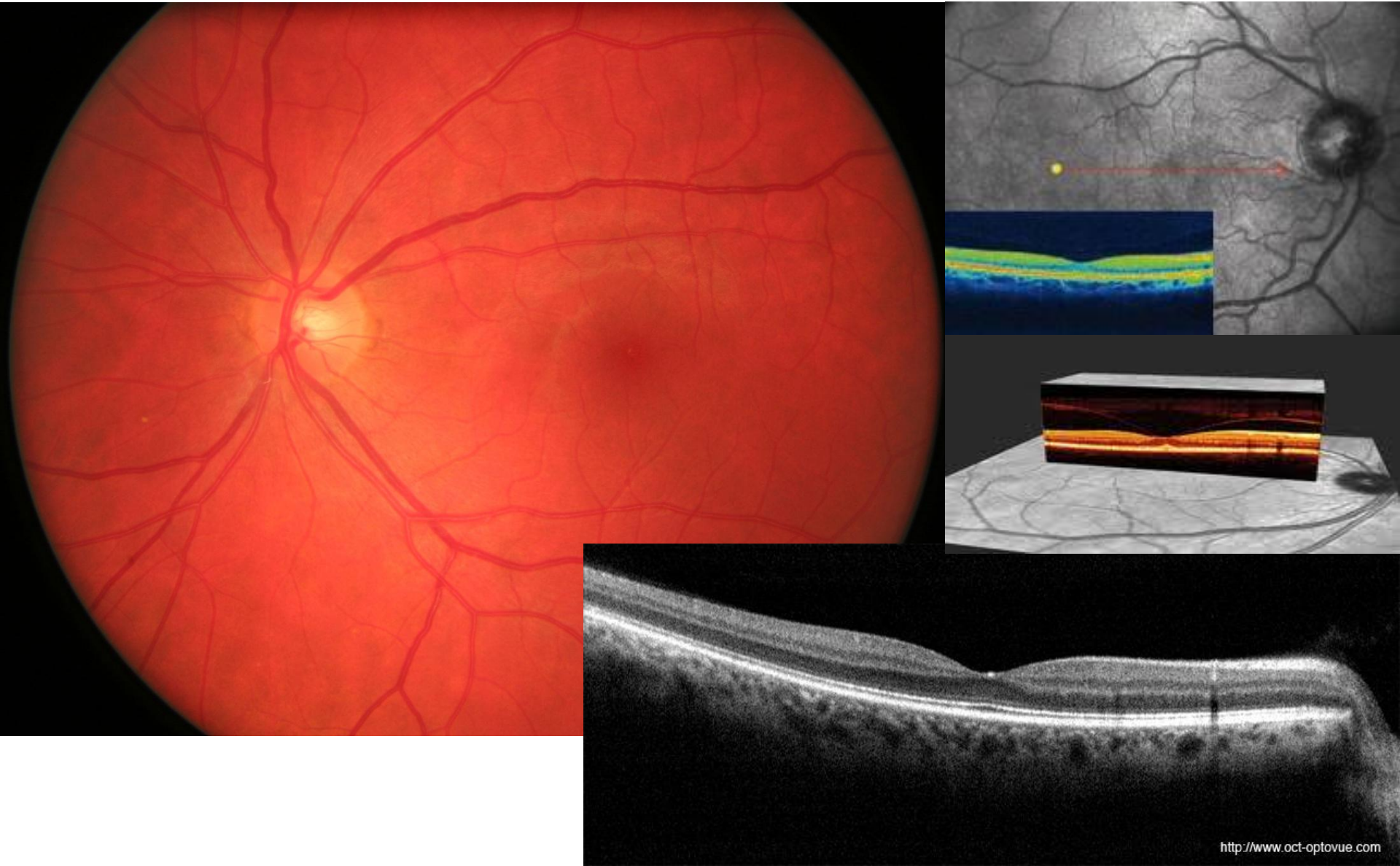
Cranial nerves

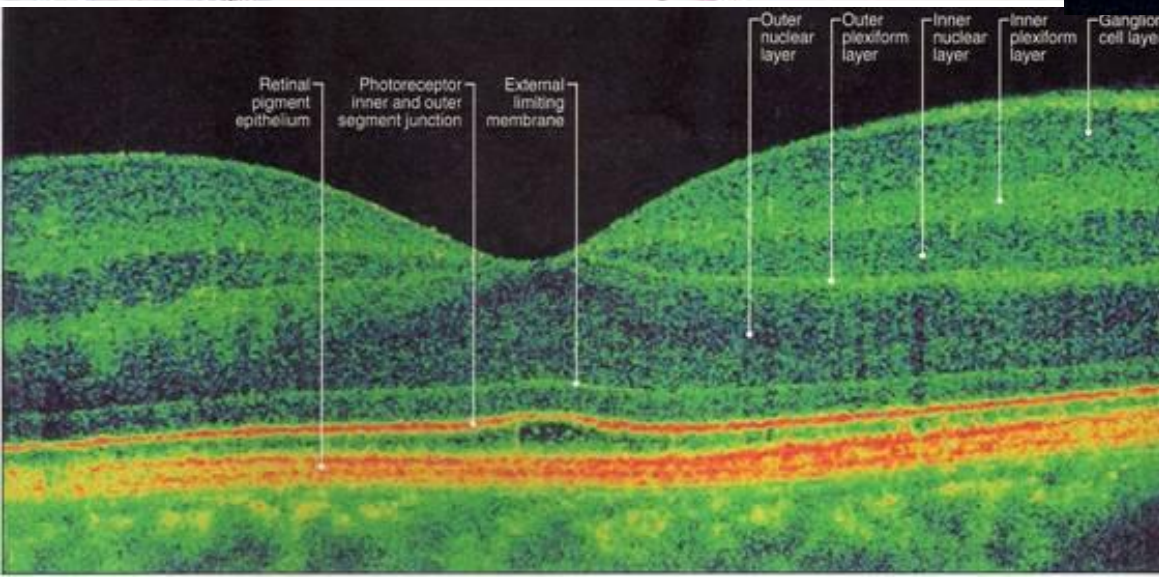
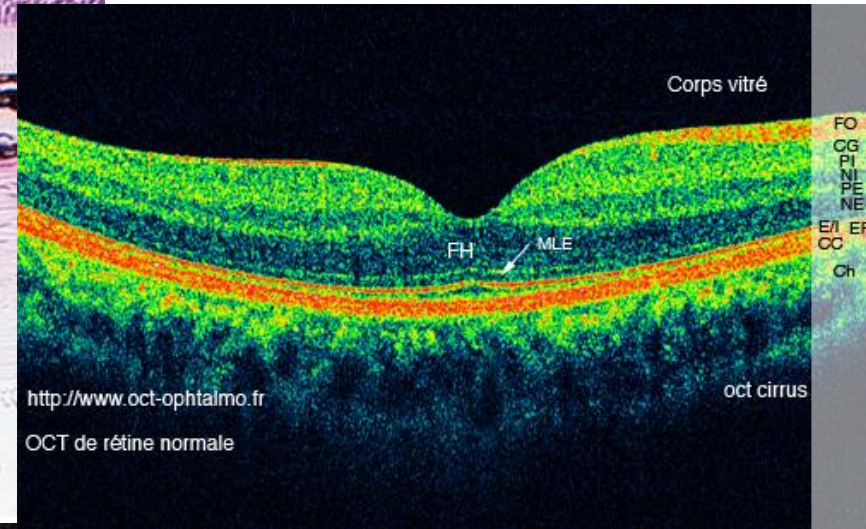
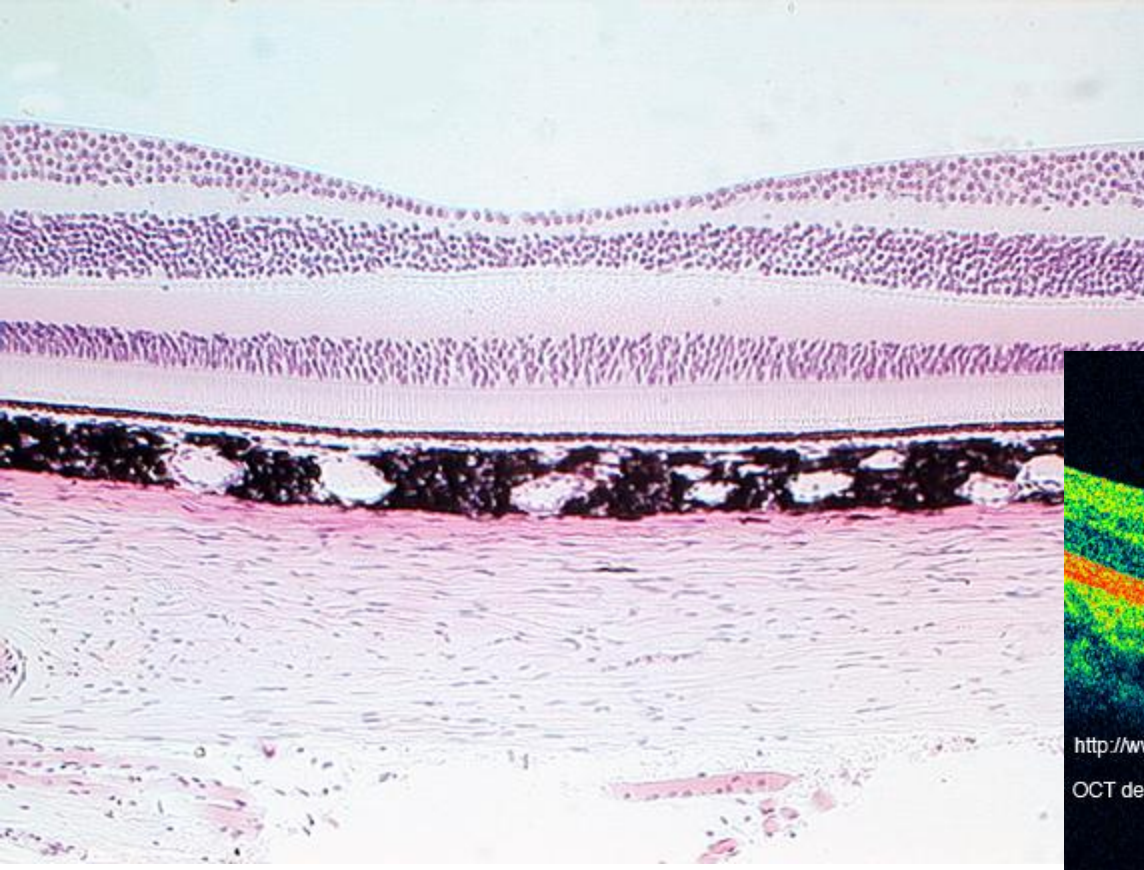





OCT - ocular coherence tomography





Cranial nerves

Oculomotor Nerve (CN III)

Functions: Somatic motor (general somatic efferent) and visceral motor (general visceral efferent parasympathetic).

Nuclei: There are **two oculomotor nuclei**, each serving one of the functional components of the nerve.

The somatic motor nucleus of the oculomotor nerve is in the midbrain.

The visceral motor (*parasympathetic*) accessory (Edinger-Westphal) nucleus of the oculomotor nerve lies dorsal to the rostral two thirds of the somatic motor nucleus .

The oculomotor nerve (CN III) provides the following:

Motor to the striated muscle of **four** of the six extraocular muscles (superior, medial, and inferior recti and inferior oblique) and superior eyelid (*levator palpebrae superioris*); hence the nerve's name.

Proprioceptive to the muscles listed above.

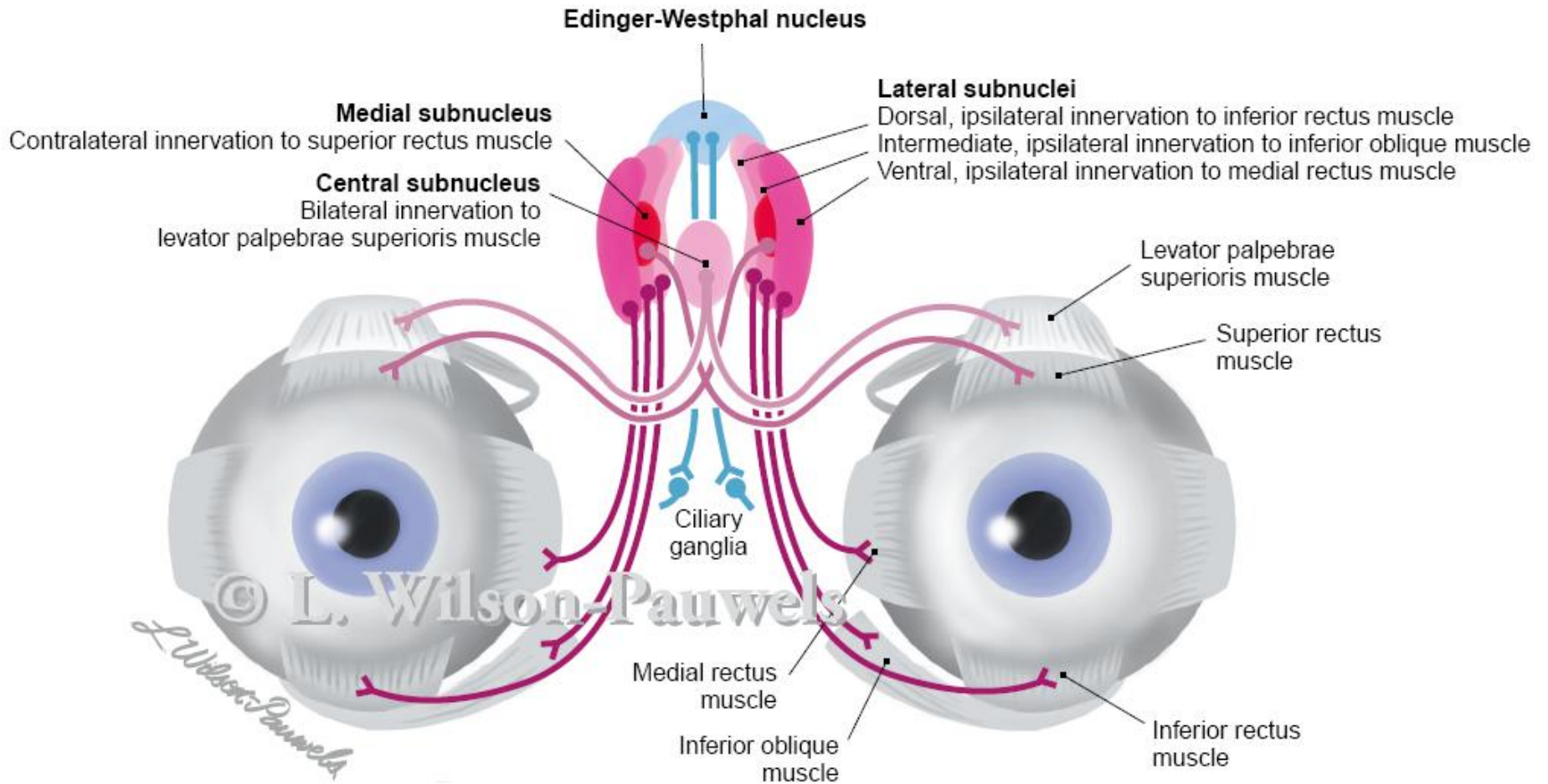
Parasympathetic through the ciliary ganglion to the smooth muscle of the sphincter of the pupil, which causes constriction of the pupil and ciliary body, which produces accommodation (allowing the lens to become more rounded) for near vision.

CN III is the **chief motor nerve** to the ocular and extraocular muscles. It emerges from the midbrain, pierces the dura lateral to the sellar diaphragm roofing over the hypophysis, and then runs through the roof and lateral wall of the cavernous sinus.

It leaves the cranial cavity and enters the orbit through the superior orbital fissure.

Within this fissure, CN III divides into a **superior division** (which supplies the superior rectus and levator palpebrae superioris) and an **inferior division** (which supplies the inferior and medial rectus and inferior oblique).

The inferior division also carries **presynaptic parasympathetic** (visceral efferent) fibers to the ciliary ganglion, where they synapse. Postsynaptic fibers from this ganglion pass to the eyeball in the short ciliary nerves to innervate the ciliary body and sphincter of the pupil.



Cranial nerves

Trochlear Nerve (CN IV)

Functions: Somatic motor (general somatic efferent) and proprioceptive to one extraocular muscle (superior oblique).

Nucleus: The nucleus of the trochlear nerve is located in the midbrain, immediately caudal to the oculomotor nucleus.

The trochlear nerve (CN IV) is the **smallest** cranial nerve.

It emerges from the **posterior surface** of the midbrain (the **only cranial nerve** to do so), passing anteriorly around the brainstem, running **the longest intracranial** (*subarachnoid*) course of the cranial nerves. It pierces the dura mater at the margin of the cerebellar tentorium and passes anteriorly in the lateral wall of the cavernous sinus.

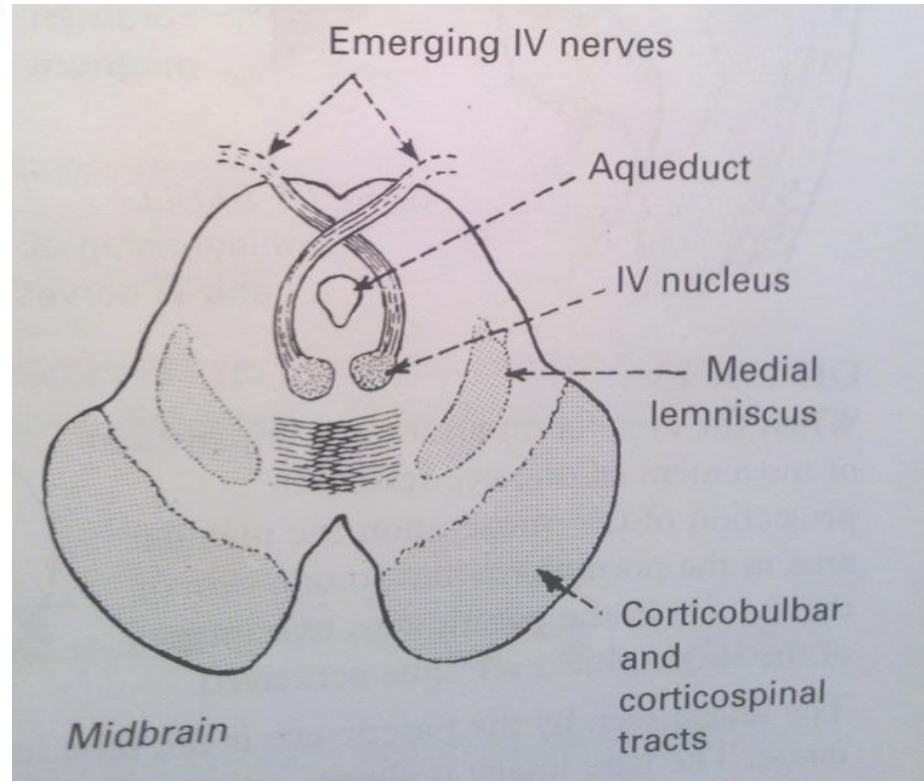
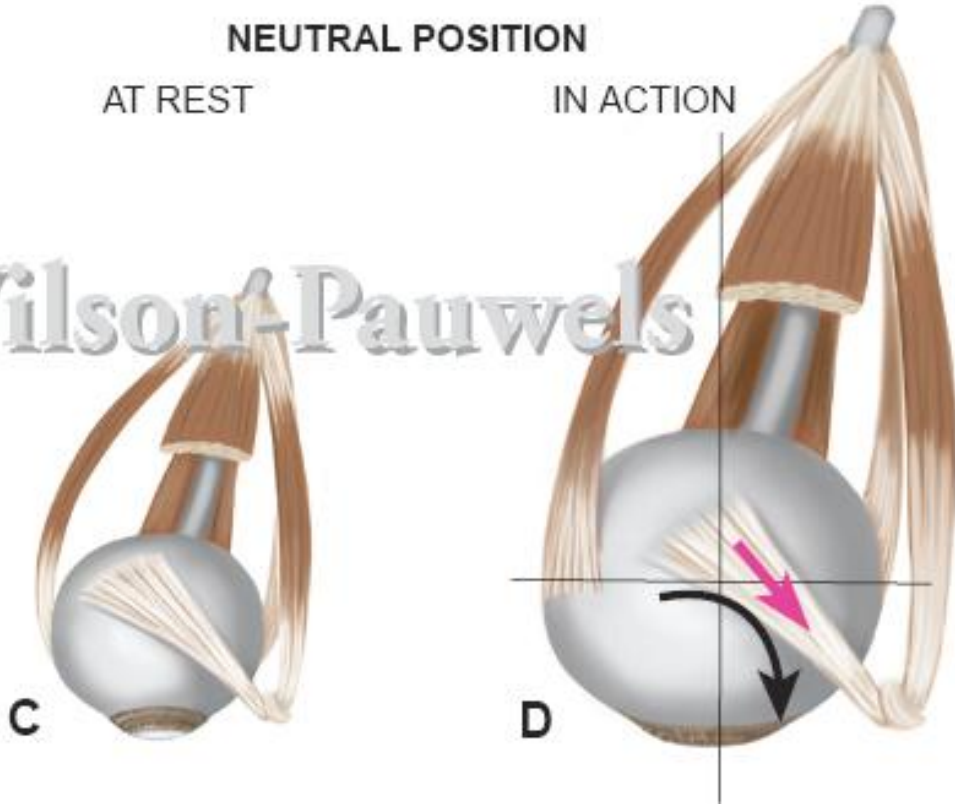
CN IV continues past the sinus to pass through the superior orbital fissure into the orbit, where it supplies the superior oblique the only extraocular muscle that uses a pulley, or **trochlea**, to redirect its line of action (hence the nerve's name).

NEUTRAL POSITION

AT REST

IN ACTION

Wilson-Pauwels



Cranial nerves

Abducent Nerve (CN VI)

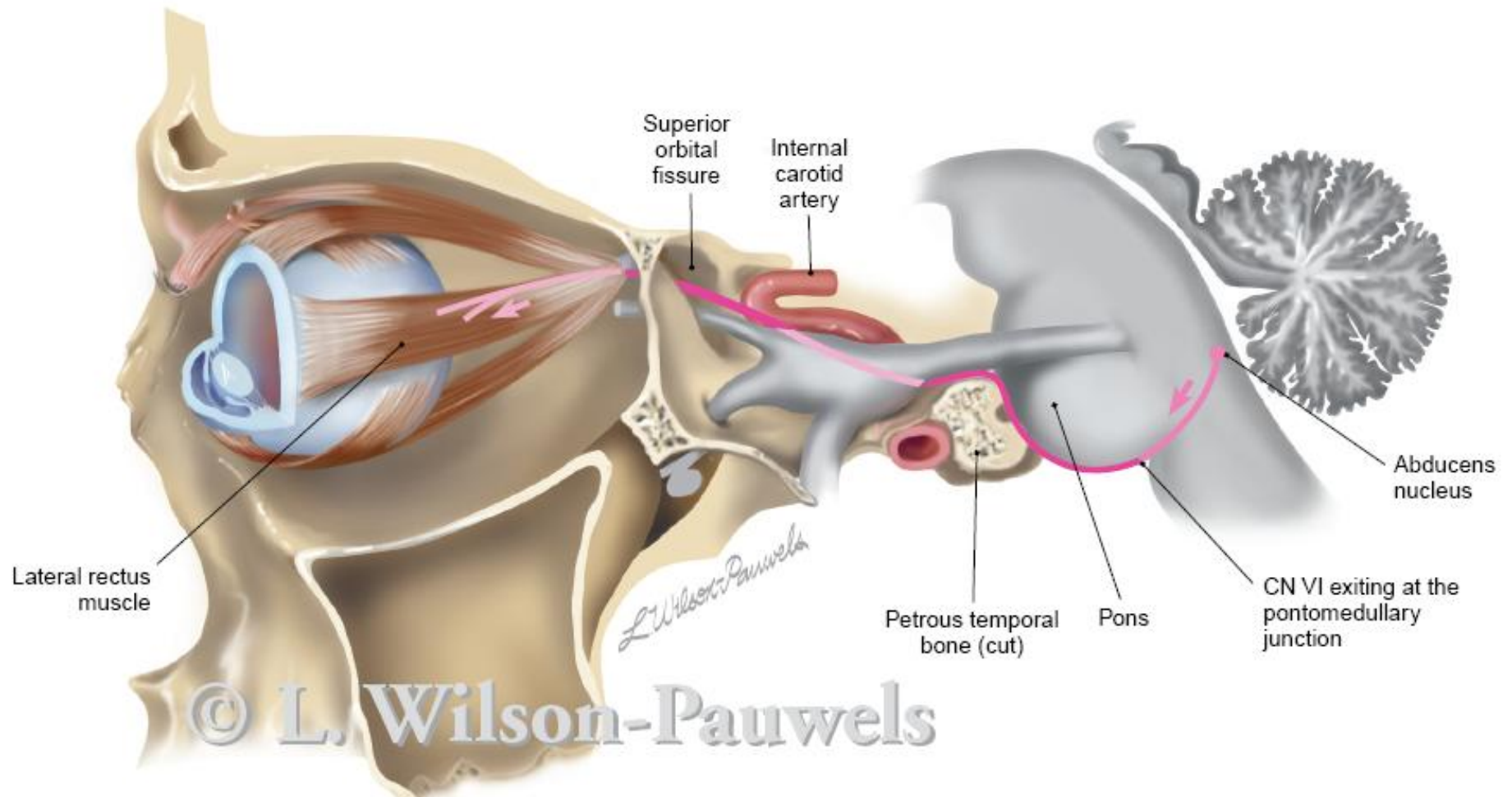
Functions: Somatic motor (general somatic efferent and proprioceptive) to one extraocular muscle (lateral rectus).

Nucleus: The abducent nucleus is in the pons near the median plane.

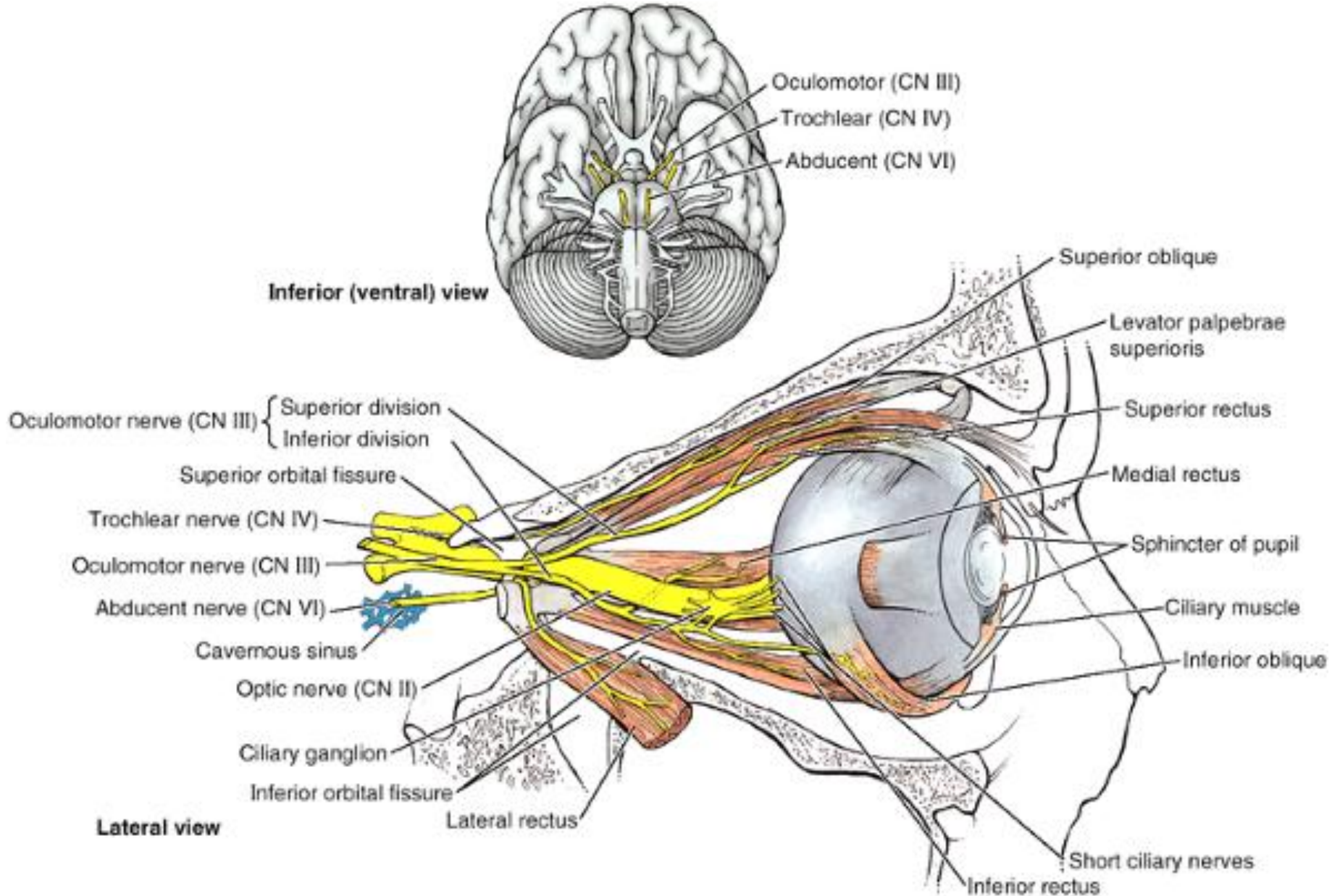
The abducent nerves (CN VI) emerge from the brainstem between the pons and the medulla and traverse the pontine cistern of the subarachnoid space, straddling the basilar artery. Each abducent nerve then pierces the dura to run **the longest intradural** course within the cranial cavity of the cranial nerves that is, its point of entry into the dura covering the clivus is the most distant from its exit from the cranium via the **superior orbital fissure**.

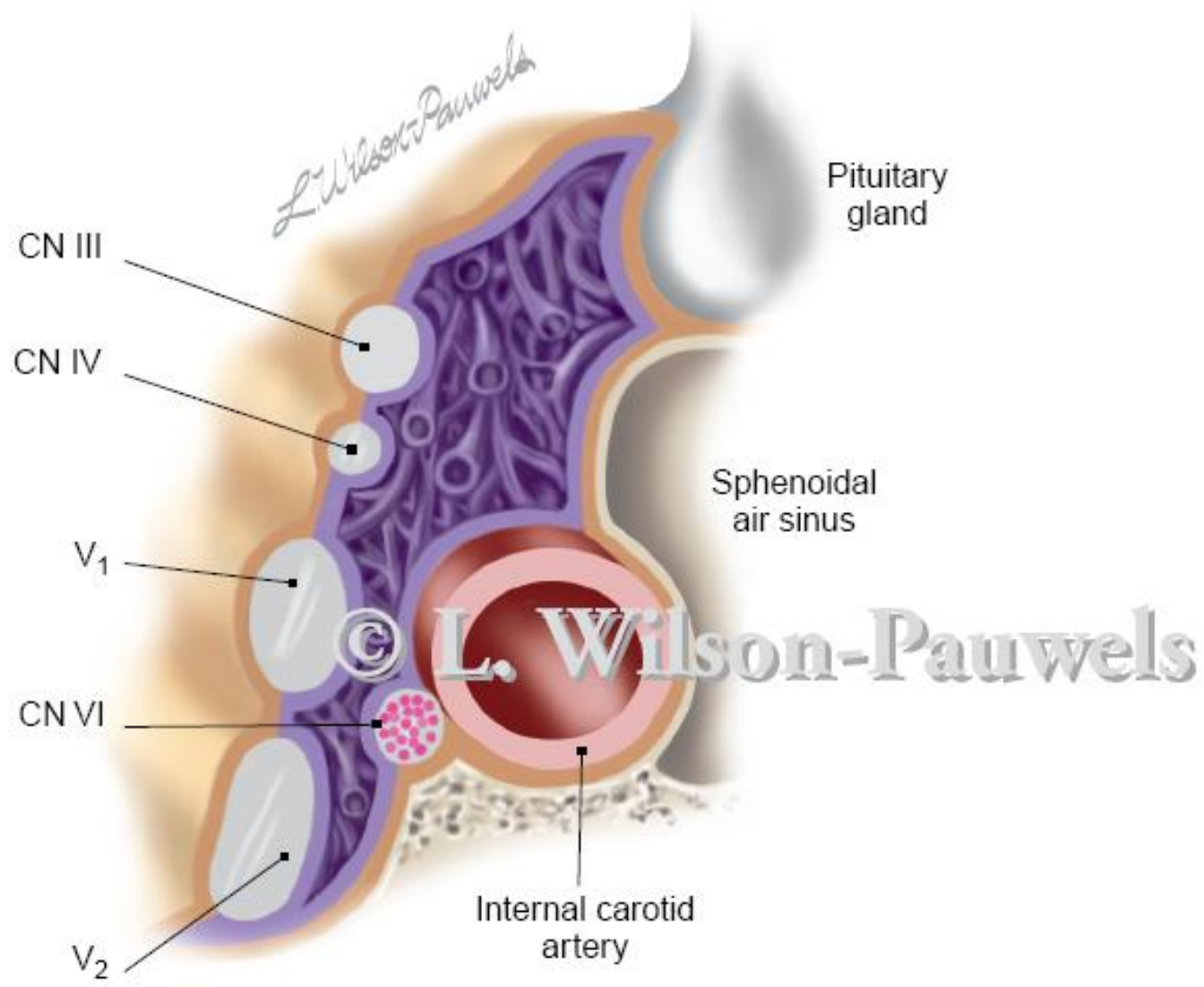
During **its intradural course**, it bends sharply over the crest of the petrous part of the temporal bone and then courses through the cavernous sinus, surrounded by the venous blood in the same manner as the internal carotid artery, which it parallels in the sinus.

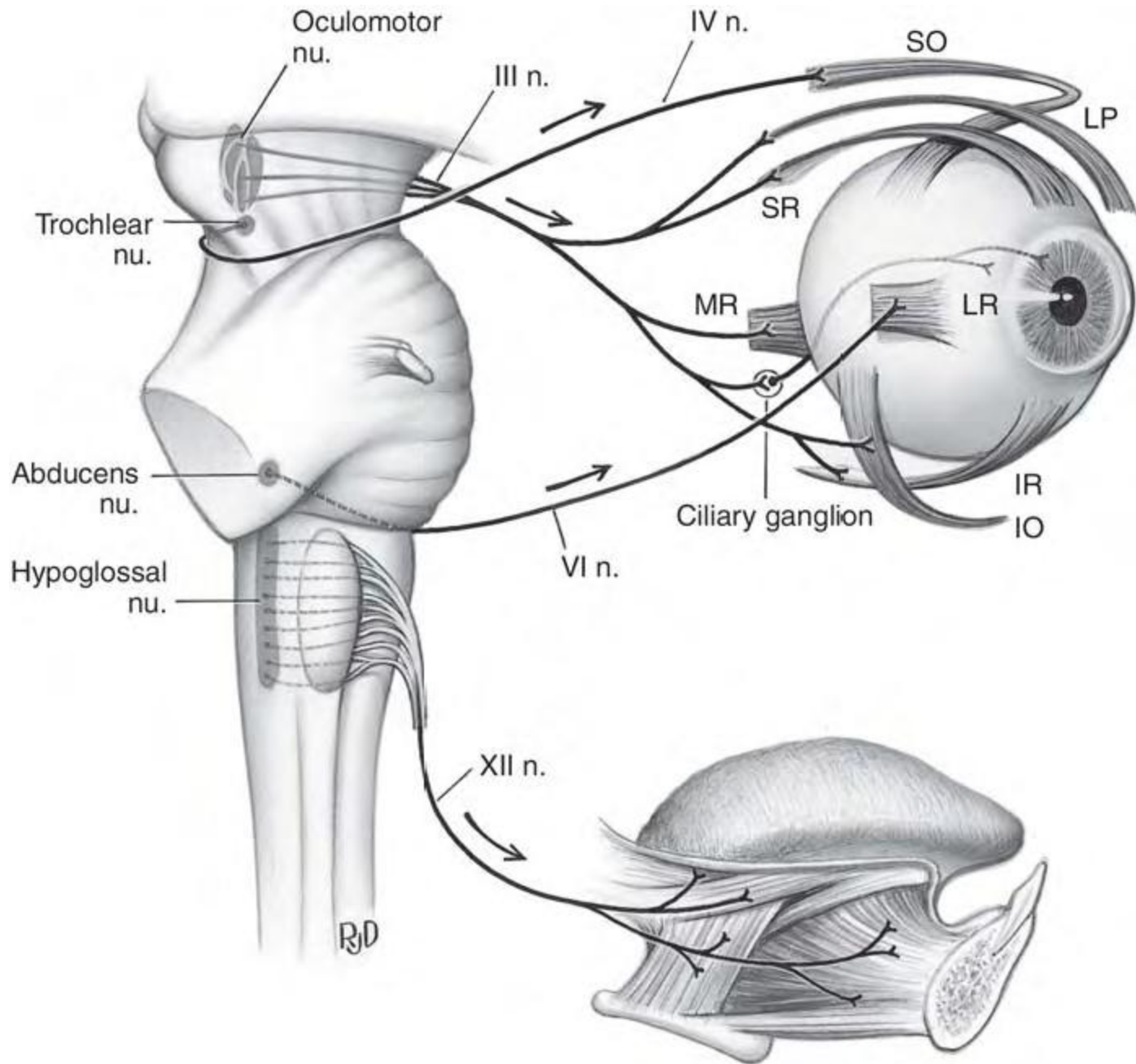
CN VI traverses the common tendinous ring as it enters the orbit, running on and penetrating the medial surface of the lateral rectus, which **abducts the eye** (this function being the basis for the name of the nerve).

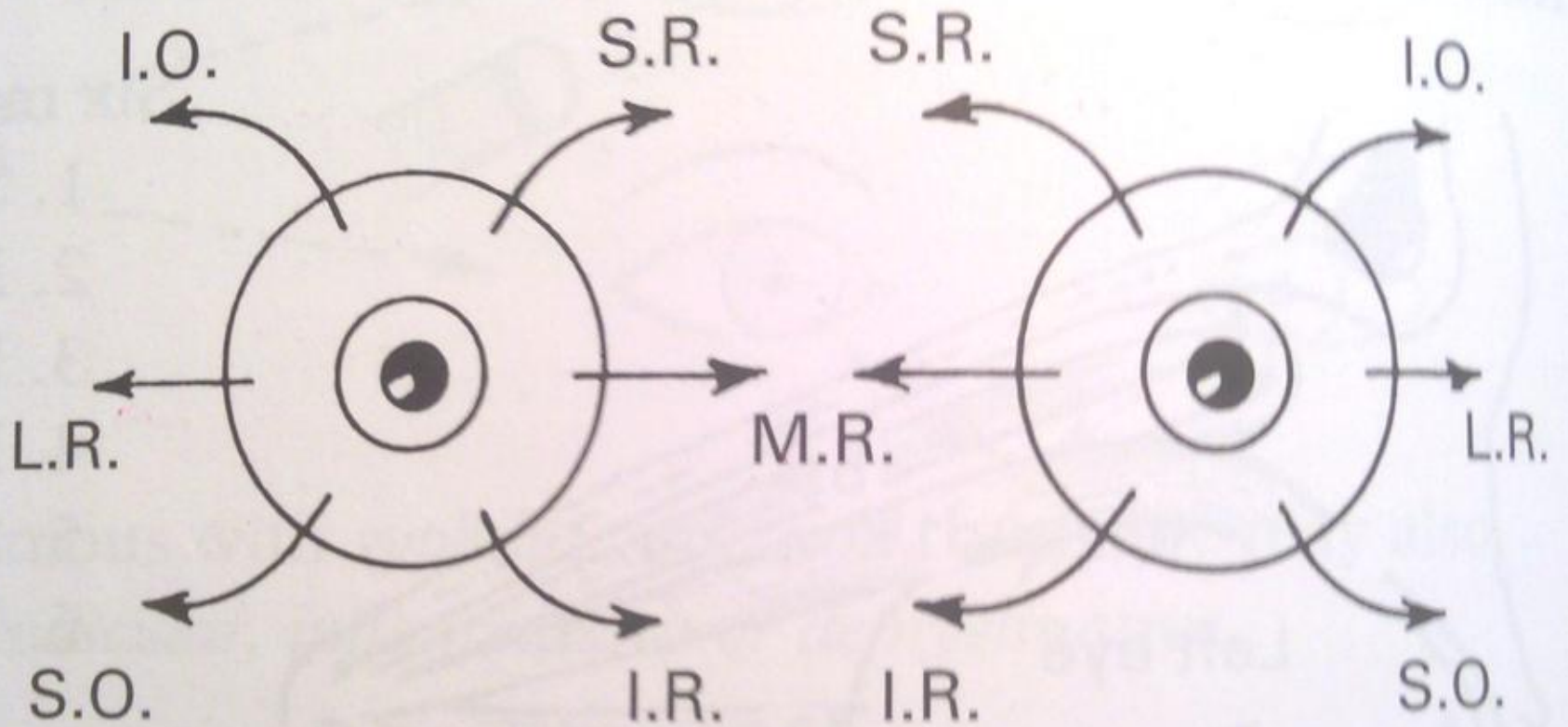


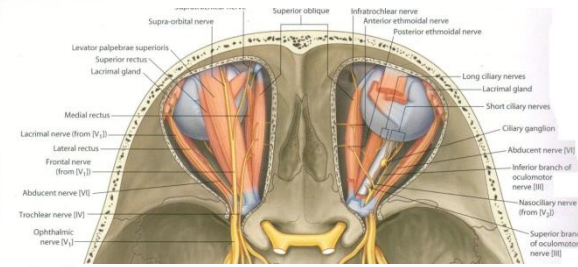
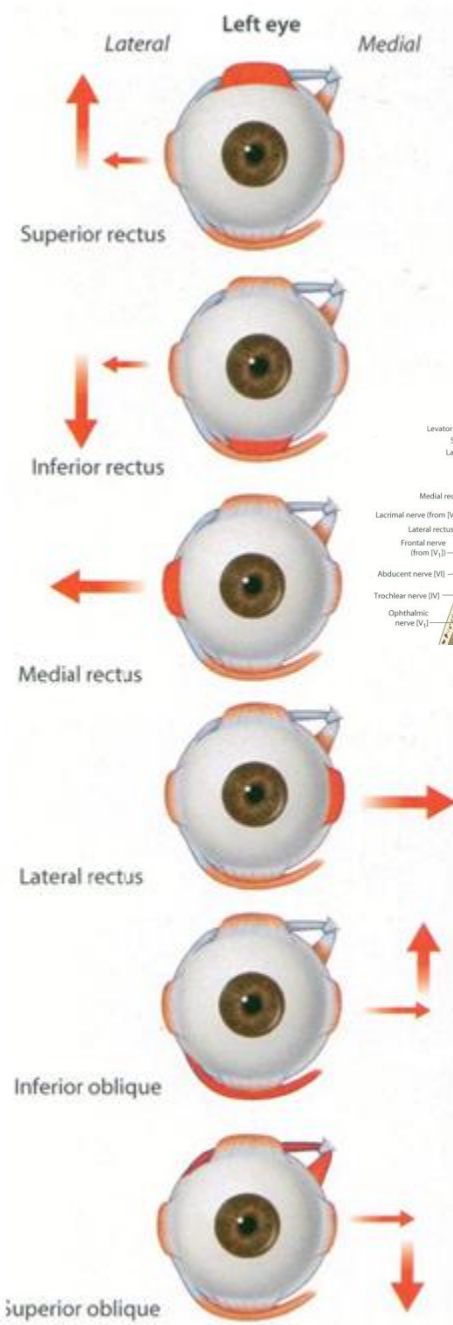
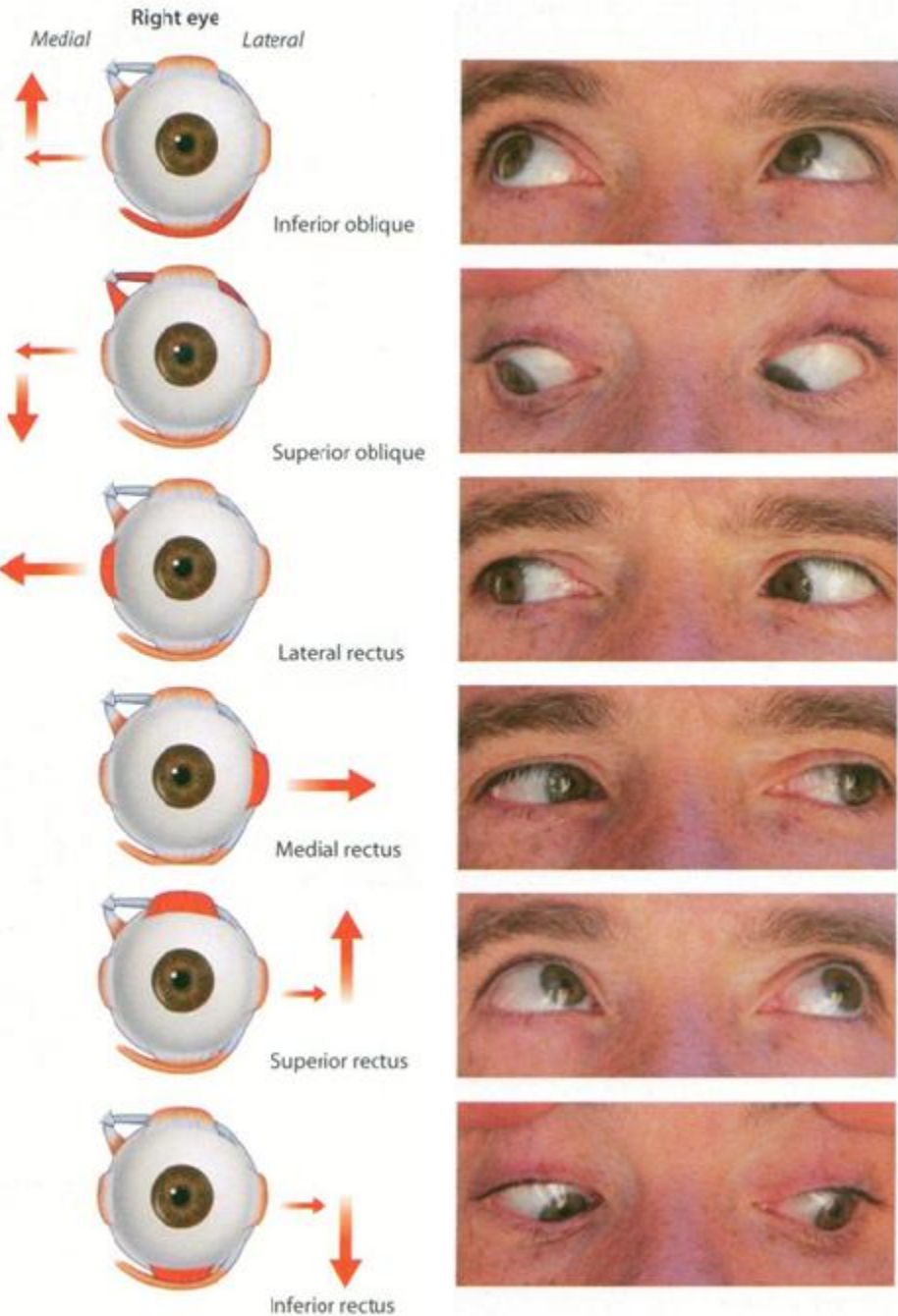
Cranial nerves







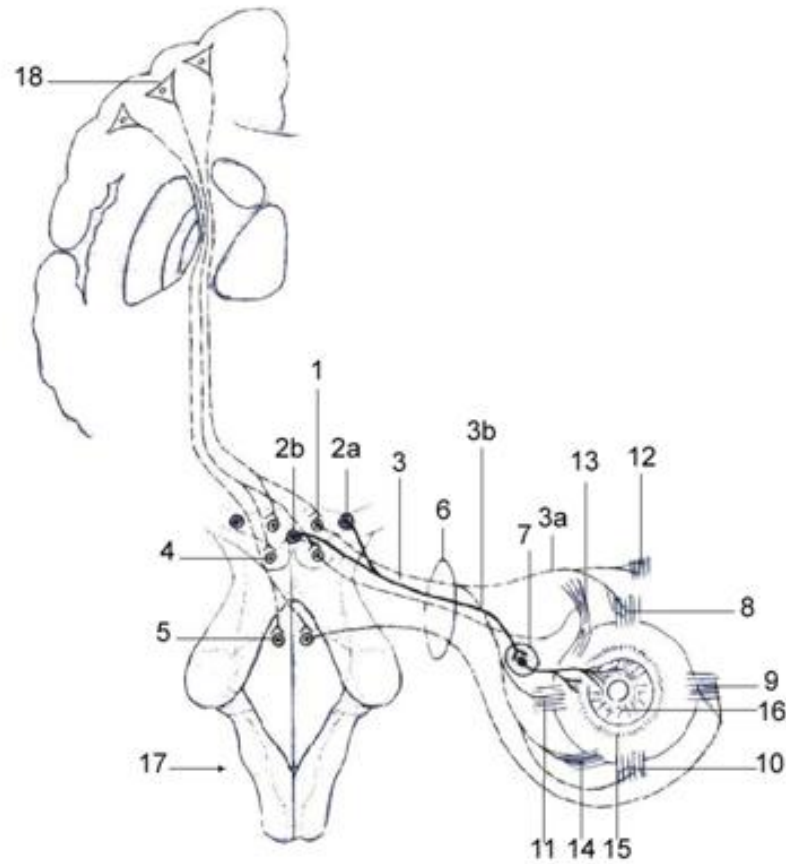




Movement of eyes when testing specific muscle (clinical testing).

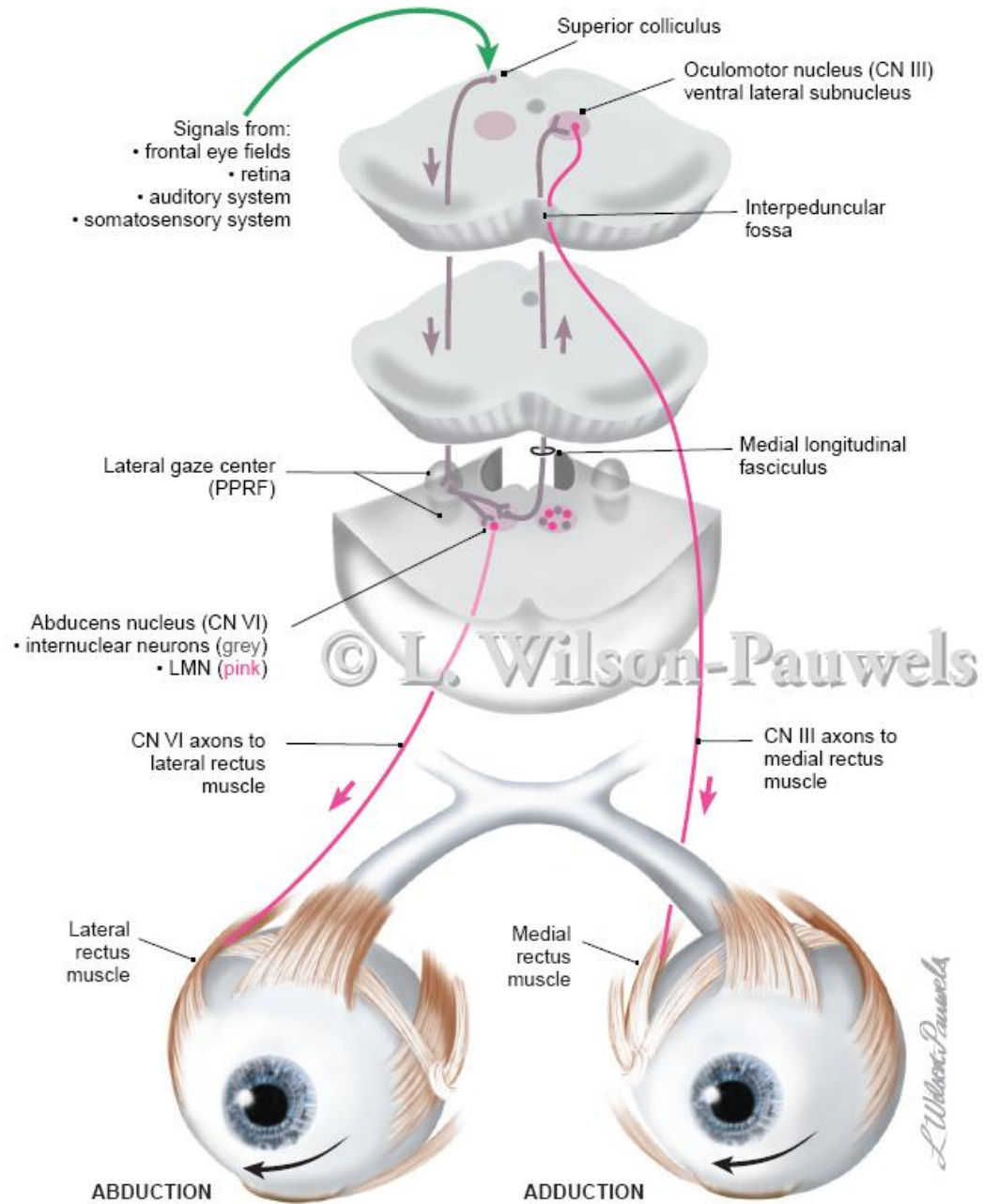
For testing some muscles, a patient is "asked" to first move the eye into a position (small arrow) where the indicated muscle can best be tested. The large arrow indicates the direction the patient is then "asked" to move the eye to test the muscle

Innervation of the muscles of the eyeball

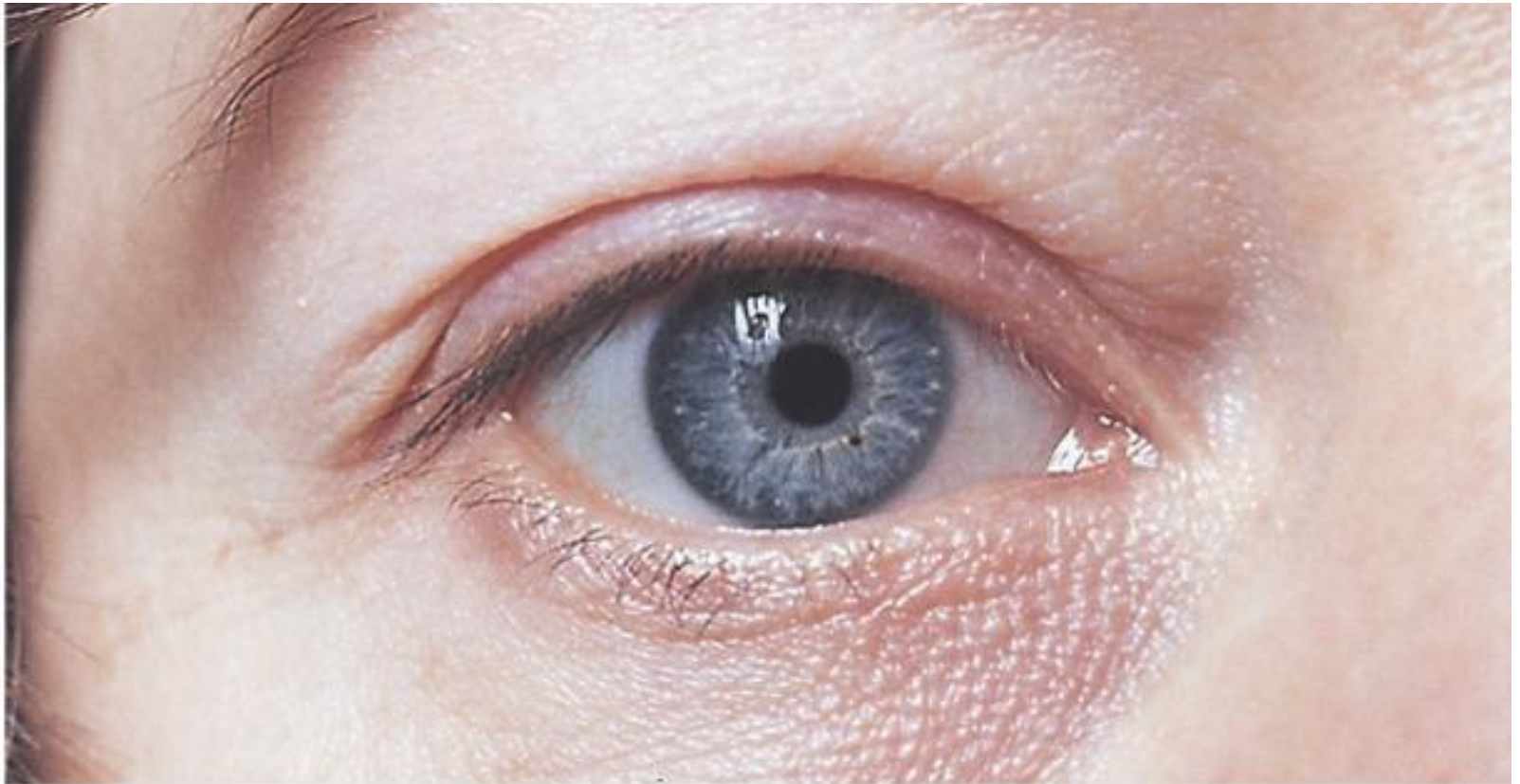


- 1 – nucl. n. oculomotorii (III);
 2a – n. accessorius (Якубович-Edinger-Westfal);
 2b – nucleus impar (Perl) (III);
 3 – nervus oculomotorius:
 3a – ramus superior;
 3b – ramus inferior;
 4 – nucl.n. trochlearis (IV);
 5 – nucl.n. abducentis (VI);
 6 – fissura orbitalis superior;
 7 – ganglion ciliare;

- 8 – m. rectus superior;
 9 – m. rectus lateralis;
 10 – m. rectus inferior;
 11 – m. rectus medialis;
 12 – m. levator palpebrae superioris;
 13 – m. obliquus superior;
 14 – m. obliquus inferior;
 15 – m. ciliaris;
 16 – m. sphincter pupillae;
 17 – truncus cerebri;
 18 – neurocytoma pyramidalis magnus (Betz).



EYE MUSCLES: IRIS

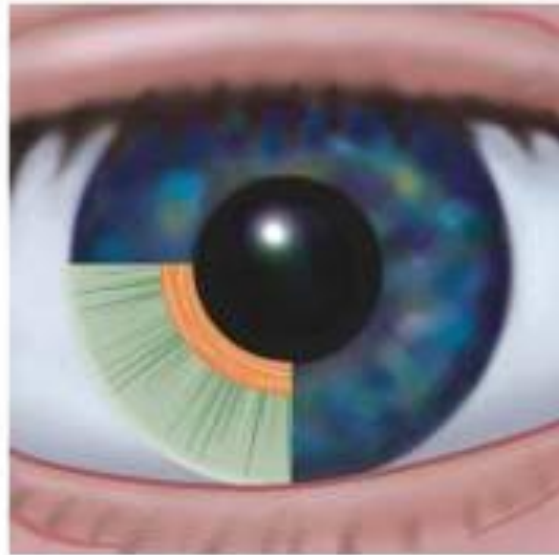


The iris function

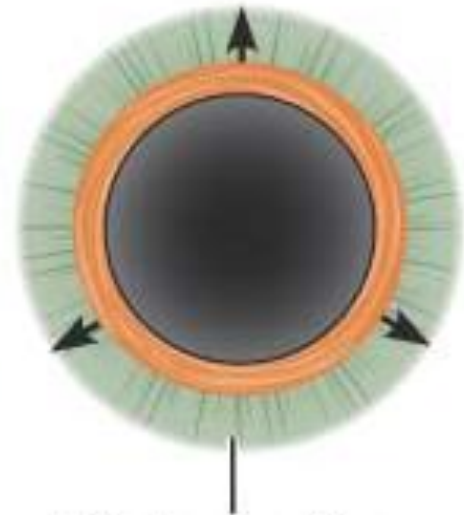
Parasympathetic +



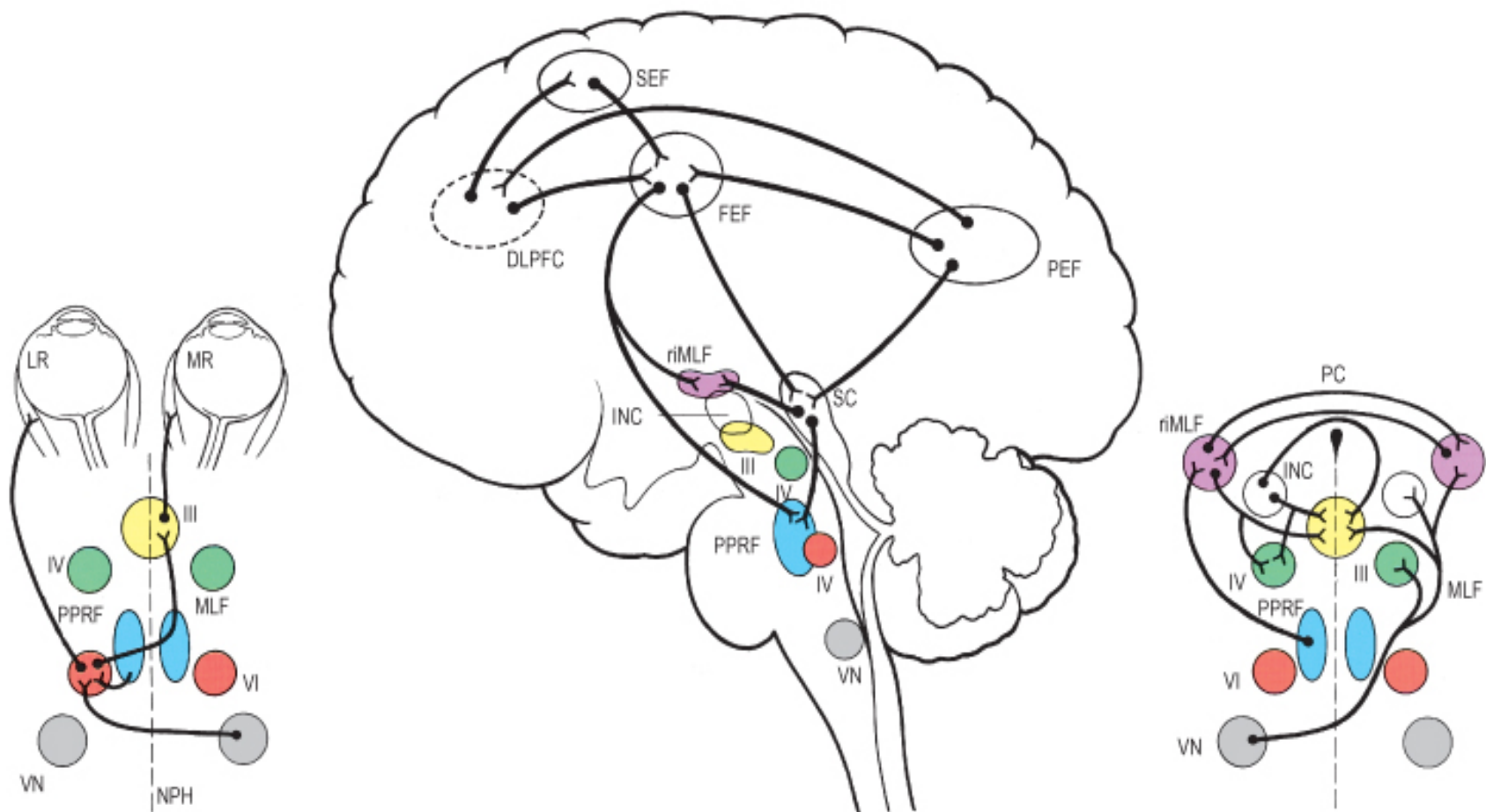
Sphincter pupillae muscle



Sympathetic +

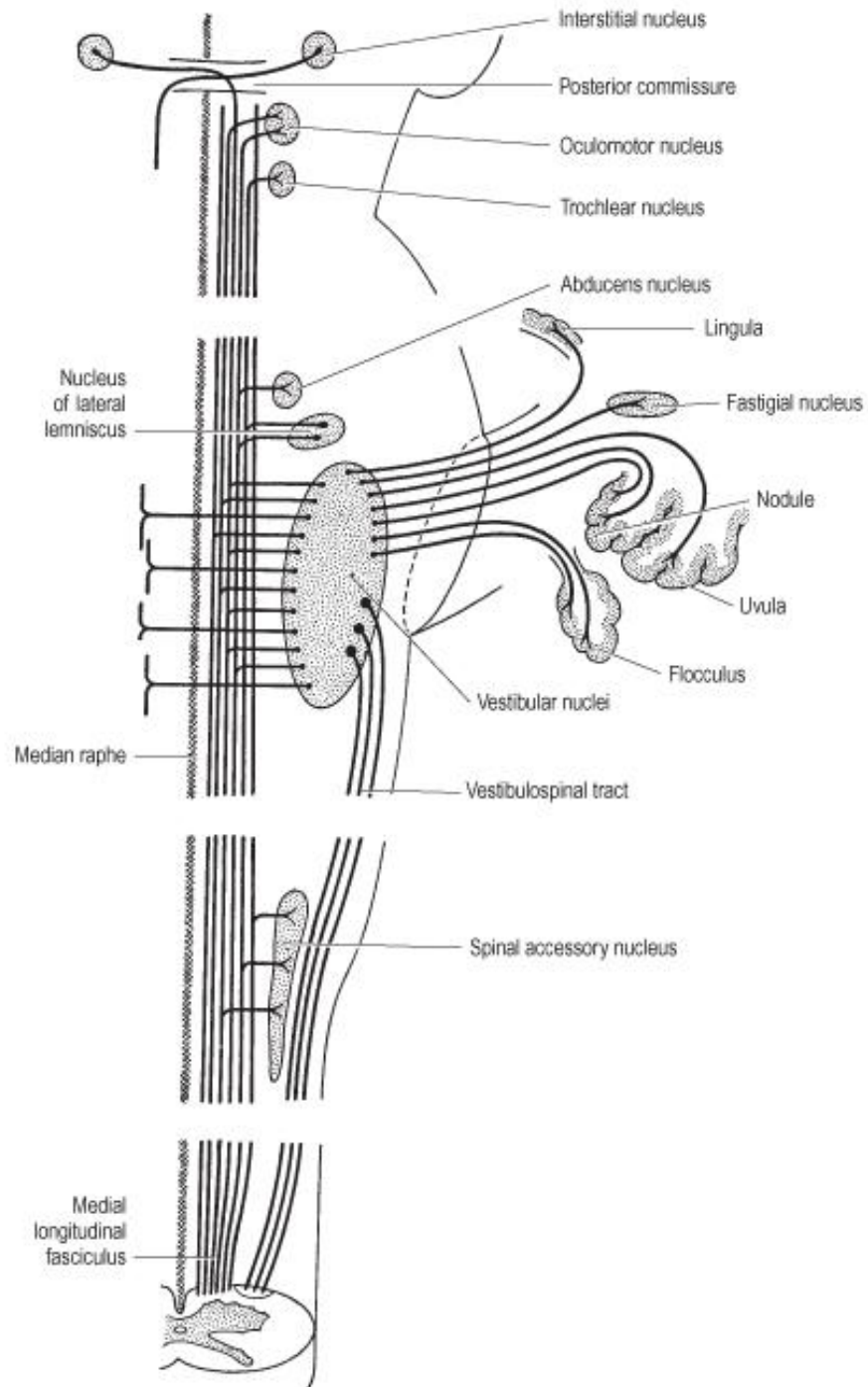


Dilator pupillae muscle



© Elsevier Ltd 2005. Standing: Gray's Anatomy 39e - www.graysanatomyonline.com

Figure 24.3 Summary of eye movement control. The central drawing shows the supranuclear connections from the frontal eye field (FEF) and the posterior eye field (PEF) to the superior colliculus (SC), rostral interstitial nucleus of the medial longitudinal fasciculus (riMLF), and the paramedian pontine reticular formation (PPRF). The FEF and SC are involved in the production of saccades, while the PEF is thought to be important in the production of pursuit. The drawing on the left shows the brain stem pathways for horizontal gaze. Axons from the PPRF travel to the ipsilateral abducens nucleus innervating lateral rectus (LR). Abducens internuclear axons cross the midline and travel in the medial longitudinal fasciculus (MLF) to the portion of the oculomotor nucleus (III) innervating medial rectus (MR) of the contralateral eye. The drawing on the right shows the brain stem pathways for vertical gaze. Important structures include the riMLF, PPRF, the interstitial nucleus of Cajal (INC), and the posterior commissure (PC). Other abbreviations: DLPFC, dorsolateral prefrontal cortex; IV, trochlear nucleus; SEF, supplementary eye field; VN, vestibular nucleus.



Cranial nerves

Trigeminal Nerve (CN V)

Functions: General sensory (general somatic afferent) and branchial motor (special visceral efferent) to derivatives of the 1st pharyngeal arch.

Nuclei: There are four trigeminal nuclei one motor and three sensory.

The trigeminal nerve (CN V) is the **largest** cranial nerve.

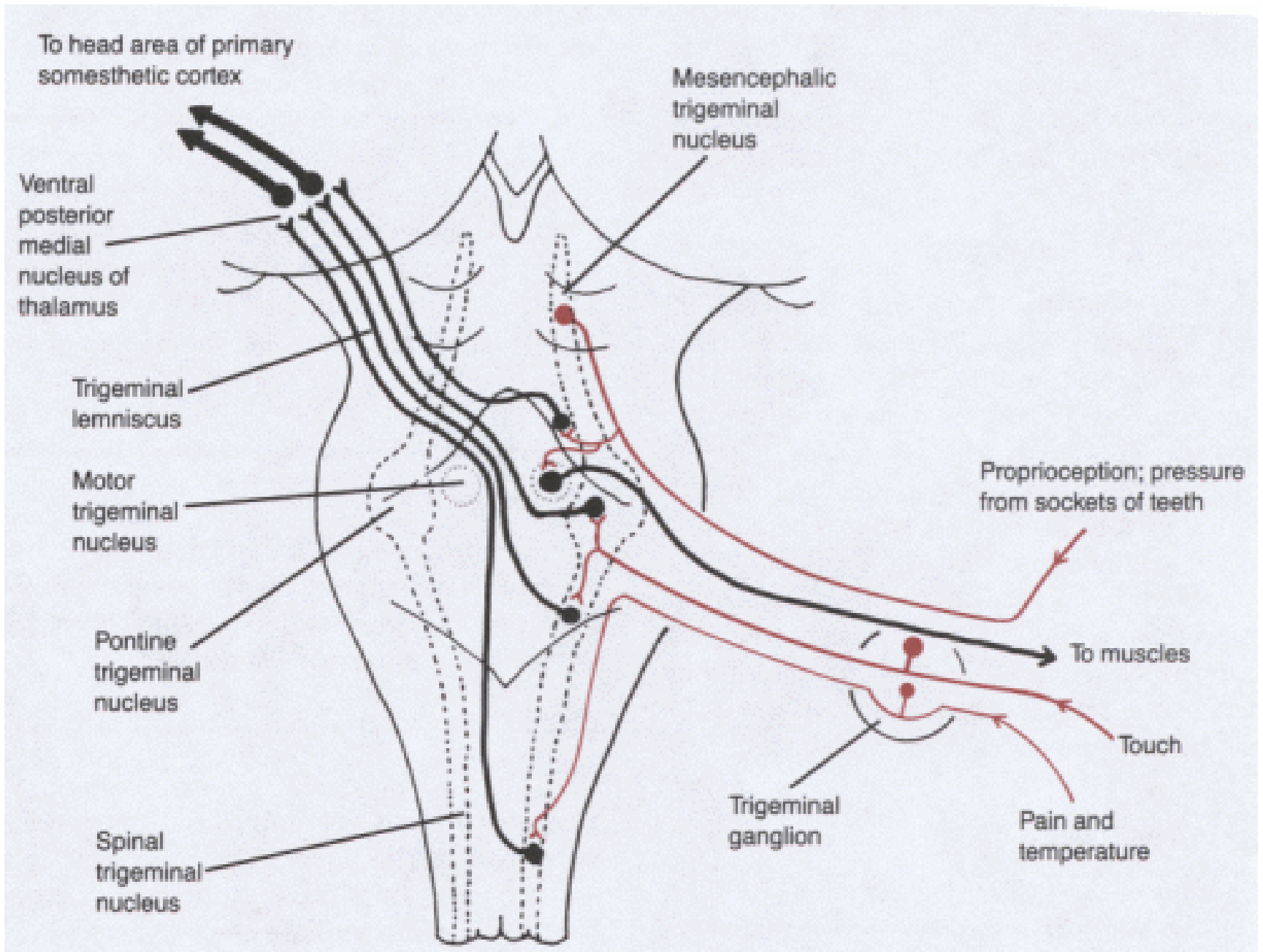
It emerges from the lateral aspect of the pons by a large sensory root and a small motor root. The roots of CN V are comparable to the posterior and anterior roots of spinal nerves.

CN V is the principal general sensory nerve for the head (face, teeth, mouth, nasal cavity, and dura of the cranial cavity). The large **sensory root** of CN V is composed mainly of the central processes of the pseudounipolar neurons that make up the trigeminal ganglion. The trigeminal ganglion is flattened and crescent shaped (hence its unofficial name, semilunar ganglion) and is housed within a dural recess (trigeminal cave) lateral to the cavernous sinus. The peripheral processes of the ganglionic neurons form three nerves or divisions:

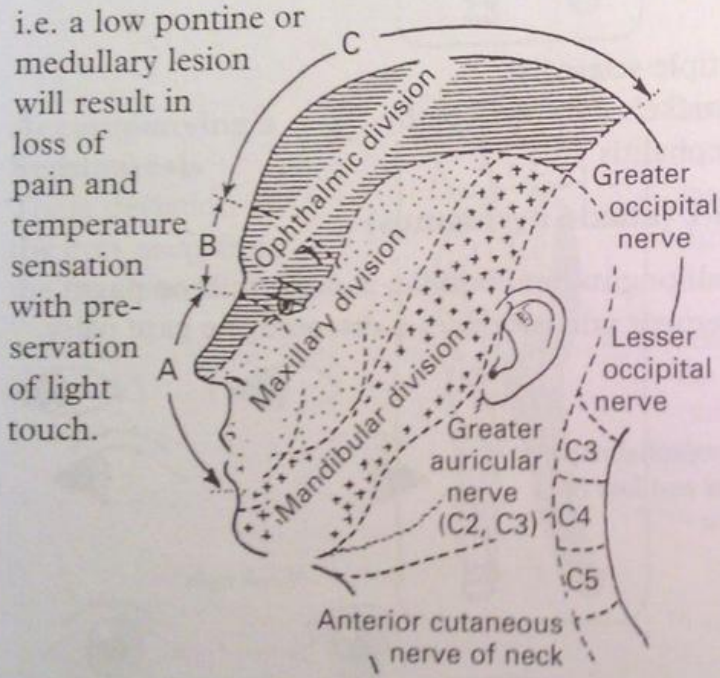
ophthalmic nerve (CN V₁), maxillary nerve (CN V₂), and sensory component of the mandibular nerve (CN V₃). Maps of the zones of cutaneous innervation by the three divisions resemble the dermatome maps for cutaneous innervation by spinal nerves. Unlike dermatomes, however, there is little overlap in innervation by the divisions; lesions of a single nerve result in clearly demarcated areas of numbness.

The fibers of the **motor root** of CN V pass inferior to the trigeminal ganglion along the floor of the trigeminal cave, bypassing the ganglion just as the anterior roots of spinal nerves bypass the spinal sensory ganglia. They are distributed exclusively via the mandibular nerve (CN V₃), blending with the sensory fibers as the nerve traverses the foramen ovale in the cranium; entering branches pass to the muscles of mastication, mylohyoid, anterior belly of the digastric, tensor veli palatini, and tensor tympani, which are derived from the 1st pharyngeal arch.

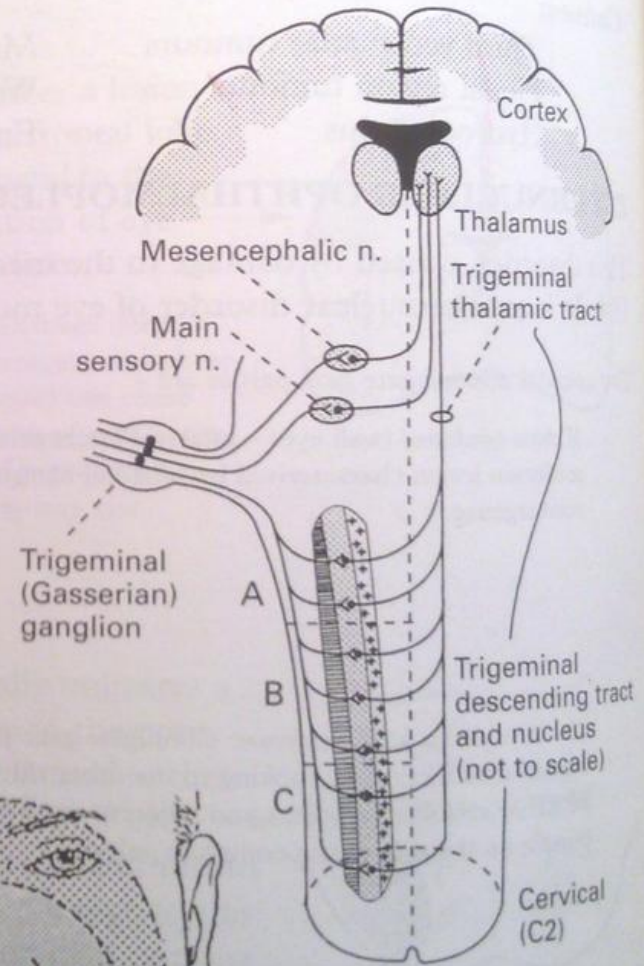
Although CN V conveys no presynaptic parasympathetic (visceral efferent) fibers from the CNS, all four parasympathetic ganglia are associated with the divisions of CN V. Postsynaptic parasympathetic fibers from the ganglia join branches of CN V and are carried to their destinations along with the CN V sensory and motor fibers.



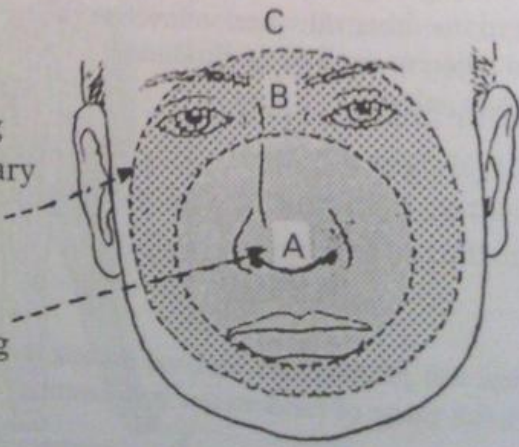
Motoneurons arise from...
 The separate location of the main sensory nucleus and nucleus of the descending trigeminal tract account for **dissociated sensory loss**, i.e. a low pontine or medullary lesion will result in loss of pain and temperature sensation with preservation of light touch.



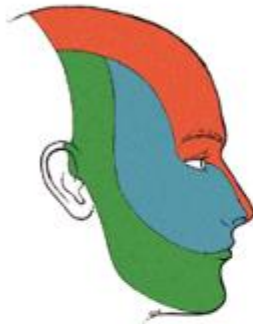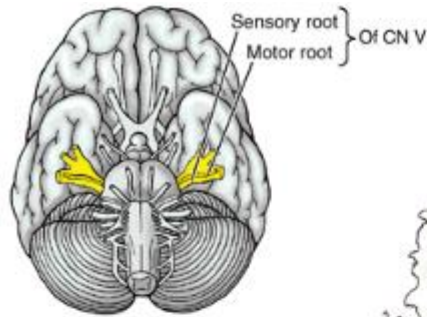
Longitudinal arrangement of the trigeminal nuclei (sensory paths)



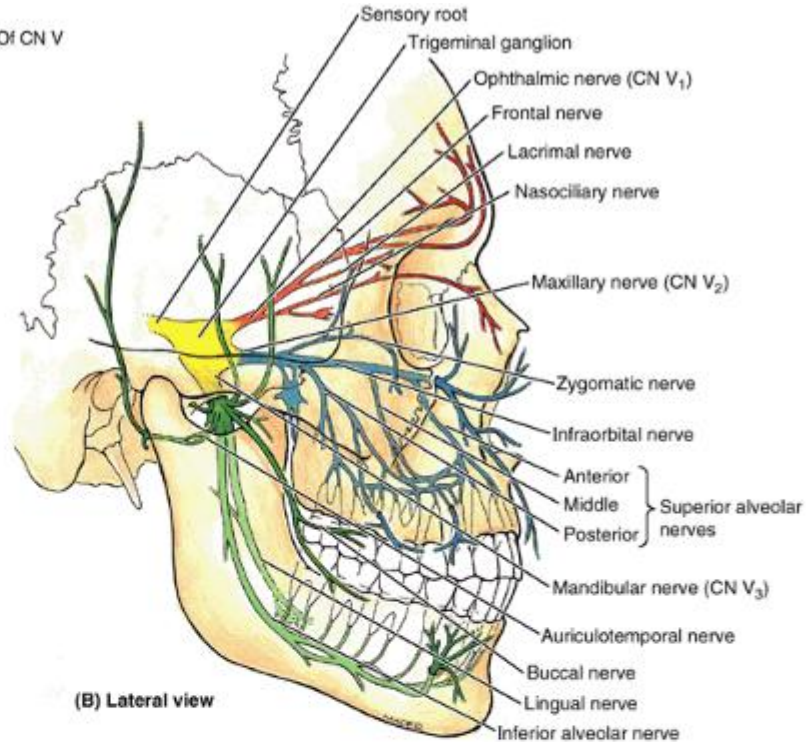
Note the topographical arrangement of the descending nucleus. Low pontine, medullary and cervical lesions produce a characteristic 'onion skin' distribution of pinprick and temperature loss. An ascending lesion spares the muzzle area until last.



Cranial nerves



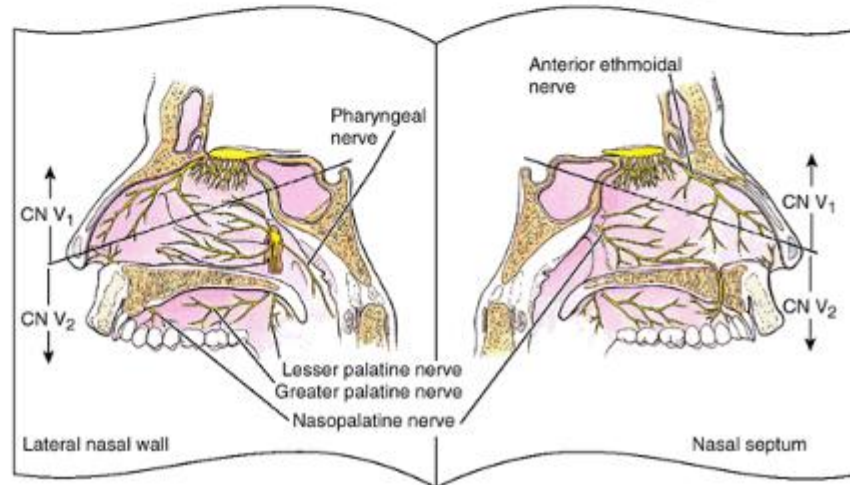
(A) Lateral view

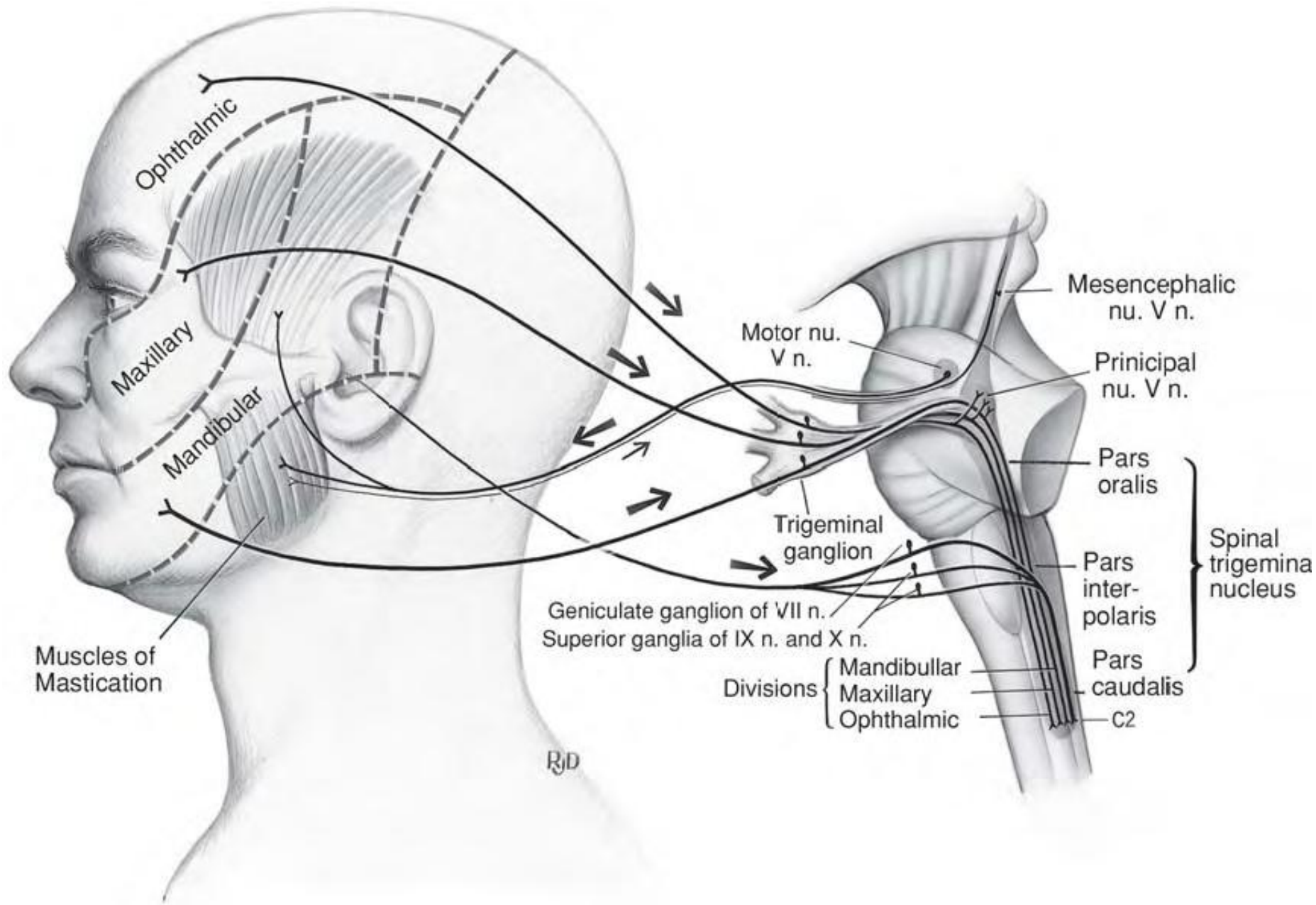


(B) Lateral view

Key	
	Ophthalmic nerve (CN V ₁)
	Maxillary nerve (CN V ₂)
	Mandibular nerve (CN V ₃)

(C) Open-book view





Ophthalmic

Maxillary

Mandibular

Muscles of Mastication

RJD

Motor nu. V n.

Trigeminal ganglion

Geniculate ganglion of VII n.
Superior ganglia of IX n. and X n.

Divisions {
Mandibular
Maxillary
Ophthalmic

Mesencephalic nu. V n.

Principal nu. V n.

Pars oralis

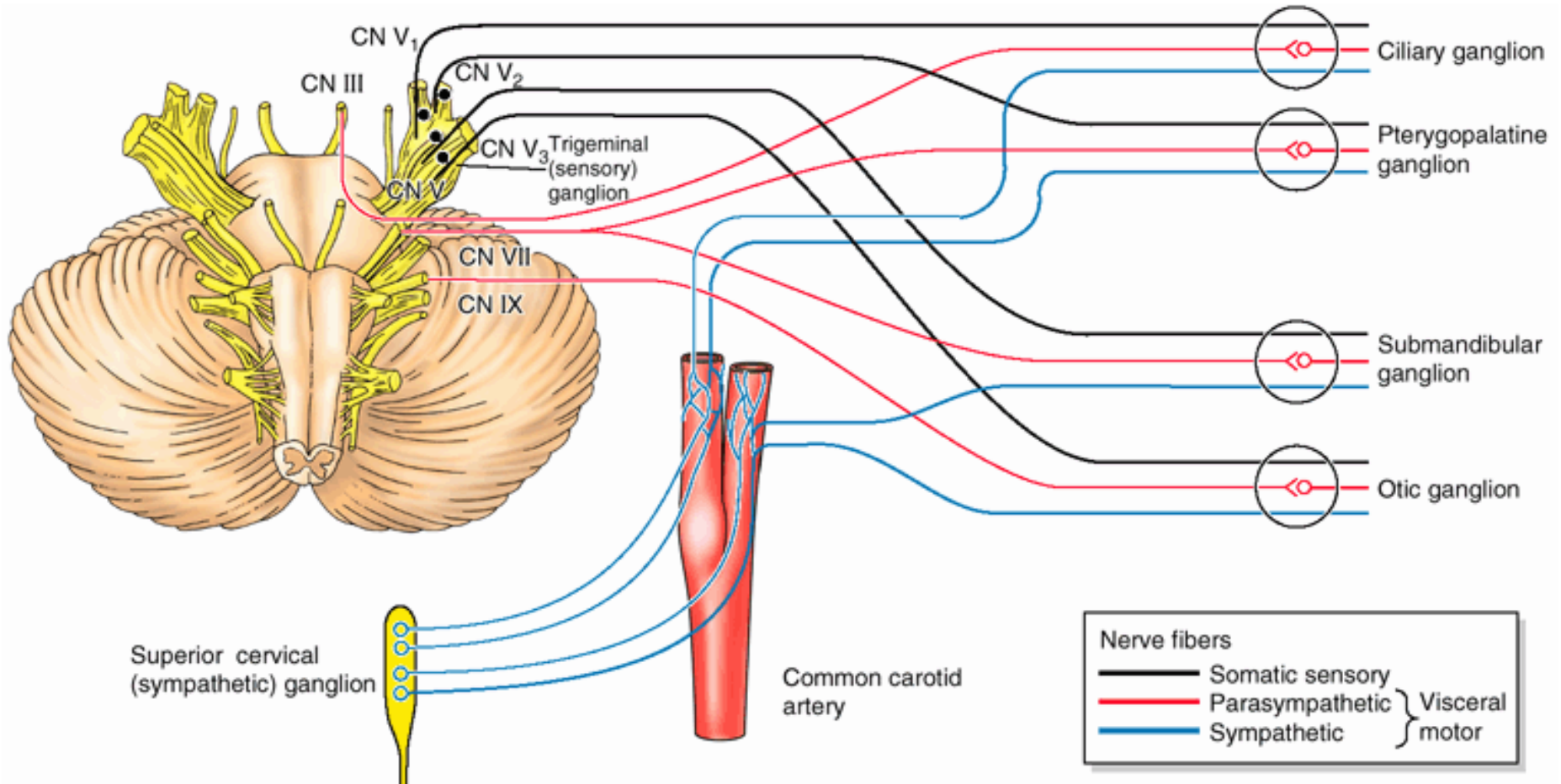
Pars inter-polaris

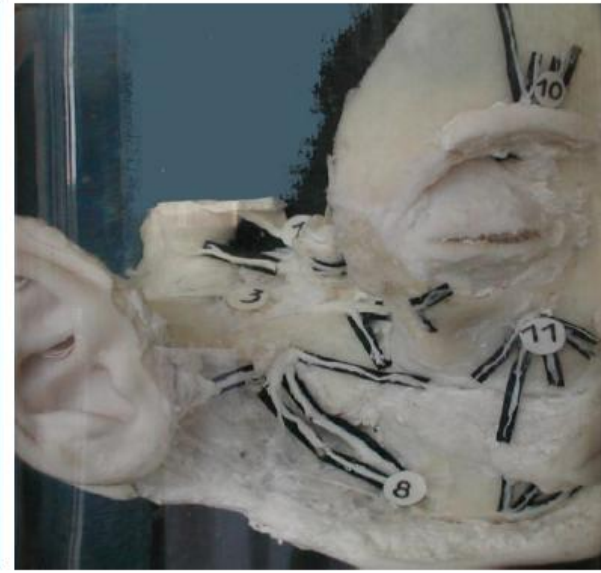
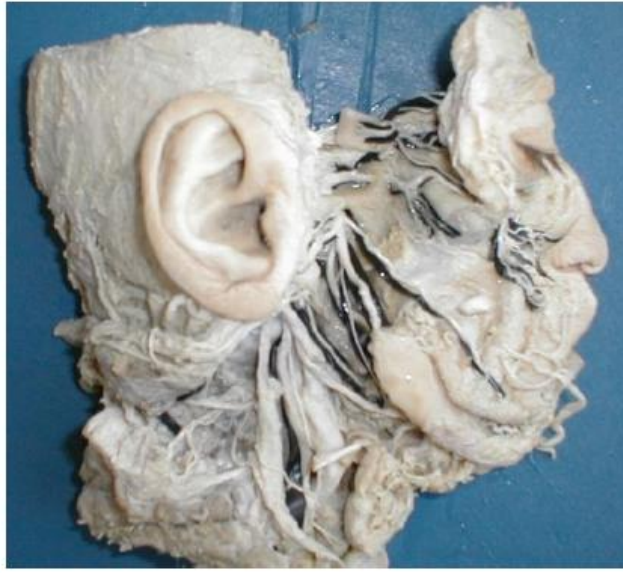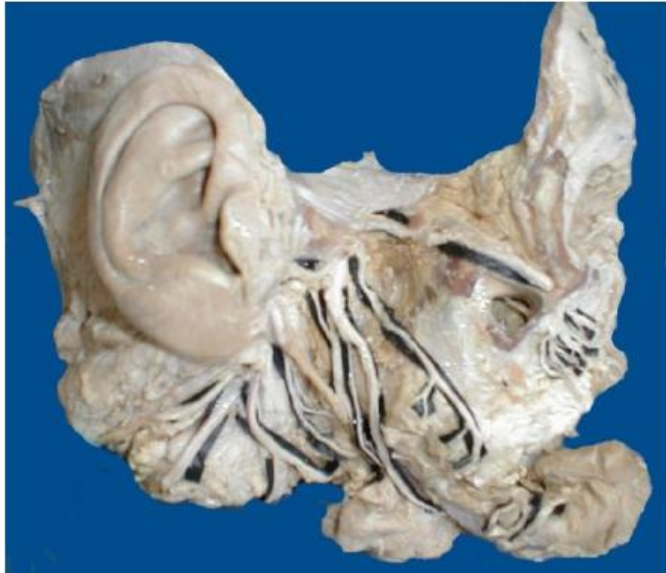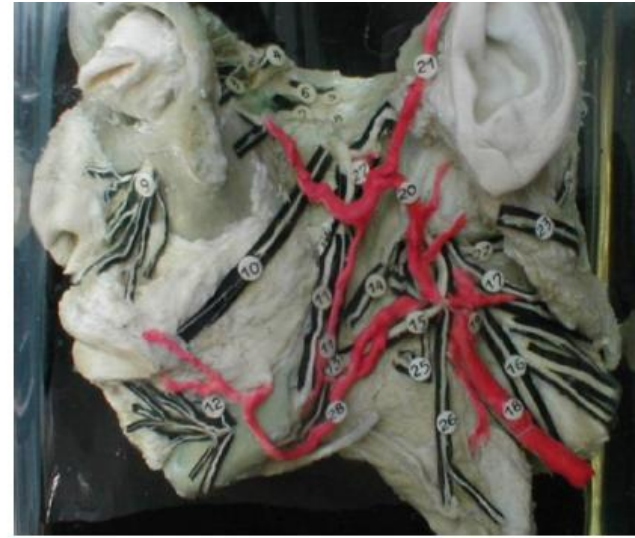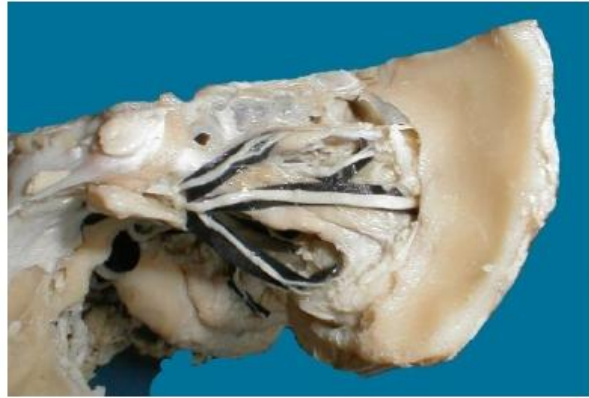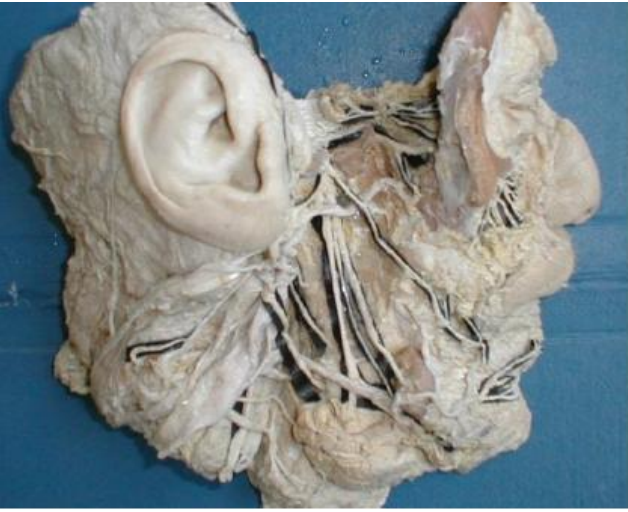Pars caudalis

Spinal trigemina nucleus

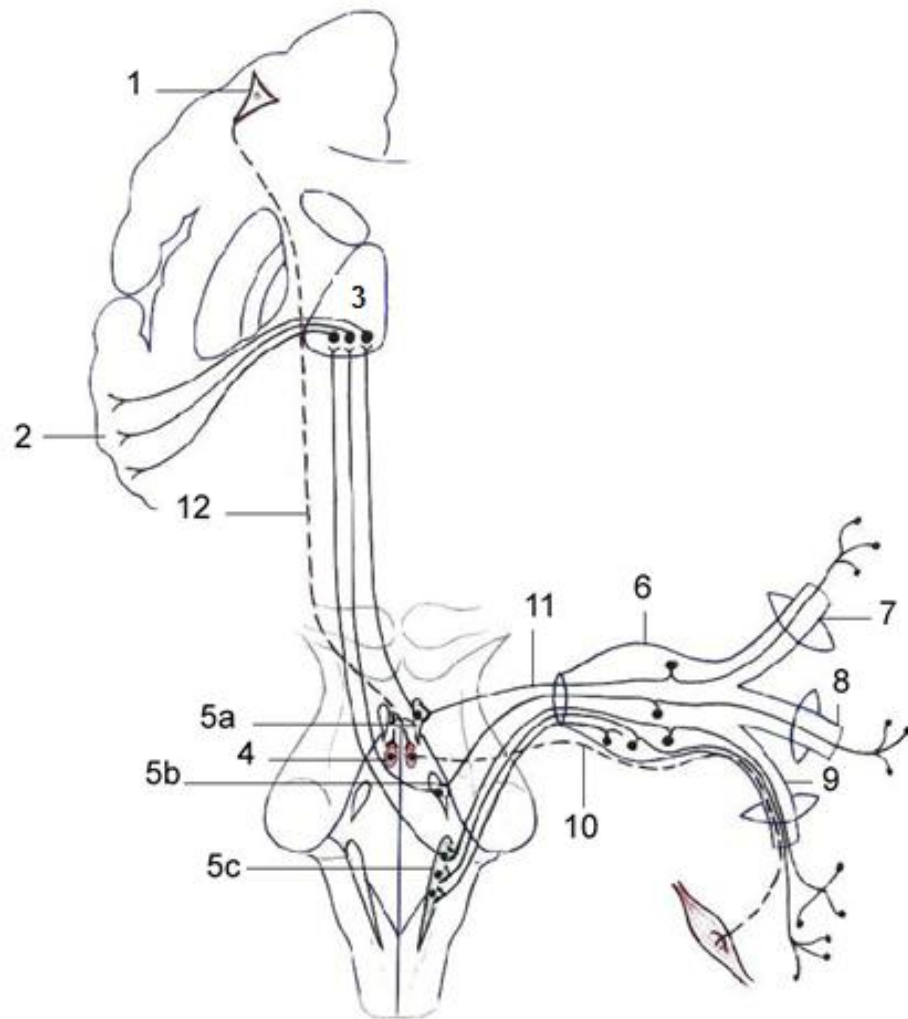
c2

Cranial nerves



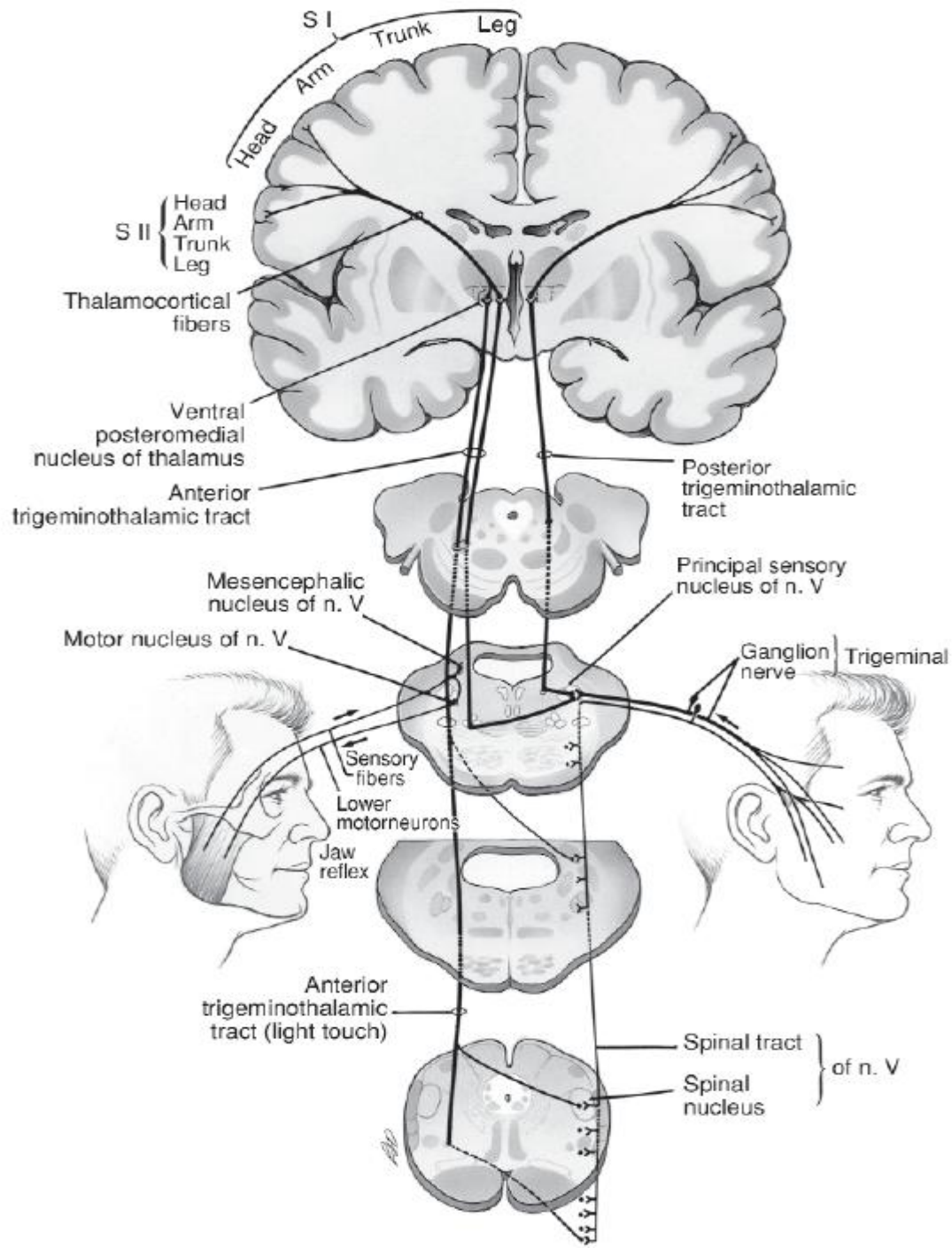


Conducting pathways of the trigeminal nerve (V)



1 – neuronum I (neurocytus pyramidalis magnus, Betz) (gyrus precentralis);
 2 – gyrus postcentralis;
 3 – neuronum III (thalamus opticus);
 4 – nucl. n. trigemini (V);
 5 – nuclei sensoriales n. trigemini (V);
 5a – nucl. mesencephalicus n. trigemini (V);
 5b – nucl. pontinus (V);

5c – nucl. spinalis nervi trigemini (V);
 6 – ganglion trigeminale (Gasser);
 7 – n. ophthalmicus;
 8 – n. maxillaris;
 9 – n. mandibularis;
 10 – radix motoria n. trigemini;
 11 – radix sensoria n. trigemini;
 12 – tractus corticonuclearis.



Cranial nerves

Facial Nerve (CN VII)

Functions: Sensory (special visceral afferent and general somatic afferent), motor (branchial motor or special visceral efferent), and parasympathetic (general visceral efferent). It also carries proprioceptive fibers from the muscles it innervates.

Nuclei: The motor nucleus of the facial nerve is a branchiomotor nucleus in the ventrolateral part of the pons. The cell bodies of the primary sensory neurons are in the geniculate ganglion. The central processes of those concerned with taste end in the nuclei of the solitary tract in the medulla. The processes of those concerned with general sensations (pain, touch, and thermal) from around the external ear end in the spinal nucleus of the trigeminal nerve.

The facial nerve (CN VII) emerges from the junction of the pons and medulla as two divisions, the motor root and the intermediate nerve. The **larger motor root** (facial nerve proper) innervates the muscles of facial expression, and the **smaller intermediate nerve** (L. nervus intermedius) carries taste, parasympathetic, and somatic sensory fibers. During its course, CN VII traverses the posterior cranial fossa, internal acoustic meatus, facial canal, stylomastoid foramen of the temporal bone, and parotid gland. After traversing the internal acoustic meatus, the nerve proceeds a short distance anteriorly within the temporal bone and then turns abruptly posteriorly to course along the medial wall of the tympanic cavity. The sharp bend is the geniculum of the facial nerve (L. genu, knee), sometimes called the external genu of CN VII, the site of the geniculate ganglion (sensory ganglion of CN VII). While traversing the temporal bone within the facial canal, CN VII gives rise to the: **Greater petrosal nerve. Nerve to the stapedius. Chorda tympani nerve.**

Then, after running the longest intraosseous course of any cranial nerve, CN VII emerges from the cranium via the stylomastoid foramen; gives off the posterior auricular branch; enters the parotid gland; and forms the **parotid plexus**, which gives rise to the following five terminal motor branches: **temporal, zygomatic, buccal, marginal mandibular, and cervical.**

Branchial Motor As the nerve of the 2nd pharyngeal arch, the facial nerve supplies striated muscles derived from its mesoderm, mainly the muscles of facial expression and auricular muscles. It also supplies the posterior bellies of the digastric, stylohyoid, and stapedius muscles.

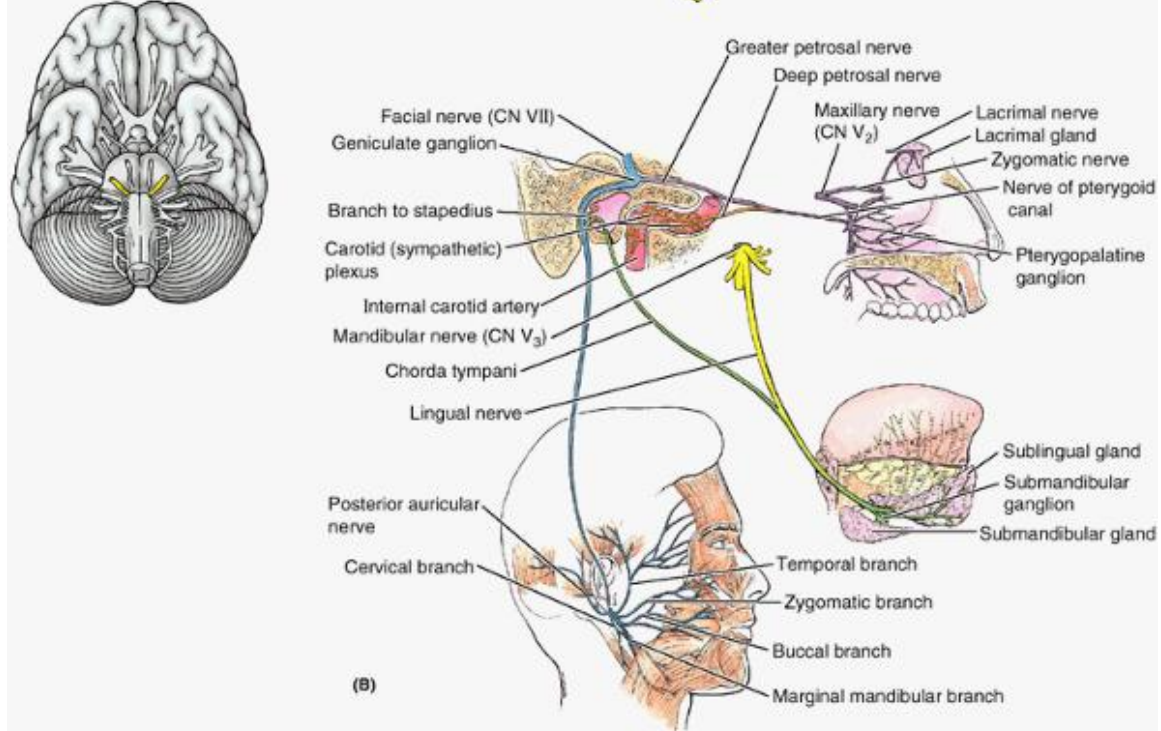
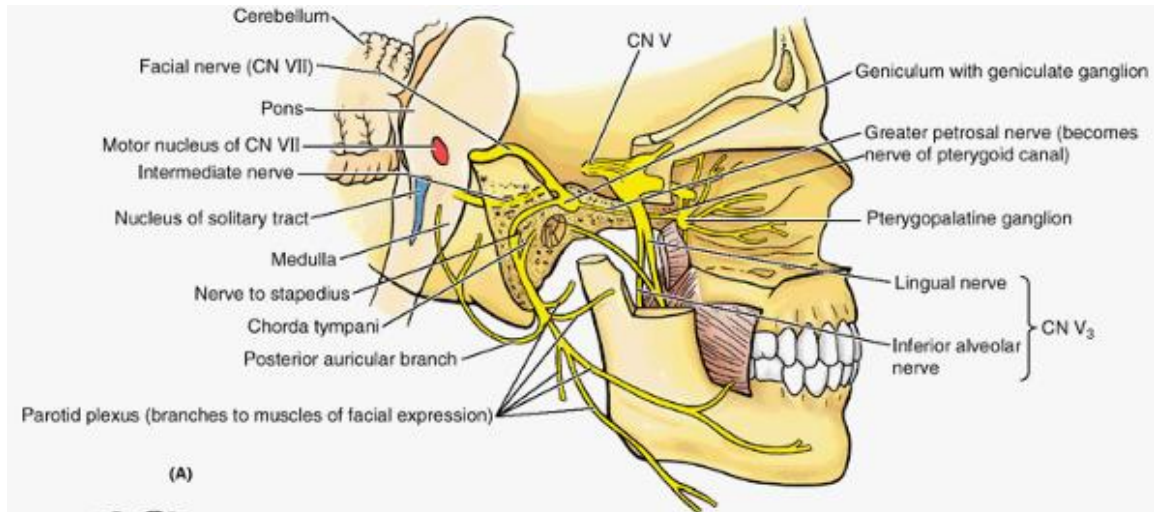
Presynaptic Parasympathetic

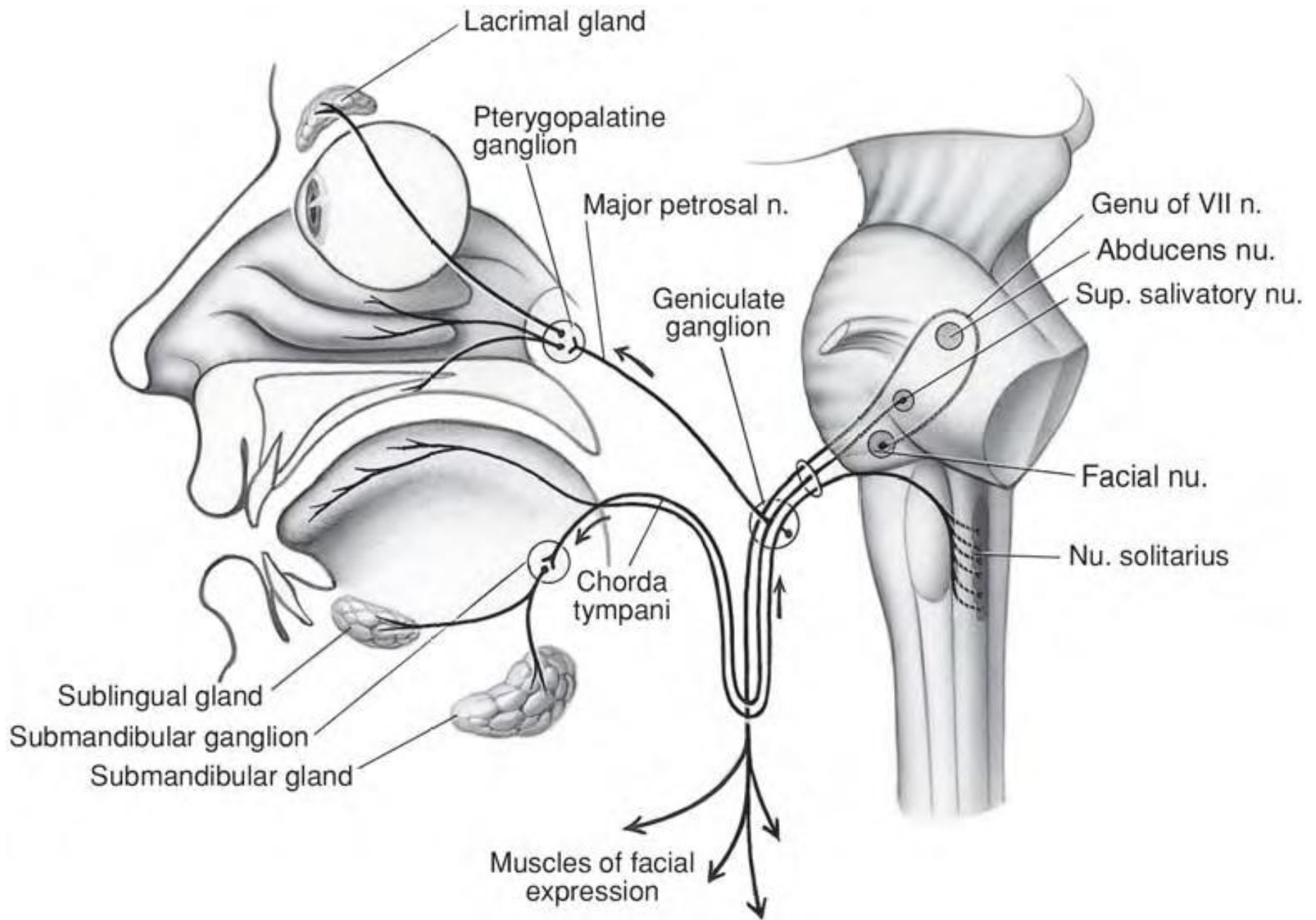
CN VII provides presynaptic parasympathetic fibers to the pterygopalatine ganglion for innervation of the lacrimal mucous glands and to the submandibular ganglion for innervation of the sublingual and submandibular salivary glands. The pterygopalatine ganglion is associated with the maxillary nerve (CN V₂), which distributes its postsynaptic fibers, whereas the submandibular ganglion is associated with the mandibular nerve (CN V₃). Parasympathetic fibers synapse in these ganglia, whereas sympathetic and other fibers pass through them.

General Sensory Some fibers from the geniculate ganglion supply a small area of the skin of the concha of the auricle, close to external acoustic meatus.

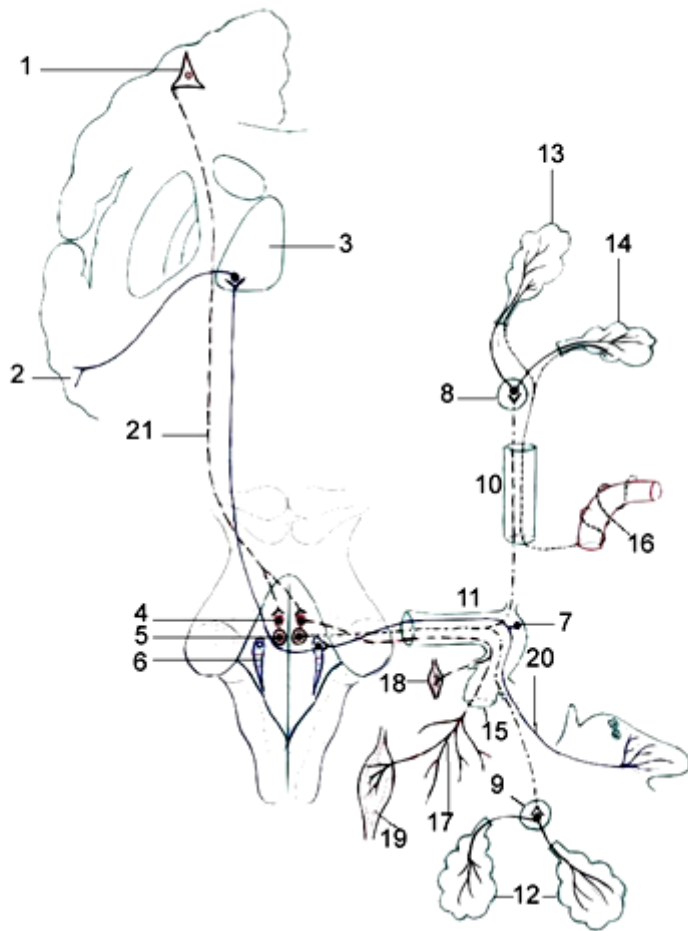
Taste (Special Sensory) Fibers carried by the chorda tympani join the lingual nerve to convey taste sensation from the anterior two thirds of the tongue and soft palate.

Cranial nerves

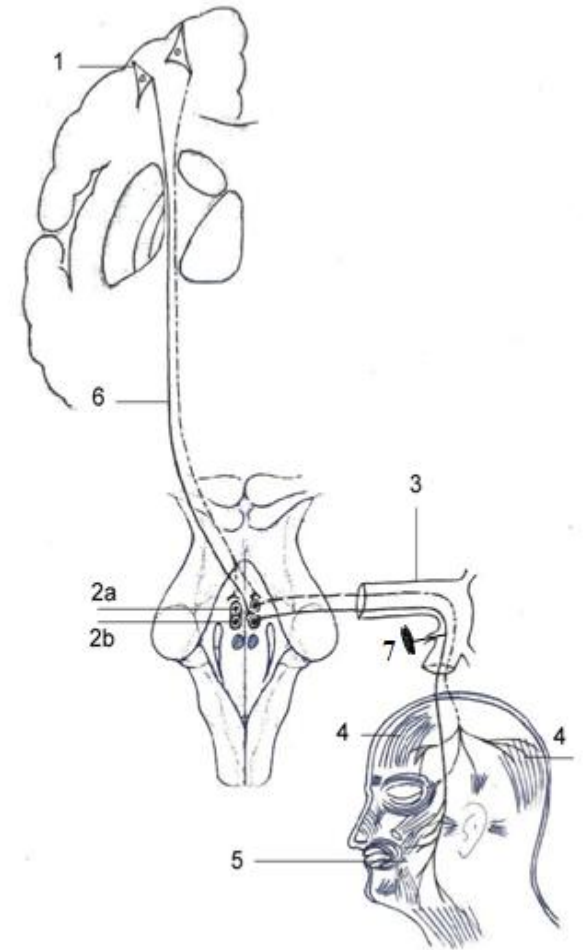




Conducting pathways of the facial nerve (VII)



Efferent, motor pathways of the facial nerve (VII)



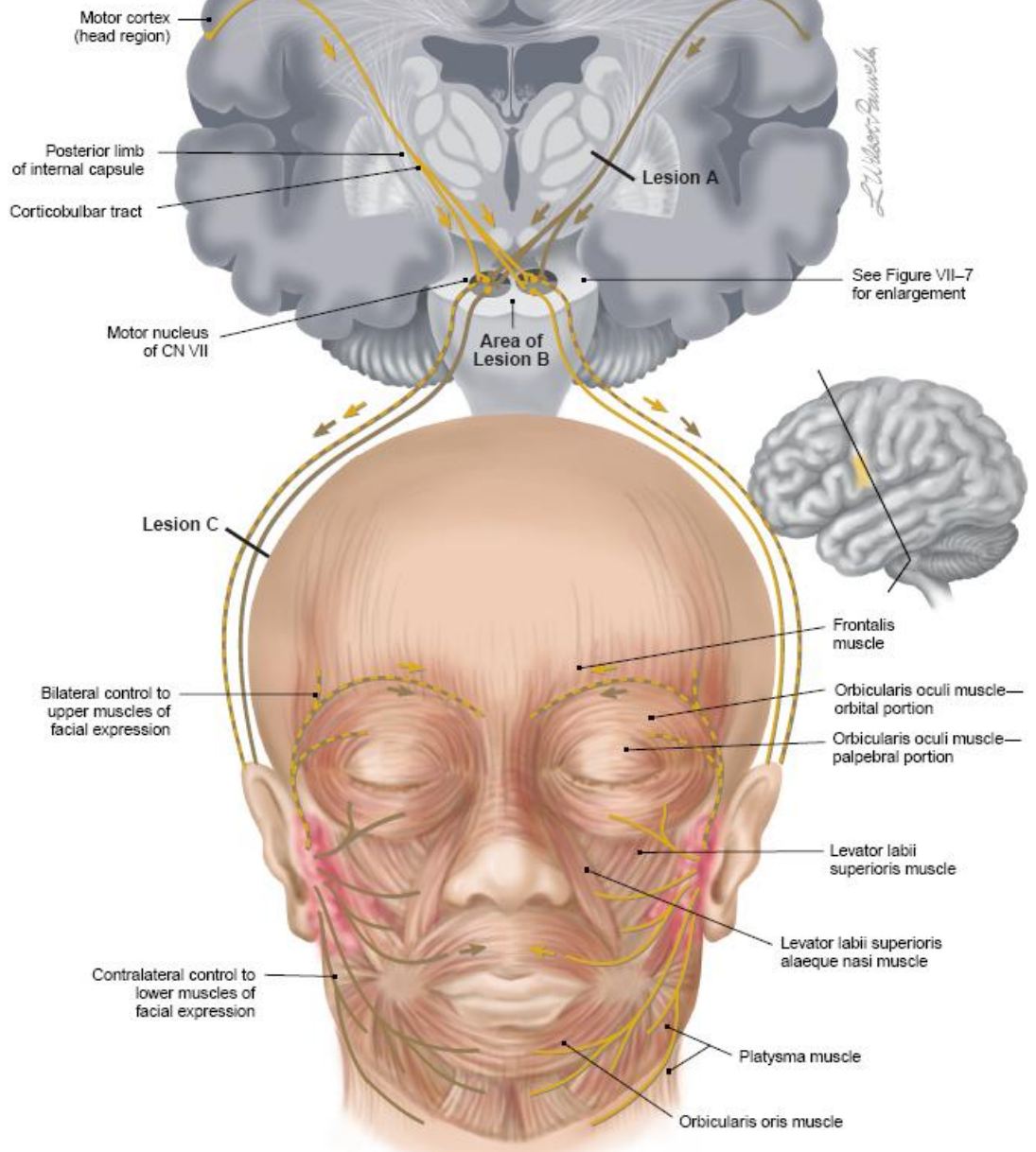
- 1 – neuronum I (neurocytus pyramidalis magnus, Betz) (gyrus precentralis);
- 2 – girus parahipocampalis et uncus;
- 3 – thalamus opticus;
- 4 – nucl. n. facialis (motorius) (neuronum II) (VII);
- 5 – n. salivatorius superior (VII);
- 6 – n. tractus solitarii (VII);
- 7 – ganglion geniculi;
- 8 – ganglion pterygopalatinum;
- 9 – ganglia submandibularia et sublingualia;
- 10 – canalis pterygoideus;

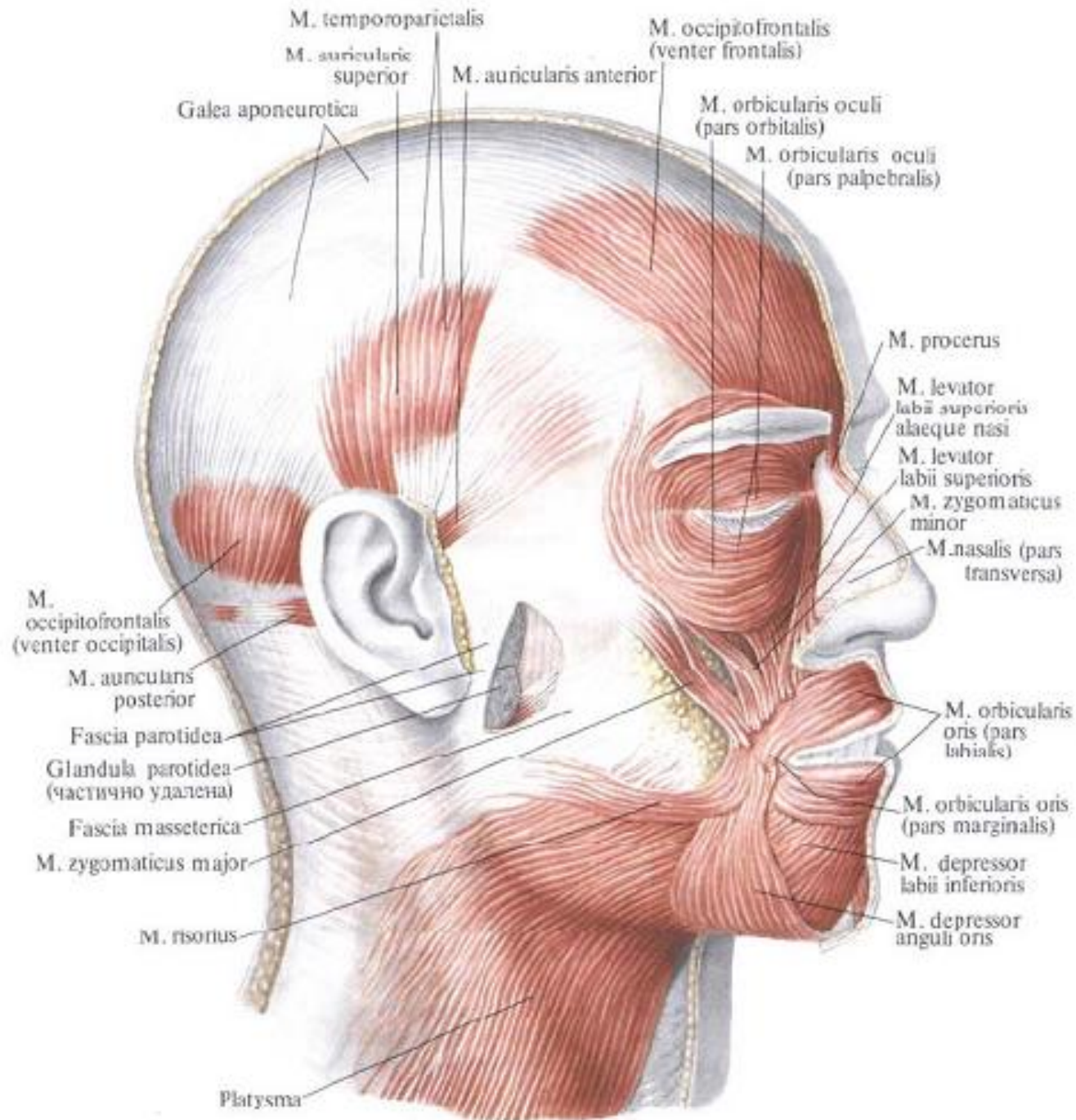
- 11 – canalis n. facialis (Fallopianus);
- 12 – glandulae sublingualis et submandibularis;
- 13 – glandula lacrimalis;
- 14 – glandulae nasales;
- 15 – foramen stylomastoideum;
- 16 – plexus caroticus internus;
- 17 – plexus parotideus;
- 18 – m. stapedius;
- 19 – mm. faciei;
- 20 – chorda tympani;
- 21 – tractus corticonuclearis.

- 1 – neuronum I (neurocytus pyramidalis magnus, Betz) (gyrus precentralis);
- 2 – neuronum II (nucl. n. facialis, motorius) (VII);
- 2a – pars superior;
- 2b – pars inferior;

- 3 – canalis n. facialis;
- 4 – mm. faciei superiores;
- 5 – mm. faciei inferiores;
- 6 – tractus corticonuclearis;
- 7 – m. stapedius.

© L. Wilson-Pauwels







Occipitofrontalis



Corrugator supercilii



Procerus + transverse part of nasalis



Orbicularis oculi



Lev. labii sup. alaeque nasi + alar part of nasalis



Buccinator + orbicularis oris




Zygomaticus major + minor



Risorius



Risorius + depressor labii inferioris



Levator labii superioris + depressor labii



Dilators of mouth:
Risorius plus levator labii superioris + depressor labii inferioris



Orbicularis oris



Depressor anguli oris



Mentalis



Platysma



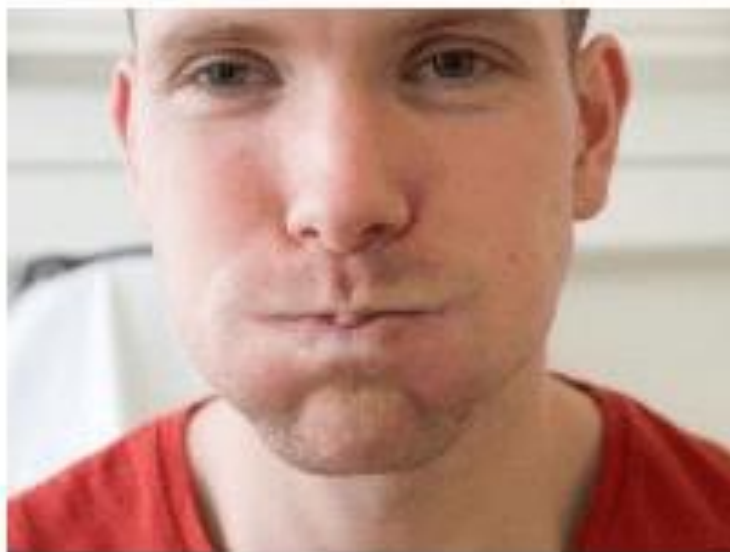Crease up the forehead



Keep eyes closed against resistance



Reveal the teeth



Puff out the cheeks

Format: Abstract ▾

Send to ▾

Neurosci Biobehav Rev. 2014 Jan;38:135-59. doi: 10.1016/j.neubiorev.2013.11.002. Epub 2013 Nov 12.

The facial motor system.

Cattaneo L¹, Pavesi G².

Author information

- 1 Center for Mind/Brain Sciences, University of Trento, Via delle Regole 101, Mattarello, Trento 38123, Italy. Electronic address: luigi.cattaneo@unitn.it.
- 2 Department of Neuroscience, University of Parma, Via Gramsci 14, Parma 43100, Italy.

Abstract

Facial movements support a variety of functions in human behavior. They participate in automatic somatic and visceral motor programs, they are essential in producing communicative displays of affective states and they are also subject to voluntary control. The multiplicity of functions of facial muscles, compared to limb muscles, is reflected in the heterogeneity of their anatomical and histological characteristics that goes well beyond the conventional classification in single facial muscles. Such parcellation in different functional muscular units is maintained throughout the central representation of facial movements from the brainstem up to the neocortex. Facial movements peculiarly lack a conventional proprioceptive feedback system, which is only in part vicariated by cutaneous or auditory afferents. Facial motor activity is the main marker of endogenous affective states and of the affective valence of external stimuli. At the cortical level, a complex network of specialized motor areas supports voluntary facial movements and, differently from upper limb movements, in such network there does not seem to be a prime actor in the primary motor cortex.

Copyright © 2013 Elsevier Ltd. All rights reserved.

KEYWORDS: Blink; Eyelids; Face; Facial palsy; Lip; Motor control; Mouth; Proprioception; Voluntary movements

PMID: 24239732 DOI: [10.1016/j.neubiorev.2013.11.002](https://doi.org/10.1016/j.neubiorev.2013.11.002)

[Indexed for MEDLINE]

Cranial nerves

Vestibulocochlear Nerve (CN VIII)

Functions: Special sensory (special somatic afferent) that is, special sensations of hearing and equilibrium.

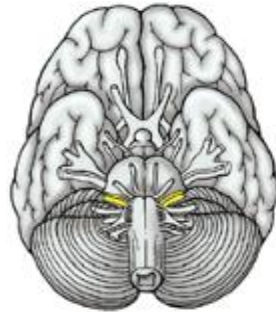
Nuclei: Four vestibular nuclei are located at the junction of the pons and medulla in the lateral part of the floor of the 4th ventricle; two cochlear nuclei are in the medulla.

The vestibulocochlear nerve (CN VIII) emerges from the junction of the pons and medulla and enters the internal acoustic meatus. Here it separates into the vestibular and cochlear nerves.

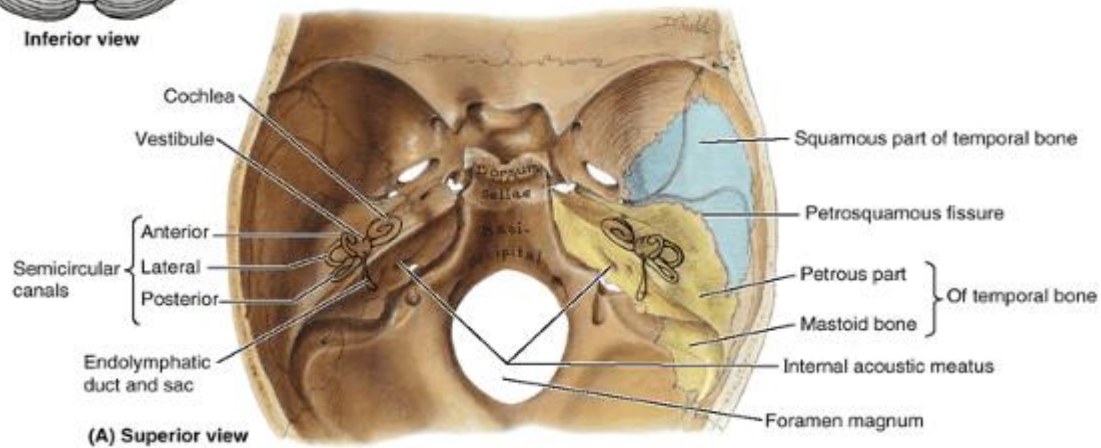
The **vestibular nerve** is concerned with equilibrium. It is composed of the central processes of bipolar neurons in the vestibular ganglion; the peripheral processes of the neurons extend to the maculae of the utricle and saccule (sensitive to the line of linear acceleration relative to the position of the head) and to the ampullae of the semicircular ducts (sensitive to rotational acceleration).

The **cochlear nerve** is concerned with hearing. It is composed of the central processes of bipolar neurons in the spiral ganglion; the peripheral processes of the neurons extend to the spiral organ.

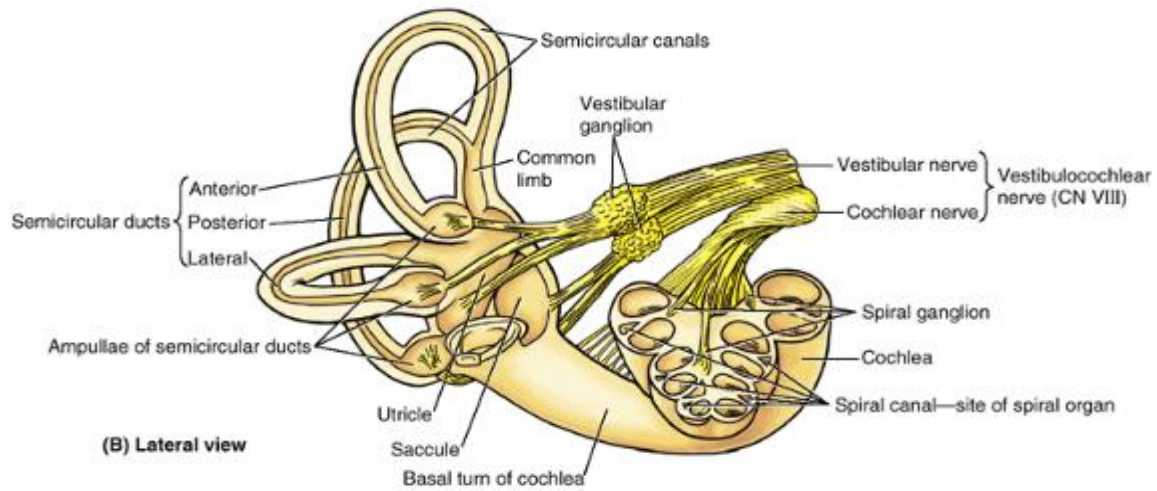
Cranial nerves



Inferior view

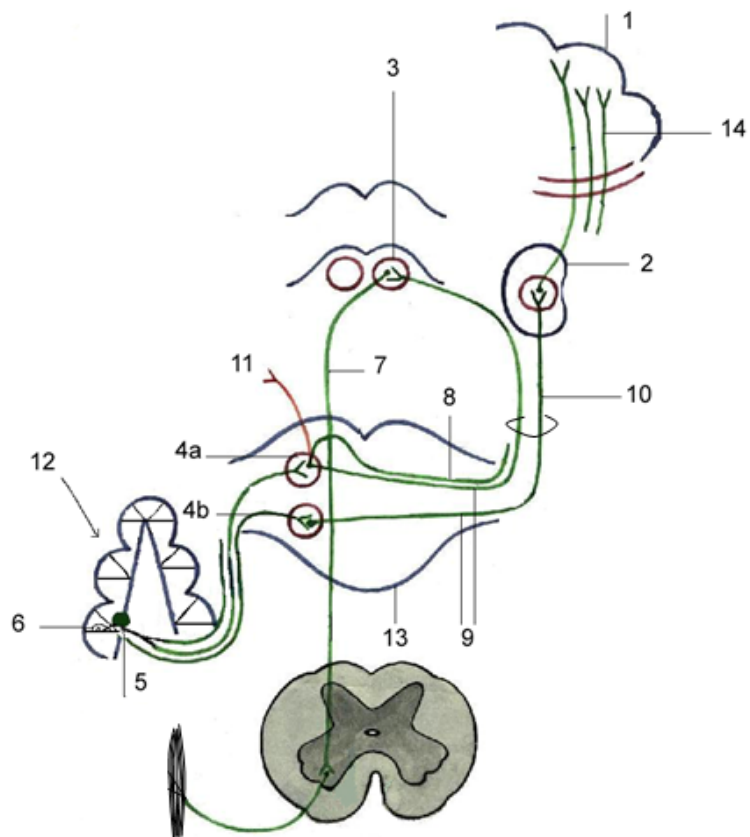


(A) Superior view



(B) Lateral view

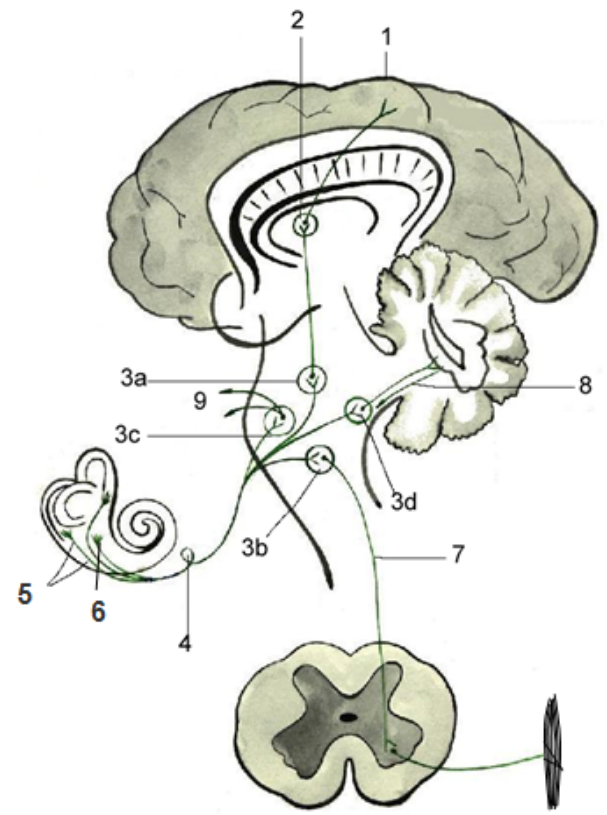
Conducting pathways of the auditory analyzer



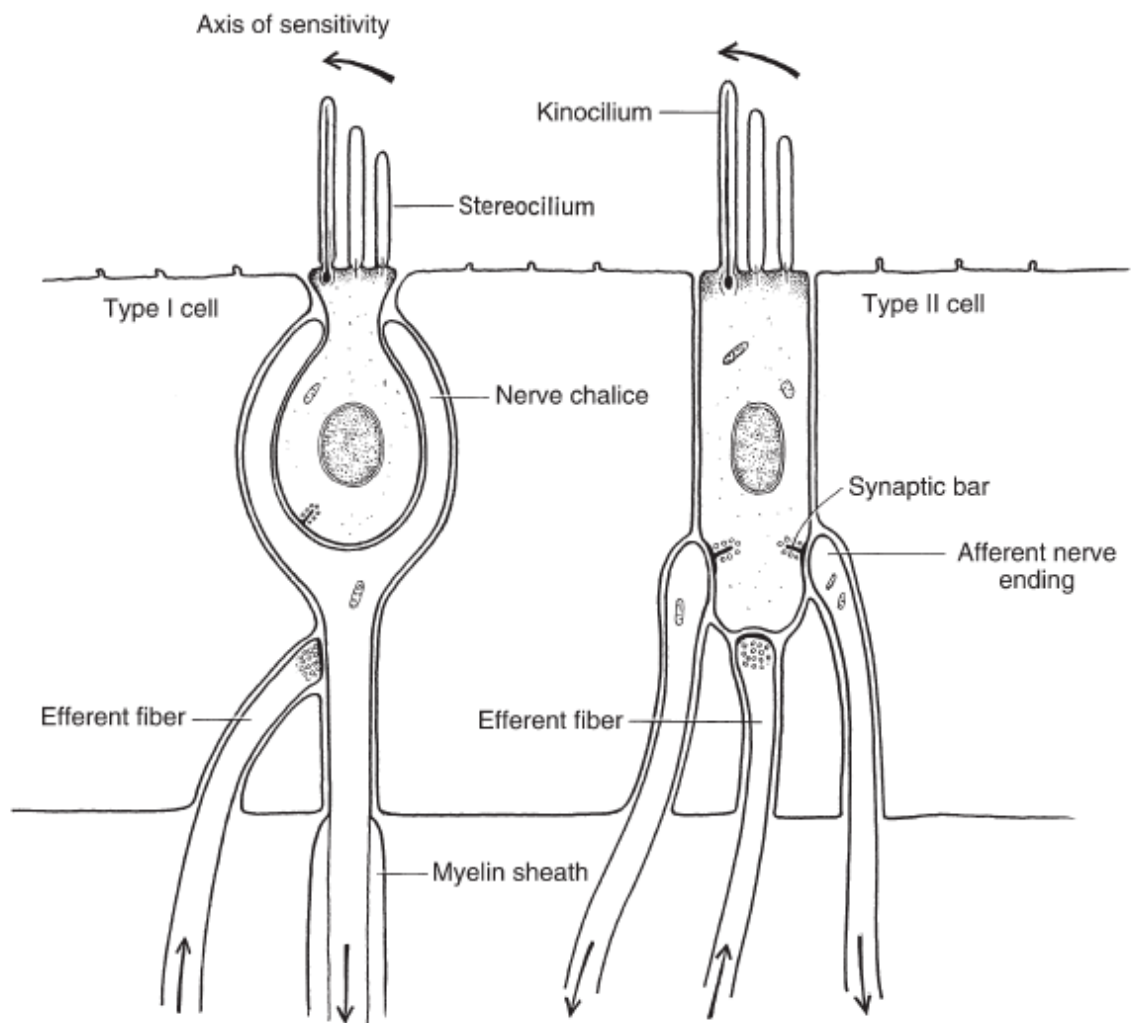
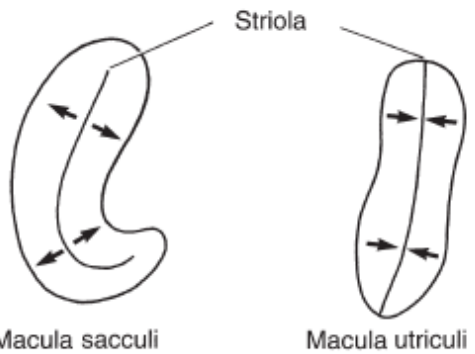
- 1 – gyri temporales transversi (Heschl) (gyrus temporalis superior);
- 2 – neuronum III (corpus geniculatum mediale);
- 3 – neuronum III (colliculus inferior tecti mesencephali);
- 4 – neuronum II (nuclei partes cochlearis n. vestibulocochlearis);
- 4a – nucleus dorsalis;
- 4b – nucleus ventralis;
- 5 – neuronum I [ganglion spirale (Corti)];

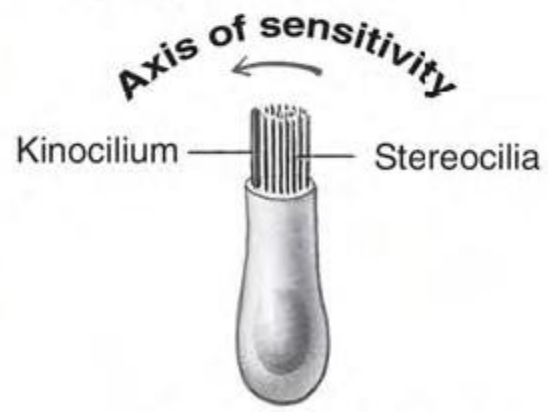
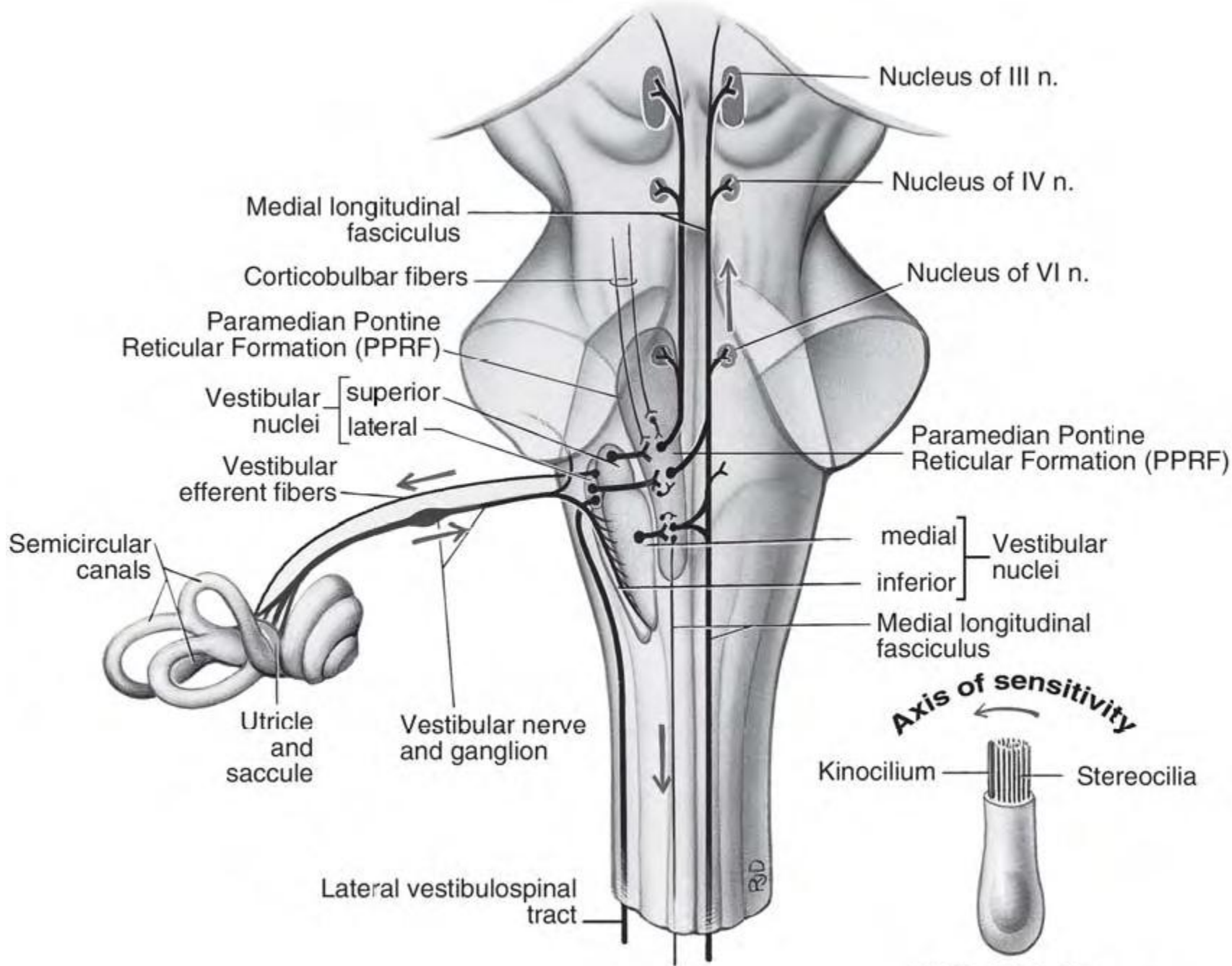
- 6 – organum Corti (epitheliocytus neurosensorius);
- 7 – tractus tectospinalis;
- 8 – striae medullares;
- 9 – corpus trapezoideum;
- 10 – lemniscus lateralis;
- 11 – conexiones ad nervos III, IV, VI;
- 12 – cochlea (labirintus osseus);
- 13 – pons Varolio;
- 14 – radiatio acustica.

Conducting pathways of the vestibular analyzer



- 1 – lobus temporalis;
- 2 – neuronum III (thalamus opticus);
- 3 – neuronum II (nuclei vestibulares n. vestibulocochlearis);
- a – superior (Bexmepes);
- b – inferior (Roller);
- c – lateralis (Deiters);
- d – medialis (Schwalbe);
- 4 – ganglion vestibulare (Scarpa) (neuronum I);
- 5 – cristae ampullares ductuum semicircularium;
- 6 – macula utriculi et macula sacculi;
- 7 – tractus vestibulospinalis (Levental);
- 8 – tractus vestibulocerebellaris et tractus cerebellovestibularis;
- 9 – conexiones ad nervos craniales IX, X et III, IV, VI.





HAIR CELL OF VESTIBULAR SYSTEM

Cranial nerves

Glossopharyngeal Nerve (CN IX)

Functions: Sensory (general somatic afferent, special visceral afferent, general visceral afferent), motor (special visceral efferent), and parasympathetic (general visceral efferent) for derivatives of the 3rd pharyngeal arch.

Nuclei: Four nuclei in the medulla send or receive fibers via CN IX: two motor and two sensory. Three of these nuclei are shared with CN X.

The glossopharyngeal nerve (CN IX) emerges from the lateral aspect of the medulla and passes anterolaterally to leave the cranium through the anterior aspect of the jugular. At this foramen are **superior and inferior (sensory) ganglia**, which contain the pseudounipolar cell bodies for the afferent components of the nerve. CN IX follows the **stylopharyngeus, the only muscle** the nerve supplies, and passes between the superior and the middle constrictor muscles of the pharynx to reach the oropharynx and tongue. It contributes sensory fibers to the pharyngeal plexus of nerves.

CN IX is afferent from the tongue and pharynx (hence its name) and efferent to the stylopharyngeus and parotid gland.

Branchial Motor Motor fibers pass to one muscle, the stylopharyngeus, derived from the 3rd pharyngeal arch.

Parasympathetic (Visceral Motor)

Following a circuitous route initially involving the tympanic nerve, presynaptic parasympathetic fibers are provided to the otic ganglion for innervation of the parotid gland. The otic ganglion is associated with the mandibular nerve (CN V₃), branches of which convey the postsynaptic parasympathetic fibers to the parotid gland .

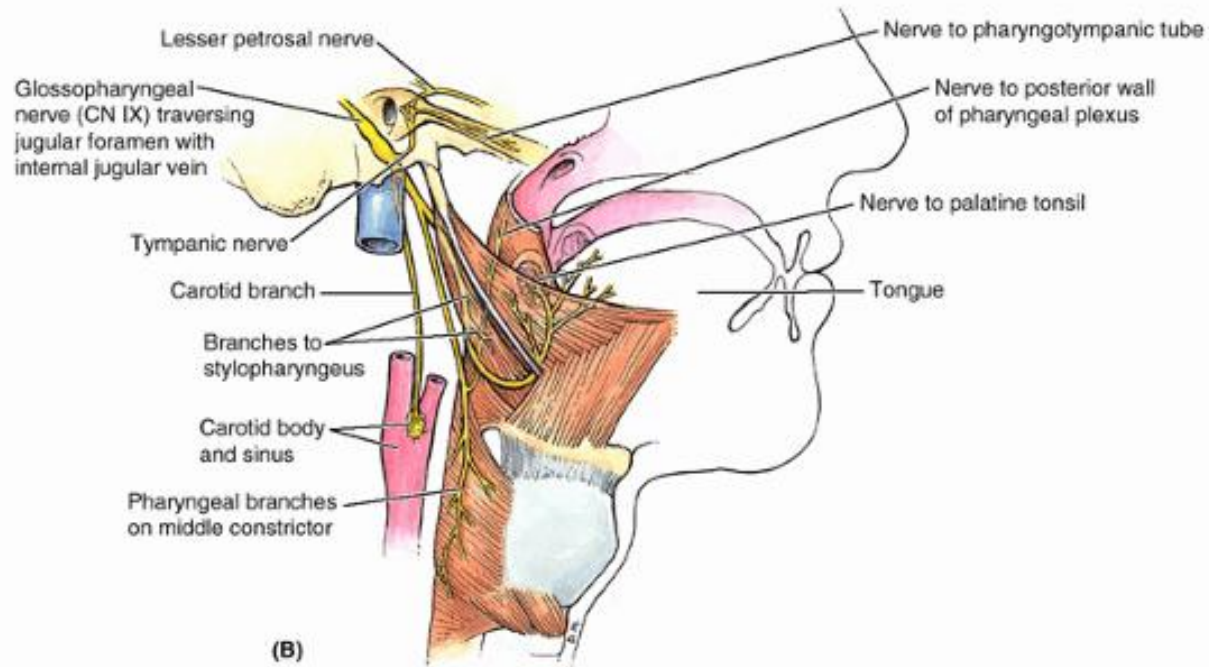
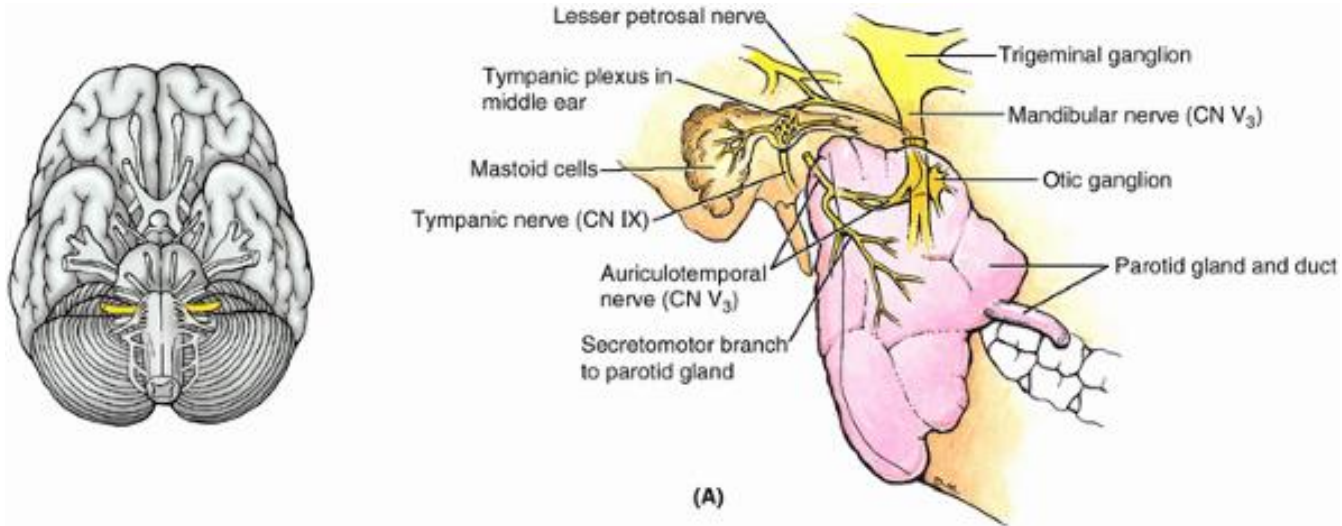
Sensory (General Sensory)

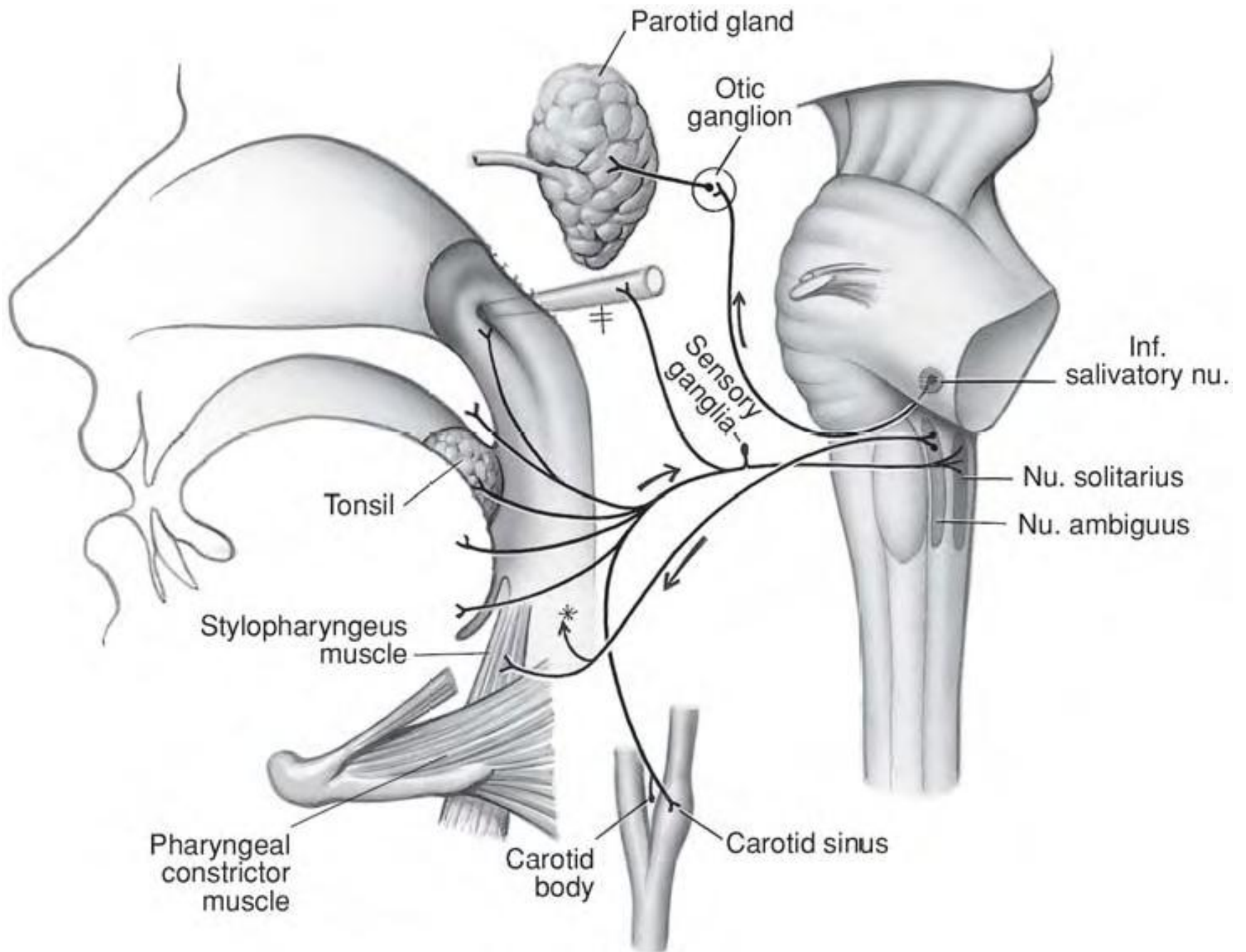
The general sensory branches of CN IX are as follows : **The tympanic nerve. The carotid sinus nerve** to the carotid sinus, a baro- (presso) receptor sensitive to changes in blood pressure, and the carotid body, a chemoreceptor sensitive to blood gas (oxygen and carbon dioxide levels).

The pharyngeal, tonsillar, and lingual nerves to the mucosa of the oropharynx and isthmus of the fauces (L. throat), including palatine tonsil, soft palate, and posterior third of the tongue. In addition to general sensation (touch, pain, temperature), tactile (actual or threatened) stimuli determined to be unusual or unpleasant here may evoke the gag reflex or even vomiting.

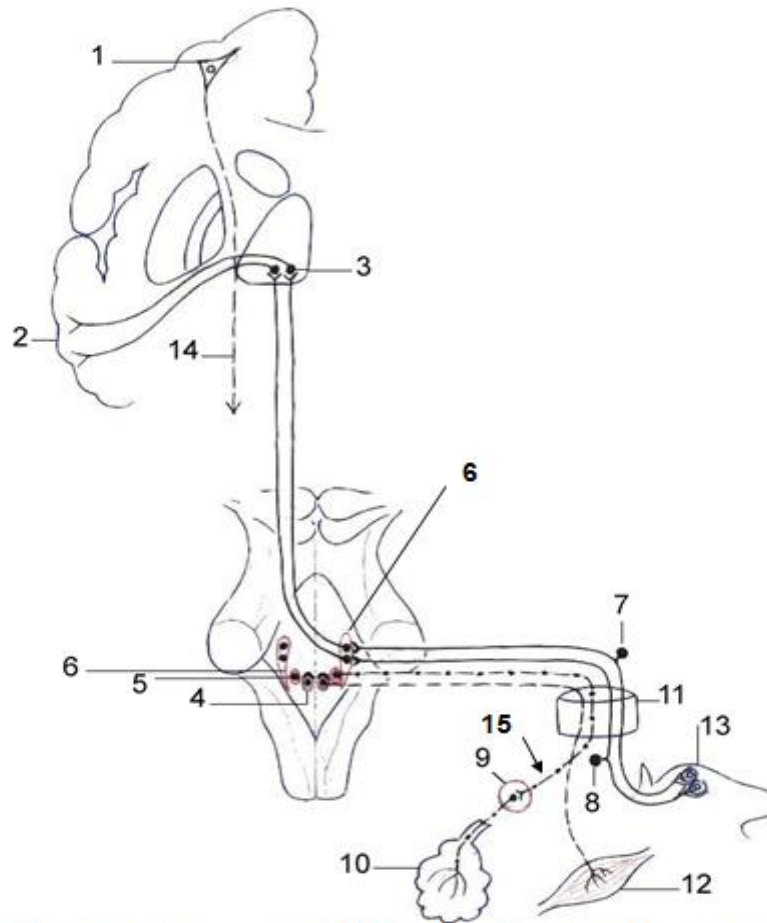
Taste (Special Sensory) Taste fibers are conveyed from the posterior third of the tongue to the sensory ganglia.

Cranial nerves





Conducting pathways of the glossopharyngeal nerve (IX)



- 1 – neuronum I (motorium) (gyrus precentralis, neurocytus pyramidalis magnus, Betz);
- 2 – uncus et gyrus postcentralis;
- 3 – neuronum III (thalamus opticus);
- 4 – neuronum II (motorium) (nucleus ambiguus);
- 5 – nucleus salivatorius inferior (neuronum I);
- 6 – neuronum II (sensitivum) (nucleus tractus solitarii);
- 7 – neuronum I (sensitivum) (ganglion superius);
- 8 – neuronum I (sensitivum) (ganglion inferius, nodosum);
- 9 – ganglion oticum (neuronum II);
- 10 – glandula parotis;
- 11 – foramen jugulare;
- 12 – ramus musculi stylopharyngei;
- 13 – 1/3 posterior linguae (papillae valatae);
- 14 – tractus corticonuclearis;
- 15 – nervus tympanicus.

Cranial nerves

Vagus Nerve (CN X)

Functions: Sensory (general somatic afferent, special visceral afferent, general visceral afferent), motor (special visceral efferent), and parasympathetic (general visceral efferent).

Sensory from the inferior pharynx, larynx, and thoracic and abdominal organs.

Sense of taste from the root of the tongue and taste buds on the epiglottis. Branches of the internal laryngeal nerve (a branch of CN X) supply a small area, mostly general but some special sensation; most general and special sensation to the root is supplied by CN IX.

Motor to the soft palate; pharynx; intrinsic laryngeal muscles (phonation); and a nominal extrinsic tongue muscle, the palatoglossus, which is actually a palatine muscle based on its derivation and innervation.

Proprioceptive to the muscles listed above.

Parasympathetic to thoracic and abdominal viscera.

Nuclei: Four nuclei of CN X in the medulla send or receive fibers via CN IX two motor and two sensory. Three of these nuclei are shared with CN IX.

The vagus nerve (CN X) has the longest course and most extensive distribution of all the cranial nerves, most of which is outside of (inferior to) the head. The term vagus is derived from the Latin word *vagari* meaning **wandering**. CN X was so called because of its extensive distribution. It arises by a series of rootlets from the lateral aspect of the medulla that merge and leave the cranium through the jugular foramen positioned between CN IX and CN XI.

What was formerly called the cranial root of the accessory nerve is actually a part of CN X.

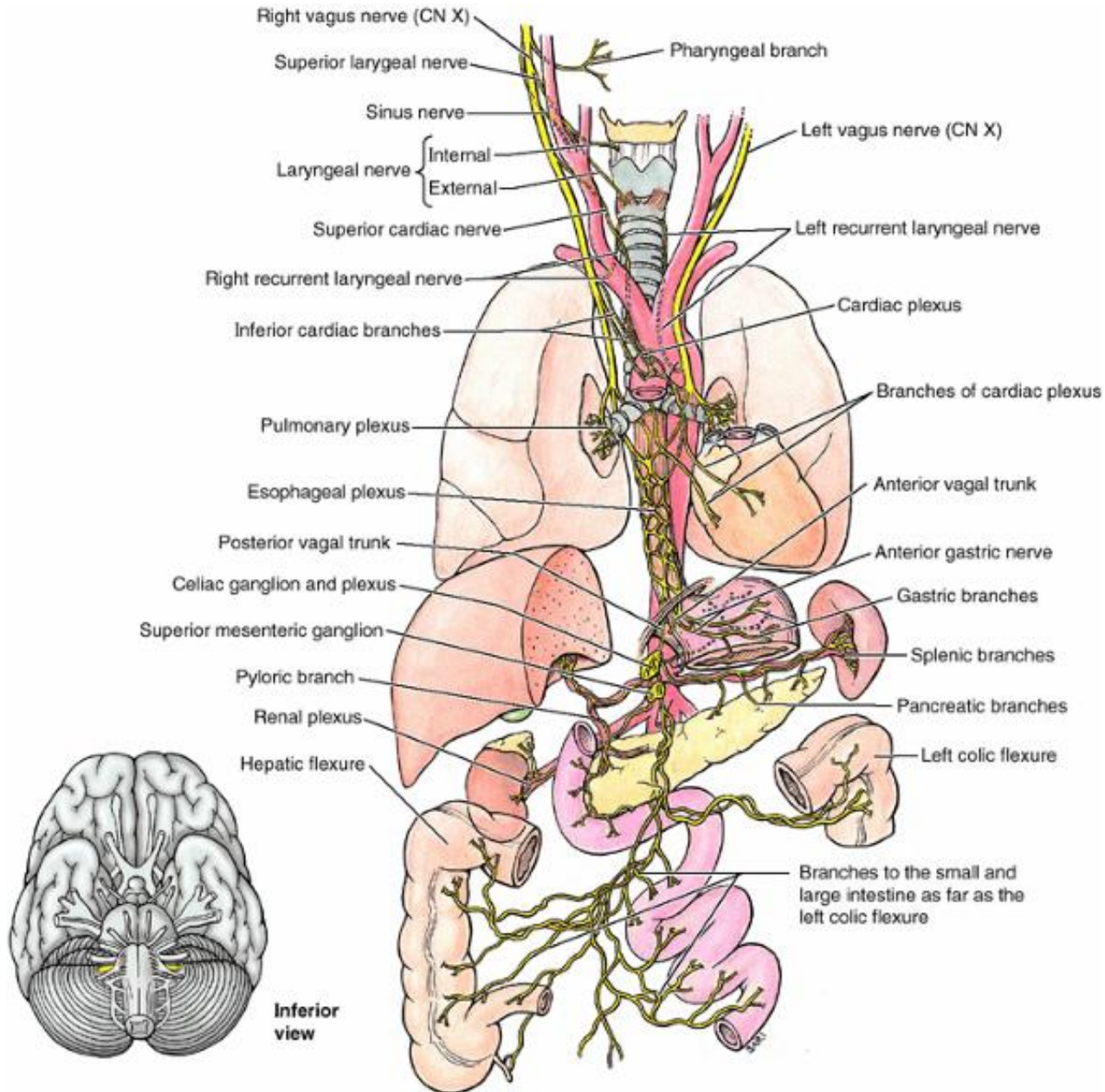
CN X has a **superior ganglion** in the jugular foramen that is mainly concerned with the general sensory component of the nerve. Inferior to the foramen is an inferior ganglion (nodose ganglion) concerned with the visceral sensory components of the nerve. In the region of the superior ganglion are connections to CN IX and the superior cervical (sympathetic) ganglion. CN X continues inferiorly in the carotid sheath to the root of the neck, supplying branches to the palate, pharynx, and .

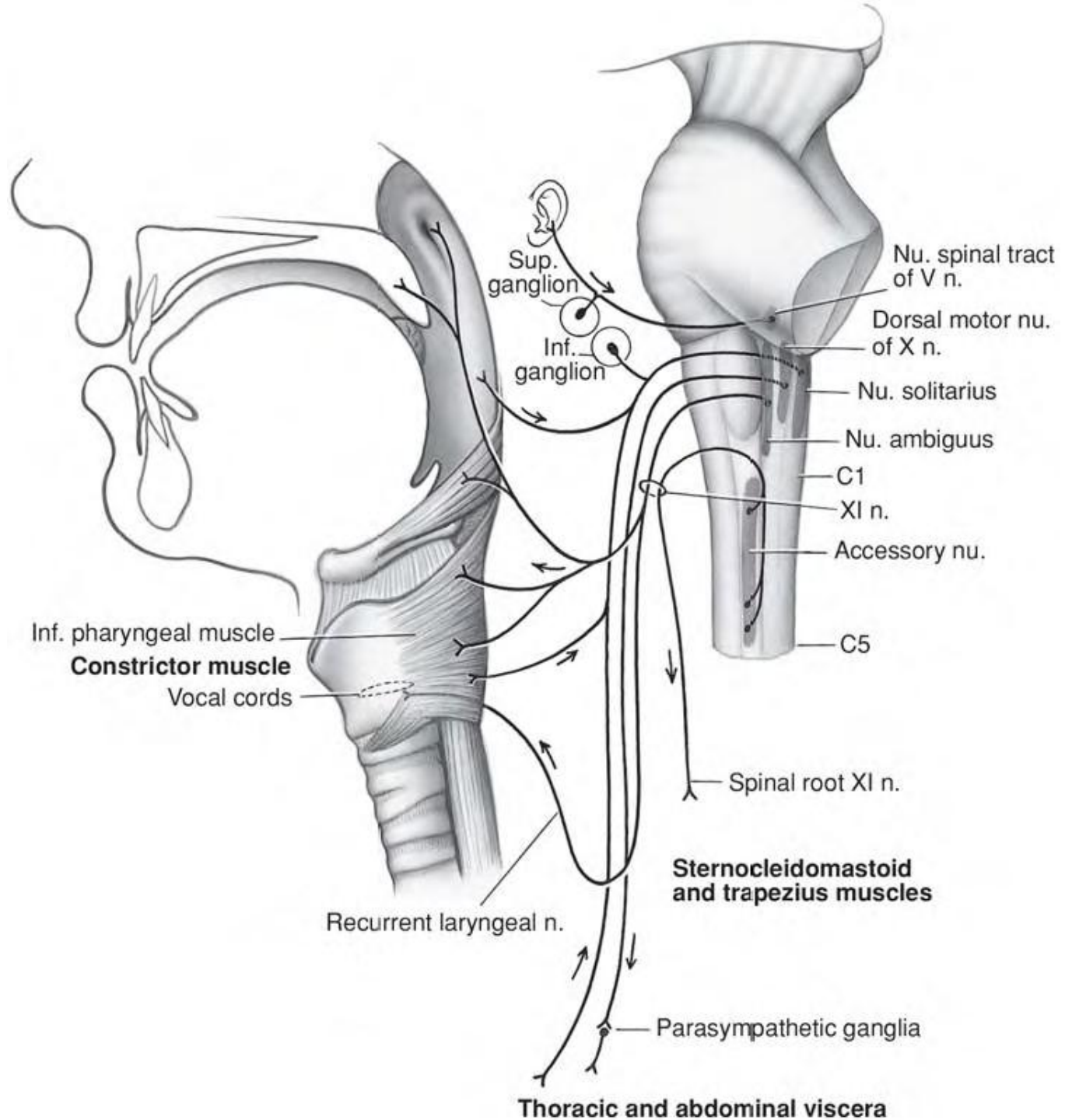
The course of CN X in the thorax differs on the two sides, a consequence of rotation of the midgut during development. CN X supplies branches to the heart, bronchi, and lungs. The vagi join the esophageal plexus surrounding the esophagus, which is formed by branches of the vagi and sympathetic trunks. This plexus follows the esophagus through the diaphragm into the abdomen, where the anterior and posterior vagal trunks break up into branches that innervate the esophagus, stomach, and intestinal tract as far as the left colic flexure.

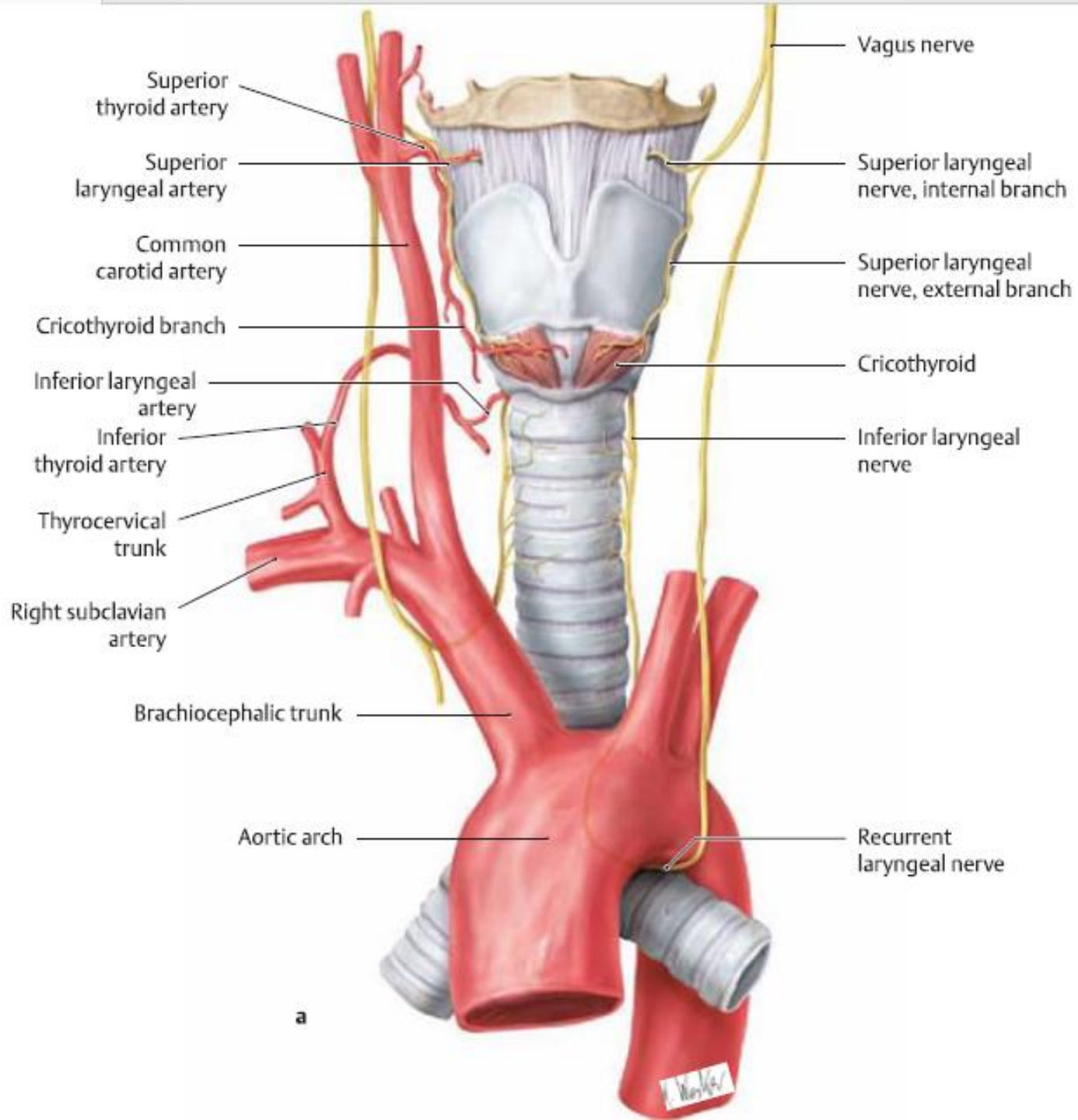
Cranial nerves

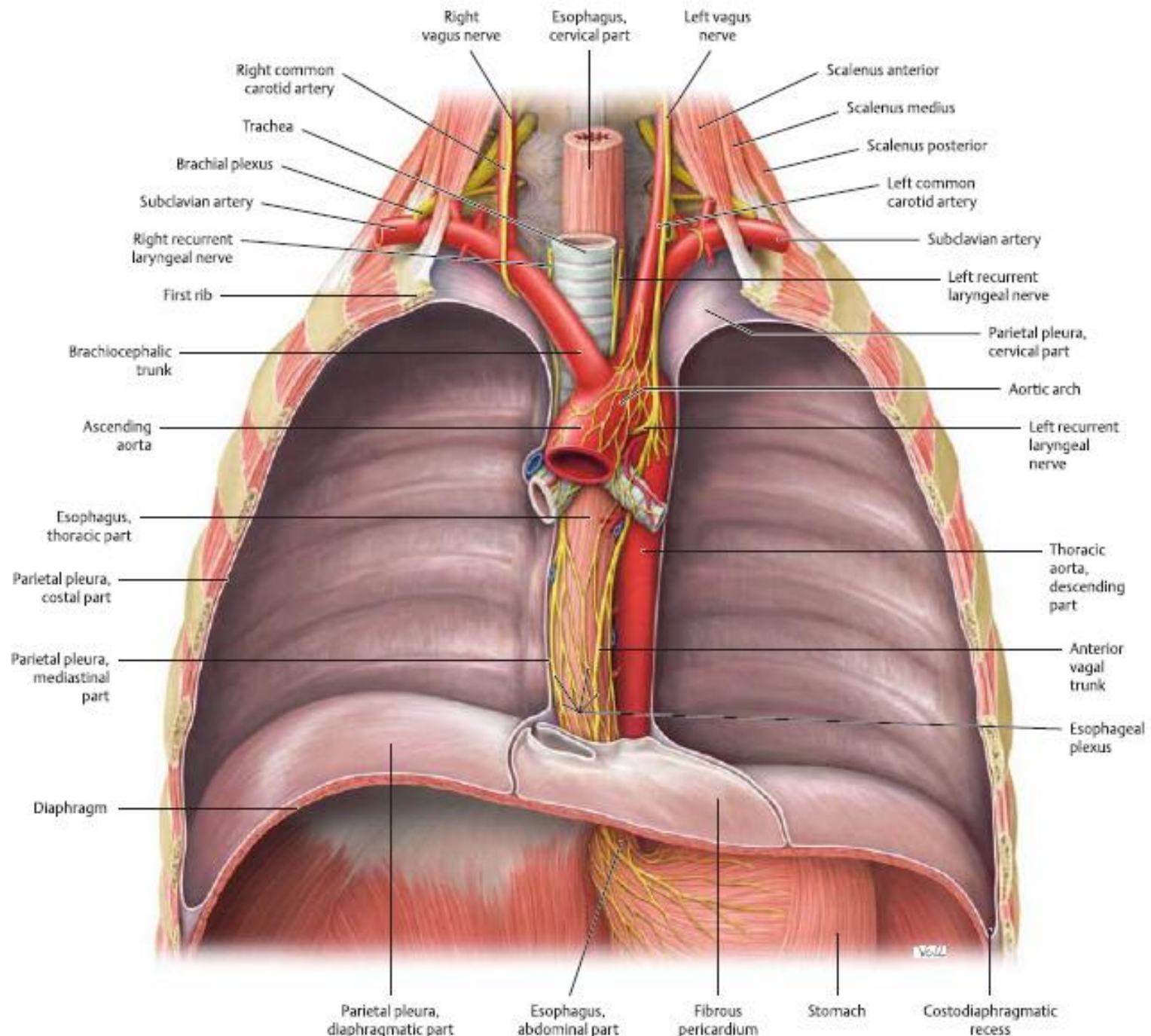
Divisions (Parts)	Branches
<p>Cranial Vagi arise by a series of rootlets from medulla (includes traditional cranial root of CN XI)</p>	<p>Meningeal branch to dura mater (sensory; actually fibers of C2 spinal ganglion neurons that hitch a ride with vagus nerve) Auricular branch</p>
<p>Cervical Exit cranium/enter neck through jugular foramen; right and left vagus nerves enter carotid sheaths and continue to root of neck</p>	<p>Pharyngeal branches to pharyngeal plexus (motor) Cervical cardiac branches (parasympathetic, visceral afferent) Superior laryngeal nerve (mixed) internal (sensory) and external (motor) branches Right recurrent laryngeal nerve (mixed)</p>
<p>Thoracic Vagi enter thorax through superior thoracic aperture; left vagus contributes to anterior esophageal plexus; right vagus to posterior plexus; form anterior and posterior trunks</p>	<p>Left recurrent laryngeal nerve (mixed; all distal branches convey parasympathetic and visceral afferent fibers for reflex stimuli) Thoracic cardiac branches Pulmonary branches Esophageal plexus</p>
<p>Abdominal Anterior and posterior vagal trunks enter abdomen through esophageal hiatus in diaphragm; distribute asymmetrically</p>	<p>Esophageal branches Gastric branches Hepatic branches Celiac branches (from posterior trunk) Pyloric branch (from anterior trunk) Renal branches Intestinal branches (to left colic flexure)</p>

Cranial nerves

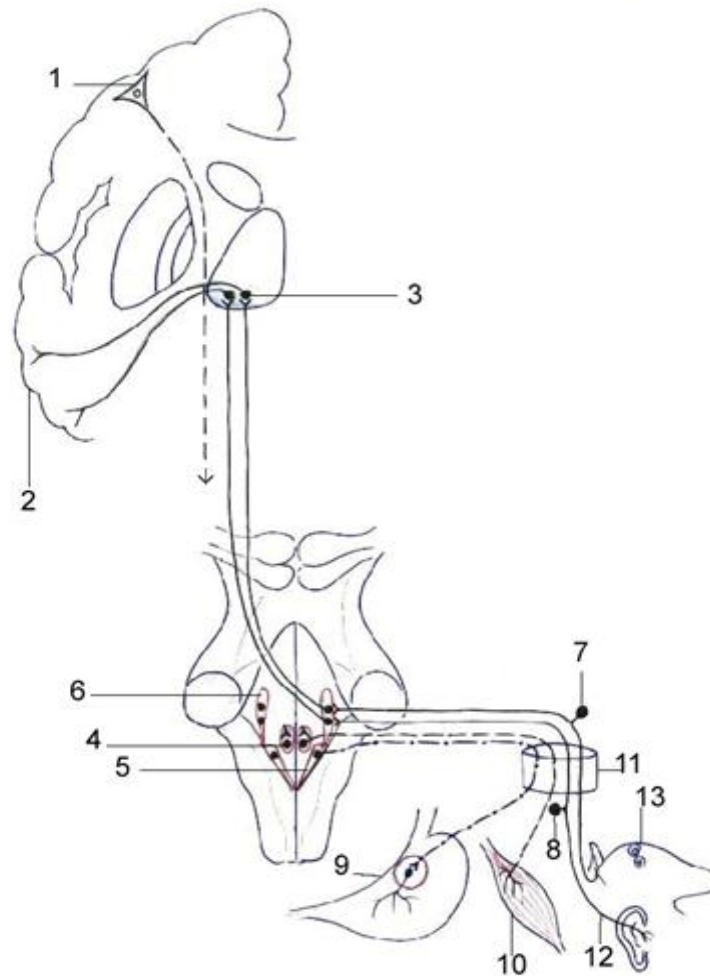








Conducting pathways of the vagus nerve (X)



1 – neuronum I (motorium) (gyrus precentralis, neurocytus pyramidalis magnus, Betz);

2 – uncus et gyrus postcentralis;

3 – neuronum III (sensitivum) (thalamus opticus);

4 – neuronum II (motorium) (nucleus ambiguus);

5 – nucleus dorsalis nervi vagi (neuronum I);

6 – neuronum II (sensitivum) (nucleus tractus solitarii);

7 – neuronum I (sensitivum) (ganglion superius, jugulare);

8 – neuronum I (sensitivum) (ganglion inferius, nodosum);

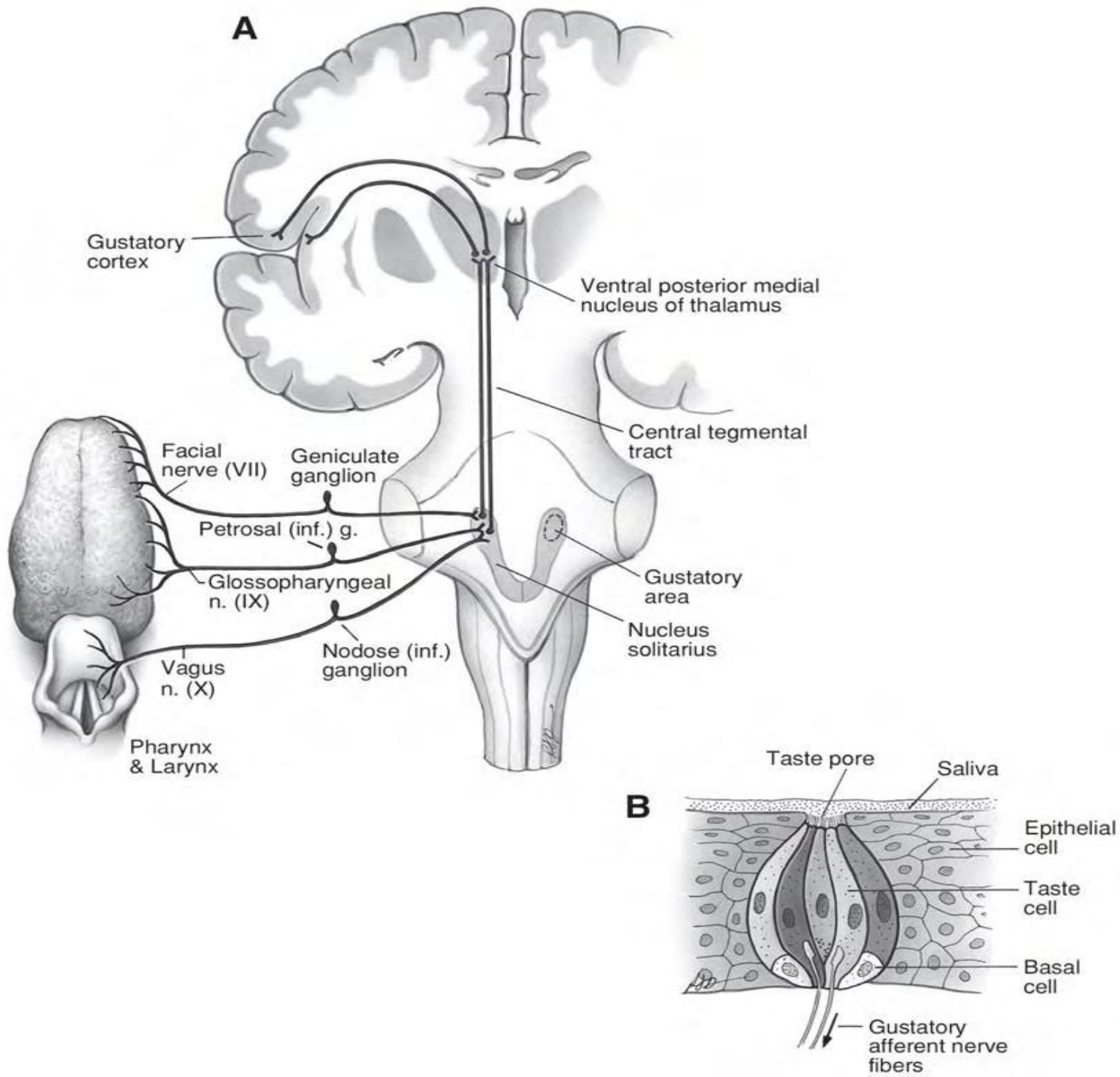
9 – ganglia intravisceralia et paravisceralia (neuronum II);

10 – mm. pharyngis, laryngis, palati mollis etc.;

11 – foramen jugulare;

12 – nervus auricularis posterior;

13 – radix linguae.

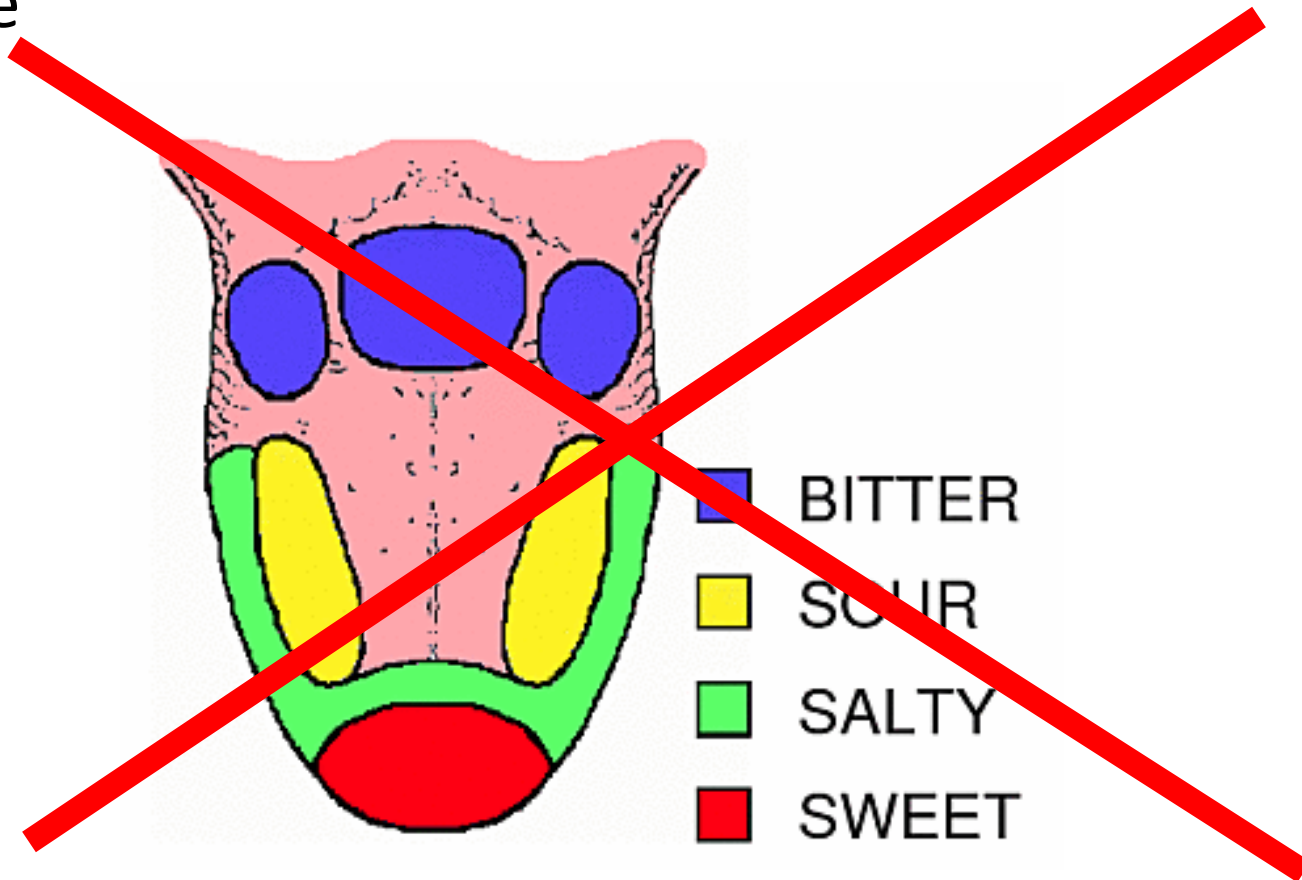


The sensation of flavors result from combinations of **gustatory**, **olfactory**, and **somatosensory** inputs.

The cerebral cortex mediates the appreciation of these representations of taste.

Taste

- Different areas of the tongue detect certain types of taste



The tongue taste map is **WRONG**: Flavours are actually perceived by neurons in the brain, scientists reveal

- Scientists at Columbia University say brain not tongue decides taste
- They say our thousands of taste buds can all detect different flavours
- These are salty, bitter, sour, sweet and savoury
- But they send signals to the brain which interprets them into flavours
- Findings put to bed the myth that our tongues have a 'taste map'

By [JONATHAN O'CALLAGHAN FOR MAILONLINE](#)

PUBLISHED: 13:13 BST, 10 November 2014 | **UPDATED:** 14:52 BST, 10 November 2014



Share



147
shares

34

View comments

In school we're taught that our tongues have specific areas that are susceptible to different tastes: salty, bitter, sour, sweet or savoury.

But scientists say that is a myth, and they've found that each of the several thousand sensors on our tongue can recognise any of the tastes.

And it is down to cells in the brain, not in the tongue, to work out which taste is which.





A



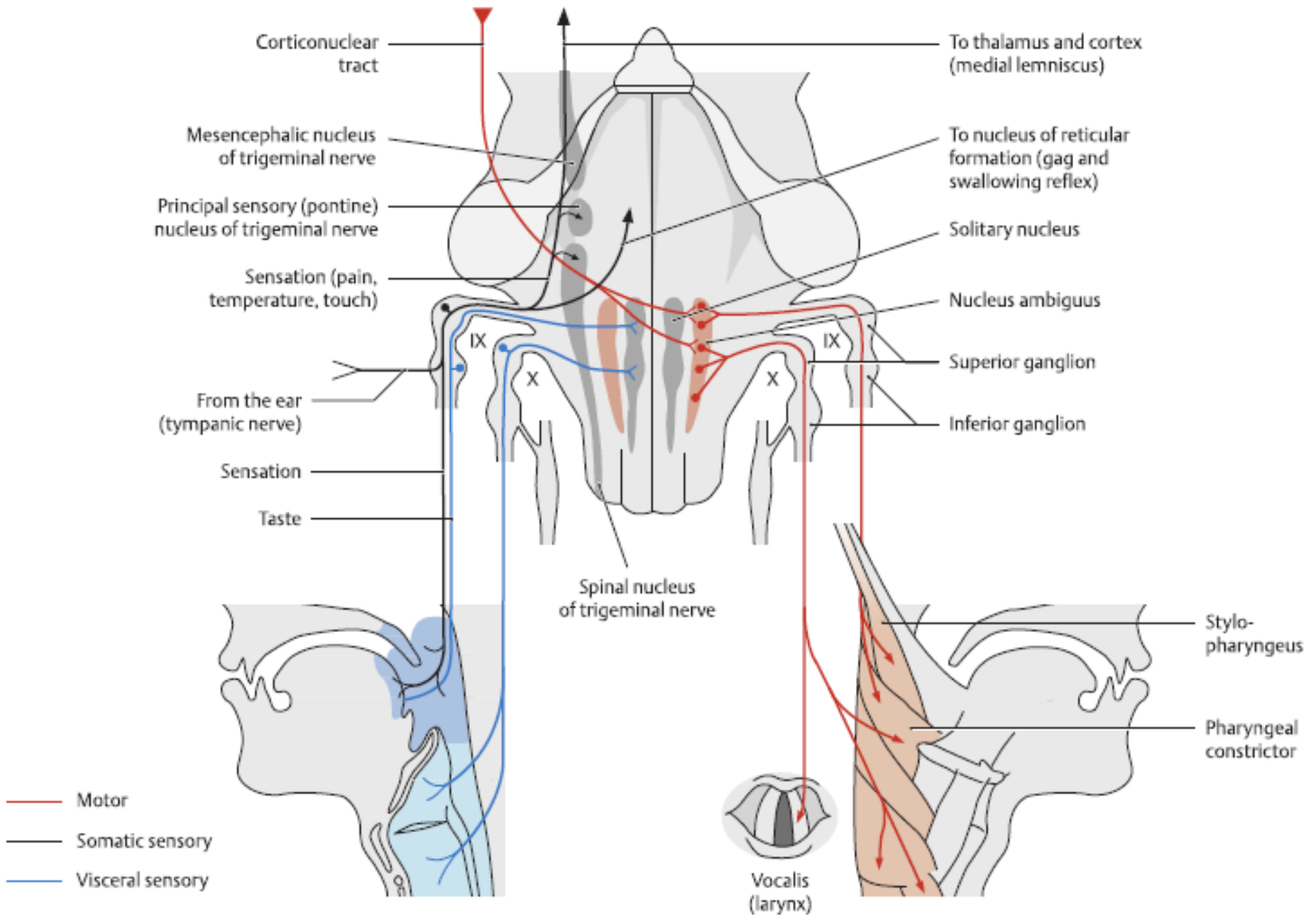
B

Reflexes Involving Nerves VII, IX, X, and XI

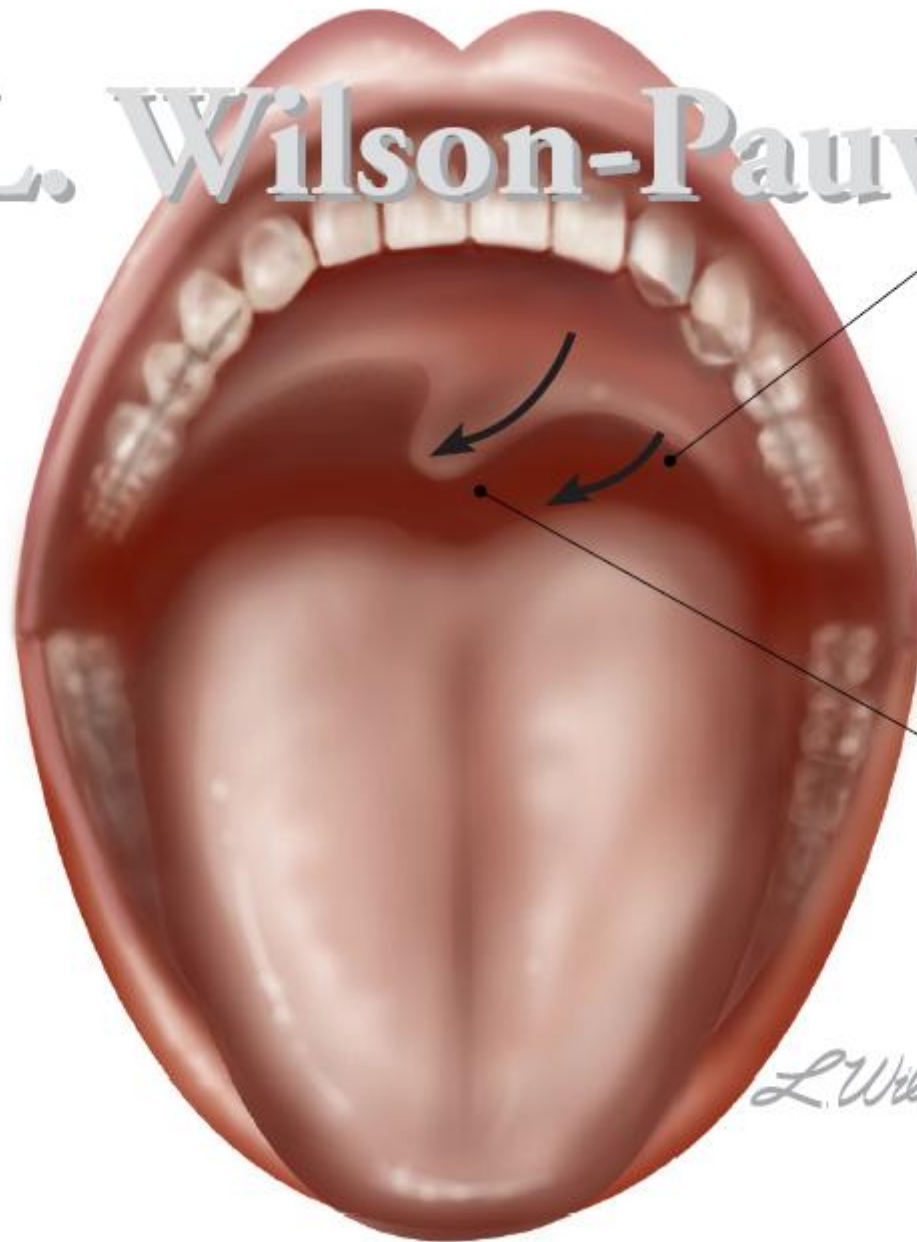
- *Taste–Salivary Gland Reflex.*
- *Carotid Sinus Reflex.*
- *Carotid Body Reflex.*
- *Gag (Pharyngeal) Reflex.*
- *Cough Reflex.*



Testing the gag reflex by lightly touching the wall of the pharynx.



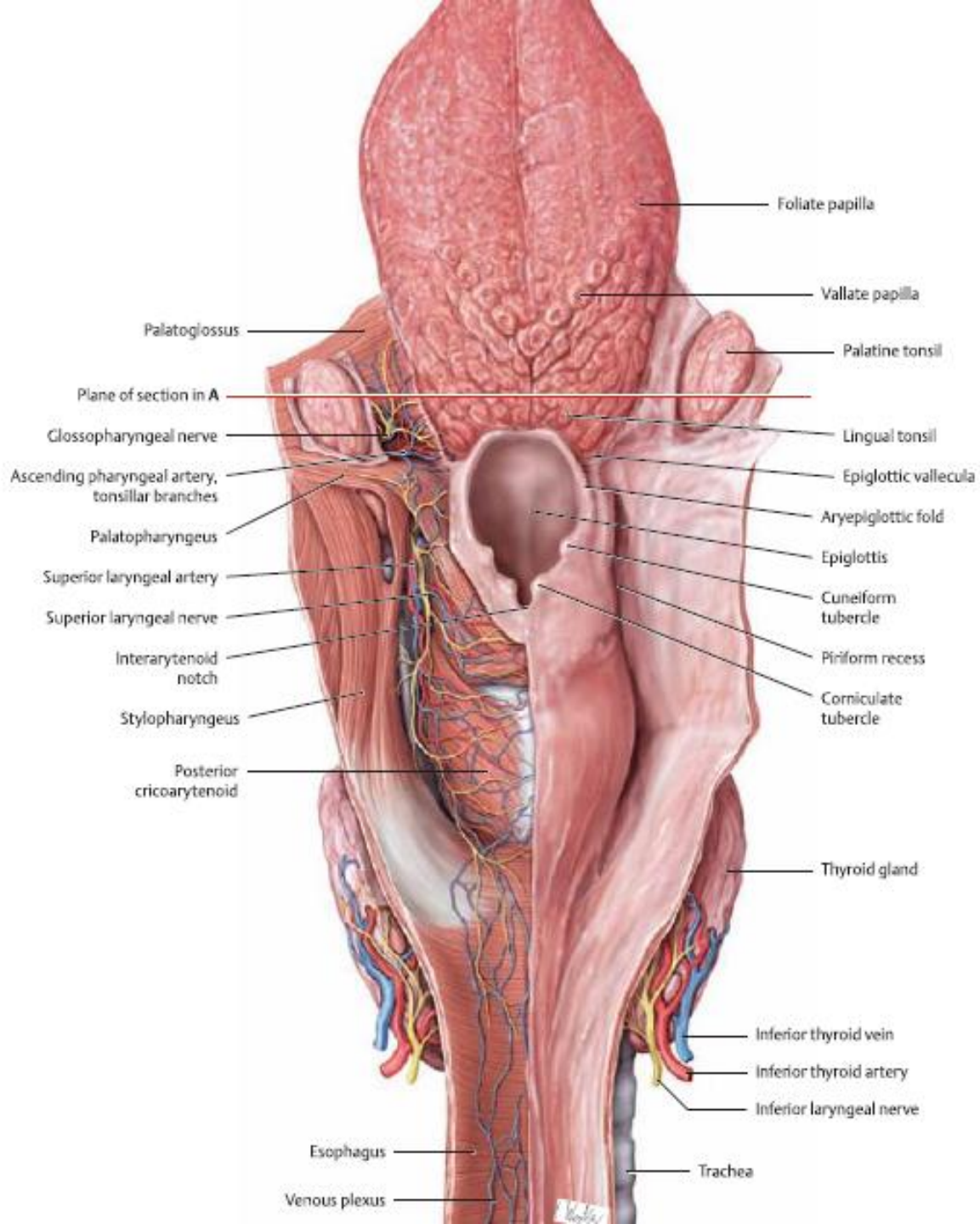
© L. Wilson-Pauwels

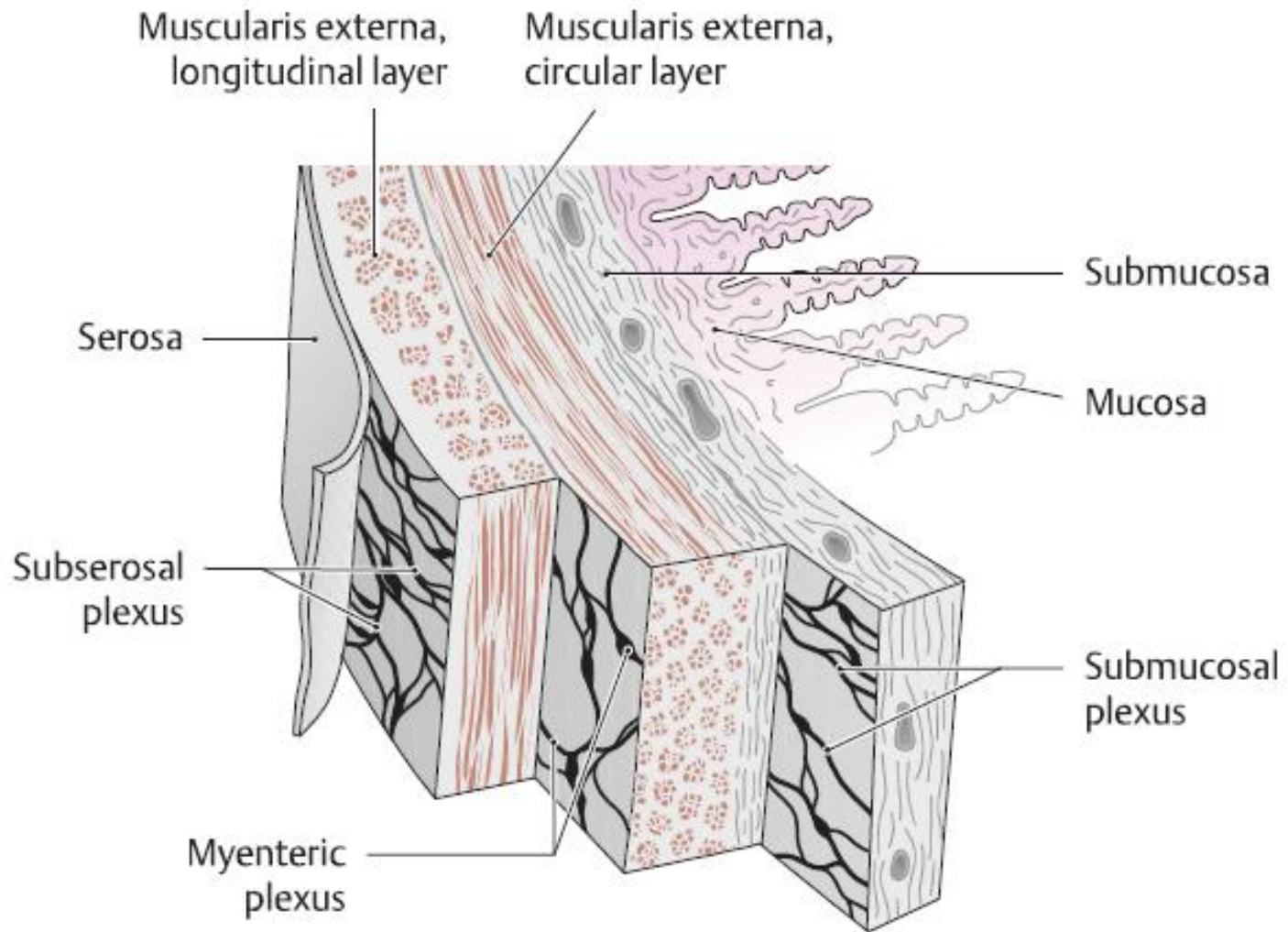


Arch of soft palate
(dropped)

Uvula
deviated to
normal intact side

L. Wilson-Pauwels



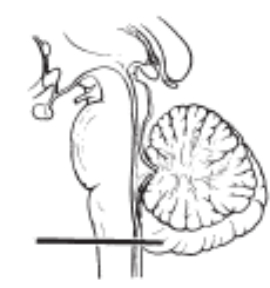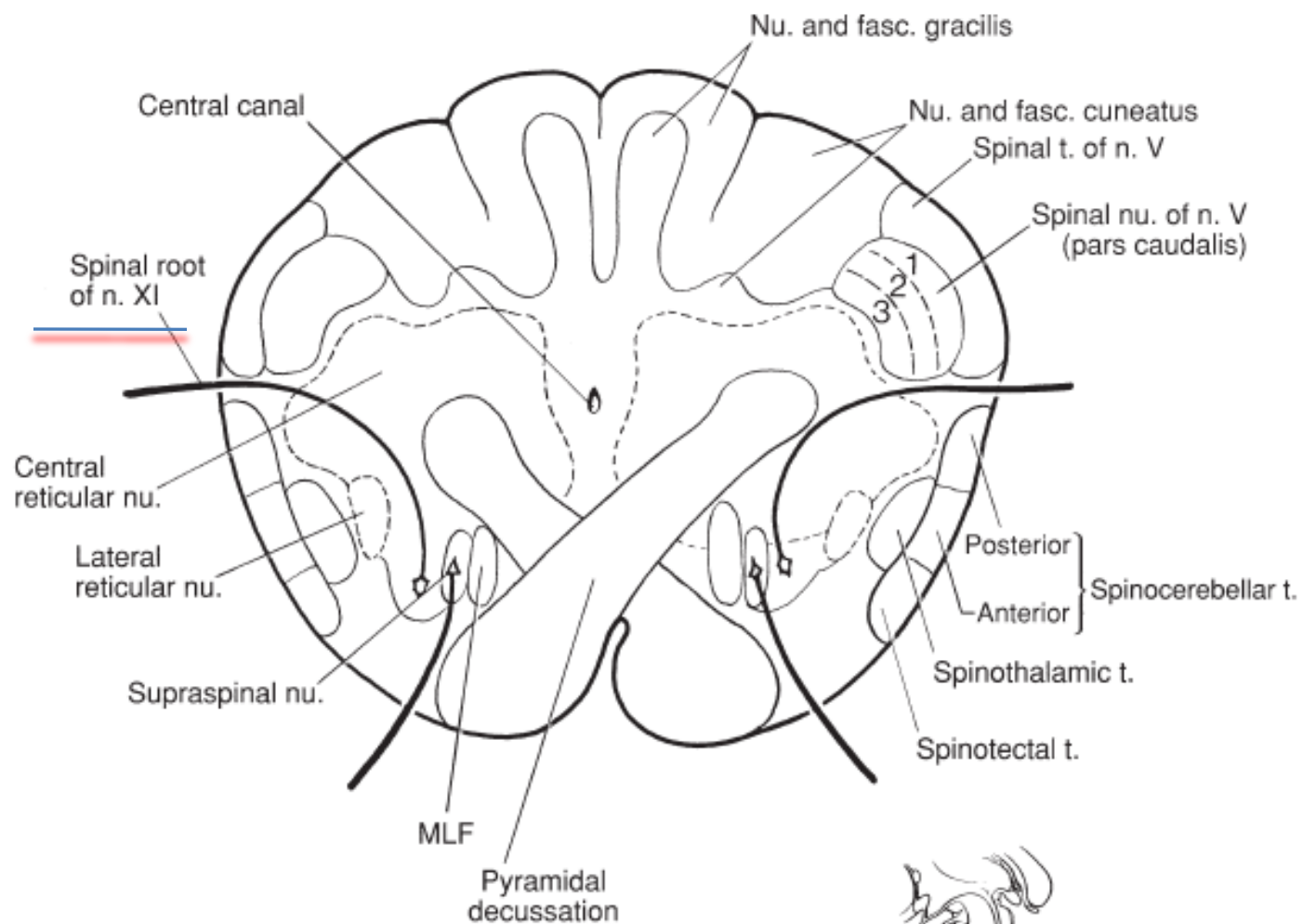


Cranial nerves

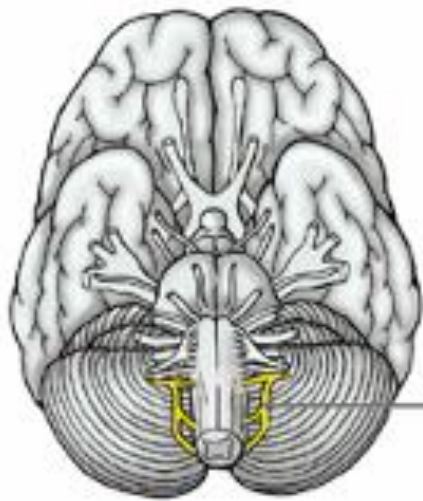
Spinal Accessory Nerve (CN XI)

Functions: Motor to the striated sternocleidomastoid and trapezius muscles.

Nuclei: The spinal accessory nerve arises from the nucleus of the accessory nerve, a column of anterior horn motor neurons in the superior five or six cervical segments of the spinal cord .



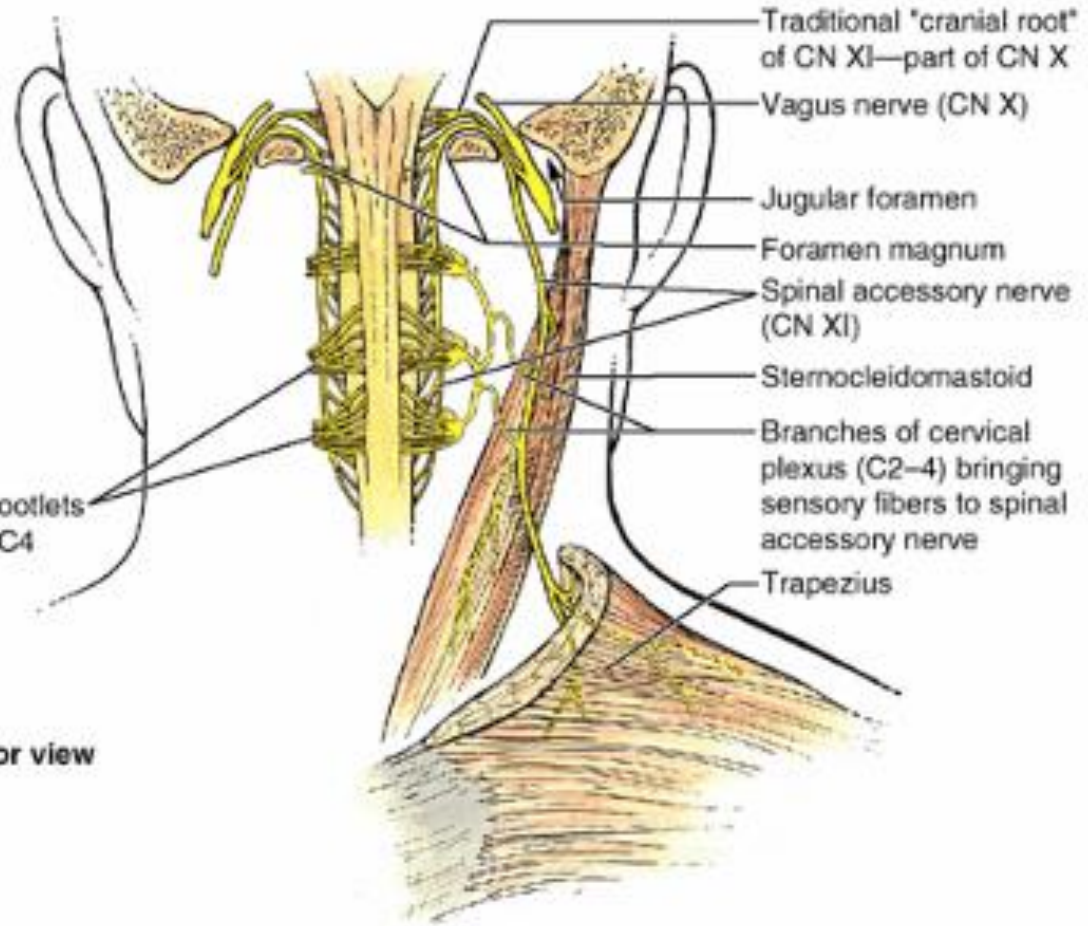
Cranial nerves



Inferior view

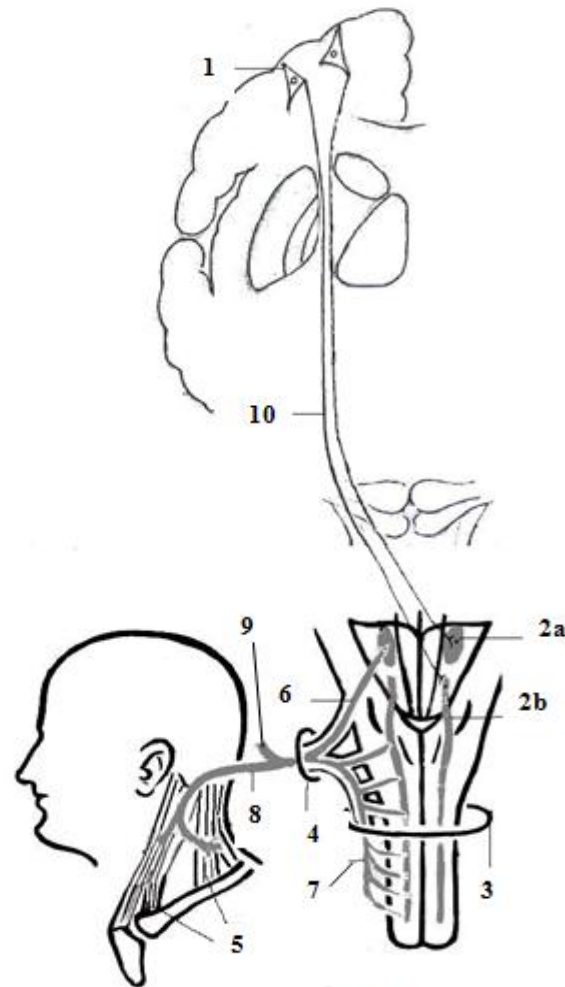
Spinal accessory nerve (CN XI)

Posterior rootlets of C3 and C4



Posterior view

Conducting pathways of the accessory nerve (XI)



1 – neuronum I (*gyrus precentralis, neurocytus pyramidalis magnus, Betz*);

2 – neuronum II [*nuclei motorii n. accessorii*];

a – *nucleus ambiguus (IX, X, XI)*;

b – *nucleus spinalis (XI)*;

3 – *foramen occipitale magnum*;

4 – *foramen jugulare*;

5 – *mm. sternocleidomastoideus et trapezius*;

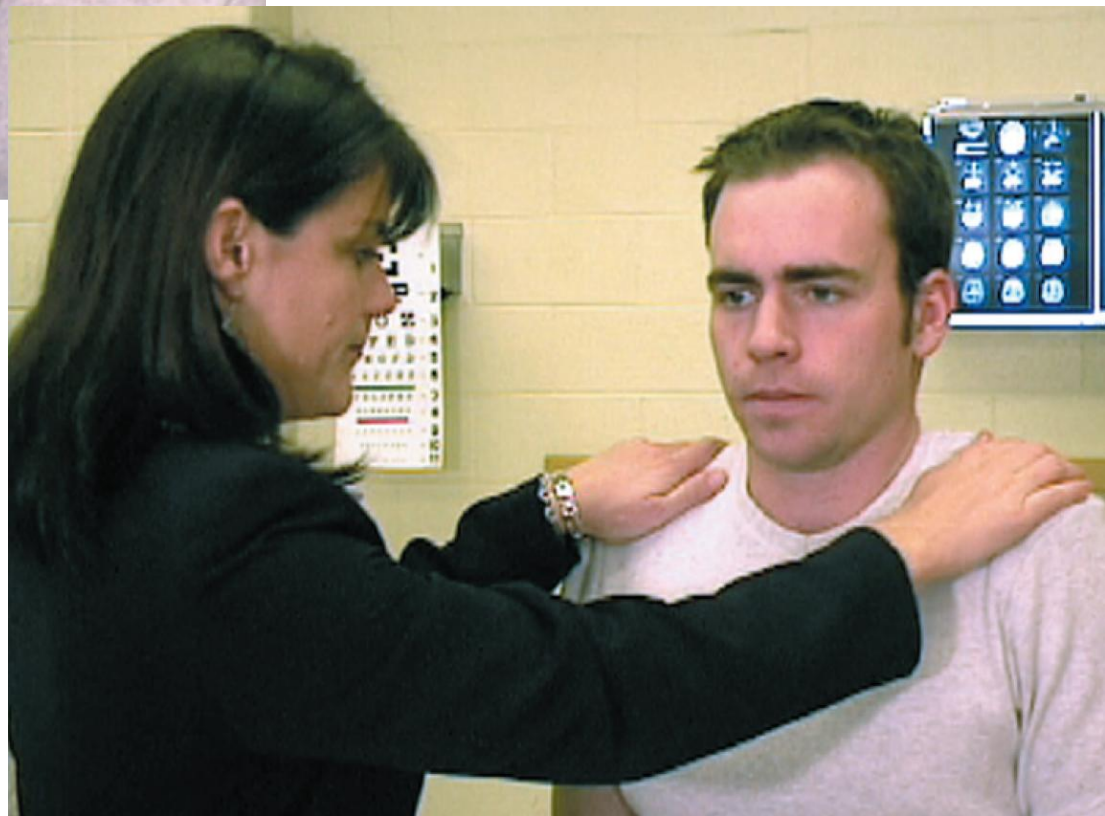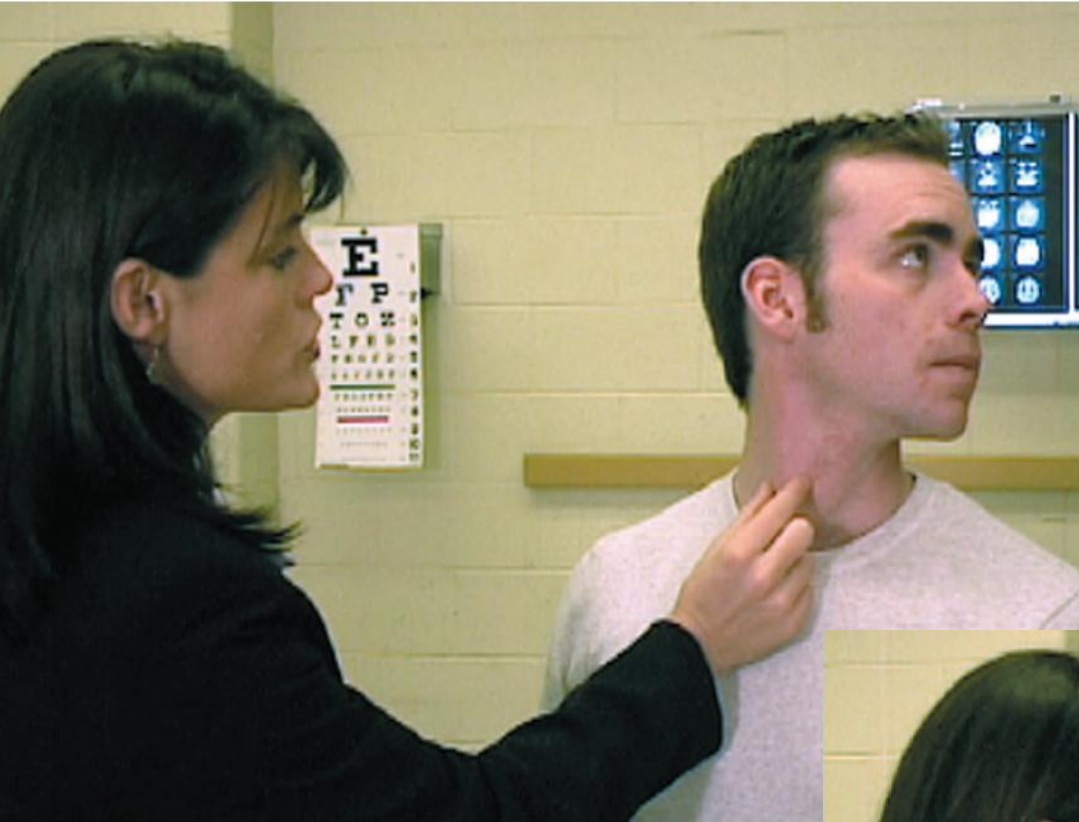6 – *radices craniales nervi accessorii*;

7 – *radices spinales nervi accessorii*;

8 – *ramus externus*;

9 – *ramus internus*;

10 – *tractus corticonuclearis*



Cranial nerves

Hypoglossal Nerve (CN XII)

Functions: Motor (general somatic efferent) to the intrinsic and extrinsic muscles of the tongue (G. glossa) **styloglossus, hyoglossus, and genioglossus.**

The hypoglossal nerve (CN XII) arises as a purely motor nerve by several rootlets from the medulla and leaves the cranium through the hypoglossal canal. After exiting the cranial cavity, CN XII is joined by a branch or branches of the cervical plexus conveying general somatic motor fibers from C1 and C2 spinal nerves and general somatic sensory fibers from the spinal ganglion of C2. These spinal nerve fibers hitch a ride with CN XII to reach the hyoid muscles, with some of the sensory fibers passing retrograde along it to reach the dura mater of the posterior cranial fossa. CN XII passes inferiorly medial to the angle of the mandible and then curves anteriorly to enter the tongue.

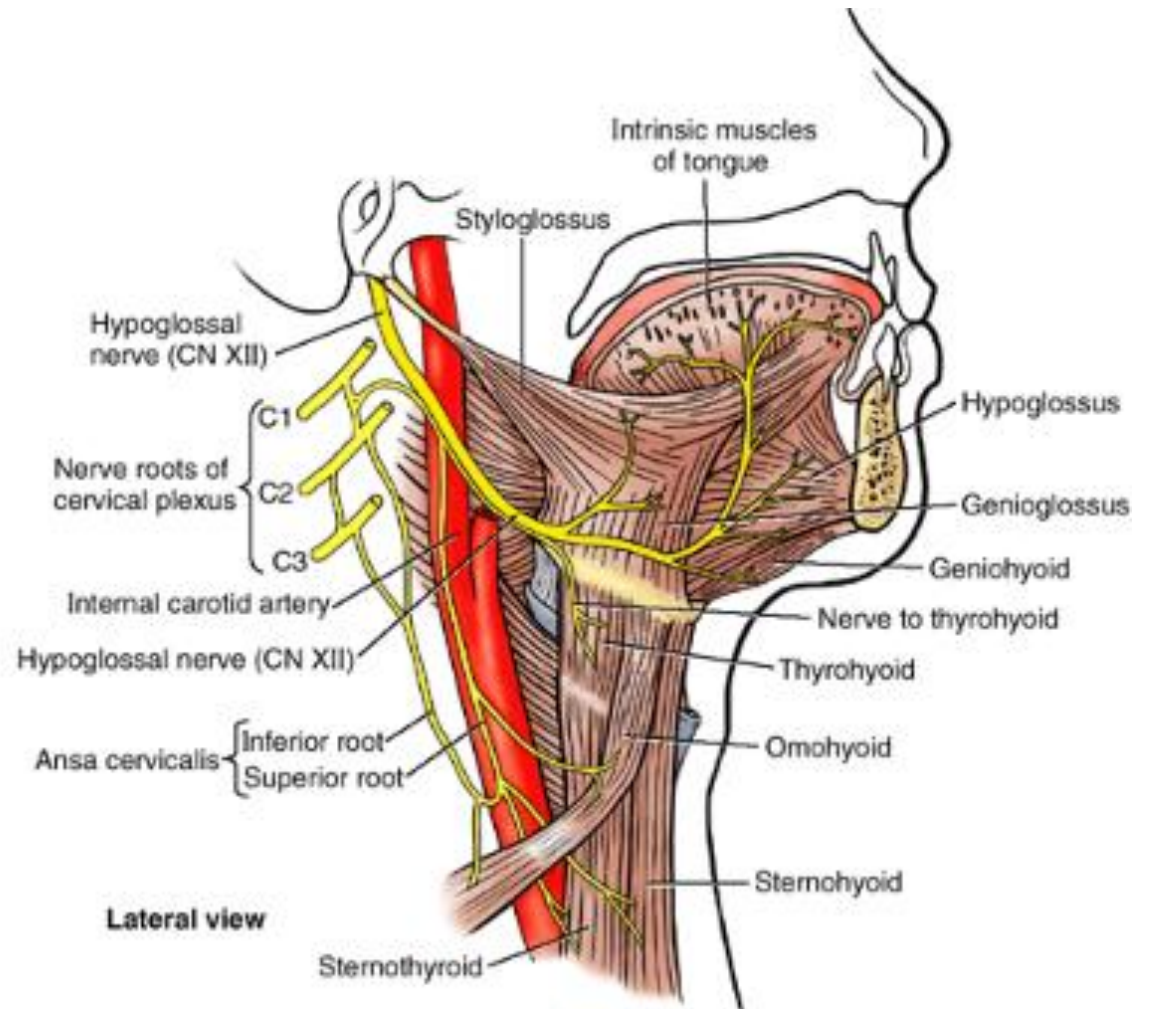
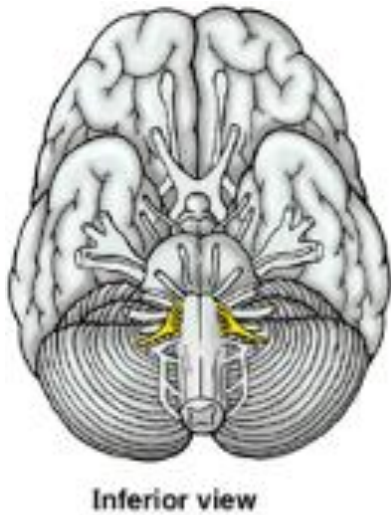
CN XII ends in many branches that supply all the extrinsic muscles of the tongue, except the palatoglossus (which is actually a palatine muscle). CN XII has the following branches:

A meningeal branch returns to the cranium through the hypoglossal canal and innervates the dura mater on the floor and posterior wall of the posterior cranial fossa. The nerve fibers conveyed are from the sensory spinal ganglion of spinal nerve C2 and are not hypoglossal fibers.

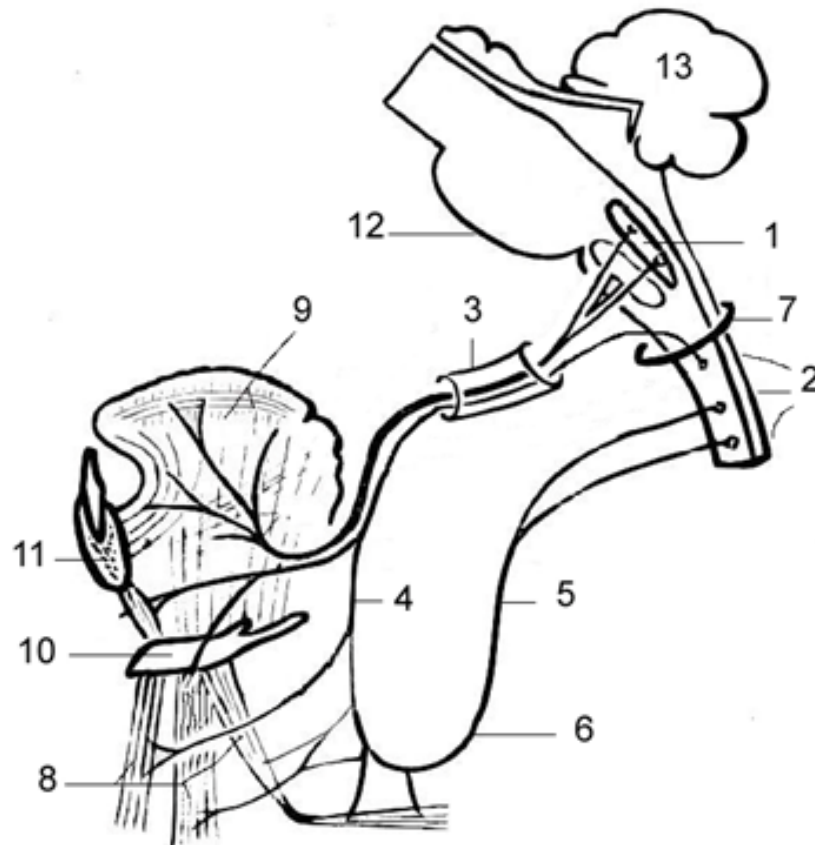
The superior root of the ansa cervicalis branches from CN XII to supply the infrahyoid muscles (sternohyoid, sternothyroid, and omohyoid). This branch actually conveys only fibers from the cervical plexus (the loop between the anterior rami of C1 and C2) that joined the nerve outside the cranial cavity, not hypoglossal fibers. Some fibers continue past the descending branch to reach the thyrohyoid muscle.

Terminal lingual branches supply the styloglossus, hyoglossus, genioglossus, and intrinsic muscles of the tongue.

Cranial nerves



Conducting pathways of the hypoglossal nerve (XII)



- 1 – nucleus nervi hypoglossi;
- 2 – medulla spinalis (segmenti C₁, C₂, C₃);
- 3 – canalis hypoglossus;
- 4 – radix superior ansae cervicalis;
- 5 – radix inferior ansae cervicalis;
- 6 – ansa cervicalis;
- 7 – foramen magnum;
- 8 – mm. infrahyoidei;
- 9 – rami linguales (musculi linguae);
- 10 – os hyoideum;
- 11 – mandibula;
- 12 – truncus cerebri;
- 13 – cerebellum.



A



B

'I want to be a ballerina': Girl, 9, stuns doctors with miraculous recovery after half her brain is removed during surgery

By MAIL FOREIGN SERVICE
UPDATED: 00:11 BST, 26 March 2010



 89
View comments

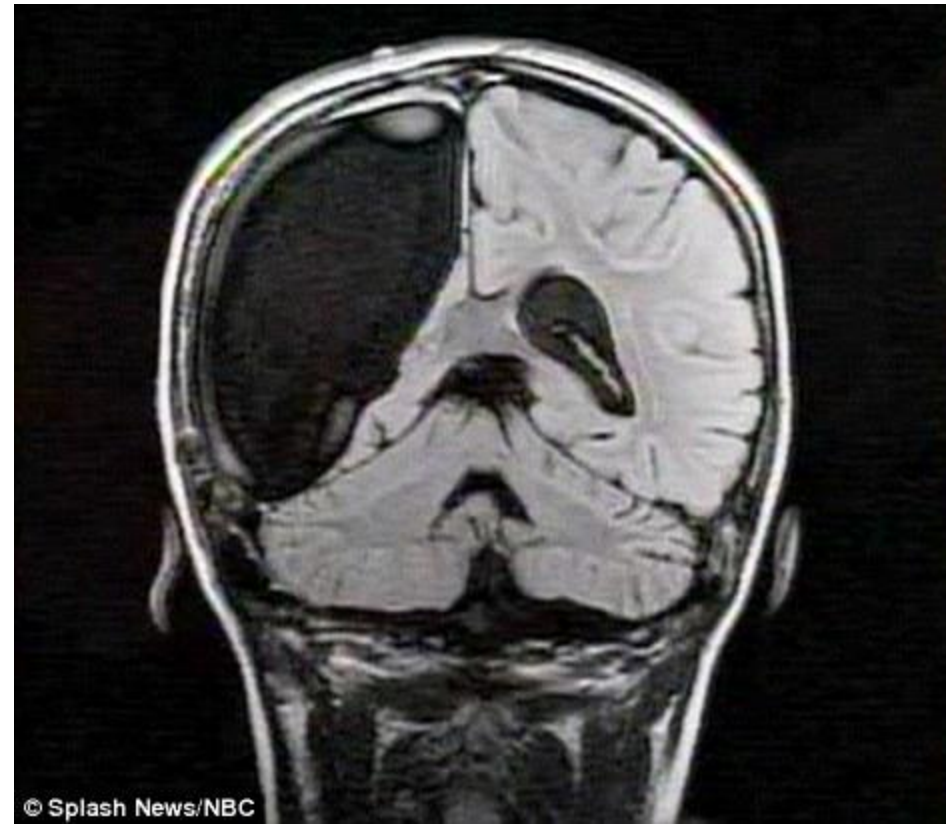Nine-year-old Cameron Mott had half her brain taken out during major surgery, but it has not stopped the youngster pursuing her dreams.

Cameron has stunned doctors and her family with a miraculous recovery from the radical surgery and now wants to become a ballerina.

The nine-year-old developed the brain disorder Rasmussen's syndrome at the age of three, which saw the disease eat away at the right side of her brain.



© Splash News/NBC



© Splash News/NBC

**VĂ MULȚUMESC
PENTRU ATENȚIE!**

