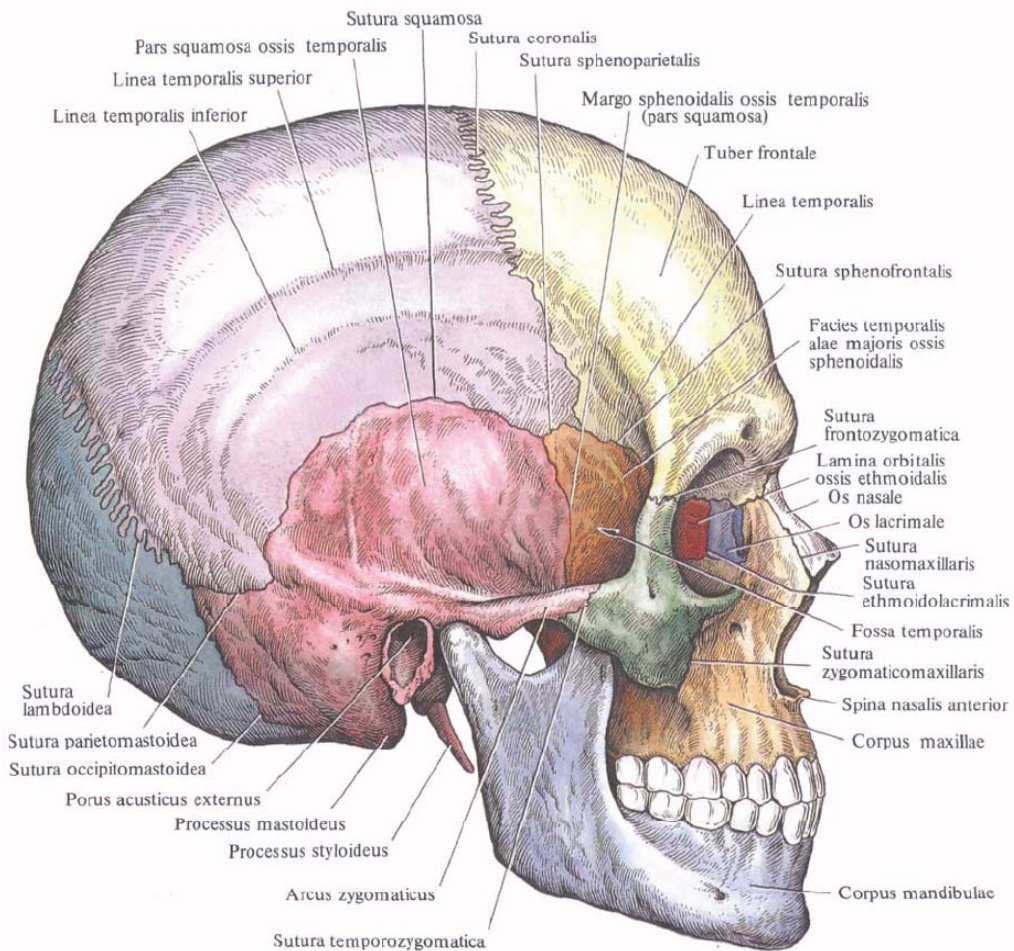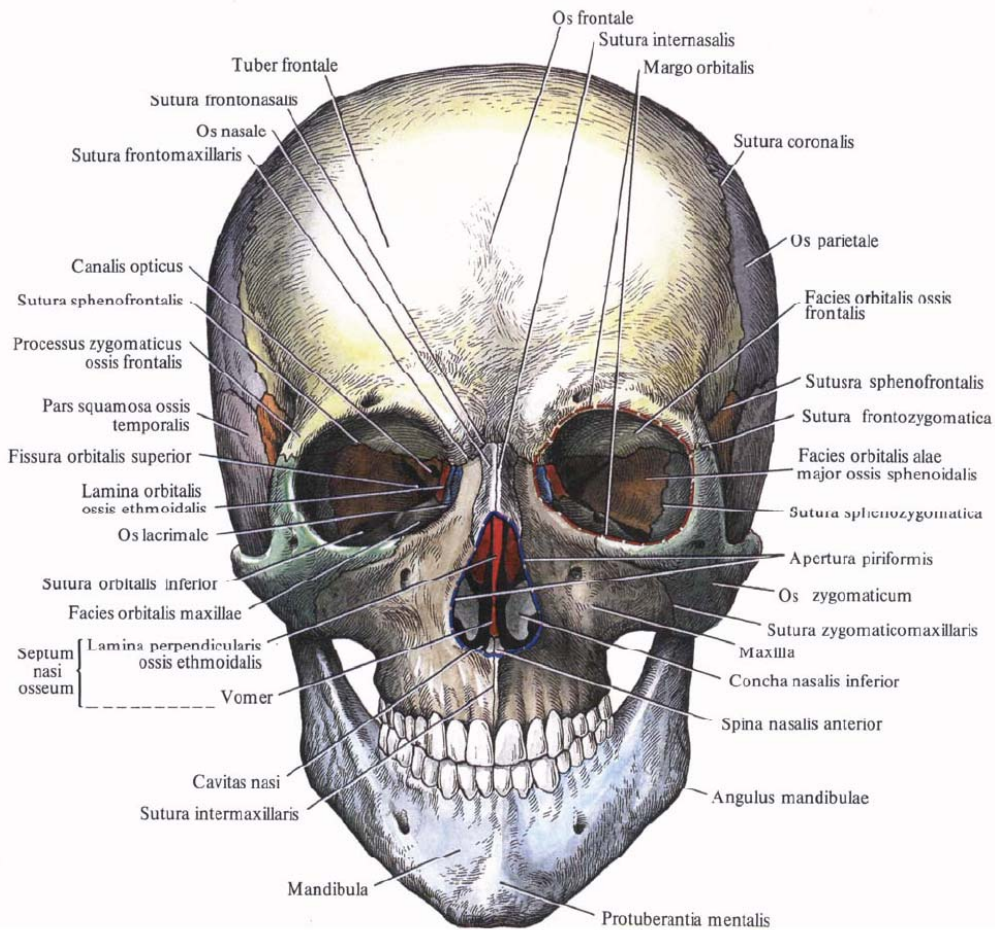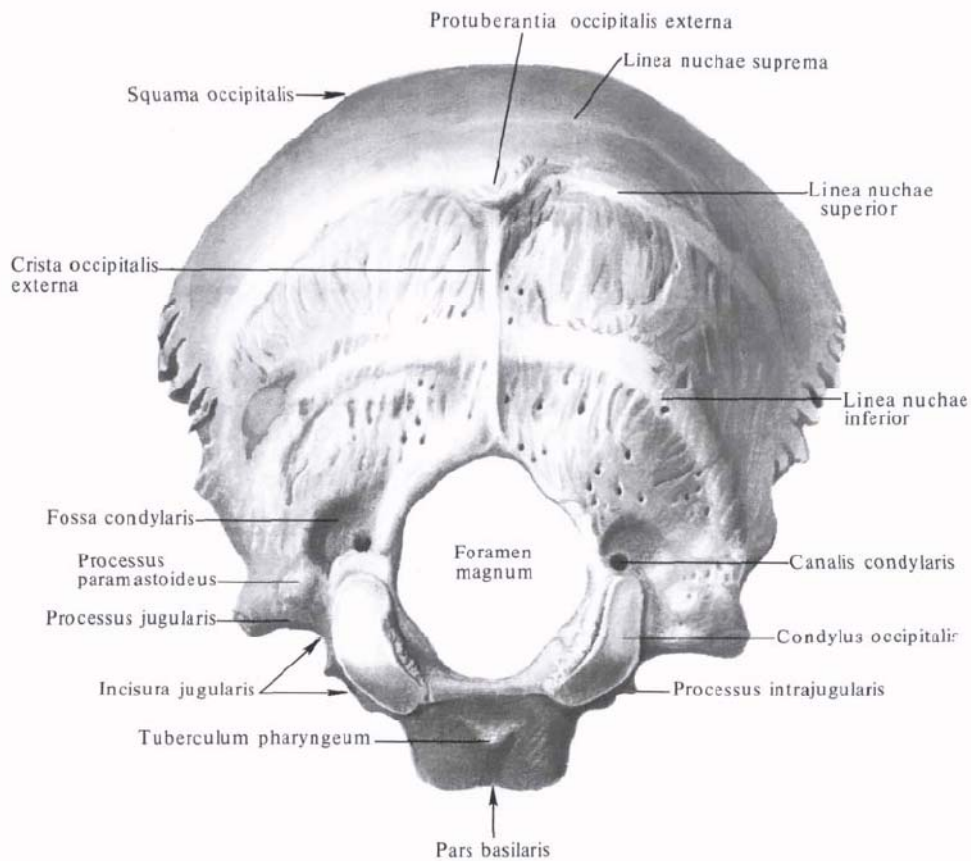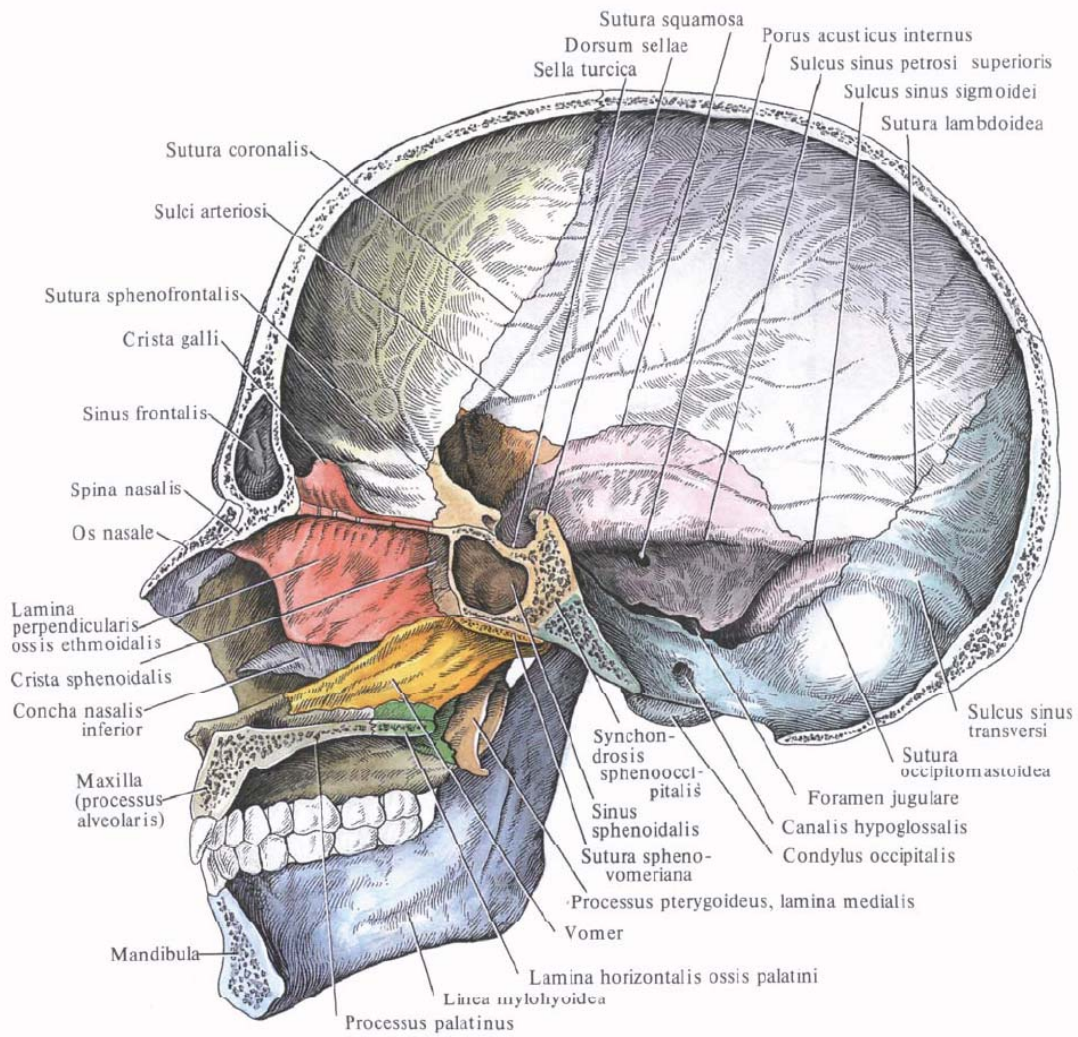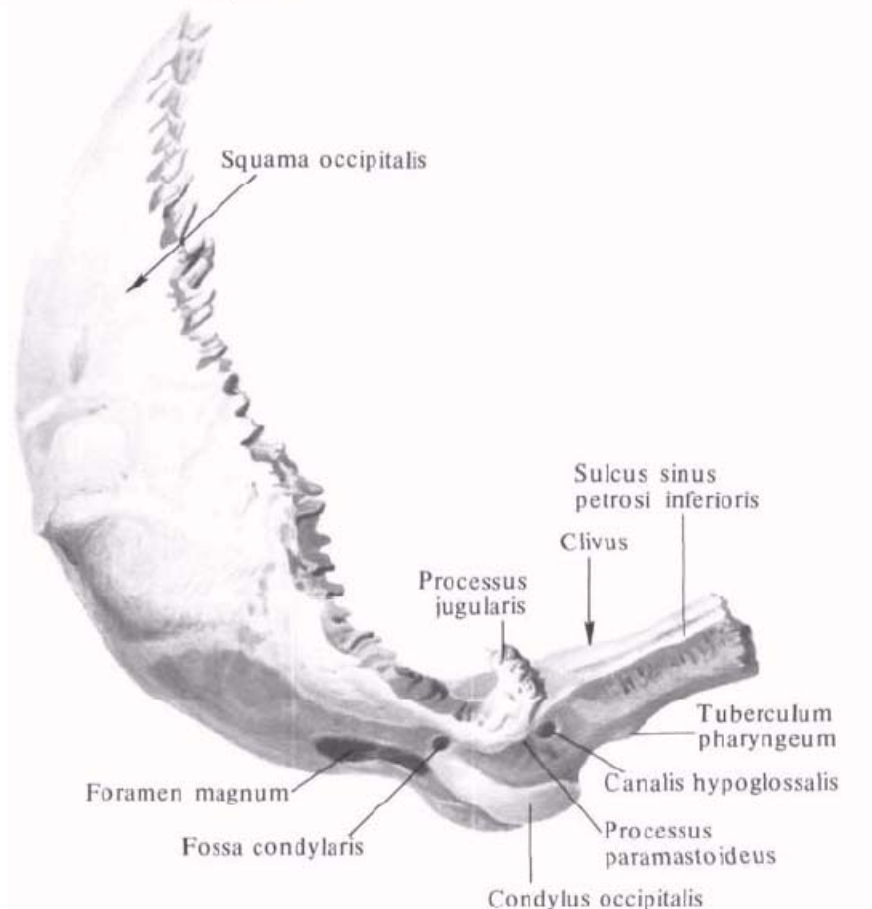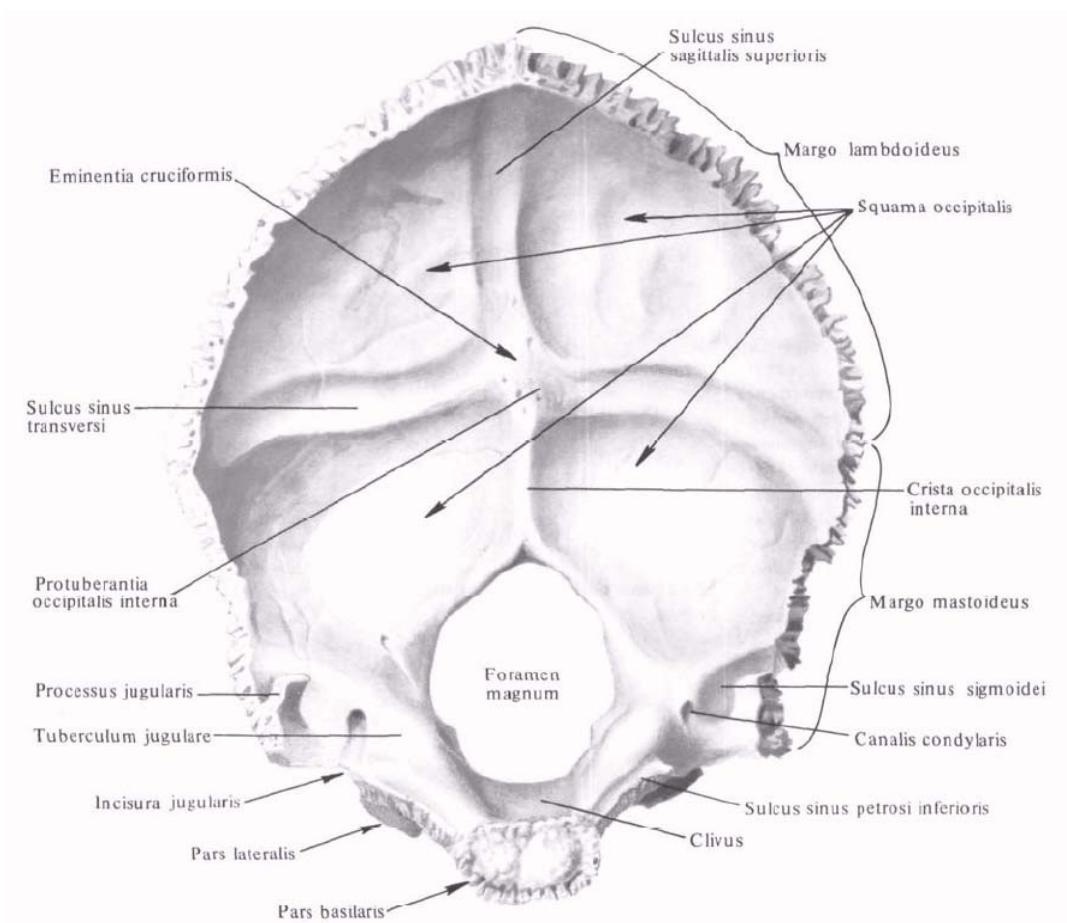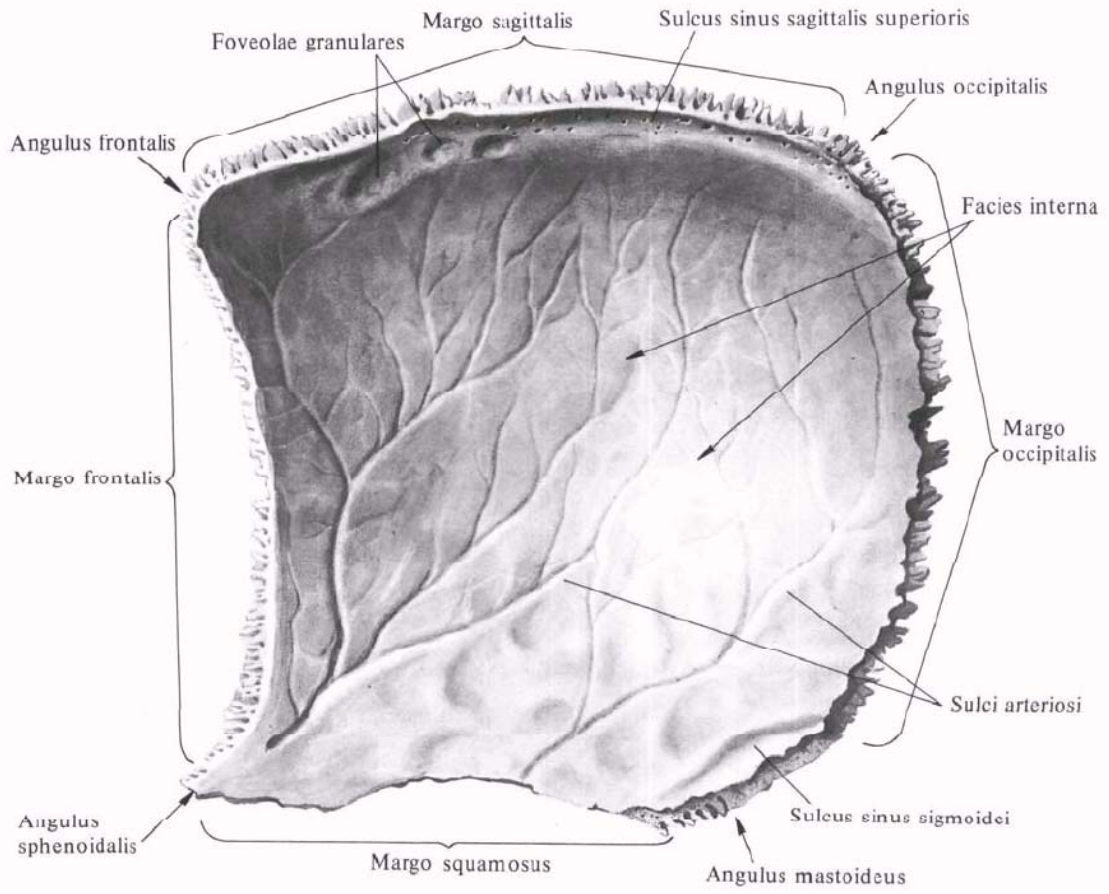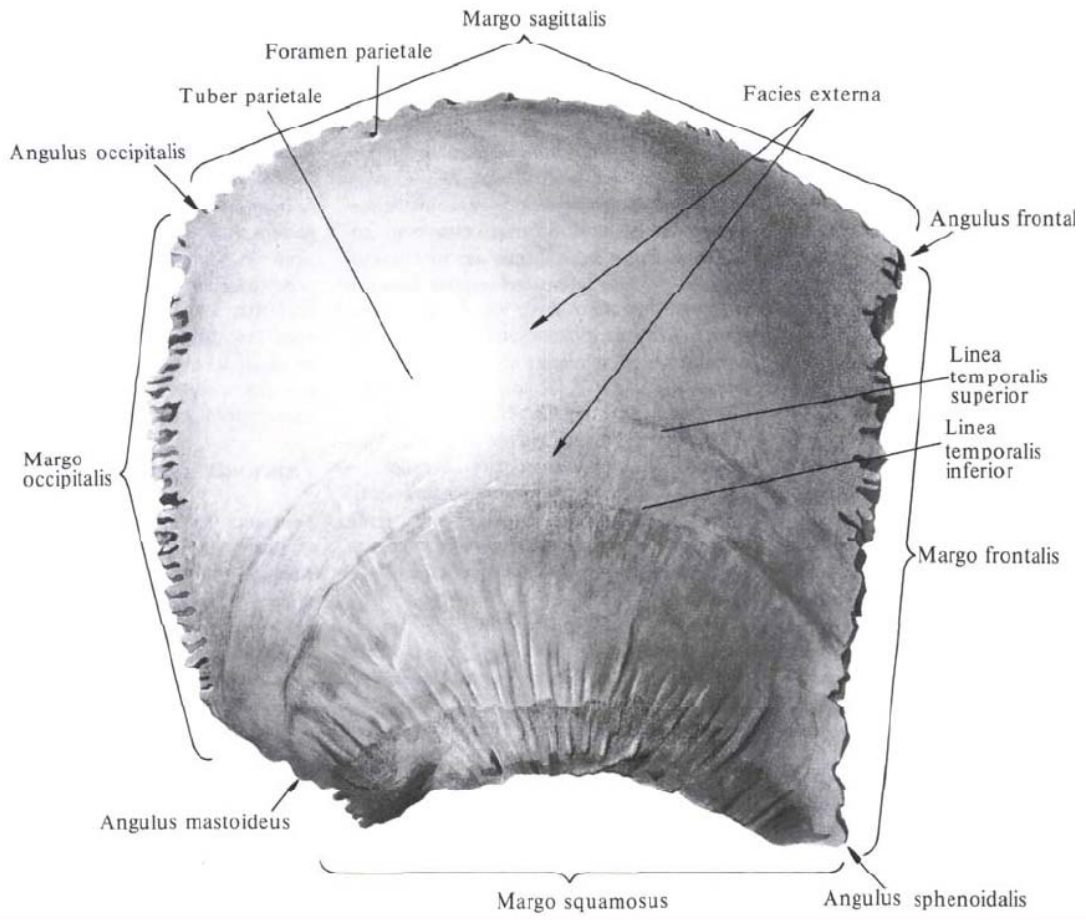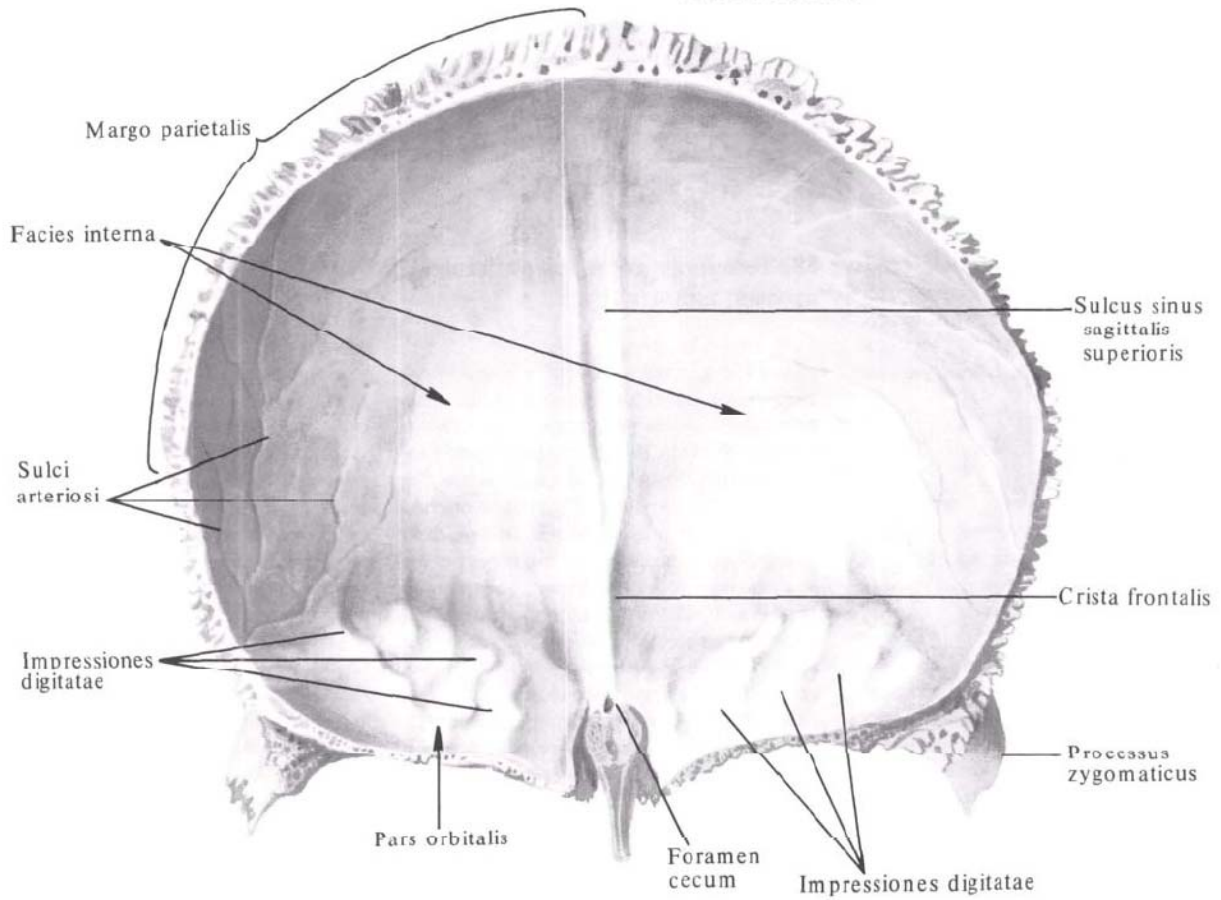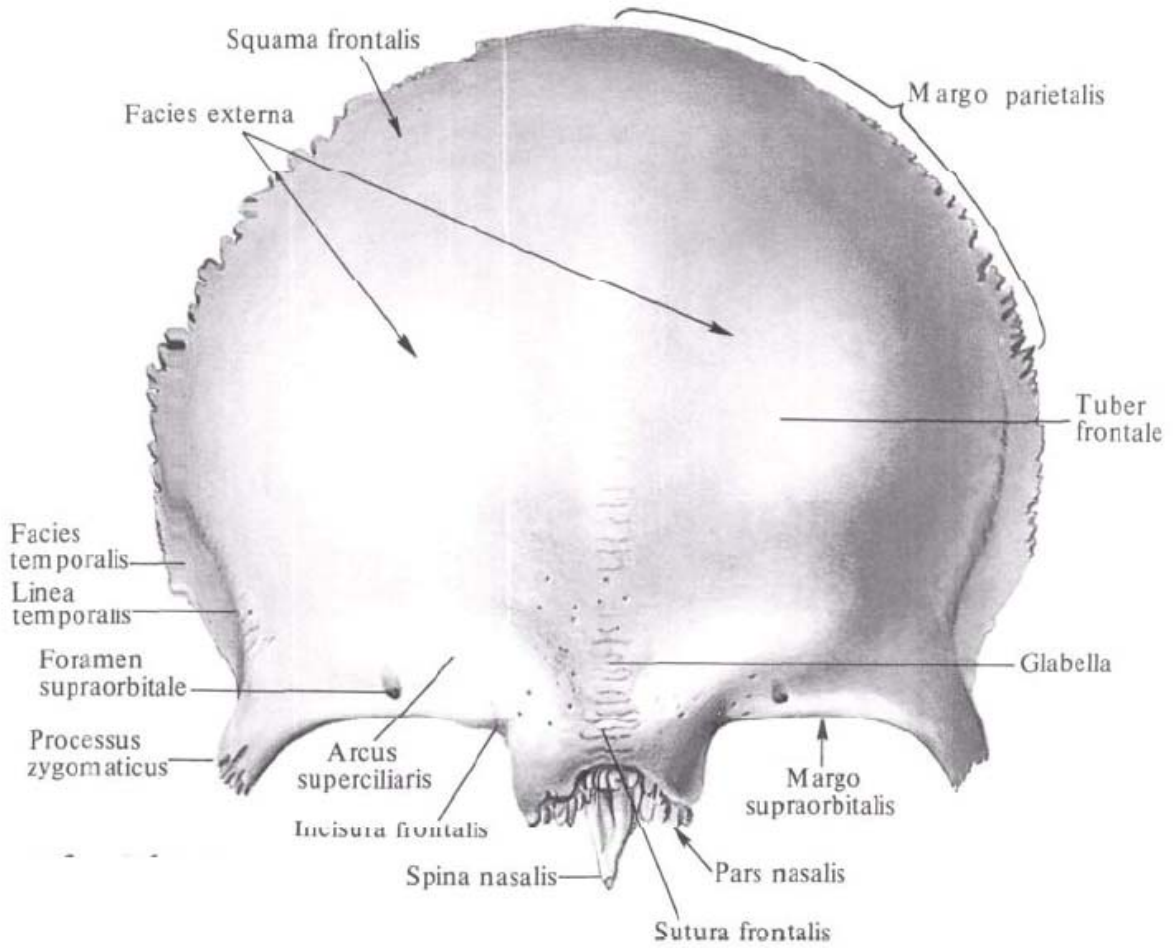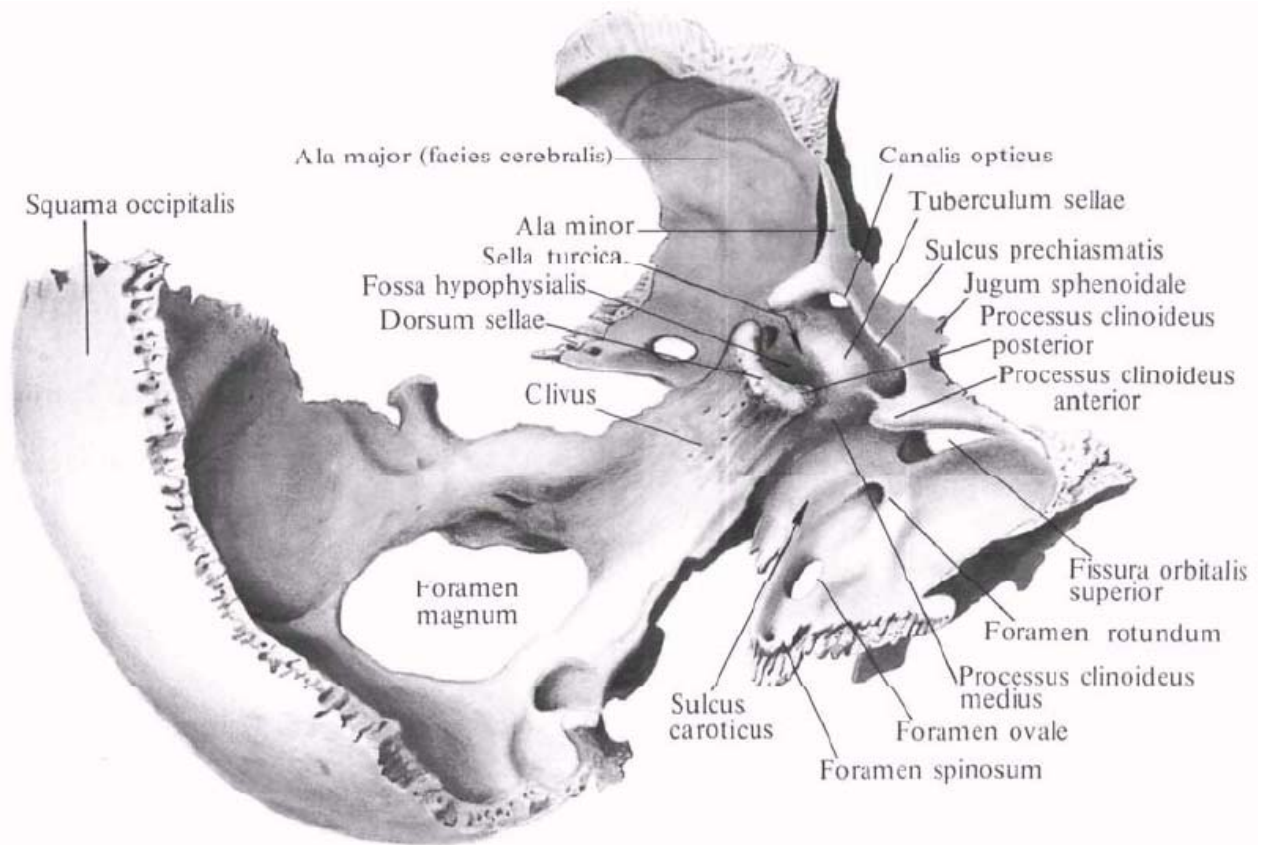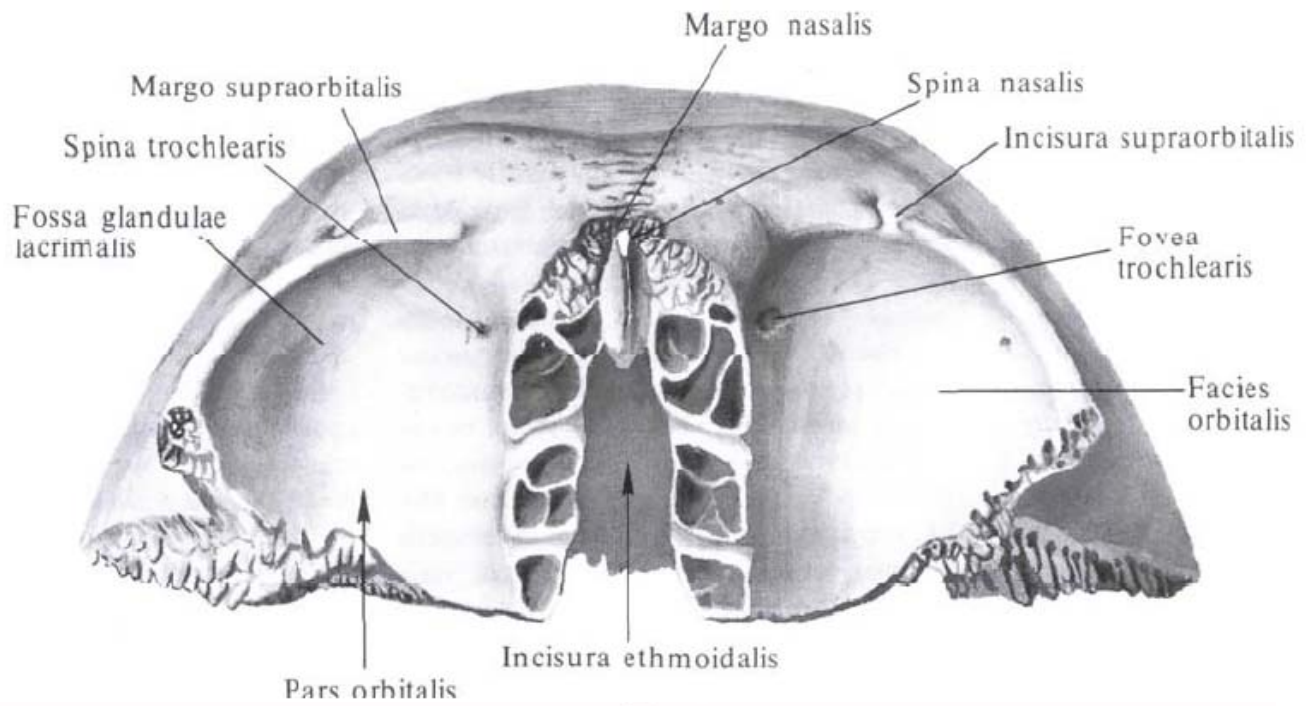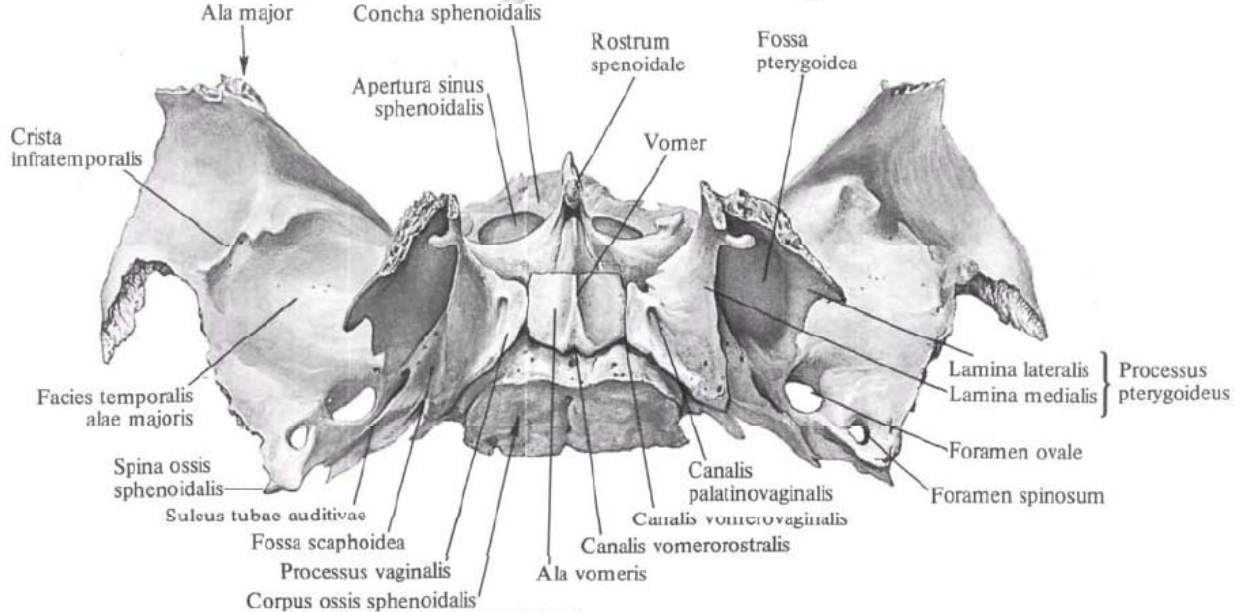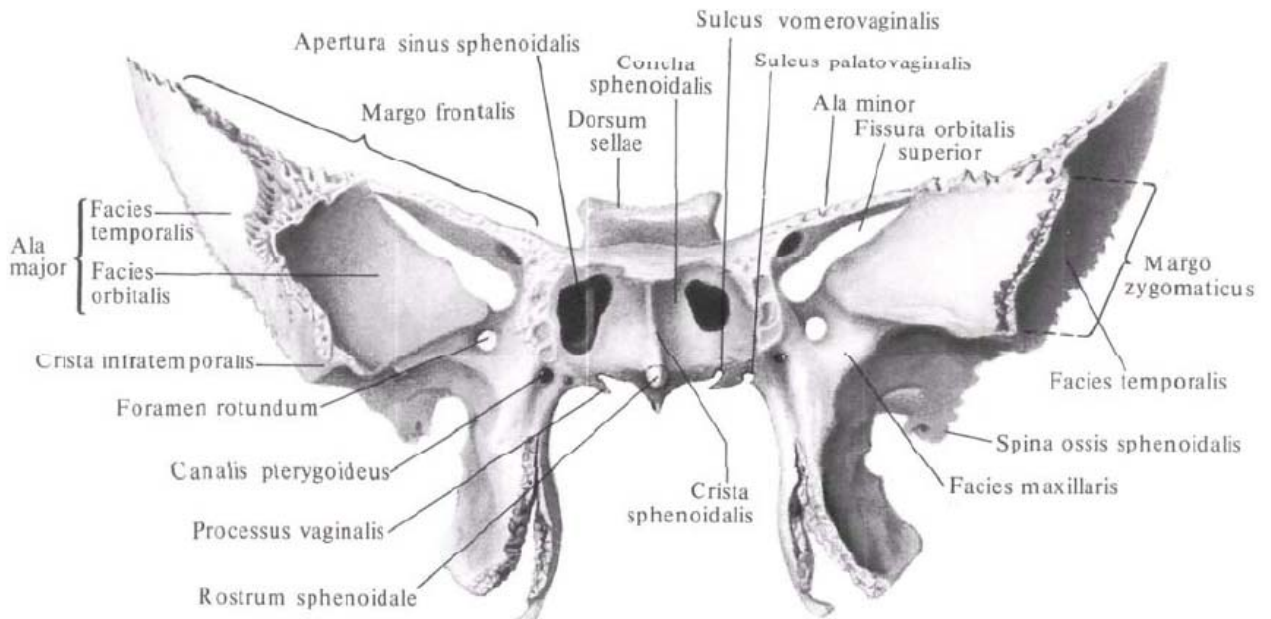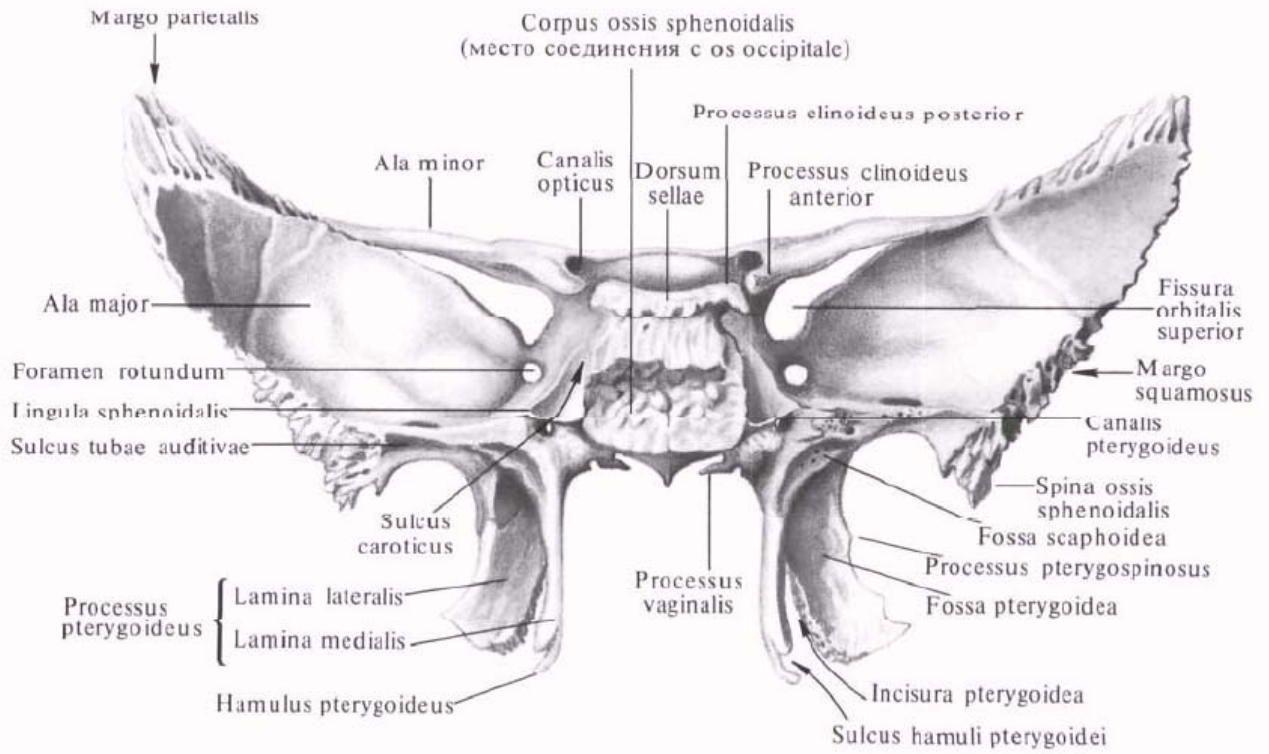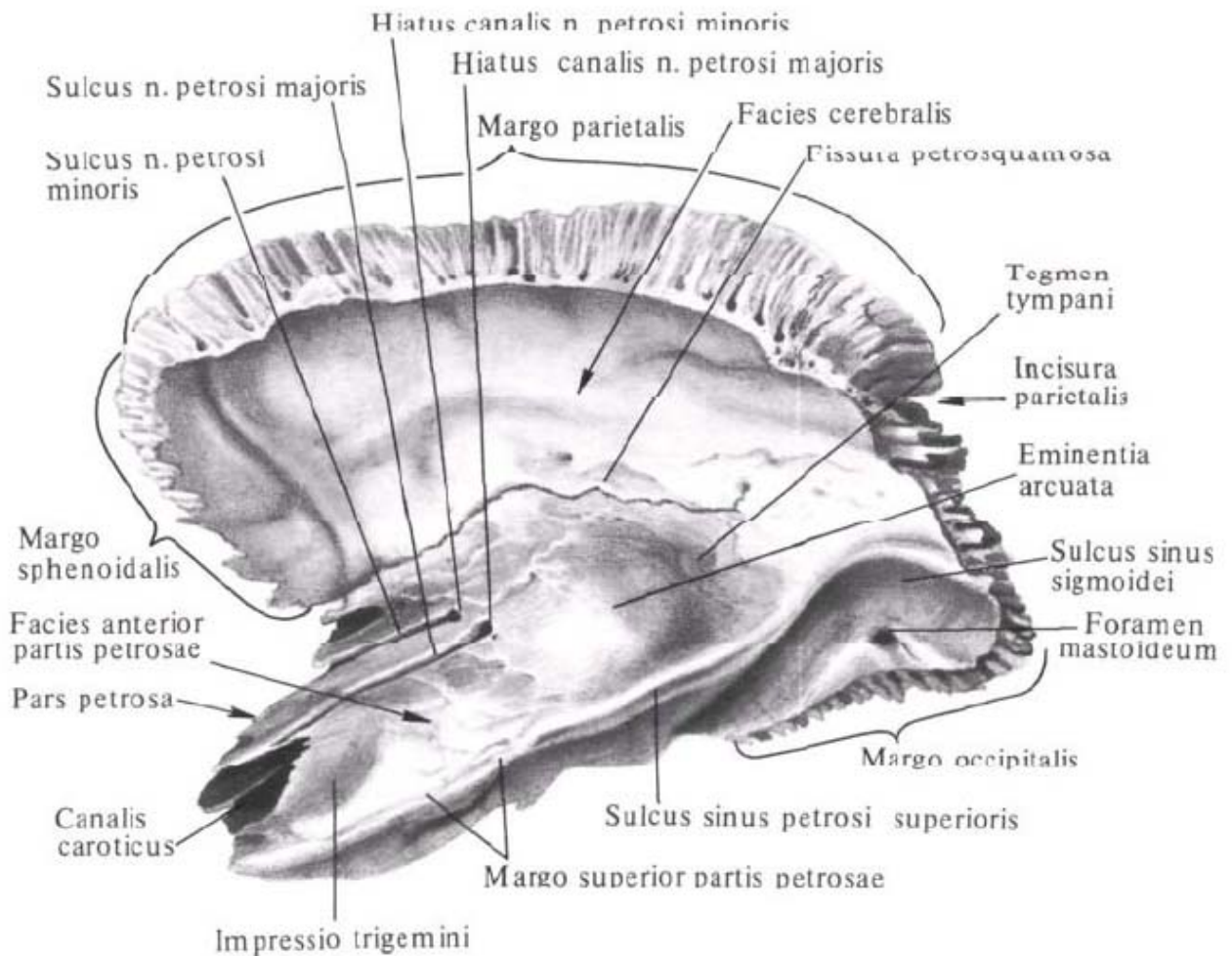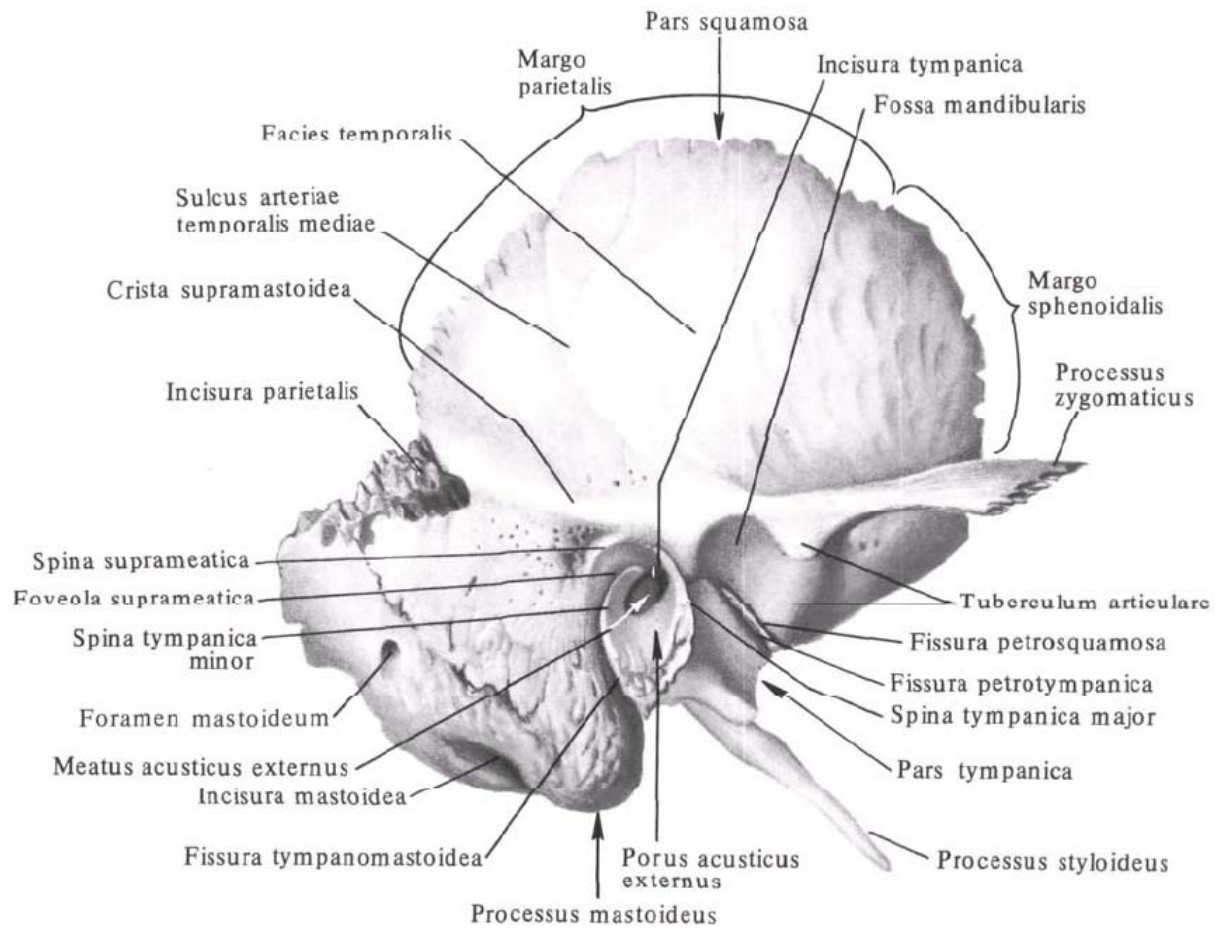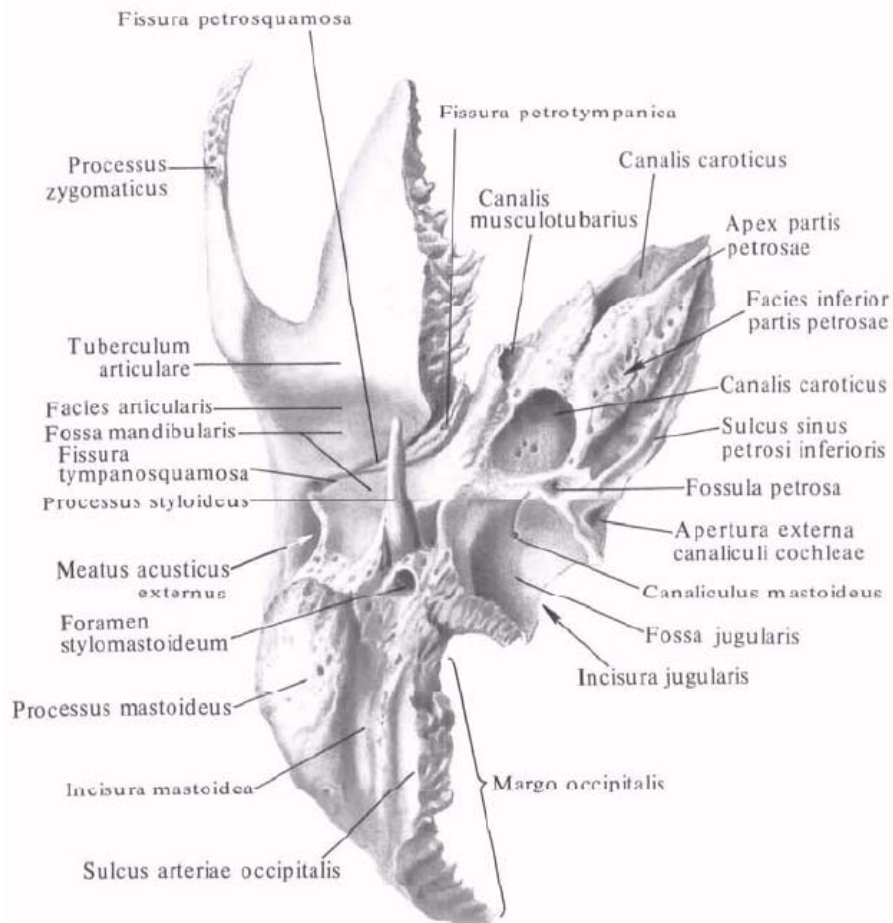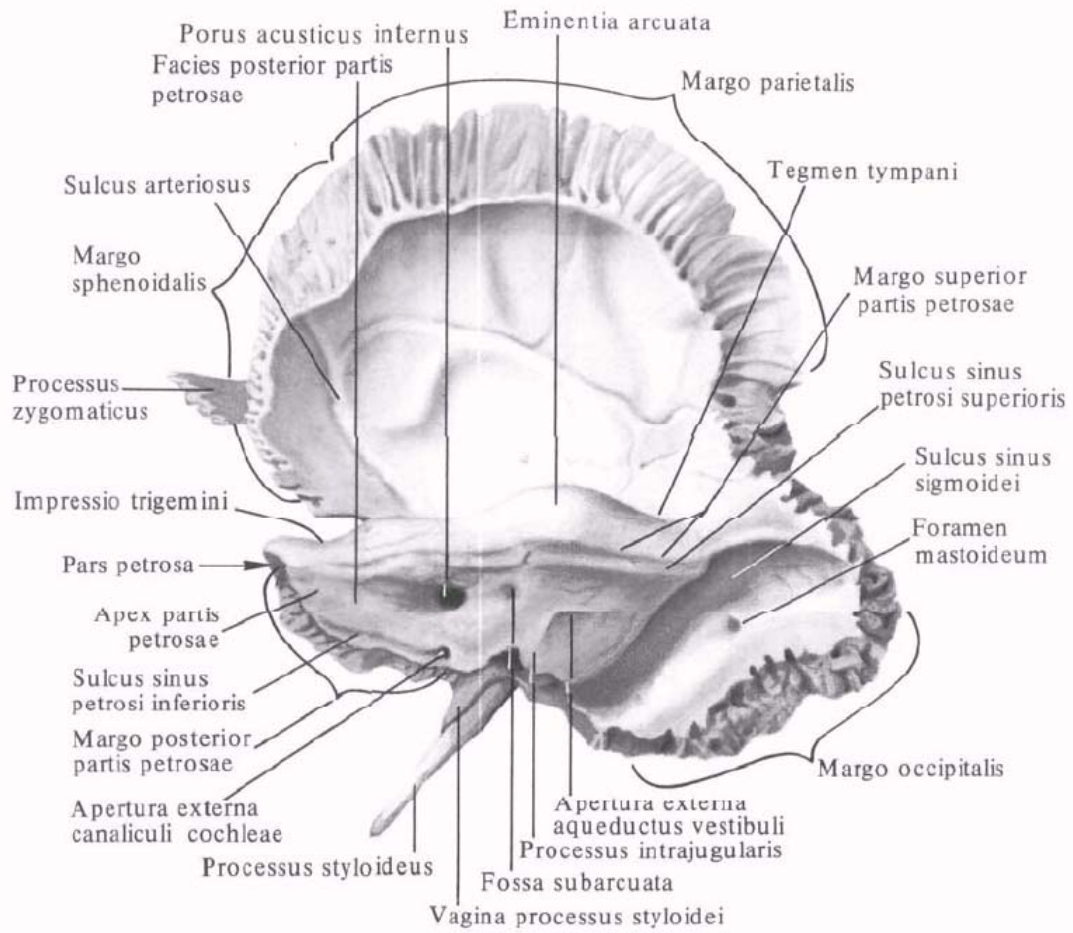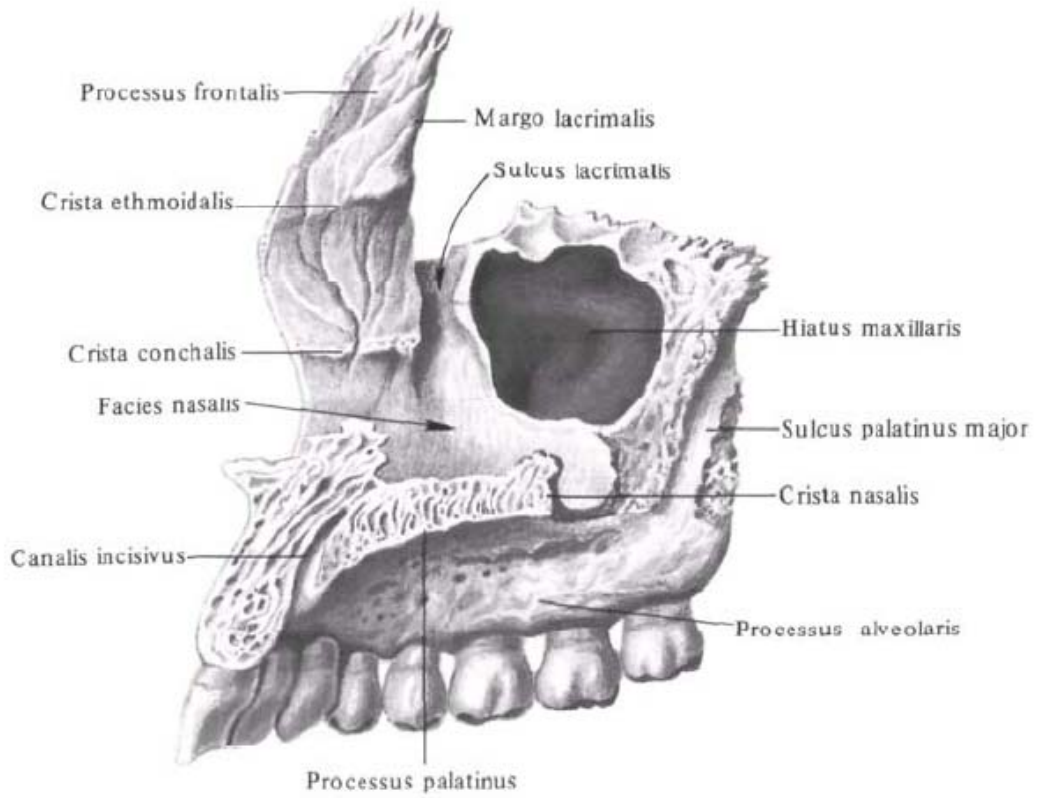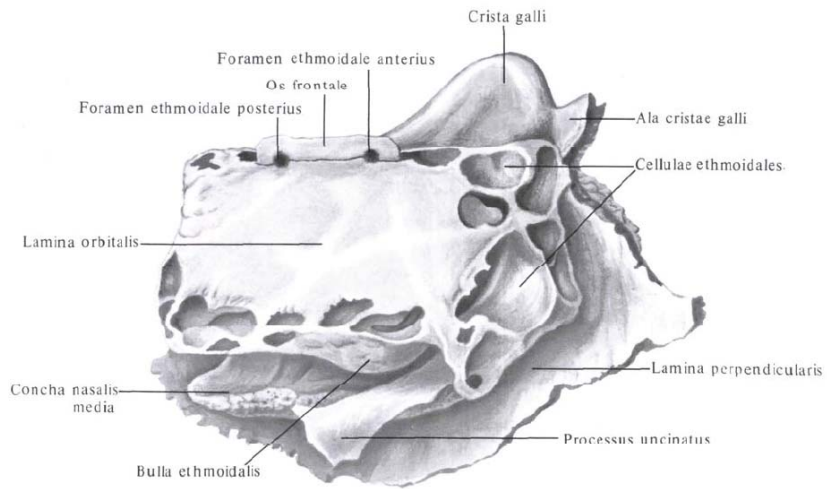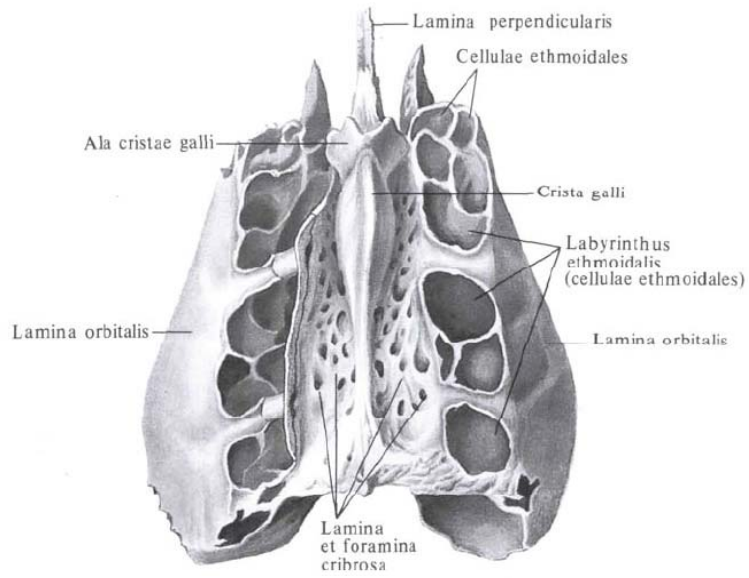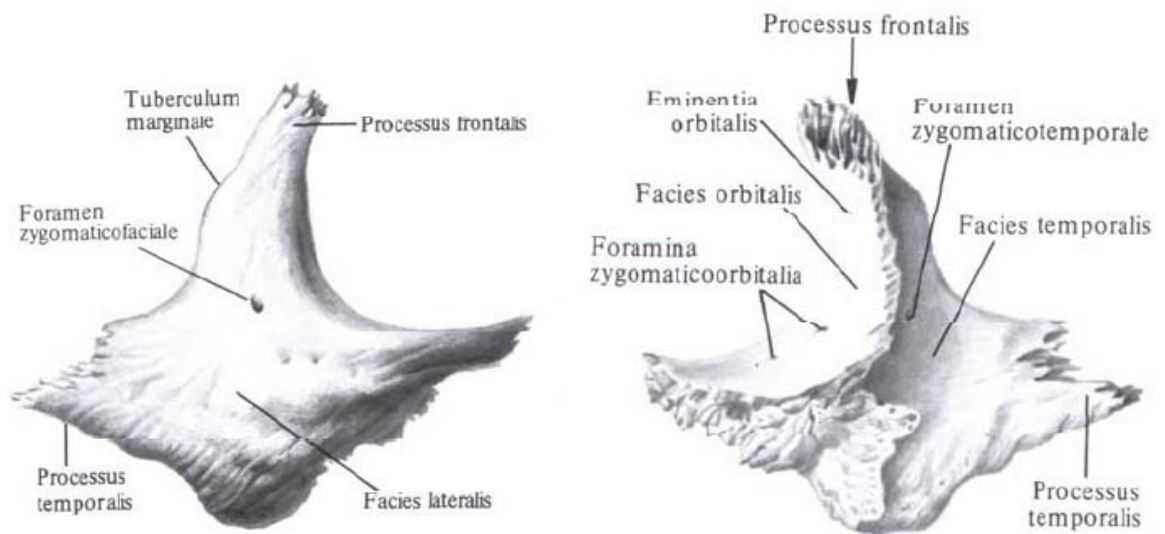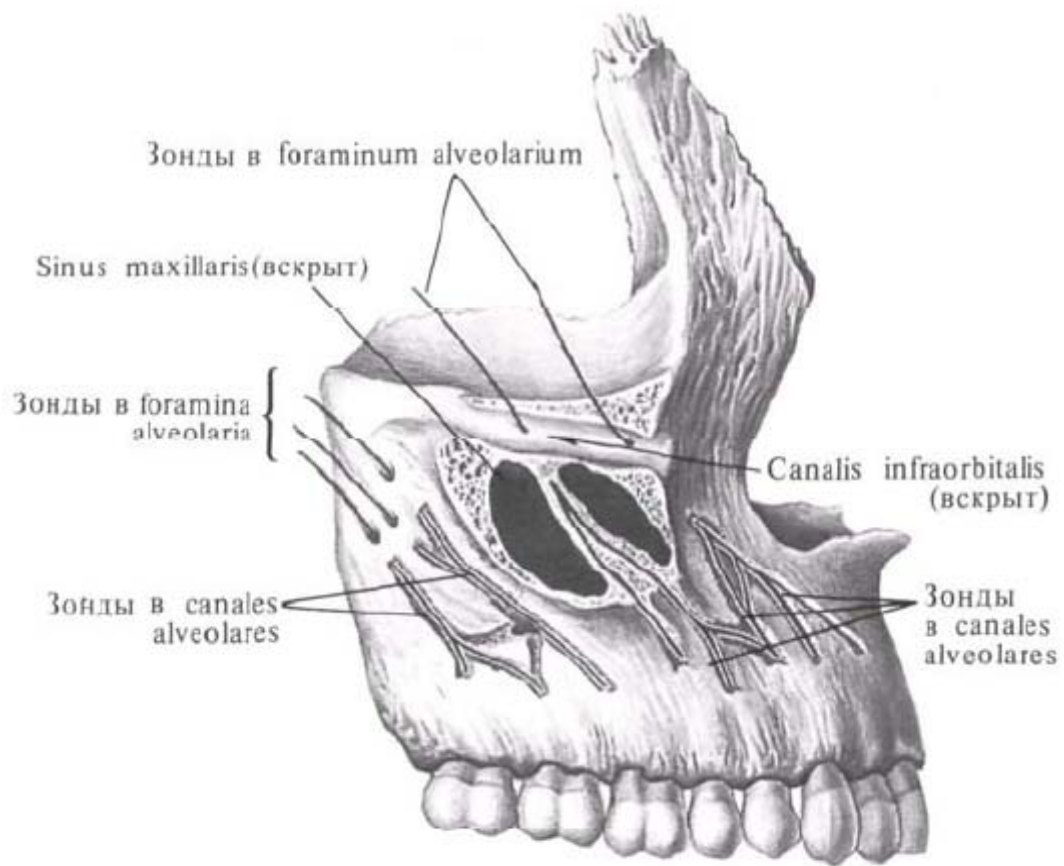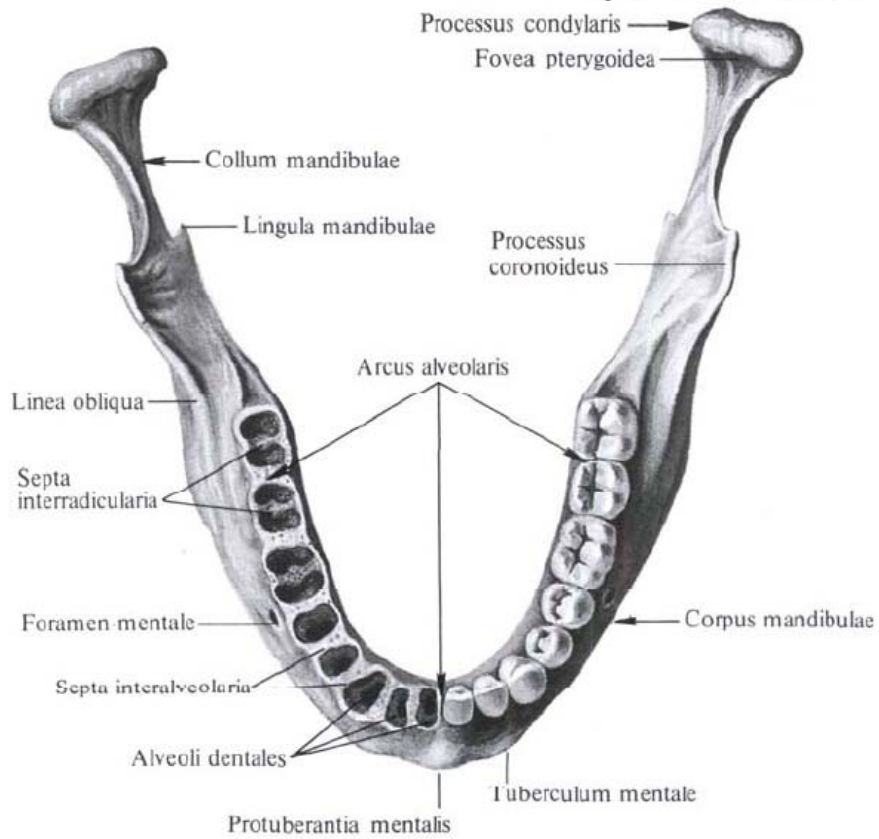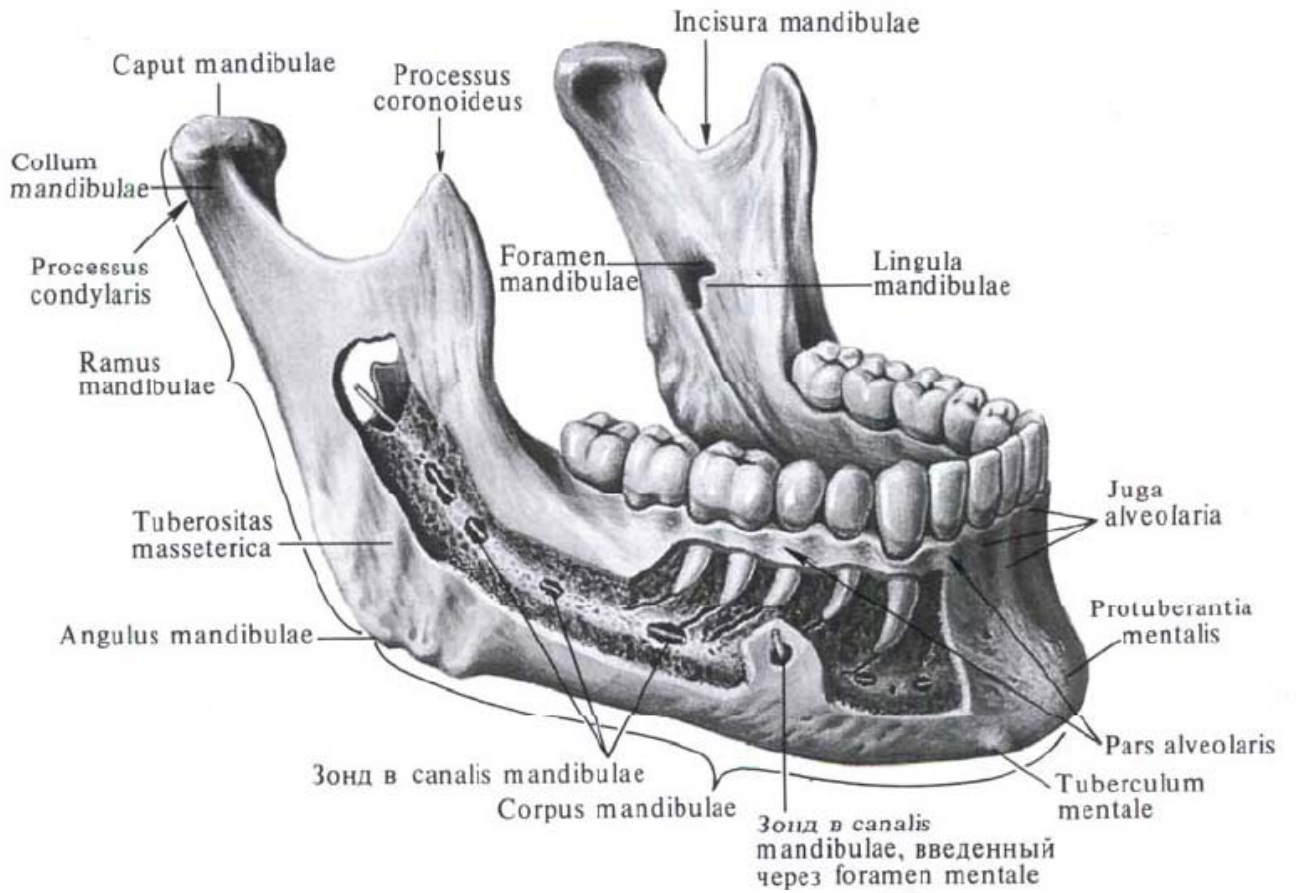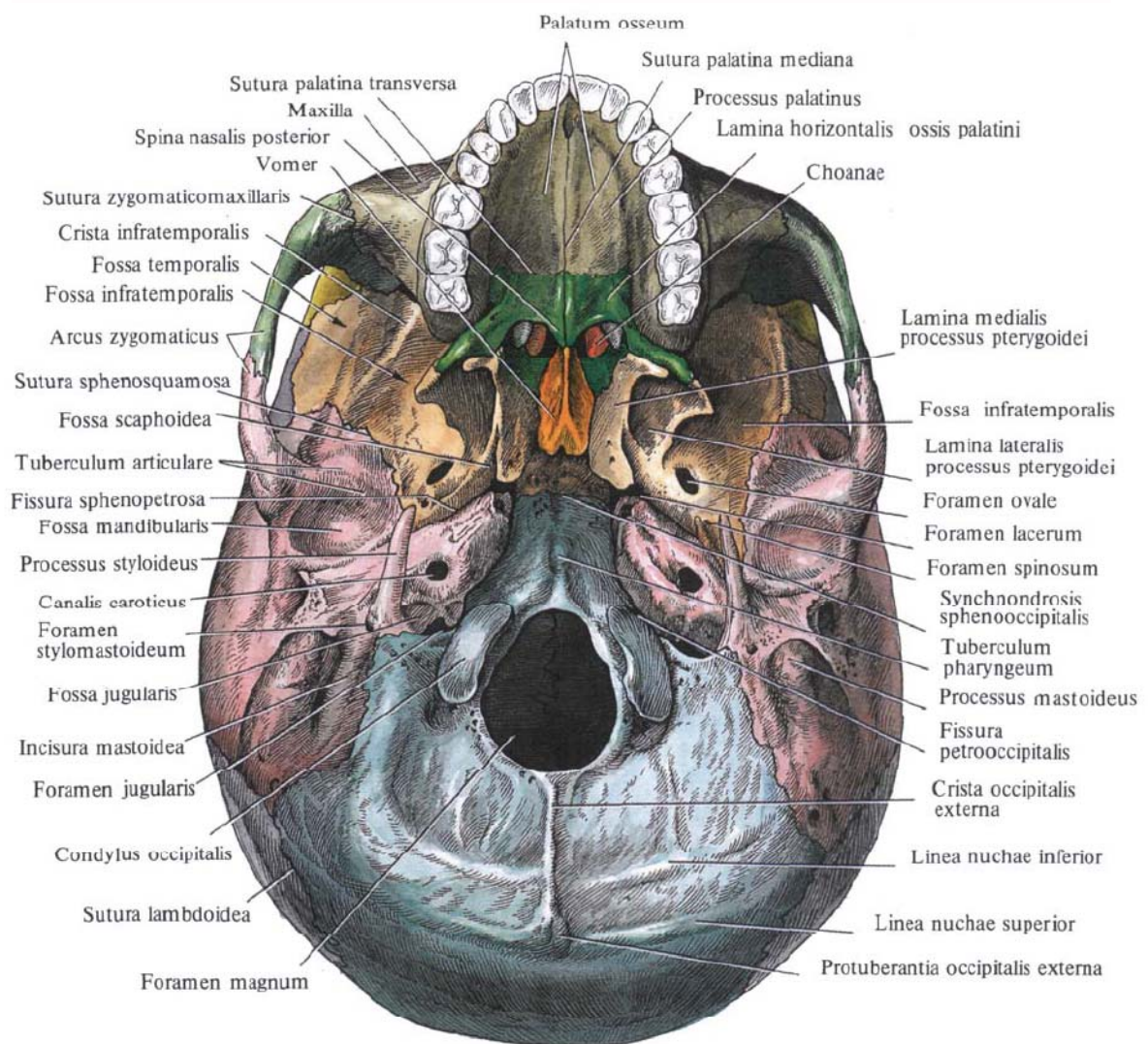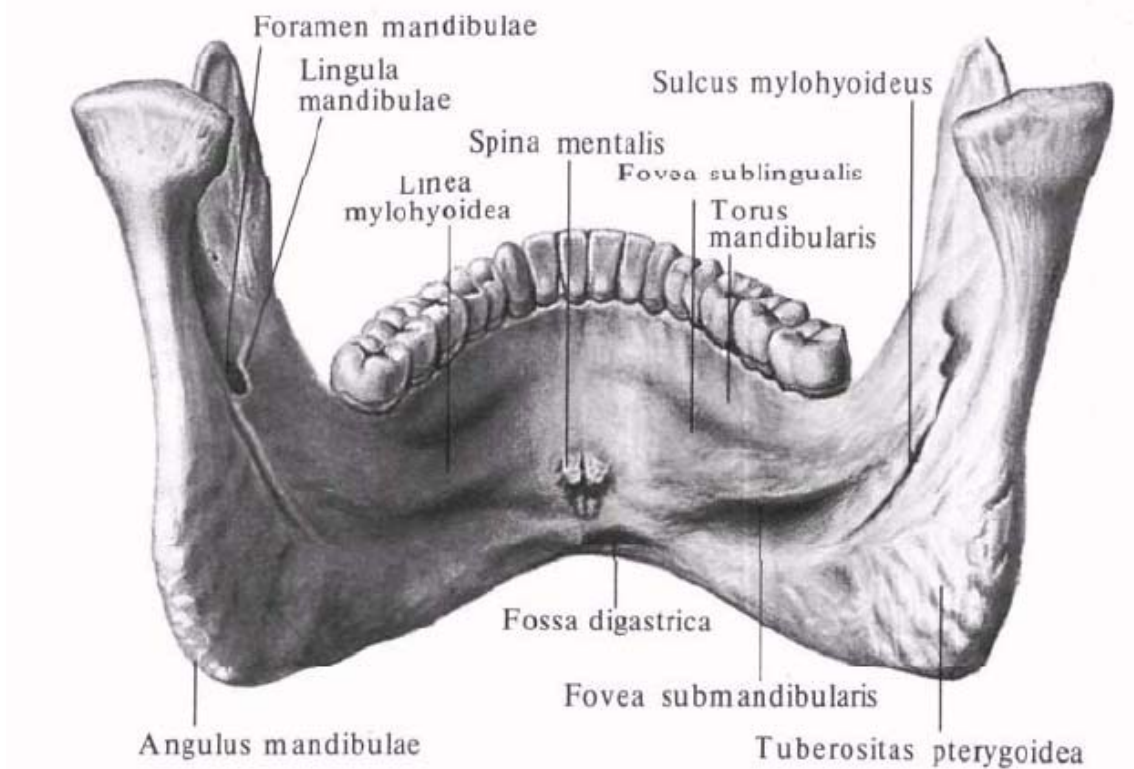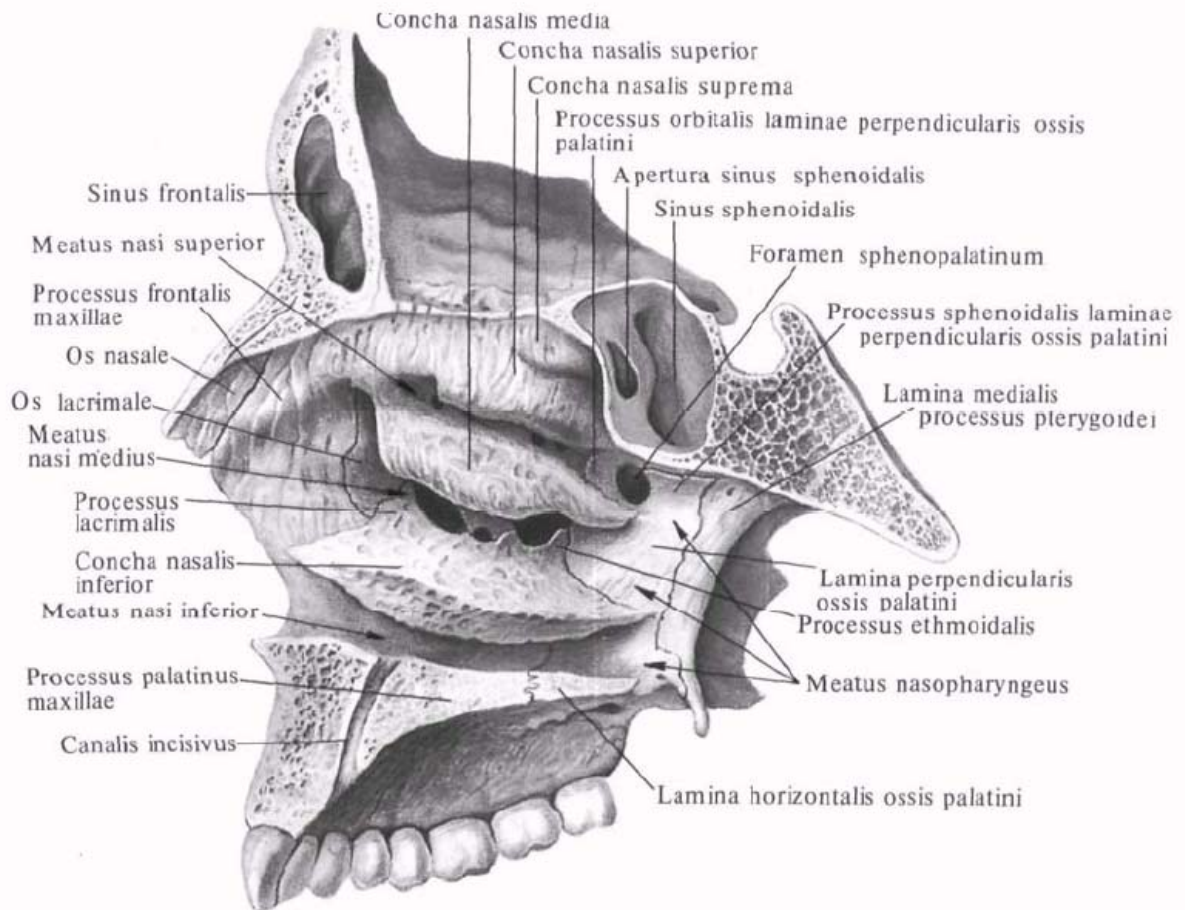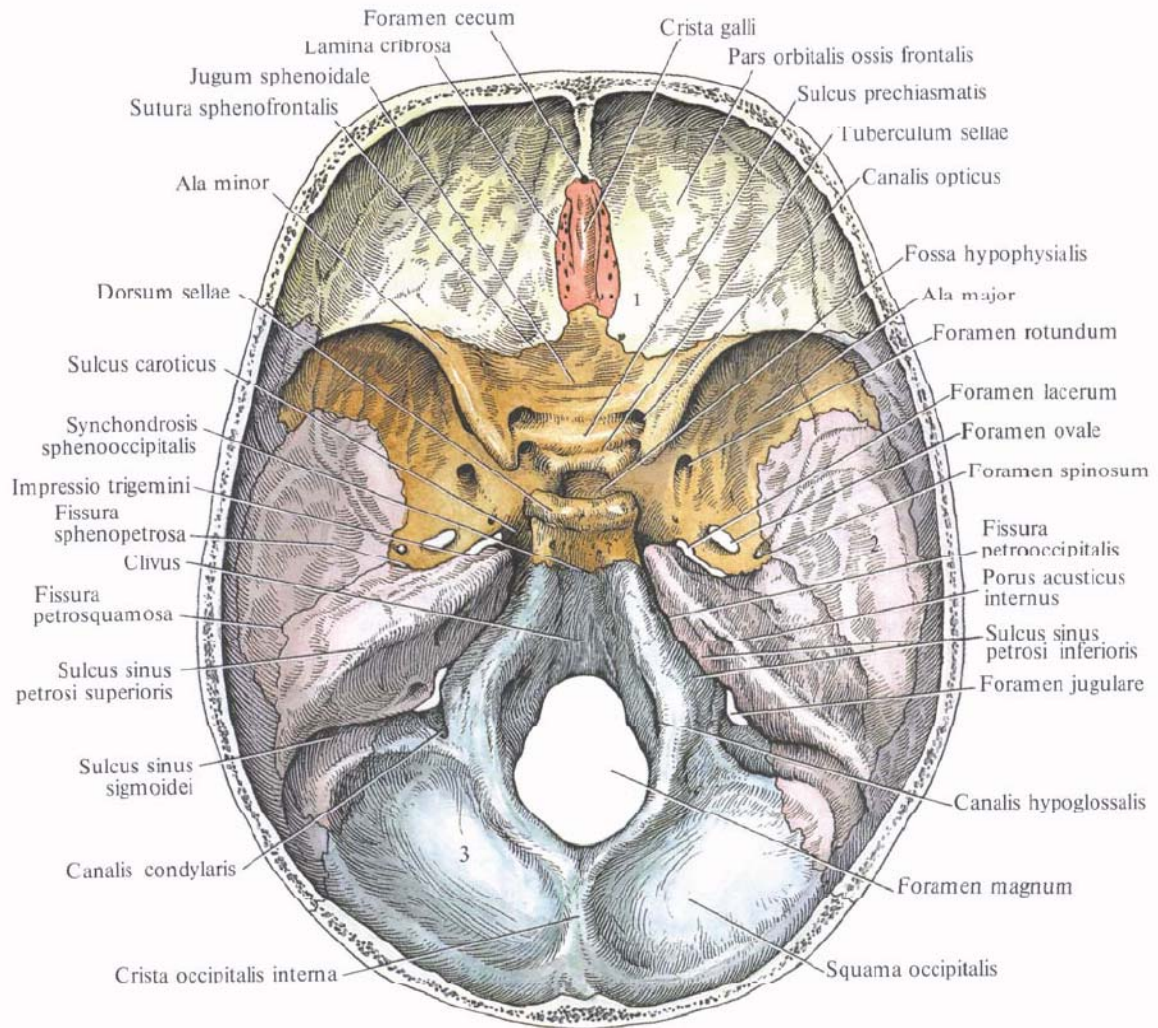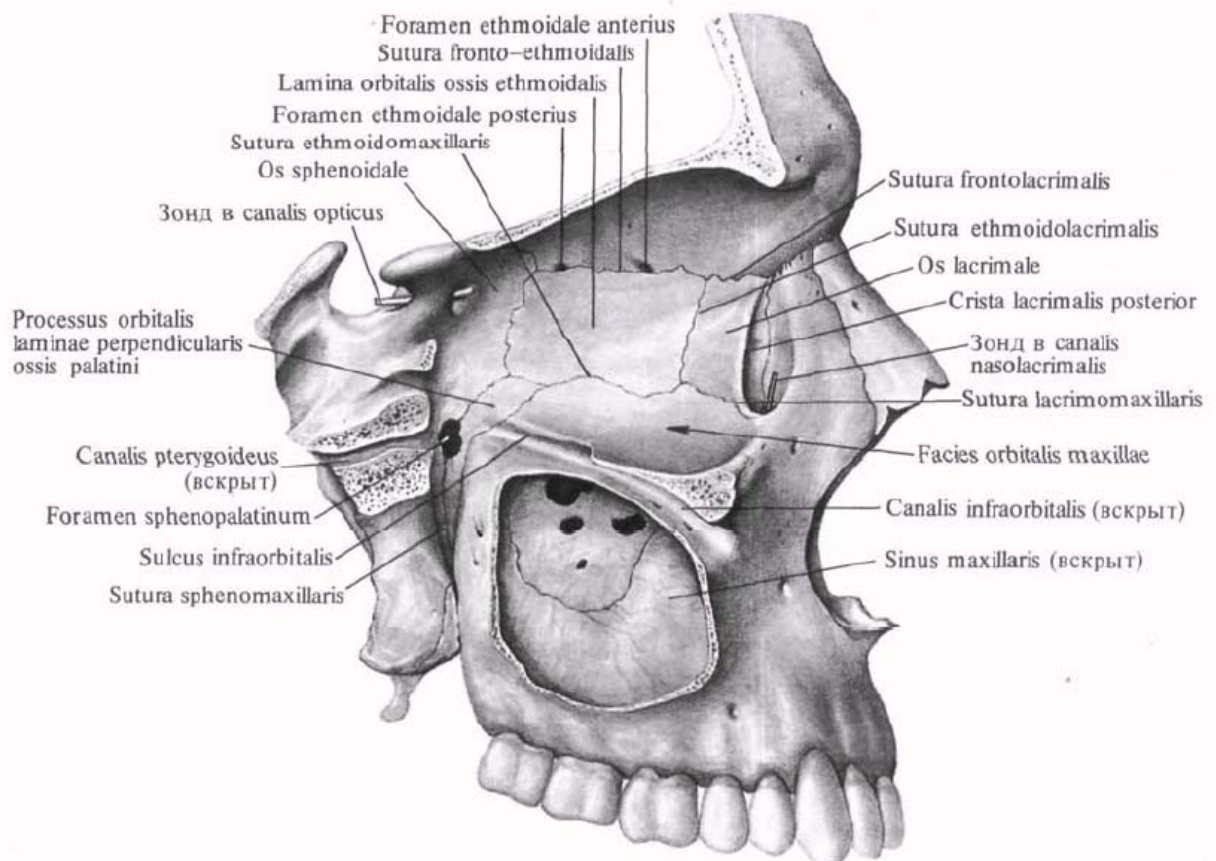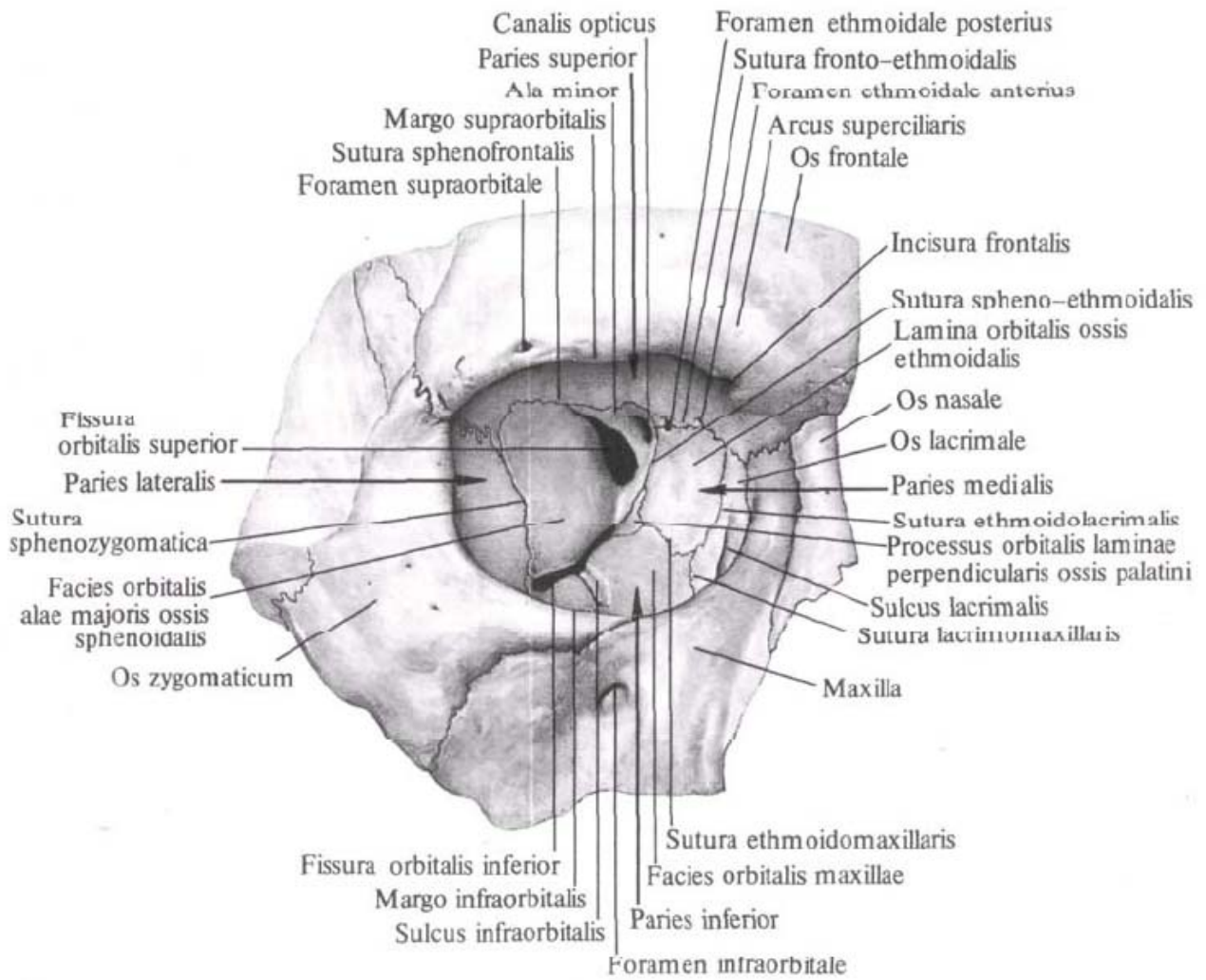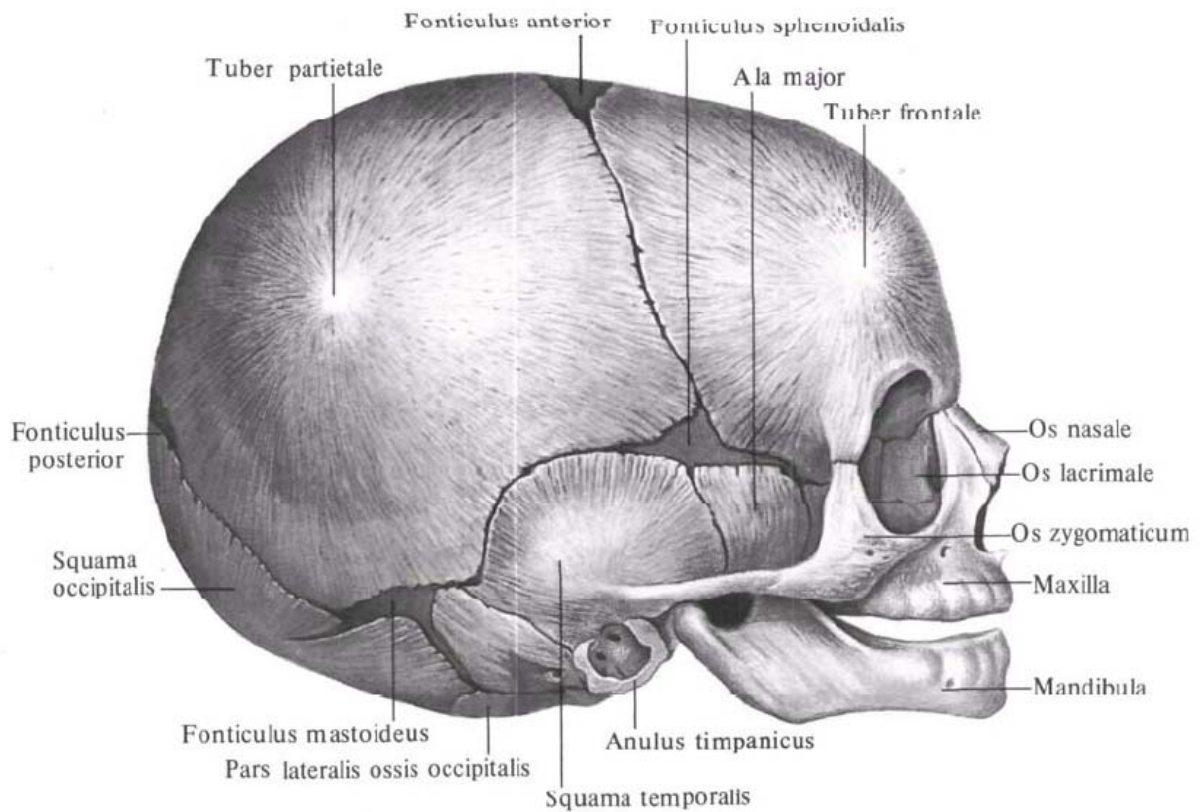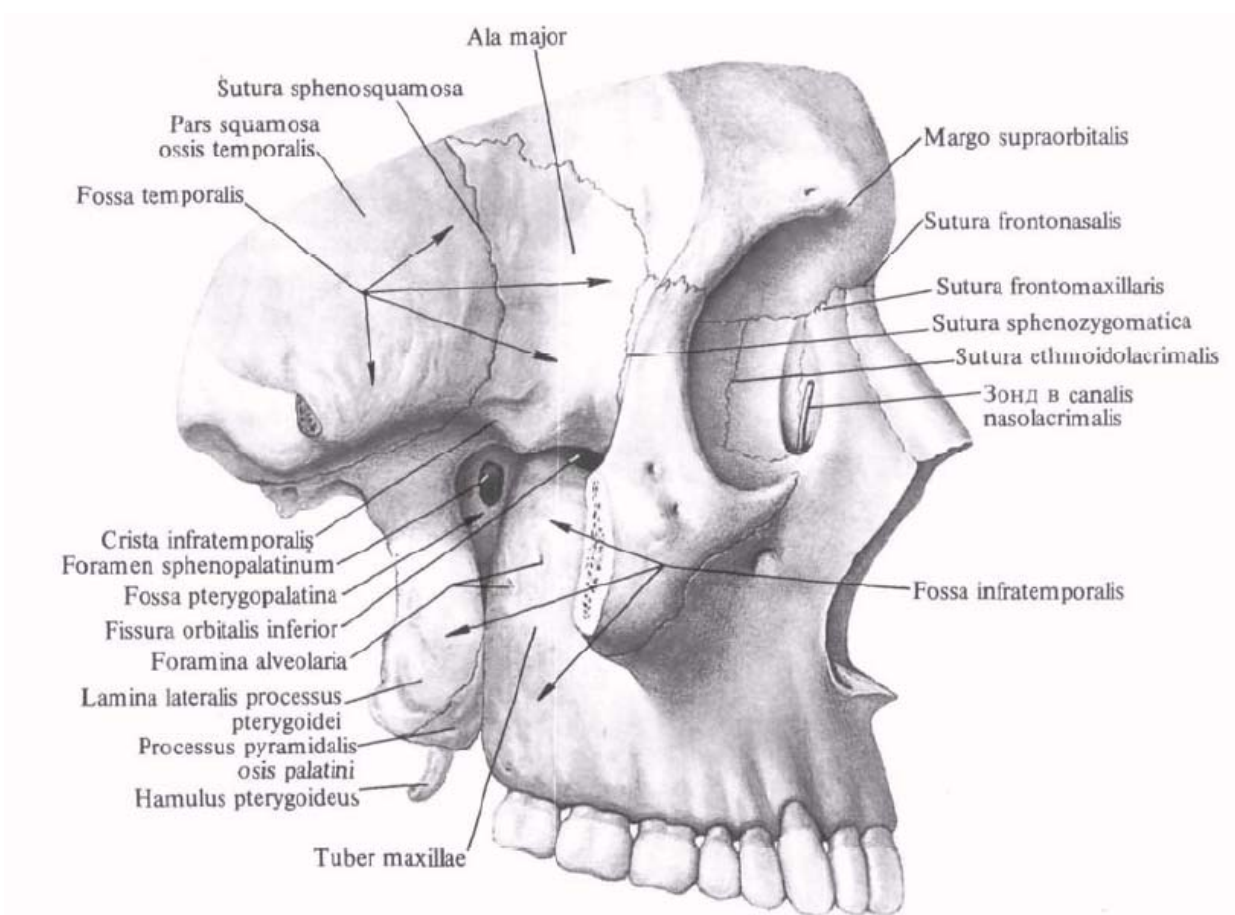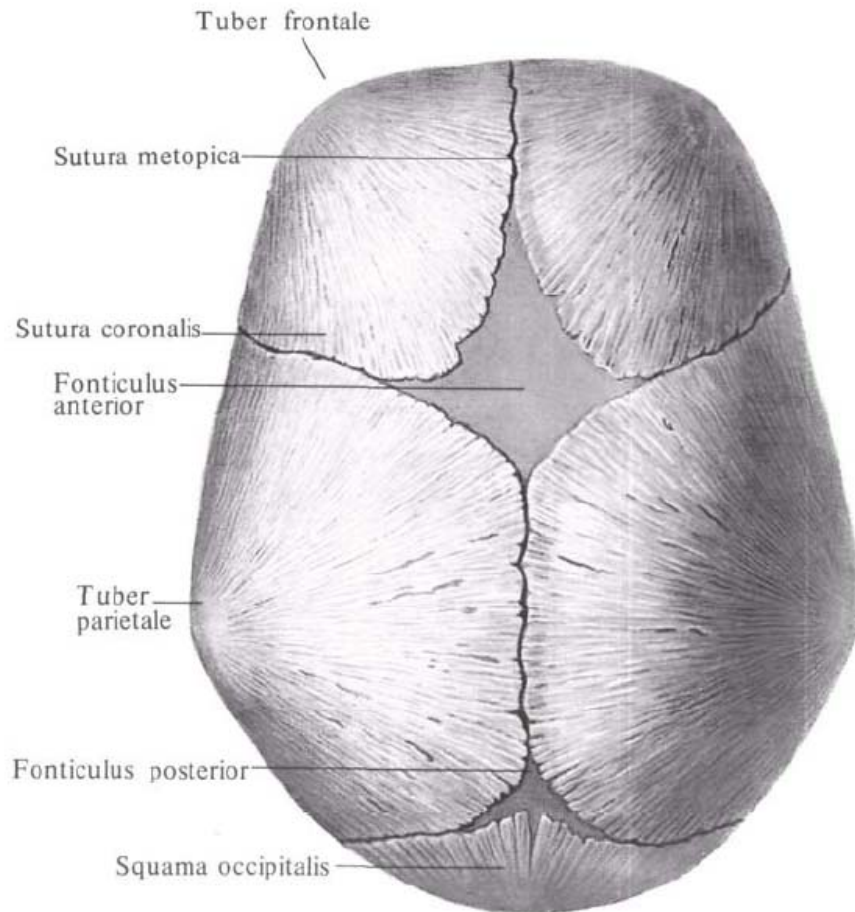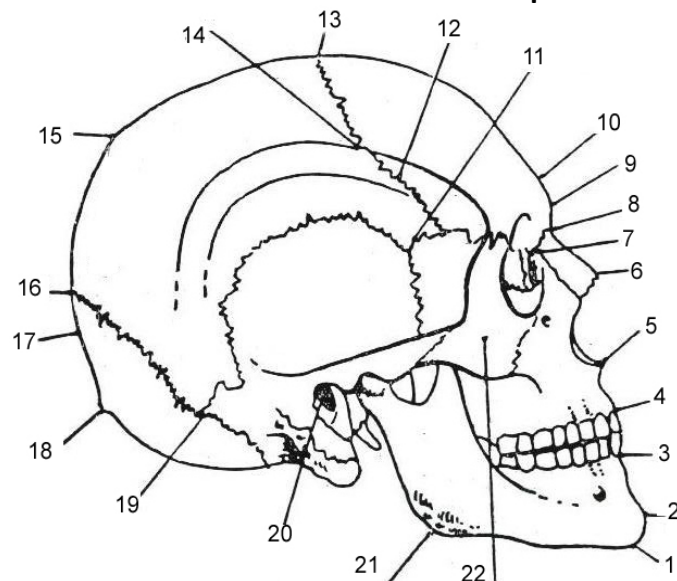


The scheme of the craniometrical points



1 – gnathion;

2 – spina mentalis;

3 – punctum incisivum inferius;

4 – punctum incisivum superius;

5 – punctum nasospinale;

6 – rhinion;

7 – dakrion;

8 – nasion;

9 – glabella;

10 – ophrion;

11 – pterion;

12 – sutura coronalis;

13 – bregma;

14 – stephanion;

15 – obelion;

16 – lambda;

17 – opistocranion;

18 – inion;

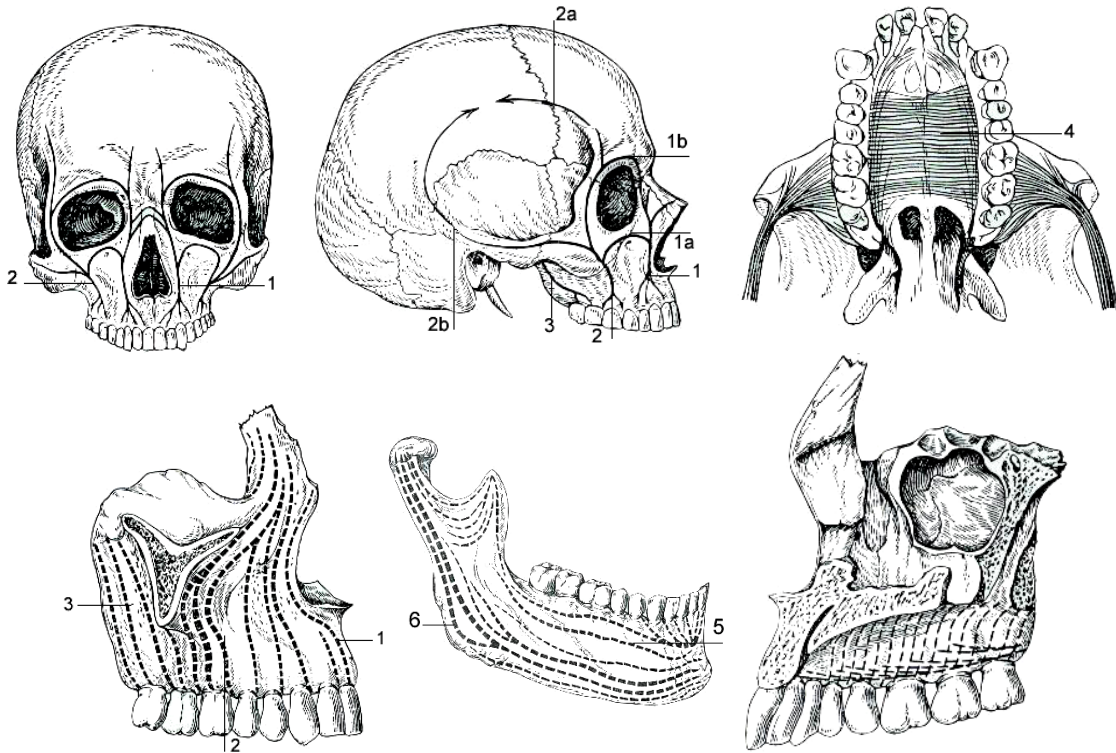
19 – asterion;

20 – punctum auriculare;

21 – gonion;

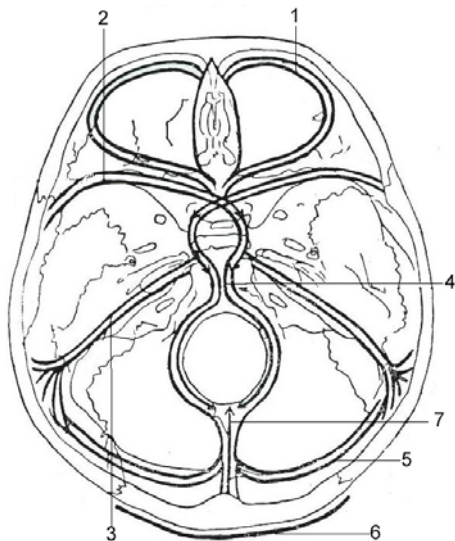
22 – punctum ossis zygomatici.

Presistance of pillars of the visceral cranium

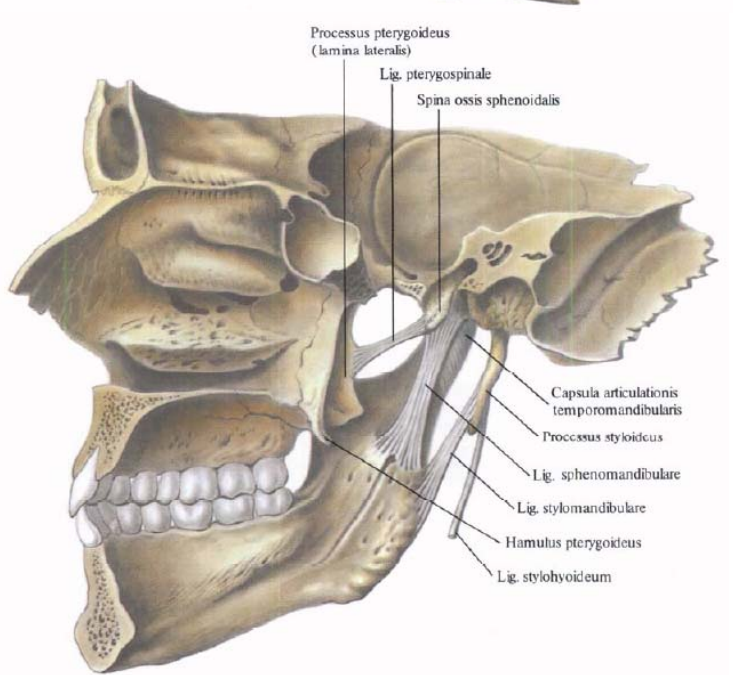
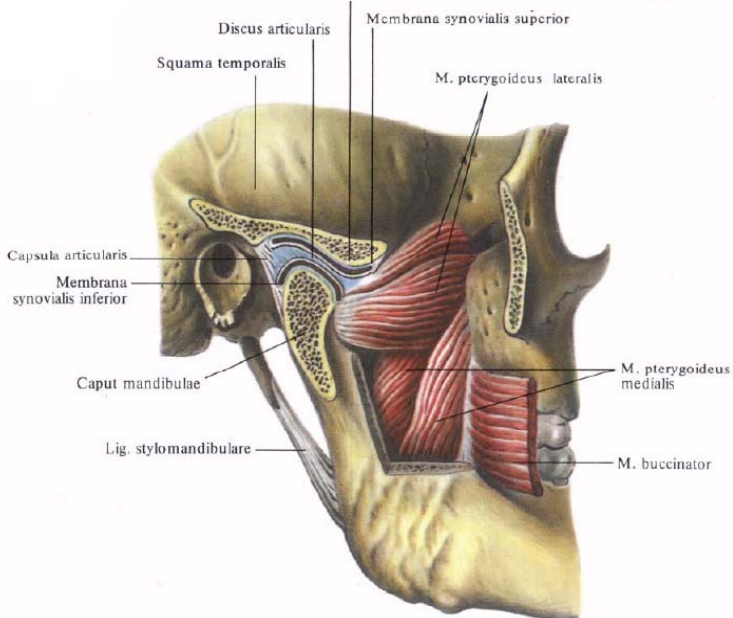
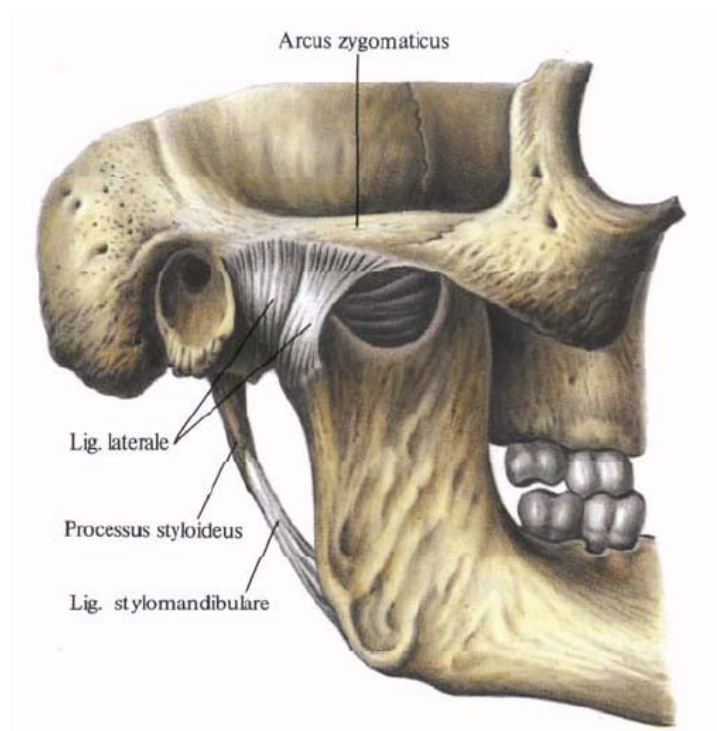


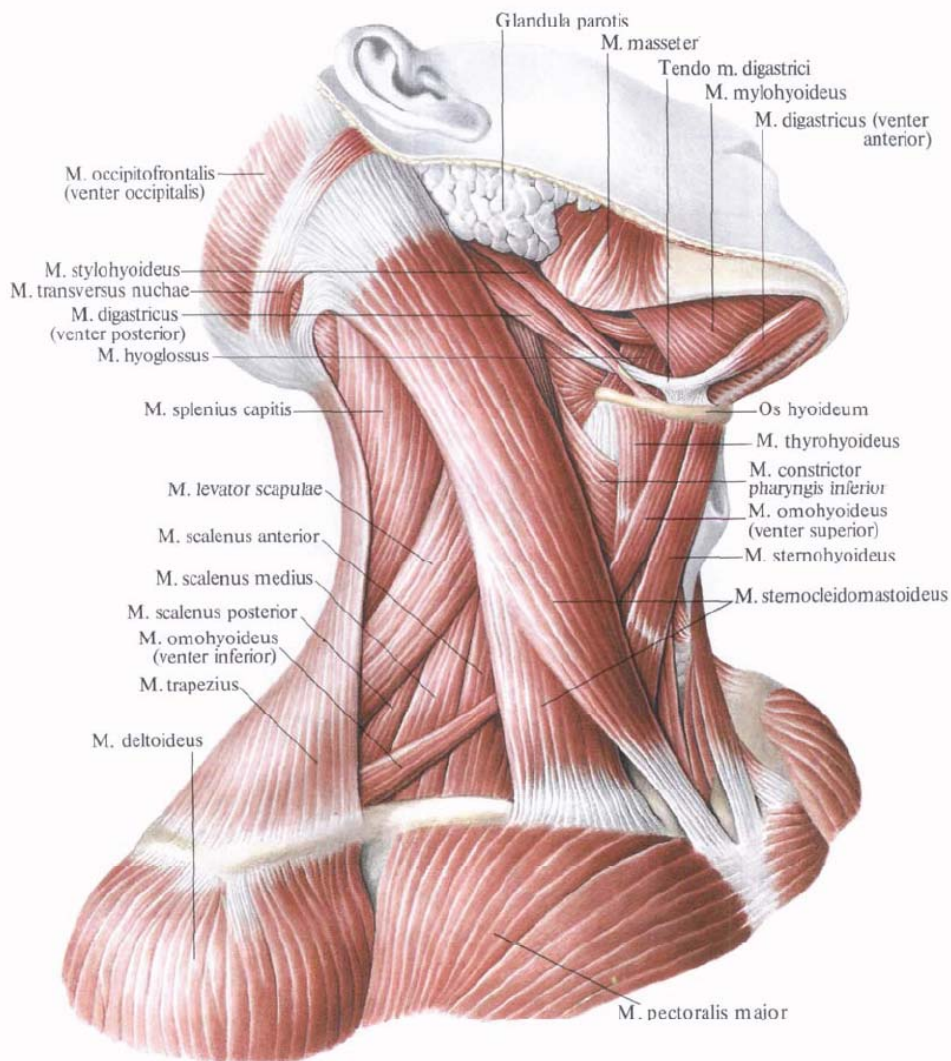
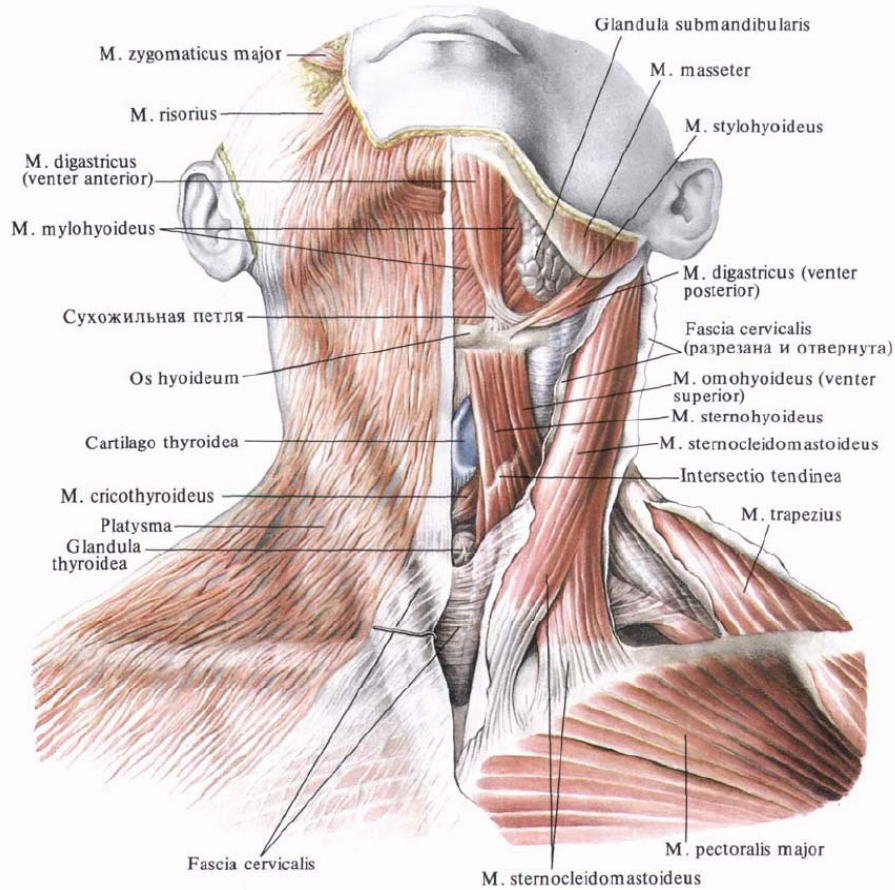
1. *Sustentaculum (columna, linea sustentaculi) anterius (caninum seu nasofrontale);*
1a. linea infraorbitalis;
1b. linea supraorbitalis;
2. *Sustentaculum medium (zygomaticum seu alveolo-zygomaticum);*
2a. linea anterior;
2b. linea posterior;
3. *Sustentaculum posterius (pterygopalatinum seu pterygoideum);*
4. *Linea resistentiae palati (palati ossei);*
5. *Linea trajecta alveolaris;*
6. *Linea trajecta ascendens.*

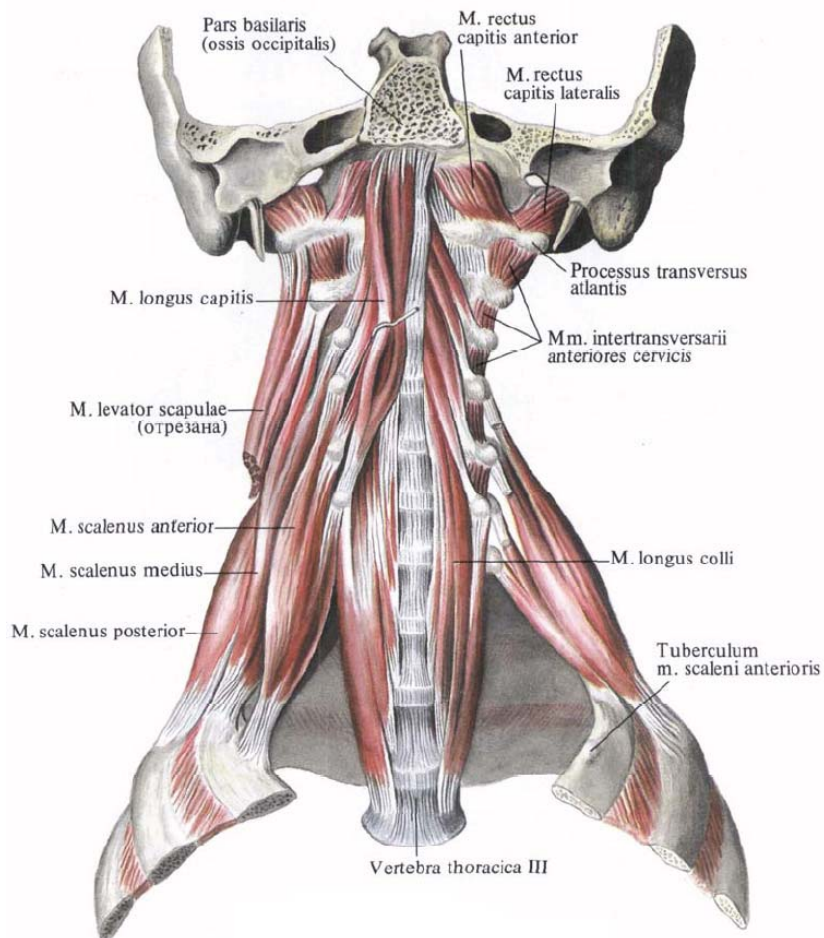
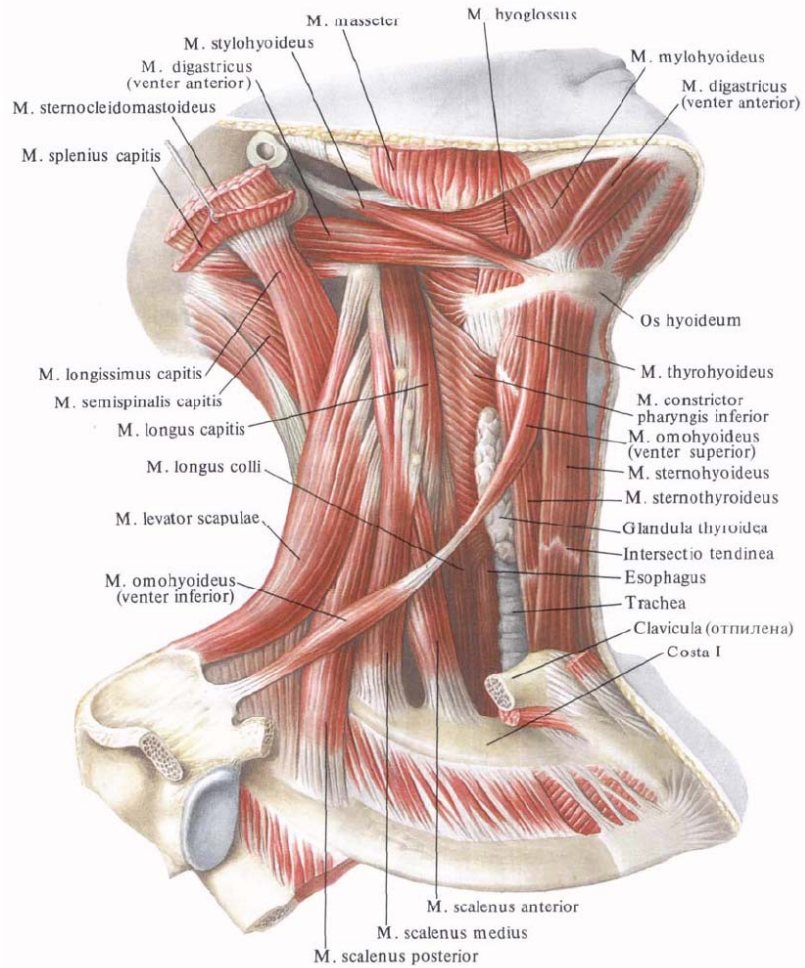
Structures of resistance of the base of the skull. The lines of most frequent fractures

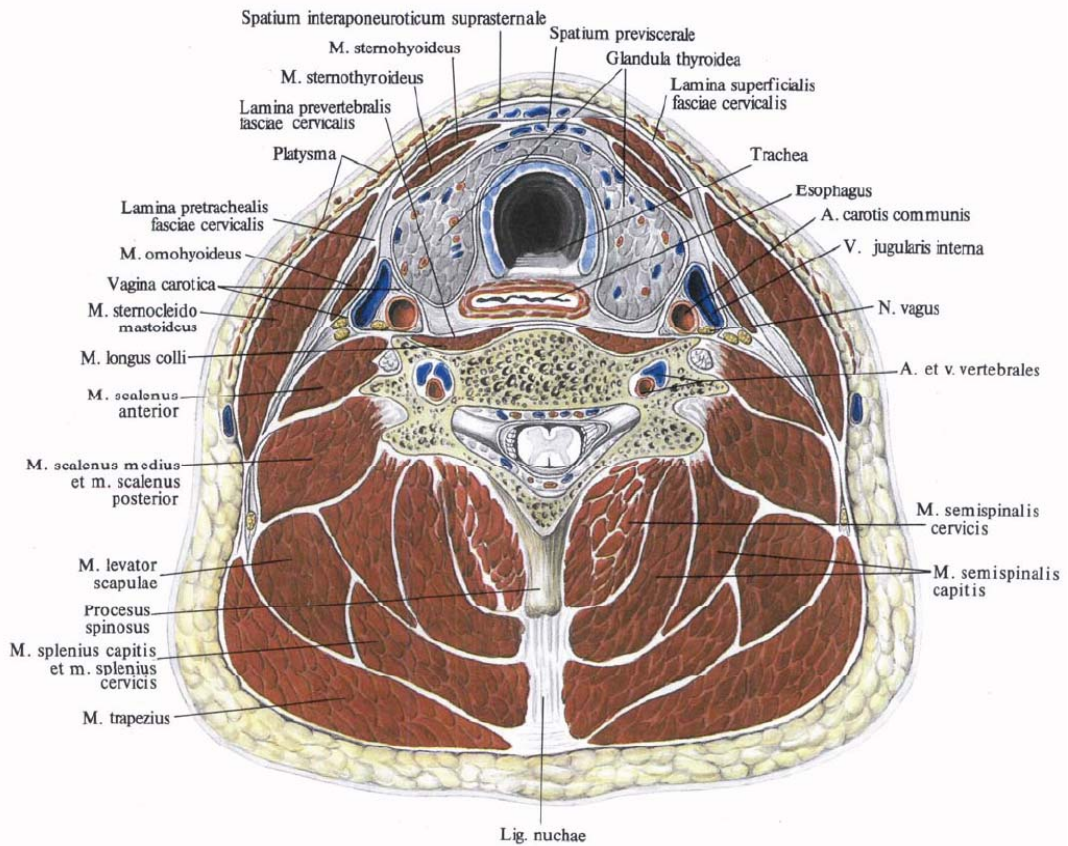
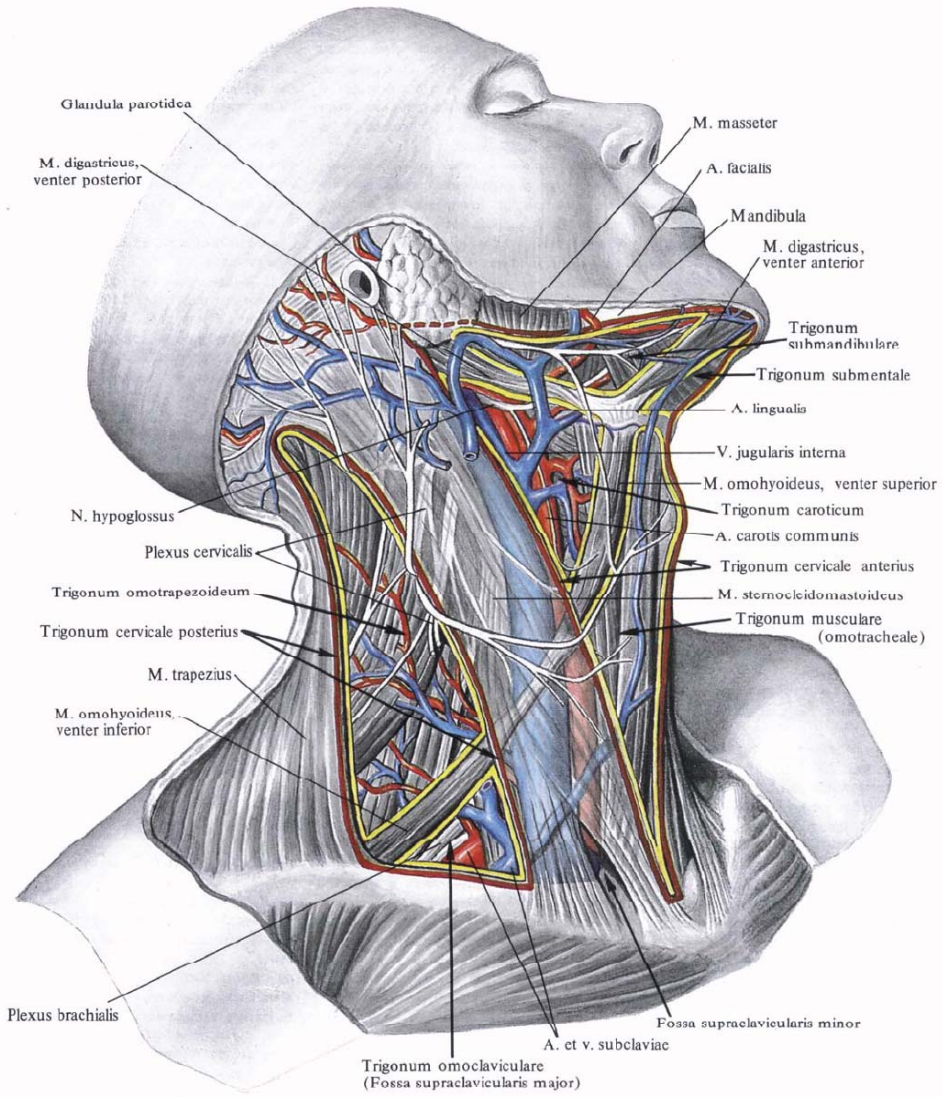


1. *Arcus orbitalis (arcus transversus I) (frontalis) [linea sustentaculi (resistentiae frontalis)];*
2. *Jugum sphenoidale et alae minores ossis sphenoidalis (arcus transversus II, orbitosphenoidalis seu columna anterior);*
3. *Margo inferior partium petrosarum temporalium (arcus transversus III, petromastoideus) posterior;*
4. *Basis ossea mediosagittalis;*
5. *Sinus transversus (arcus transversus IV);*
6. *Linea resistentiae occipitalis.*

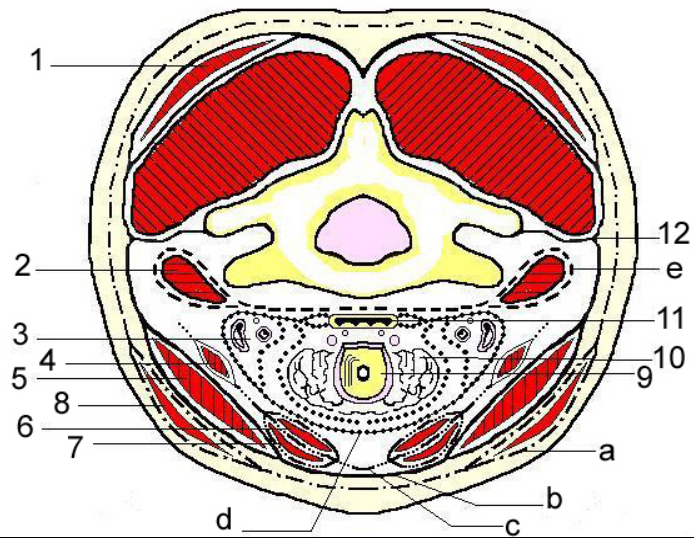






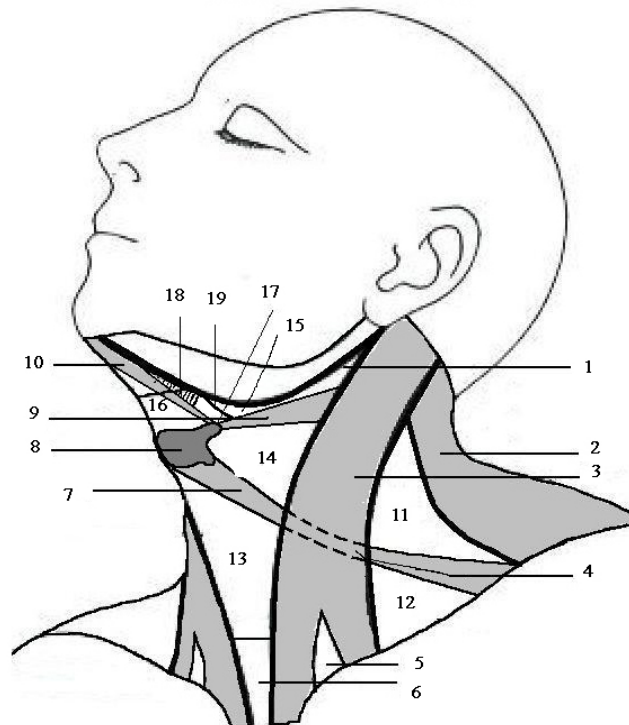


Fascia of the neck

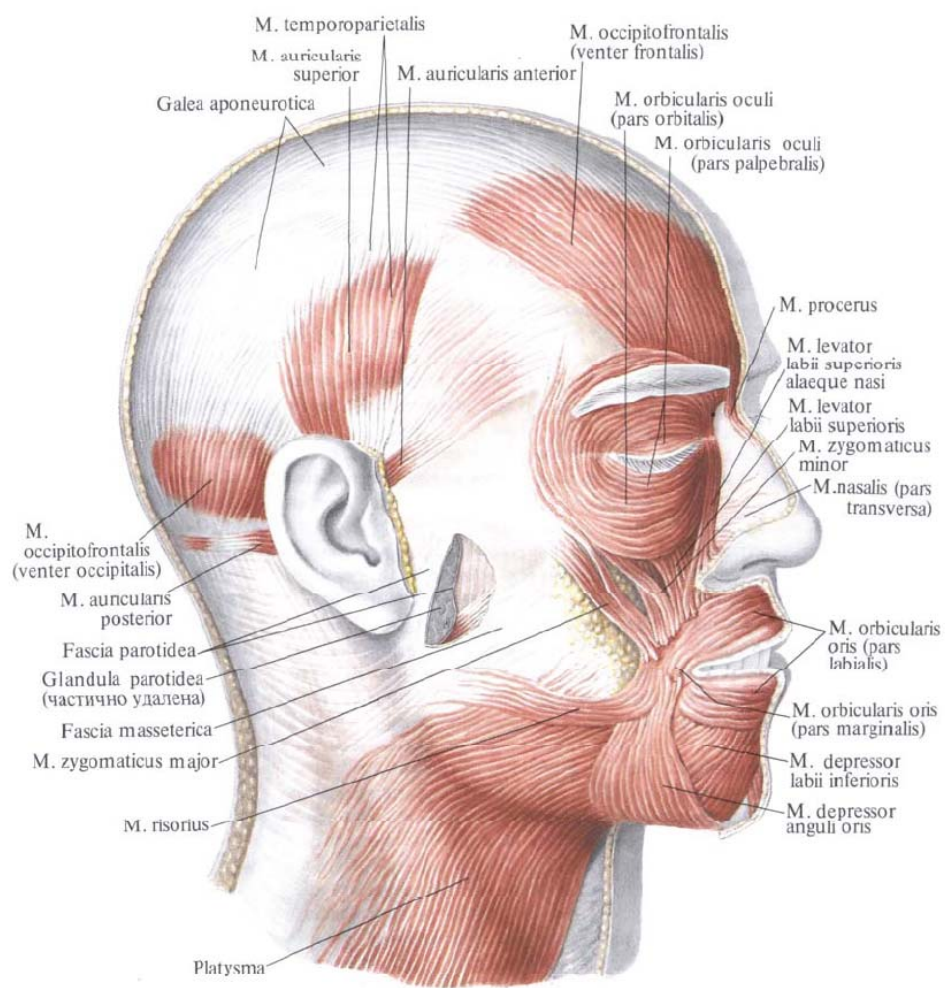
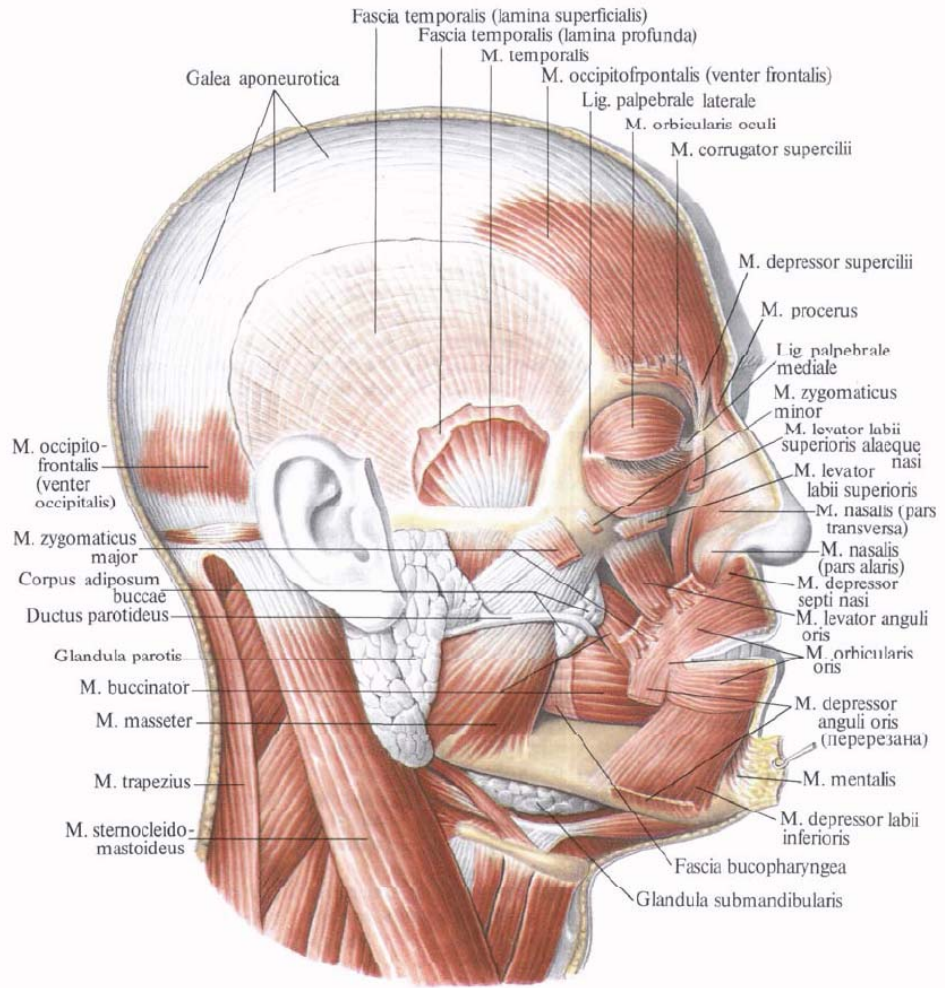


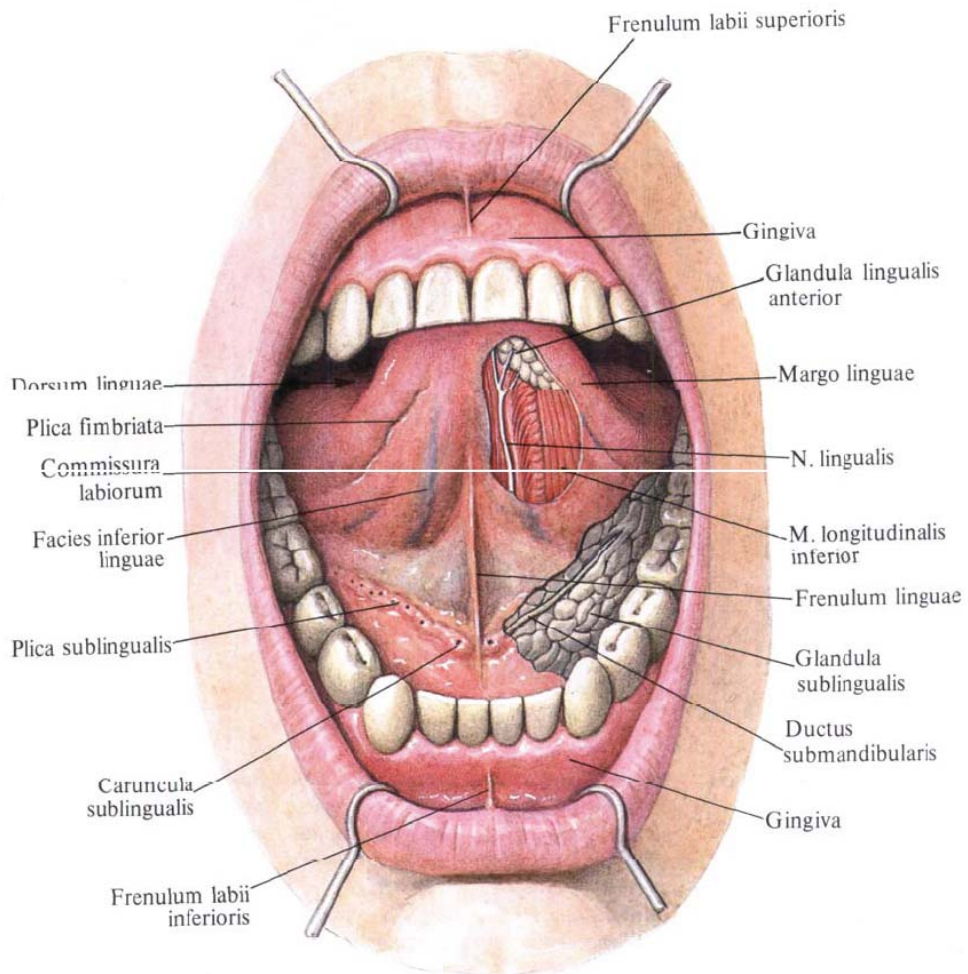
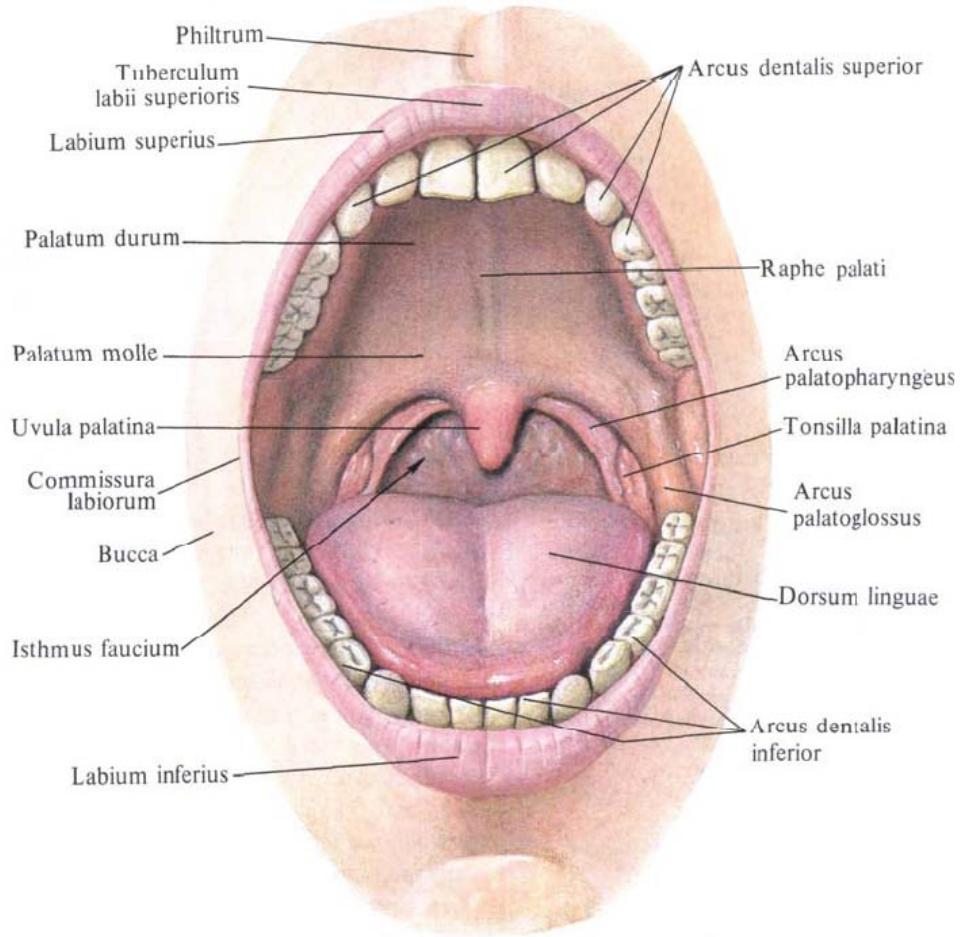
<p>1 – <i>m. trapezius</i>; 2 – <i>mm. scaleni et mm. prevertebrales</i>; 3 – <i>fasciculus neurovascularis</i>; 4 – <i>m. omohyoideus</i>; 5 – <i>m. sternocleidomastoideus</i>; 6 – <i>m. thyreochoideus</i>;</p>	<p>7 – <i>m. sternohyoideus</i>; 8 – <i>platysma</i>; 9 – <i>larynx</i>; 10 – <i>glandula thyroidea</i>; 11 – <i>oesophagus</i>; 12 – <i>septum intermusculare</i>.</p>
<p>a – <i>fascia colli superficialis (I)</i>; b – <i>lamina superficialis fasciae colli propriae (II)</i>; c – <i>lamina profunda fasciae colli propriae (III)</i>;</p>	<p>d – <i>fascia endocervicalis (lamina parietalis et visceralis) (IV)</i>; e – <i>fascia prevertebralis (V)</i>.</p>

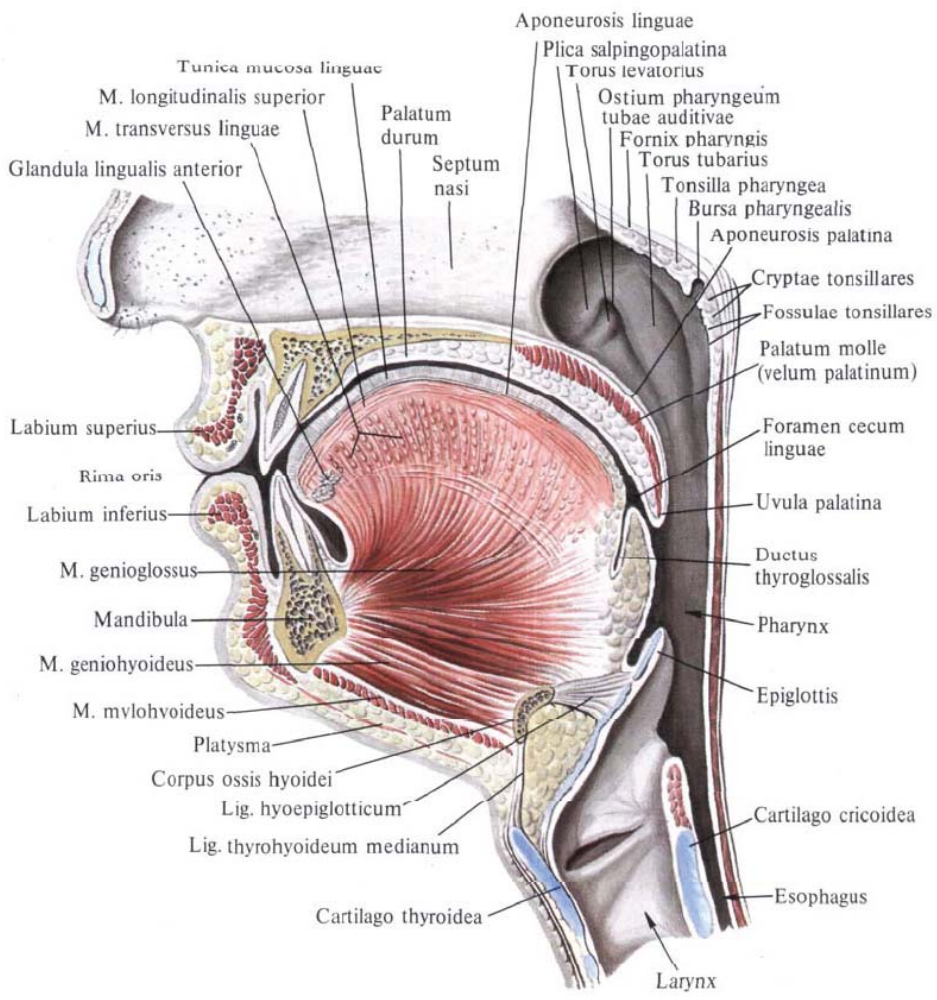
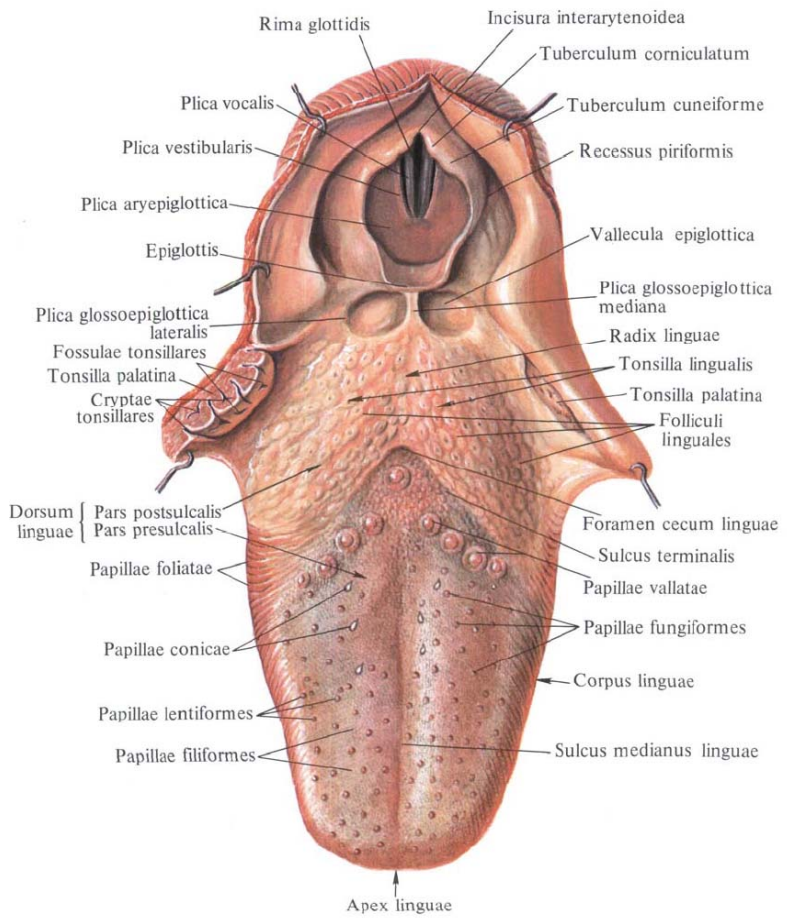
Triangles of the neck

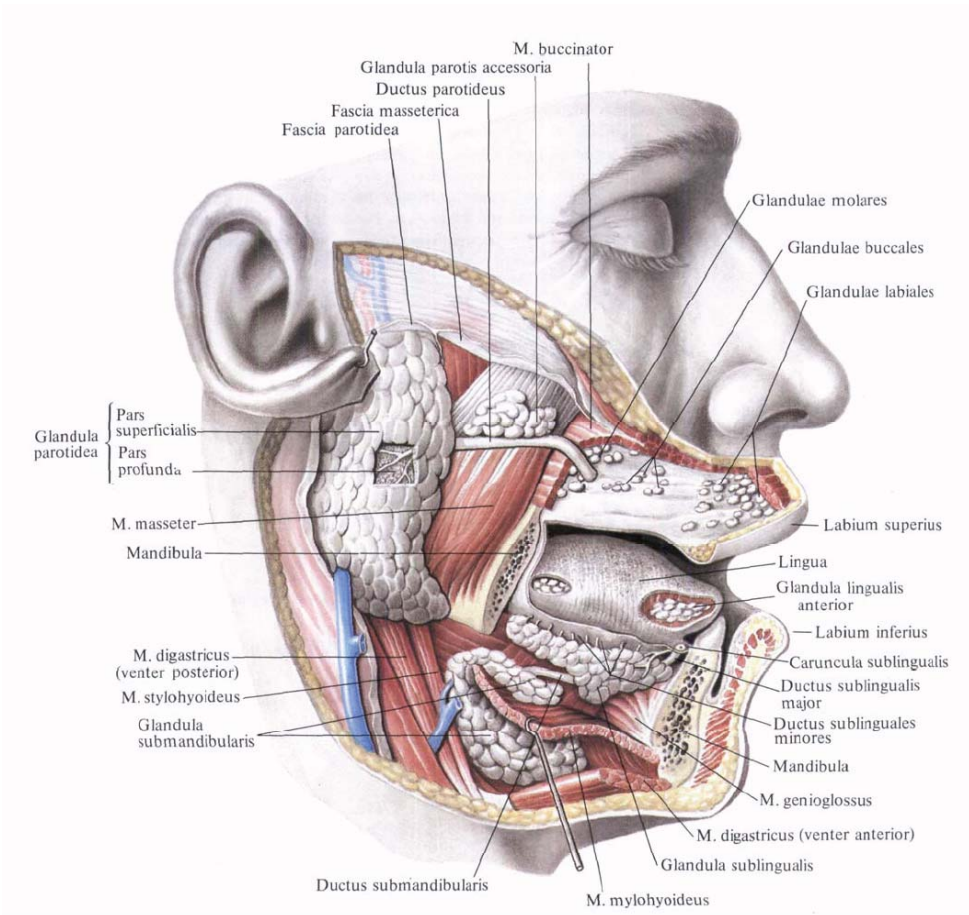
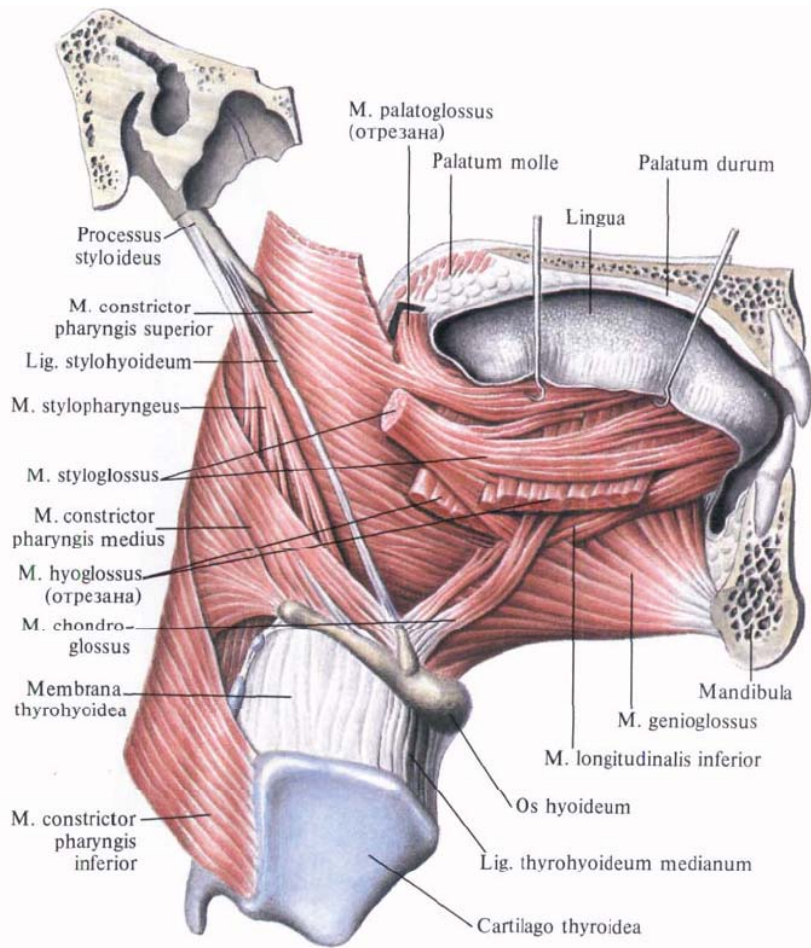


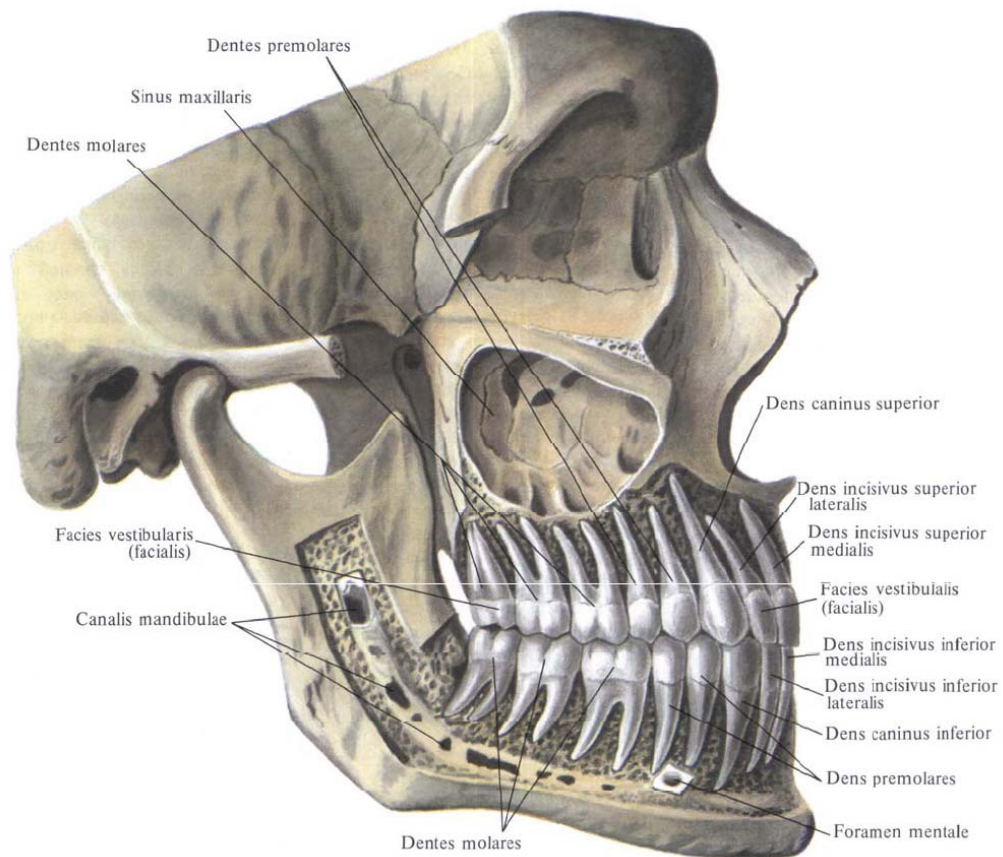
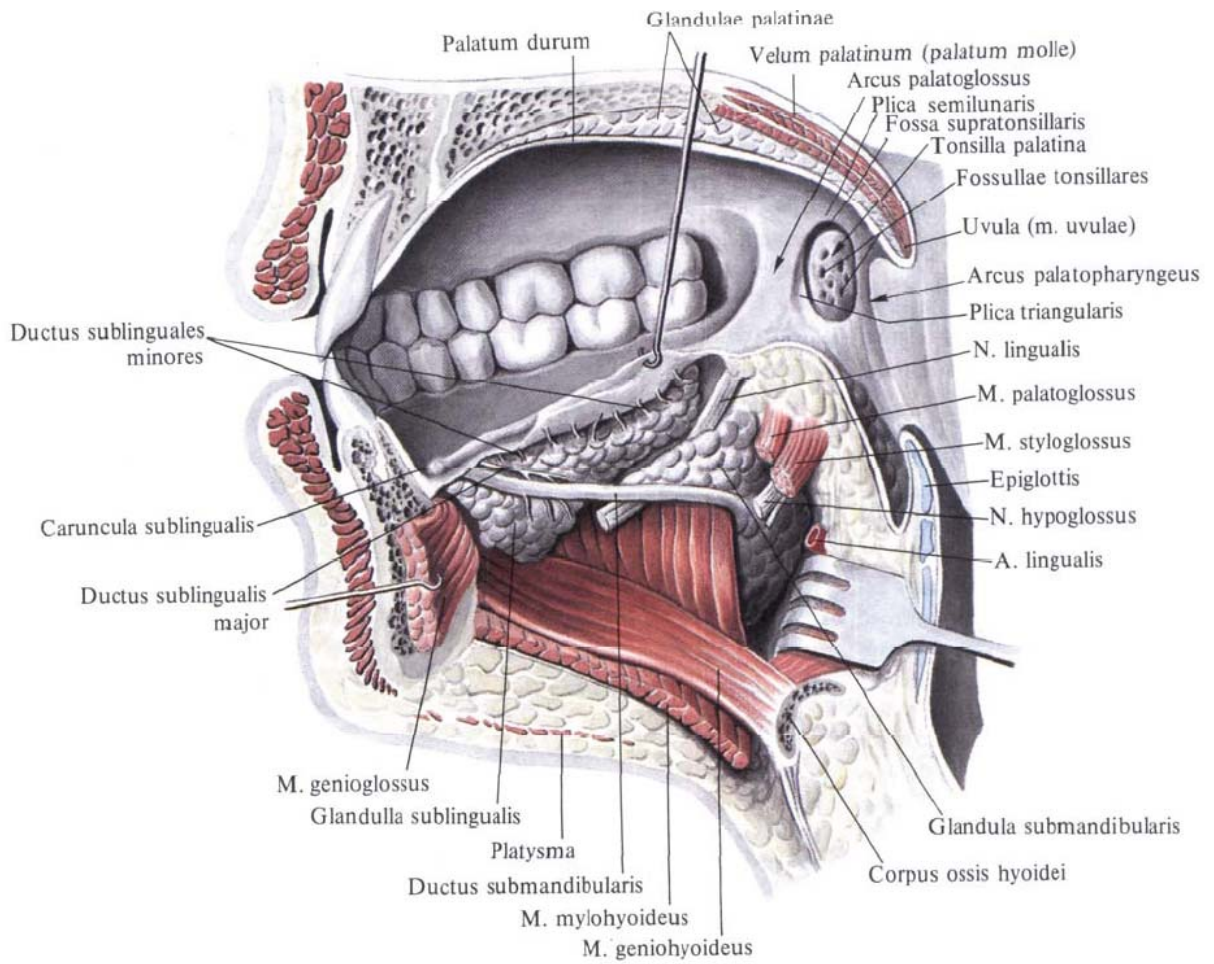
<p>1 – <i>fossa retromandibularis</i>; 2 – <i>m. trapezius</i>; 3 – <i>m. sternocleidomastoideus</i>; 4 – <i>tendo m. omohyoidei</i>; 5 – <i>fossa supraclavicularis minor</i>; 6 – <i>fossa jugularis</i>; 7 – <i>m. omohyoideus</i>; 8 – <i>os hyoideum</i>; 9, 10 – <i>m. digastricus (venter anterior et venter posterior)</i>;</p>	<p>11 – <i>trigonum omotrapezoideum</i>; 12 – <i>trigonum omooclaviculare</i>; 13 – <i>trigonum omotracheale</i>; 14 – <i>trigonum caroticum</i>; 15 – <i>trigonum submandibulare</i>; 16 – <i>trigonum submentale</i>; 17 – <i>trigonum a. lingualis (Πυροζοβ)</i>; 18 – <i>m. mylohyoideus</i>; 19 – <i>n. hypoglossus (XII)</i>.</p>
---	---

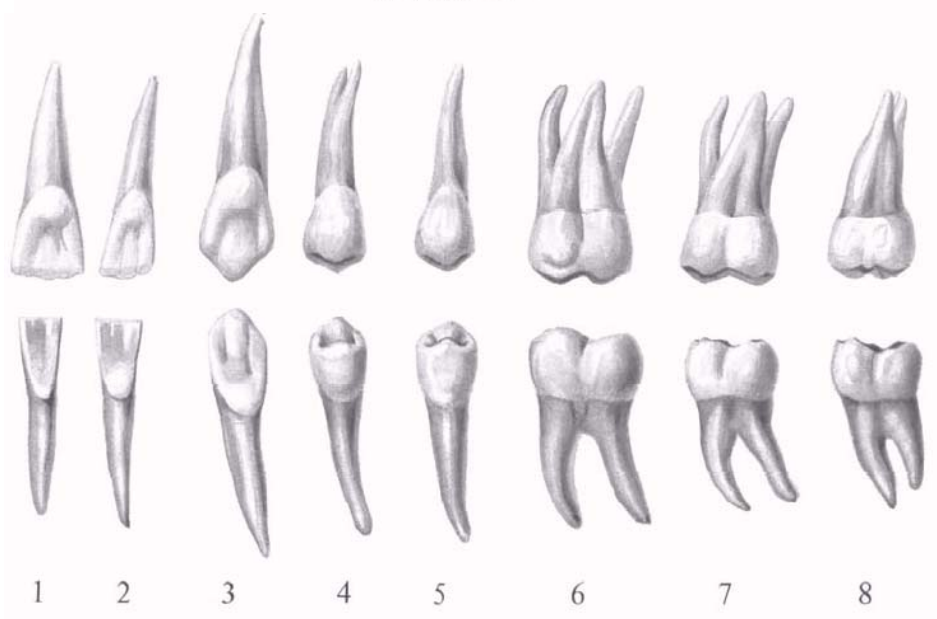
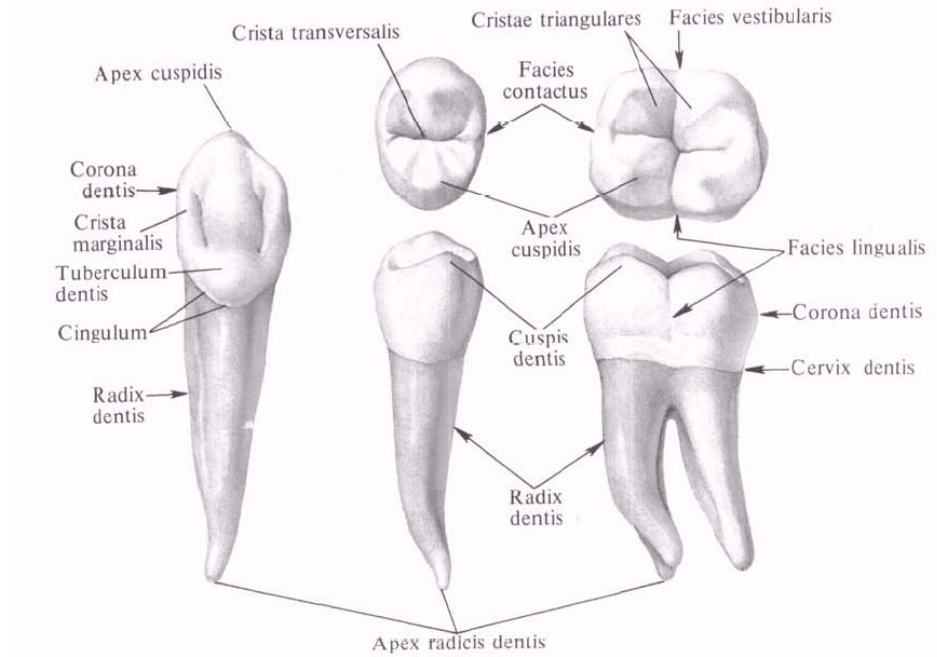
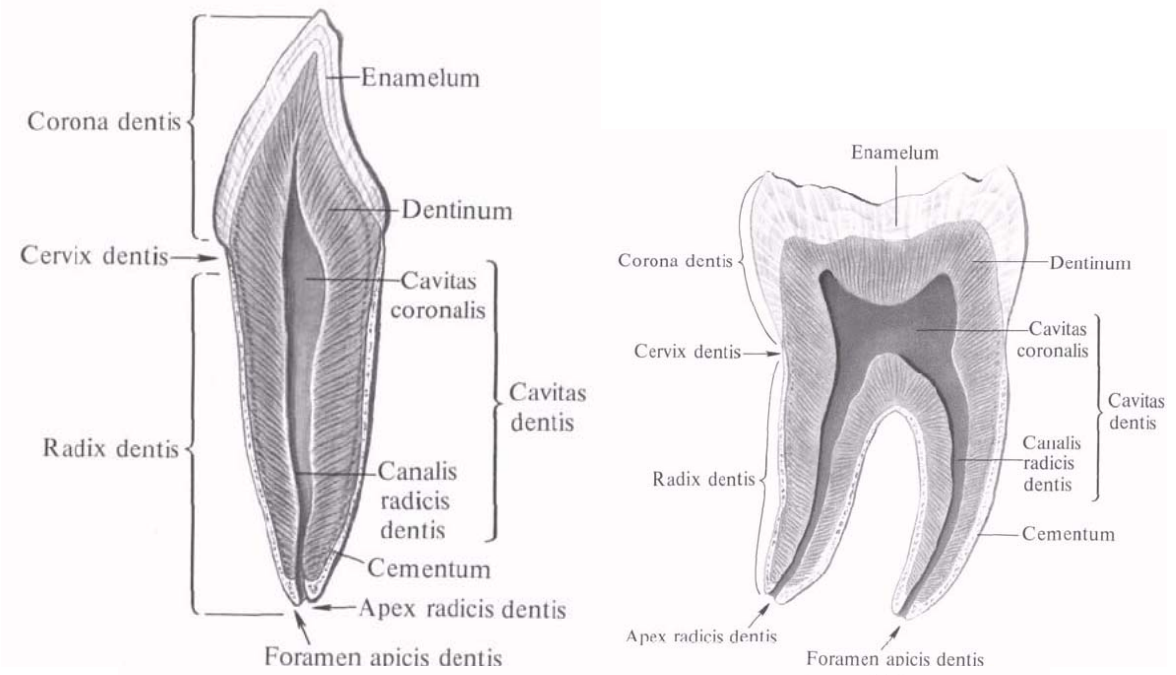


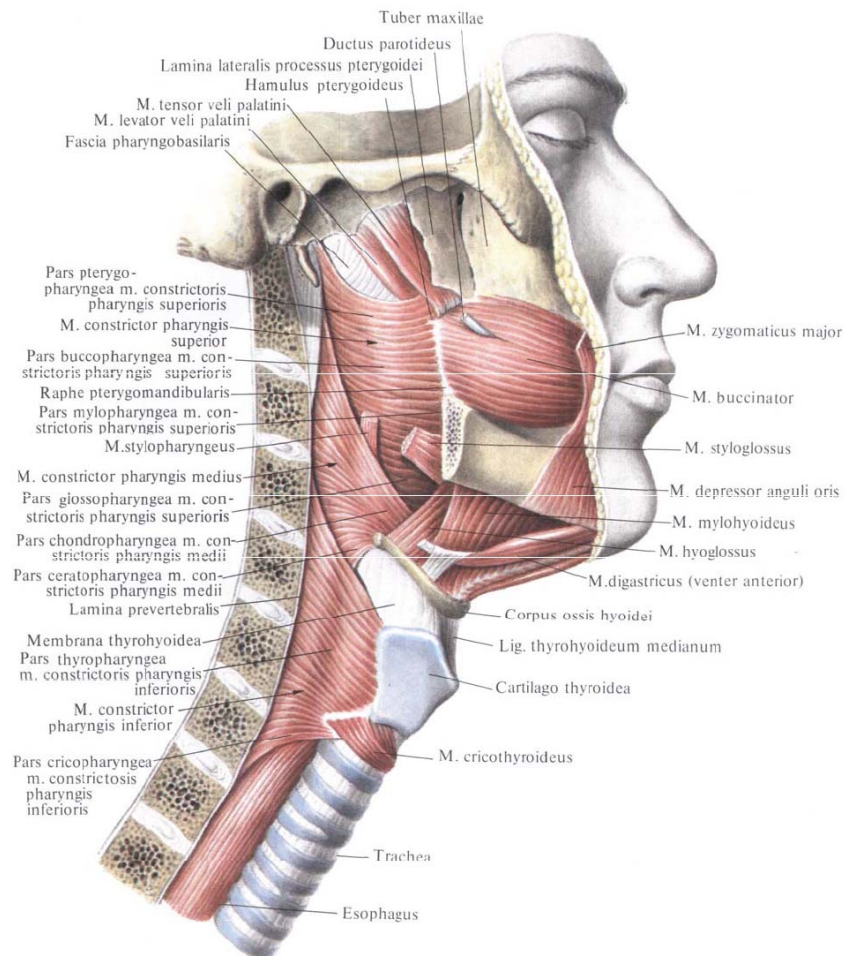
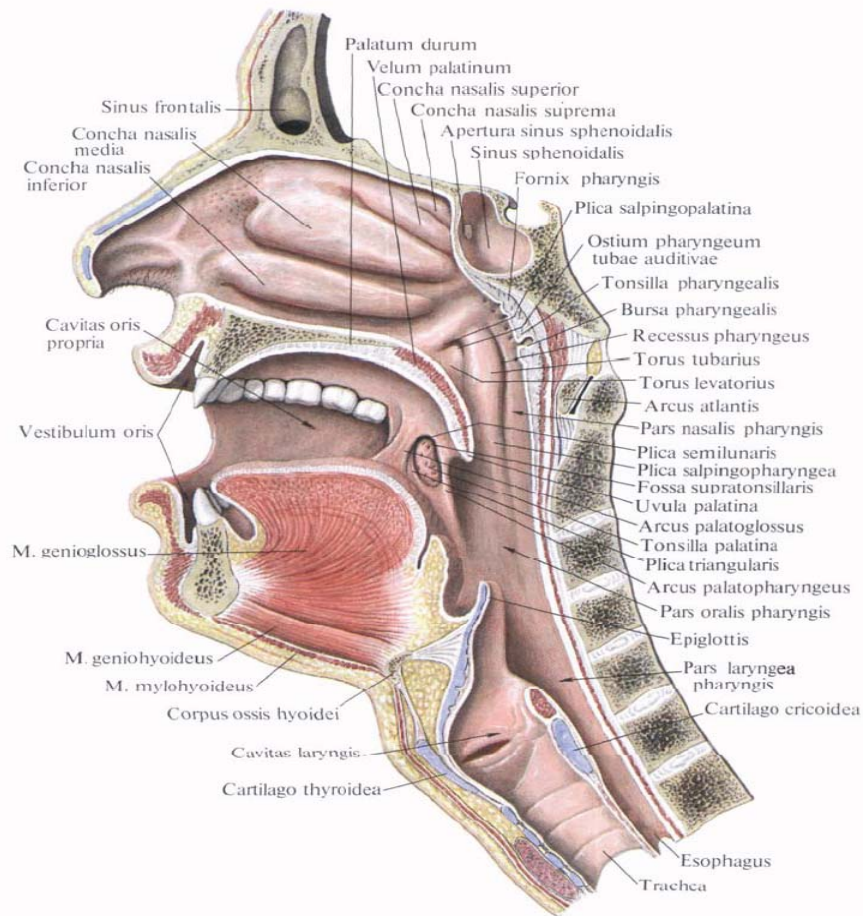


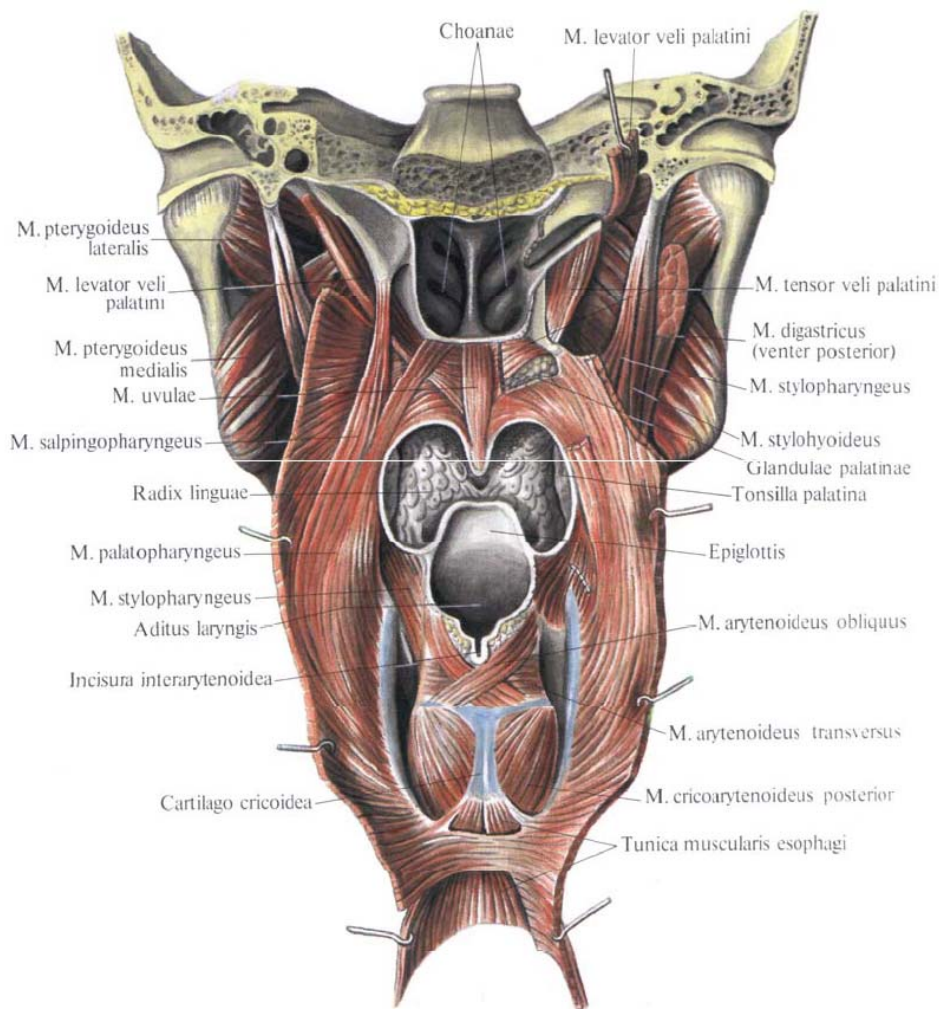
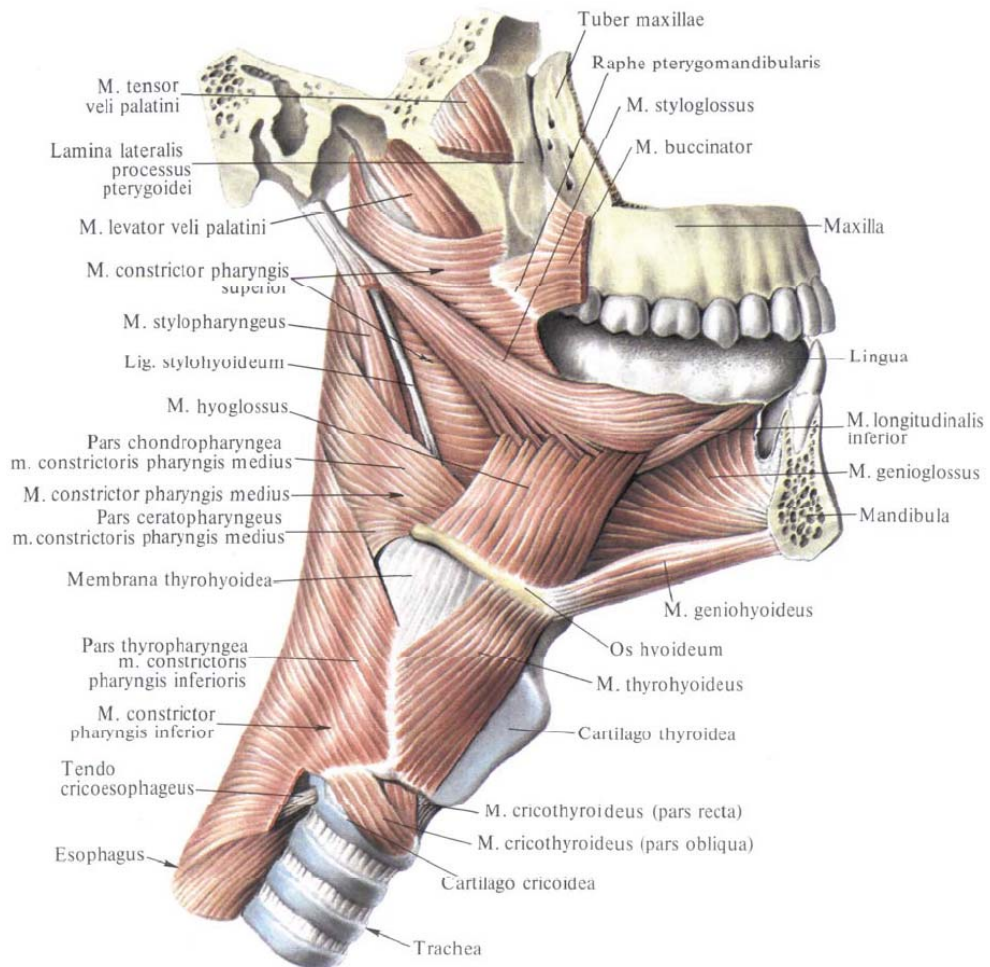


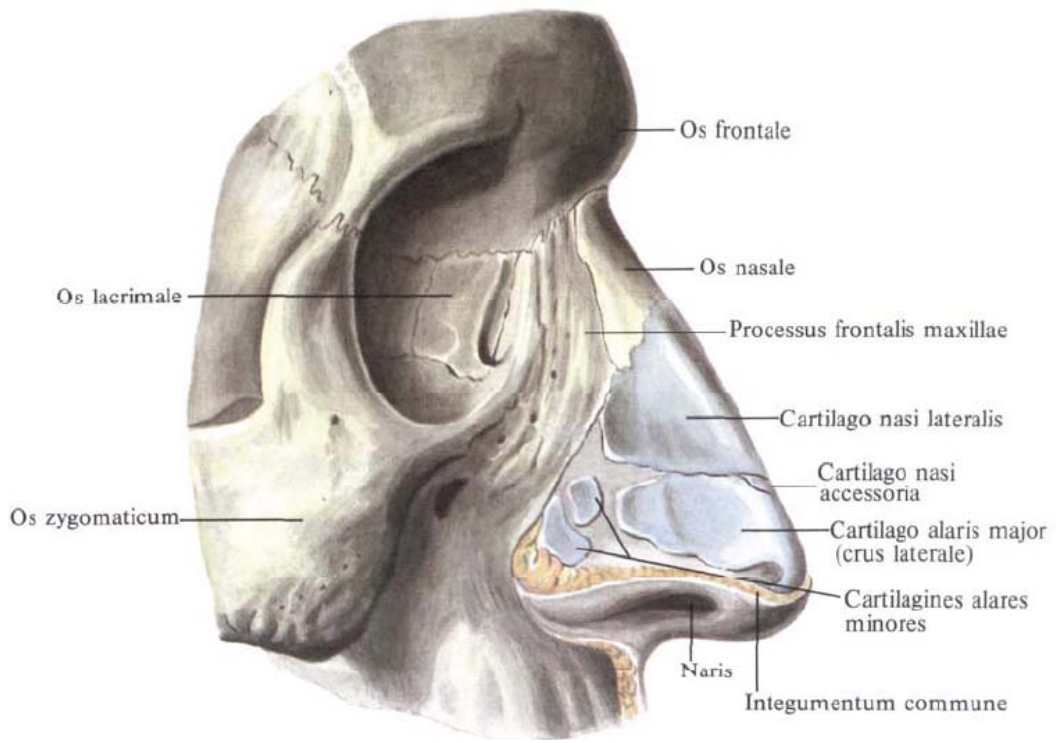
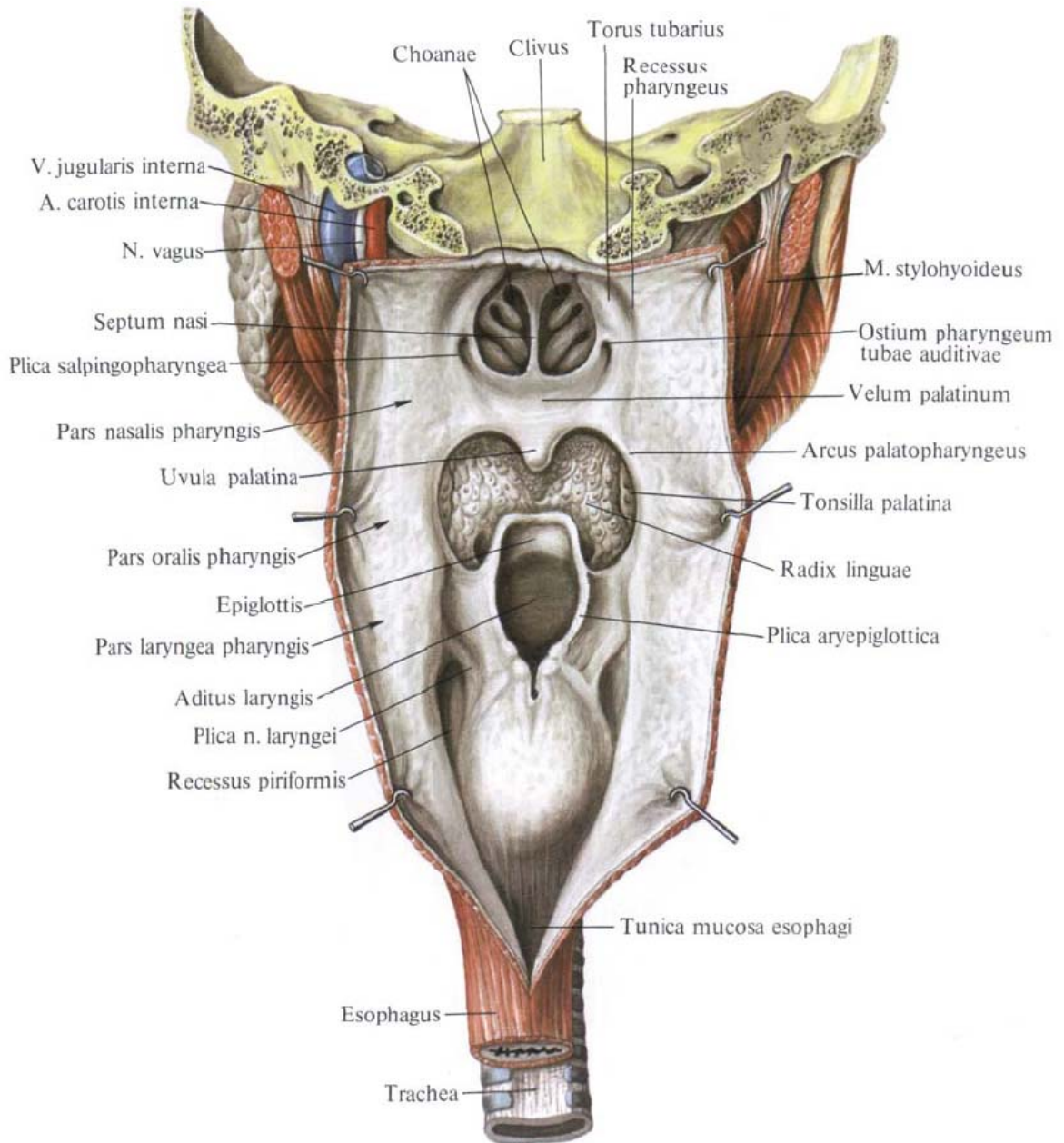


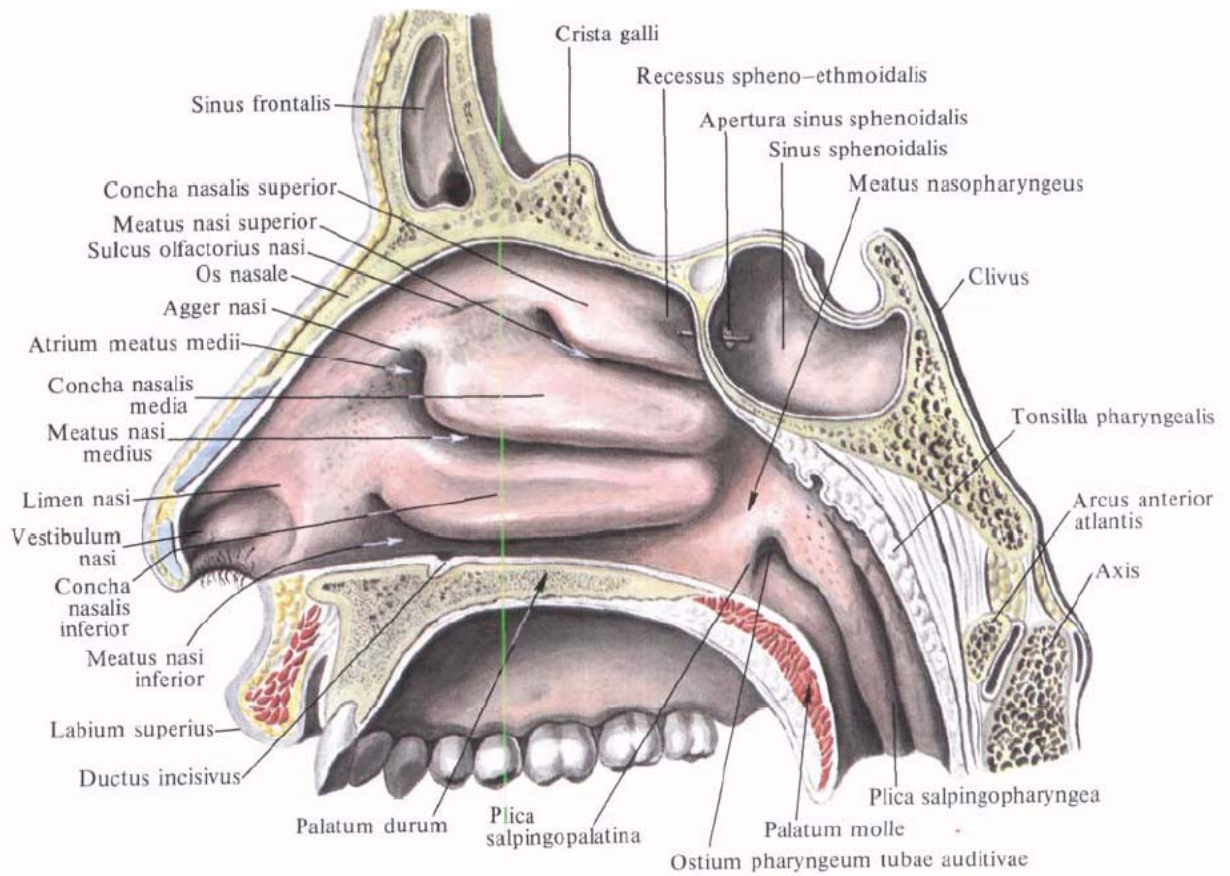
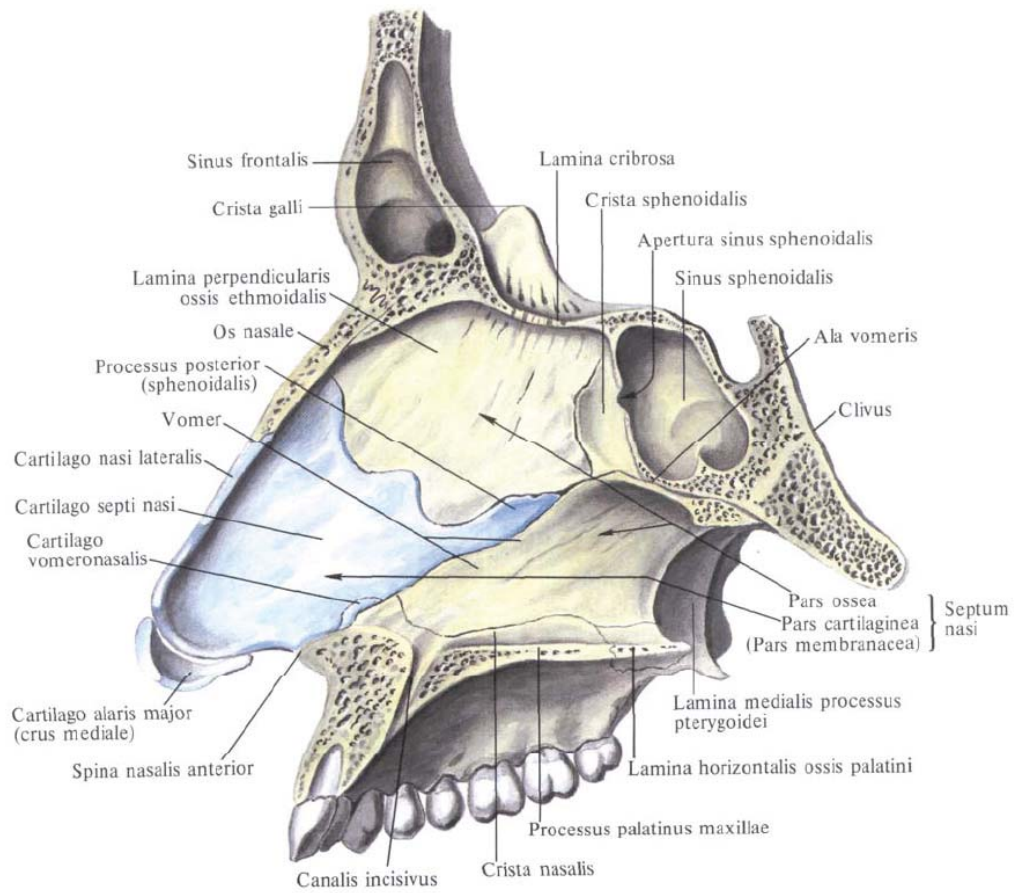


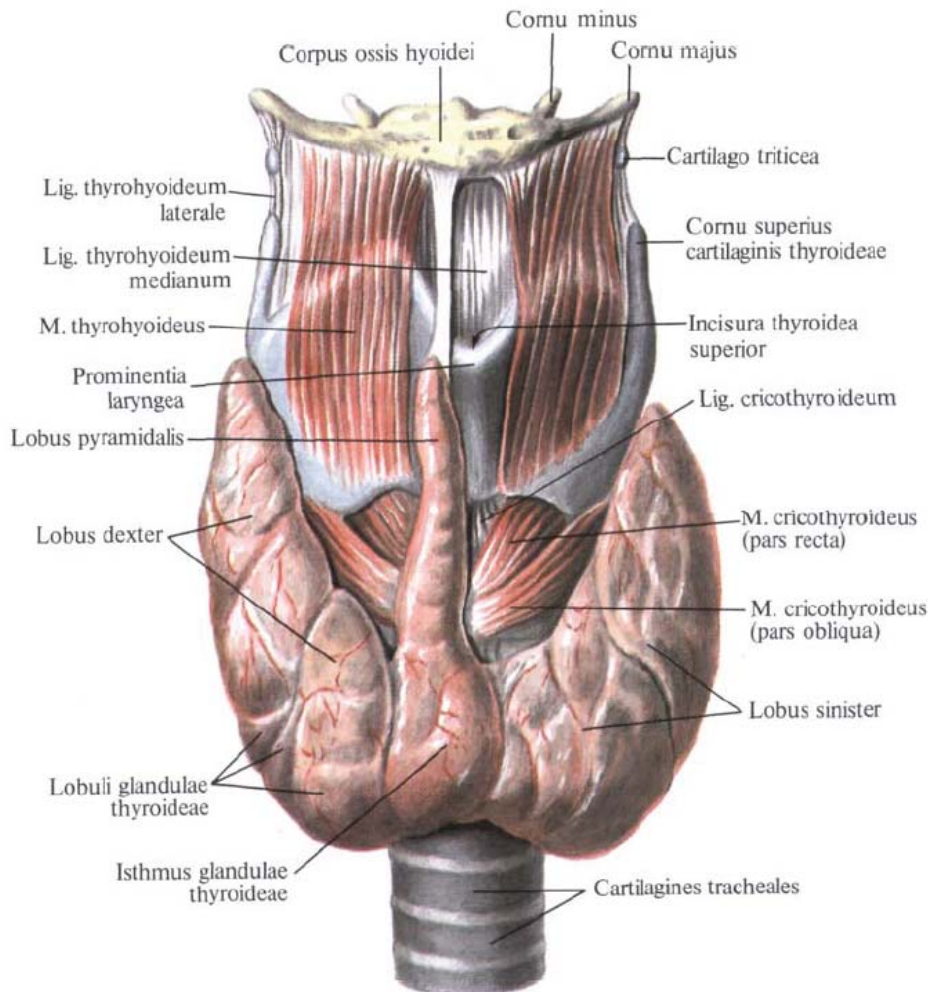
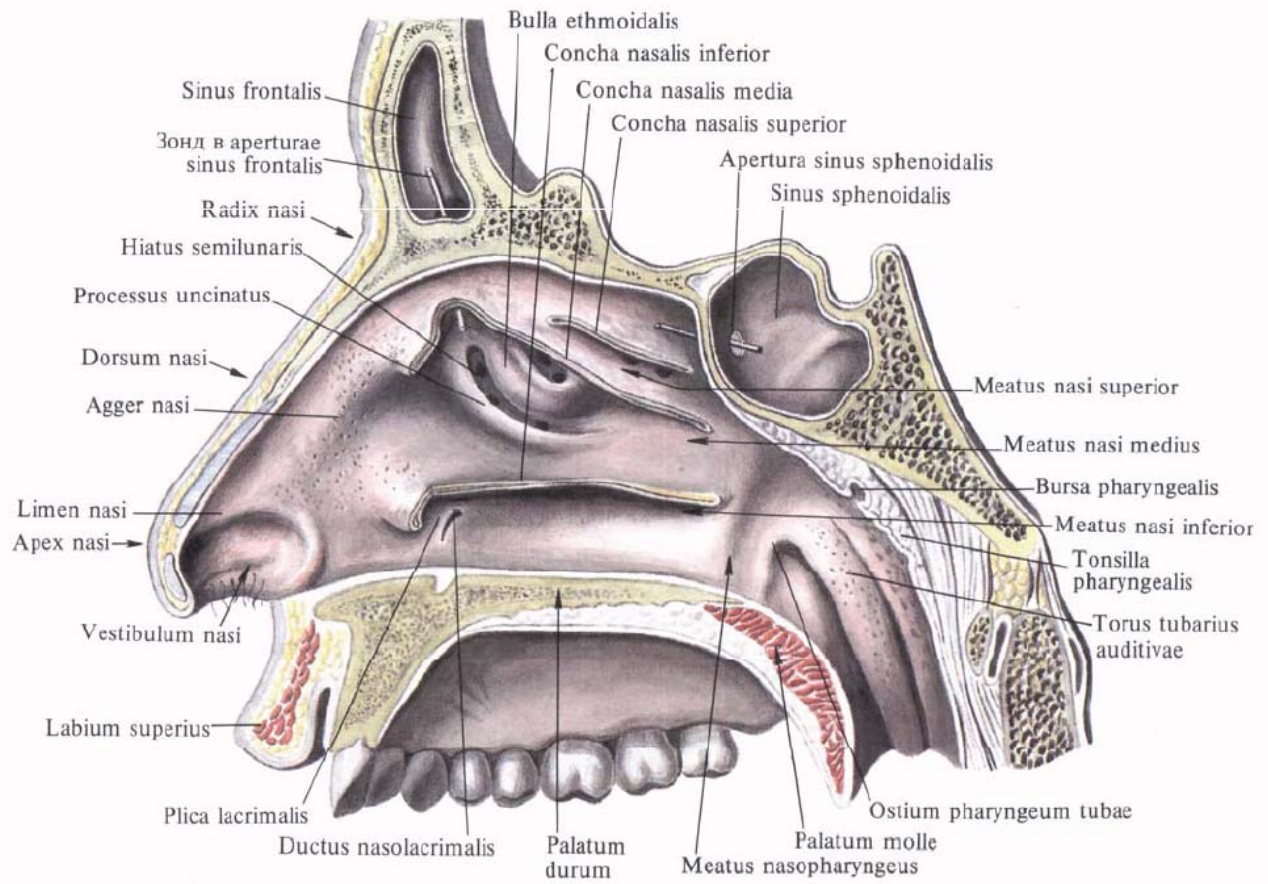


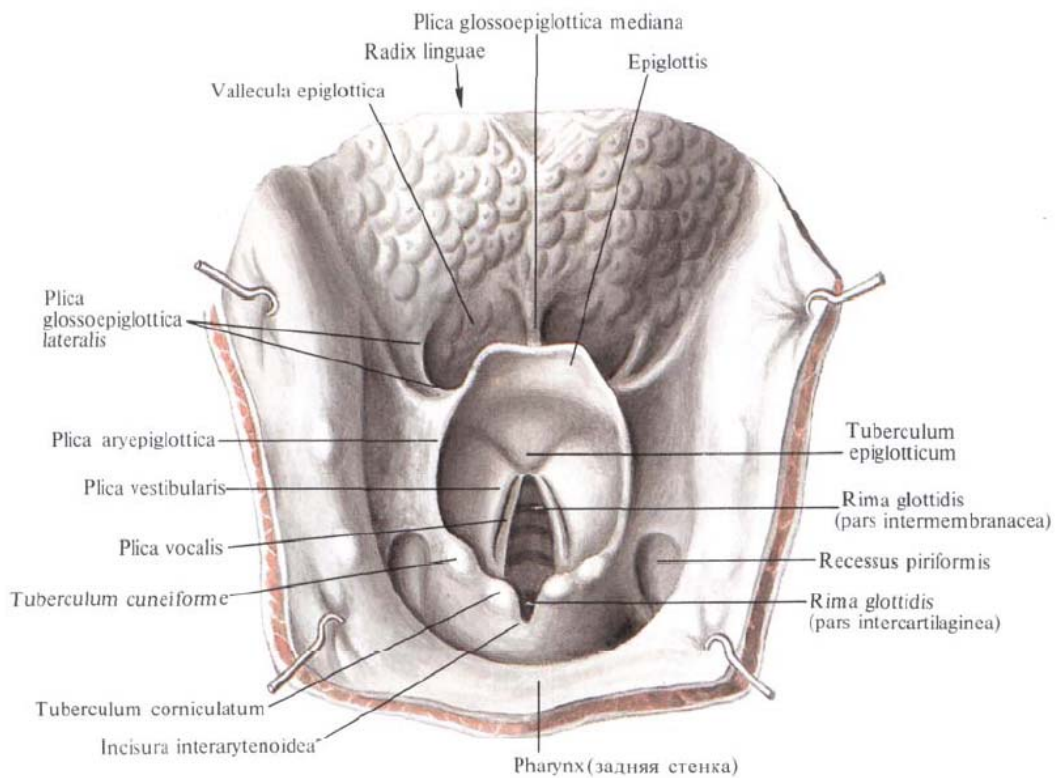
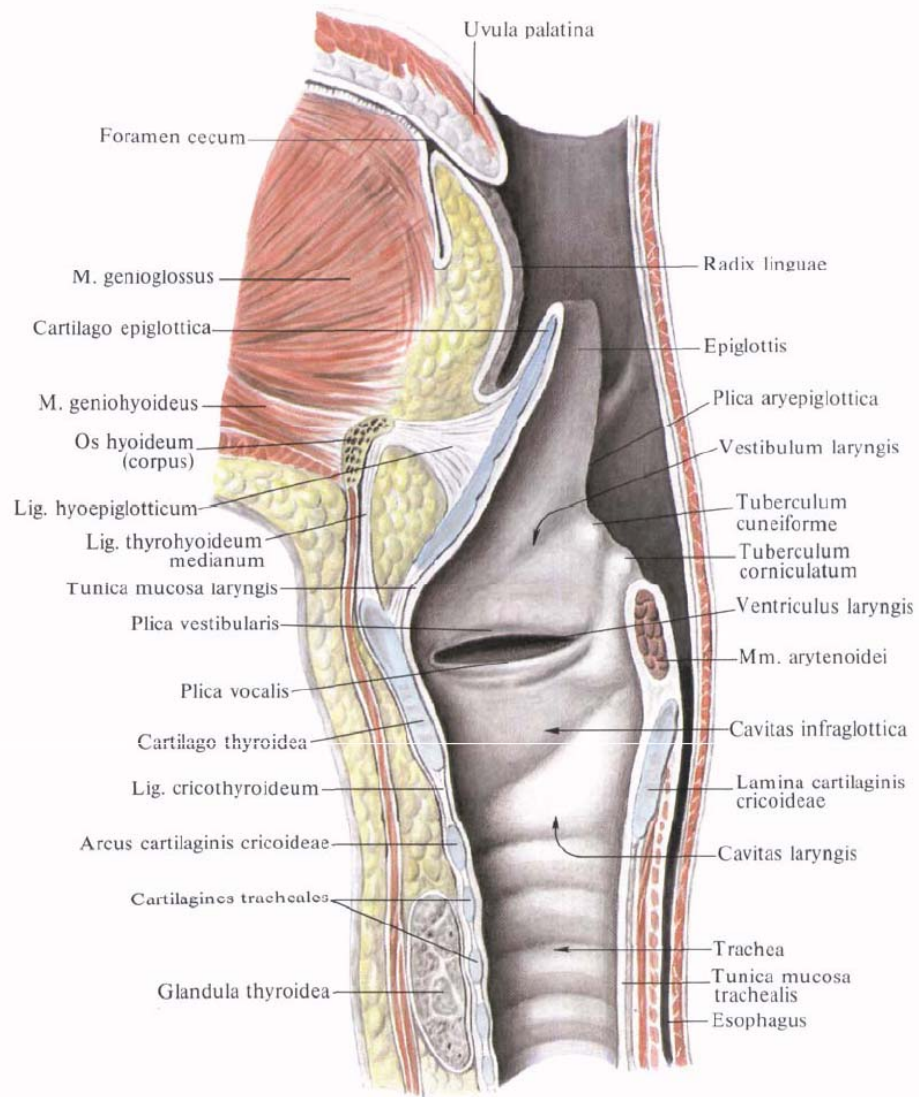


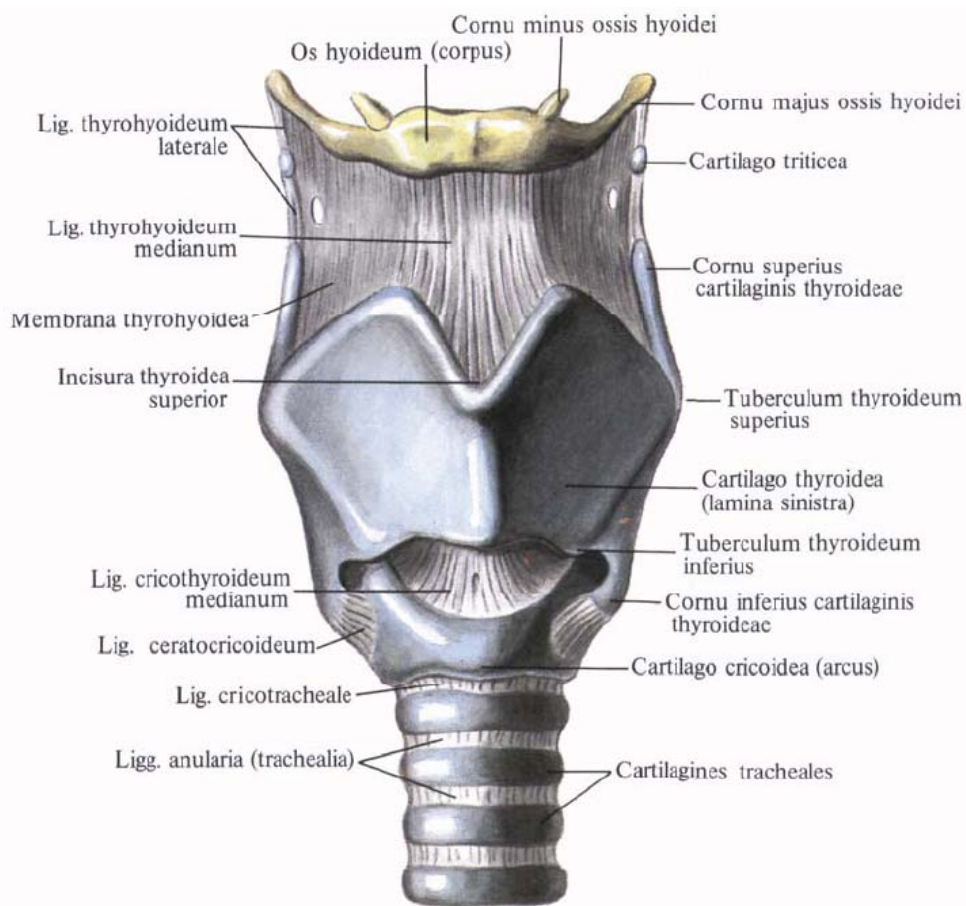
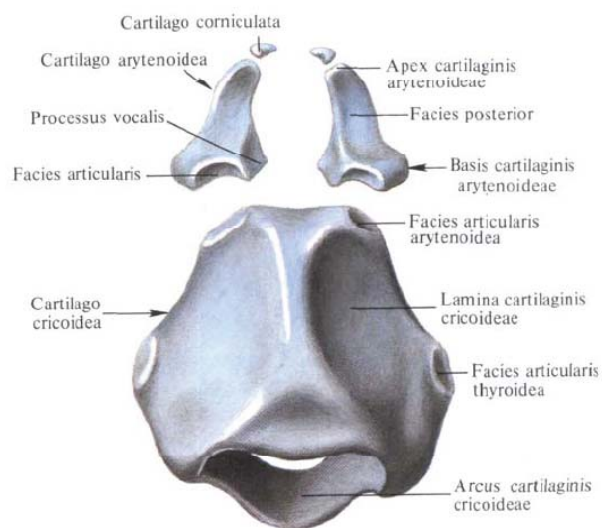
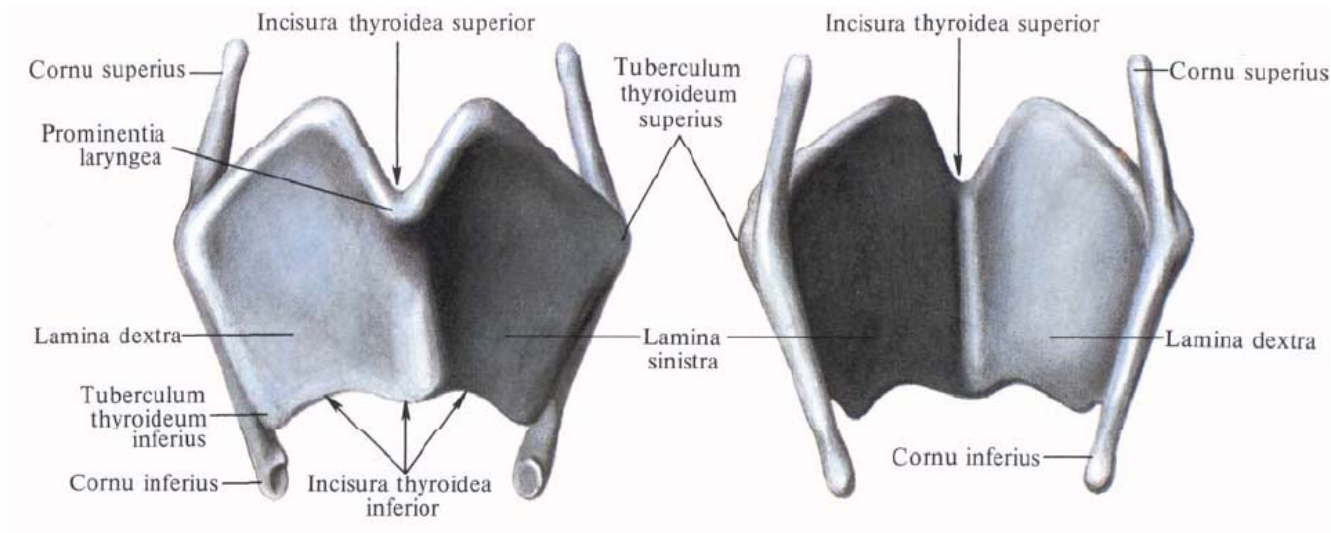


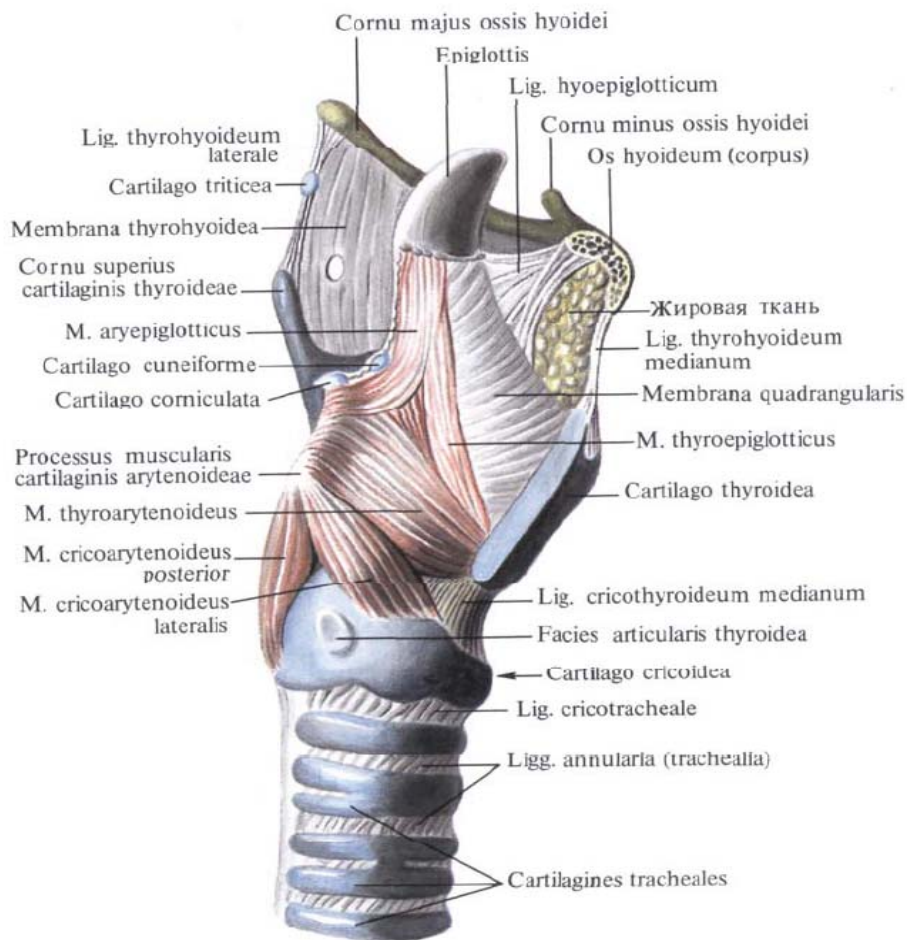
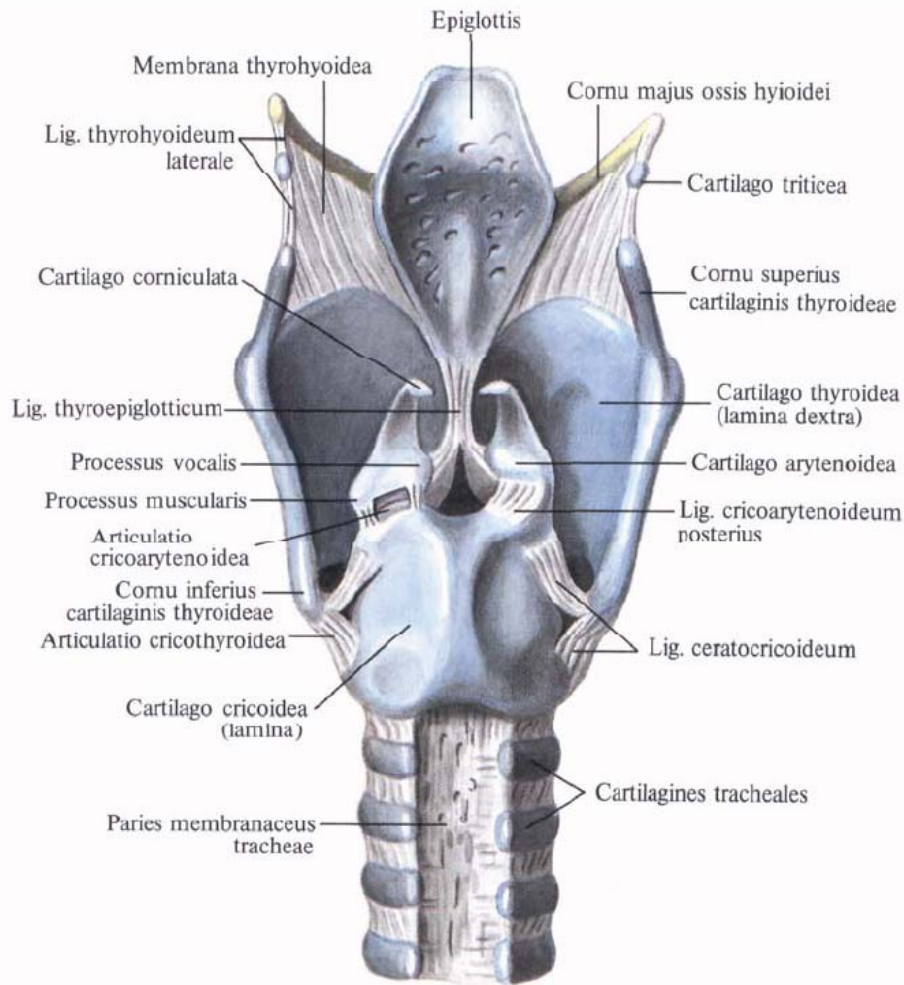


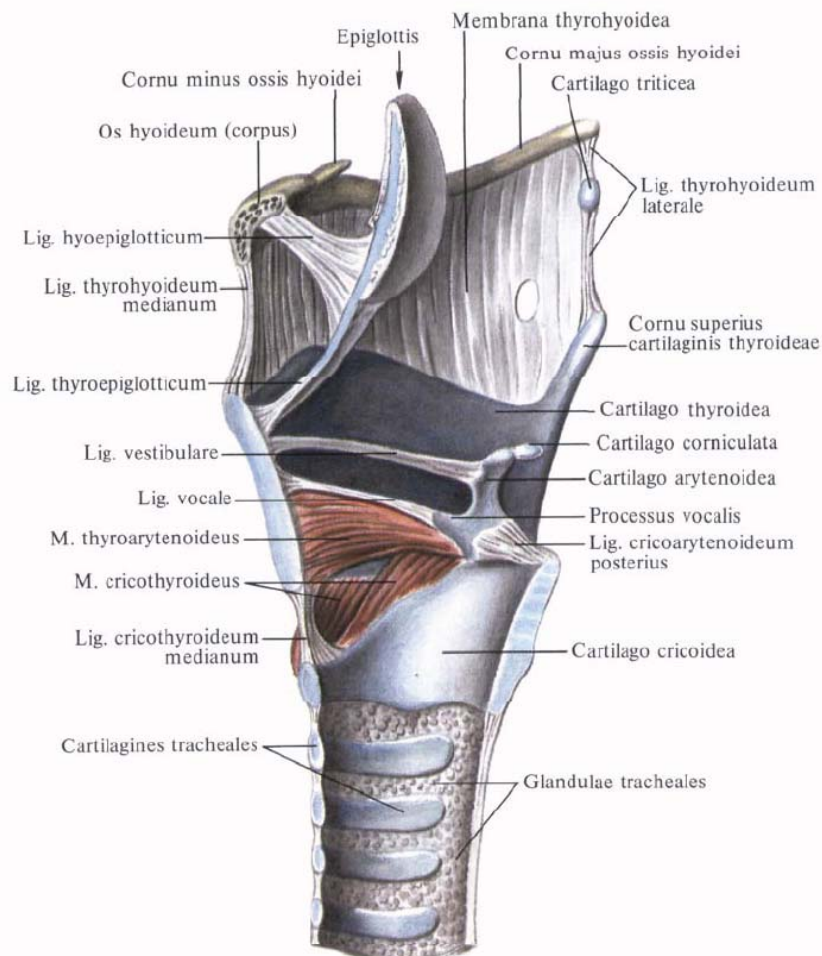
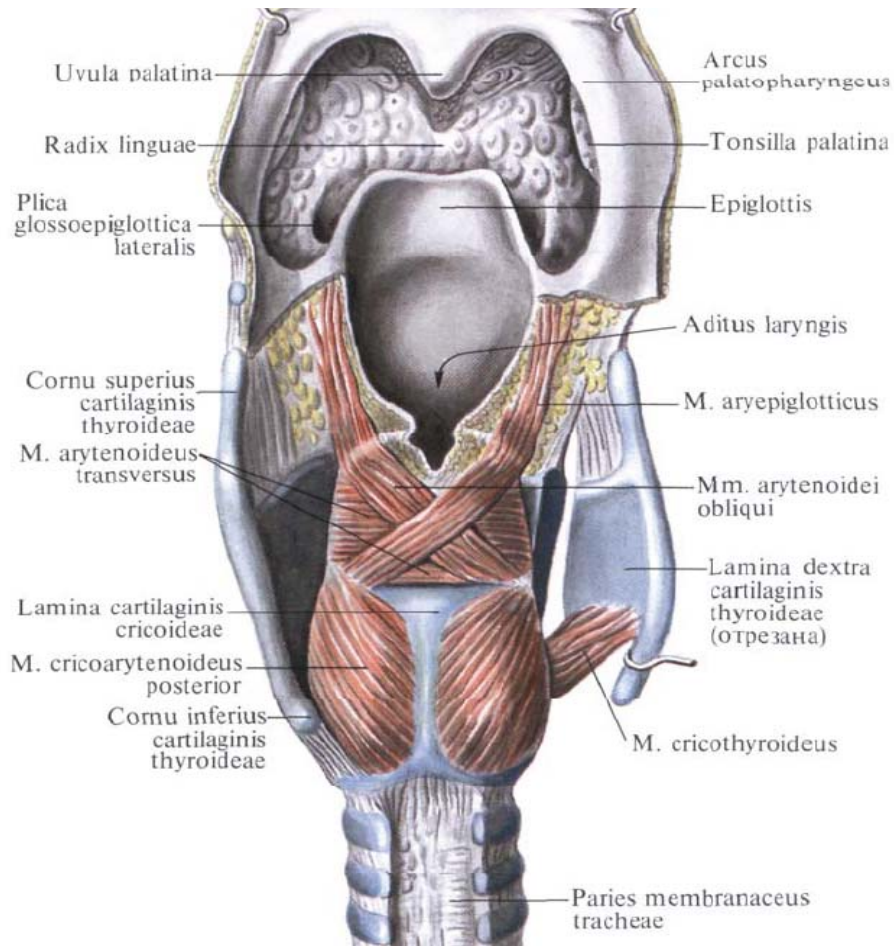


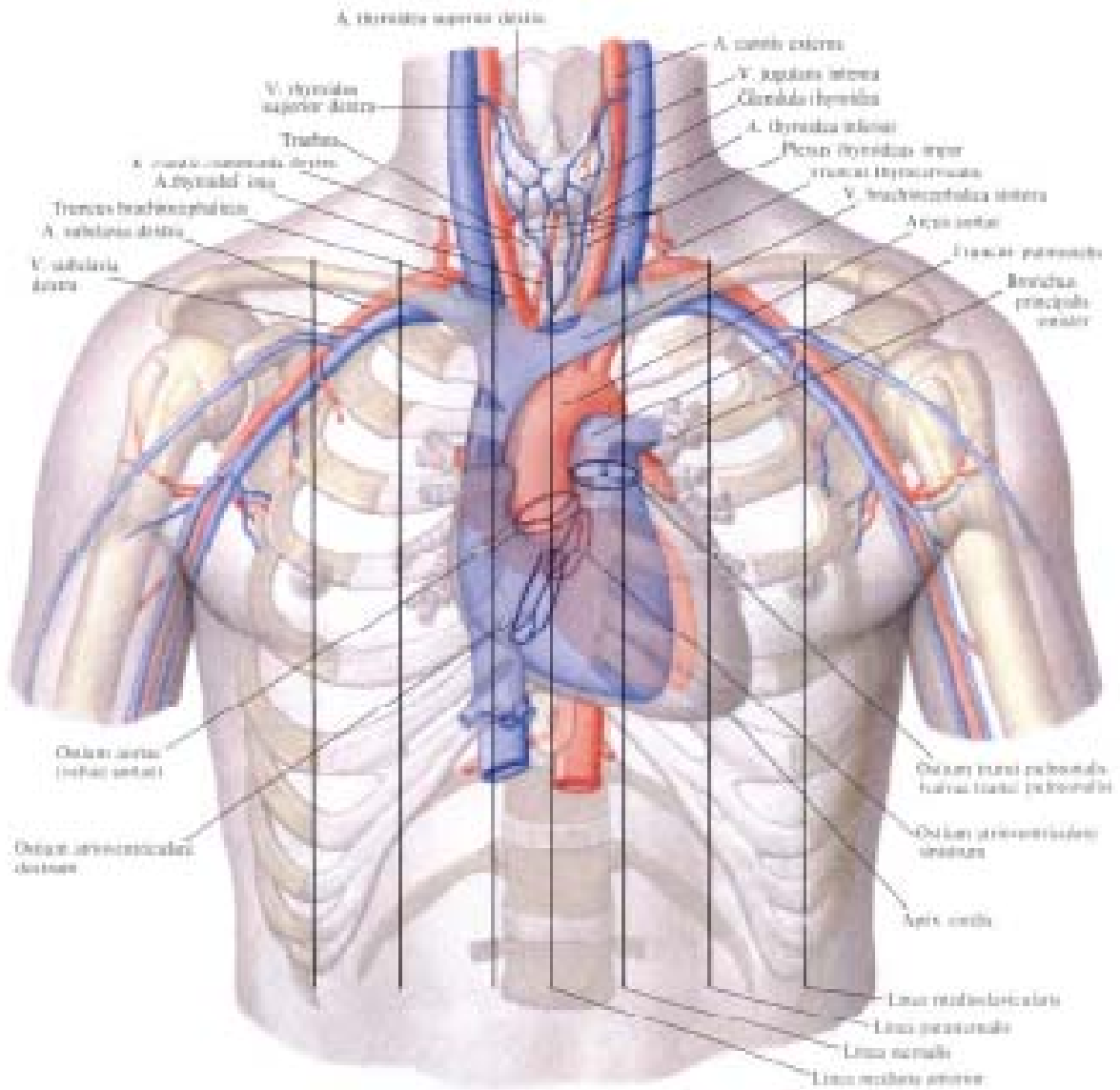




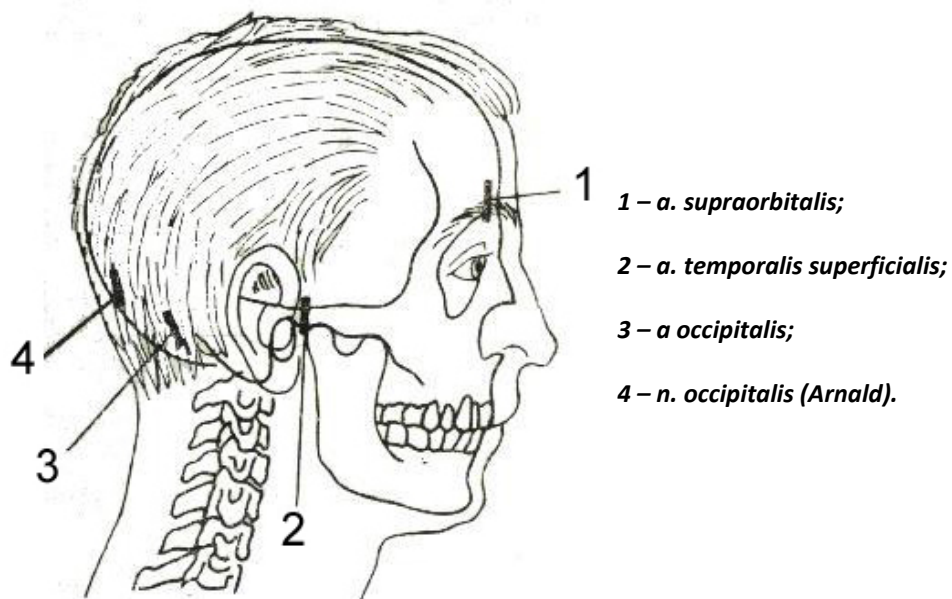


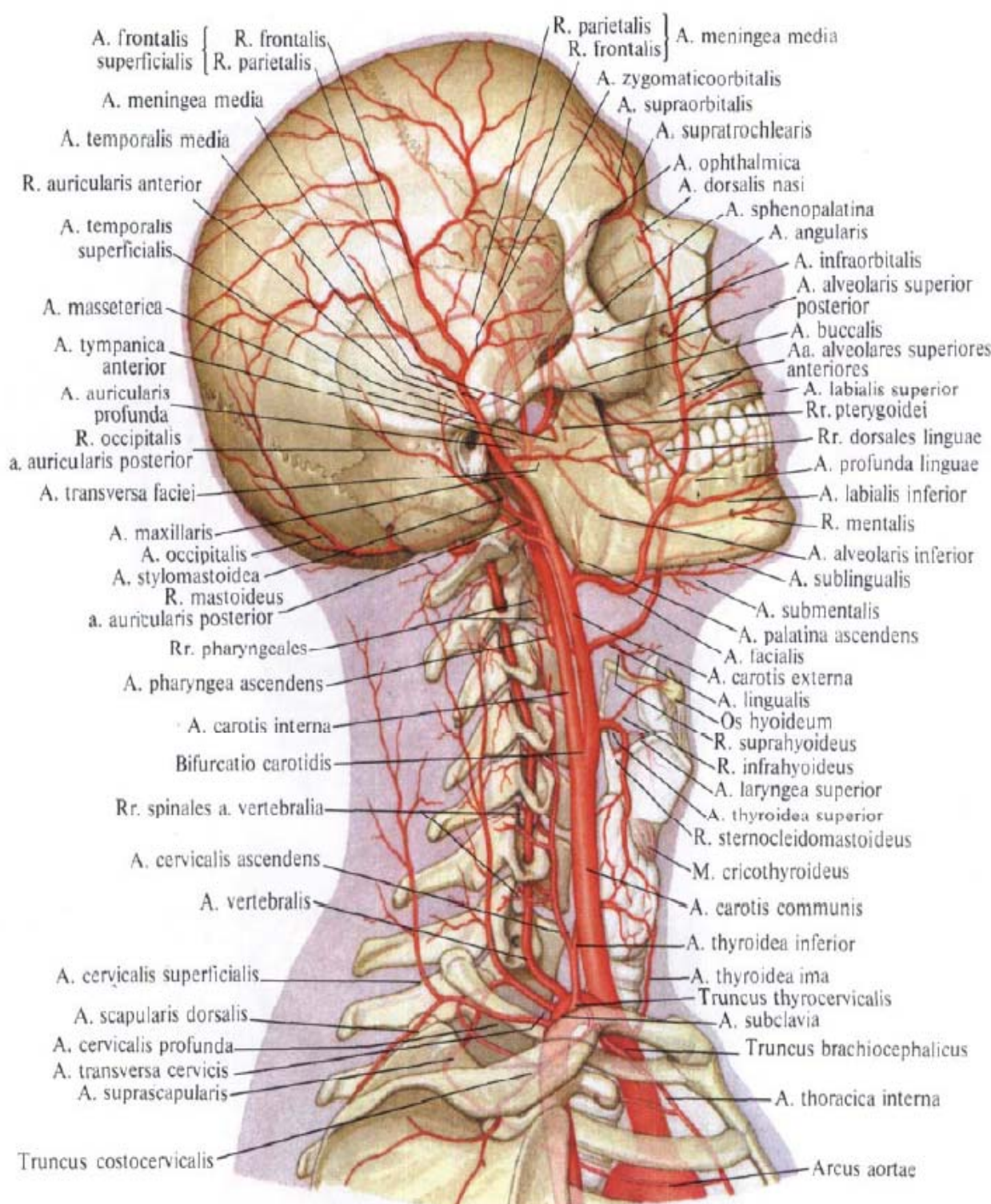


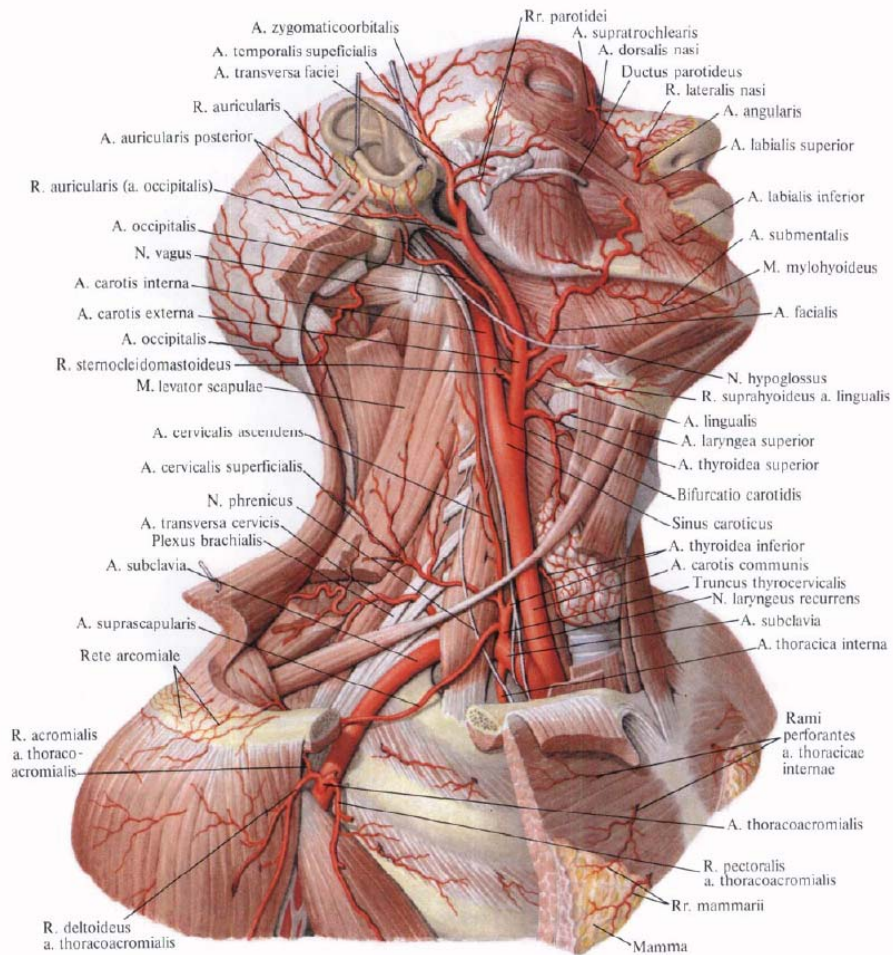
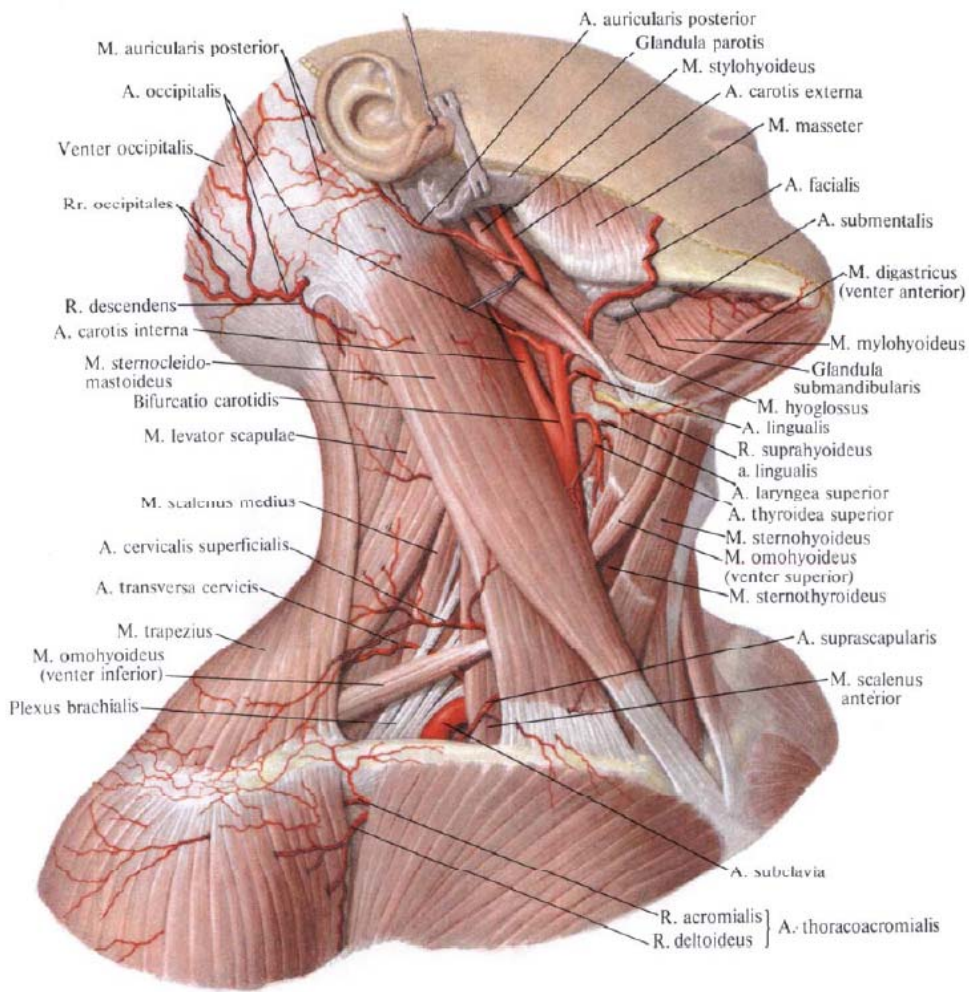


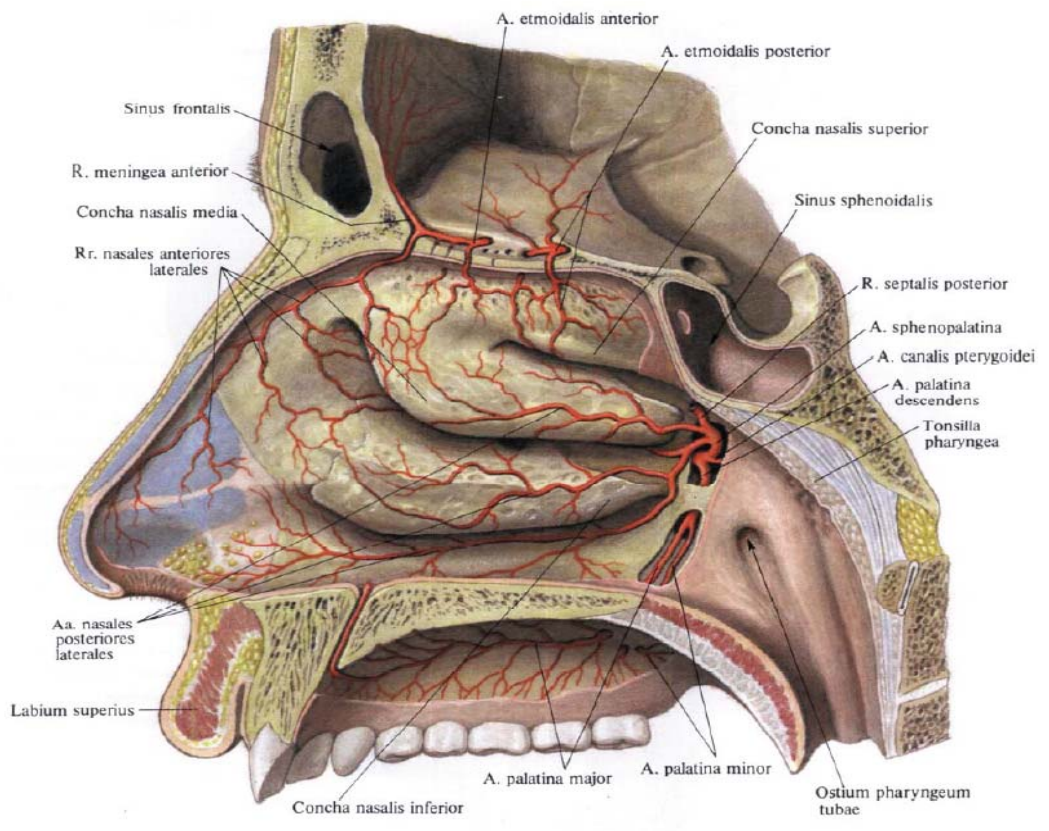
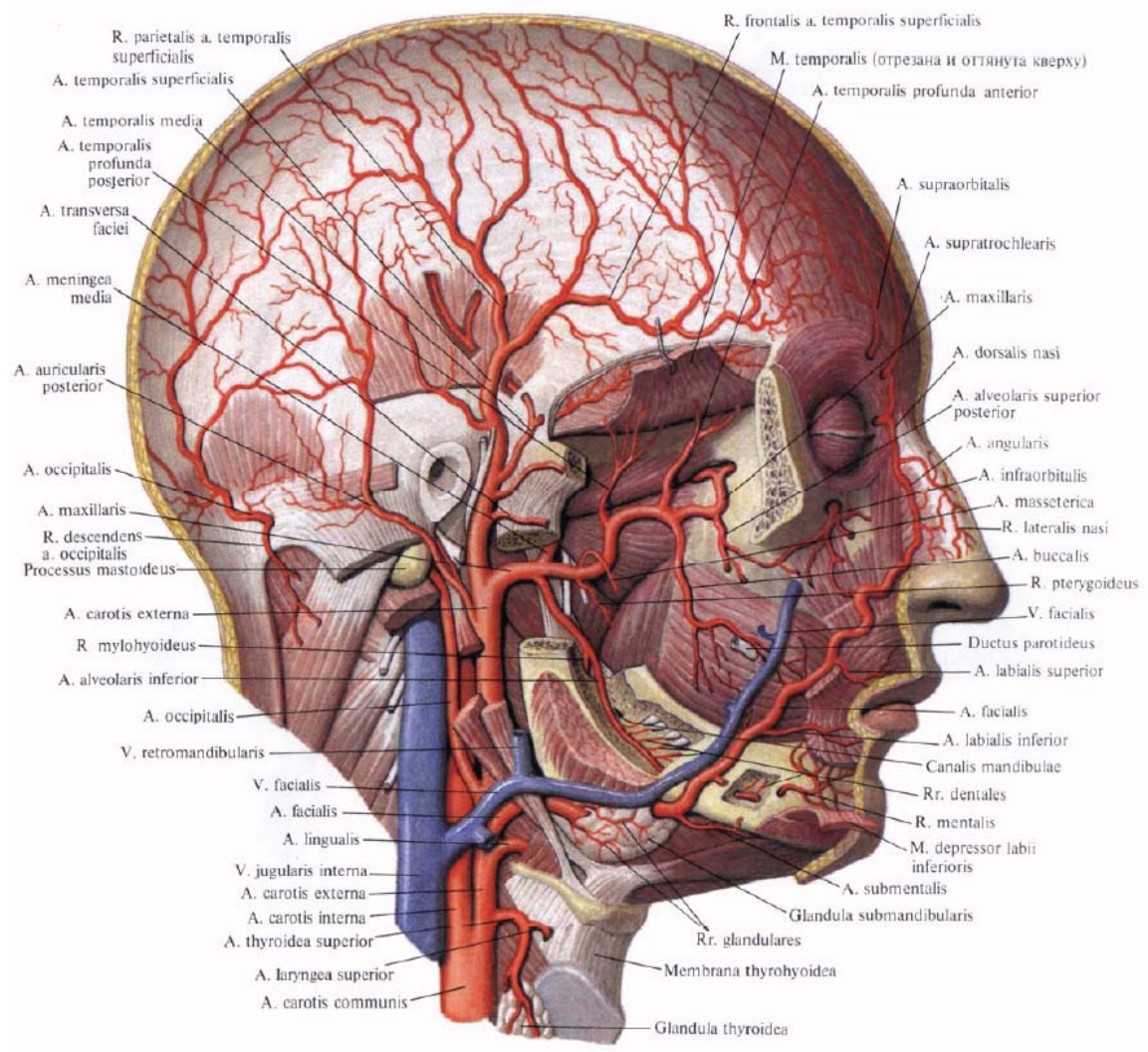


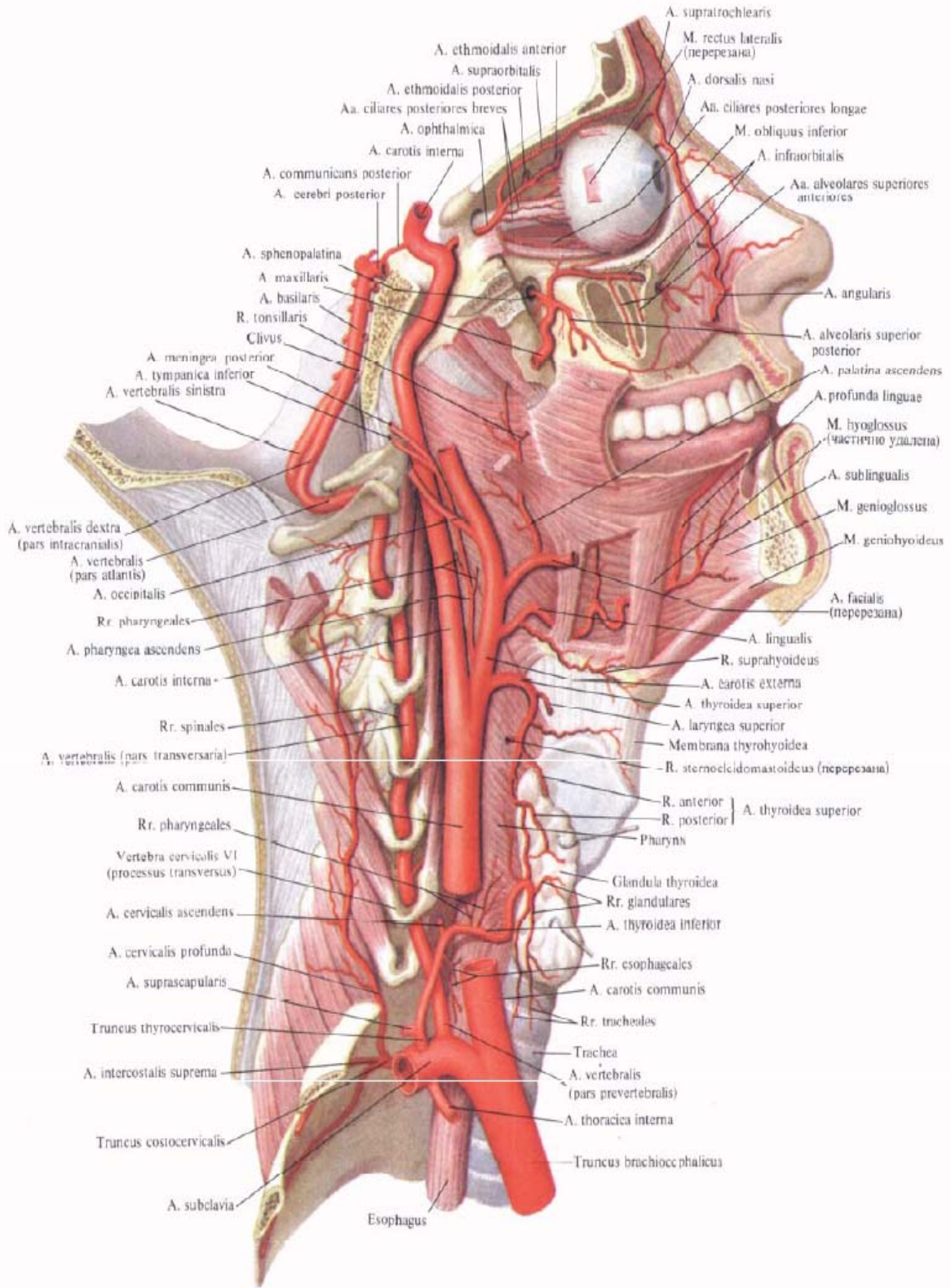
Points of palpation of some arteries and nerves of the head

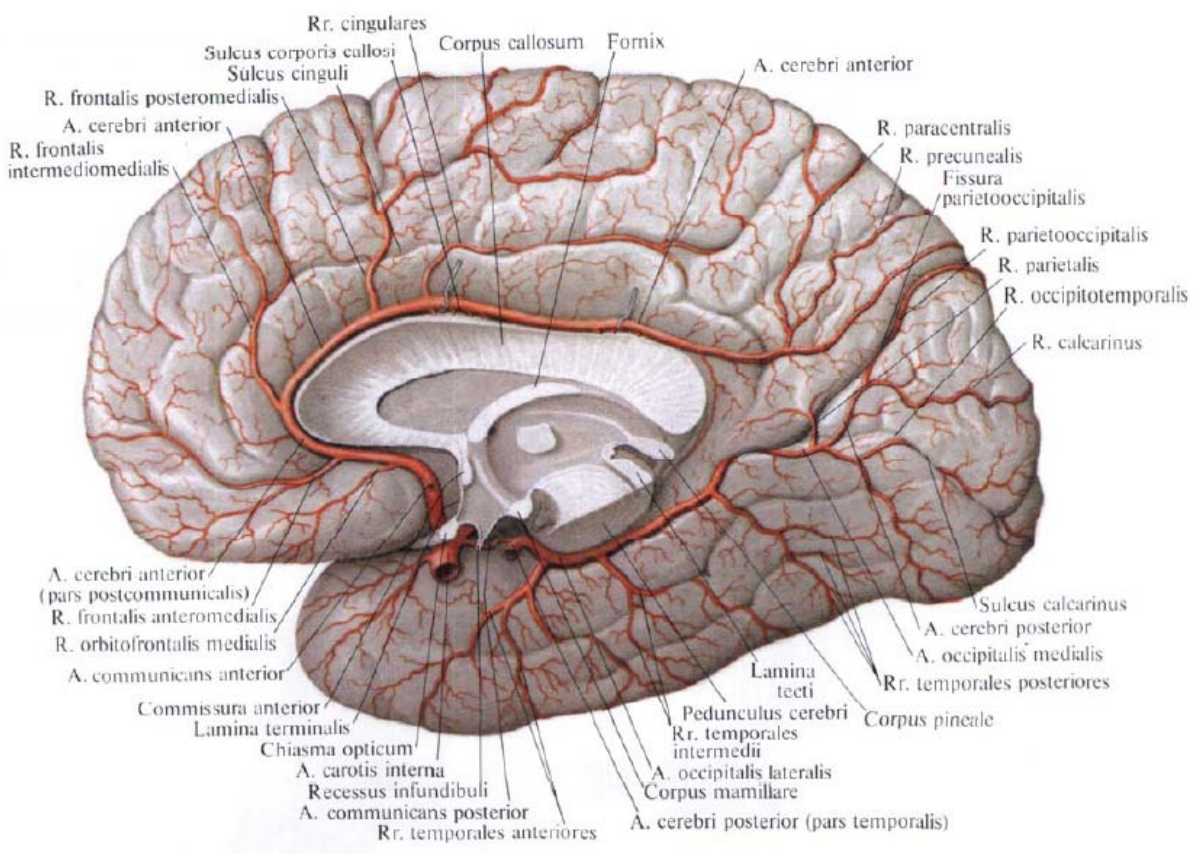
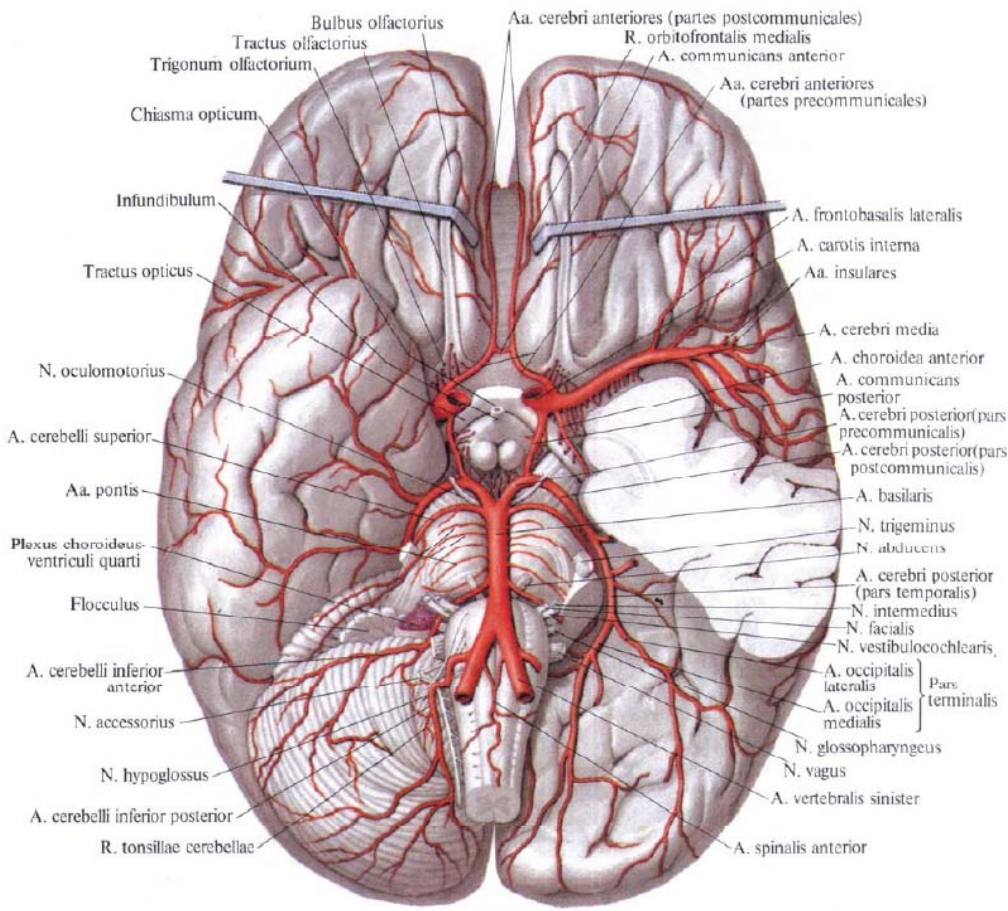


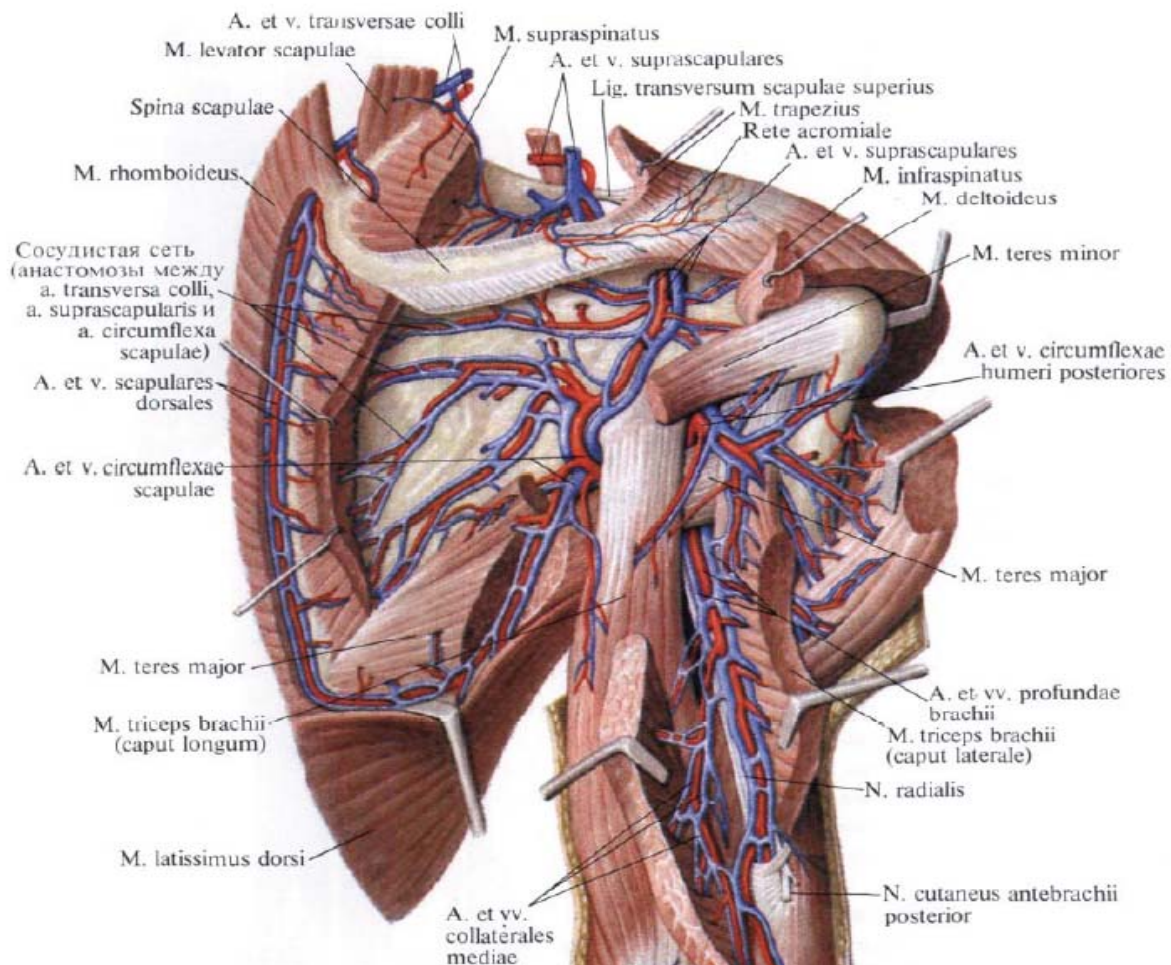
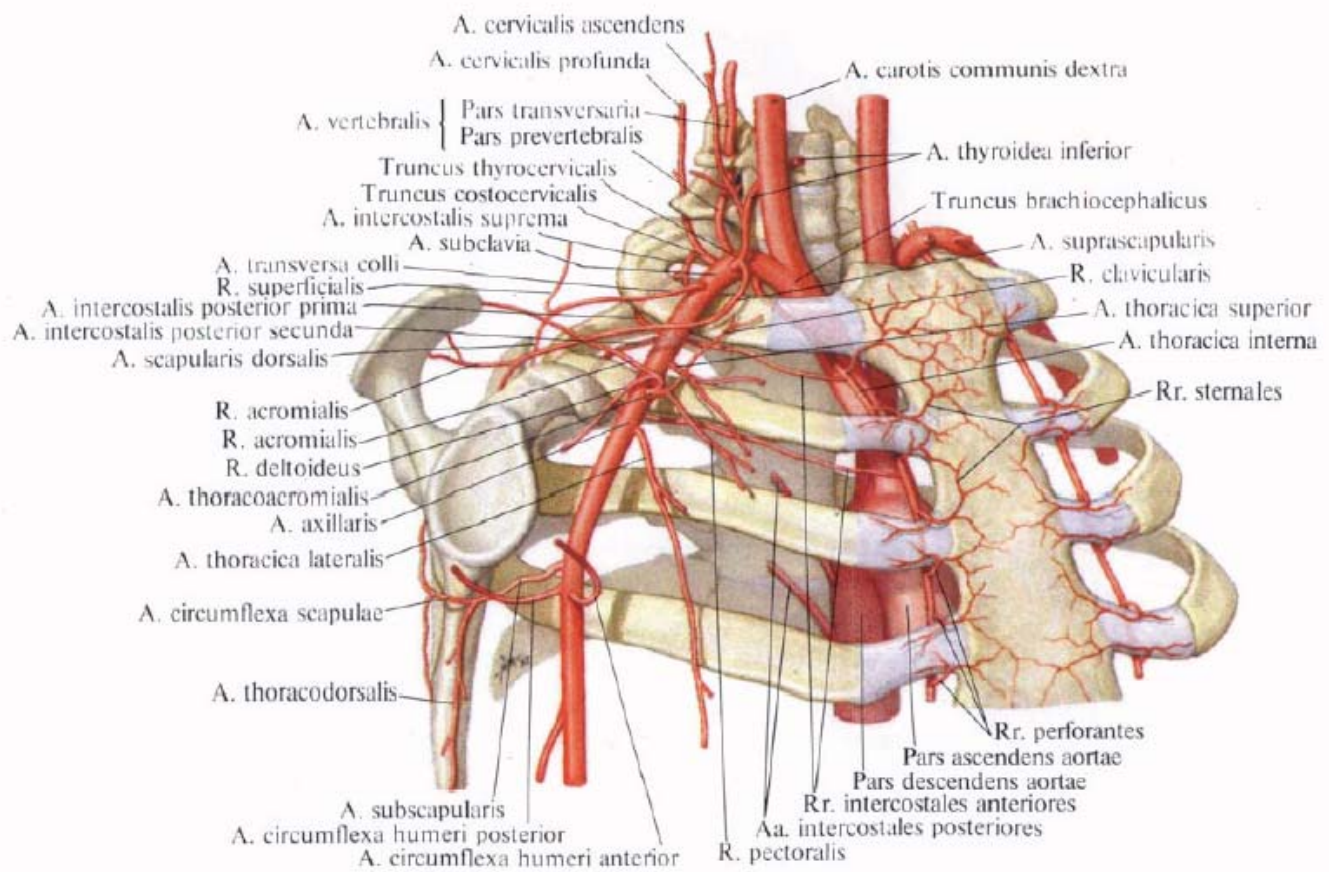


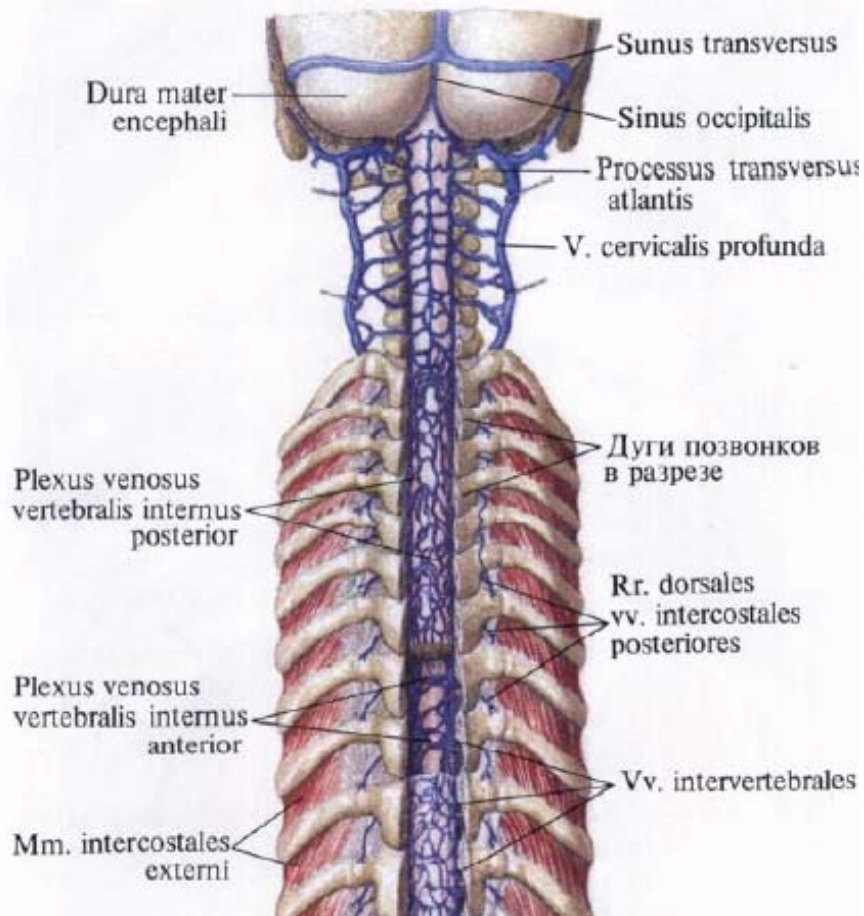
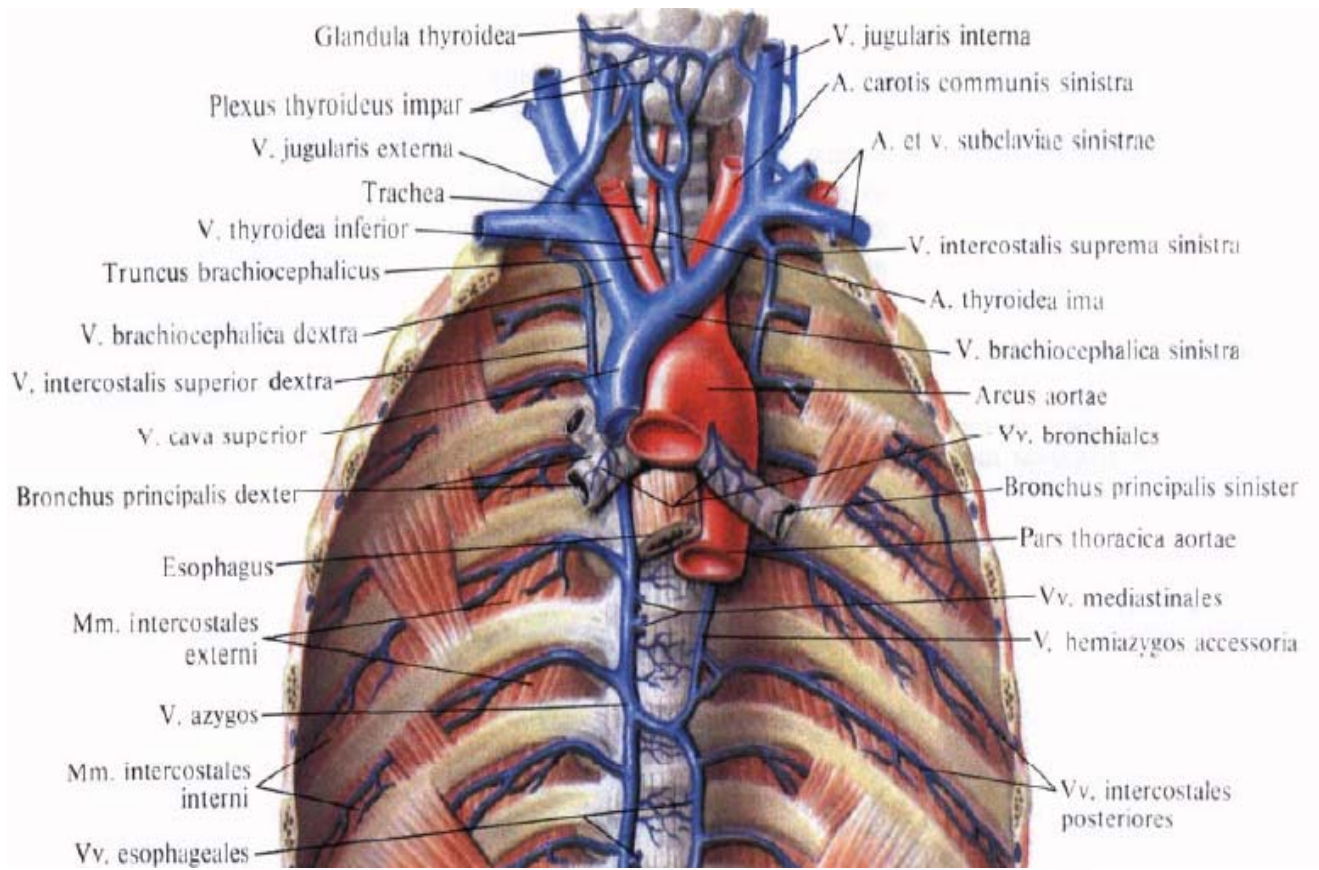


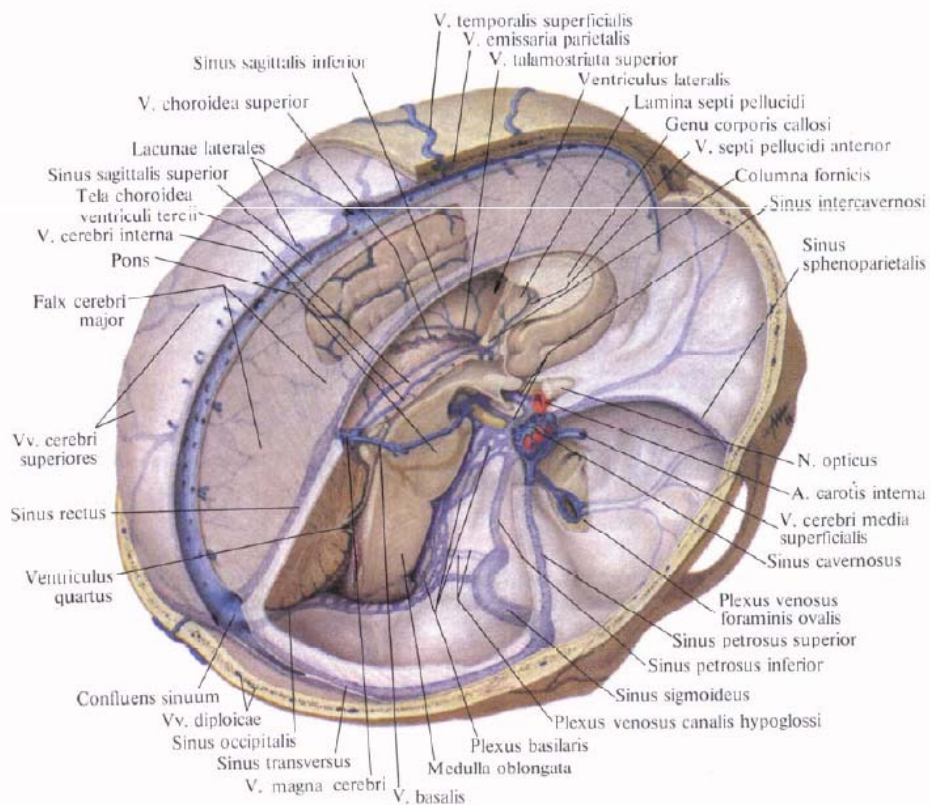
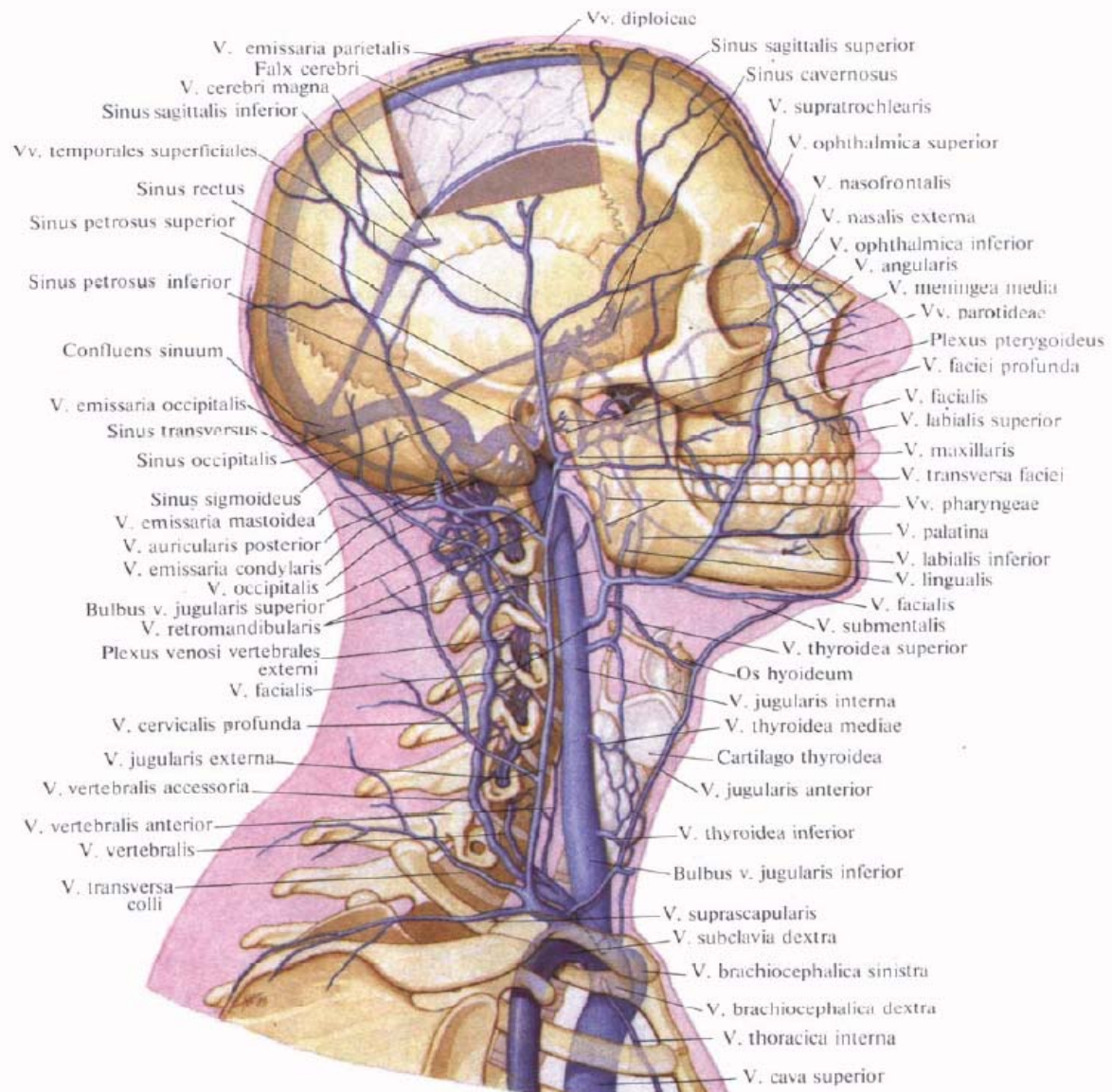


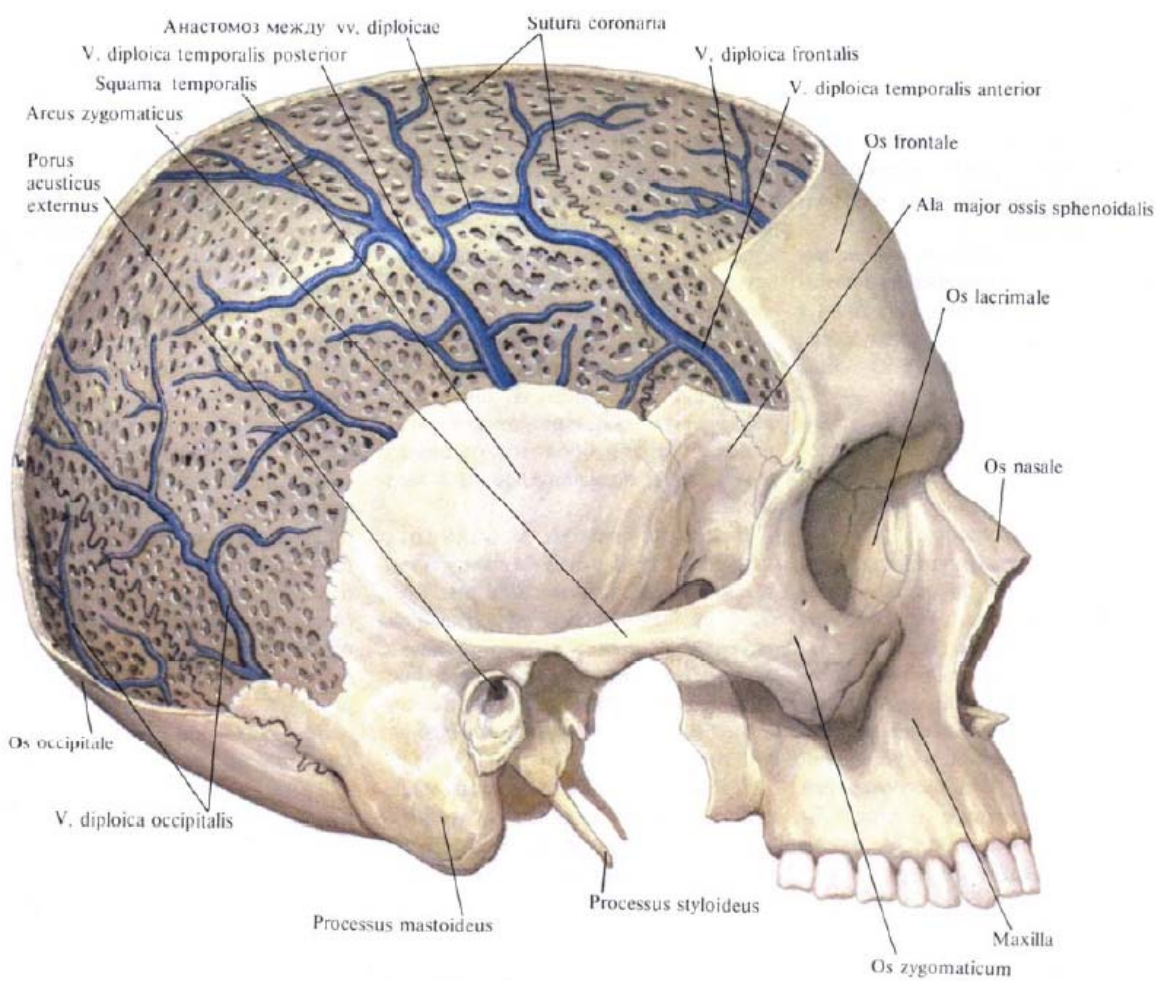
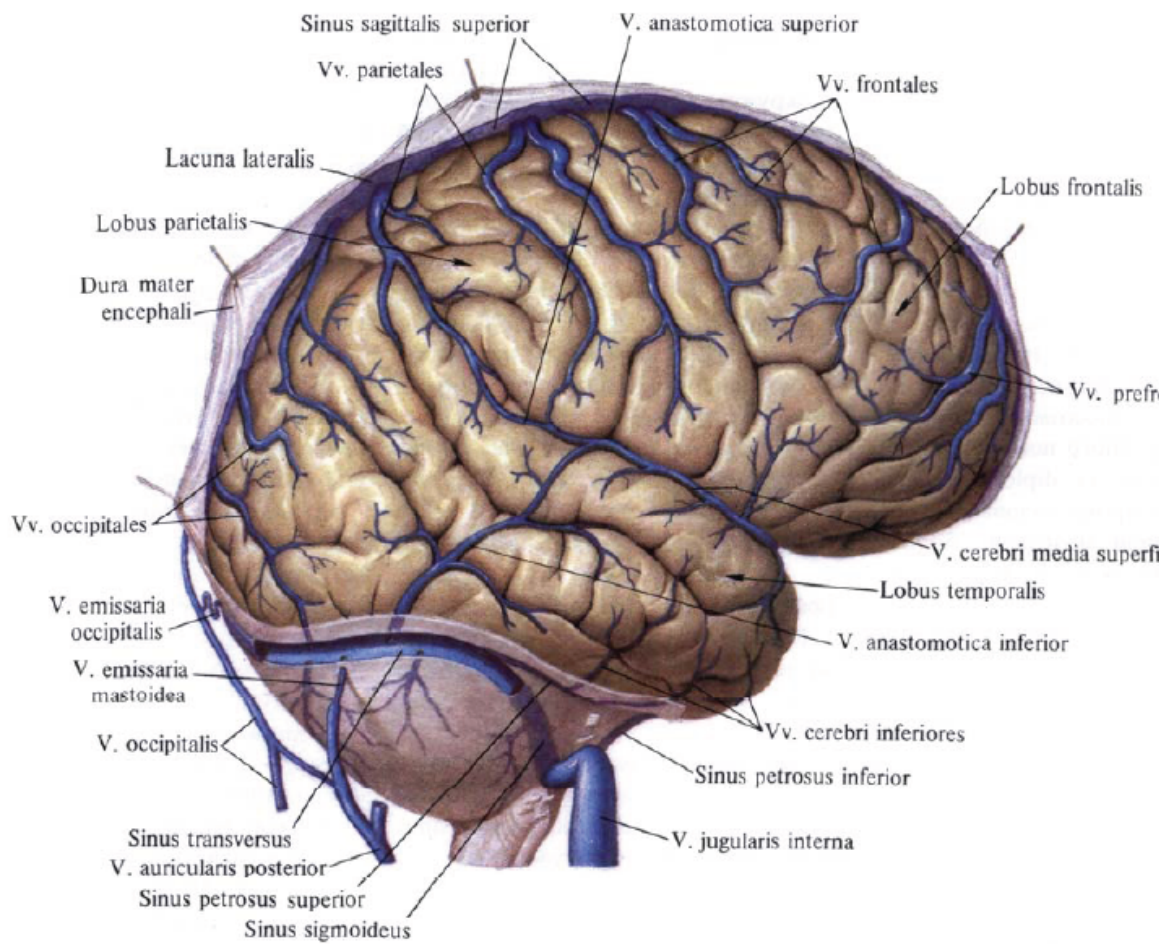


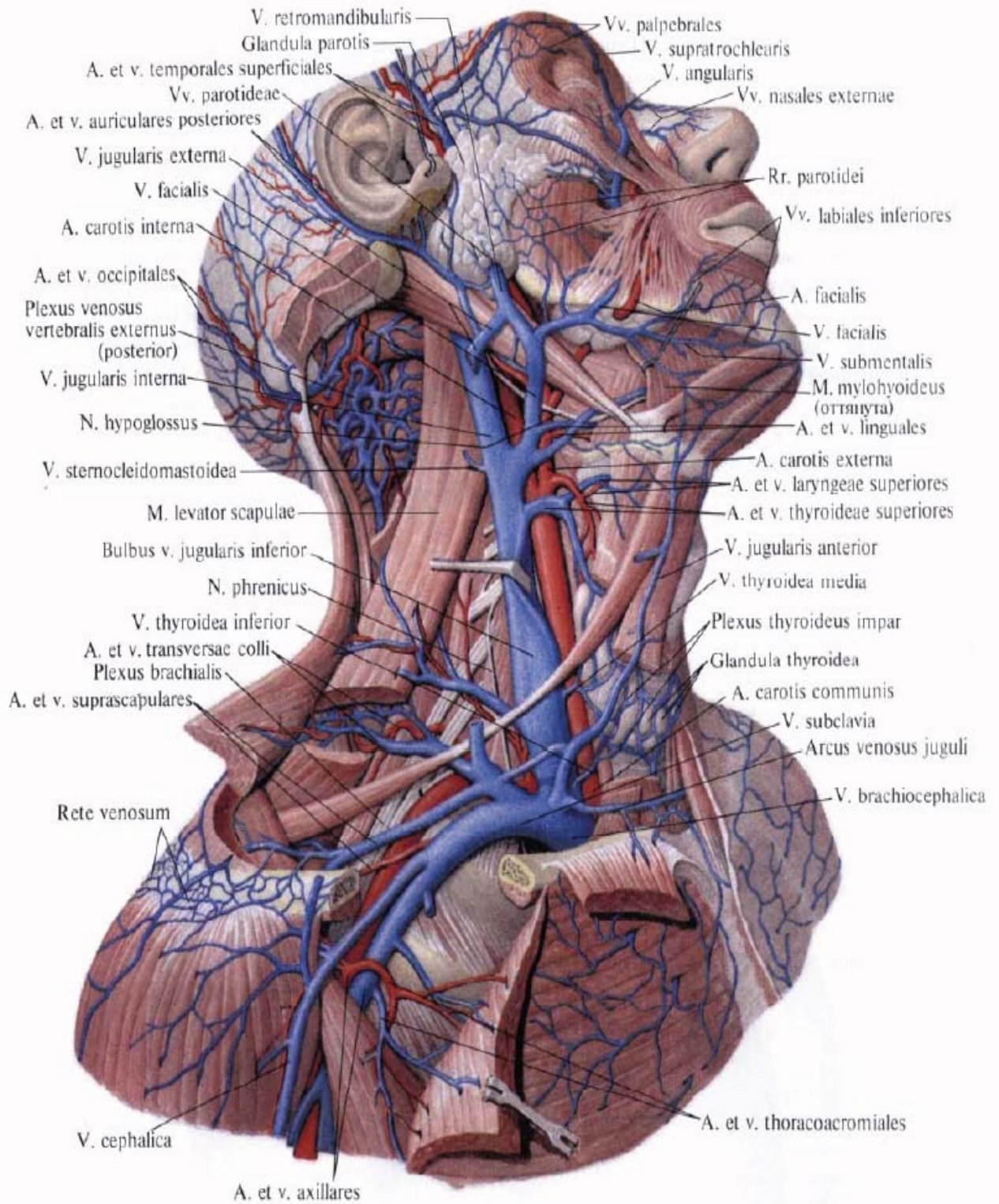


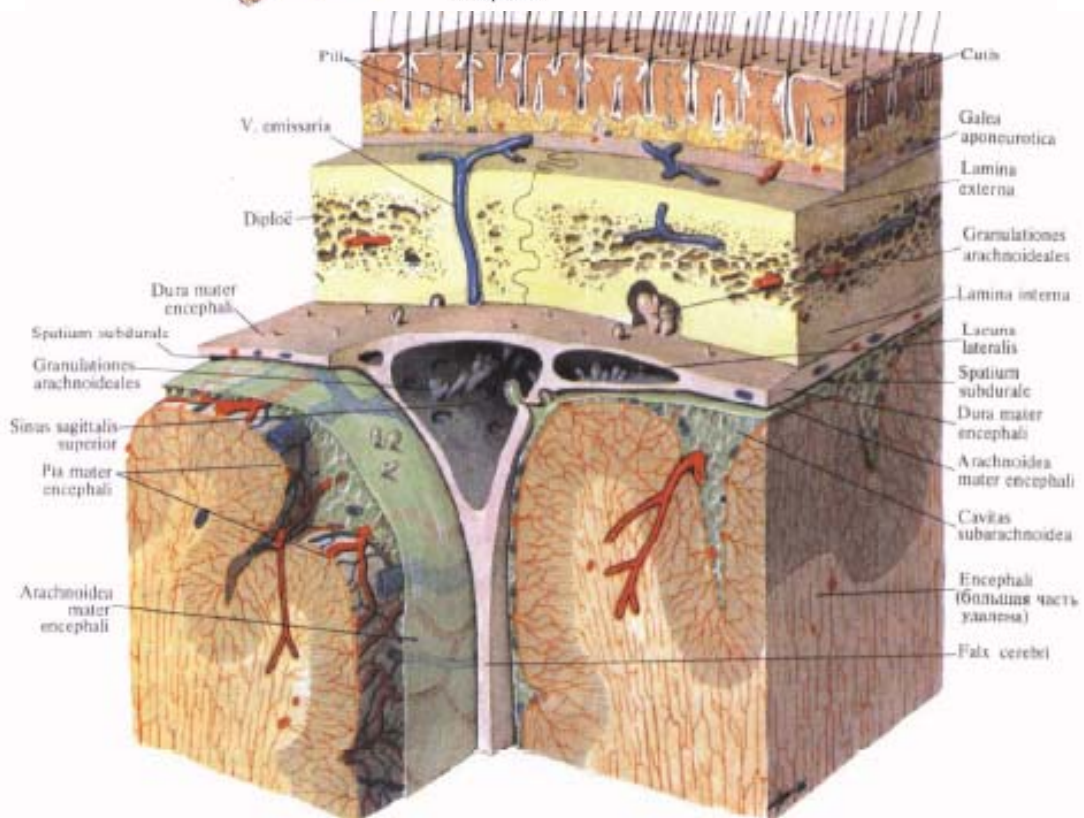
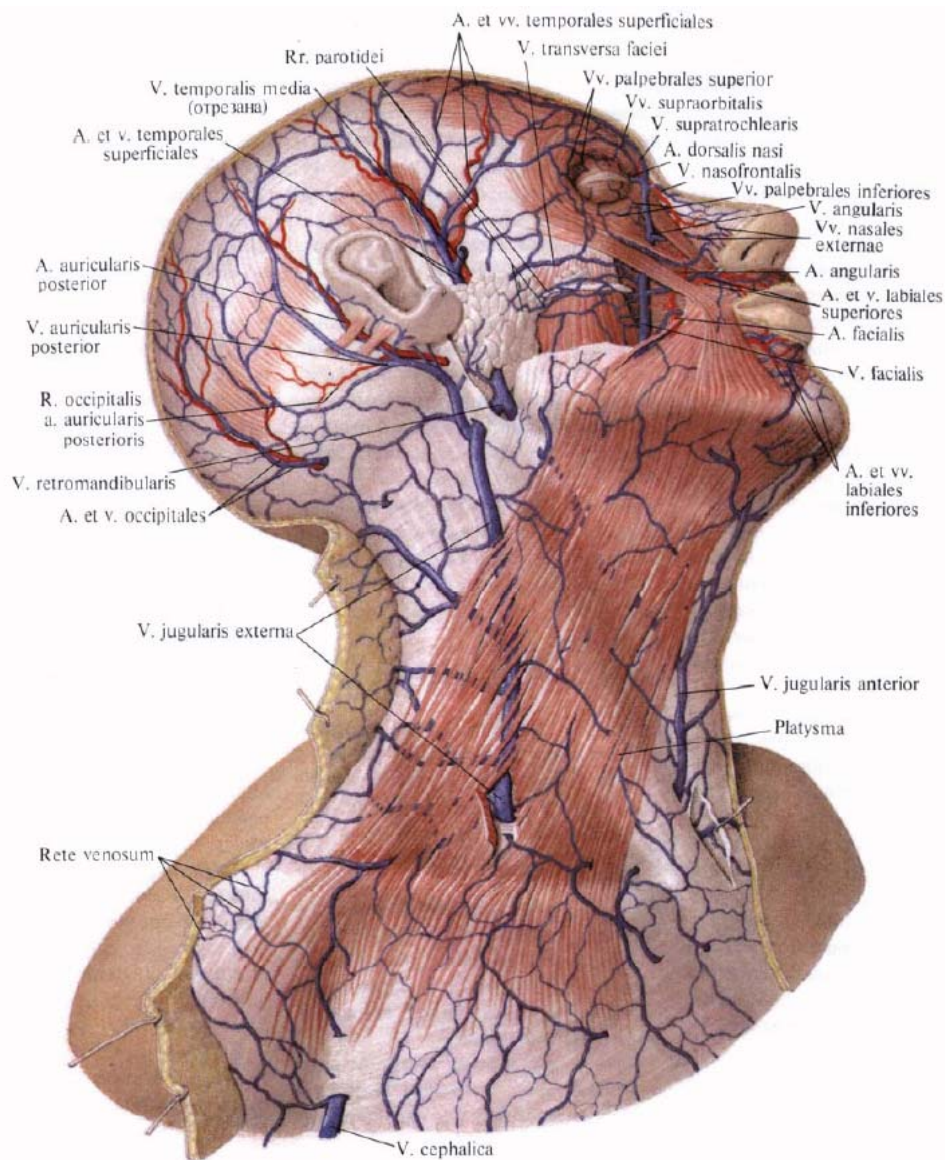


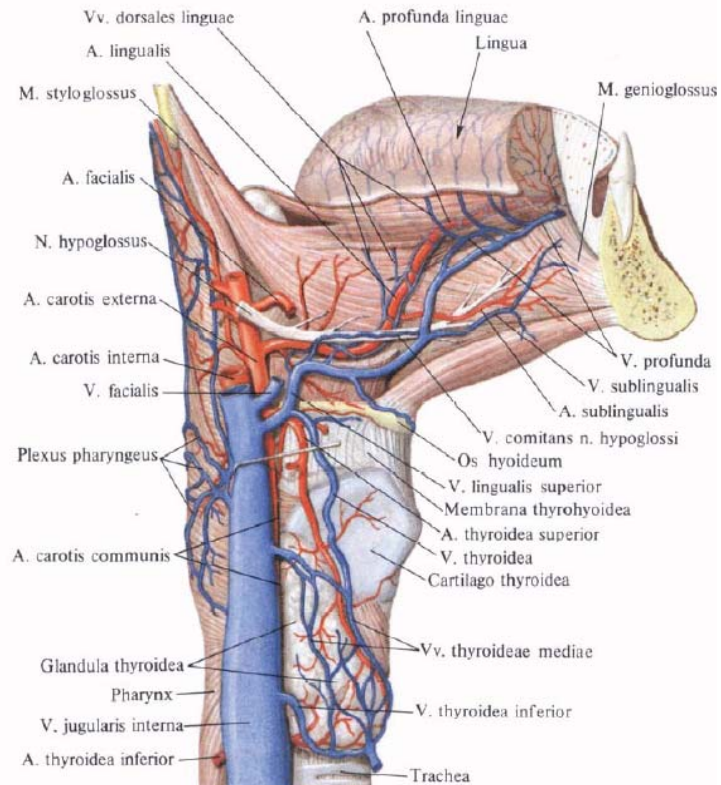
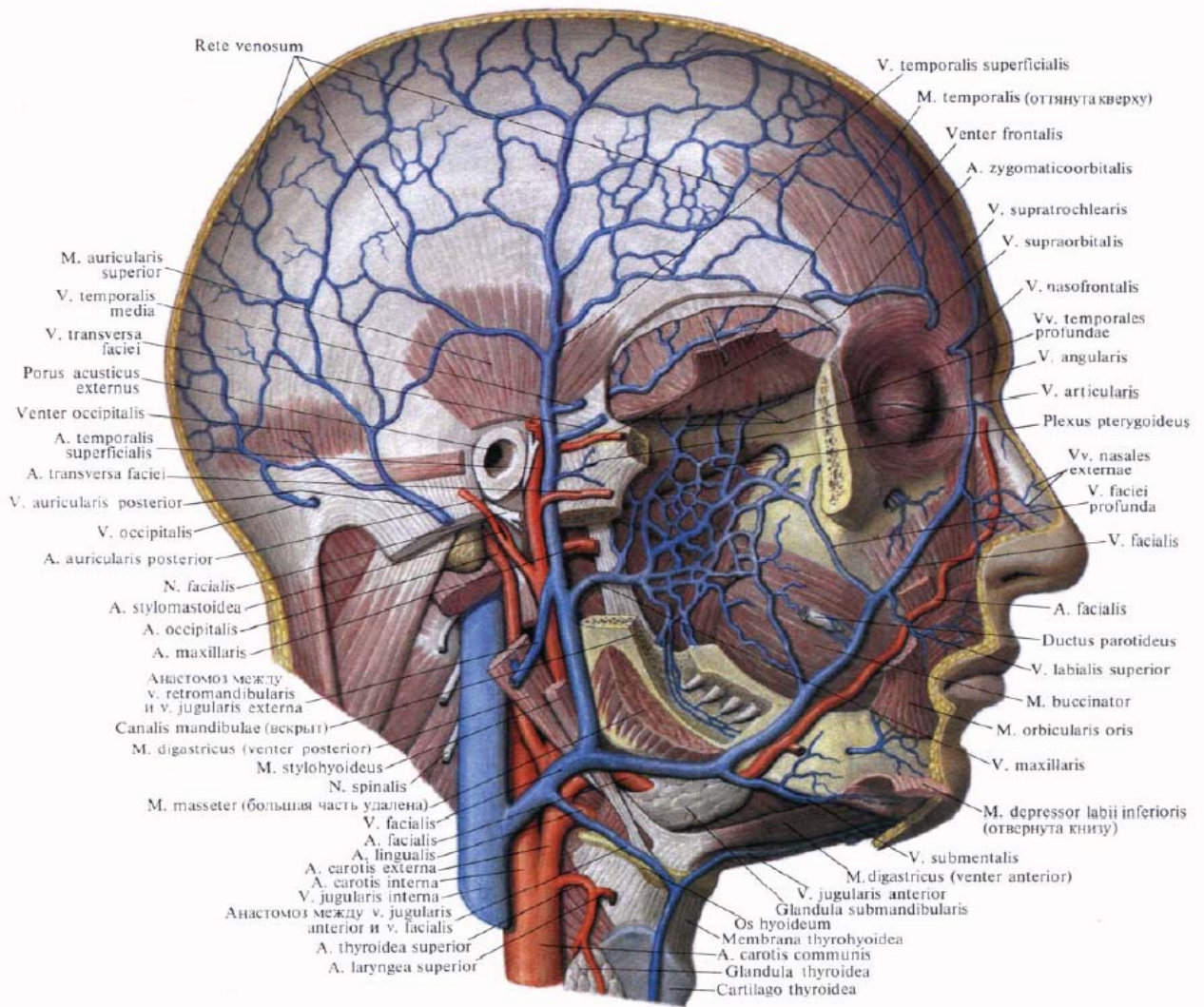


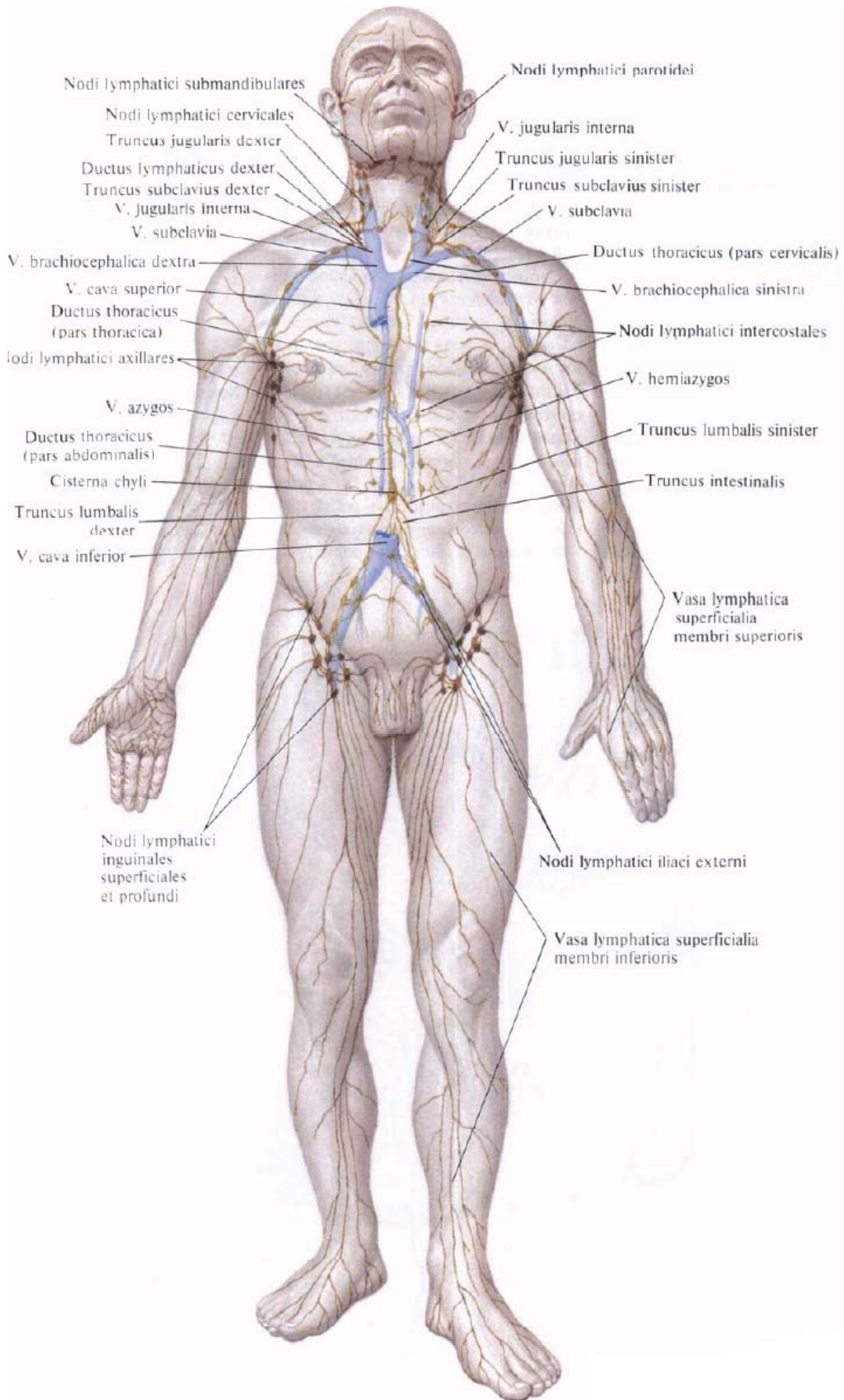


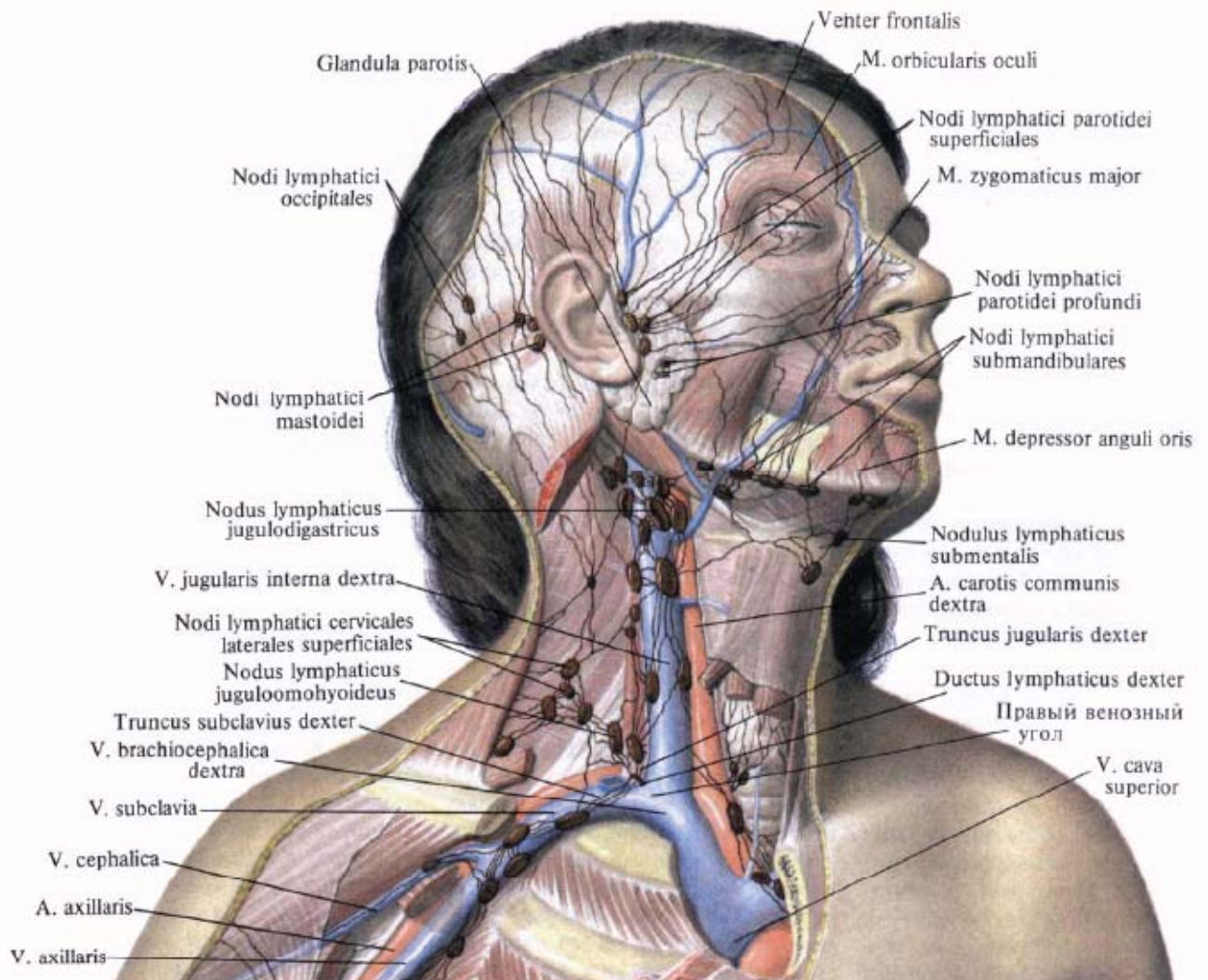
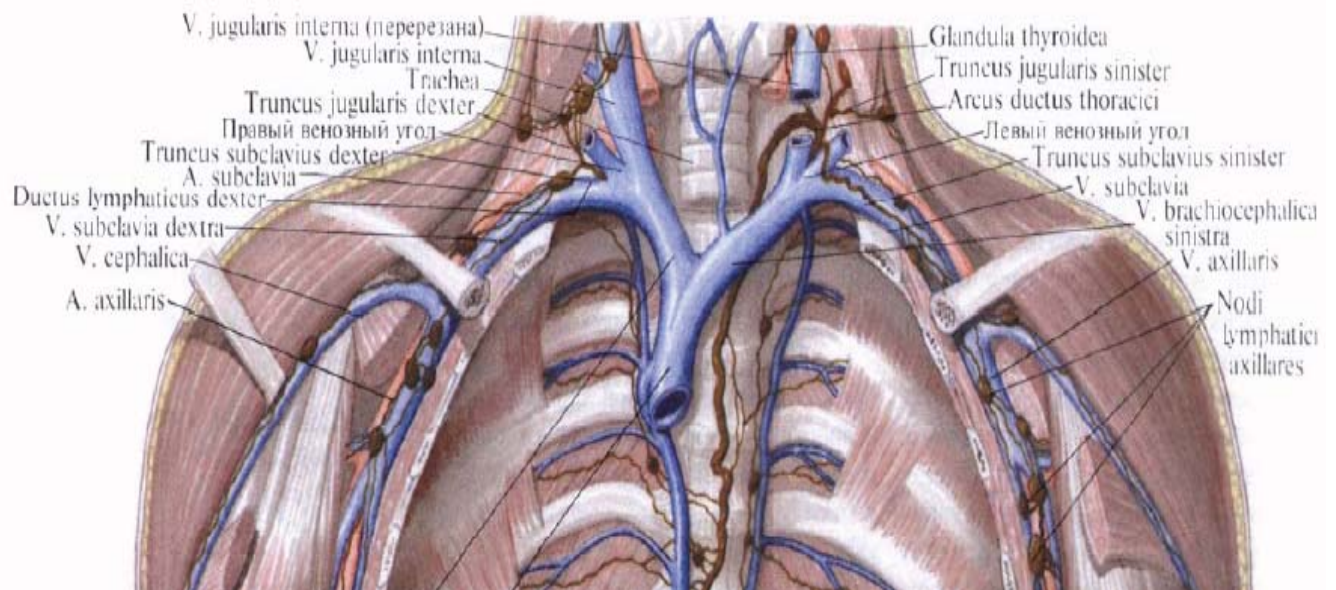


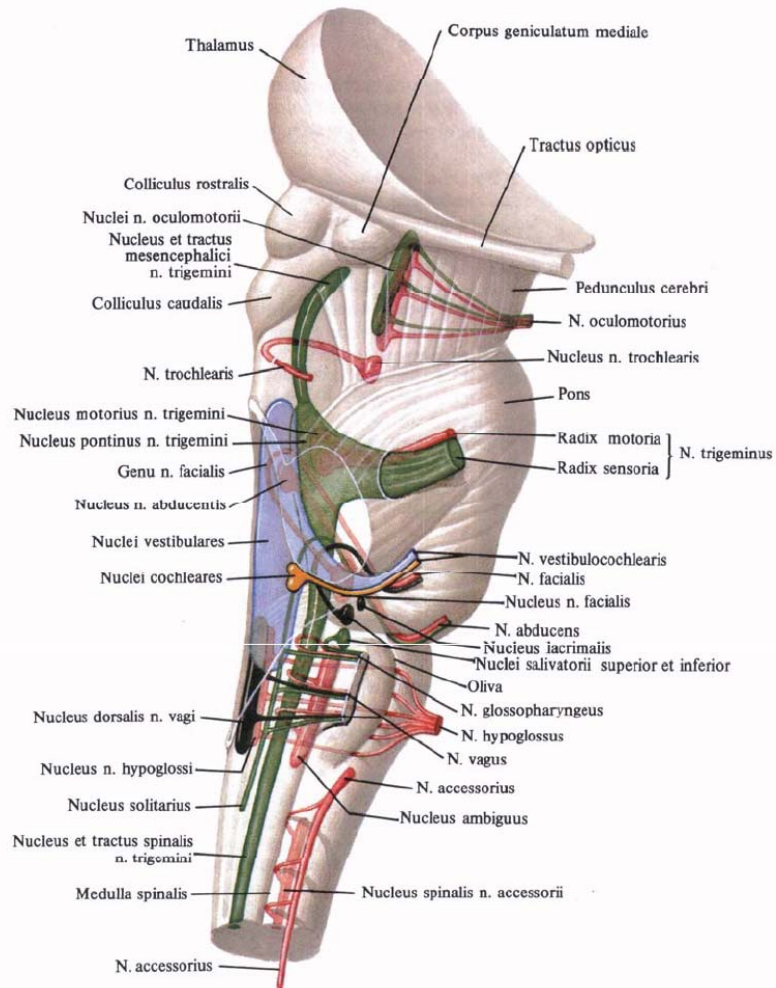
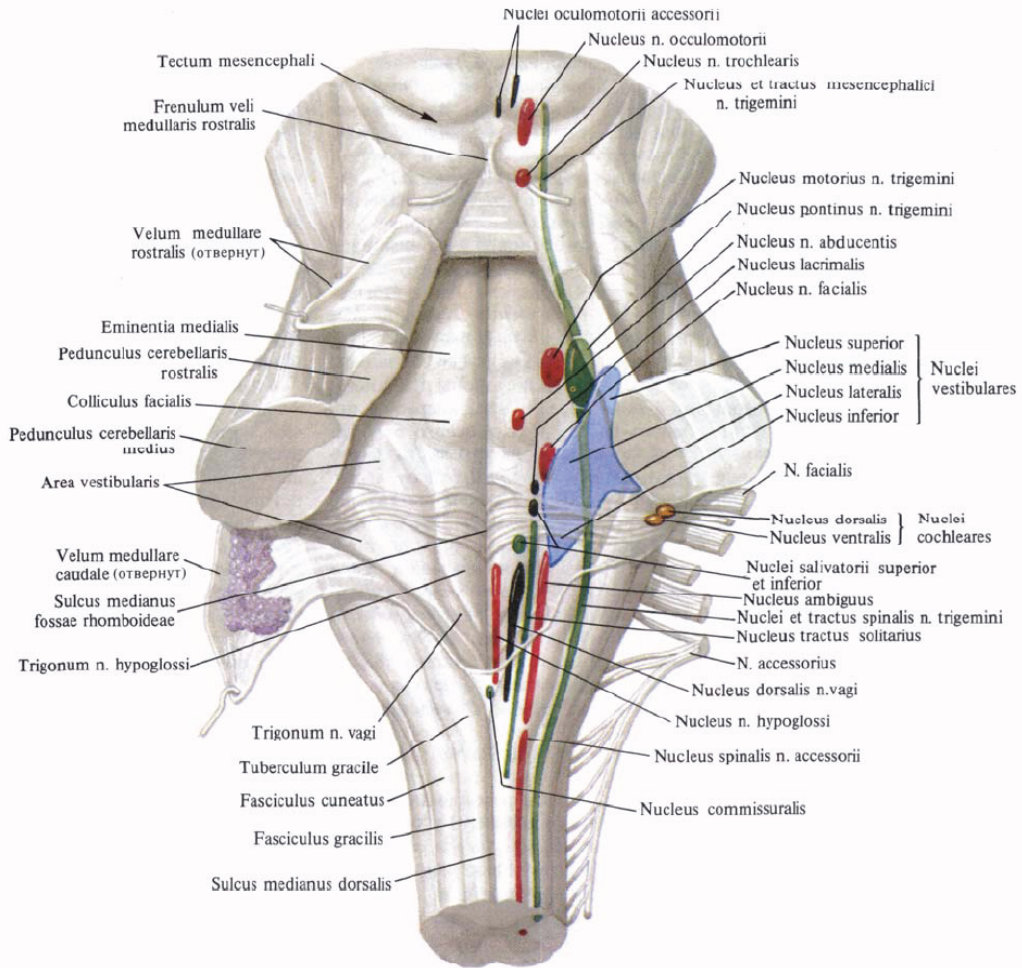


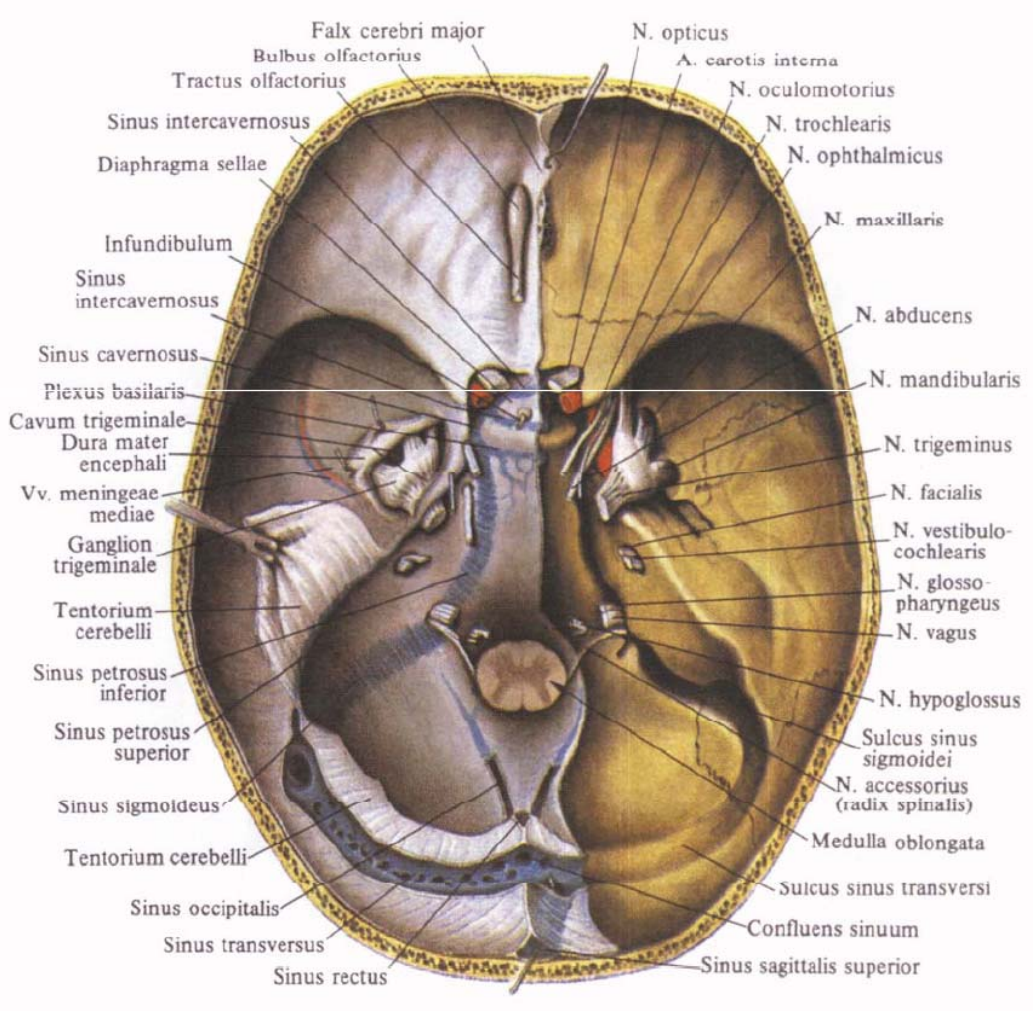
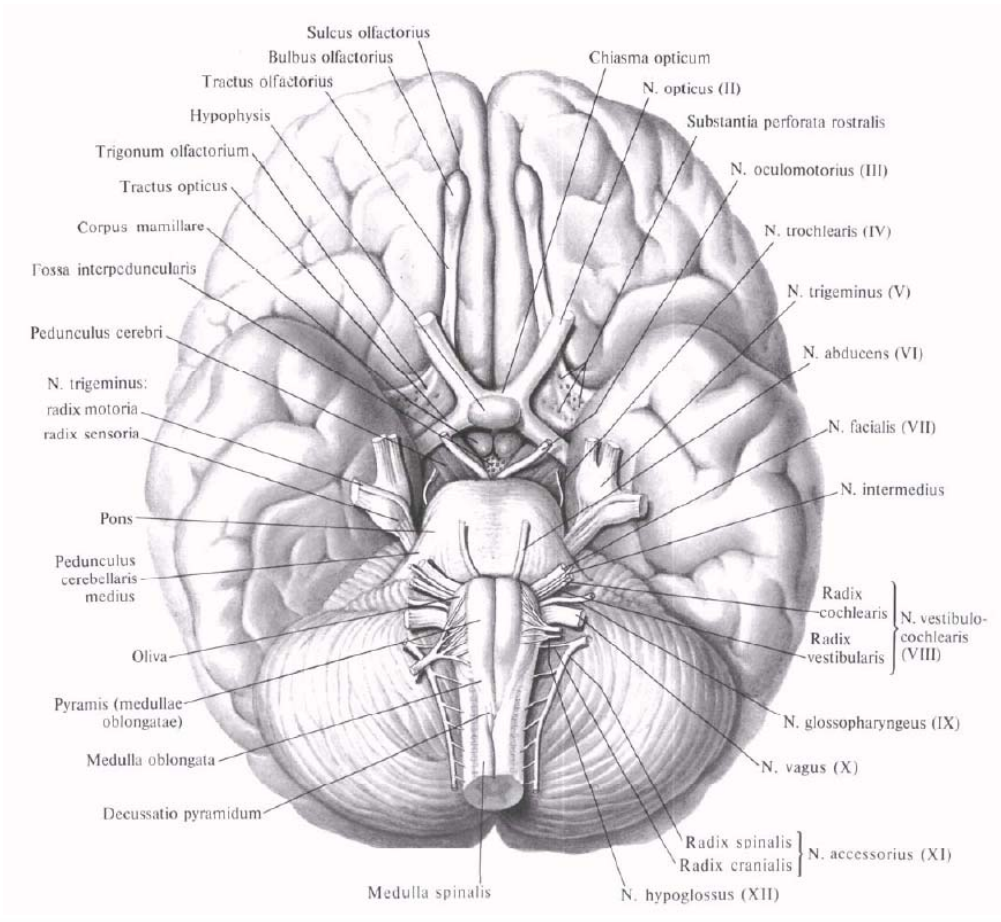


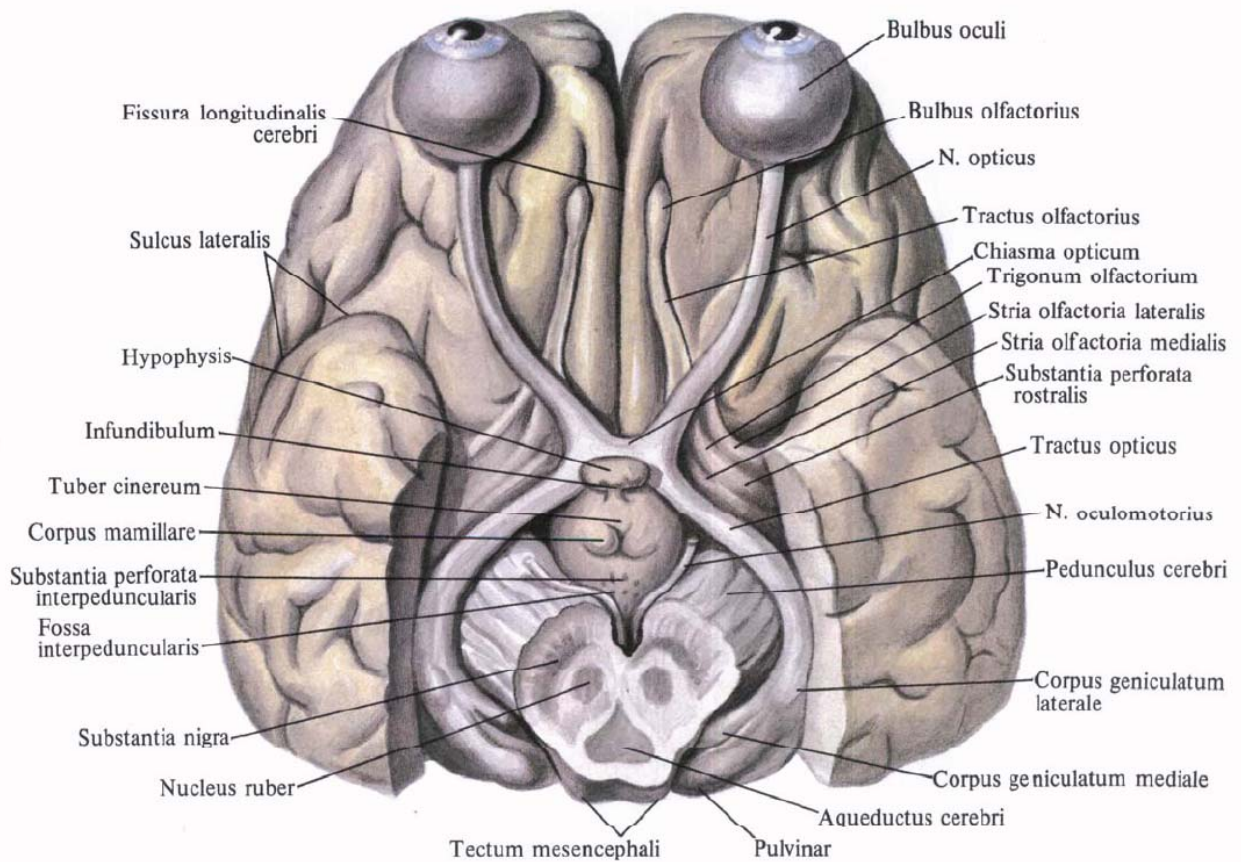
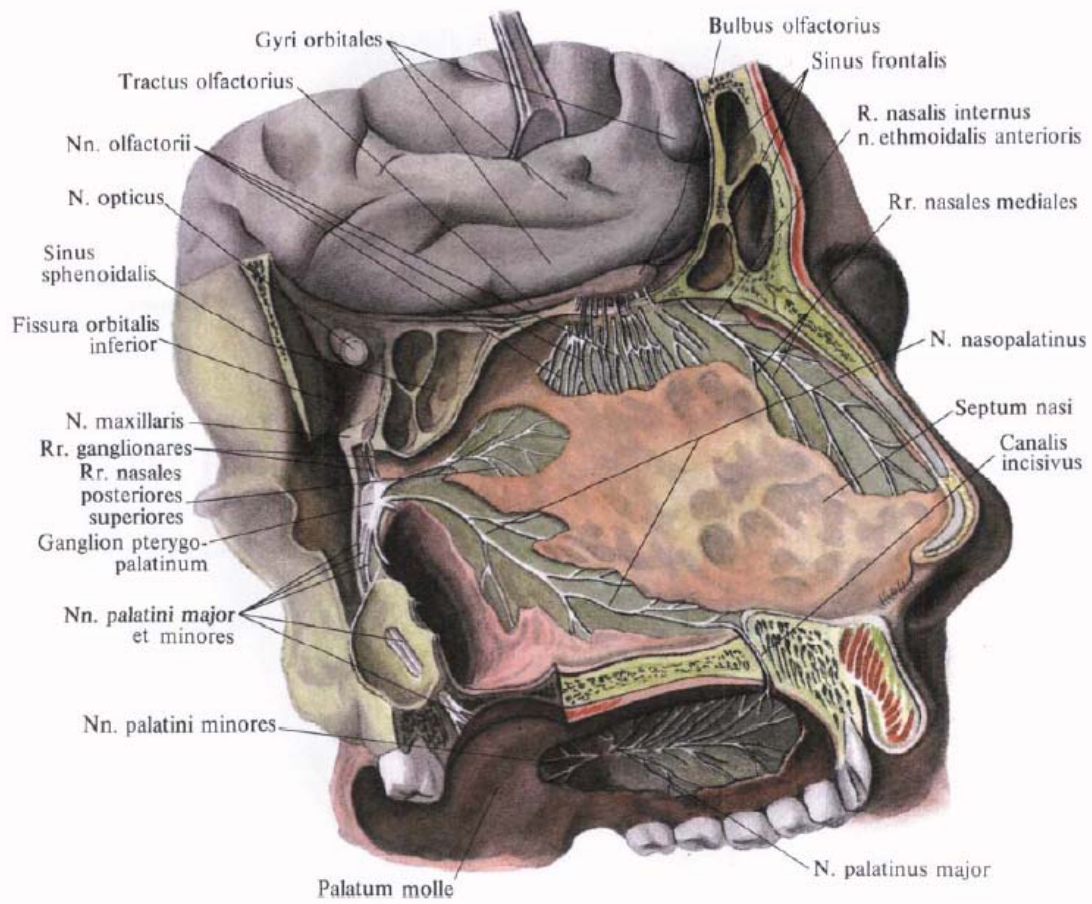


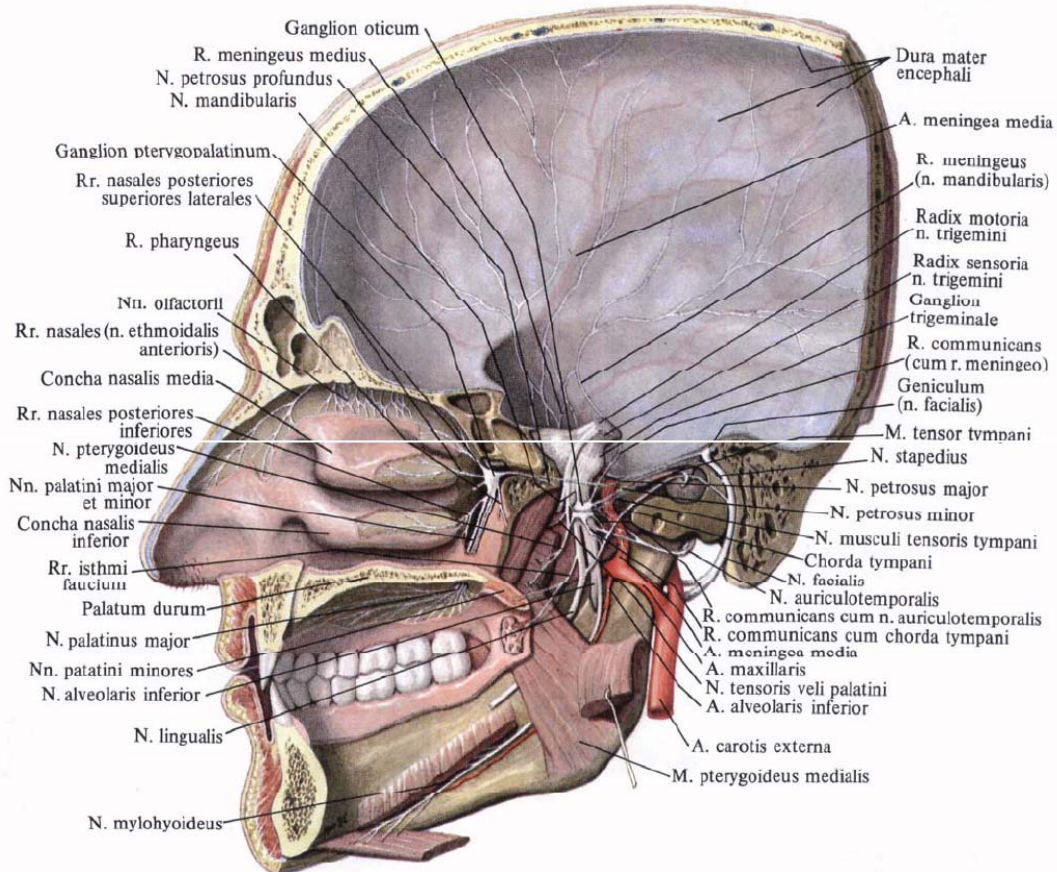
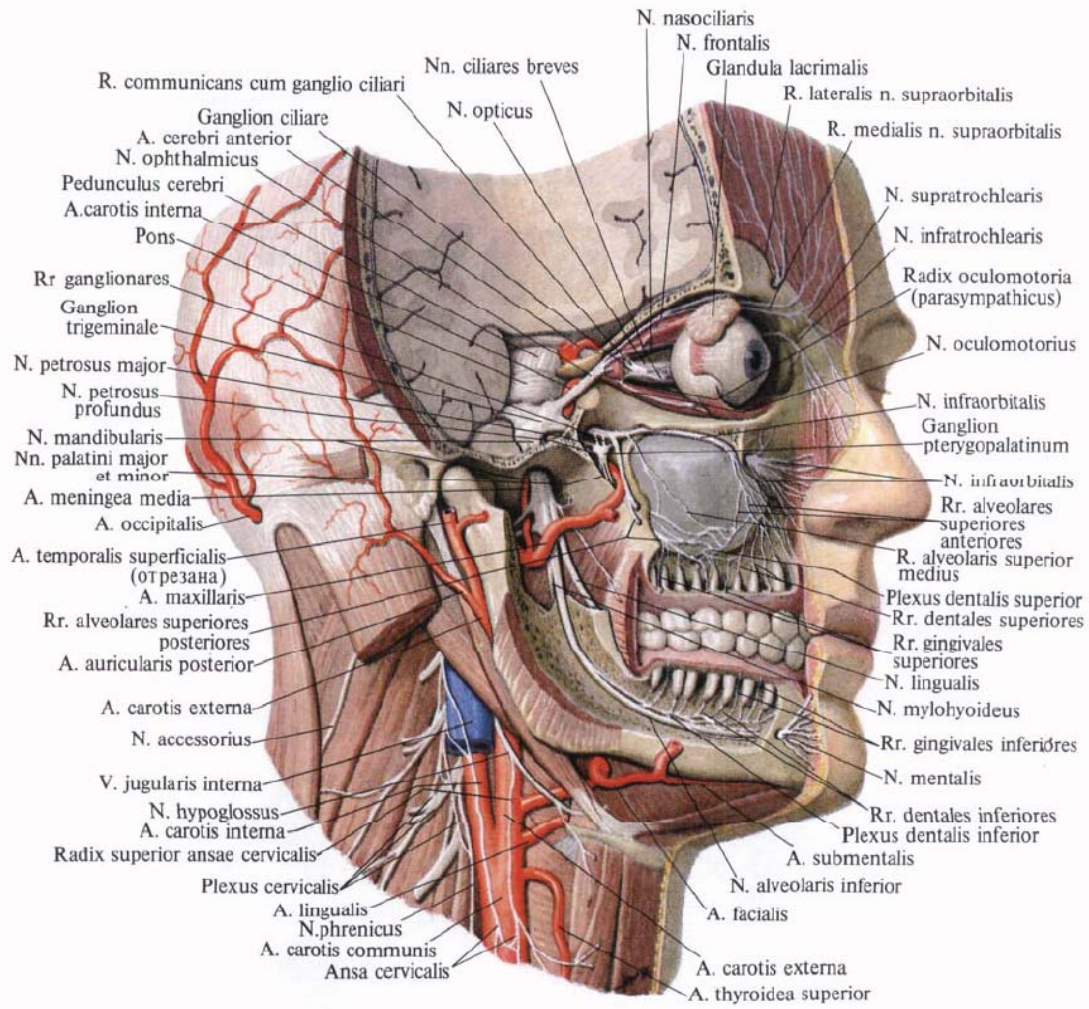


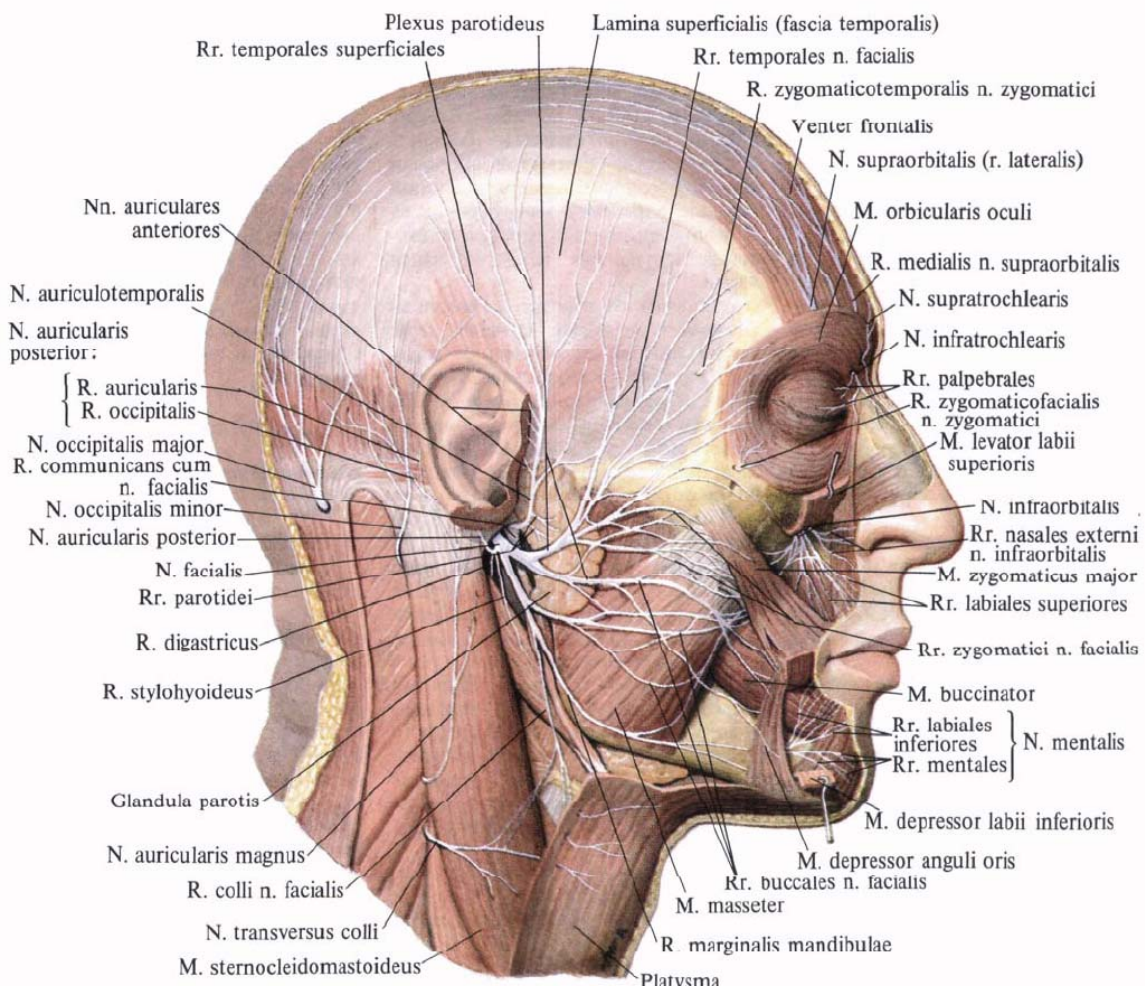
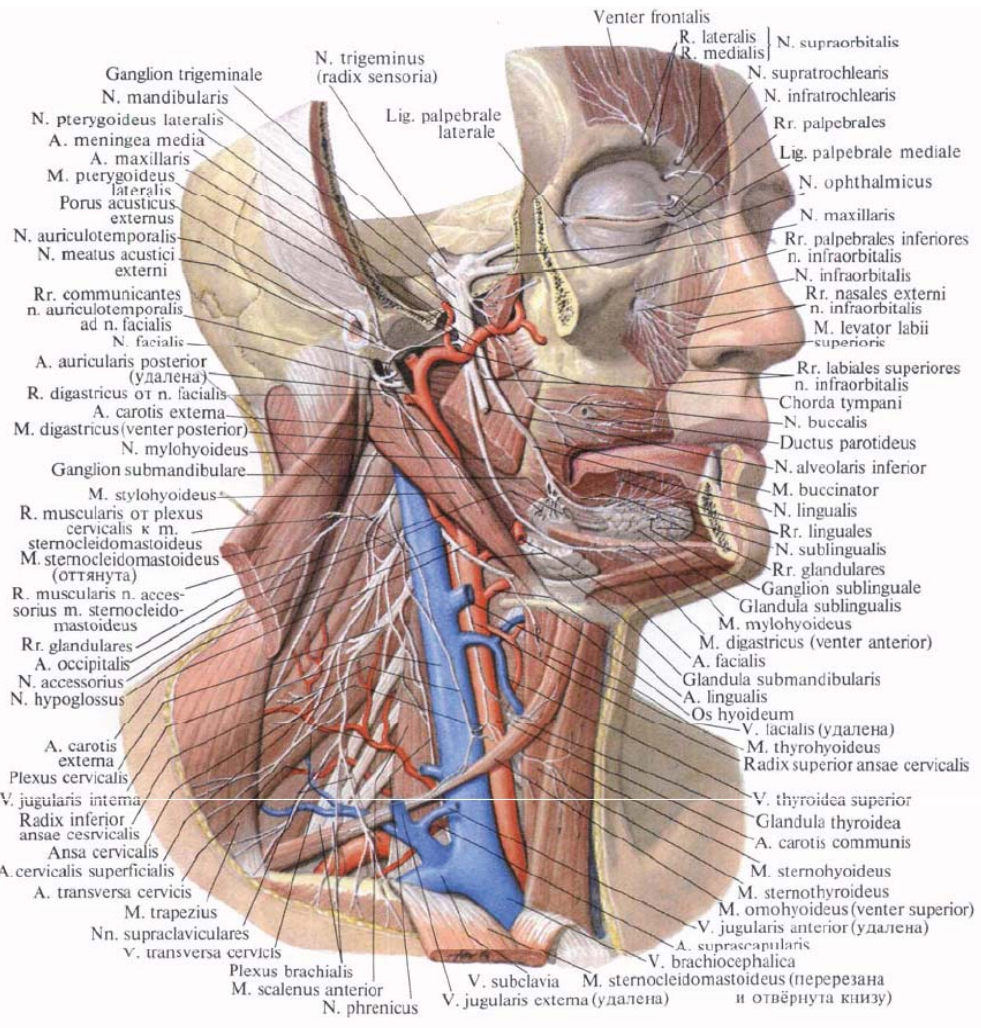


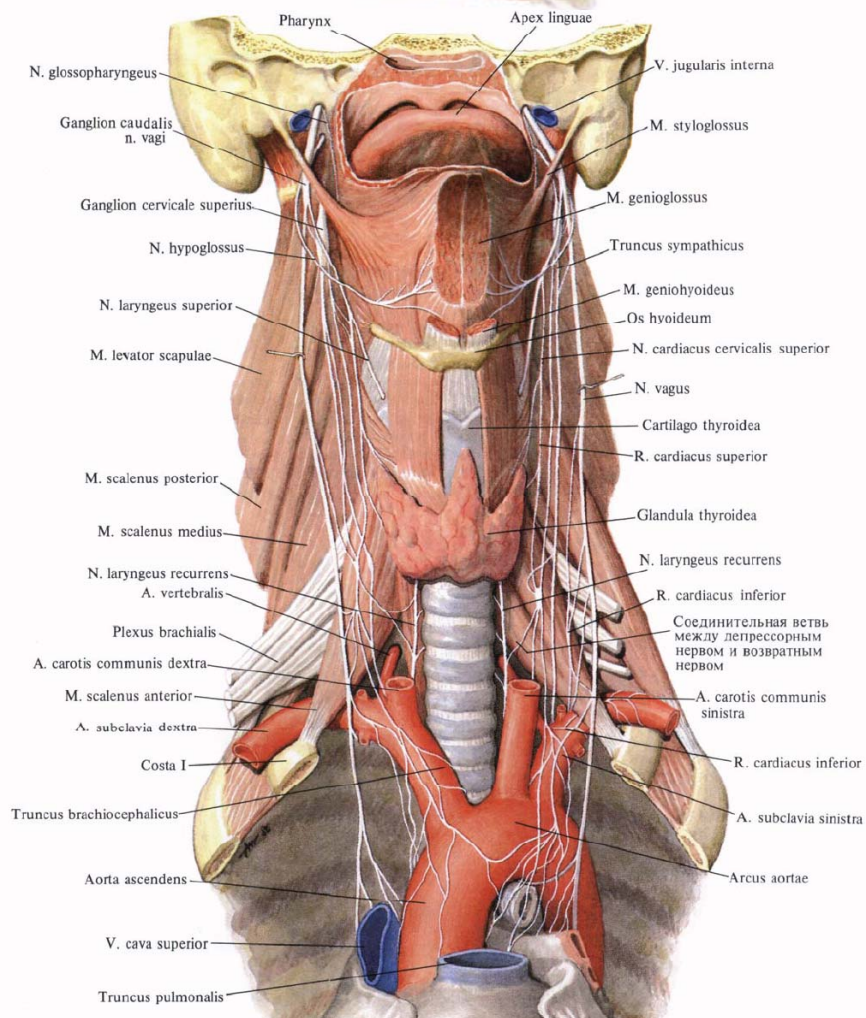
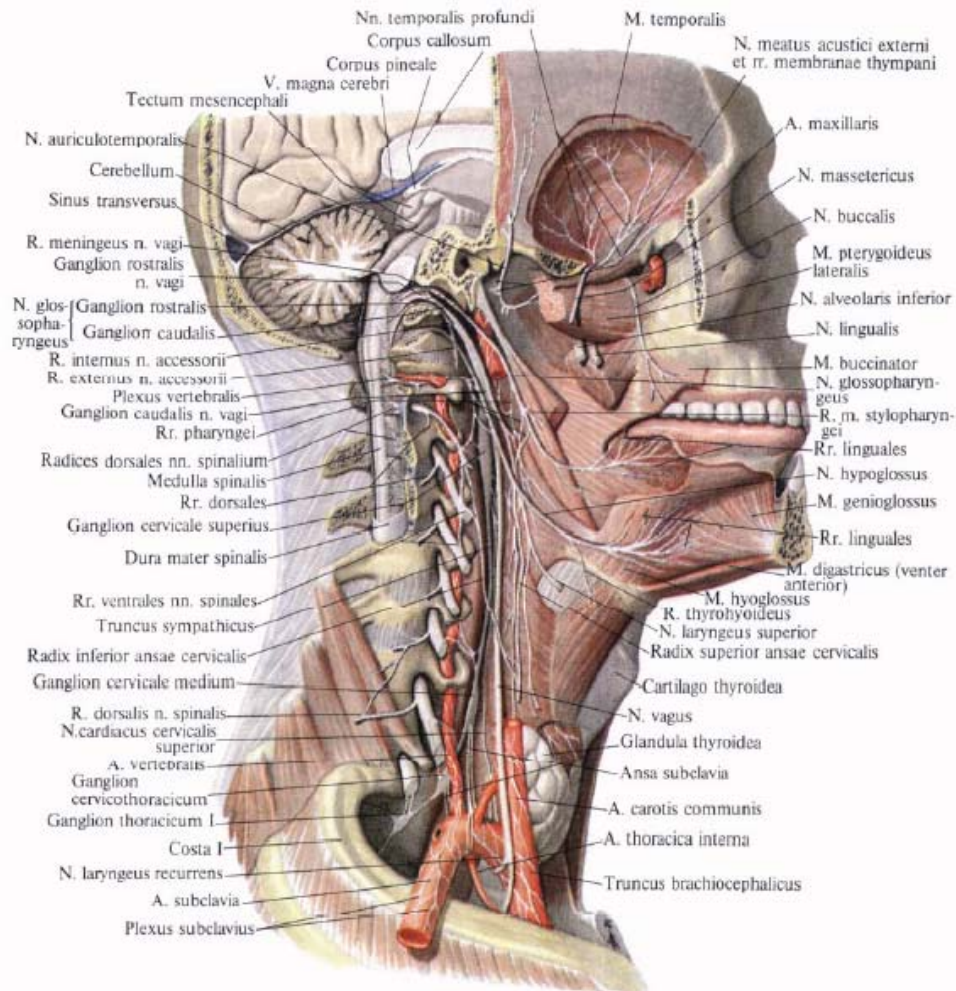


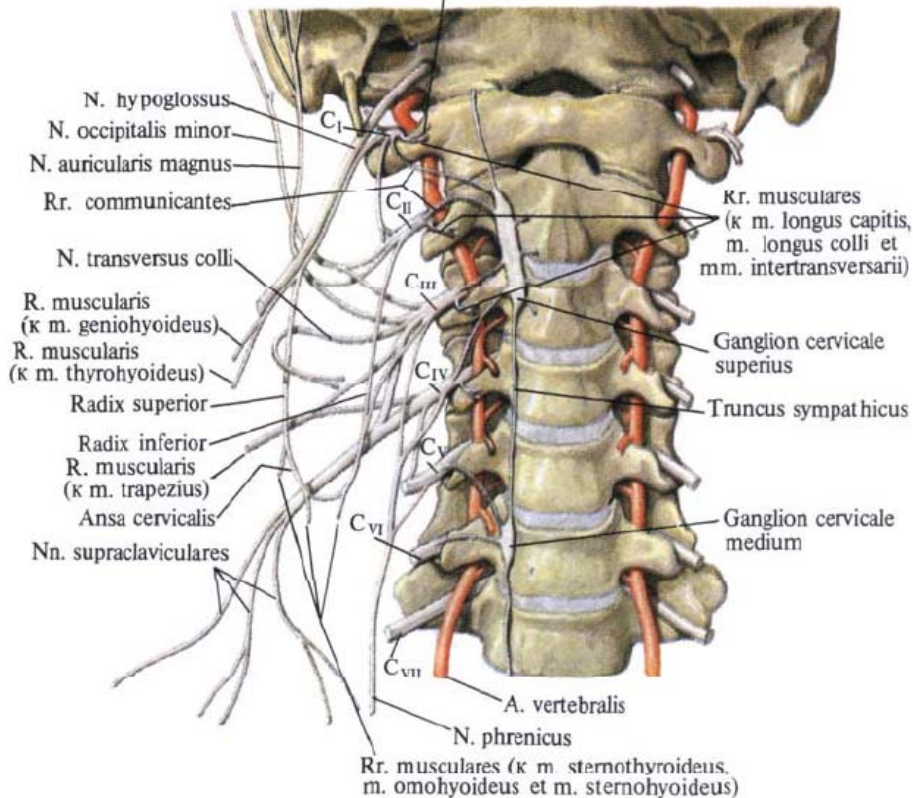
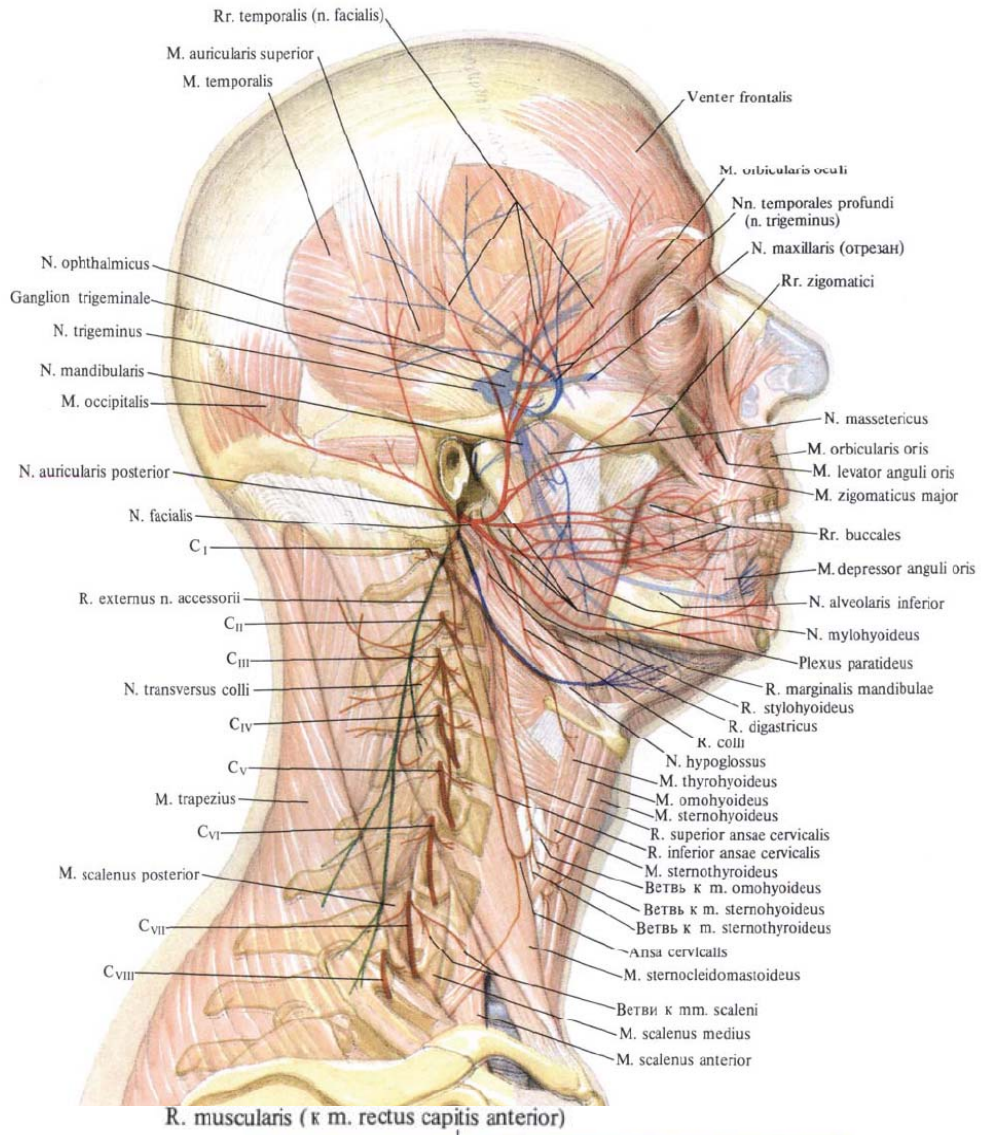


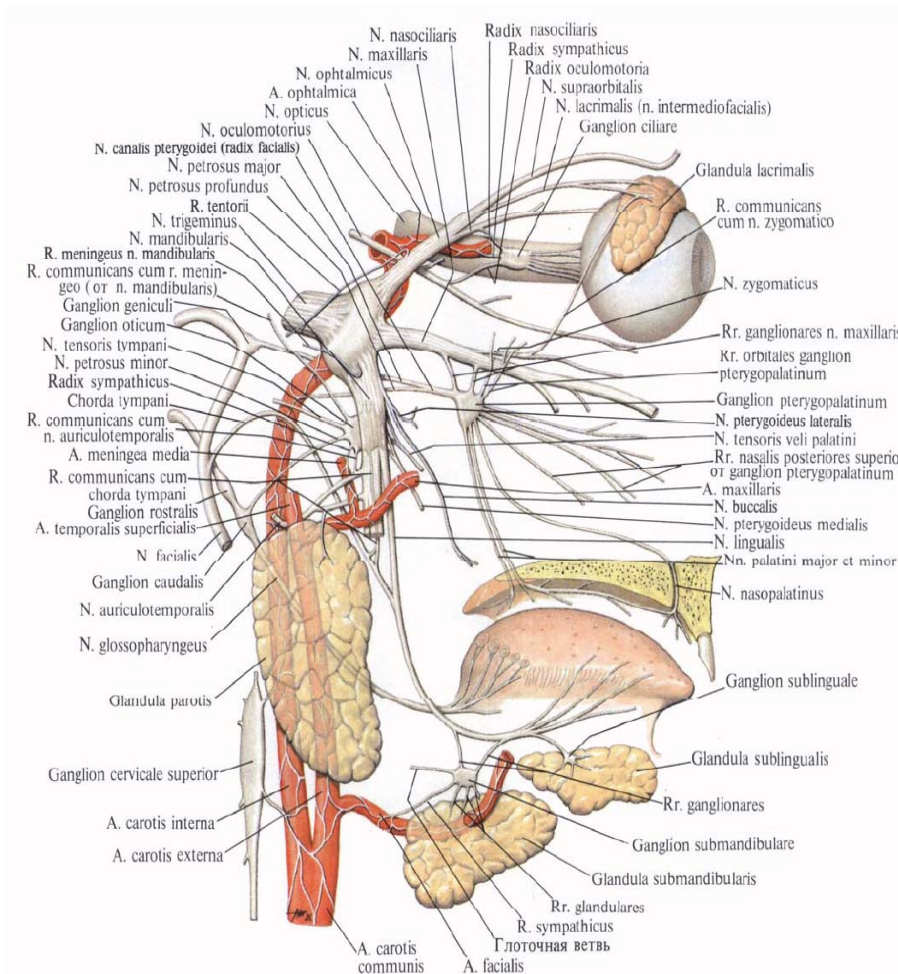
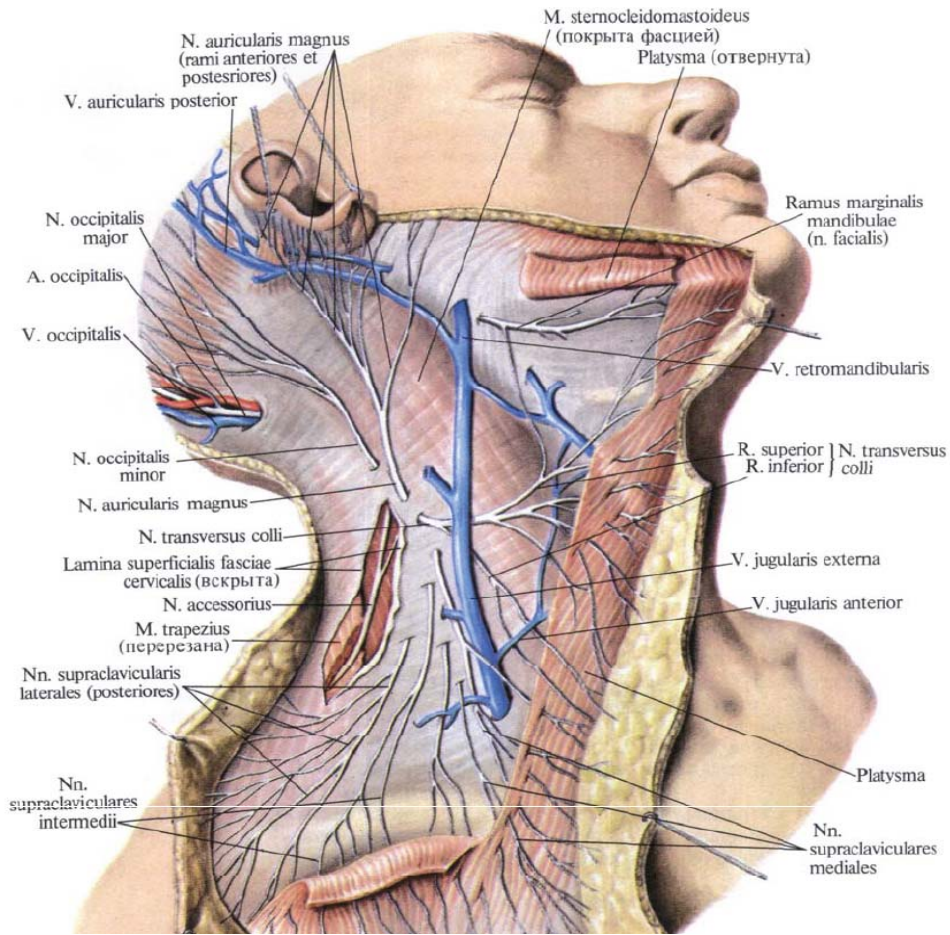


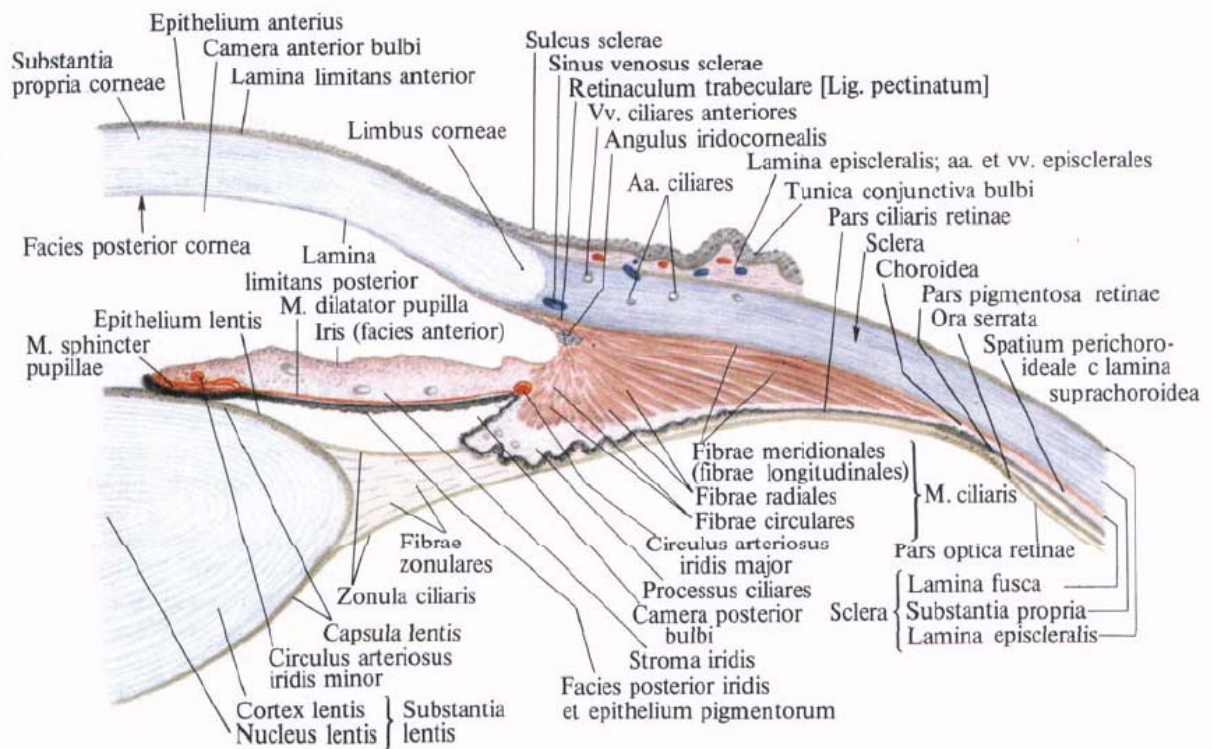
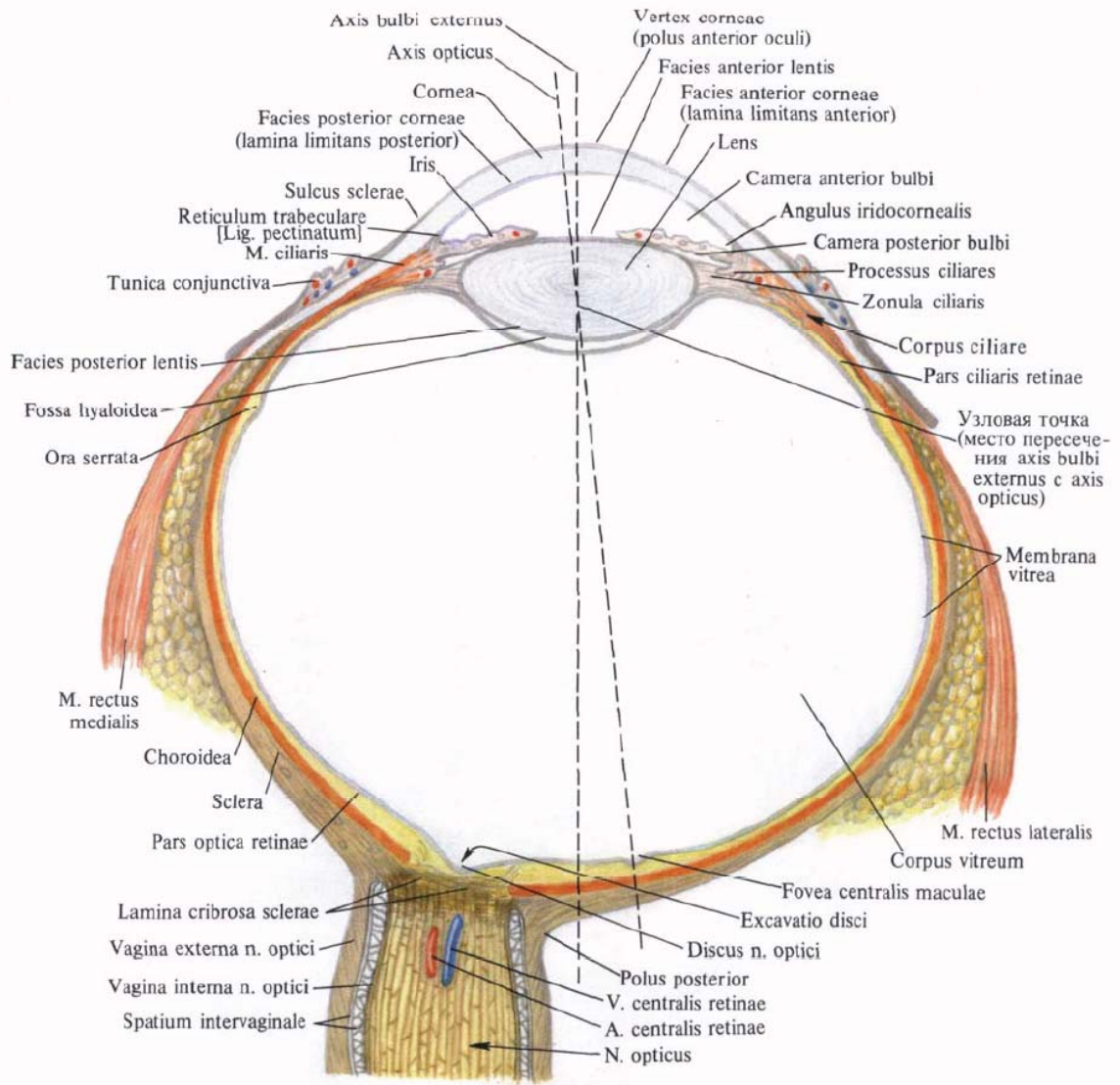


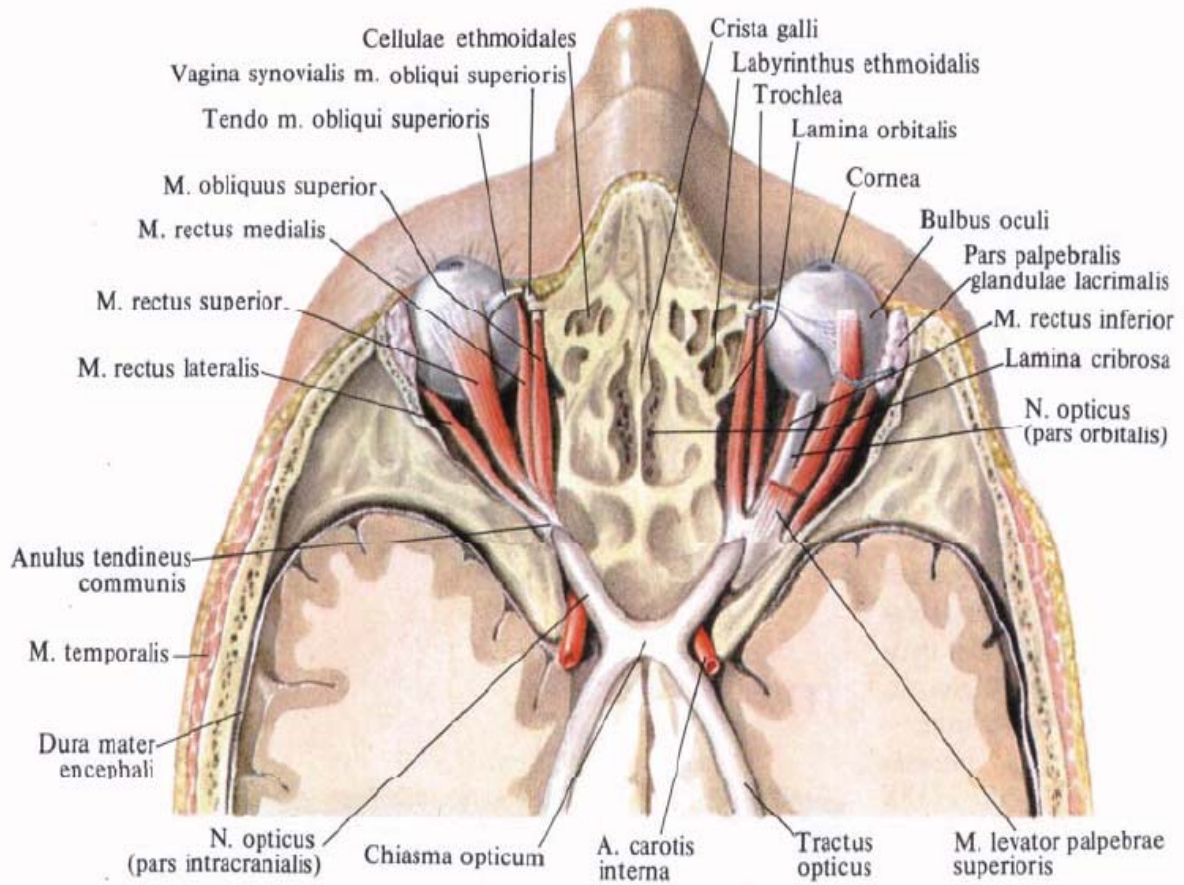
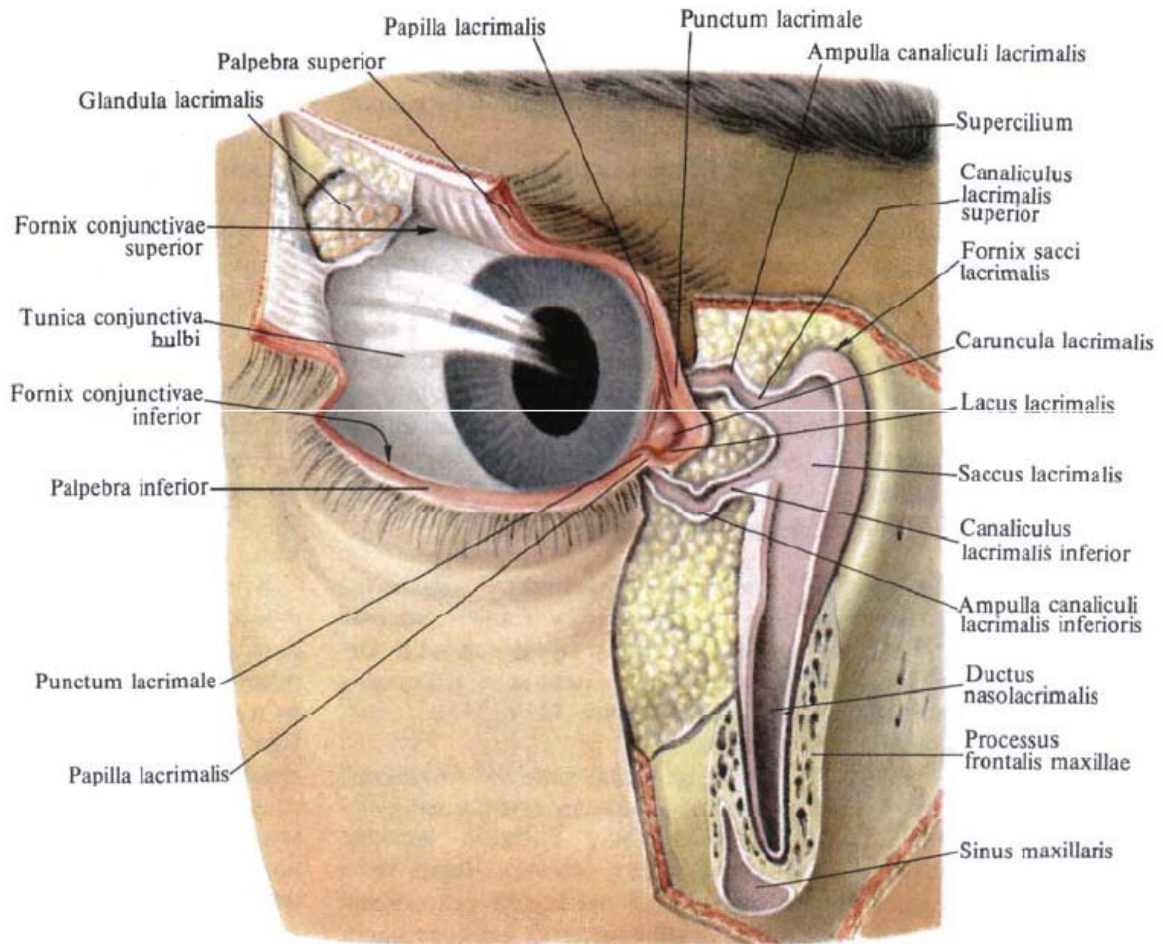


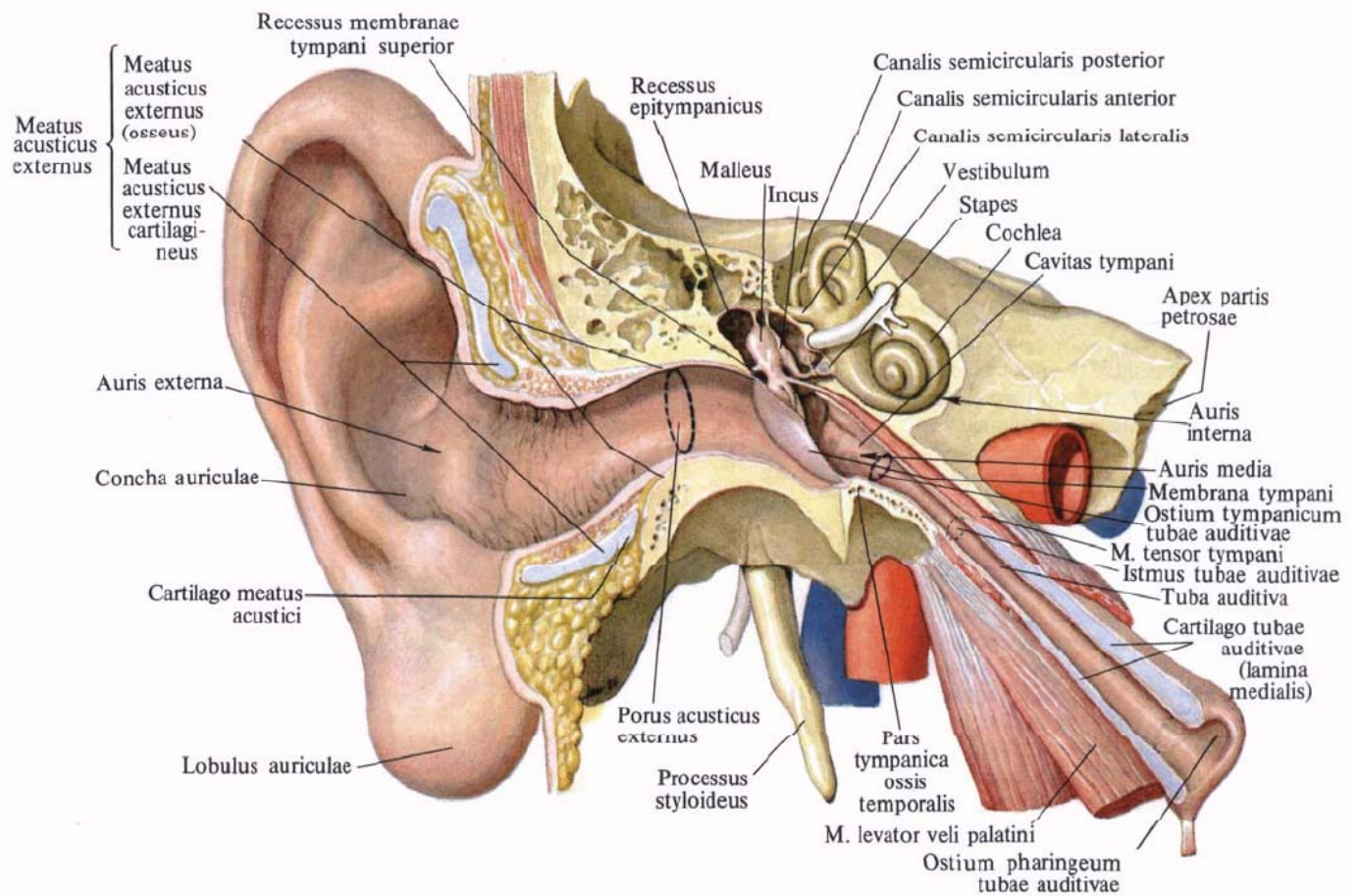
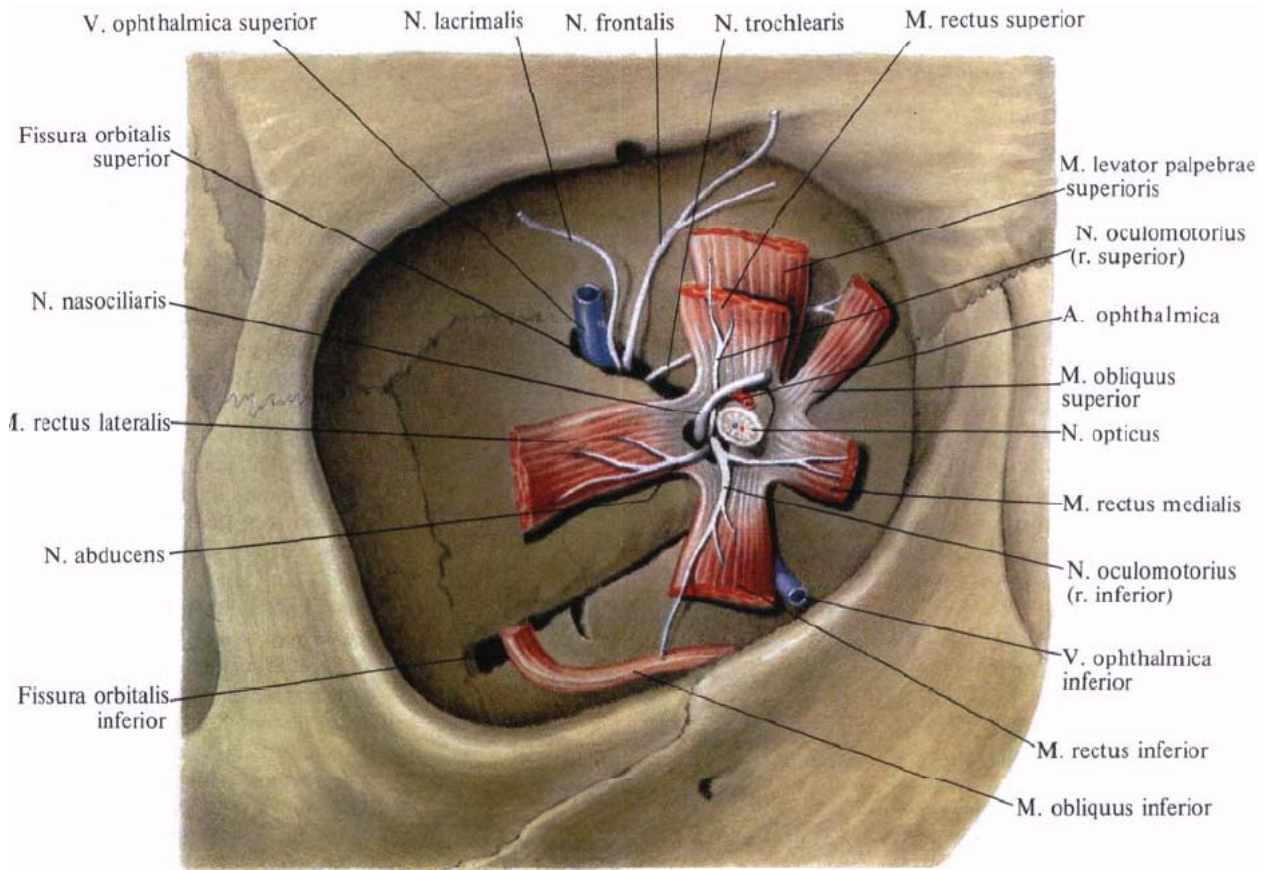


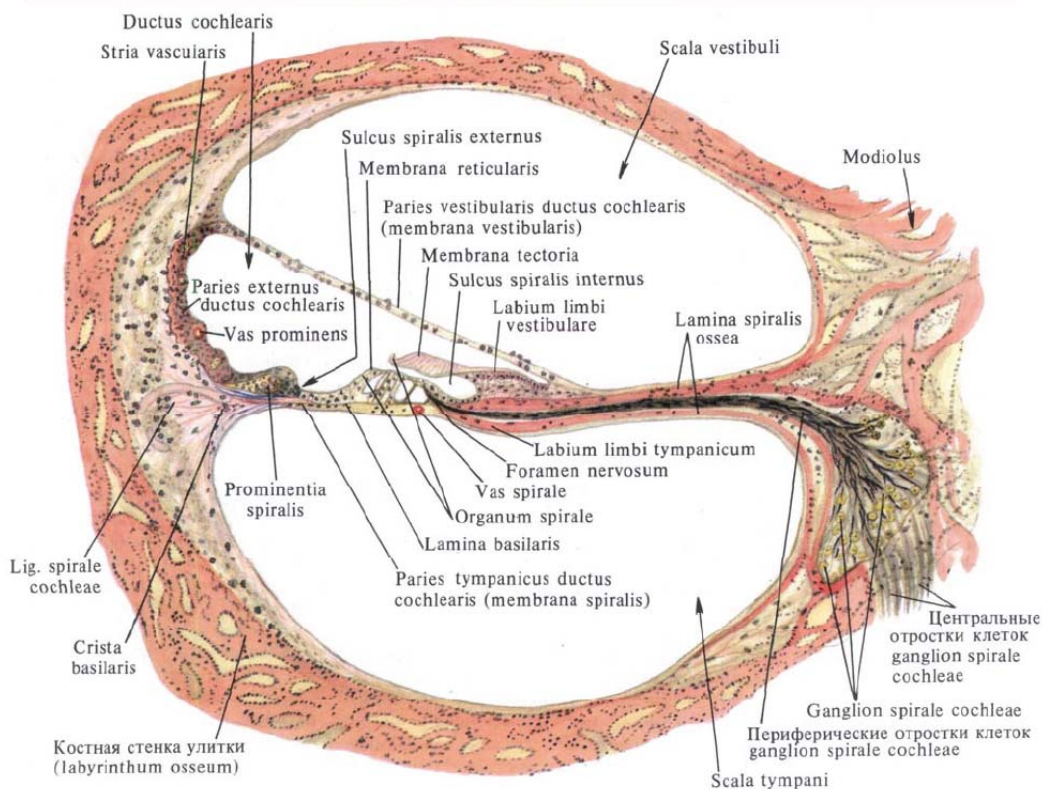
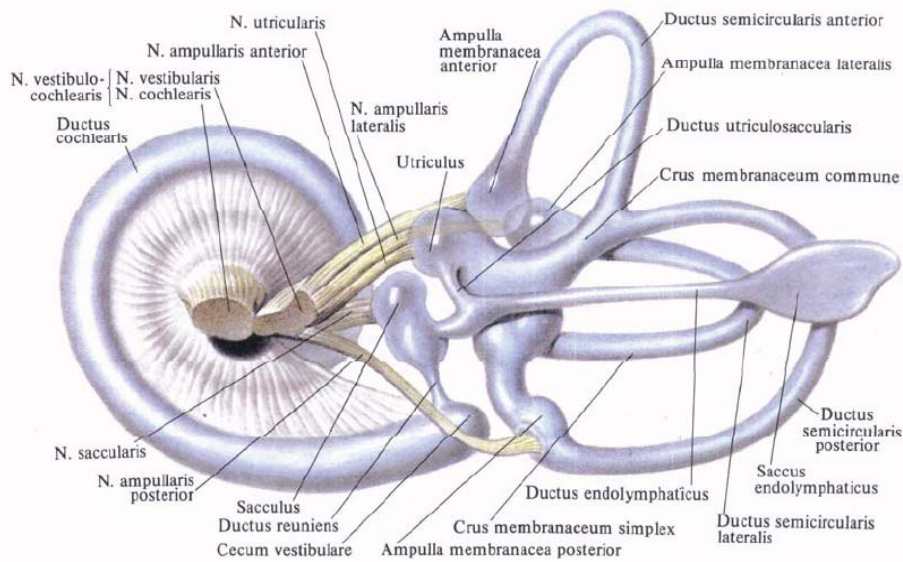
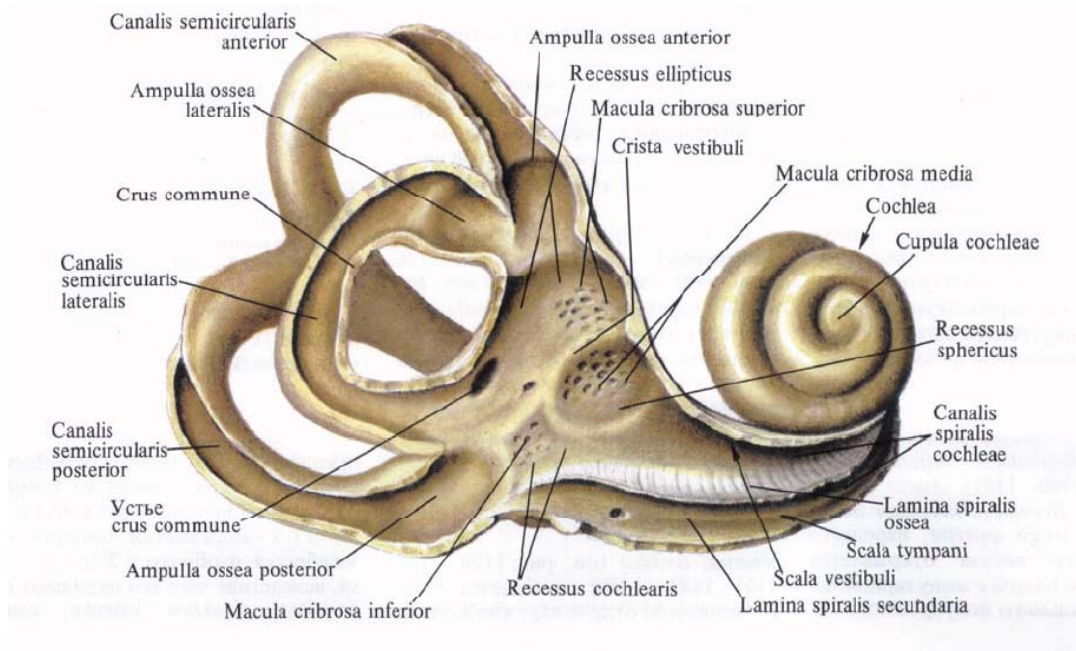




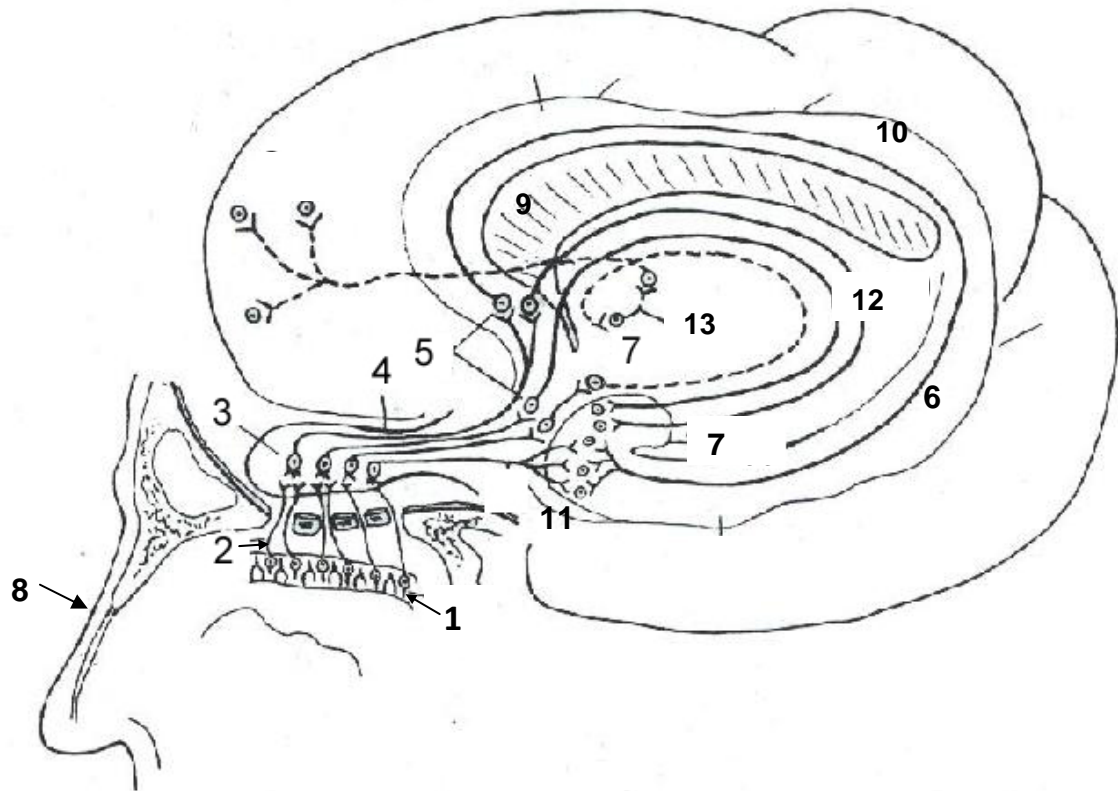






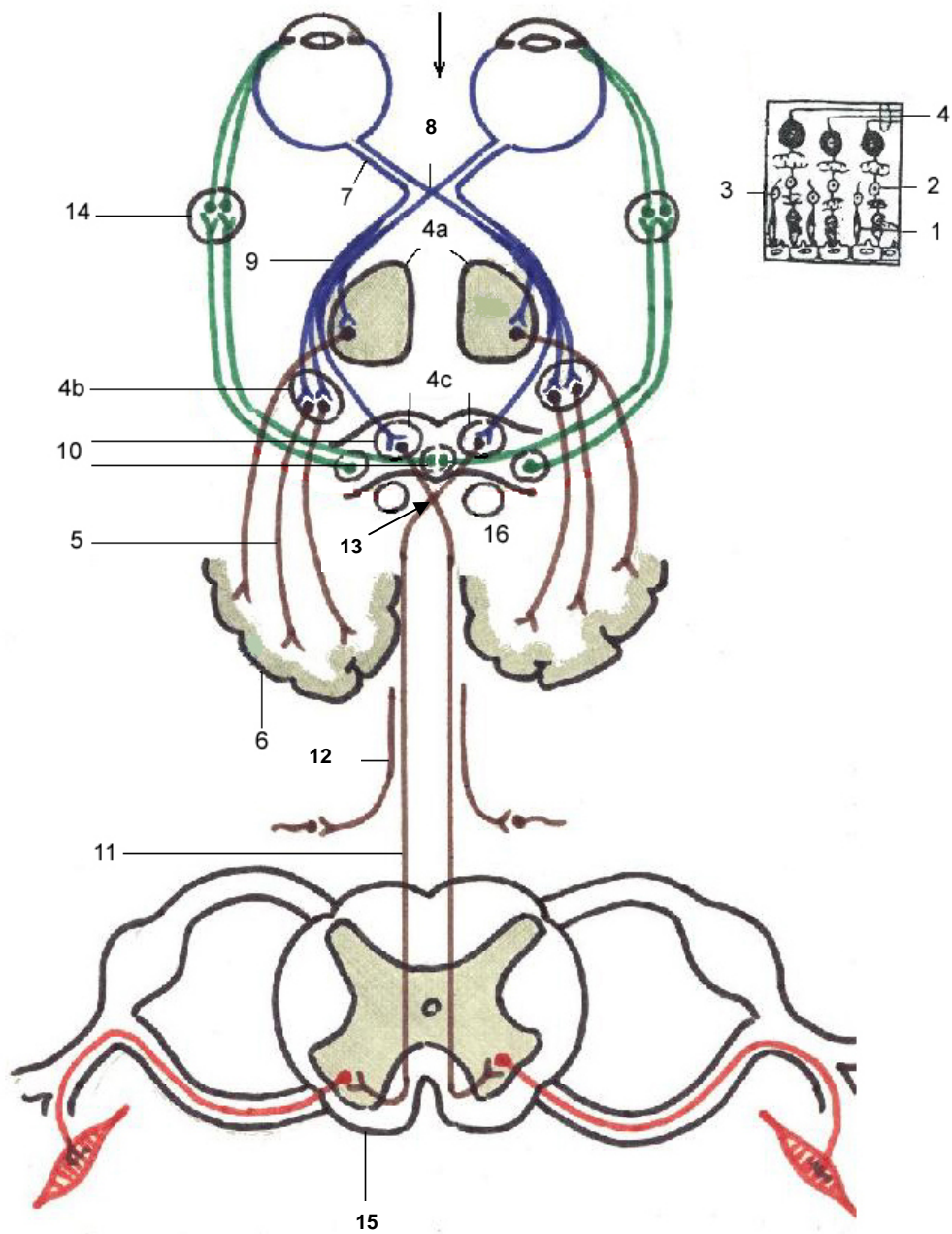


Conducting pathways of the olfactory analyzer



- 1 – neuronum I (cellulae bipolares neurosensoriales);
- 2 – filae olfactoriae;
- 3 – neuronum II (cellulae mitrales bulbi olfactorii);
- 4 – tractus olfactorius;
- 5 – neuronum III (trigonum olfactorium, substantia perforata anterior, septum pellucidum);
- 6 – gyrus parahippocampalis;
- 7 – uncus, corpus amygdaloideum et area subcallosa;
- 8 – nasus externus;
- 9 – corpus callosum;
- 10 – gyrus cinguli;
- 11 – gyrus dentatus;
- 12 – fornix;
- 13 – thalamus.

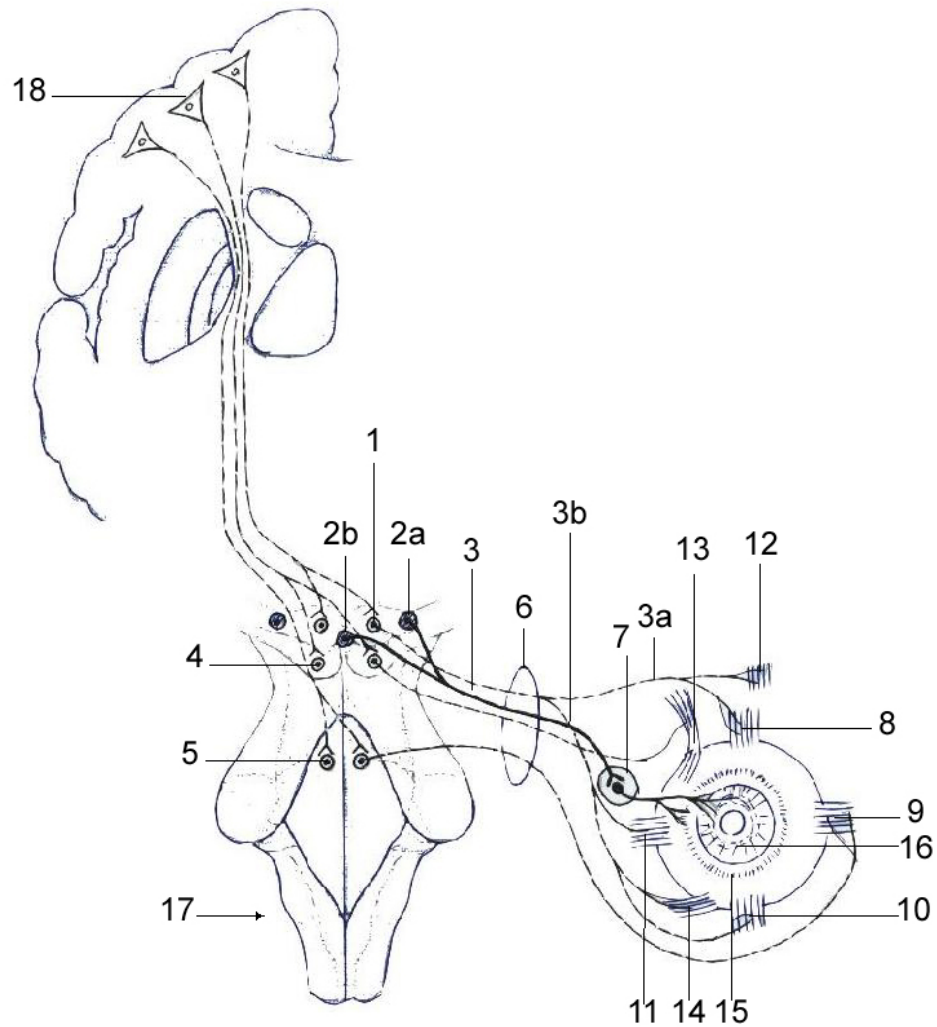
Conducting pathways of the optic analyzer



1 – epitheliocytii (neurosensorii) coniferi et bacilliferi;
2 – neuronum I (neuron bipolare);
3 – neuronum II (neuron ganglionare multipolare);
4 – neuronum III:
4a – pulvinar thalami;
4b – corpus geniculatum laterale;
4c – colliculi superiores;
5 – radiatio optica (Gratiolet);
6 – regio sulci calcarini;
7 – nervus opticus;

8 – chiasma optica;
9 – tractus opticus;
10 – nuclei n. oculomotorii;
11 – tractus tectospinalis;
12 – tractus tectobulbaris;
13 – decussatio dorsalis tegmenti (Meynert);
14 – ganglion ciliare;
15 – medulla spinalis;
16 – colliculi inferiores.

Innervation of the muscles of the eyeball



1 – nucl. n. oculomotorii (III);

2a – n. accessorius (Якубович-Edinger-Westfal);

2b – nucleus impar (Perl) (III);

3 – nervus oculomotorius:

3a – ramus superior;

3b – ramus inferior;

4 – nucl.n. trochlearis (IV);

5 – nucl.n. abducentis(VI);

6 – fissura orbitalis superior;

7 – ganglion ciliare;

8 – m. rectus superior;

9 – m. rectus lateralis;

10 – m. rectus inferior;

11 – m. rectus medialis;

12 – m. levator palpebrae superioris;

13 – m. obliquus superior;

14 – m. obliquus inferior;

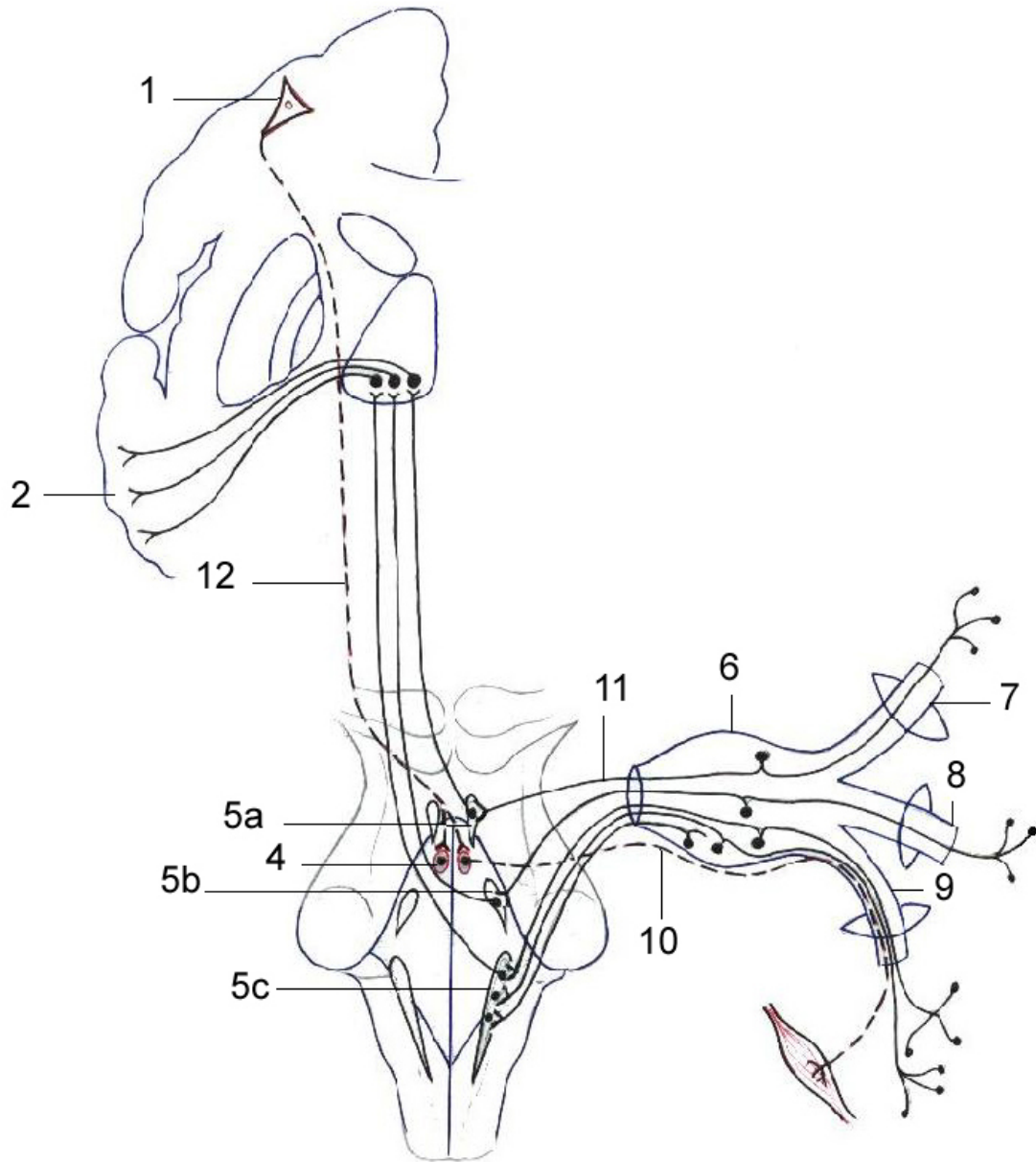
15 – m. ciliaris;

16 – m. sphincter pupillae;

17 – truncus cerebri;

18 – neurocytus pyramidalis magnus (Betz).

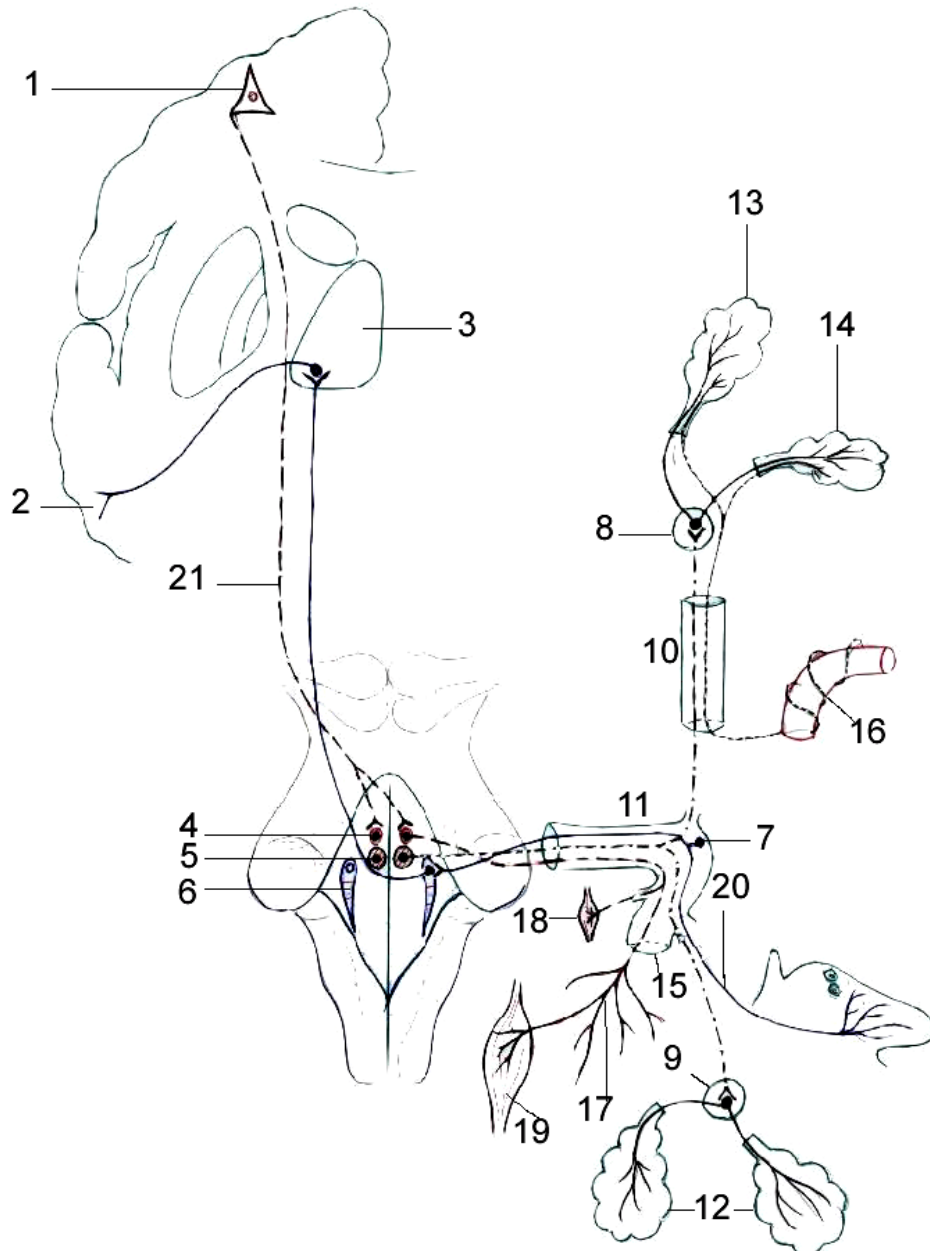
Conducting pathways of the trigeminal nerve (V)



1 – neuronum I (neurocytus pyramidalis magnus, Betz) (gyrus precentralis);
 2 – gyrus postcentralis;
 3 – neuronum III (thalamus opticus);
 4 – nucl. n. trigemini (V);
 5 – nuclei sensoriales n. trigemini (V);
 5a – nucl. mesencephalicus n. trigemini (V);
 5b – nucl. pontinus (V);

5c – nucl. spinalis nervi trigemini (V);
 6 – ganglion trigeminale (Gasser);
 7 – n. ophthalmicus;
 8 – n. maxillaris;
 9 – n. mandibularis;
 10 – radix motoria n. trigemini;
 11 – radix sensoria n. trigemini;
 12 – tractus corticonuclearis.

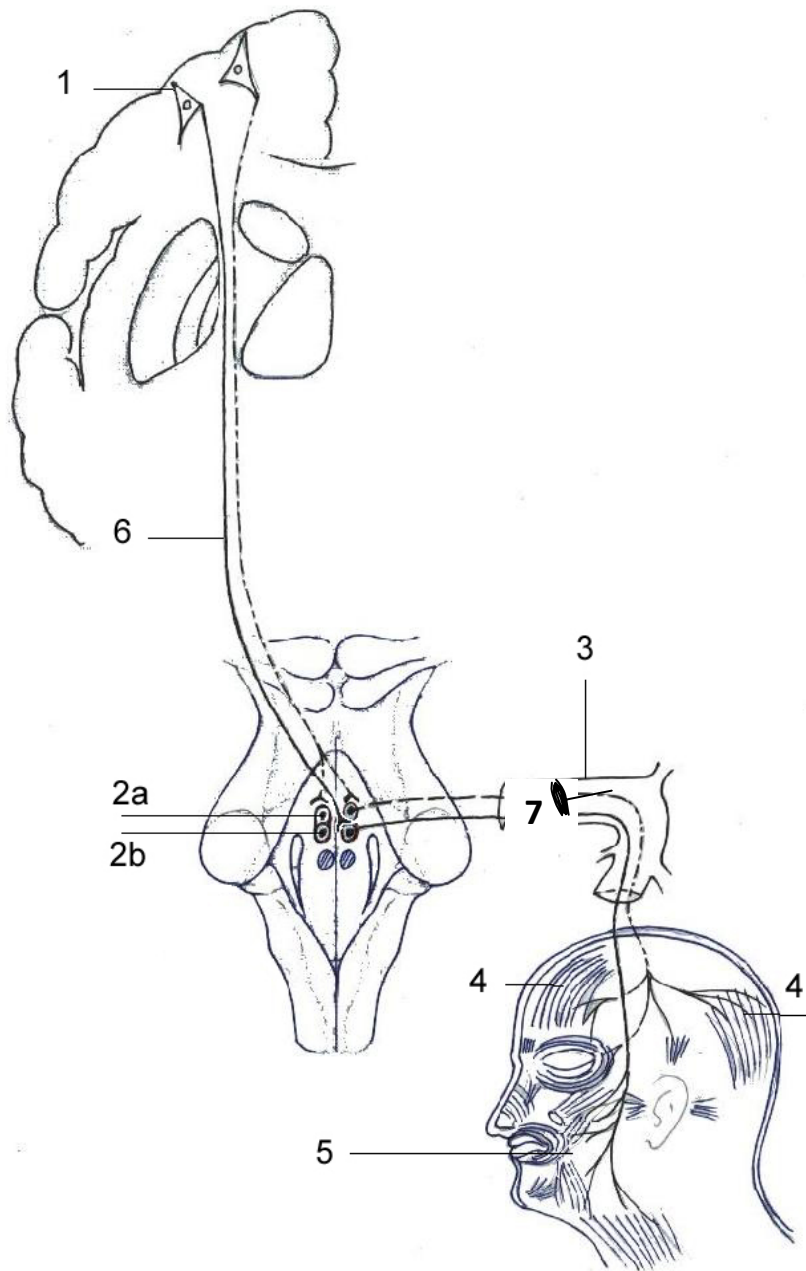
Conducting pathways of the facial nerve (VII)



- 1 – neuronum I (neurocytus pyramidalis magnus, Betz) (gyrus precentralis);
- 2 – girus parahipocampalis et uncus;
- 3 – thalamus opticus;
- 4 – nucl. n. facialis (motorius) (neuronum II) (VII);
- 5 – n. salivatorius superior (VII);
- 6 – n. tractus solitarii (VII);
- 7 – ganglion geniculi;
- 8 – ganglion pterygopalatinum;
- 9 – ganglia submandibularia et sublingualia;
- 10 – canalis pterygoideus;

- 11 – canalis n. facialis (Fallopium);
- 12 – glandulae sublingualis et submandibularis;
- 13 – glandula lacrimalis;
- 14 – glandulae nasales;
- 15 – foramen stylomastoideum;
- 16 – plexus caroticus internus;
- 17 – plexus parotideus;
- 18 – m. stapedius;
- 19 – mm. faciei;
- 20 – chorda tympani;
- 21 – tractus corticonuclearis.

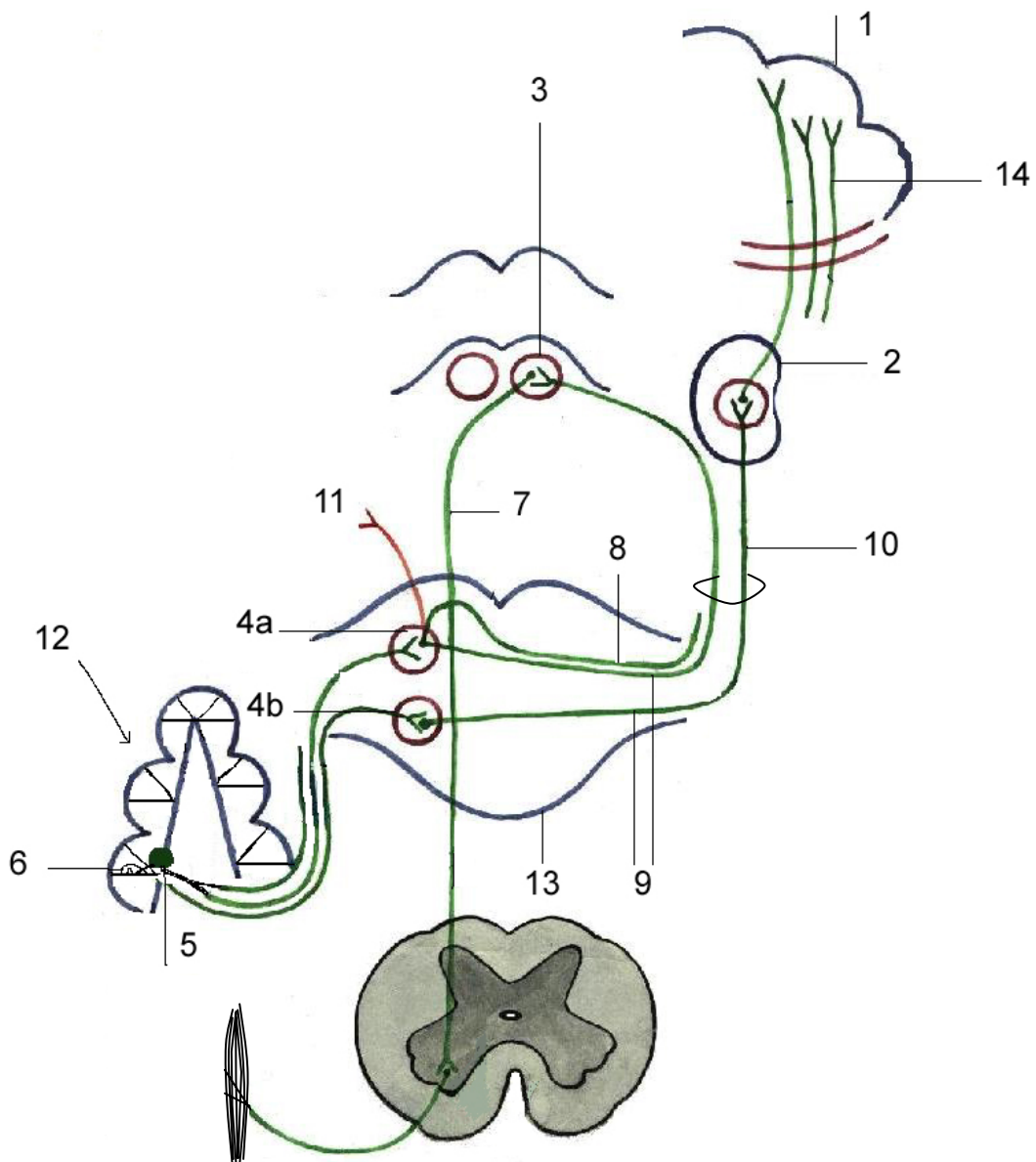
Efferent, motor pathways of the facial nerve (VII)



1 – neuronum I (neurocytus pyramidalis magnus, Betz) (girus precentralis);
 2 – neuronum II (nucl. n. facialis, motorius) (VII);
 2a – pars superior;
 2b – pars inferior;

3 – canalis n. facialis;
 4 – mm. faciei superiores;
 5 – mm. faciei inferiores;
 6 – tractus corticonuclearis;
 7 – m. stapedius.

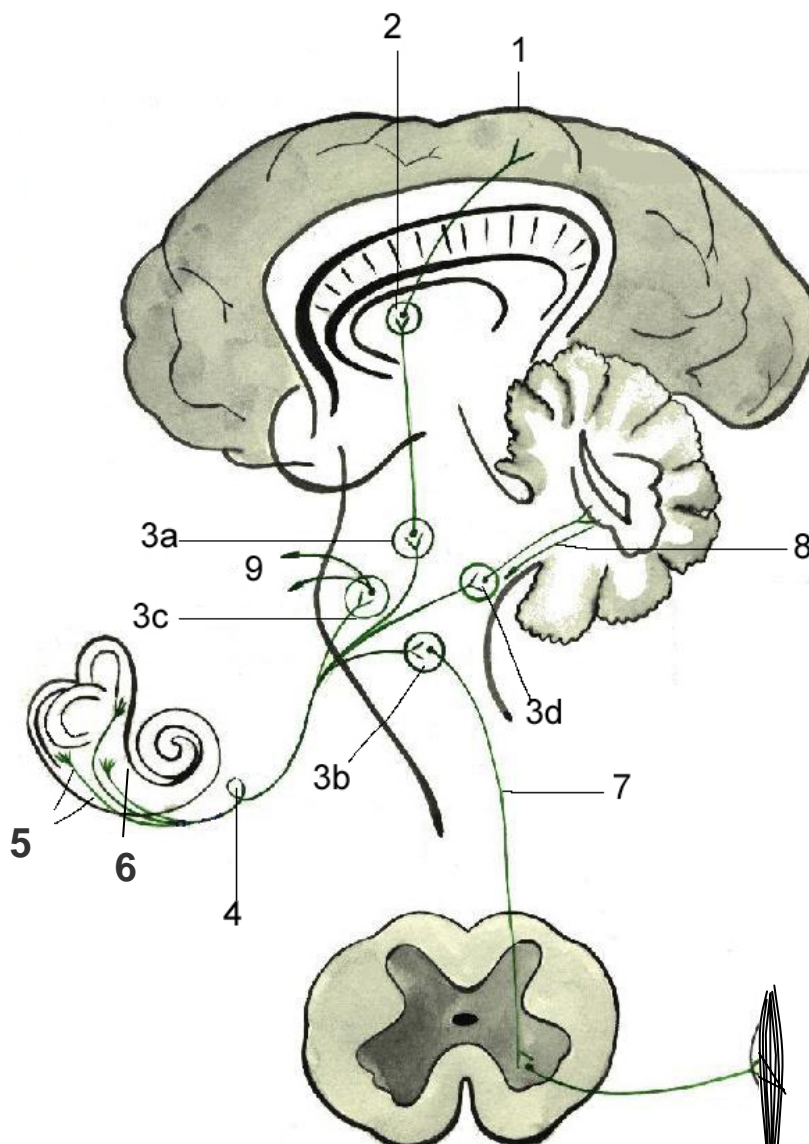
Conducting pathways of the auditory analyzer



- 1 – gyri temporales transversi (Heschl) (gyrus temporalis superior);
- 2 – neuronum III (corpus geniculatum mediale);
- 3 – neuronum III (colliculus inferior tecti mesencephali);
- 4 – neuronum II (nuclei partes cochlearis n. vestibulocochlearis);
- 4a – nucleus dorsalis;
- 4b – nucleus ventralis;
- 5 – neuronum I [ganglion spirale (Corti)];
- 6 – organum Corti (epitheliocytus neurosensorius);
- 7 – tractus tectospinalis;
- 8 – striae medullares;
- 9 – corpus trapezoideum;
- 10 – lemniscus lateralis;
- 11 – conexiones ad nervos III, IV, VI;
- 12 – cochlea (labyrinthus osseus);
- 13 – pons Varolio;

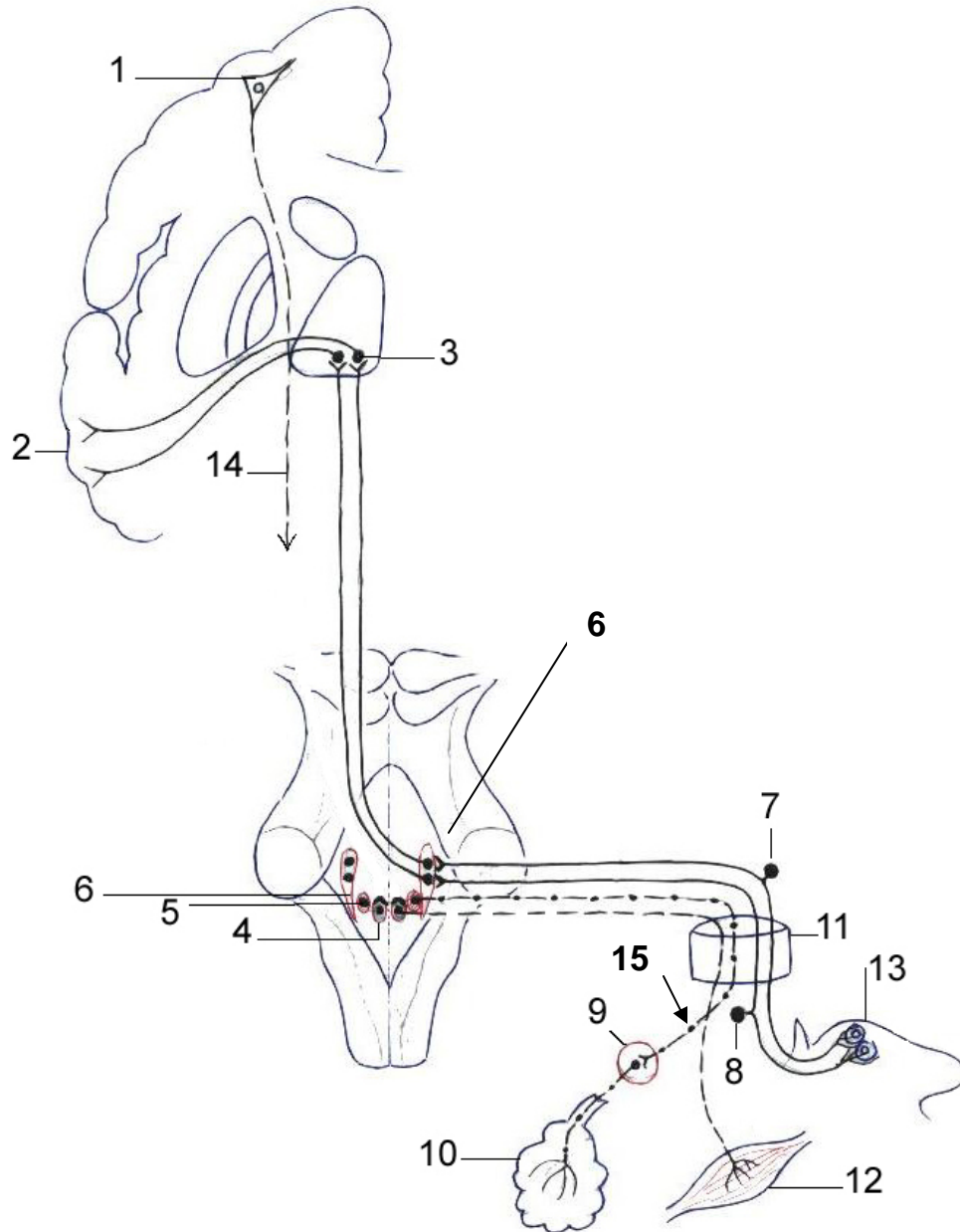
14 – radiatio acustica.

Conducting pathways of the vestibular analyzer



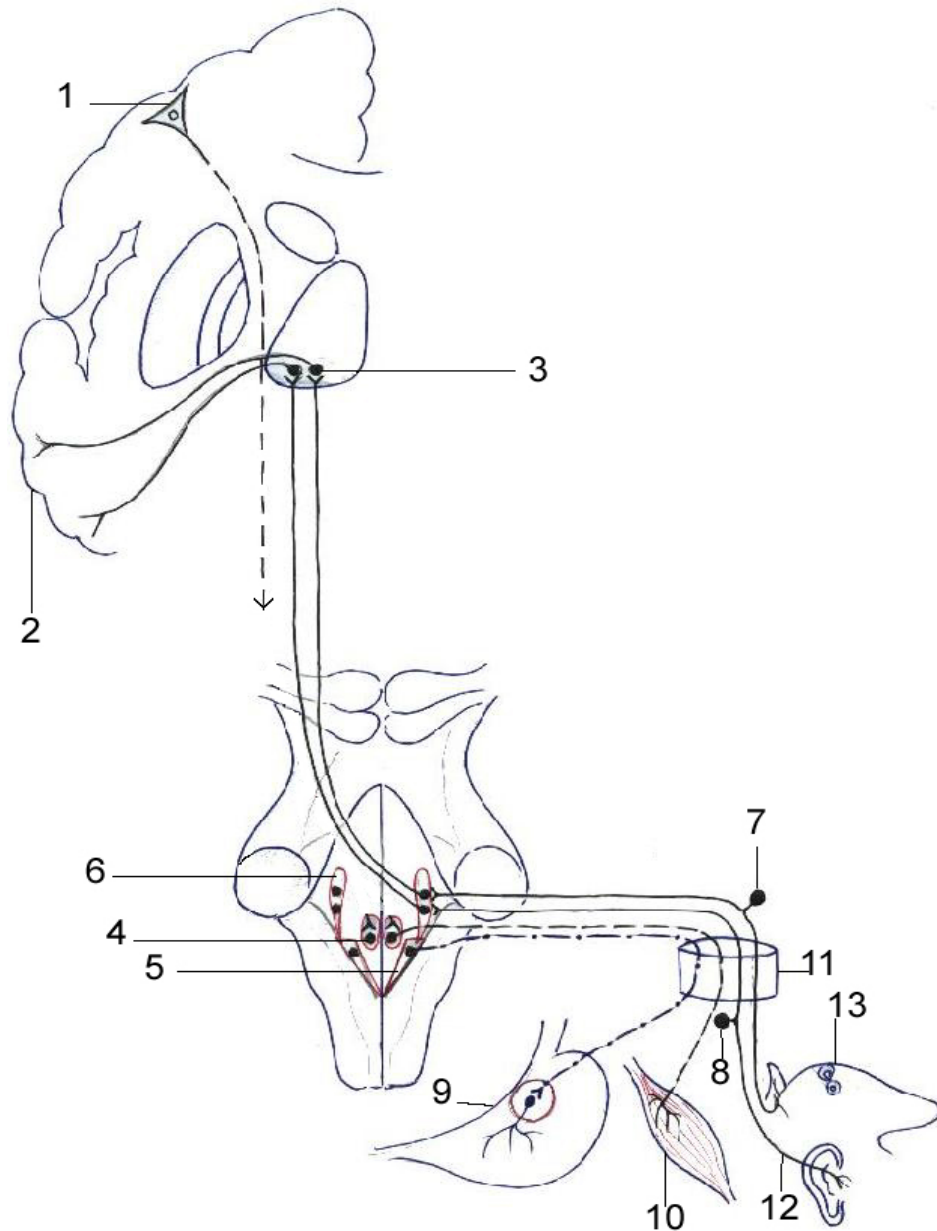
- 1 – lobus temporalis;
- 2 – neuronum III (thalamus opticus);
- 3 – neuronum II (nuclei vestibulares n. vestibulocochlearis):
- a – superior (Бехмепоє);
- b – inferior (Roller);
- c – lateralis (Deiters);
- d – medialis (Schwalbe);
- 4 – ganglion vestibulare (Scarpa) (neuronum I);
- 5 – cristae ampullares ductuum semicircularium;
- 6 – macula utriculi et macula sacculi;
- 7 – tractus vestibulospinalis (Levental);
- 8 – tractus vestibulocerebellaris et tractus cerebellovestibularis;
- 9 – conexiones ad nervos craniales IX, X et III, IV, VI.

Conducting pathways of the glossopharyngeal nerve (IX)



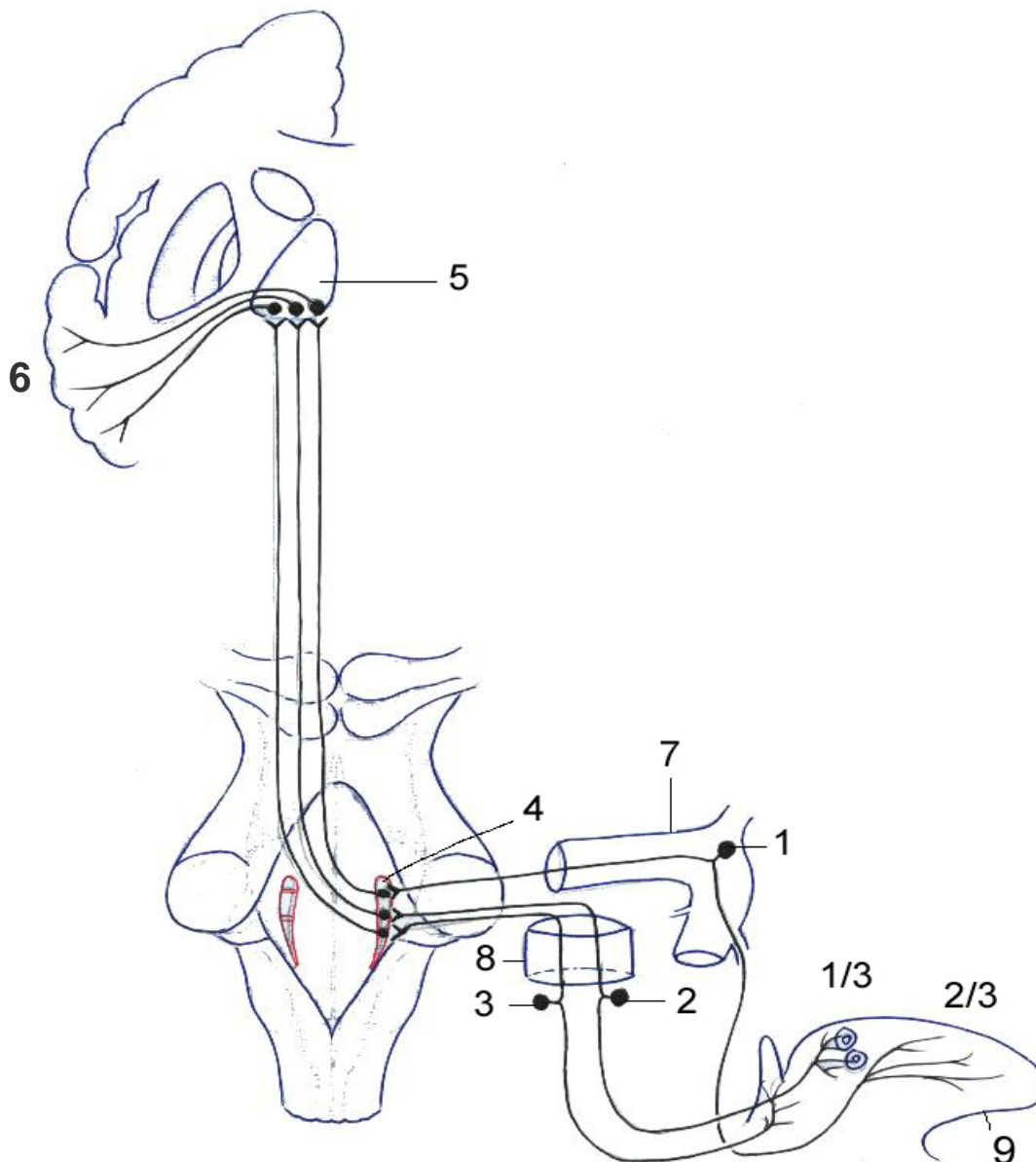
- 1 – neuronum I (motorium) (gyrus precentralis, neurocytus pyramidalis magnus, Betz);
- 2 – uncus et gyrus postcentralis;
- 3 – neuronum III (thalamus opticus);
- 4 – neuronum II (motorium) (nucleus ambiguus);
- 5 – nucleus salivatorius inferior (neuronum I);
- 6 – neuronum II (sensitivum) (nucleus tractus solitarii);
- 7 – neuronum I (sensitivum) (ganglion superius);
- 8 – neuronum I (sensitivum) (ganglion inferius, nodosum);
- 9 – ganglion oticum (neuronum II);
- 10 – glandula parotis;
- 11 – foramen jugulare;
- 12 – ramus musculi stylopharyngei;
- 13 – 1/3 posterior linguae (papillae valatae);
- 14 – tractus corticonuclearis;
- 15 – nervus tympanicus.

Conducting pathways of the vagus nerve (X)



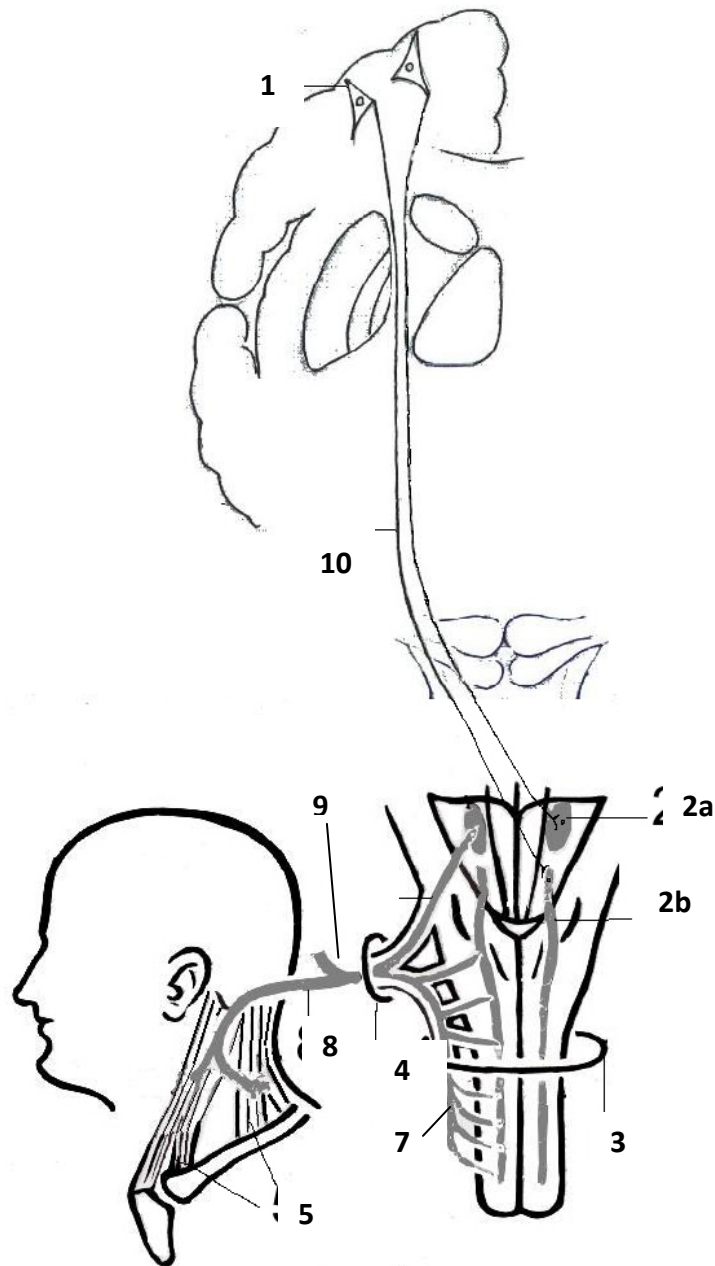
- 1 – neuronum I (motorium) (gyrus precentralis, neurocytus pyramidalis magnus, Betz);**
- 2 – uncus et gyrus postcentralis;**
- 3 – neuronum III (sensitivum) (thalamus opticus);**
- 4 – neuronum II (motorium) (nucleus ambiguus);**
- 5 – nucleus dorsalis nervi vagi (neuronum I);**
- 6 – neuronum II (sensitivum) (nucleus tractus solitarii);**
- 7 – neuronum I (sensitivum) (ganglion superius, jugulare);**
- 8 – neuronum I (sensitivum) (ganglion inferius, nodosum);**
- 9 – ganglia intravisceralia et paravisceralia (neuronum II);**
- 10 – mm. pharyngis, laryngis, palati mollis etc.;**
- 11 – foramen jugulare;**
- 12 – nervus auricularis posterior;**
- 13 – radix linguae.**

Conducting pathways of the taste analyzer



- 1 – neuronum I (ganglion geniculi, VII);
- 2 – neuronum I (ganglion inferius, IX);
- 3 – neuronum I (ganglion inferius, X);
- 4 – neuronum II [nucleus tractus solitarii (VII, IX, X)];
- 5 – neuronum III (thalamus opticus);
- 6 – gyrus parahippocampalis et uncus;
- 7 – canalis nervi facialis (Fallopis);
- 8 – foramen jugulare;
- 9 – lingua.

Conducting pathways of the accessory nerve (XI)



1 – neuronum I (*gyrus precentralis, neurocytus pyramidalis magnus, Betz*);

2 – neuronum II [*nuclei motorii n. accessorii*;

a – *nucleus ambiguus (IX, X, XI)*;

b – *nucleus spinalis (XI)*;

3 – *foramen occipitale magnum*;

4 – *foramen jugulare*;

5 – *mm. sternocleidomastoideus et trapezius*;

6 – *radices craniales nervi accessorii*;

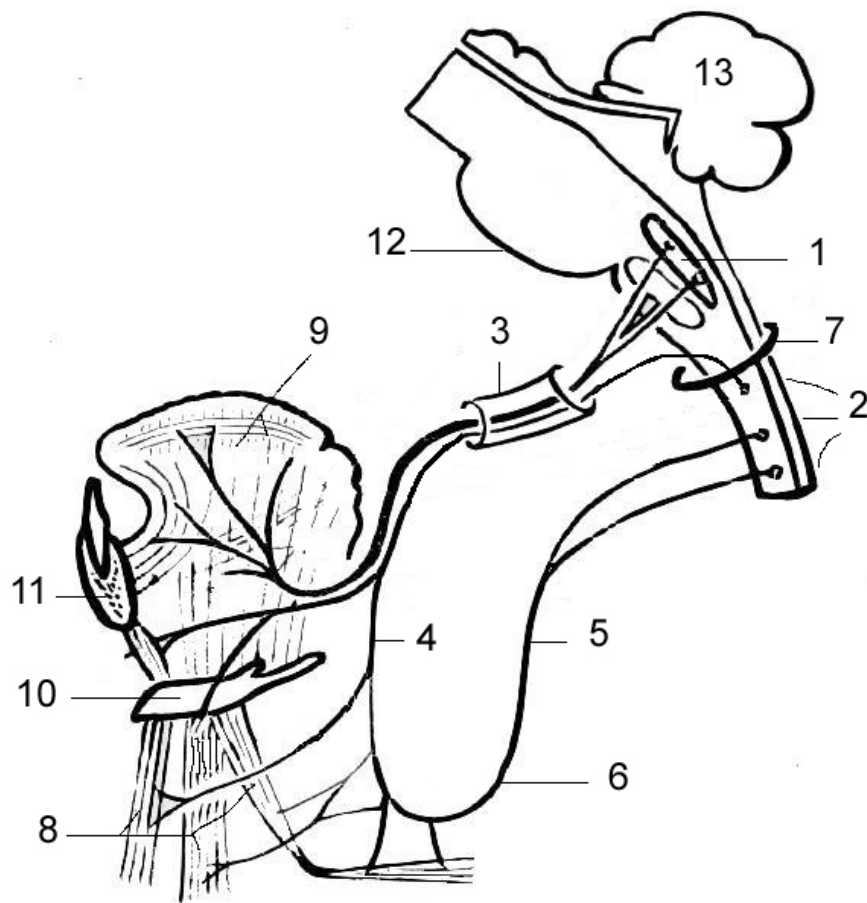
7 – *radices spinales nervi accessorii*;

8 – *ramus externus*;

9 – *ramus internus*;

10 – *tractus corticonuclearis*.

Conducting pathways of the hypoglossal nerve (XII)



- 1 – nucleus nervi hypoglossi;
- 2 – medulla spinalis (segmenti C₁, C₂, C₃);
- 3 – canalis hypoglossus;
- 4 – radix superior ansae cervicalis;
- 5 – radix inferior ansae cervicalis;
- 6 – ansa cervicalis;
- 7 – foramen magnum;
- 8 – mm. infrahyoidei;
- 9 – rami linguales (musculi linguae);
- 10 – os hyoideum;
- 11 – mandibula;
- 12 – truncus cerebri;
- 13 – cerebellum.