



Functional anatomy of the genital (reproductive) systems

Human Anatomy Department

Dr. Anastasia Bendelic

Plan:

- Development of the male and female genitalia
- Abnormalities of the male and female genitalia
- Male genital system (or male genitalia) – structural peculiarities, functions
- Female genital system (or female genitalia) – structural peculiarities, functions

According to TA (1998)

The genital systems include:

- ***female genital system*** (or female genitalia);
- ***male genital system*** (or male genitalia).

Development of the male and female genitalia

It includes two stages:

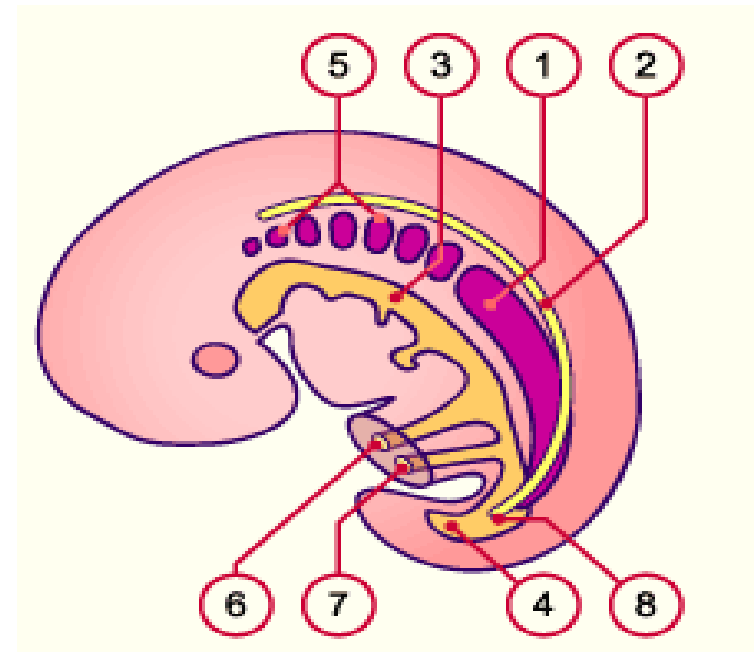
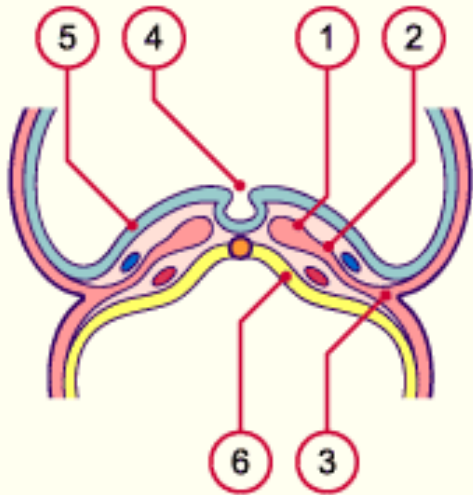
1. ***Indifferent stage*** (up to the 6th week of the embryogenesis);
2. ***Stage of sexual differentiation*** (starts at the 7th – 8th weeks of embryonic life).

Development of the male and female genitalia

The internal genitalia develop from the ***intermediate mesoderm*** and *urogenital sinus* (endoderm).

The external genitalia develop from the caudal eminence of ***ectoderm***.

The germ layers (ectoderm, mesoderm, endoderm)

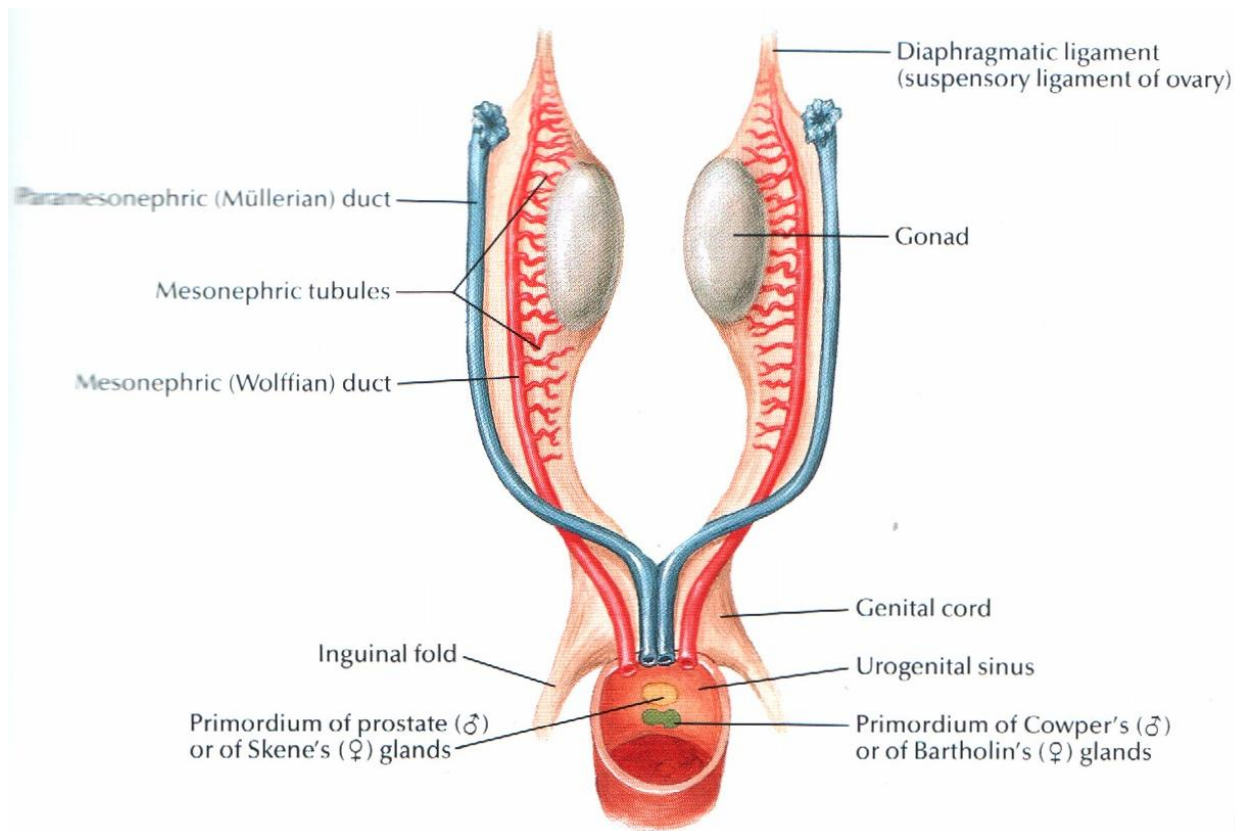


Development of the internal genitalia: indifferent stage

During the indifferent stage the following structures develop from intermediate mesoderm:

- ***indifferent gonads***;
- ***mesonephric (or Wolffian) ducts***;
- ***paramesonephric (or Müllerian) ducts***;
- and ***urogenital sinus*** (from endoderm).

Development of the internal genitalia: indifferent stage



Gonads: indifferent stage

The gonads arise from two very different kinds of cells that originate in embryo:

- The ***primordial germ cells*** will form the ***gametes*** (spermatozoa and oocytes). These cells come from ***ectoderm***.
- The ***somatic cells*** which surround the primordial germ cells and form the somatic gonadal blastema. These cells come from ***mesoderm***.

Gonads: stage of differentiation

Up to the 6th week male and female gonads cannot be distinguished.

The **testes** differentiate themselves earlier than the ovaries namely in the course of the **7th week** (44 days).

Responsible for this is the ***SRY gene*** of the ***Y chromosome***, that induces the development of the testes through the activation of a series of further genes (*sex-determining genetic factors and hormones*).

Gonads: stage of differentiation

The differentiation of the **ovaries** happens later than that of the testes, taking place during the **8th week**.

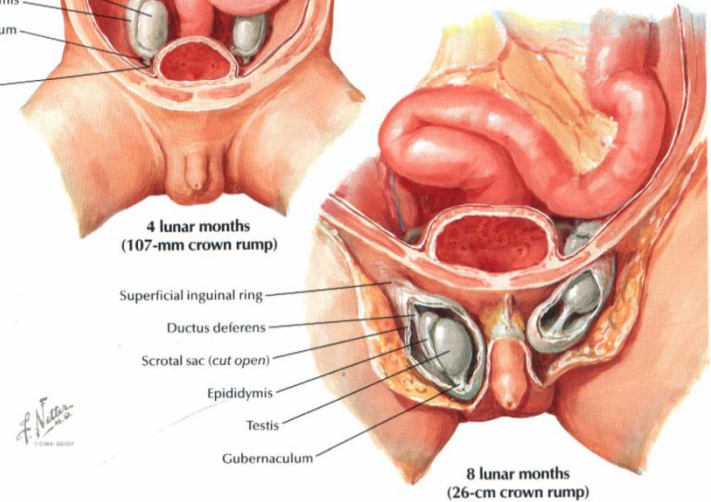
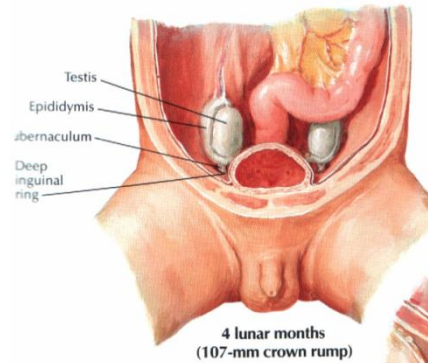
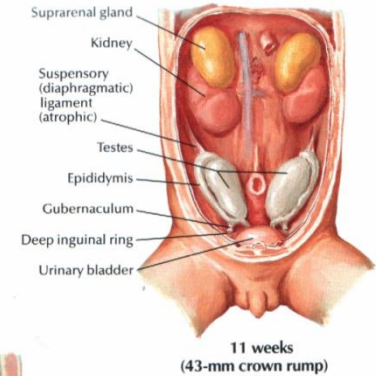
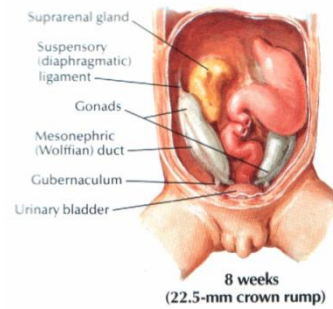
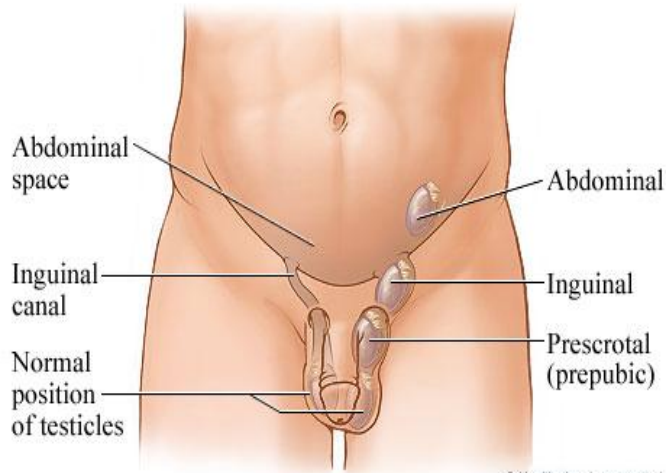
Since females lack the Y chromosome, they have no SRY gene.

Descent of the testes

Between the 3rd month of pregnancy and its end the testes become transferred from the lumbar area into the future scrotum.

This transfer is due to a combination of **growth processes** and **hormonal influences**. The **gubernaculum testis** also plays a decisive role in this phenomenon.

Descent of the testes



Descent of the testes

The region, where the testes pass through the abdominal wall, is called the ***inguinal canal***.

Between the 7th and 12th weeks the ***gubernaculum*** ***shortens*** and pulls the testes downwards.

Between the 3rd and 7th months the ***testes*** stay in the area of the inguinal canals so they can enter into them.

They reach the scrotum at roughly the time of the birth under the influence of the ***androgen hormone***.

Displacement of the ovaries

The ovaries are also moved slightly from their location in the middle of the abdomen to the pelvis.

The influence of the ***gubernaculum*** in this process is not entirely clear.

Genital ducts and urogenital sinus: stage of differentiation

In males:

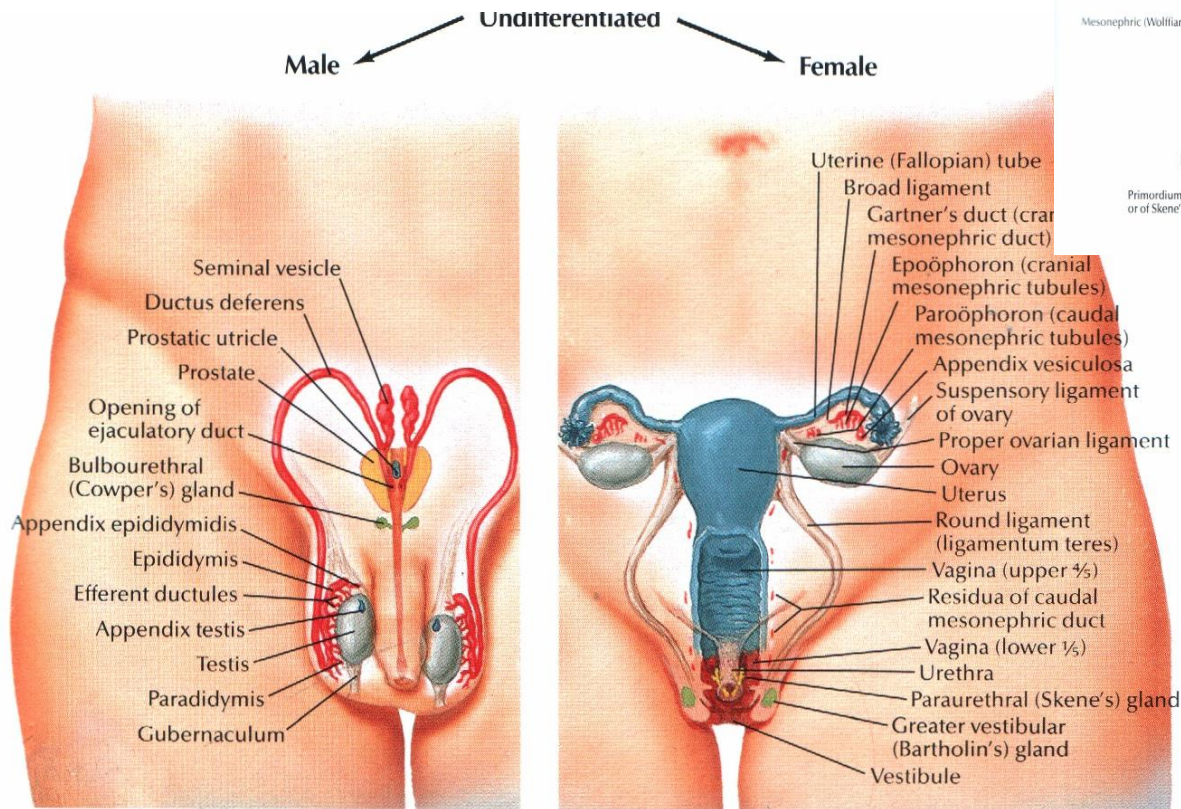
- The *mesonephric duct (of Wolff)* gives rise to the ***epididymis, ductus deferens, seminal vesicles, ejaculatory duct.***
- The *paramesonephric duct (of Müller)* atrophies due the effect of the *antimullerian hormone*.
- The *urogenital sinus* gives rise to the ***prostate*** and ***bulbourethral glands*** (Cowper`s).

Genital ducts and urogenital sinus: stage of differentiation

In females:

- The *mesonephric duct (of Wolff)* atrophies.
- The *paramesonephric duct (of Müller)* gives rise to the ***uterine tubes, uterus, vagina*** (upper part).
- The *urogenital sinus* gives rise to the ***vagina*** (lower part), ***vestibule of vagina*** and ***vestibular glands***.

Genital ducts and urogenital sinus: stage of differentiation

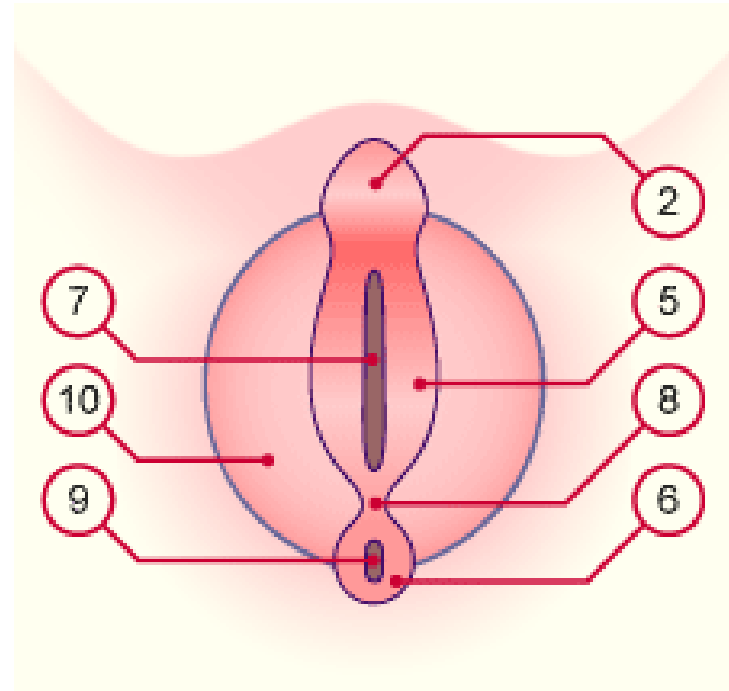
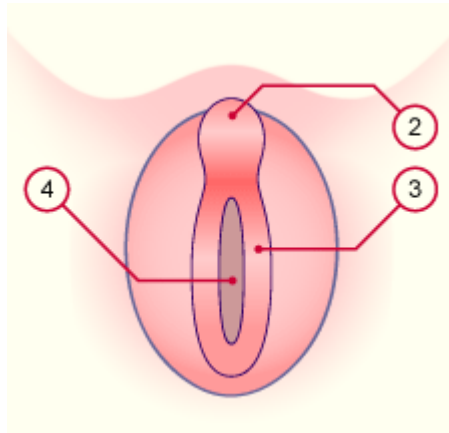


The external genitalia: indifferent stage

From the caudal eminence of the **ectoderm** develop the following structures:

- **genital tubercle;**
- **genital (or urogenital) folds;**
- **genital (or labioscrotal) swellings.**

The external genitalia: indifferent stage



The external genitalia: stage of differentiation

Under the effects of **androgen** in males:

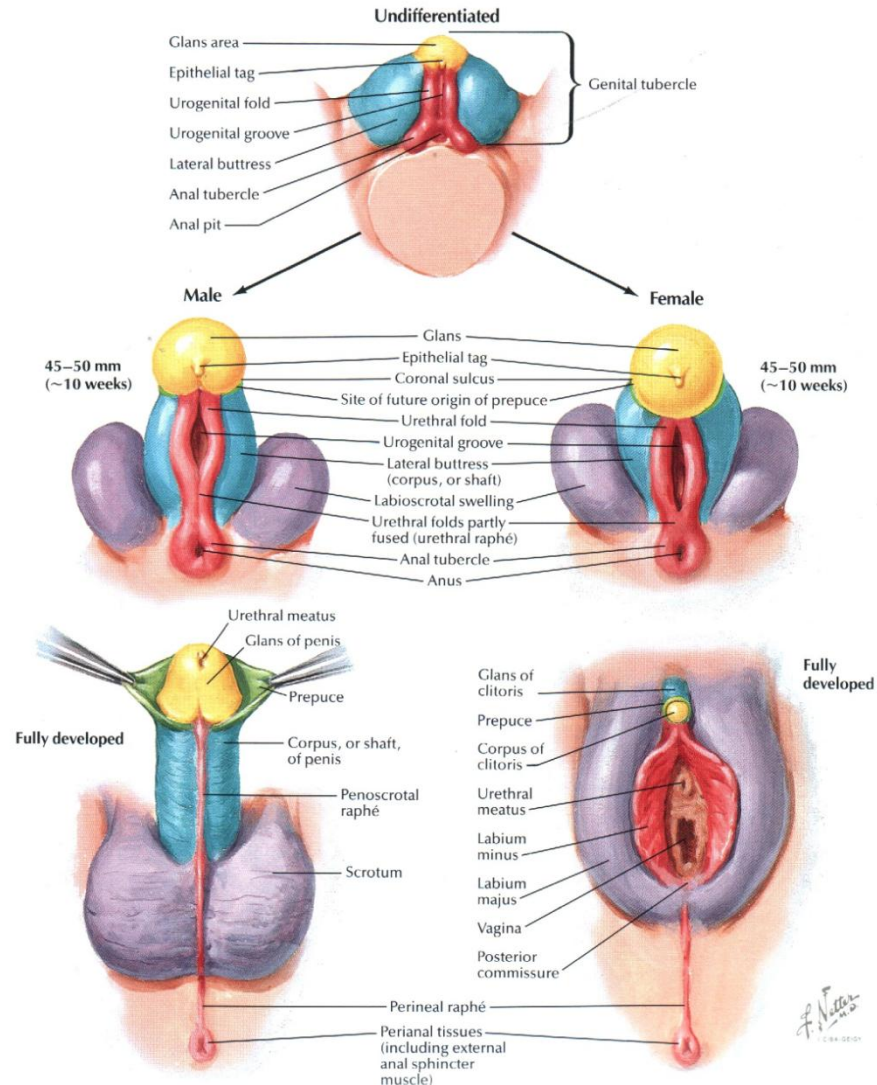
- the *genital tubercle* becomes longer and forms the **penis** (corpora cavernosa);
- from the fused *genital* (or urogenital) *folds* the penile **spongy body** (corpus spongiosus) arises in the penis;
- the two *genital swellings* also fuse in the middle and form the **scrotum**.

The external genitalia: stage of differentiation

In females:

- the *genital tubercle* form the **clitoris**;
- the *urogenital folds* do not fuse and give rise to the **labia minora**;
- the *genital swellings* also do not fuse and give rise to the **labia majora**.

The external genitalia: stage of differentiation



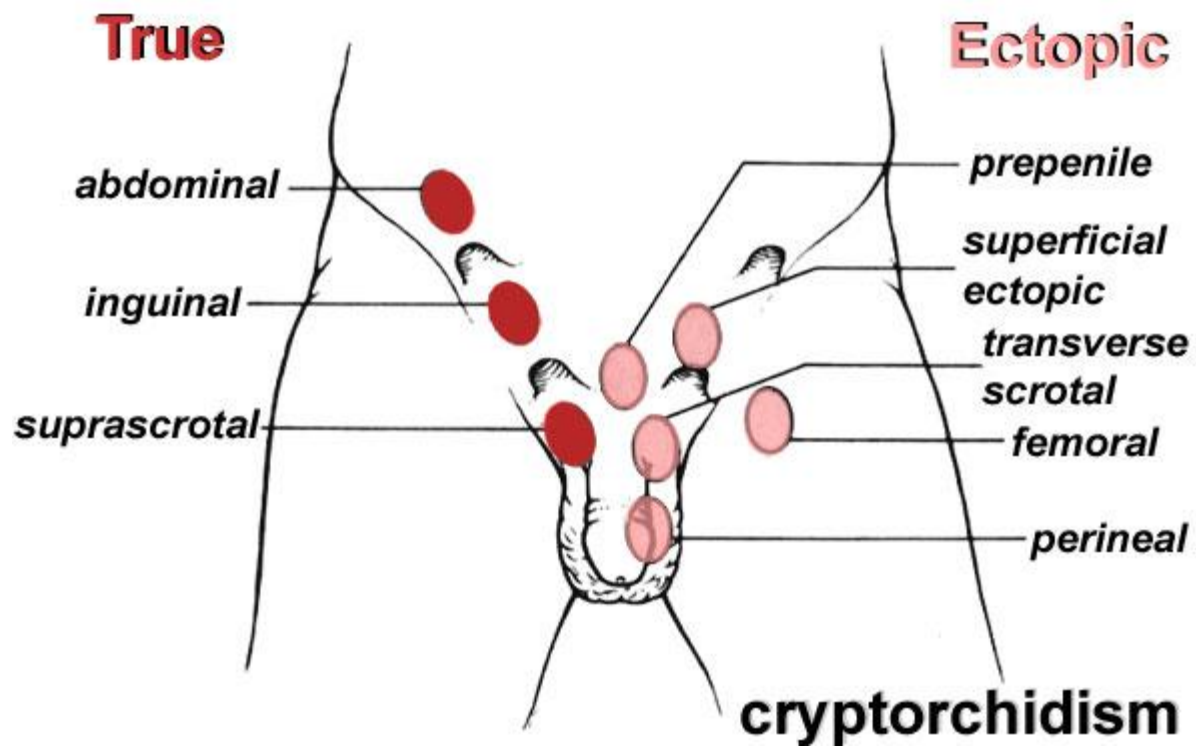
Abnormalities of the male and female genitalia

- ***True hermaphroditism*** – an individual possesses both testicular and ovarian tissues simultaneously as ***ovotestis***.
- ***Pseudohermaphroditism*** – an individual possesses male or female gonads with ambiguous external genitalia.

Abnormalities of the male and female genitalia

- **Aphallia** – agenesis (absence) of penis or clitoris (L. *phallus* - penis or clitoris).
- **Micropenis** – unusual small penis.
- **Bifid penis or clitoris** or **diphallia** – two genital tubercles have been developed.
- **Cryptorchidism** (*cryptos* - hidden, *orchis* - testis) – the testes remain in the abdominal cavity or somewhere on their way to the scrotum – most frequently in the inguinal canal (60% of the cases).
- **Ectopia of testicles** – the testes take on an abnormal location due the deviant migration.

Cryptorchidism and ectopia of testis



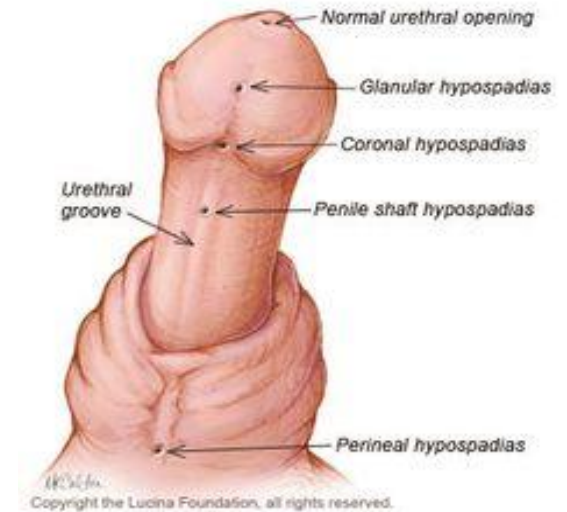
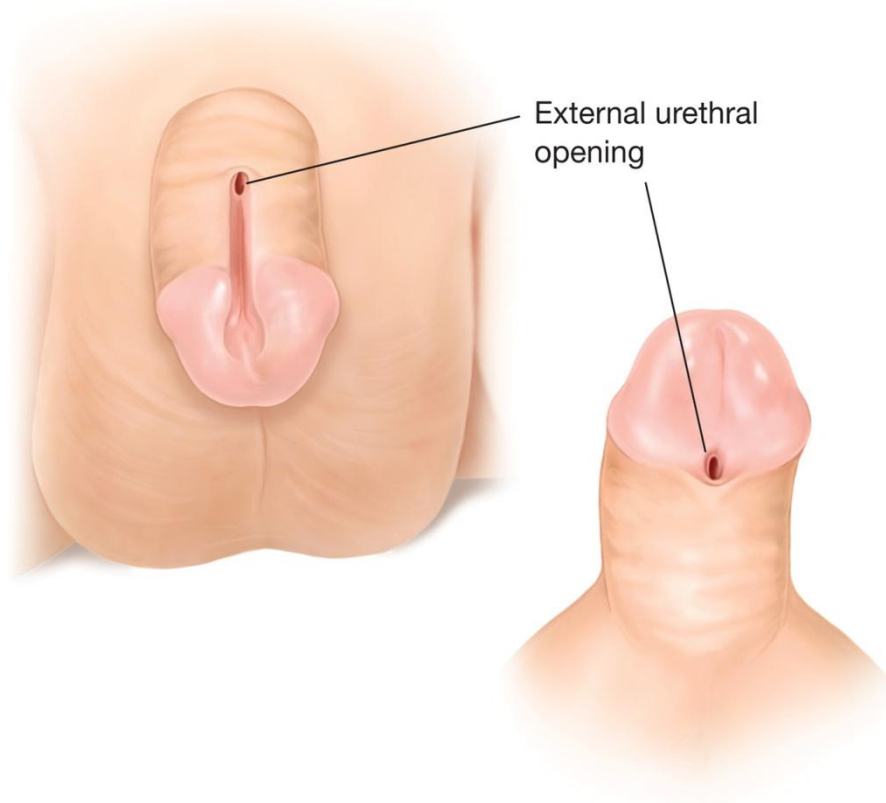
Cryptorchidism

- The first treatment step consists in giving **gonadotropic hormones** with a success rate of 20 - 30%.
- If this remain unsuccessful the treatment consists of in a surgical intervention (**orchidopexy**). Here the testis is surgically brought down into the scrotum.

Abnormalities of the male and female genitalia

- **Testicular torsion** is connected with a congenital anomaly of the testicular fixation in the scrotum.
- **Anorchism (anorchidism, anorchia)** – congenital absence of testicles.
- **Monorchism (monorchidism)** – the condition of having one testis into the scrotum.
- **Polyorchism (polyorchidism)** – presence of one or more supernumerary testes.
- **Hypospadias** – the urinary meatus is located on the inferior side of the penis.
- **Epispadias** – the urinary meatus is situated on the superior side of the penis.

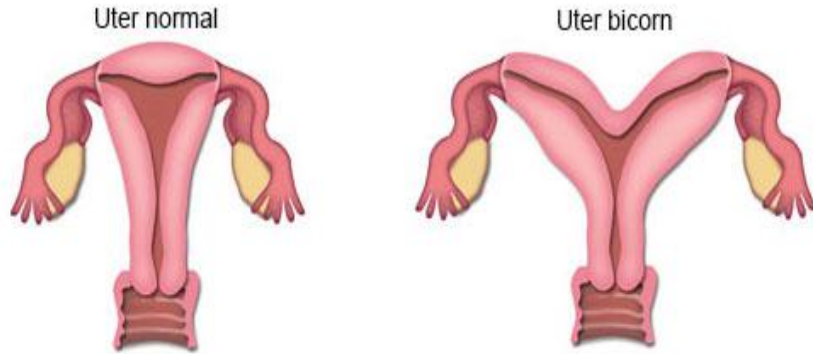
Epispadias and hypospadias



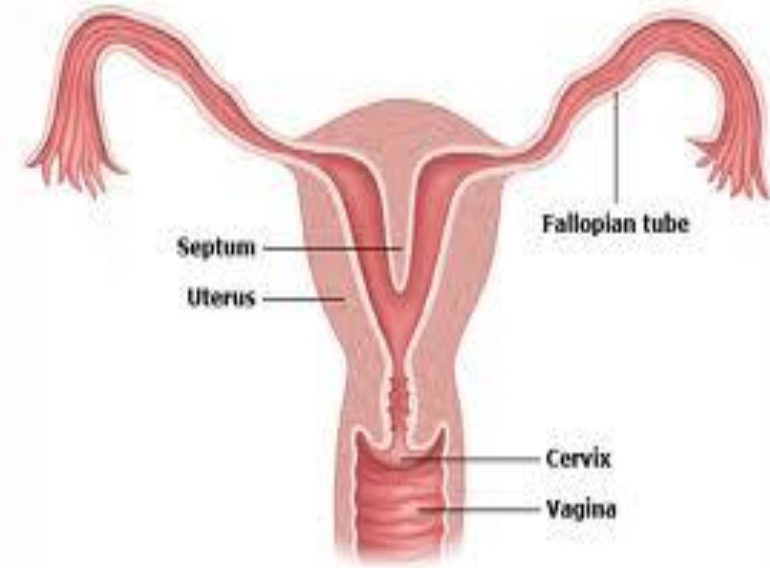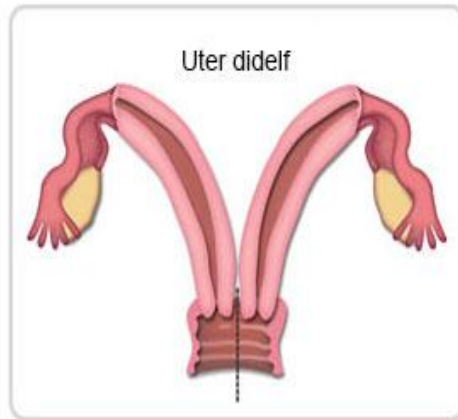
Abnormalities of the male and female genitalia

- **Supernumerary ovary** – an accessory (the third) ovary.
- **Uterus didelphys** – double uterus (fusion of the Mullerian ducts fails to occur).
- **Uterus bicornis** – a uterus that is more or less divided into two lateral horns as a result of imperfect union of the paramesonephric ducts.
- **Uterus septus** – septate uterus (absent of resorption of the medial wall of two paramesonephric ducts).
- **Absent perforation of the hymen** – can leads to the hematometrocolpos in adolescence.

Uterus didelphys, uterus bicornis, uterus septus



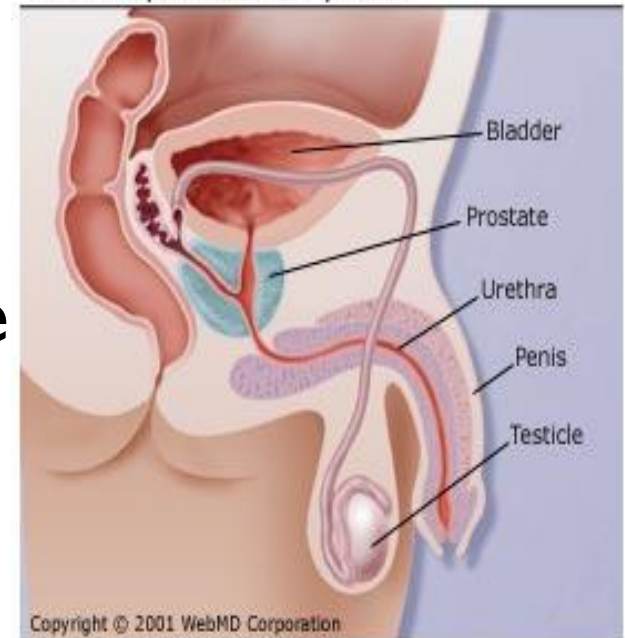
Defectele de duct Mullerian



Male genital system

- **Male internal genitalia:**
 1. *male gonads (testes or testicles);*
 2. *spermatic ways (pathway of sperm);*
 3. *accessory glands (prostate seminal vesicles, bulbourethral glands).*
- **Male external genitalia:**
 1. *penis;*
 2. *scrotum.*

Male Reproductive System

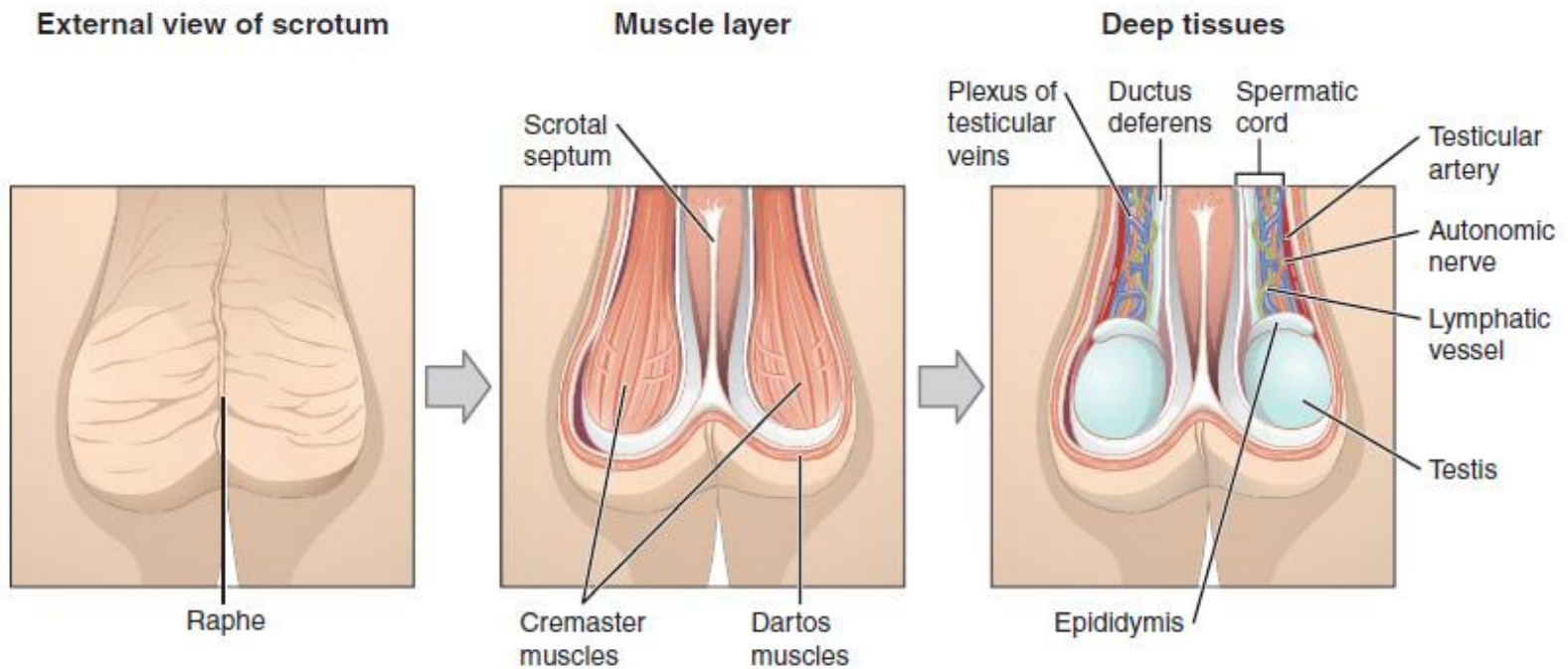


The male gonads (testes or testicles)

The testes are located in the scrotum. The **scrotum** regulates the temperature of the testes and maintains it at **35⁰ C** (two degree below the body temperature). Higher temperatures affect spermatogenesis.

Temperature control is accomplished by the smooth muscles of scrotum (**cremaster** and **dartos muscles**) moving the testes closer to or further away from the abdomen dependent on the ambient temperature.

The male gonads (testes or testicles)



The male gonads (testes or testicles)

The testes perform two functions:

- ***produce sperm cells*** (spermatogenesis);
- ***produce androgens*** (primarily testosterone).

The testis (pl. *testes*) is ovoid in shape and has:

- two ***surfaces: medial*** and ***lateral***;
- two ***borders: anterior*** and ***posterior***;
- two ***ends*** (poles or extremities): ***superior*** and ***inferior***.

The male gonads (testes or testicles)

The testis (L. *testis*, *didymis*, *orchis*) is covered by three tunics:

- ***tunica vaginalis testis*** consists of two layers, the visceral layer covers the testis;
- ***tunica albuginea*** is the middle tunic, it also forms the mediastinum of testis;
- ***tunica vasculosa*** is the inner tunic and it consists of blood vessels and connective tissue.

The male gonads (testes or testicles) – internal structure

From the mediastinum of testis a series of ***fibrous septa*** extend towards the tunica albuginea.

These septa divide the testis into the ***lobules*** (250 - 300 lobules).

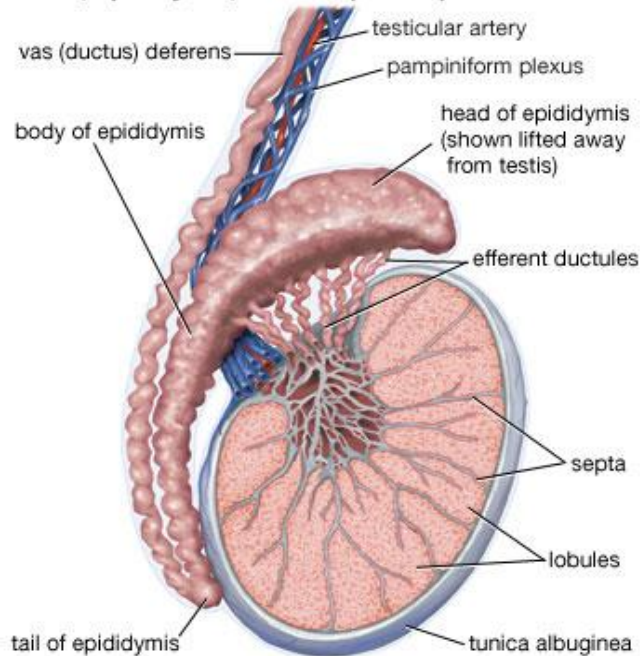
Within each lobule there are 1 - 4 ***convoluted seminiferous tubules***, which continuous with ***straight seminiferous tubules***.

These tubules open into a network called ***rete testis*** (in mediastinum of testis).

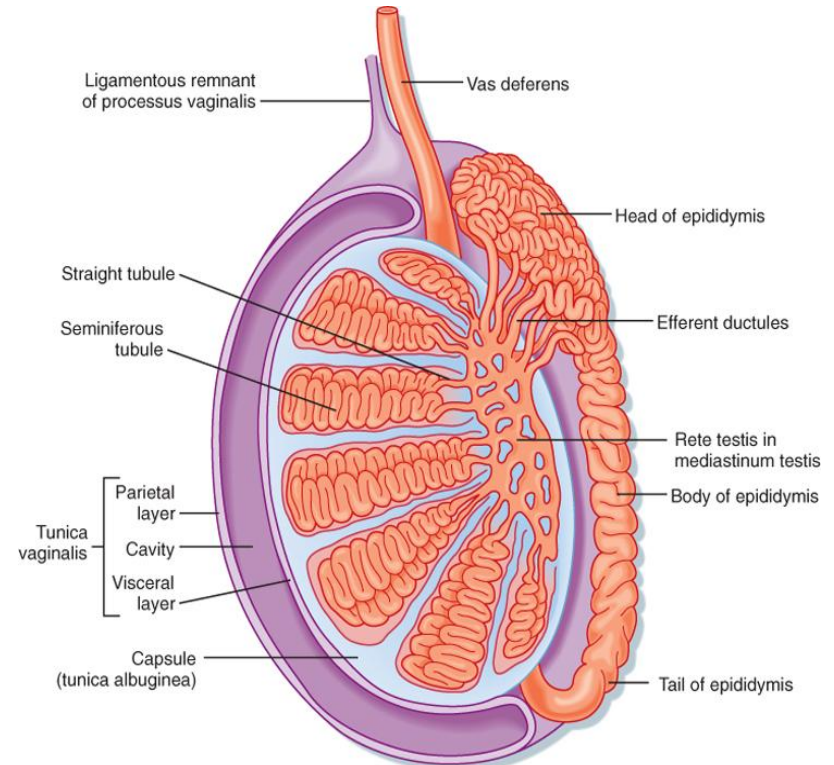
Small ***efferent ductules*** connect the *rete testis* with head of epididymis.

The male gonads (testes or testicles) – internal structure

Testis, epididymis, and vas (ductus) deferens



© 2008 Encyclopædia Britannica, Inc.



Koeppen & Stanton: Berne and Levy Physiology, 6th Edition.
Copyright © 2008 by Mosby, an imprint of Elsevier, Inc. All rights reserved.

The epididymis

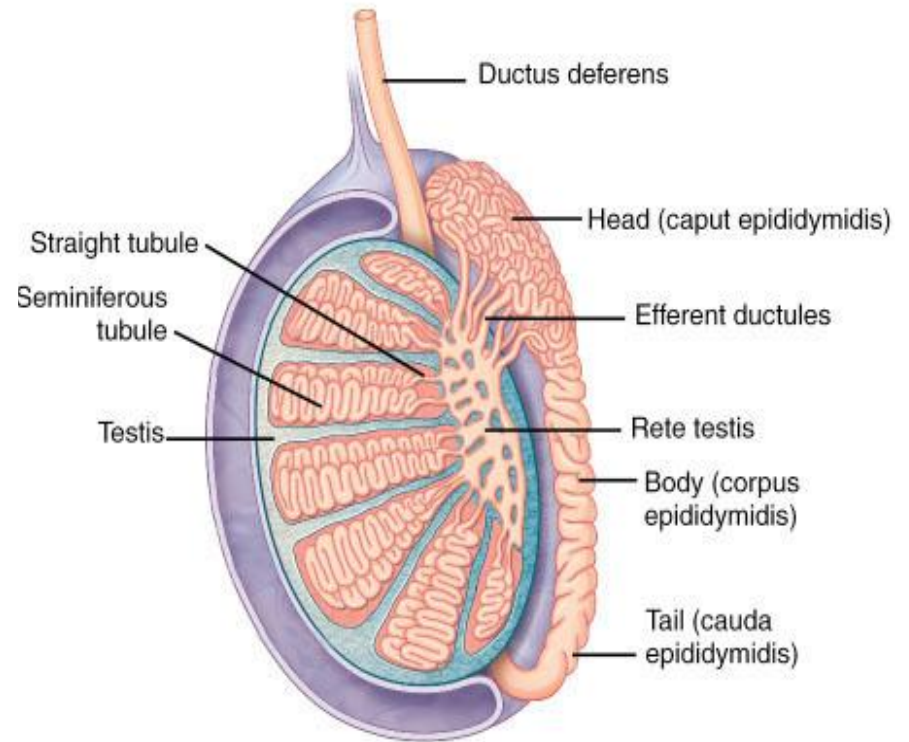
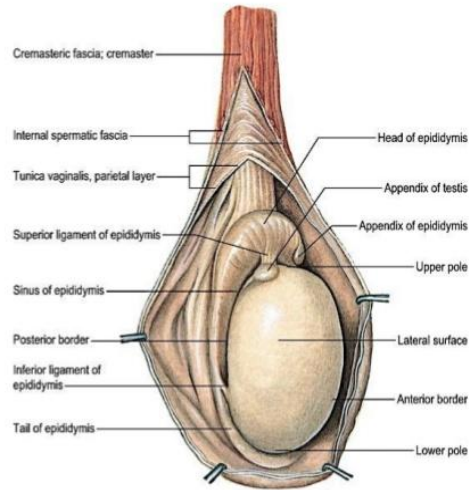
Epididymis, an elongated structure connected to the posterior border of testis, consisting of:

- **head** (L. *caput*) (receives the spermatozoa via the efferent ductules);
- **body** (L. *corpus*);
- **tail** (L. *cauda*).

The body and tail contain a very convoluted duct – **duct of epididymis** (*ductus epididymis*), which continuous with ductus deferens.

The epididymis transports, stores and matures the spermatozoa between testes and ductus deferens.

The epididymis



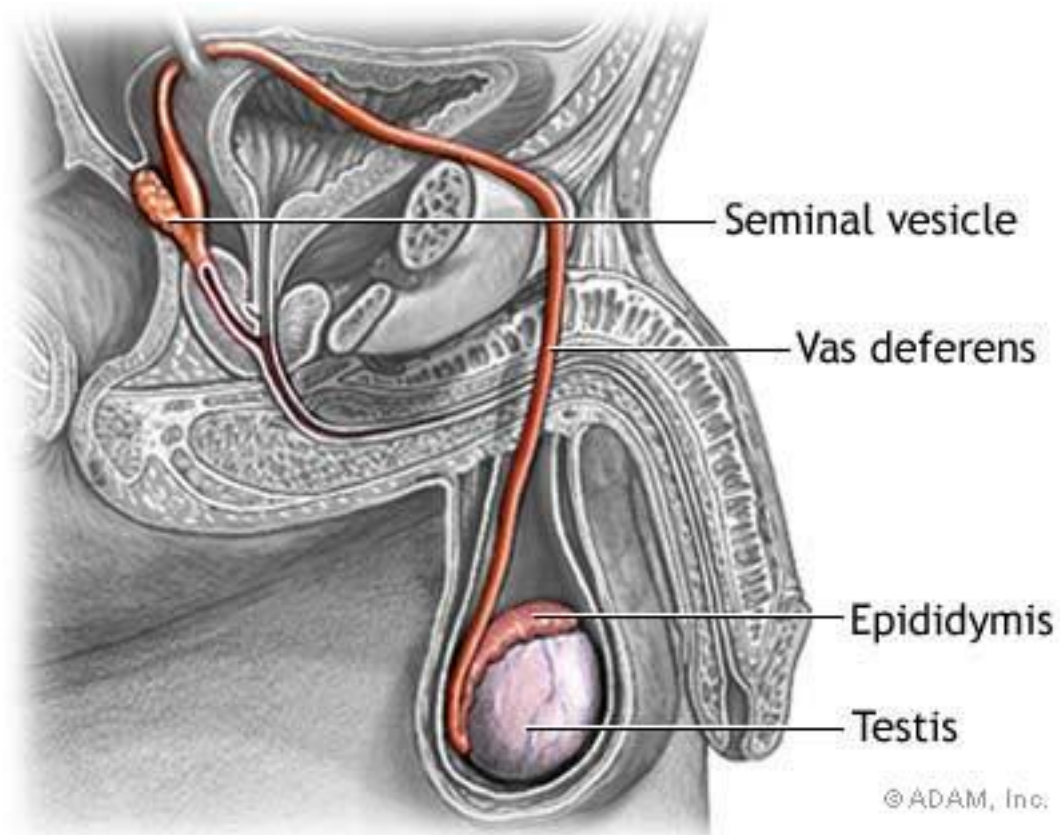
The ductus deferens

The **ductus deferens** (deferent duct, vas deferens) has 4 parts:

1. **scrotal part** (ascends posterior to the testis and epididymis);
2. **funicular part** (is the primary component of the spermatic cord = *funiculus spermaticus*);
3. **inguinal part** (penetrates the anterior abdominal wall via the inguinal canal);
4. **pelvic part** (passes along the lateral wall of the pelvis).

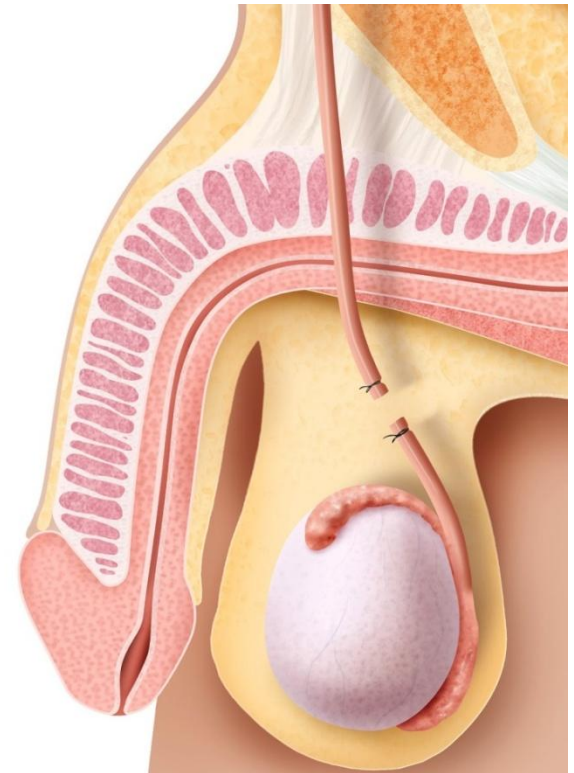
It begins at the tail of the epididymis and ends by joining the duct of the seminal vesicle.

The ductus deferens



Male sterilization

The common method of the male sterilization is the ***deferentectomy*** (popularly called a *vasectomy*). The ductus deferens is cut and ligated.



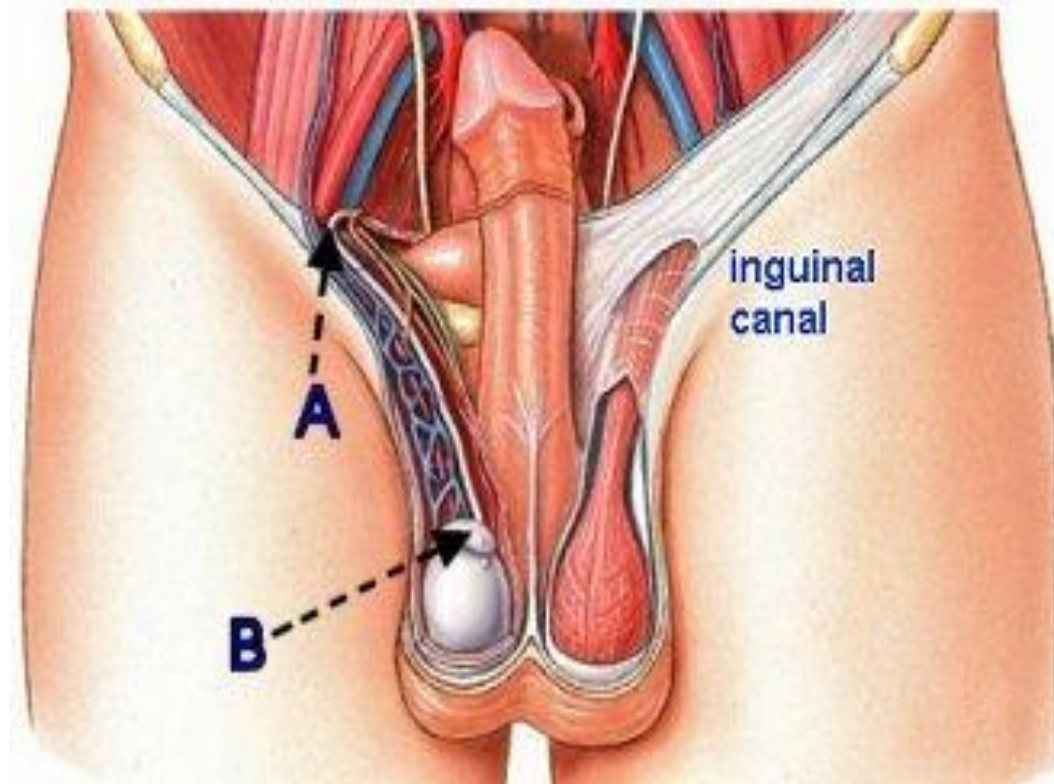
Spermatic cord

The **spermatic cord** (L. *funiculus spermaticus*) is the cord-like structure that suspends the testis into the scrotum.

It runs from the deep inguinal ring down to the testicle.

It is formed by the **ductus deferens** (or *vas deferens*) and surrounding tissue.

Spermatic cord



Spermatic cord

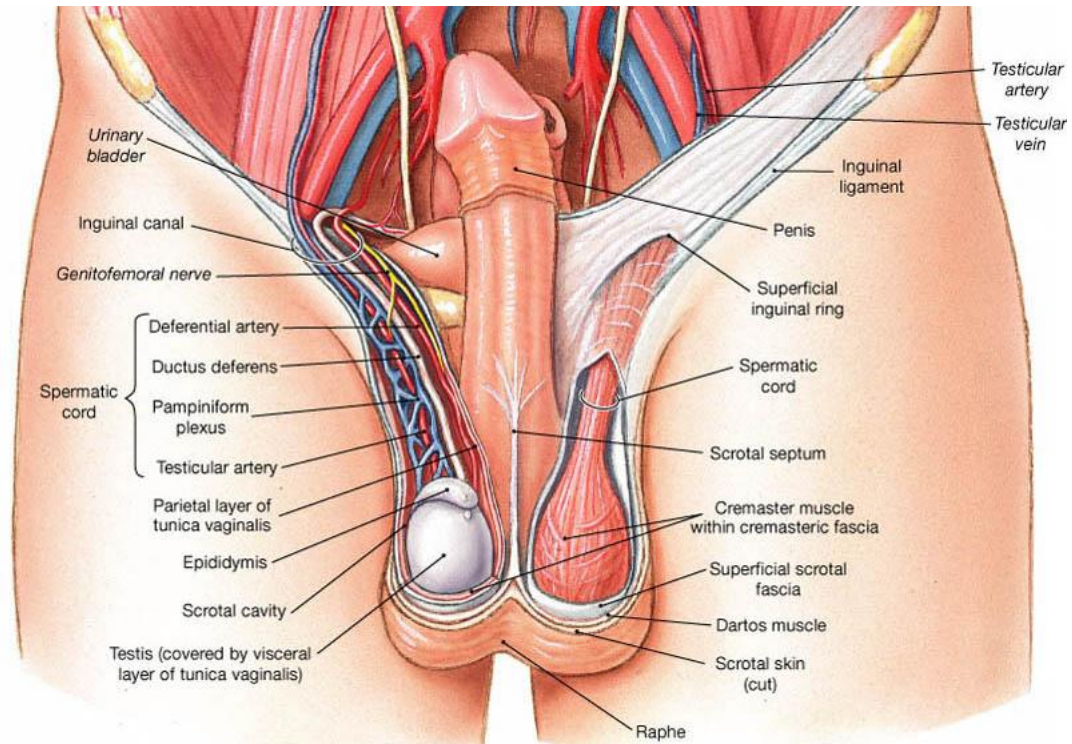
It contains:

- ***ductus deferens*** (or vas deferens);
- arteries: ***testicular artery***, ***deferential artery***, ***cremasteric artery***;
- ***pampiniform*** (venous) ***plexus***;
- ***lymphatic vessels***;
- ***nerves***.

It is surrounded by:

1. external spermatic fascia;
2. cremaster muscle and cremasteric fascia;
3. internal spermatic fascia.

Spermatic cord



The ejaculatory ducts

The ***ejaculatory ducts*** are tubes that arise by the union of the ducts of the seminal glands with the ductus deferentes (approximately 2 cm long). They open on the *seminal colliculus* (male urethra).

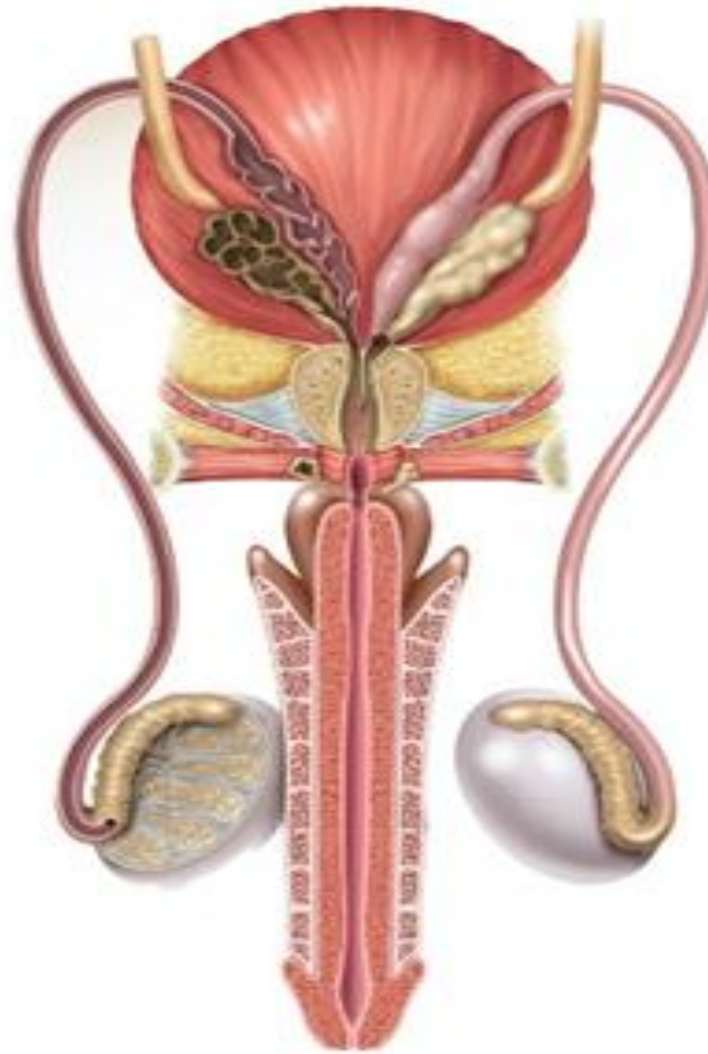
Pathway of sperm (spermatic ways)

The *convoluted seminiferous tubules* are the sites of **sperm production** (spermatogenesis).

The sperms travel through:

- ***straight seminiferous tubules;***
- ***rete testis;***
- ***efferent ductules;***
- ***duct of epididymis;***
- ***ductus deferens;***
- ***ejaculatory duct;***
- ***male urethra.***

Pathway of sperm (spermatic ways)



The prostate

The **prostate** is the largest accessory gland of the male reproductive system.

Prostatic fluid, a thin, **milky fluid** provides approximately 20% of the volume of semen and plays a role in activating the sperms.

The seminal glands (or seminal vesicles)

Each seminal gland is an elongated structure (approximately 5 cm long).

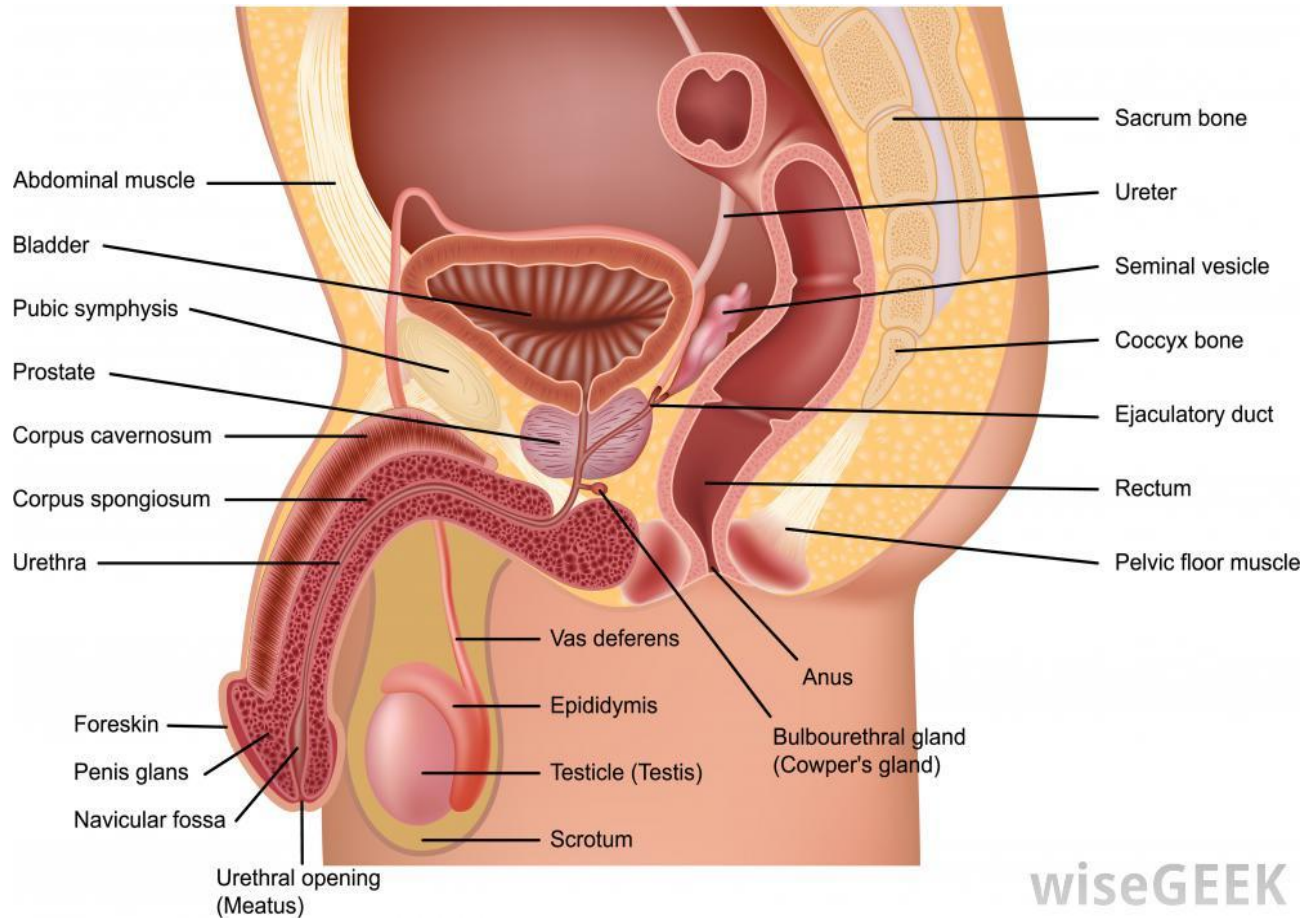
The seminal glands do not store sperms, as their names implies. They secrete a thick **alkaline fluid** with **fructose** (an energy source for the sperms).

The duct of the seminal gland joins the ductus deferens to form the **ejaculatory duct**.

The bulbourethral glands

The ***bulbourethral glands*** (*Cowper`s glands*) are small pea-size glands. Their ***mucus-like secretion*** enters the male urethra during sexual arousal.

The accessory glands



Penis

The main parts of penis are:

- ***root of the penis;***
- ***body of the penis;***
- ***glans penis*** (covered by foreskin, in circumcised men the foreskin is removed).

Internal structure. It is made up of three columns of tissue:

- two ***corpora cavernosa;***
- one ***corpus spongiosum.***

Scrotum

The scrotum houses the testicles.

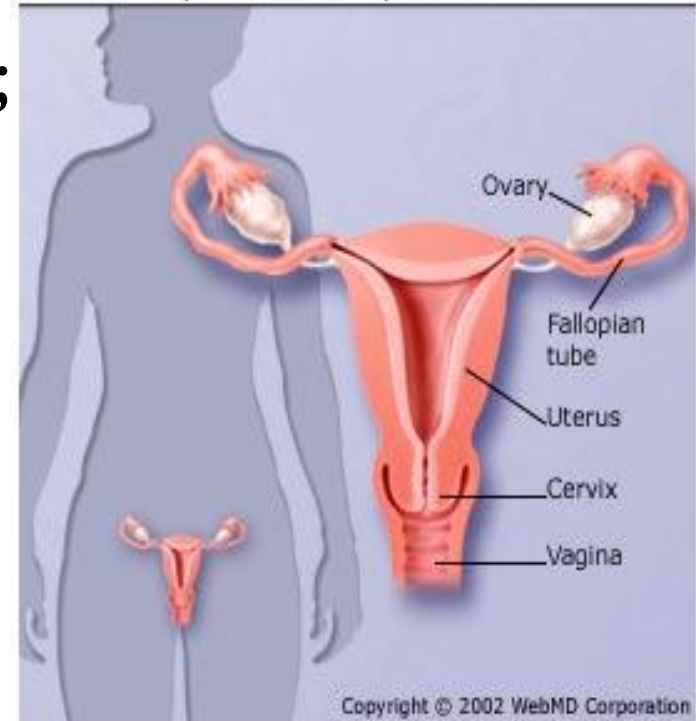
The following structure enclose the contents of the scrotum (from outside to inside):

1. **skin** of the scrotum;
2. **tunica dartos**;
3. **external spermatic fascia**;
4. **cremasteric fascia**;
5. **cremaster muscle**;
6. **internal spermatic fascia**;
7. **tunica vaginalis testis** (*lamina parietalis* and *lamina visceralis*) provides the serous cavity of the testis.

Female genital system

- **Female internal genitalia:**
 1. female gonads (ovaries);
 2. uterine tubes;
 3. uterus;
 4. vagina.
- **Female external genitalia:**
 1. vulva or pudendum;
 2. vestibular glands.

Female Reproductive System



Ovary

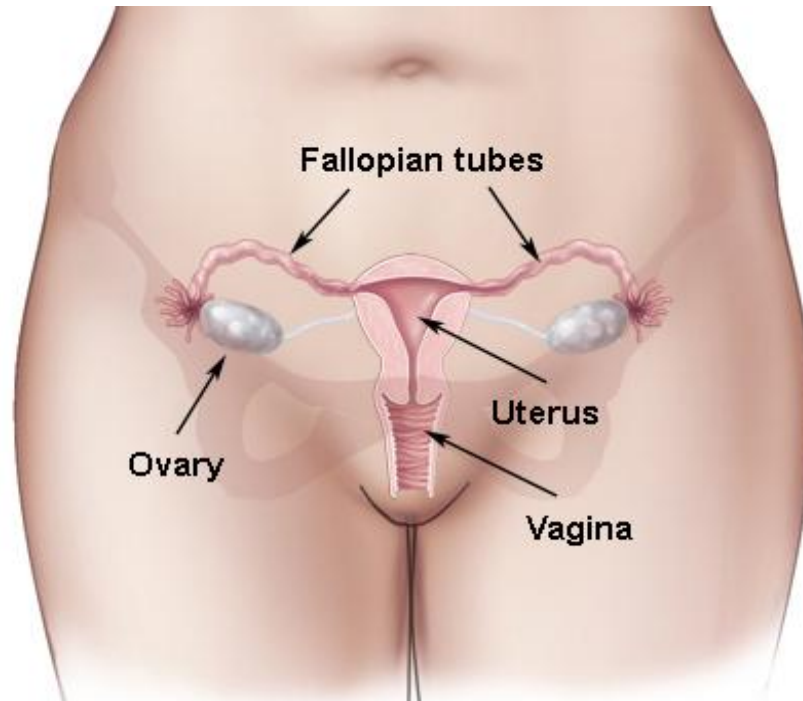
The **ovary** (ovarium, oophoron) is:

1. **an ovum-producing organ** (ovogenesis);
2. **an endocrine gland.**

It has:

- two **surfaces: medial** and **lateral**;
- two **borders: mesovarian** (anterior) and **free** (posterior);
- two ends (or **extremities**): **tubal** and **uterine.**

Ovary



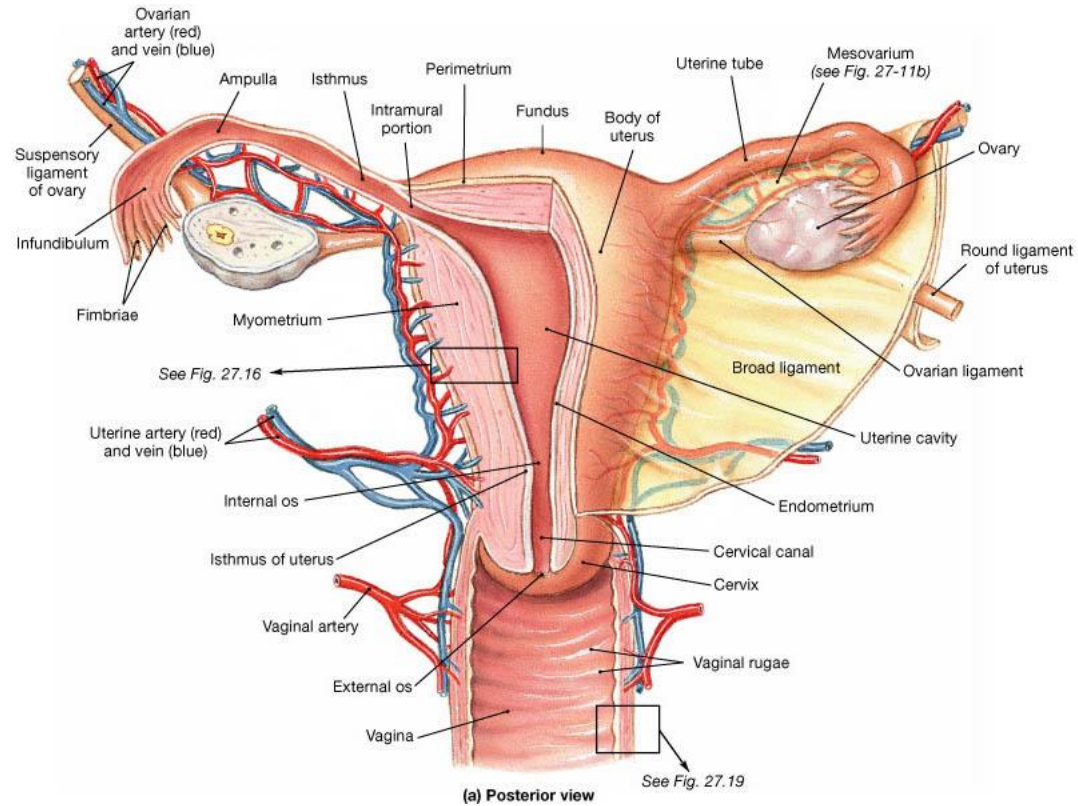
Ovary – fixation apparatus

It is located in the peritoneal cavity, on the posterior surface of the *broad ligament of uterus* to which it is attached by the **mesovarium**.

The tubal extremity of the ovary is connected to the wall of the pelvic cavity via the **suspensory ligament of ovary** (*lig. suspensorium ovarii*).

The uterine extremity is attached to the uterus via the **ligament of ovary** (*lig. ovarii proprium*).

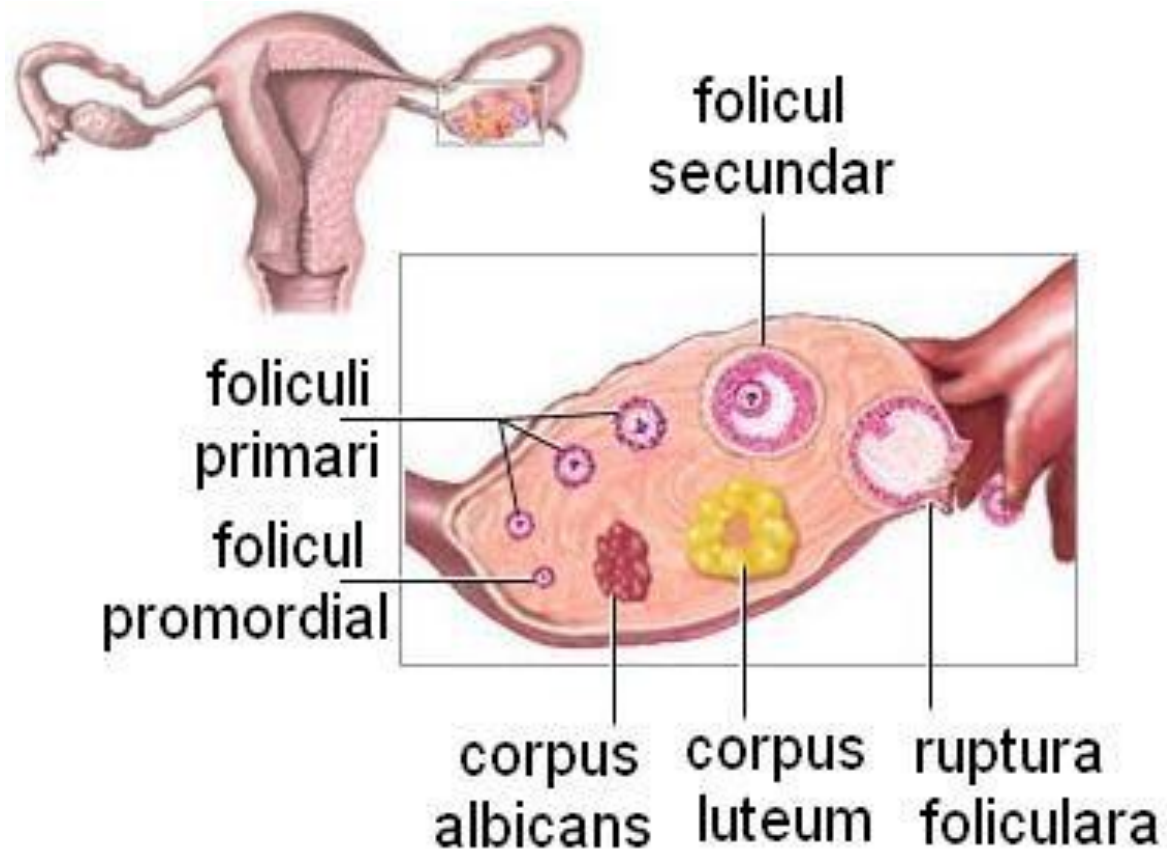
Ligaments of the ovary



Structure of the ovary

- The **ovarian cortex** consists of the **ovarian follicles**, *corpus luteum*, *corpus albicans* and *stroma*.
- The **ovarian medulla** contains blood vessels, lymphatics and nerves.

Structure of the ovary



The ovarian cycle (28 days)

The **ovarian cycle** has two phases:

- the **follicular phase** (the developing follicle produces the *oestrogen*);
- the **luteal phase** (the ruptured follicle transforms into the *corpus luteum*, which produces the *progesterone*).

These two phases are separated by the **ovulation** (the 14th day of cycle) – expulsion of an ovum from the ovary on spontaneous rupture of a mature (Graafian) follicle.

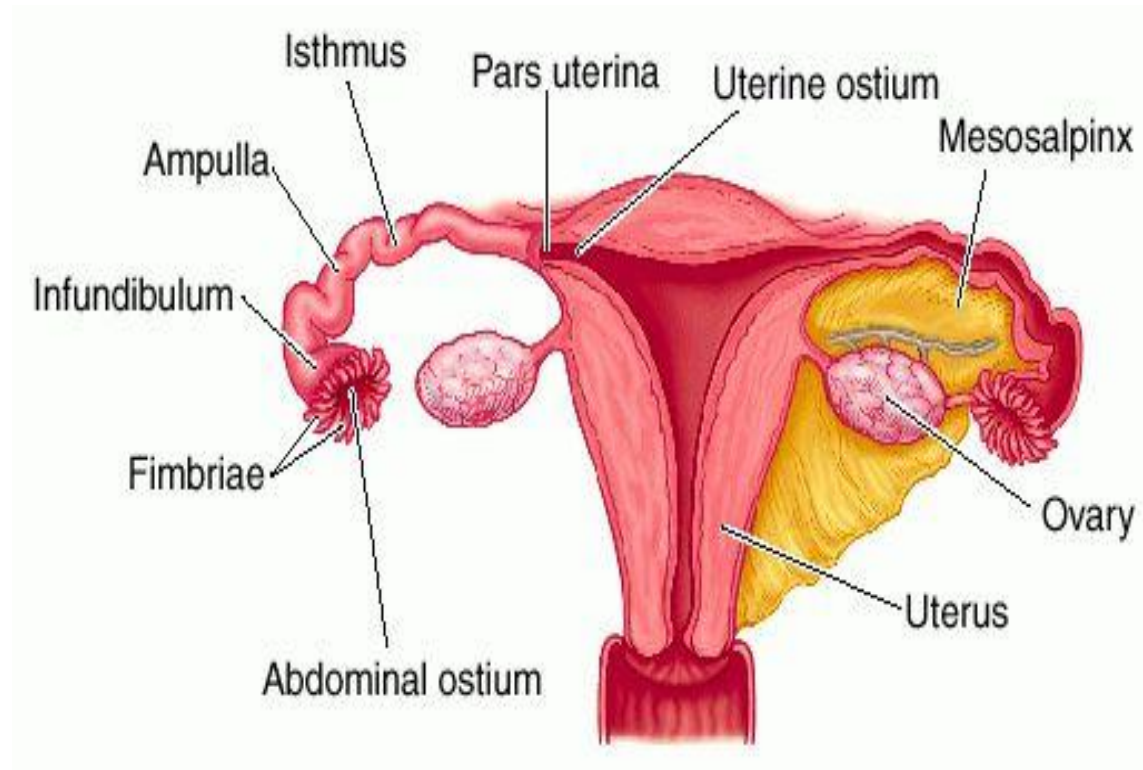
PS. The few days surrounding ovulation (from 10th to 18th of a 28 day cycle) constitute the most fertile phase.

Uterine tubes (salpinx, formerly called fallopian tubes)

There are 4 parts of the uterine tubes:

1. **uterine part** (the short intramural segment of the tube);
2. **isthmus** (the narrowest part of the tube);
3. **ampulla** (the widest and longest part of the tube);
4. **infundibulum** (the funnel-shaped distal end).

Uterine tube (or salpinx)



Uterine tubes (salpinx)

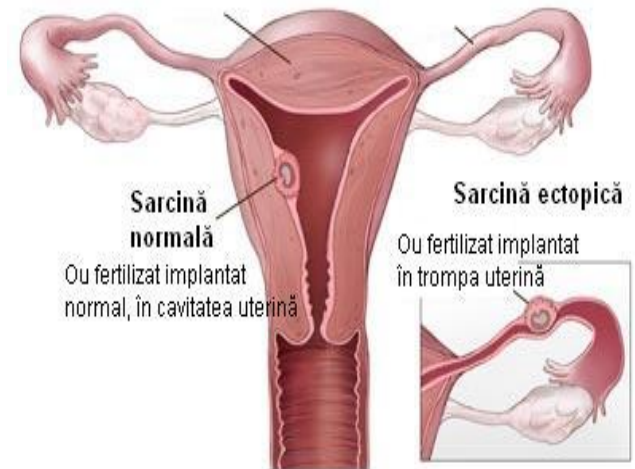
There are two orifices of the tubes:

- the ***uterine ostium*** (opens into the uterine cavity);
- the ***abdominal ostium*** (opens into the peritoneal cavity).

Ectopic tubal pregnancy

The uterine tubes provide the usual site of fertilization.

The blastocyst may implant in the mucosa of the uterine tube, producing an **ectopic tubal pregnancy**.

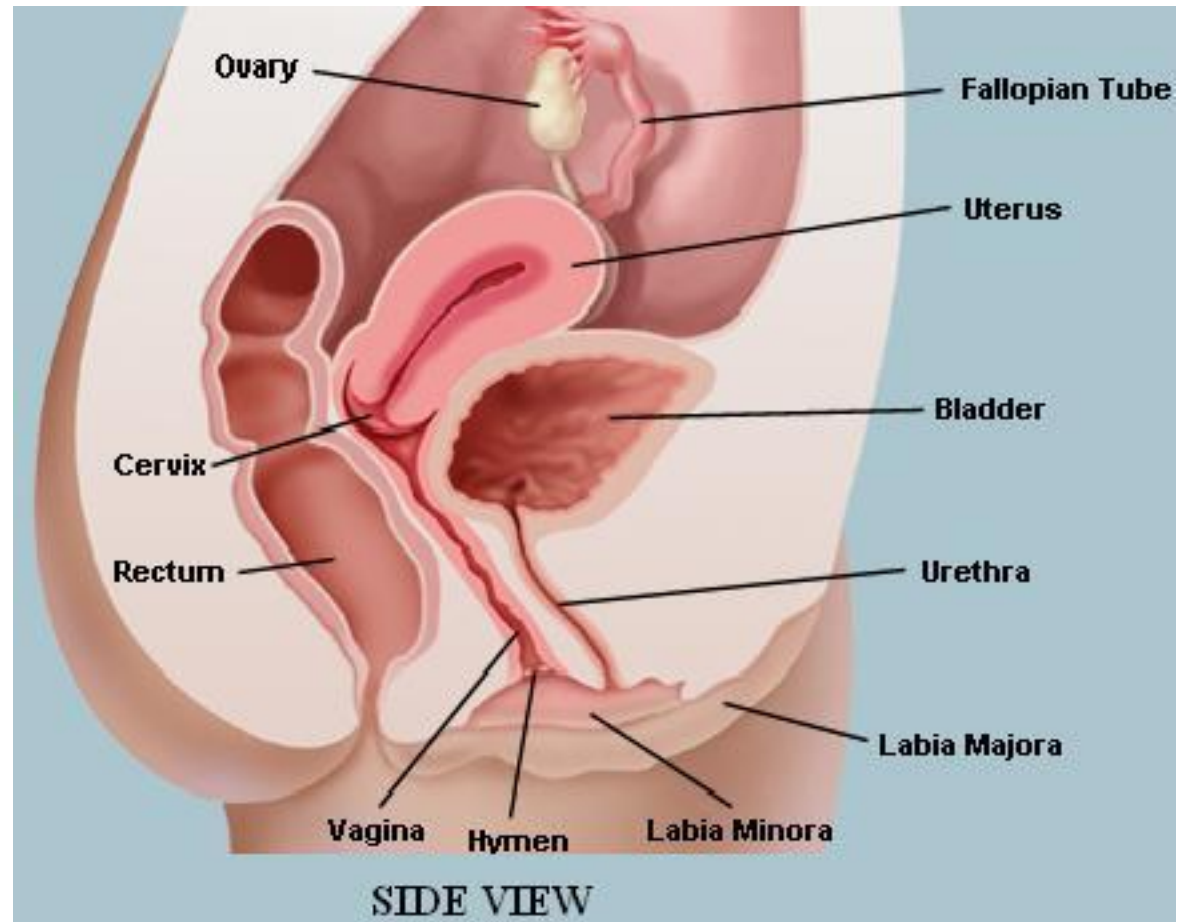


Uterus (or *metra, hystera*)

The uterus (or womb) is a pear-shaped, hollow muscular organ.

The adult uterus is usually ***anteverted*** (tipped anterosuperiorly to the axis of the vagina) and ***anteflexed*** (flexed or bent anteriorly to the cervix of uterus).

Uterus



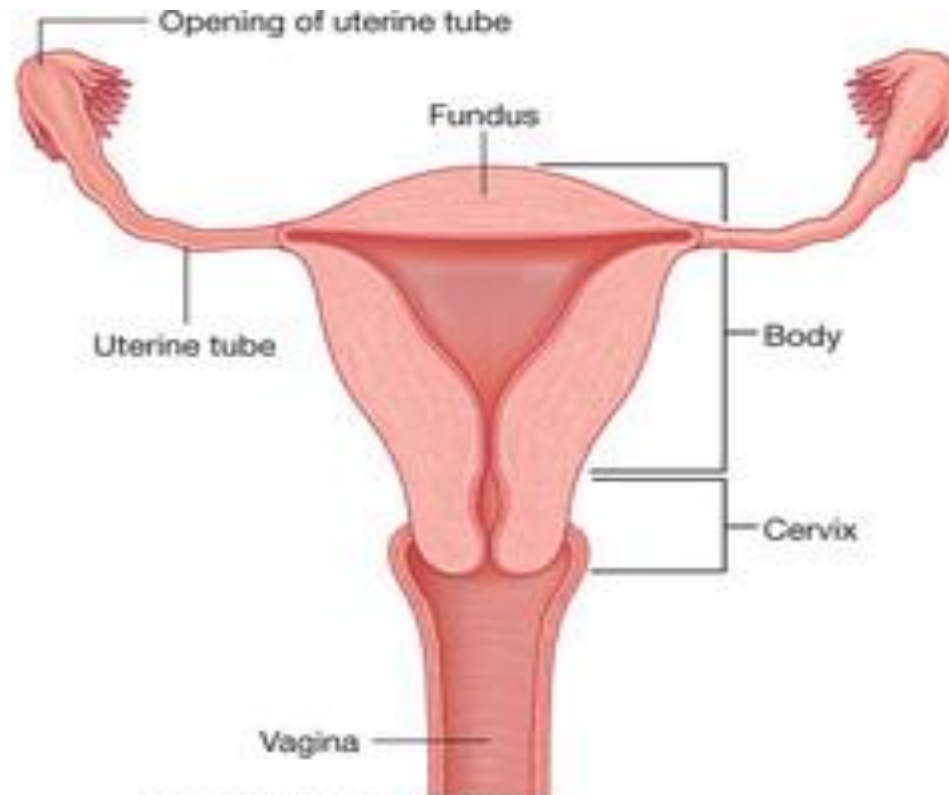
Uterus

The uterus has two main parts:

1. ***body of uterus;***
2. ***cervix of uterus.***

The body is demarcated from the cervix by the ***isthmus of uterus.***

Uterus



Drake: Gray's Anatomy for Students, 2nd Edition.
Copyright © 2009 by Elsevier Livingstone, an imprint of Elsevier, Inc. All rights reserved.

Uterus

The **body of the uterus** (superior 2/3 of the organ) has:

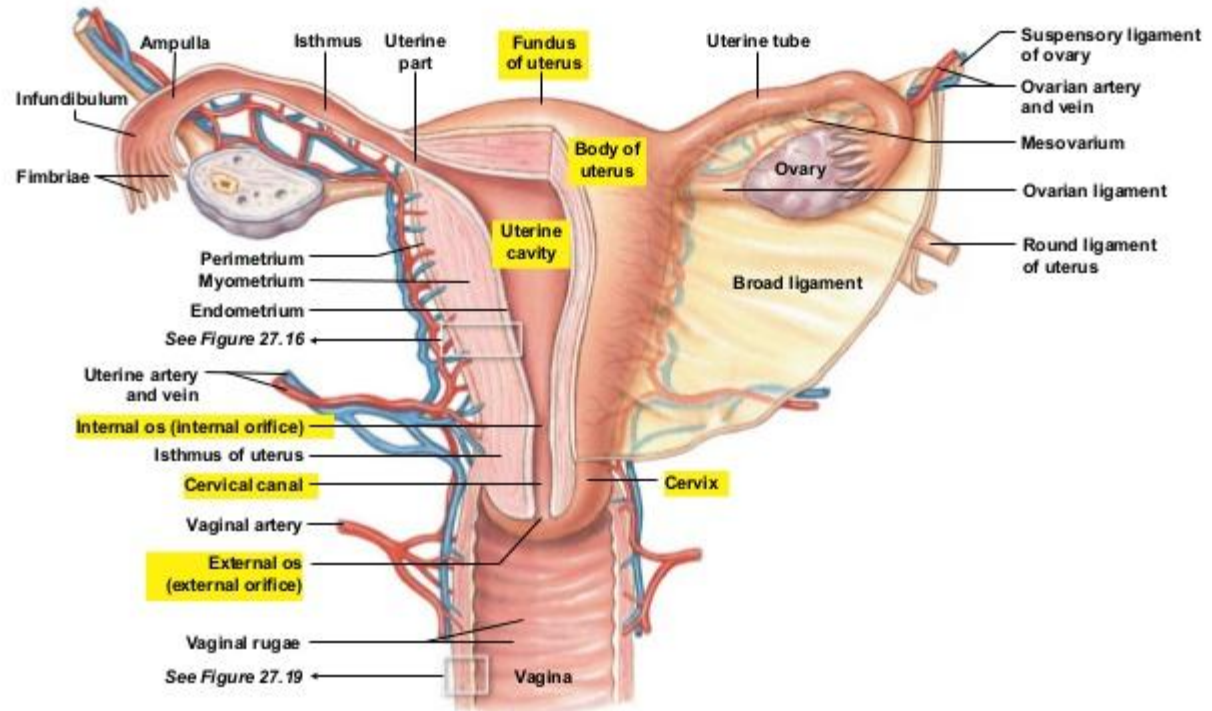
1. ***fundus of uterus***;
2. two ***surfaces*** (***vesical*** and ***intestinal***);
3. two ***borders*** (***right*** and ***left***).

The **cervix of the uterus** (inferior 1/3 of the organ) has two parts:

1. ***supravaginal part***;
2. ***vaginal part***.

Uterus

Figure 27.15a The Uterus



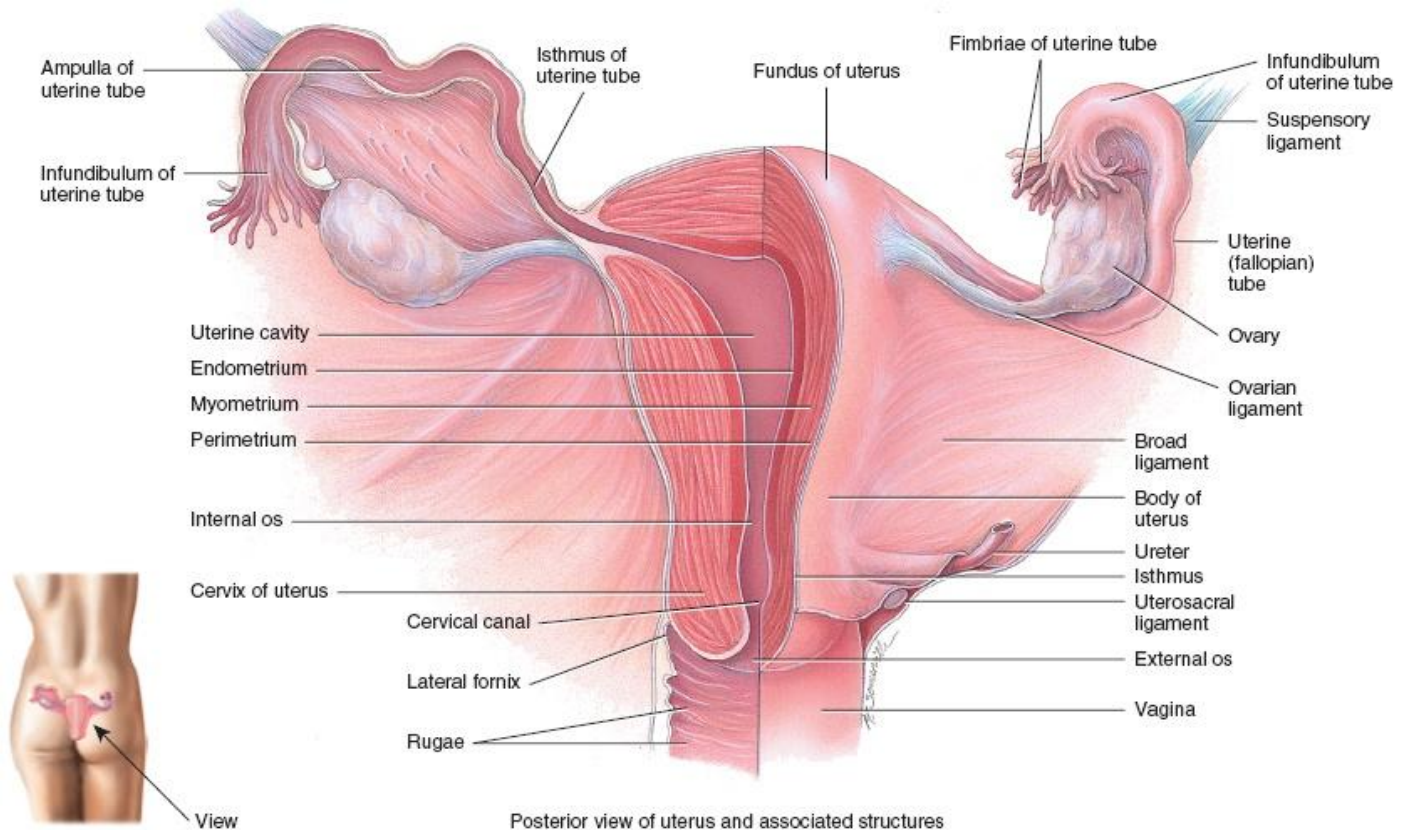
■ Posterior view of the uterus and stabilizing ligaments within the pelvic cavity

Uterus – structure of the walls

The wall of the uterus consists of the three coats, or layers:

- ***perimetrium*** (the outer, serous coat);
- ***myometrium*** (the middle coat of smooth muscles);
- ***endometrium*** (the inner, mucous coat).

Uterus – structure of the walls

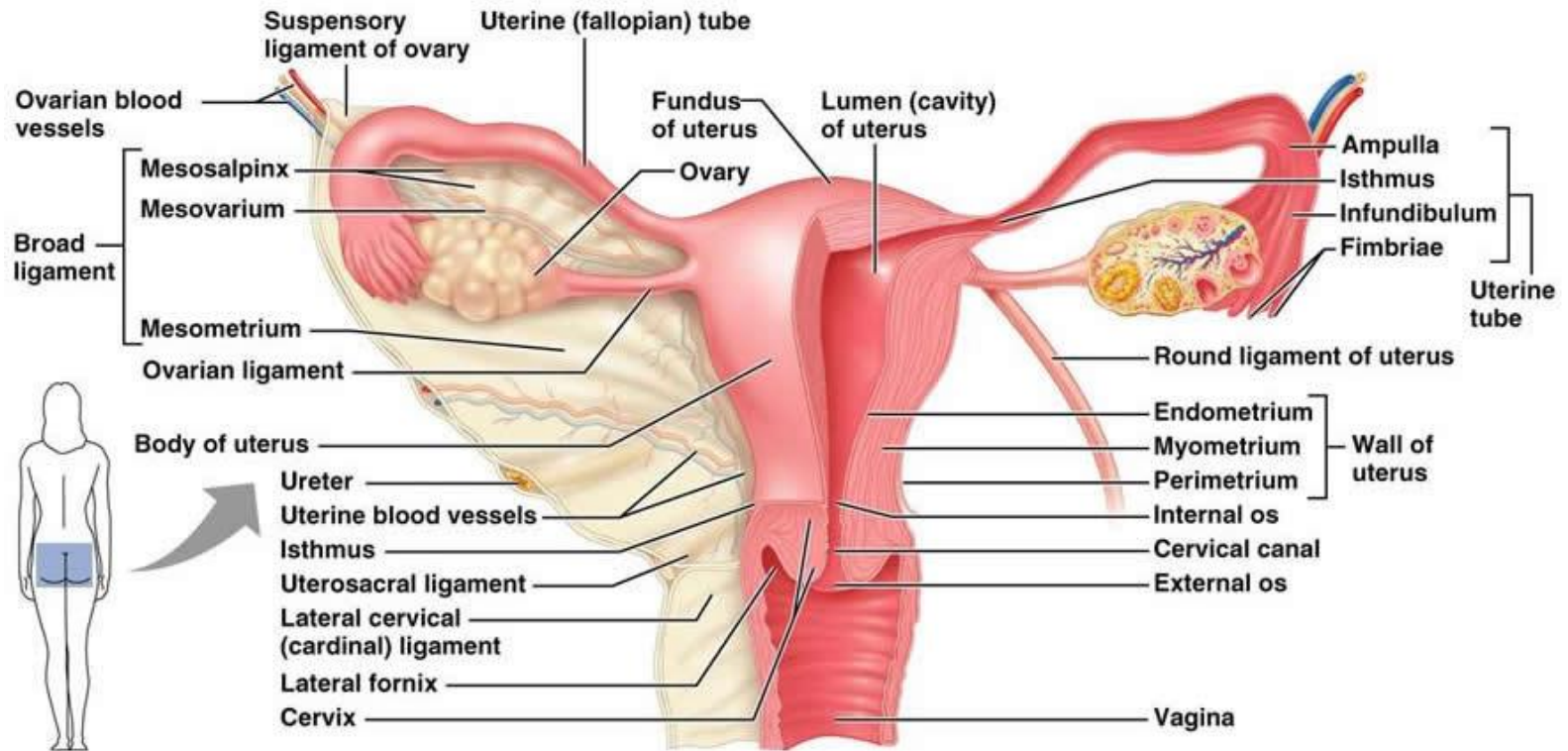


Ligaments of the uterus

- The ***round ligament of the uterus***;
- The ***broad ligament of the uterus*** (it has three parts: *mesometrium, mesovarium, mesosalpinx*);
- The ***transverse cervical (or cardinal) ligament***;
- The ***uterosacral ligament***.

The principal support of the uterus is the ***pelvic diaphragm*** (part of perineum).

Ligaments of the uterus



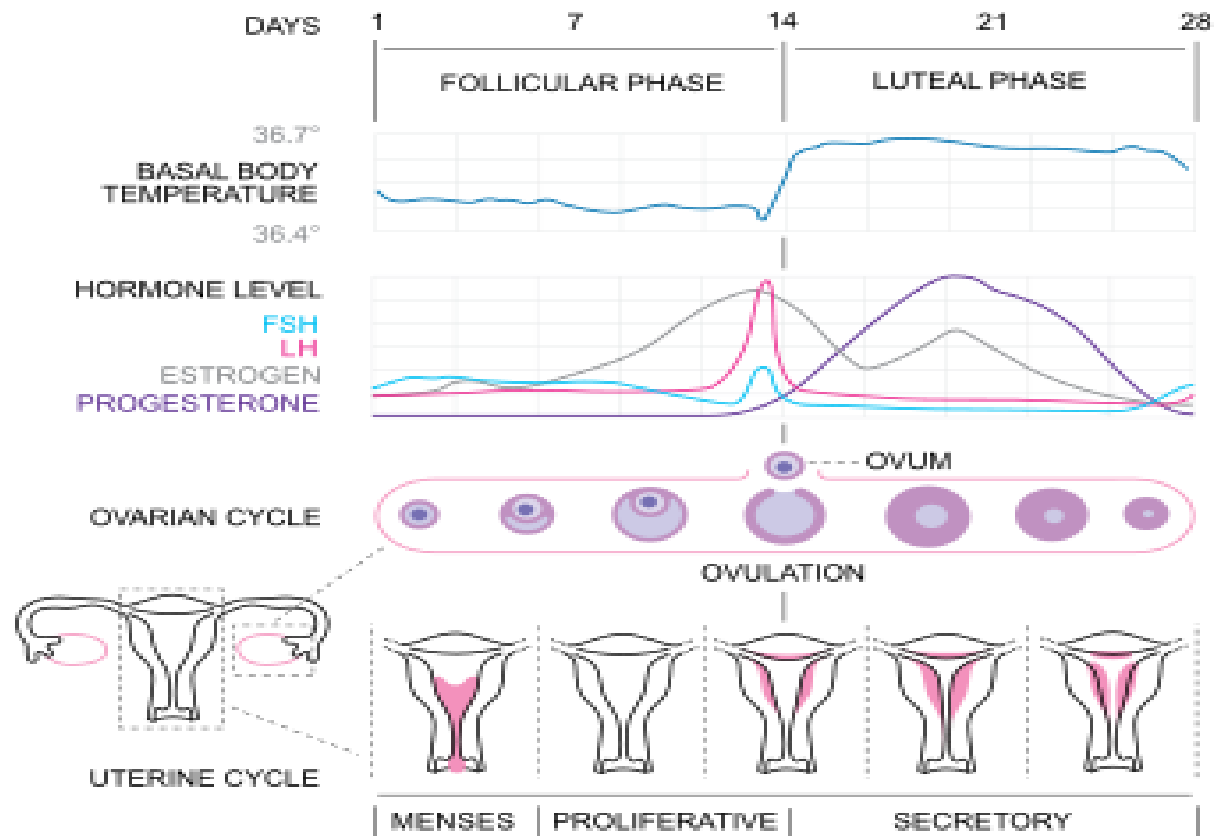
Menstrual cycle (28 days)

The ***menstrual cycle*** is the monthly series of changes in the female's uterus. It takes an average of 28 days, but this can vary from 21 to 35 days.

There are three phases of the menstrual cycle:

- ***menses*** (or menstrual phase);
- ***proliferative phase*** (or postmenstrual phase);
- ***secretory phase*** (or premenstrual phase).

Ovarian and menstrual cycles



Vagina (colpos)

The **vagina**, a musculomembranous tube, extends from the cervix of the uterus to the vestibule (the cleft between two labia minora).

The vagina is usually collapsed so that its **anterior** and **posterior walls** are in contact, except its superior end (superior wall).

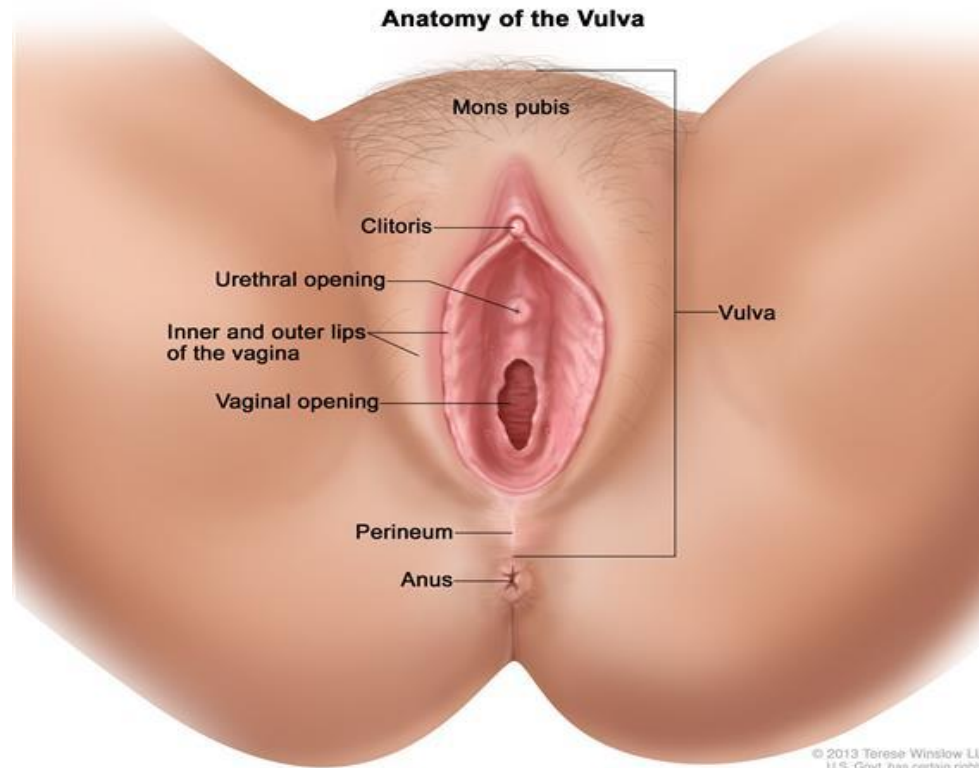
The **vaginal fornix** (superior wall), the recess around the cervix, has *anterior, posterior and lateral parts*.

Vulva (or pudendum)

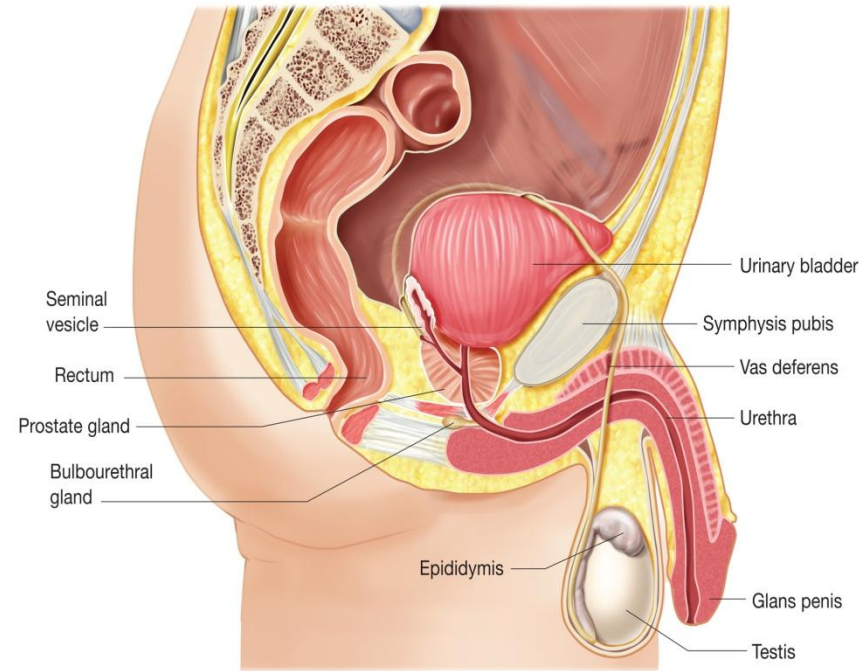
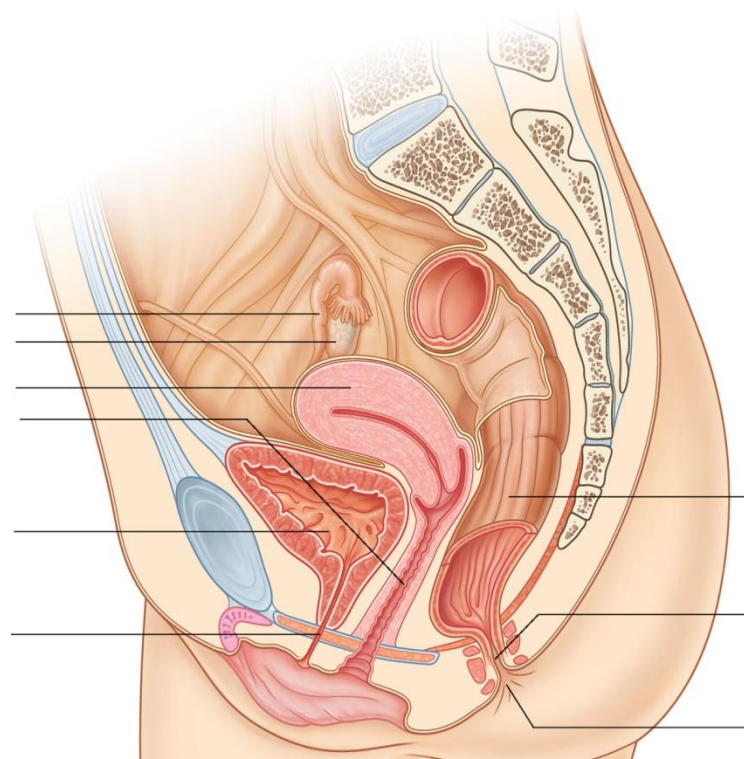
It includes:

- ***mons pubis***;
- ***labia majora*** and cleft between them called ***pudendal cleft***;
- ***labia minora*** and area between them called ***vestibule of vagina*** (or vulval vestibule);
- ***clitoris*** (homologue of corpora cavernosa penis) and ***bulb of vestibule*** (homologue of corpus spongiosus);
- ***greater*** (Bartholin`s) and ***lesser vestibular glands***.

Vulva (or external genitalia)



Genital systems



Female urethra

- It is a short fibromuscular tube (3 - 5 cm).
- It lies anterior to the vagina.
- It begins at the neck of the urinary bladder by the **internal urethral orifice** (or *internal urinary meatus*).
- It opens into the vestibule of vagina by the **external urethral orifice** (or *external urinary meatus*).
- It has two parts:
 1. **intramural** (or pelvic) **part** (located in the pelvic cavity, at the bladder neck);
 2. **perineal part** (which pierces the urogenital diaphragm of perineum).

Male urethra

- It is a fibromuscular tube that begins at the neck of the urinary bladder (**internal urethral orifice** or *meatus*) and ends at the level of the *glands penis* (**external urethral orifice** or *meatus*).
- It is significantly longer in males than females (20 cm).
- It consists of four parts:
 1. **intramural** (or preprostatic) **part** (0.5 cm);
 2. **prostatic part** (3 cm);
 3. **membranous** (or intermediate) **part** (1 cm);
 4. **spongy part** (16 cm) (with *bulbar part* and *penile part* of spongy urethra).

Male urethra

Male urethra can be divided in anterior and posterior portions.

- The **posterior urethra** is composed of the pre-prostatic, prostatic and membranous urethra.
- The **anterior urethra** is composed of the spongy urethra (that comprises the bulbar and penile parts).

It also can be divided in:

- **fixed portion**, which comprises the posterior urethra and the bulbar urethra;
- **mobile portion**, which comprises only the penile urethra.

Male urethra

Male urethra has 2 curvatures:

1. ***subpubic curvature*** (or angle);
2. ***prepubic curvature*** (or angle).

It has 3 constrictions:

1. *external urethral orifice* (or *external urinary meatus*);
2. *membranous part*;
3. *internal urethral orifice* (or *internal urinary meatus*).

It has 3 dilatations:

1. at the level of *glans penis* (navicular fossa);
2. at the level of *bulbus penis* (intraulbar fossa);
3. prostatic part.



Thank you!