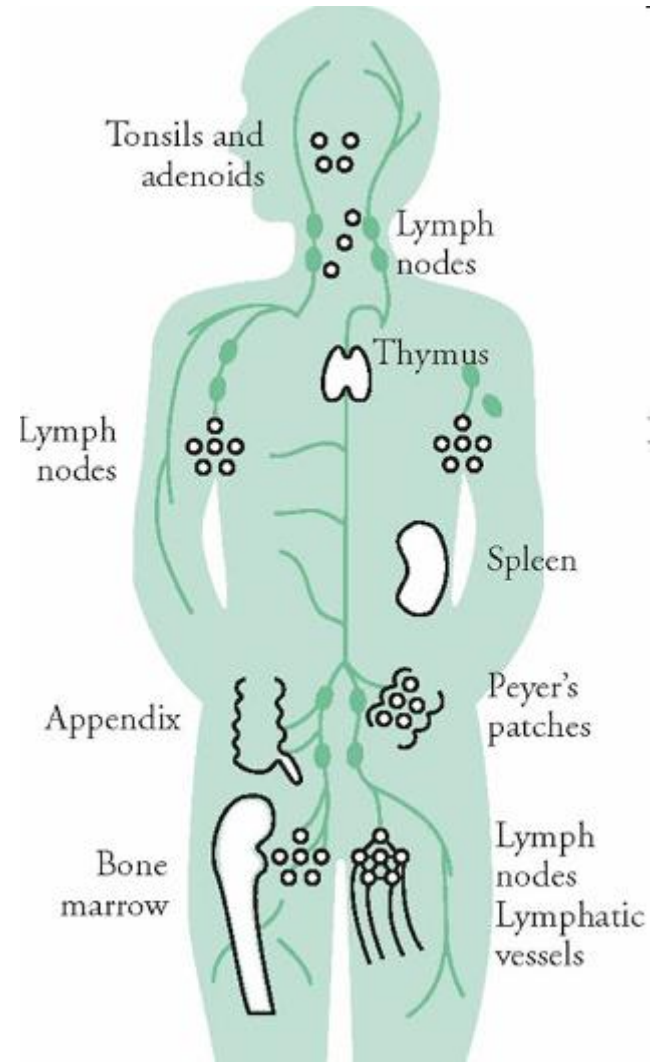
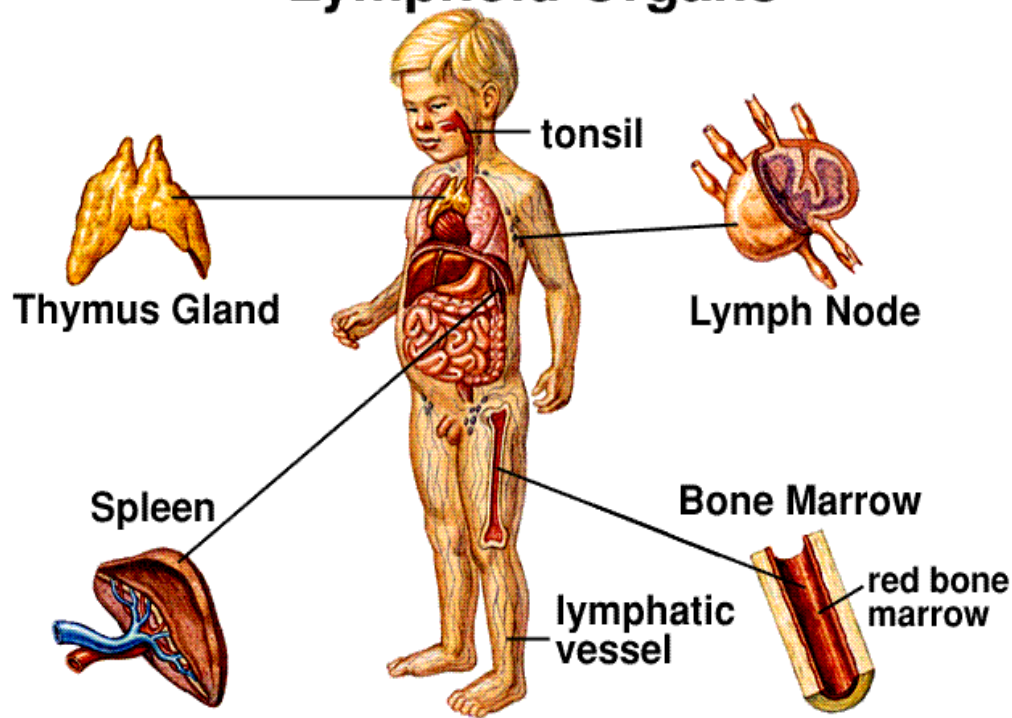


Lymph nodes and vessels

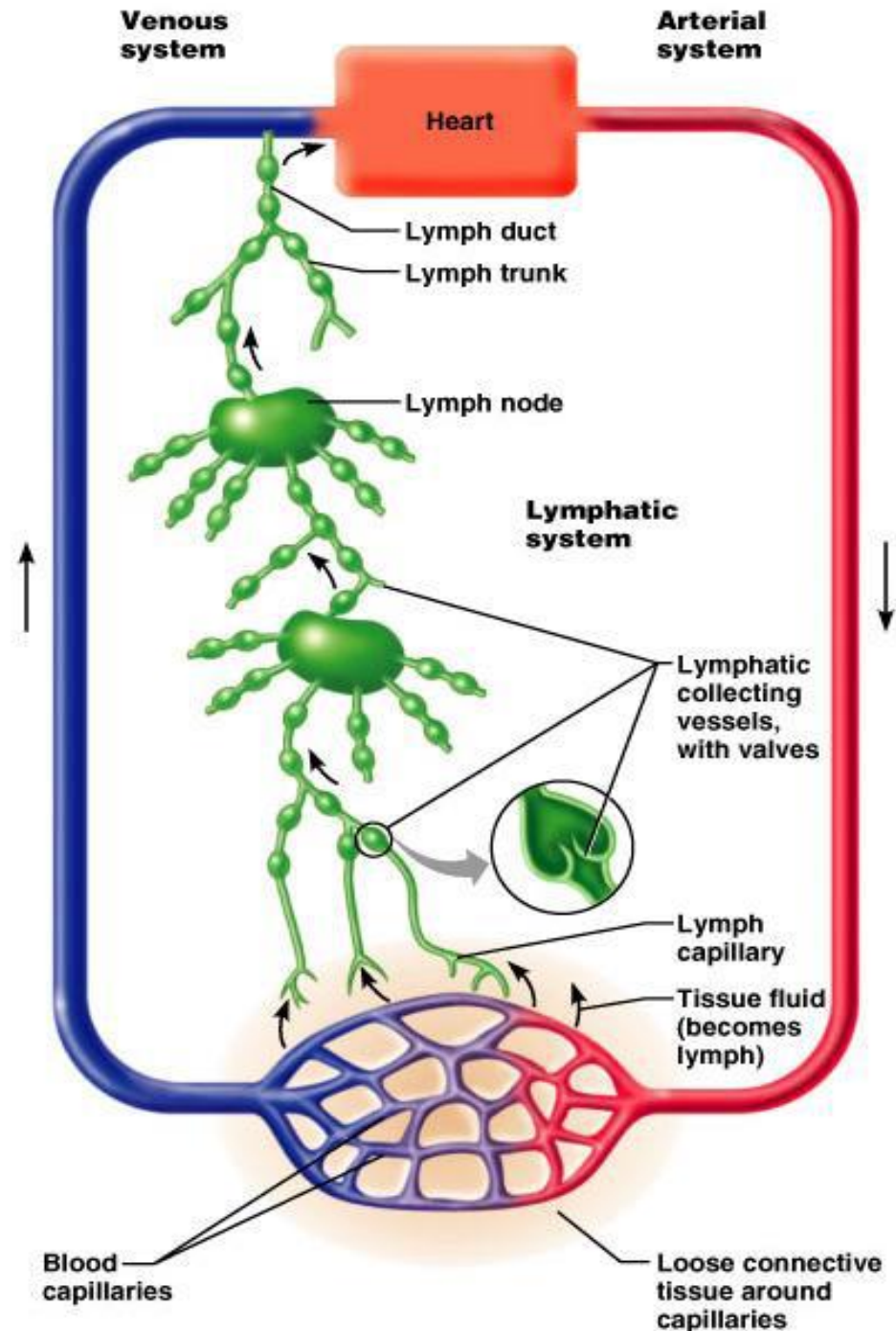
Lymphoid Organs



David Kachlík
Martin Špaček
Anne LeRoy

Lymph system

- **lymph (*lymp~~h~~a*)**
 - composition similar to plasma with low protein content
 - chylus (*chylos* = *gr. juice*) – intestinal lymph, milky (due to *chylomicrones*)
- **lymph vessel** (*vas lymphoideum*)
- **lymph organs**
- all lymph is drained into veins (into *angulus venosus*)
- missing in some organs (cartilage, cornea, bone marrow, placenta) or replaced with other fluid (brain, eyeball, inner ear...)

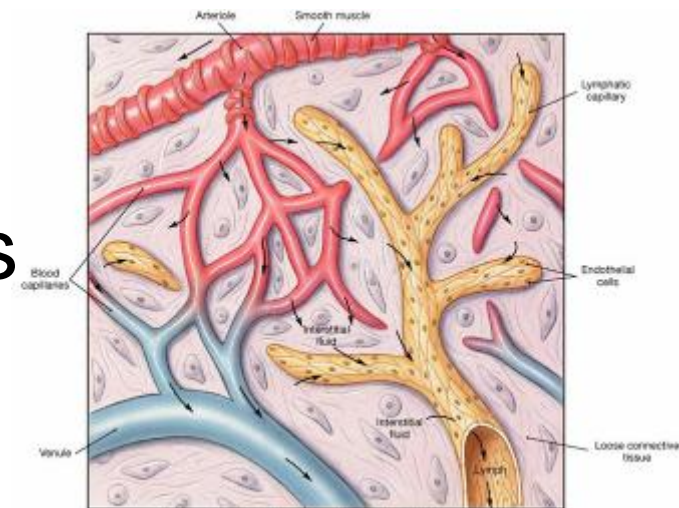


Lymph system – function

- blood filtration and „purification“ via lymph nodes – immune function
- return of extravascular fluid into blood circulation
- transport of proteins and other large particles into systemic circulation
- „education“ (maturation) and multiplication of lymphocytes
- transport of lipids in chylomicrones from small intestine into systemic circulation
- daily production = about 60 ml / kg

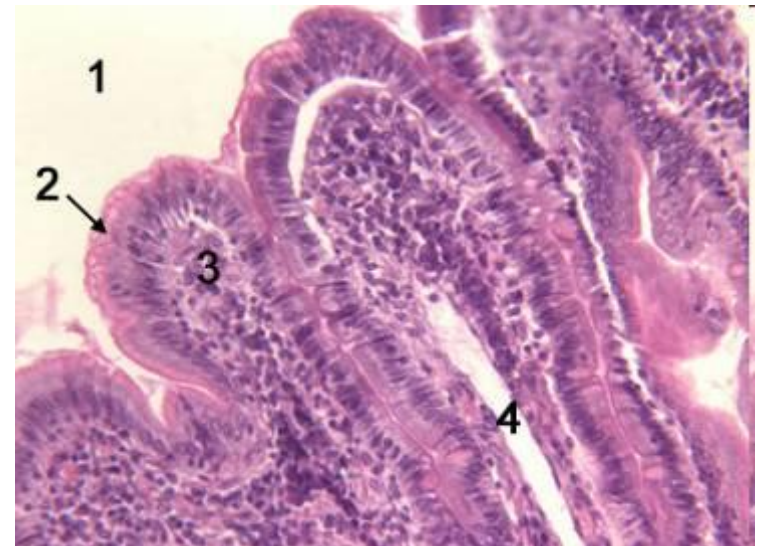
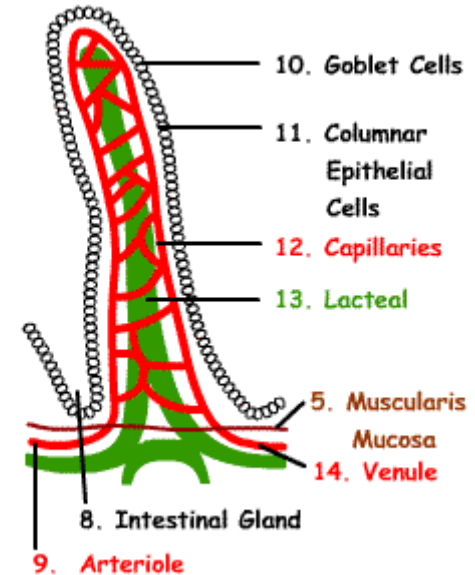
Lymph capillaries

- begin as cul-de-sac
 - fluid flows only inwards
 - plus: viruses, bacteria, tumour cells
- collect superfluous tissue fluid
- no lamina basalis
- regularly one-way valves
- parallel to venules
- collect into lymphatic vessels



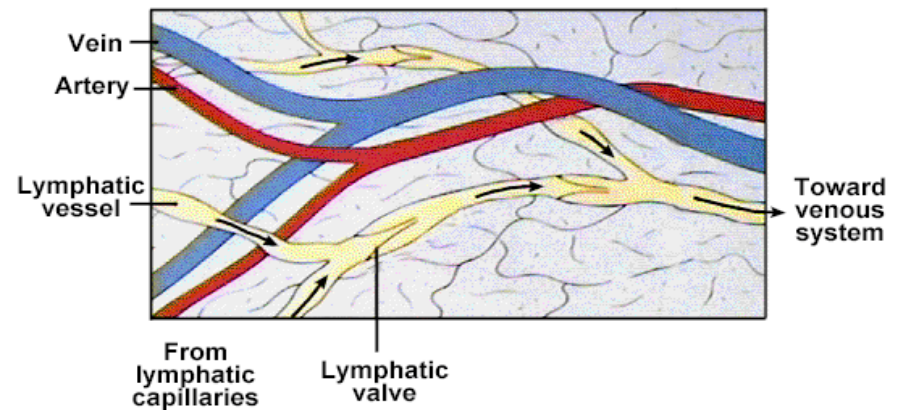
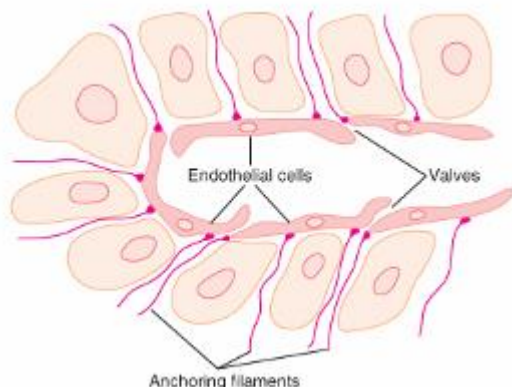

Lymph capillaries within villi

- villi of small intestine
- special arrangement
- lymph capillary in villus axis
- „lacteals“
- lipid absorption (chylomicrones)



Lymph vessels

- thin-walled vessel (thinner than in veins)
- interrupted lamina basalis
- endothelium without pores and *zonulae occludentes*
- *anchoring filaments* (enlarged openings between cells during swelling of surrounding tissue)
- larger amount of vessels
- lymph nodes put in course of lymph vessels
- lymph trunks: rather thick tunica media but thin tunica externa



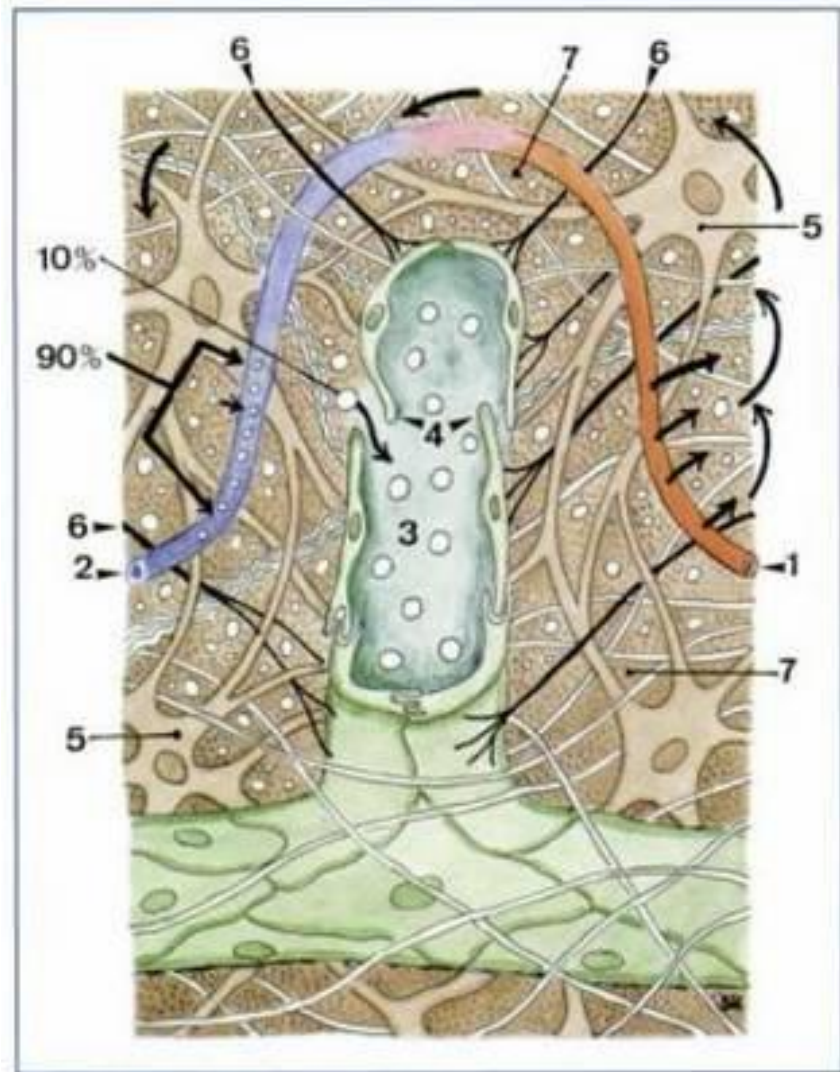
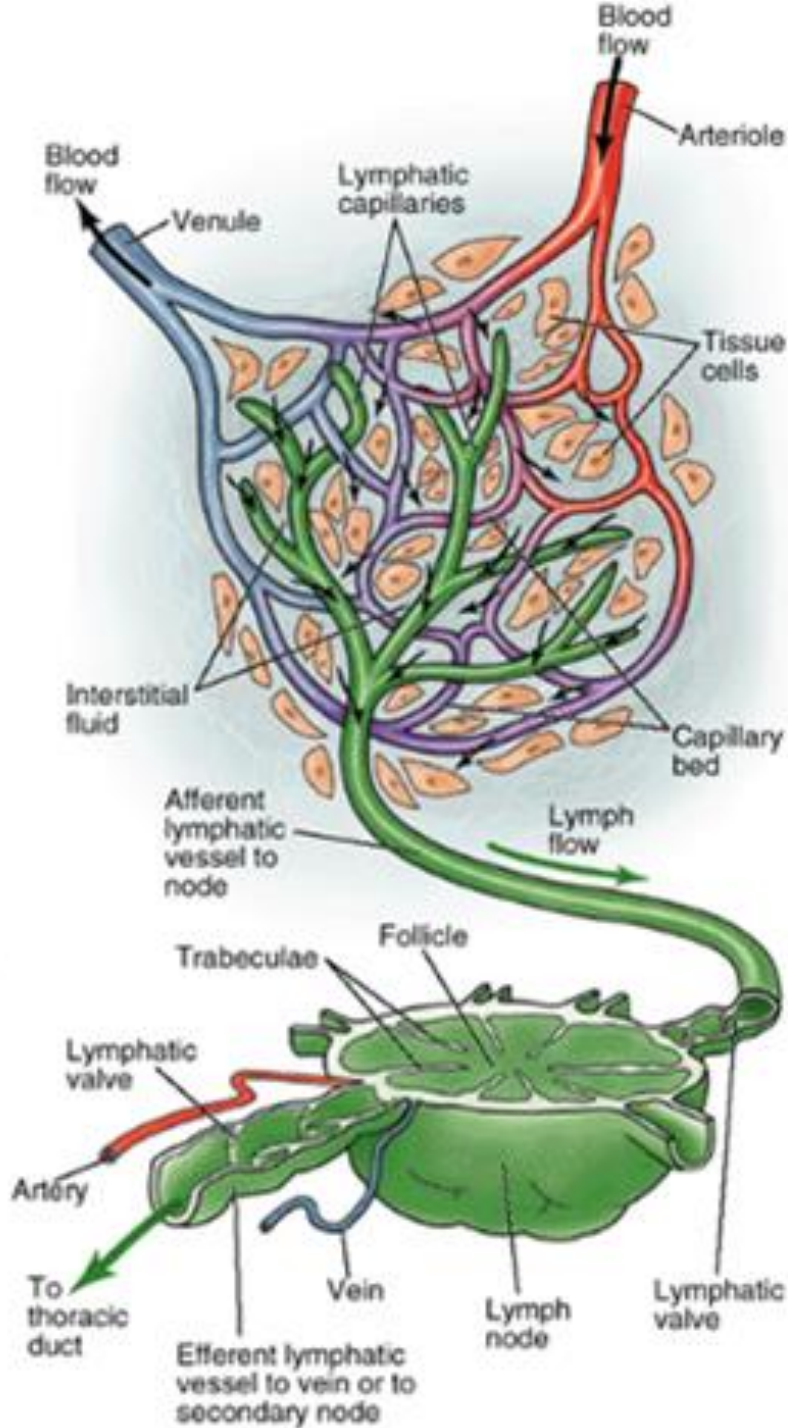
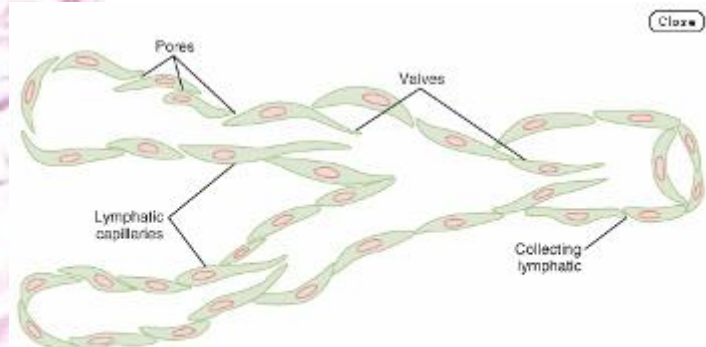
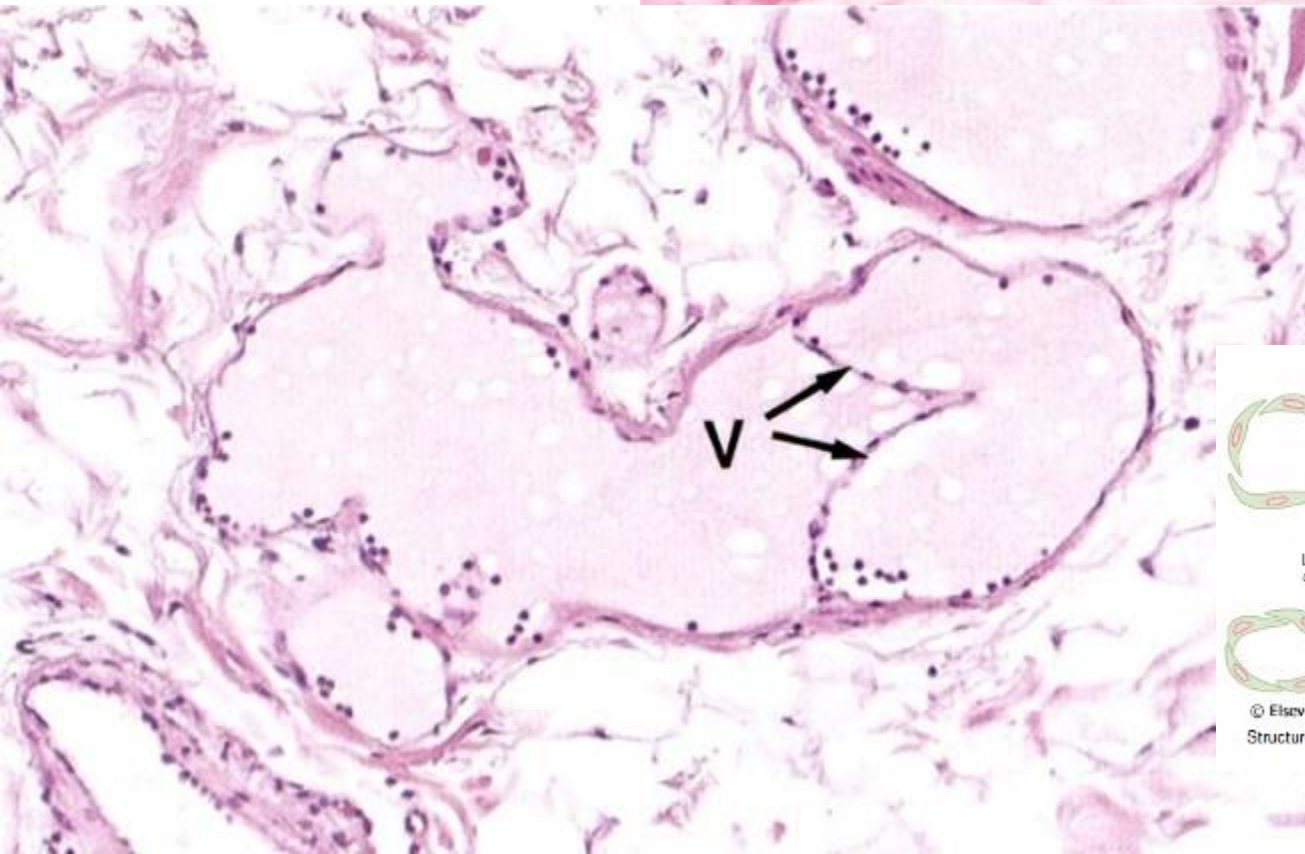
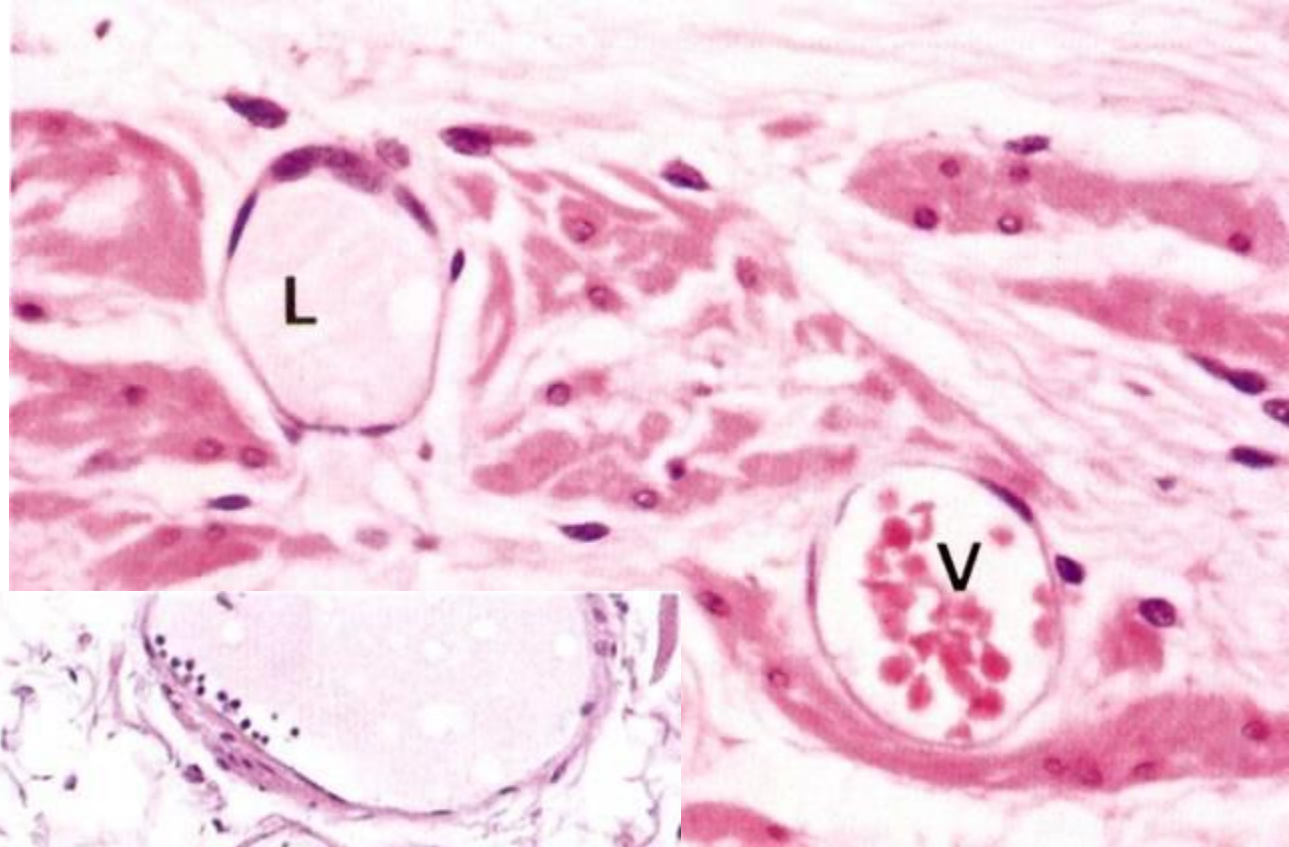


Fig. 1.21 Emplacement of the lymph capillaries in the interstitium

1 Arterial leg of the blood capillary **2** Venous leg of the blood capillary **3** Lymph capillary **4** Open intercellular fissure; swinging tip **5** Fibrocyte **6** Anchoring filaments **7** Intercellular space

Small arrows mark the direction of blood flow; the larger arrows indicate the flow of intracellular fluid [M 124]


Lymph vessels



© Elsevier. Guyton & Hall: Textbook of Medical Physiology 11e - www.studentconsult.com
Structure of lymphatic capillaries and a collecting lymphatic, showing also the lymphatic valves.

Lymph vessels general arrangement

- lymph capillaries → lymph vessels
- limbs (collectors): superficial → deep vessels
- organs: plexuses (subcapsular + deep) → lymph trunks → lymph ducts
- lymph nodes put in vessels



Lymph ducts

2 lymph ducts

– irregular division of body (drainage areas)

- **ductus thoracicus**

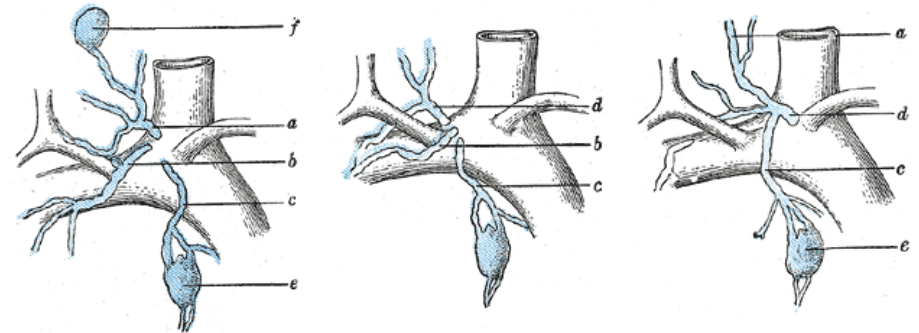
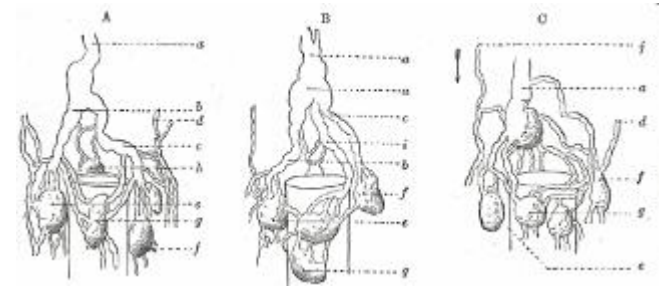
- pars abdominalis

- cisterna chyli *Pecqueti* (50%)

- pars thoracica

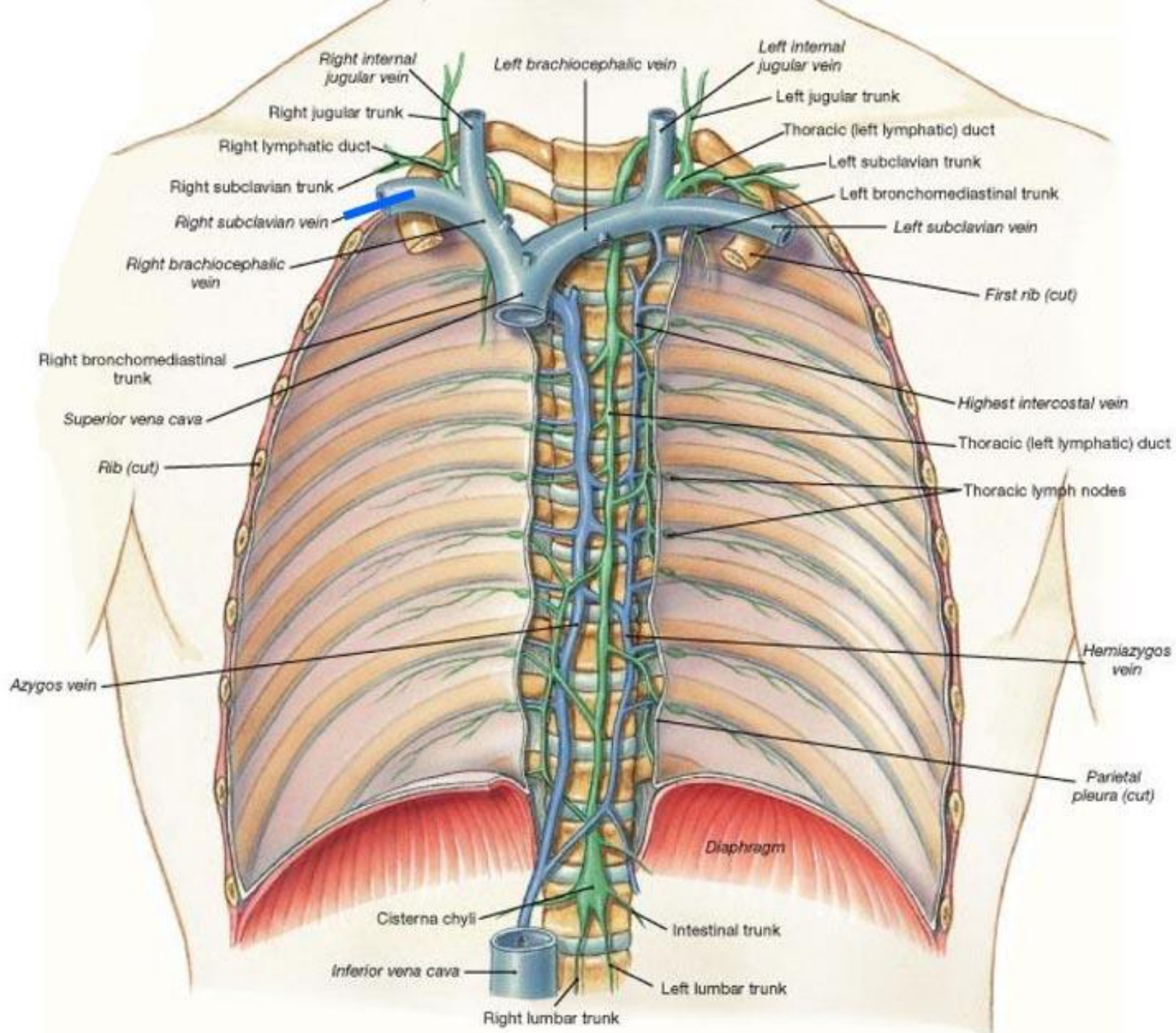
- pars cervicalis

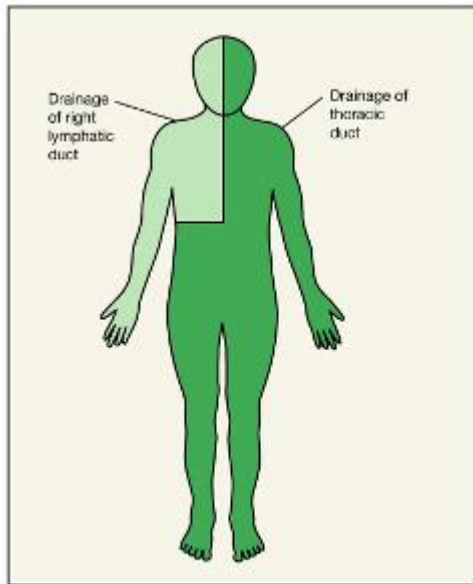
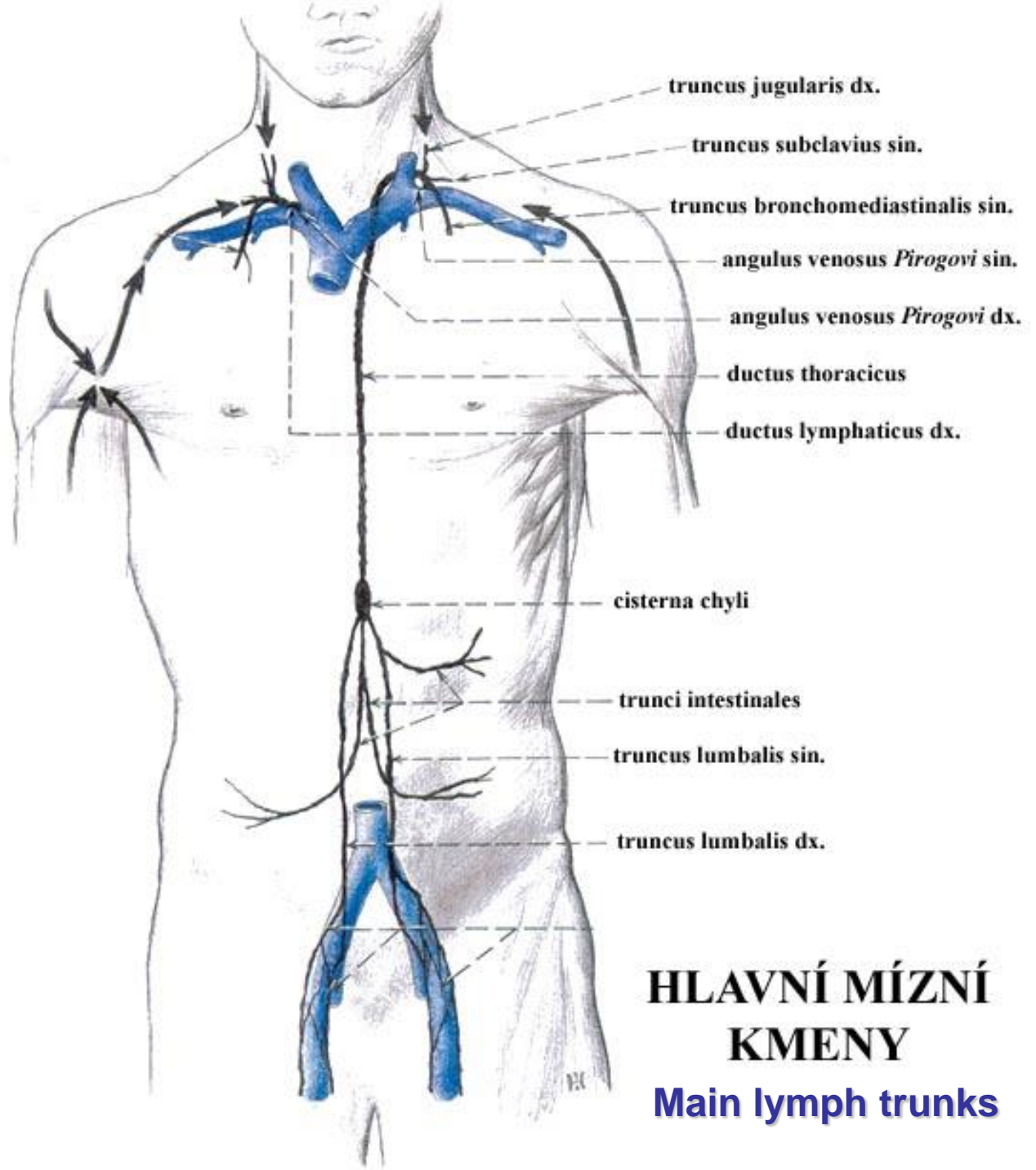
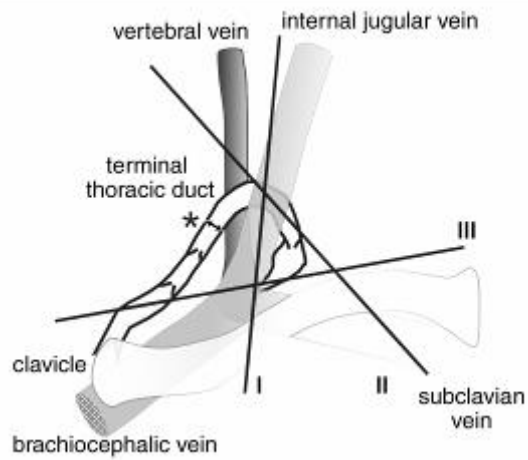
- arcus d.t.



- **ductus lymphaticus dexter**

9 lymph trunks

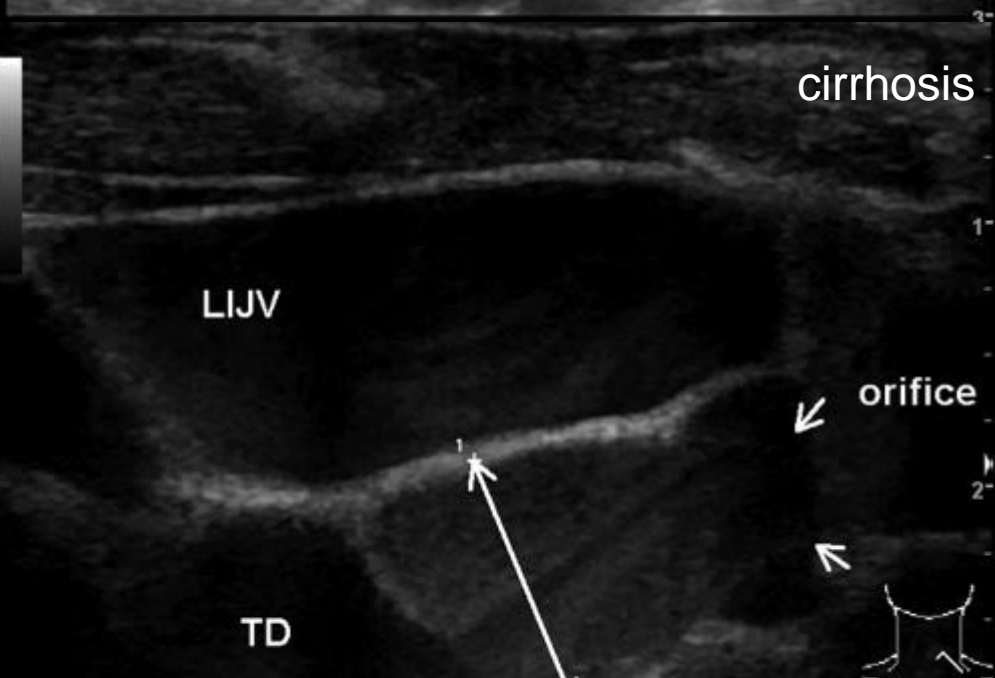
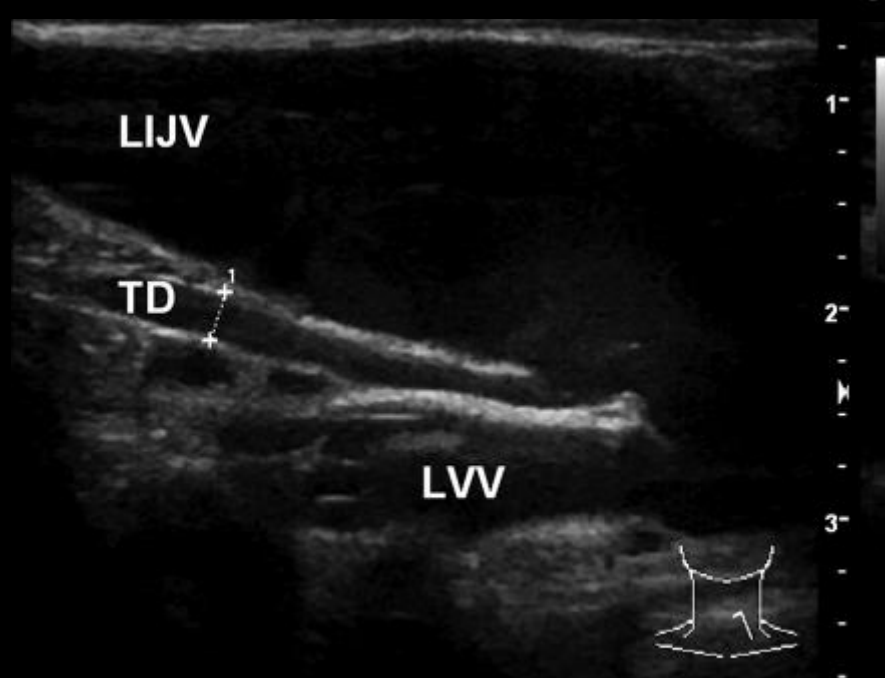
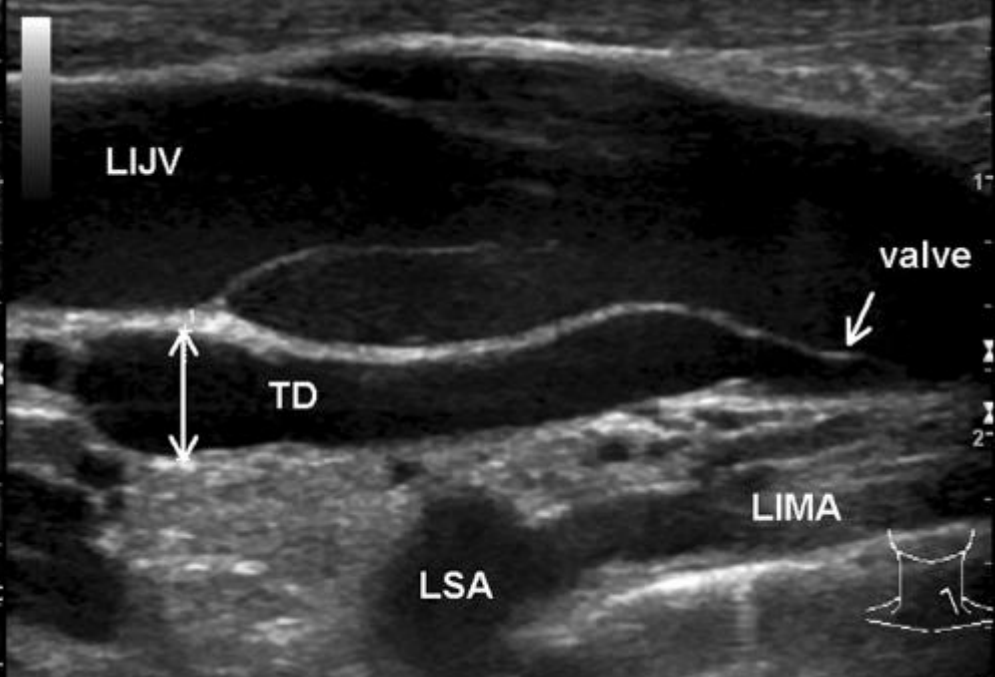
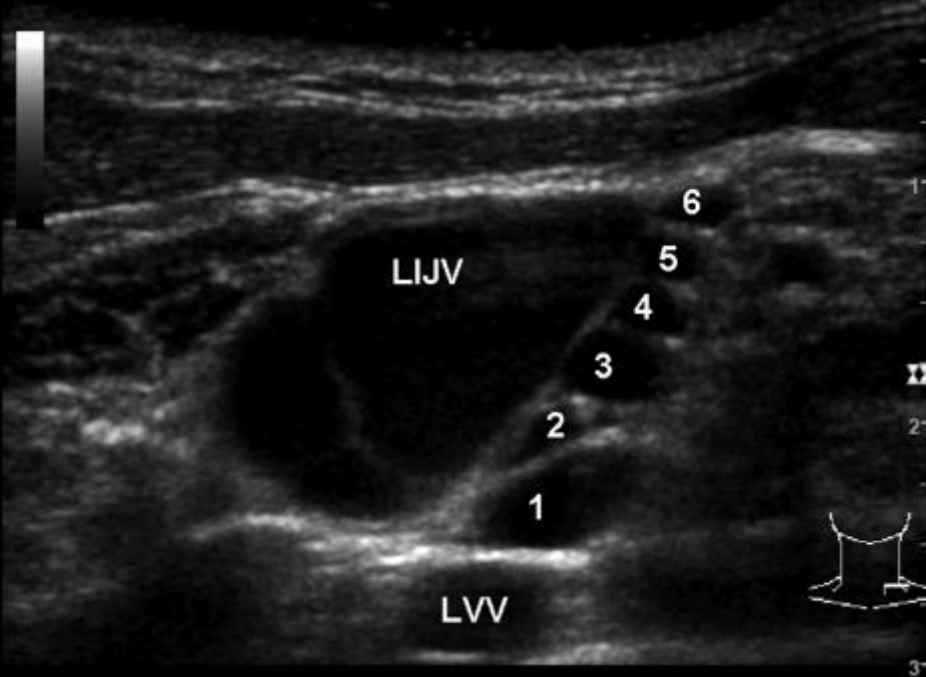




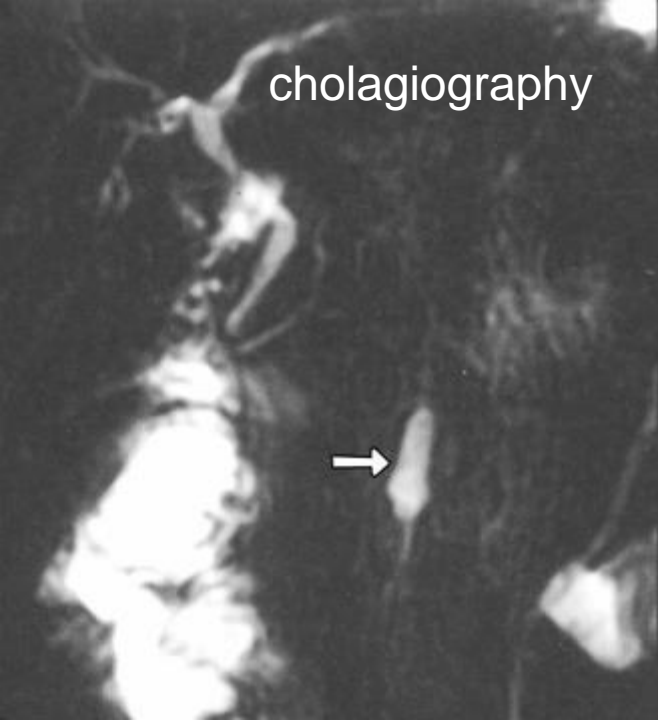
(a)

HLAVNÍ MÍZNÍ KMENY

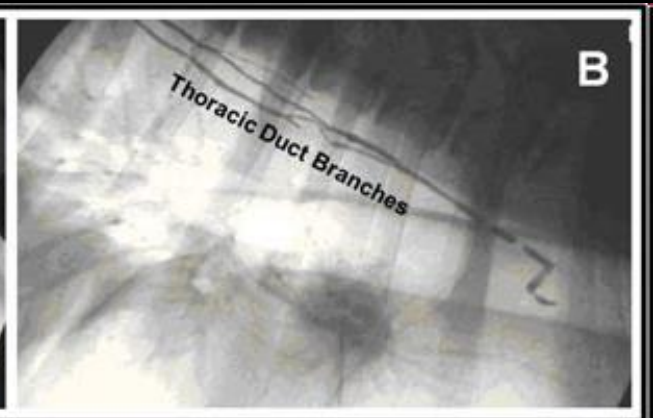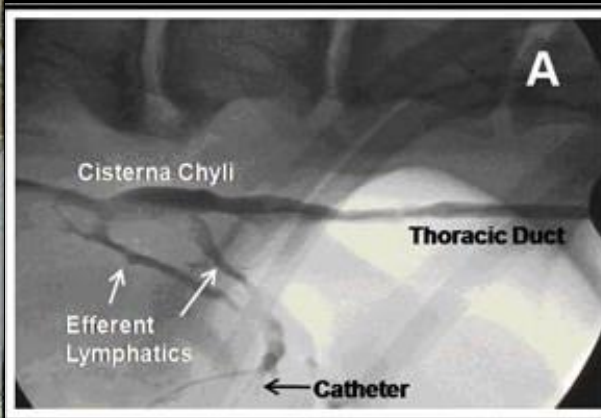
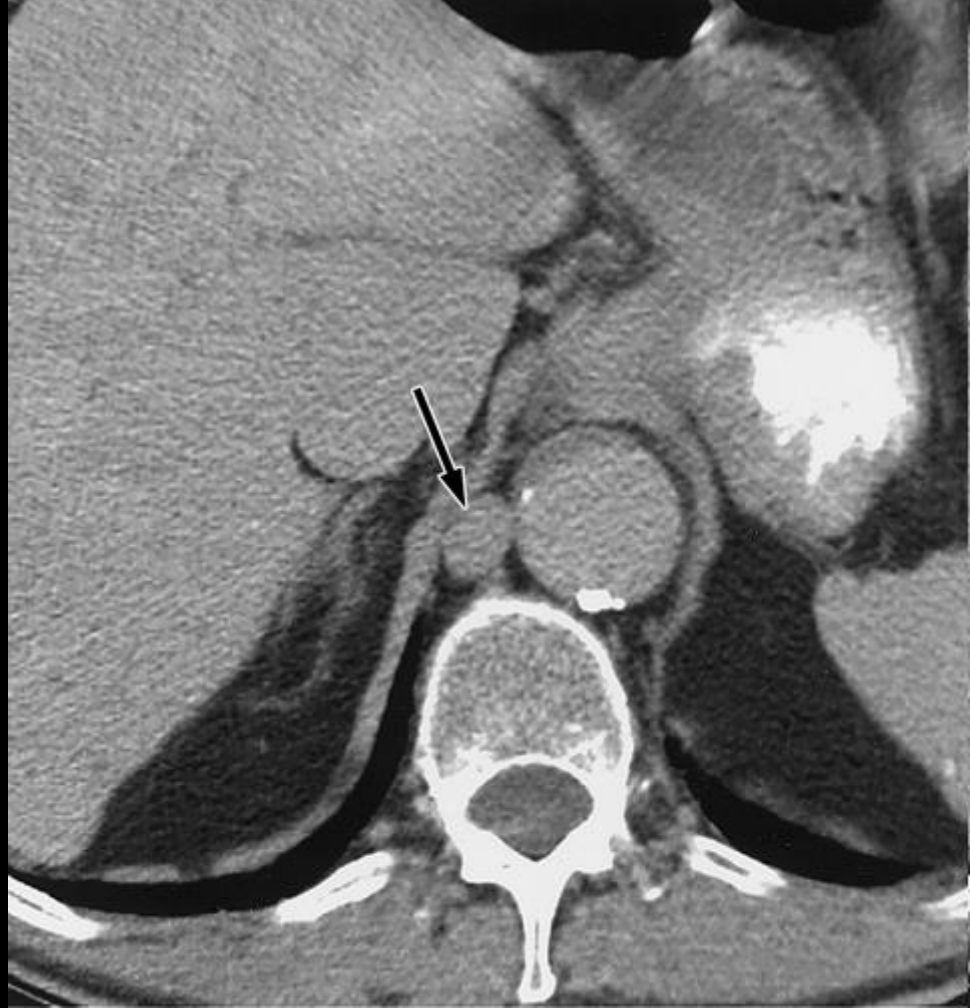Main lymph trunks



Ductus thoracicus et angulus venosus

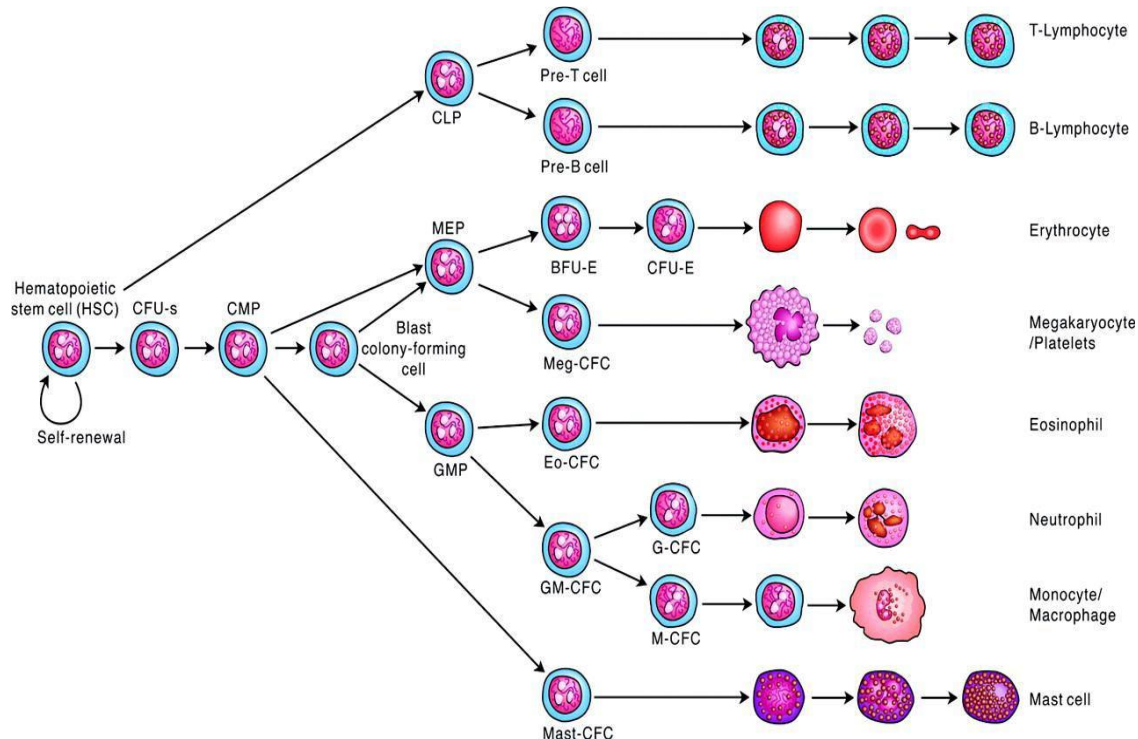


CISTERNA CHYLI



Lymphatic tissue

- morphological substrate for the majority of immune reactions
- cells derived from the pluripotent haematopoietic stem in bone marrow



Functions of cells

- **neutrophil leukocytes** and **monocytes/macrophages** participate in innate immune response
- **lymphocytes (T and B)** are involved in the acquired immunity
- antigen-presenting **dendritic cells** care for specific immune response, being located in epithelia
 - they migrate to lymph nodes where they „teach“ the T-lymphocytes
 - lymphocytes activated by antigen-presenting cells participate in anti-infectious immunity and in anti-cancer immunological surveillance

Lymph organs

= acquired (adaptive, specific) immunity

- primary (central) lymph organs

- *thymus*
- bone marrow (*medulla ossium*)
- *bursa Fabricii* – birds

function: cell production de novo, differentiation and maturation of immunocompetent cells

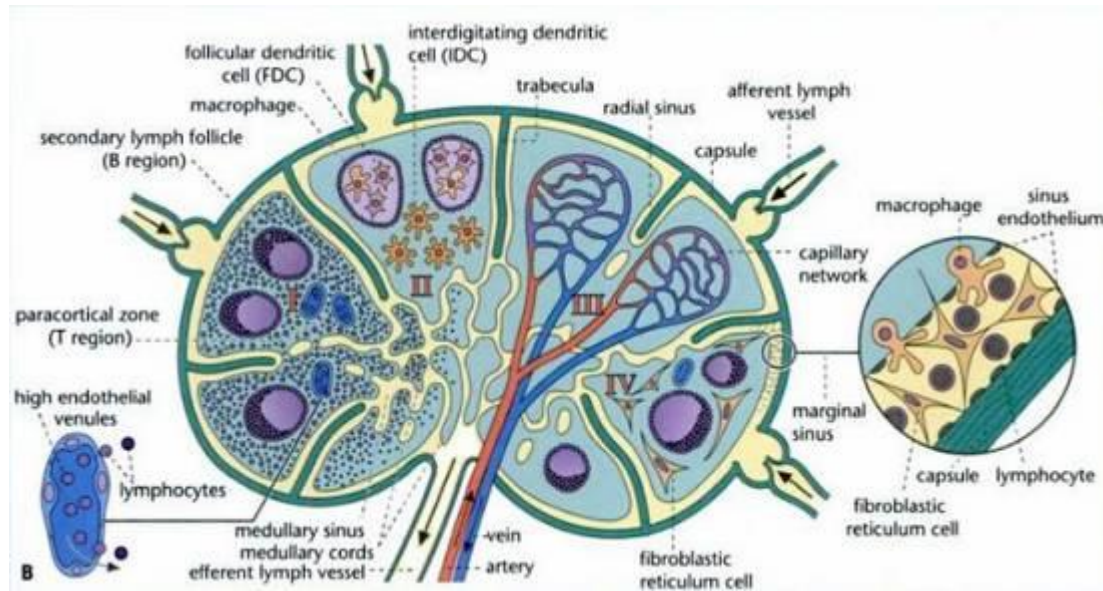
- secondary (peripheral) lymph organs

- spleen = *splen (lien)*
- **lymph nodes = *nodi lymphoidei***
- **tonsils = *tonsillae***
- **lymph nodules = *noduli lymphoidei***

function: contact with antigen-presenting cells, production of mature lymphocytes

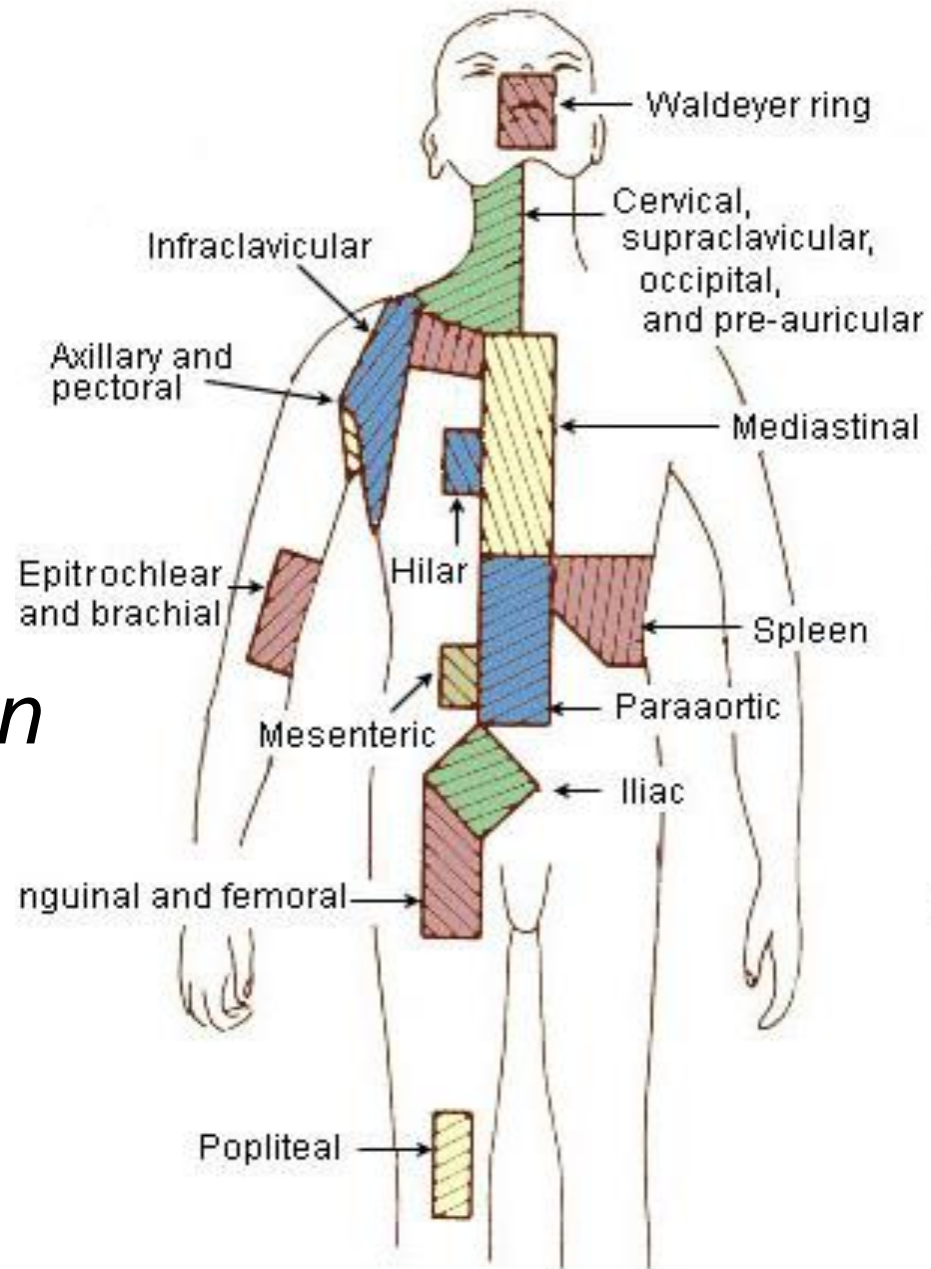
Lymph nodes

- lymph filtration
- antigen presentation
- activation, differentiation and proliferation (production of mature B- and T-lymphocytes)
- lymphocytes, macrophages, plasmatic cells



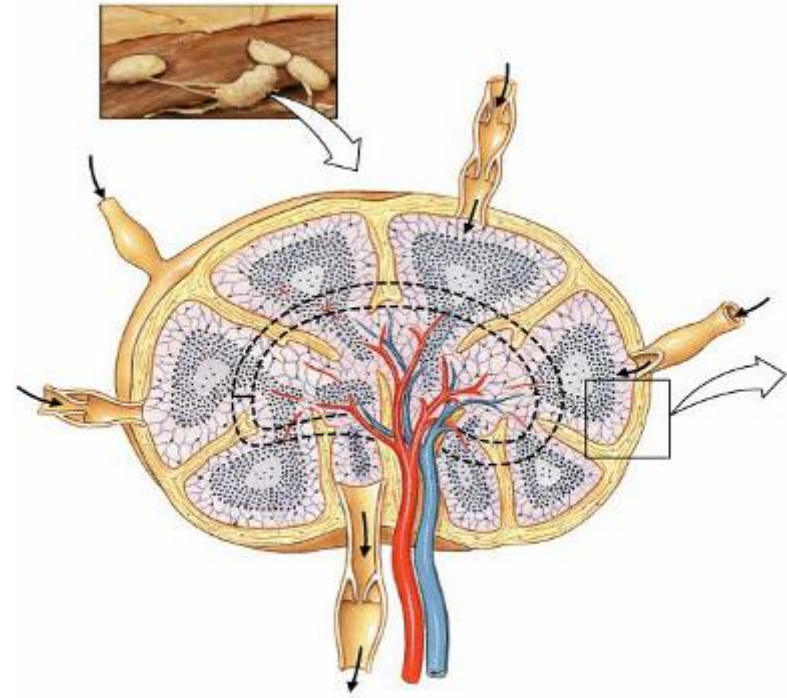
Lymph node

- **nodus lymphoideus**
(nodus lymphaticus;
lymphonodus)
- about 500 in body
- \varnothing 1-25 mm
- *swelling in inflammation
(painful)*
- *metastasis catching
(inpainful swelling)*
- „lymphadenopathy“

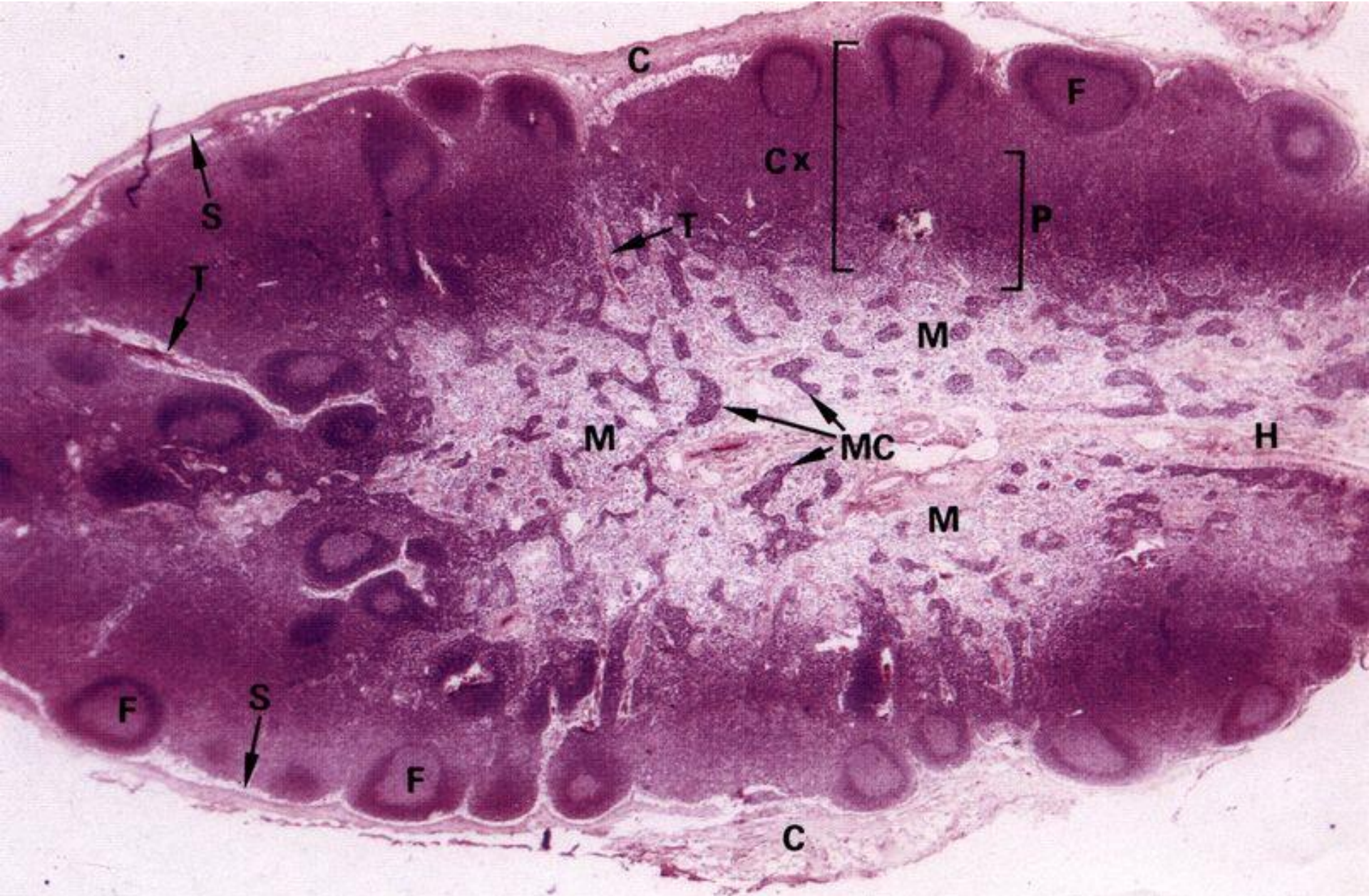


Lymph node

- capsula → trabeculae
- hilum
- cortex (+ paracortex)
 - reticulin network
- medulla
- convex part – „afferent“ (more afferent lymph vessels)
- concave hilum – „efferent“ (one efferent lymph vessel + blood vessels)



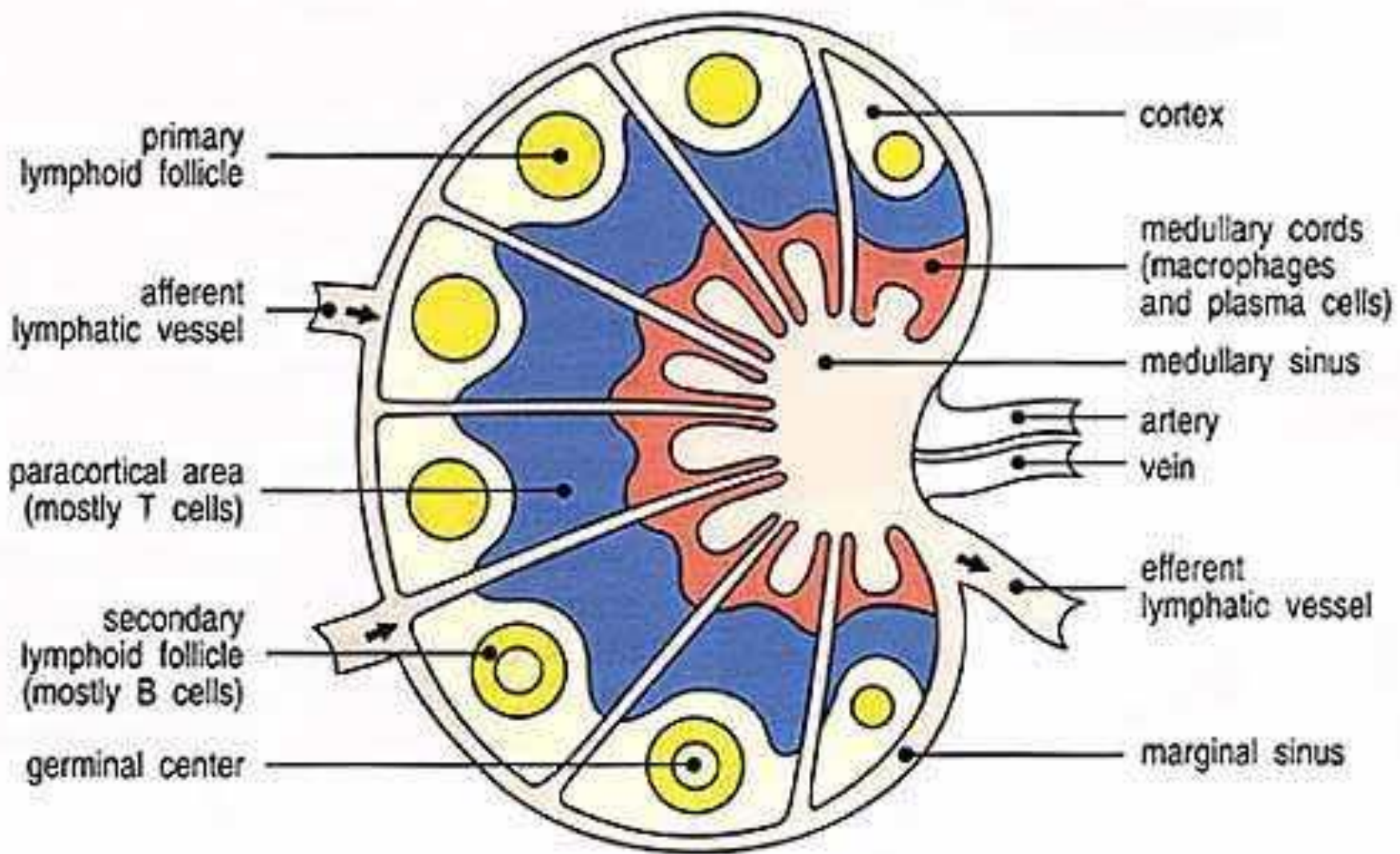
Lymph node - HE (x 8)



Lymph node – cortex

- outer cortical zone (**cortex**)
 - sinus subcapsularis
 - lymph nodules (*noduli lymphoidei*)
 - sinus internodulares
 - ***B-lymphocytes***
- inner cortical zone (**paracortex**)
 - ***T-lymphocytes*** (*CD4, CD8*)
 - *dendritic cells*
 - no lymph nodules
 - venulae altoendotheliales
 - high endothelium

The lymph node

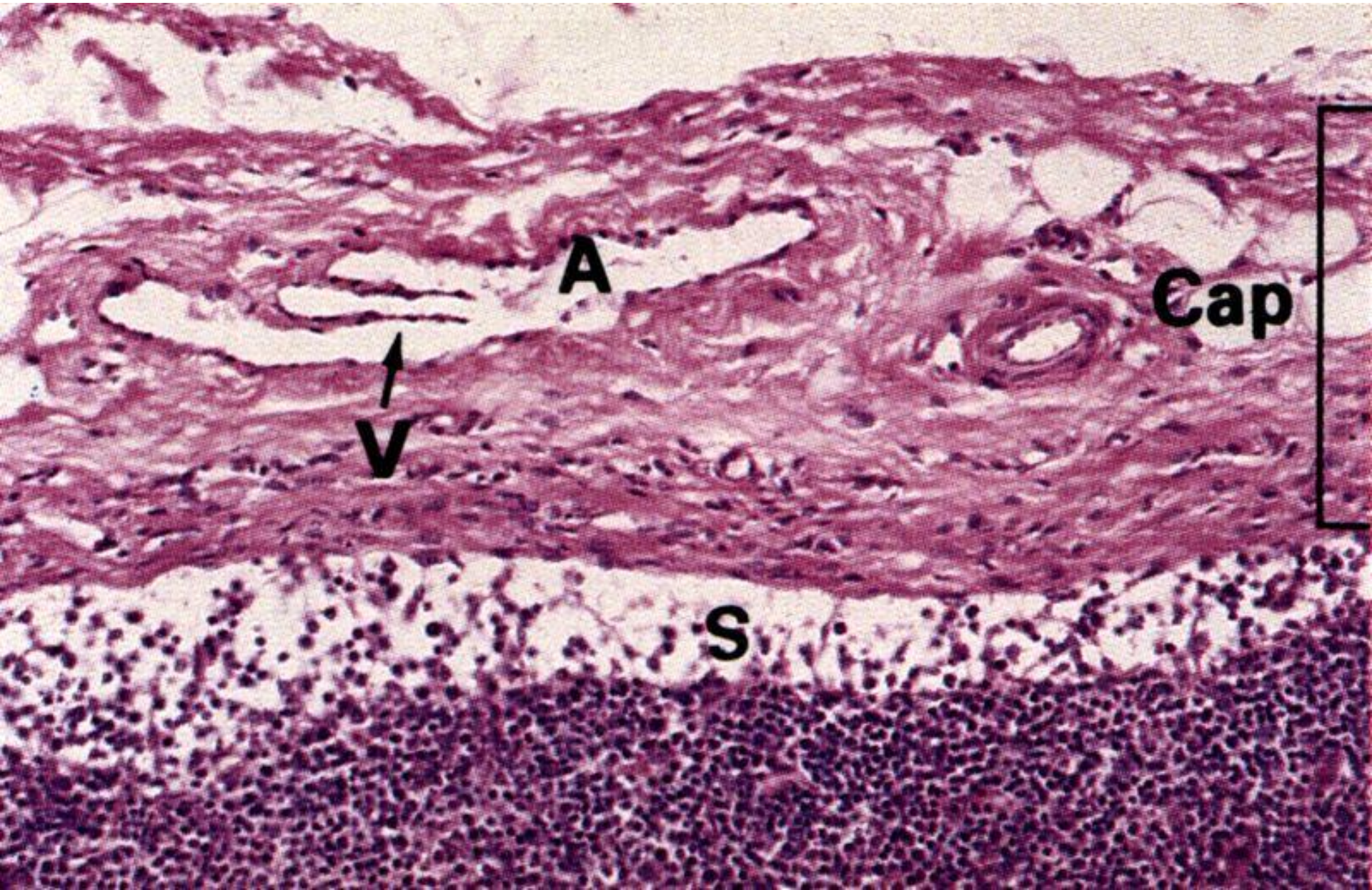


Lymph node – cortex: cells and zones

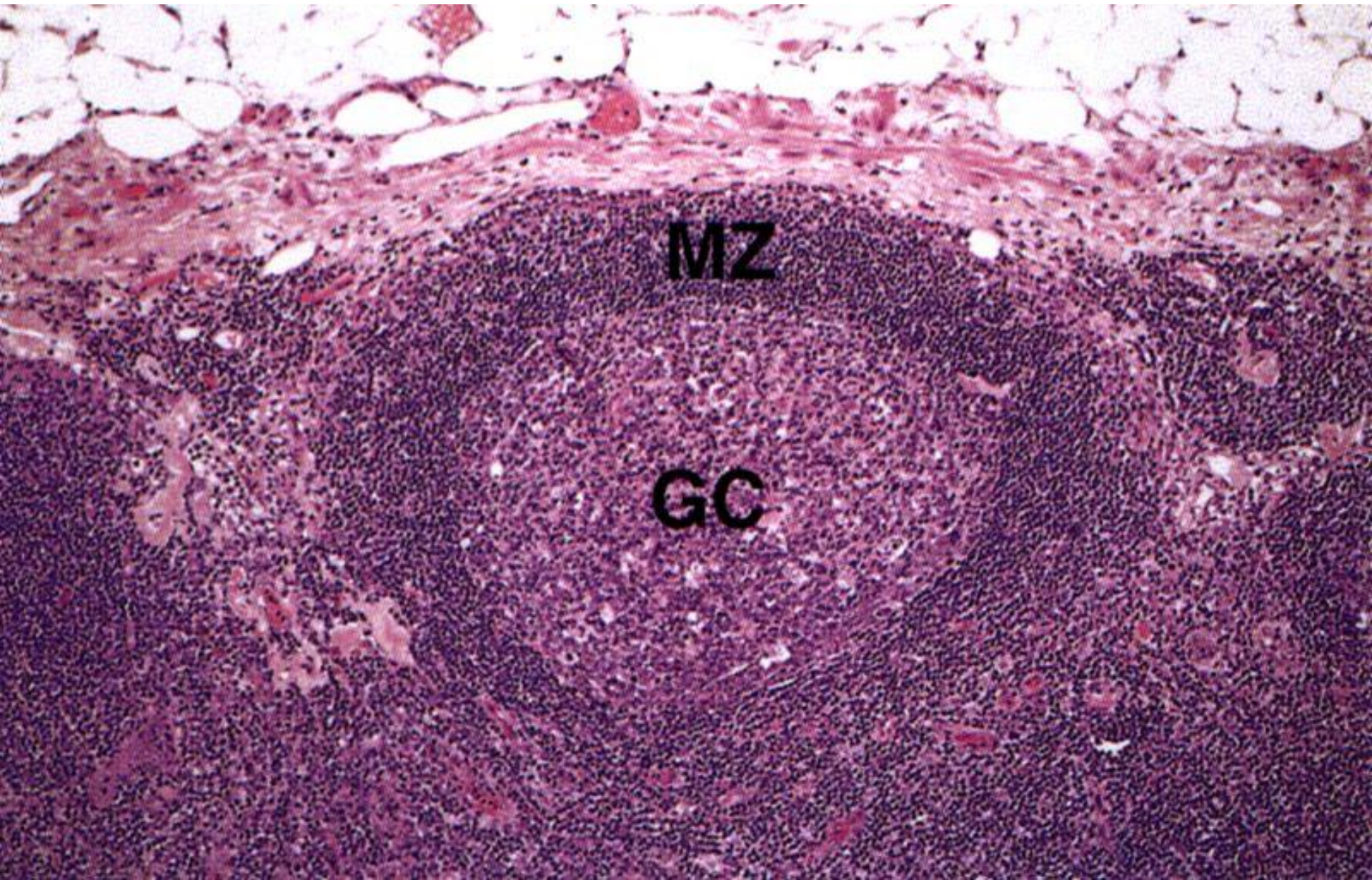
noduli lymphoidei

- B-lymphocytes
- follicular dendritic cells (FDC)
- primary nodule
 - small „naive“ B-lymphocytes
- secondary nodule
 - germinal center: antigen-stimulated B-lymphocytes (large, less deeply staining, more rapidly dividing)
 - dark zone: centroblasts
 - light zone: centrocytes
 - other cells: T-lymphocytes (help maturation of B-lymphocytes), macrophages (phagocytic apoptotic cells)
- mantle zone
 - produced as surrounding cells are marginalized by rapidly growing germinal centre
 - naive B-lymphocytes, T_H-lymphocytes, FDC, macrophages

Lymph node - HE (x 128)



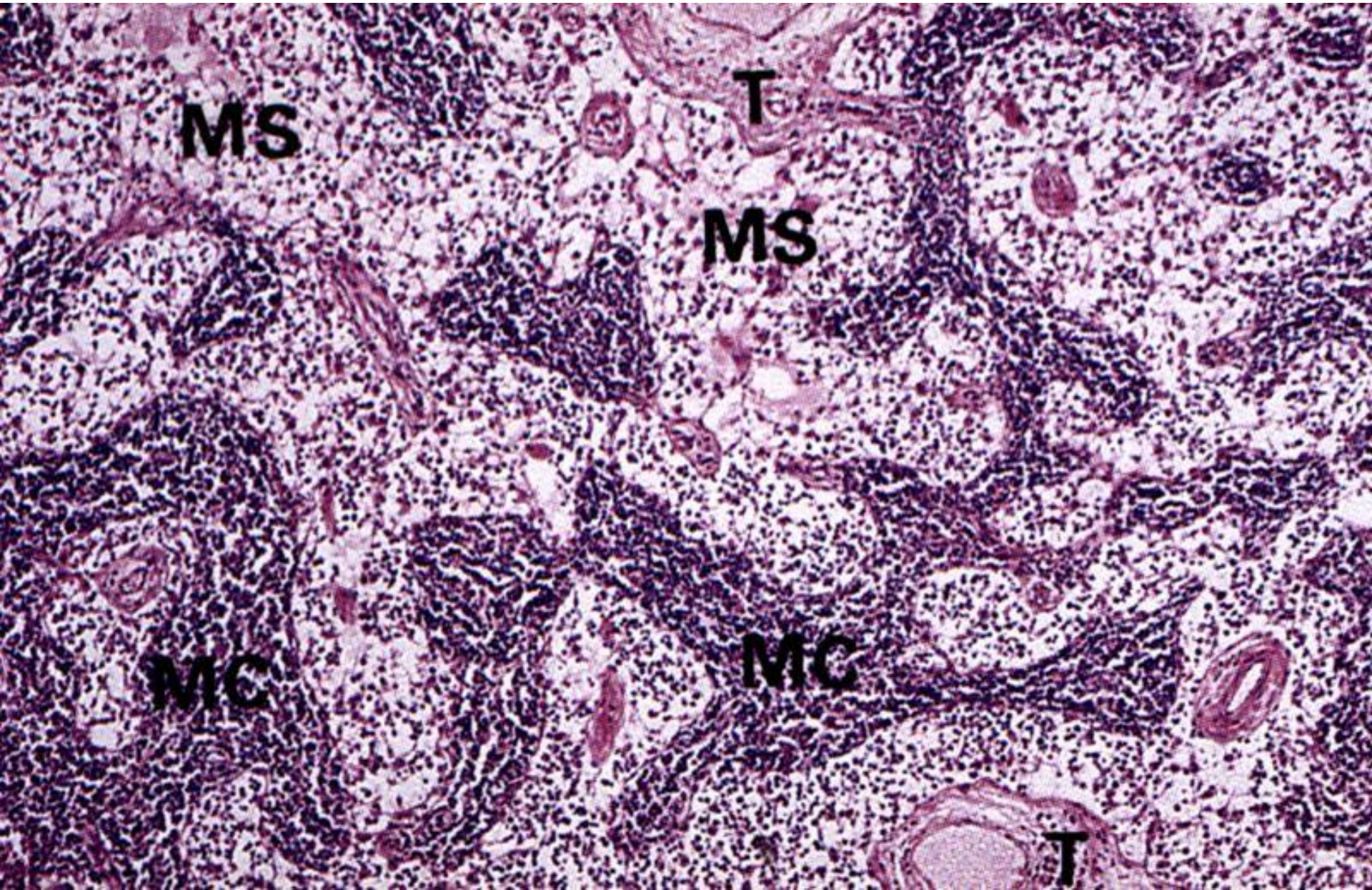
Lymph node - HE (x 50)



Lymph node – medulla

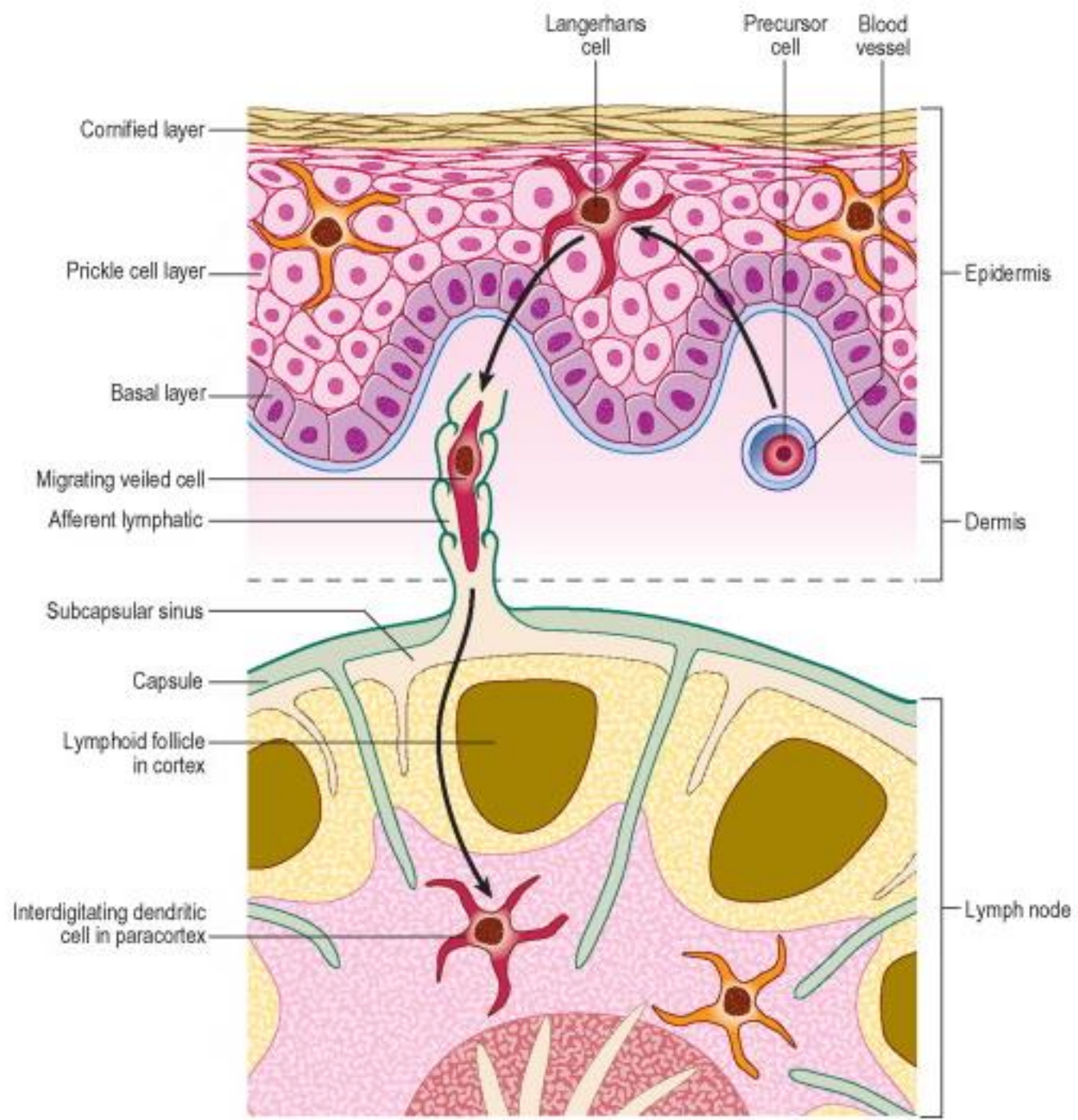
- chordae medullares (medullar cords)
 - processes of cortical lymphoid tissue
 - many *B-lymphocytes and plasmatic cells*
 - *dendritic cells (antigen-presenting cells)*
- sinus lymphaticus medullaris
 - lined with *reticular cells* and *macrophages*
 - reticular fibers cross sinuses – web

Lymph node - HE (x 20)

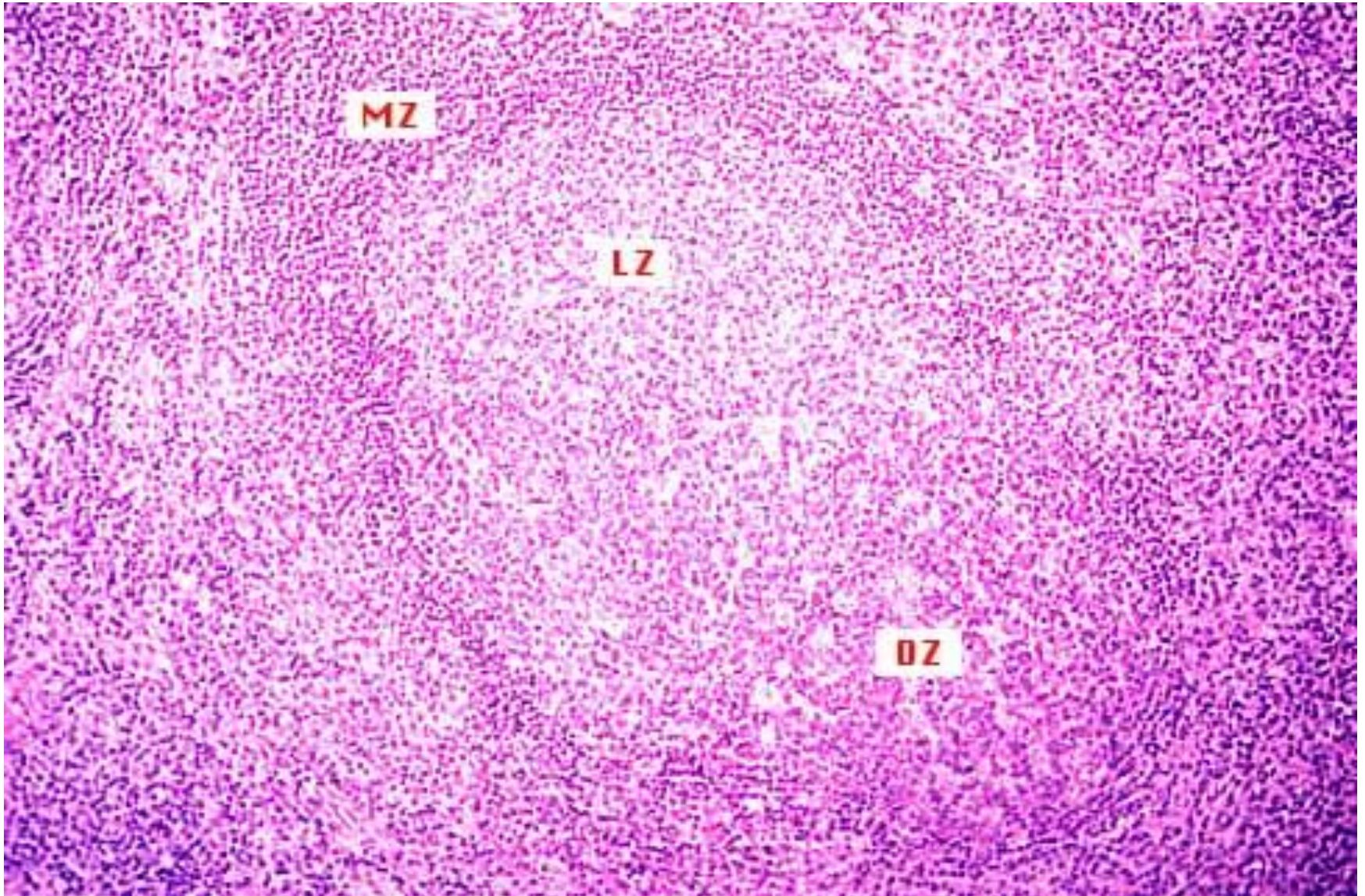


Lymph node – blood and lymph flow

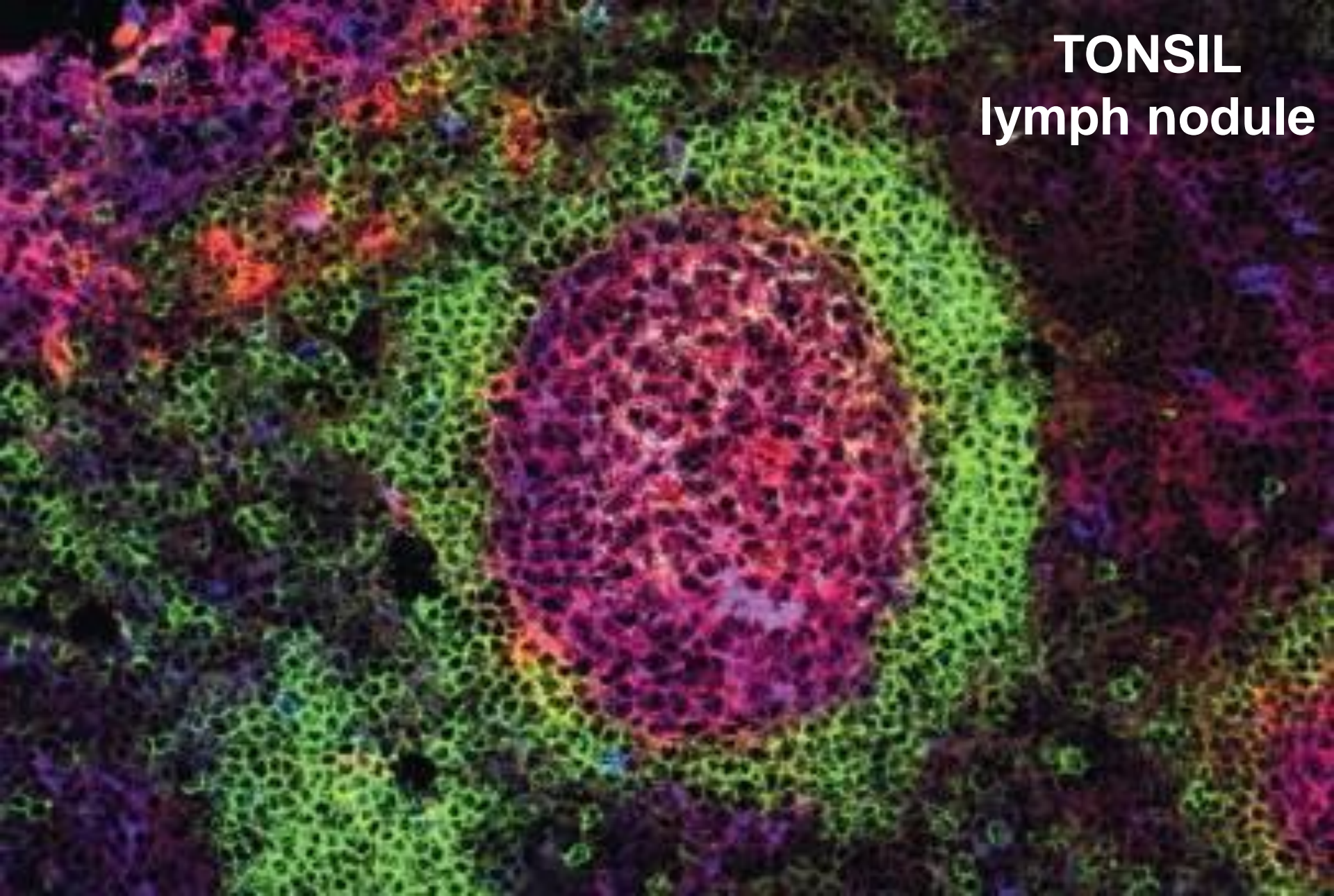
- **vessels:** „naive“ lymphocytes from primary lymphoid organs
- **vasa lymphatica afferentia:** lymph with antigenes and antigen-presenting cells (APC) → sinus subcapsularis → sinus internodulares (radiate from capsule into medulla) → sinus lymphaticus medullaris → vas lymphaticum efferens
- **vas lymphaticum efferens:** mature effector cells



Lymph nodule – germinal center



TONSIL
lymph nodule



Lymph nodes – distribution

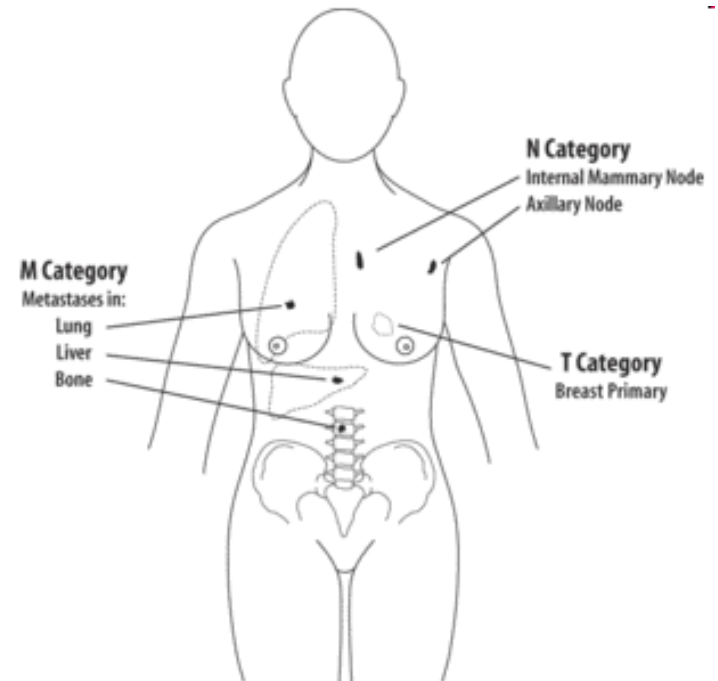

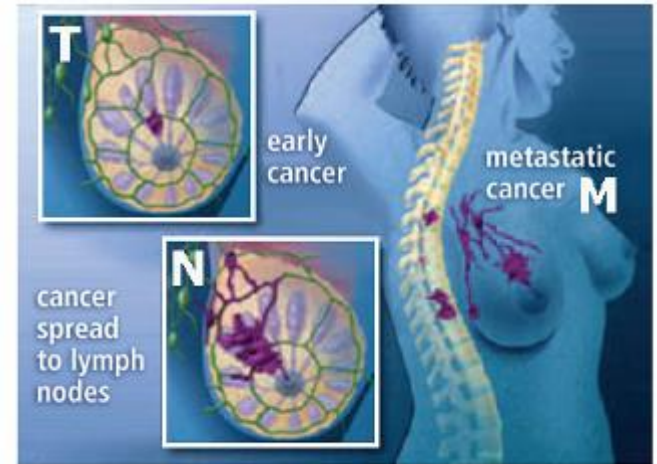
- tributary regions
- regional lymph nodes
- sentinel lymph node

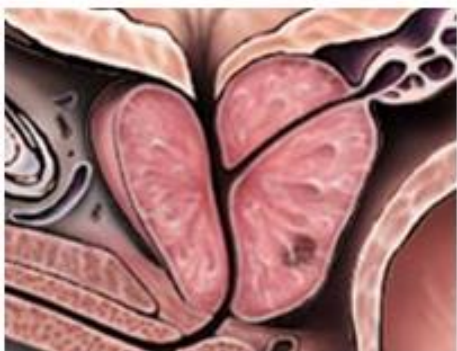- *inflammation – painful swelling*
- *tumour – unpainful swelling*
- *lymphedema (elephantiasis)*

TNM classification

TNM classification

- tumor
- nodus
- metastasis
 - contact (direct spreading)
 - *lymphogenous*
 - *haematogenous*



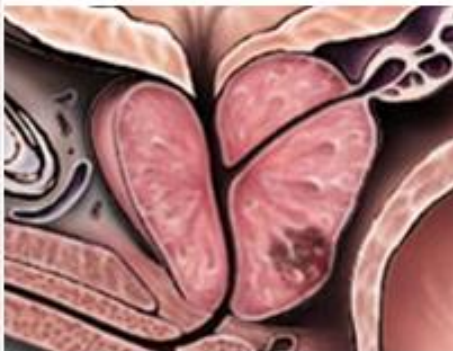T1

T1 Clinically inapparent; tumor not palpable or visible by imaging

T1a Incidental finding during transurethral resection of prostate; < 5% of tissue resected

T1b Incidental finding during transurethral resection of prostate; > 5% of tissue resected

T1c Tumor identified by needle biopsy (e.g. because of elevated PSA)

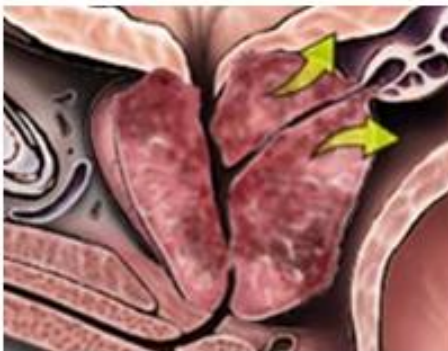T2

T2 Tumor confined within prostate (palpable or visible on TRUS)

T2a Involves half of a lobe or less

T2b Involves more than half of a lobe one lobe but not both lobes

T2c Tumor involves both lobes

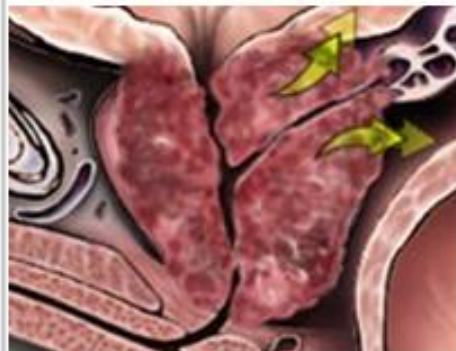T3

T3 Tumor extends through prostatic capsule, bladder neck or seminal capsule

T3a Unilateral extracapsular extension

T3b Bilateral extracapsular extension

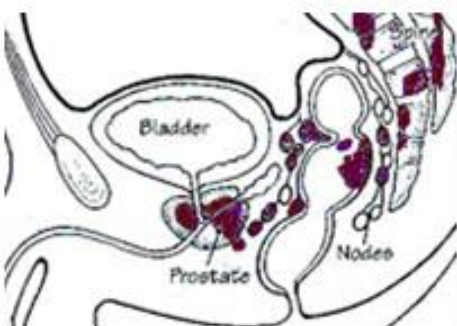
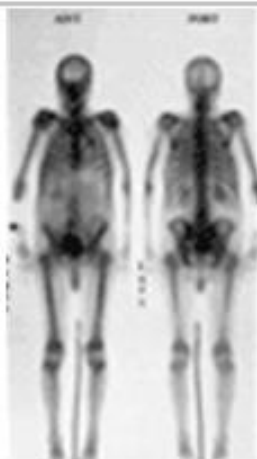
T3c Tumor invades seminal vesicle(s)

T4

T4 The tumor has spread or attached to tissues next to the prostate (other than the seminal vesicles).

T4a The tumor has spread to the neck of the bladder, the external sphincter (muscles that help control urination), or the rectum.

T4b The tumor has spread to the floor and/or the wall of the pelvis.

N0-3**M0-1**

N0 Cancer has not spread to any lymph nodes.

N1 Cancer has spread to a single regional lymph node (inside the pelvis) and is not larger than 2 centimeters

N2 Cancer has spread to one or more regional lymph nodes and is larger than 2 centimeters (3/4 inch), but not larger than 5 centimeters

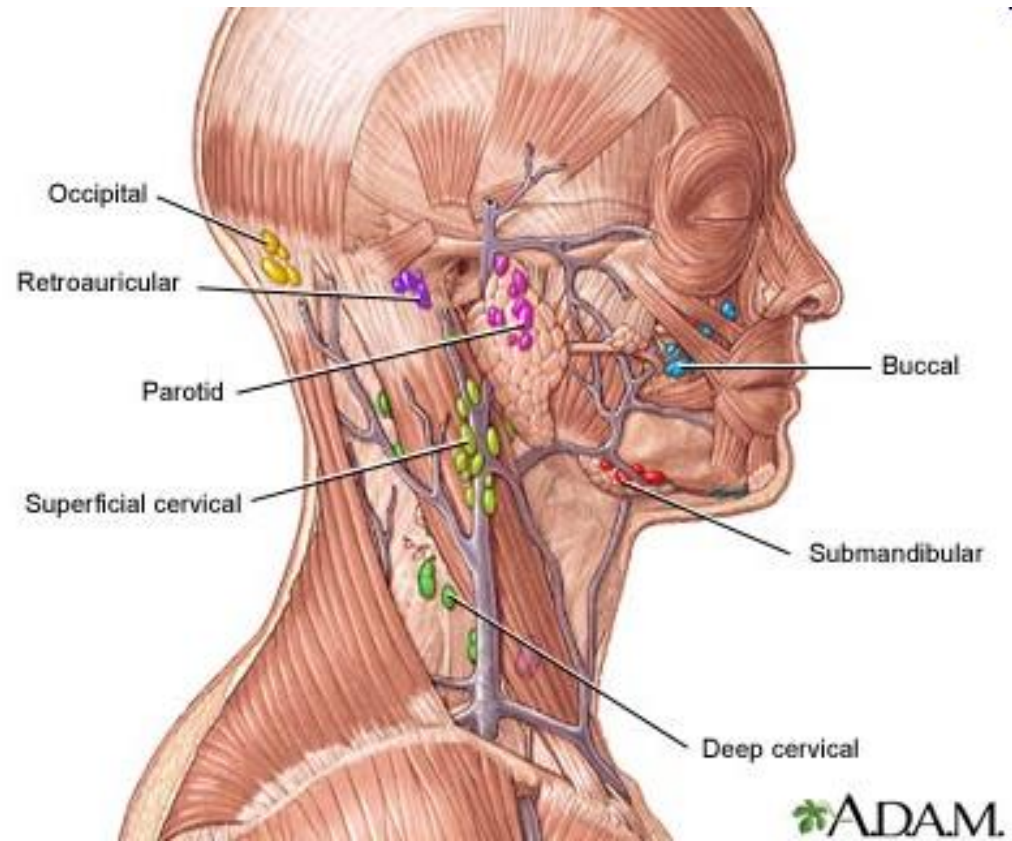
N3: Cancer has spread to a lymph node and is larger than 5 centimeters

M0: The cancer has not metastasized (spread) beyond the regional lymph nodes

M1: The cancer has metastasized to distant lymph nodes (outside of the pelvis), bones, or other distant organs such as lungs, liver, or brain

Head

- n.l. occipitales
 - *rubella*
 - *toxoplasmosis*
- n.l. mastoidei
- n.l. parotidei
- n.l. faciales



n.l. cervicales

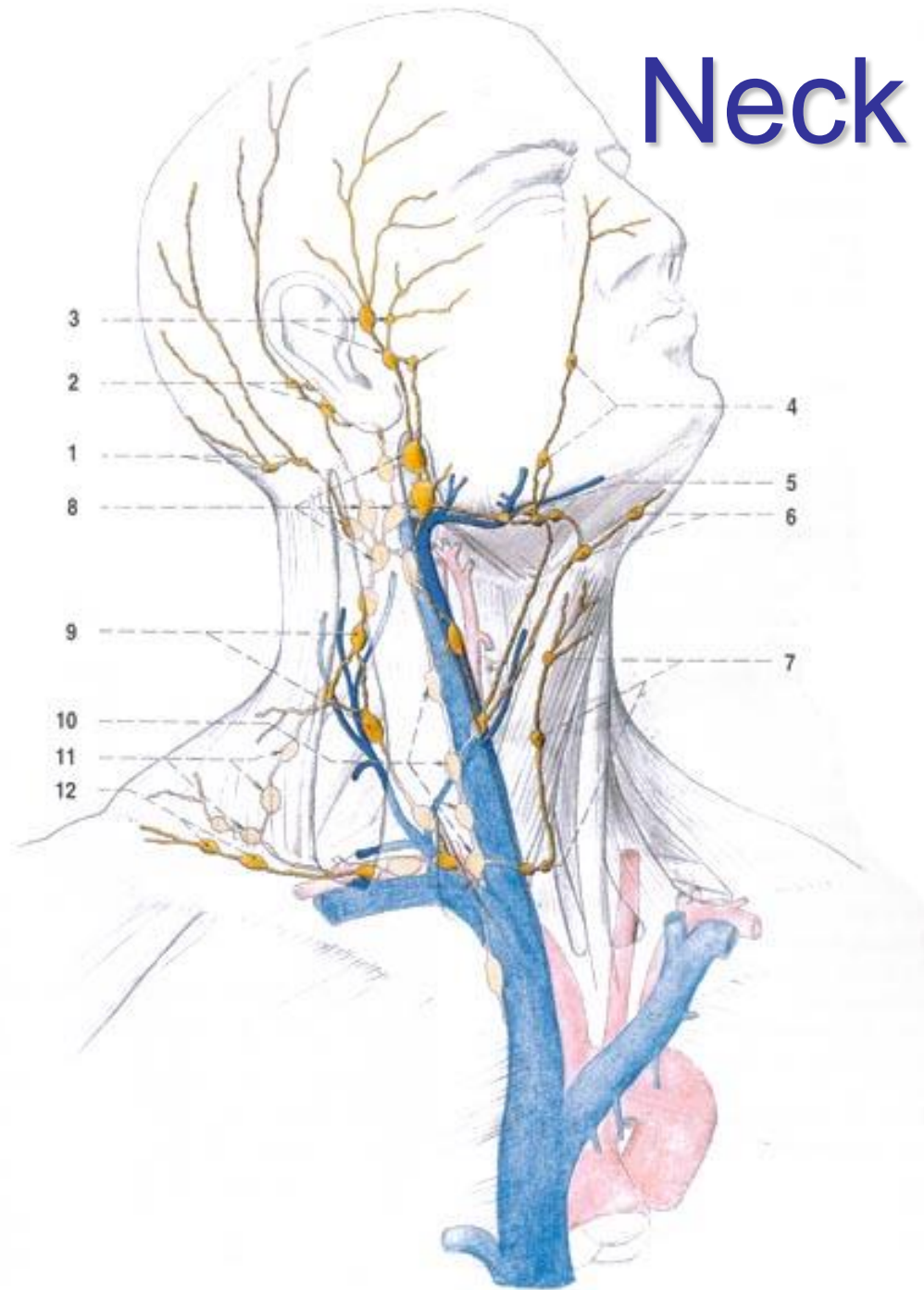
- anteriores
- laterales

n.l.c. profundi

- n.l. jugulodigastricus
- n.l. juguloomoioideus

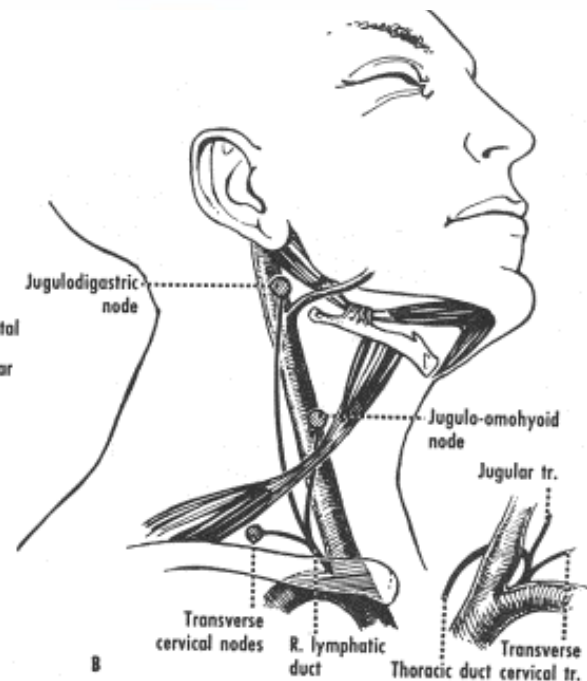
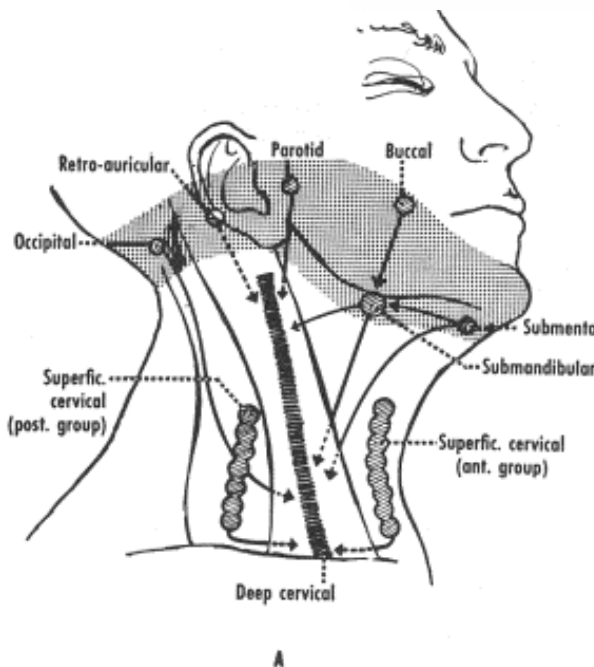
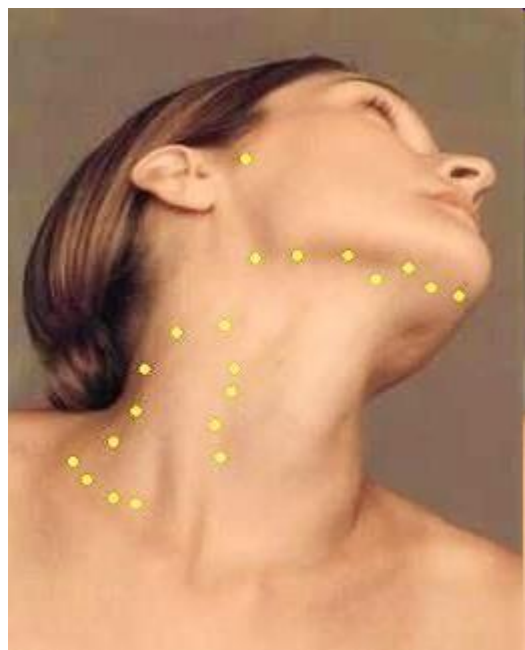
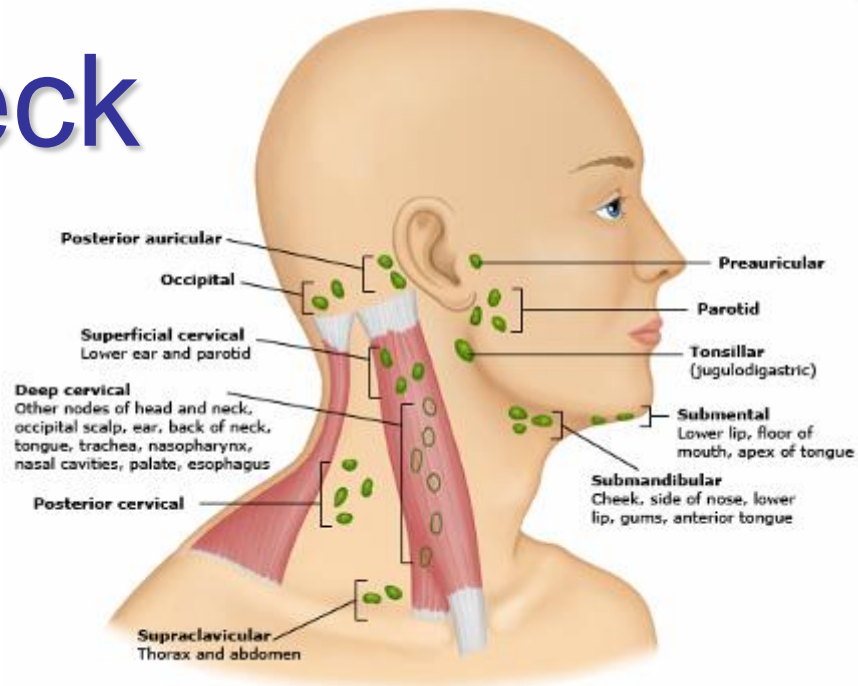
n.l.c. superficiales

- chain along v. jugularis int. (= n.l. cervicales laterales profundi)
- chain along n. XI (n.l. accessorii)
- n.l. supraclaviculares



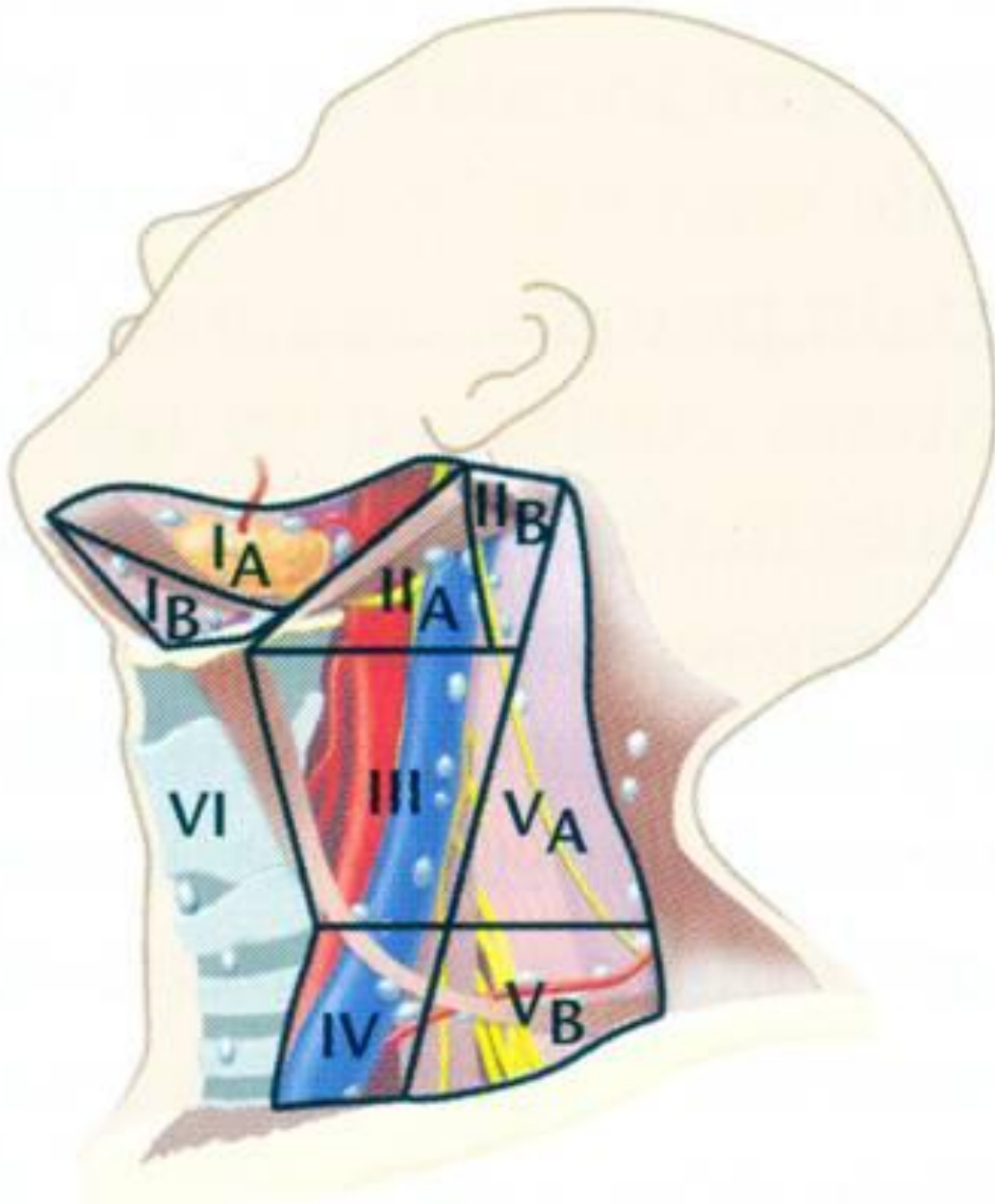
- n.l. submentales
- n.l. submandibulares
- n.l. pretracheales
- n.l. paratracheales
- n.l. retropharyngei
 - Rouvière's node
 - children, mesotitis

Neck

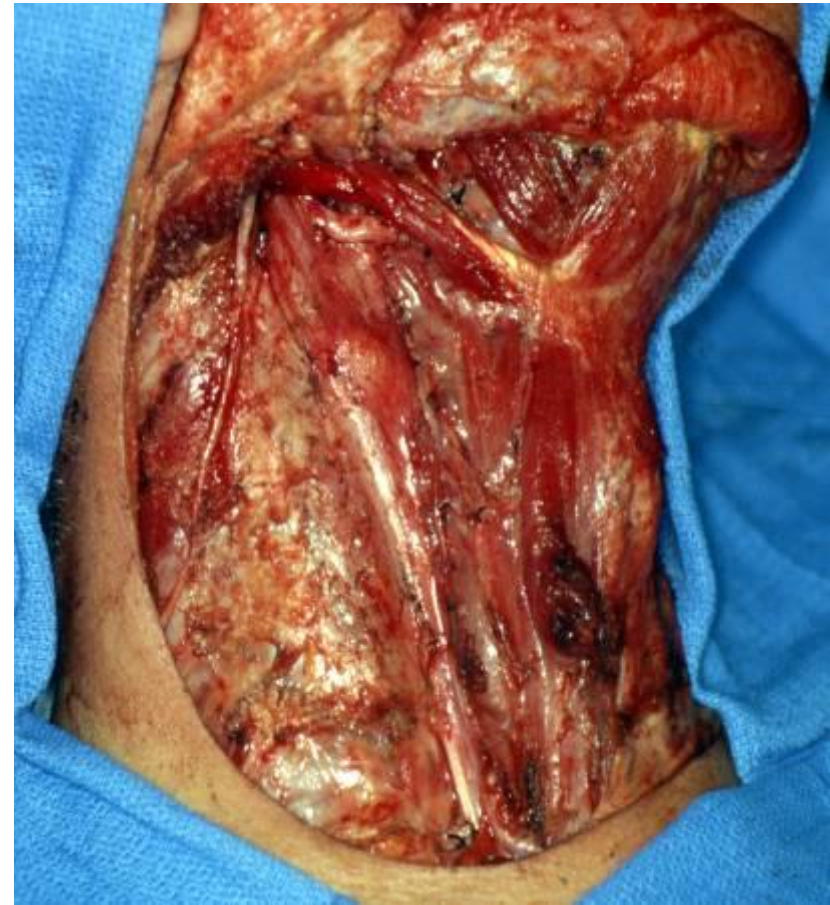

Clinical classification of cervical lymph nodes

6 quadrants



Robbins, 2001



6 levels (quadrants) of cervical lymph nodes

Ia: lower lip, mouth, anterior 1/3 of the tongue, anterior 1/3 of the mandibular alveolar ridge

Ib: mouth, nasal cavities, skin and soft tissues of the ipsilateral midface

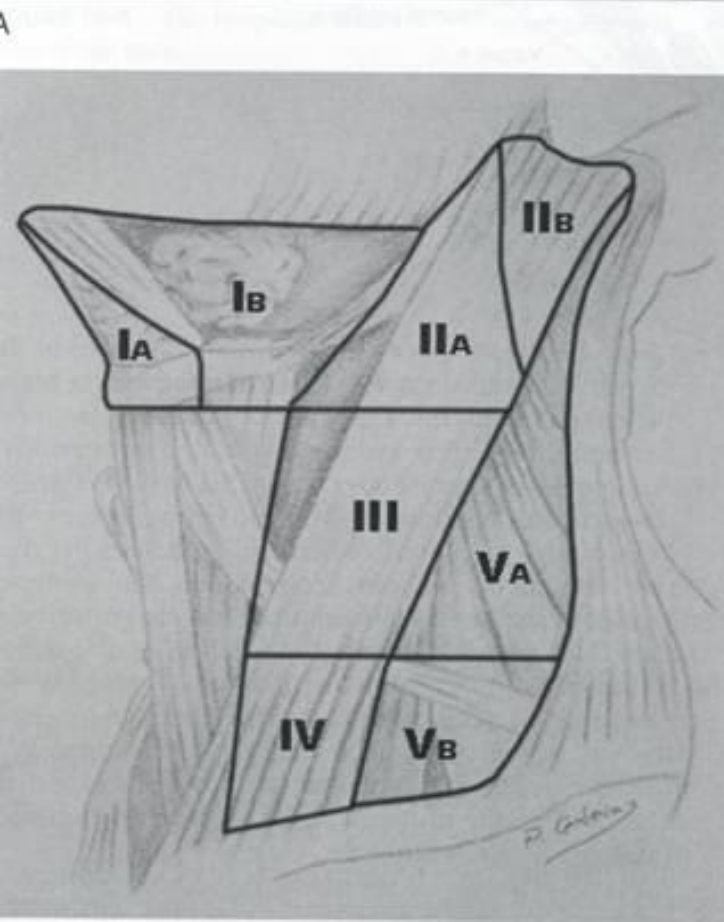
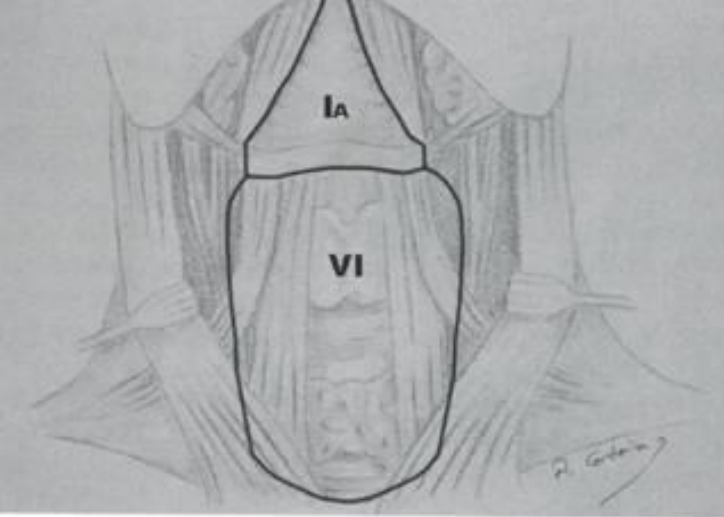
II: mouth, nasal cavities, nasopharynx, oropharynx, hypopharynx, larynx, parotid glands

III: mouth, nasopharynx, oropharynx, hypopharynx, larynx

IV: hypopharynx, larynx, cervical oesophagus

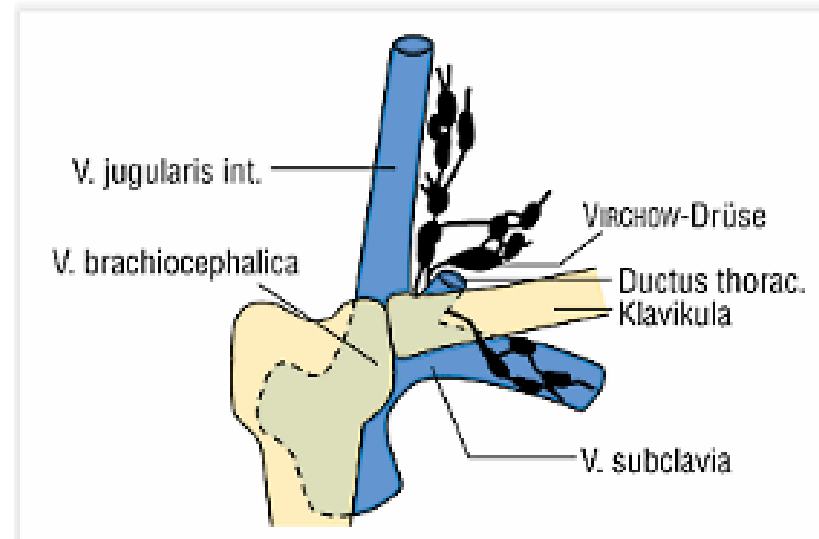
V: nasopharynx + oropharynx

VI: thyroid gland, larynx, cervical oesophagus



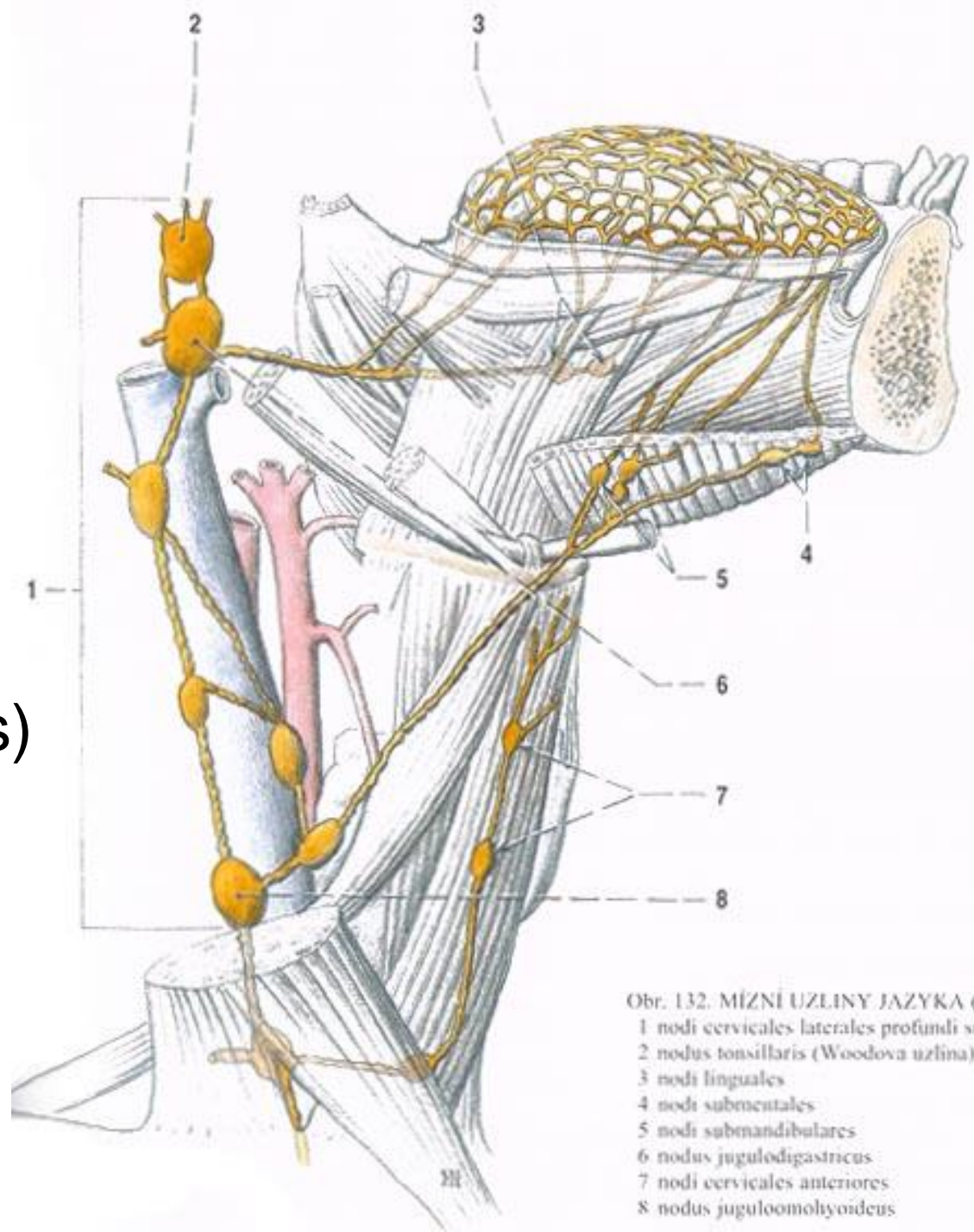
Virchow-Troisier

- n.l. supraclaviculares sinistri
- enlarged in:
 - tumor of stomach (70%)
 - tumor of left breast
 - tumor of lung
 - tumor of large intestine
 - tumor of neck on the left
 - primary lymphoma



Tongue

- **4 directions**
- n.l. submentales (apex)
- n.l. submandibulares (corpus: margines)
- n.l. cervicales profundi (corpus: center + radix)
- contralaterally across midline

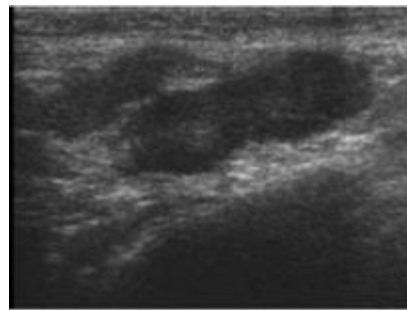
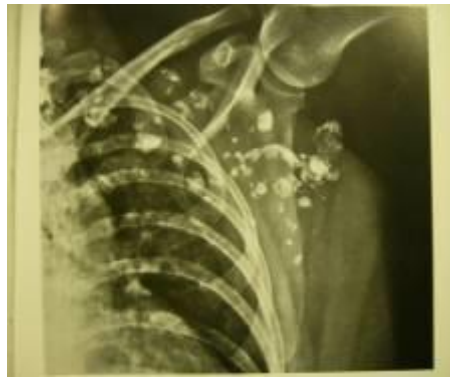

Axilla

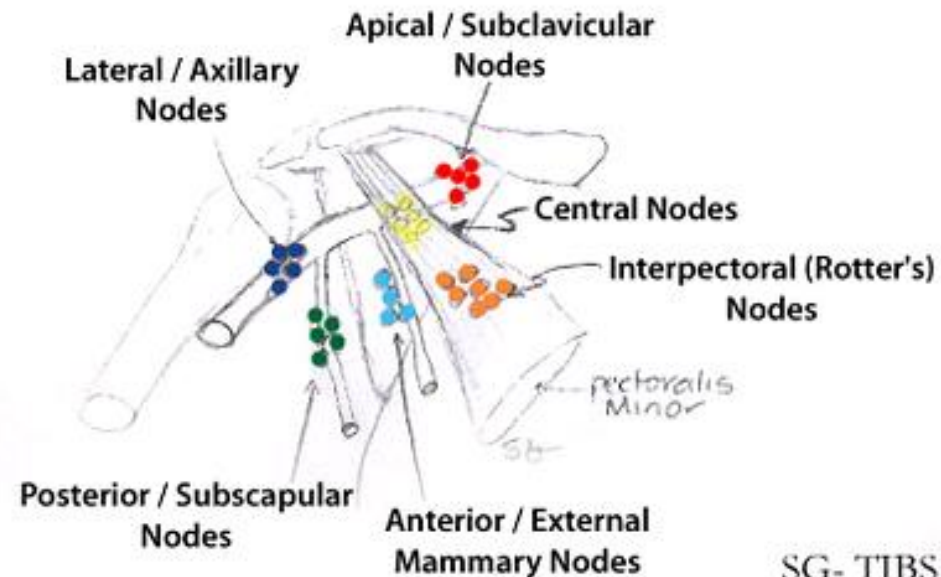
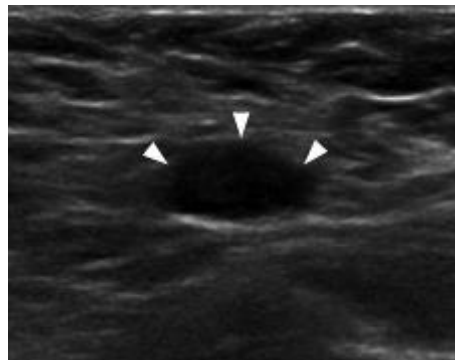
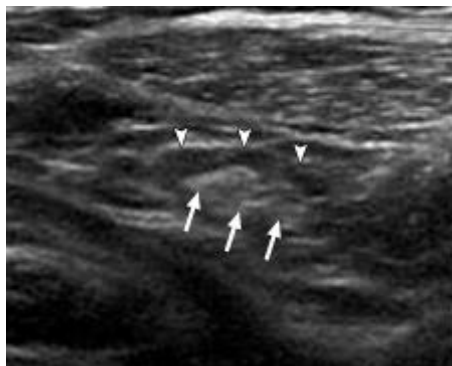
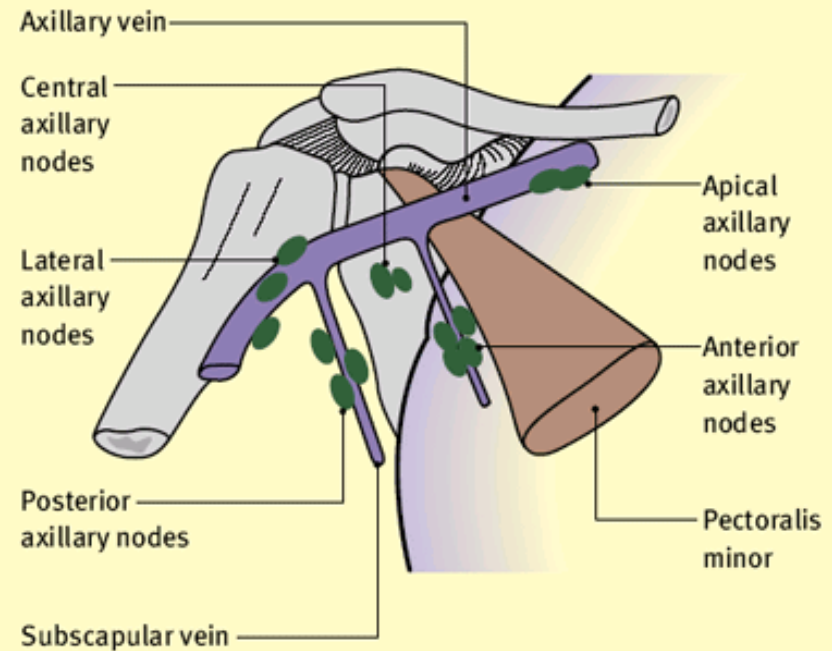
up to 40

5 groups

- apicales
- centrales
- humerales
- subscapulares
- pectorales

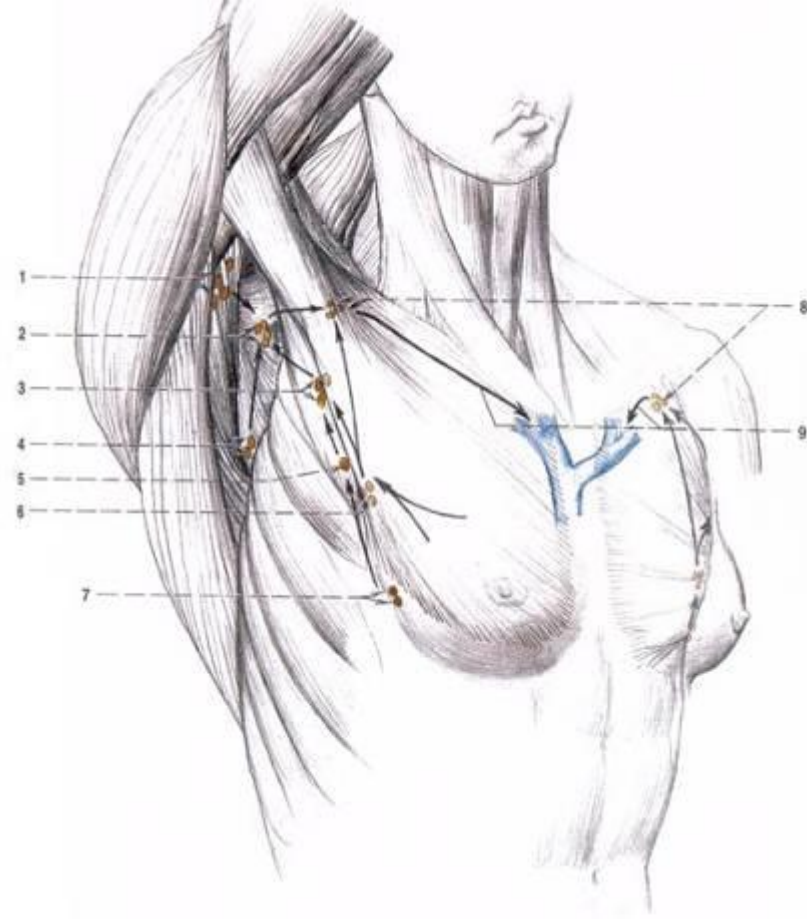


Lymph nodes of the axilla



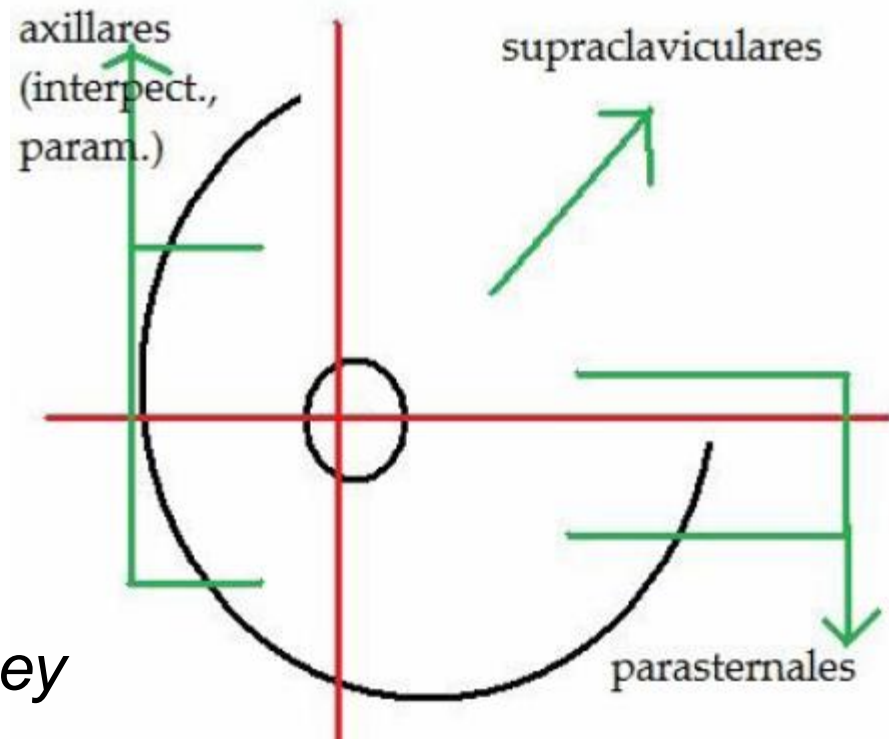
Mammary gland

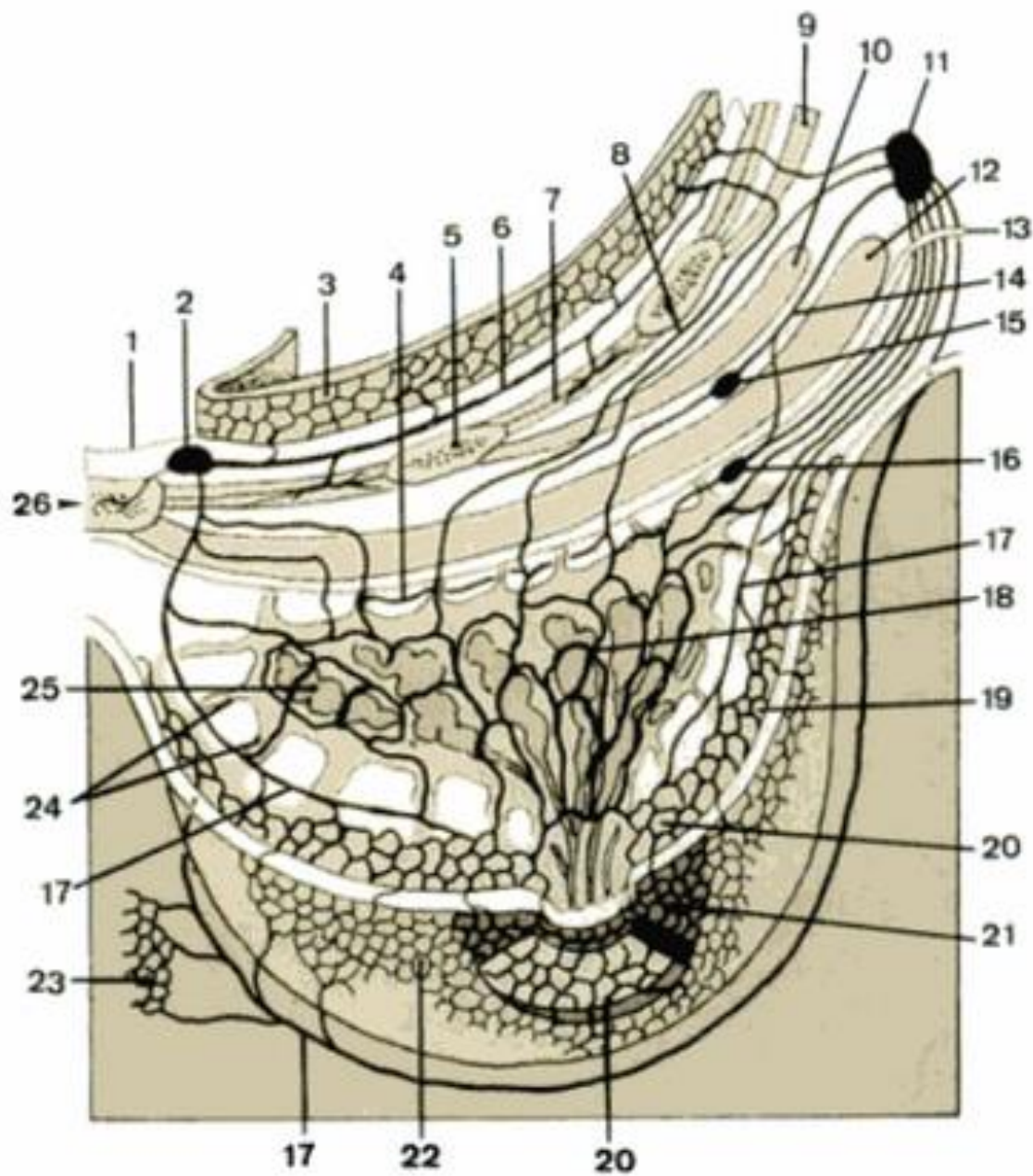
- **n.l. pectoralis *Sorgius***
 - 2nd/3th tooth of m. serratus anterior
 - *sentinel lymph node*
- n.l. infraclaviculares → supraclaviculares
- n.l. parasternales → n.l. mediastinales ant.
- across midline → n.l. axillares contralaterales



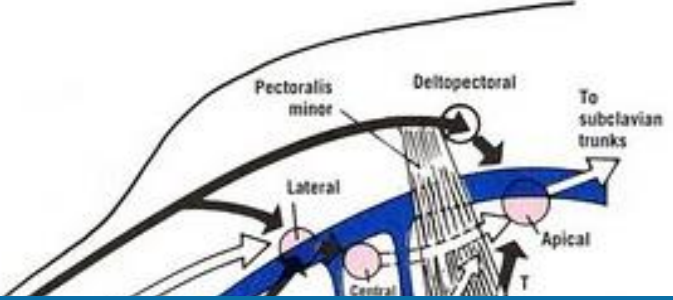
Mammary gland

- 4 quadrants
- 2 superficial plexuses:
 - plexus dermalis
 - plexus subareolaris *Sappey*
 - drainage into n.l. axillares
- 2 deep plexuses:
 - plexus fascialis
 - plexus glandularis
 - drainage into superficial plexuses and other lymph nodes
- 80% of lymph into n.l. axillares

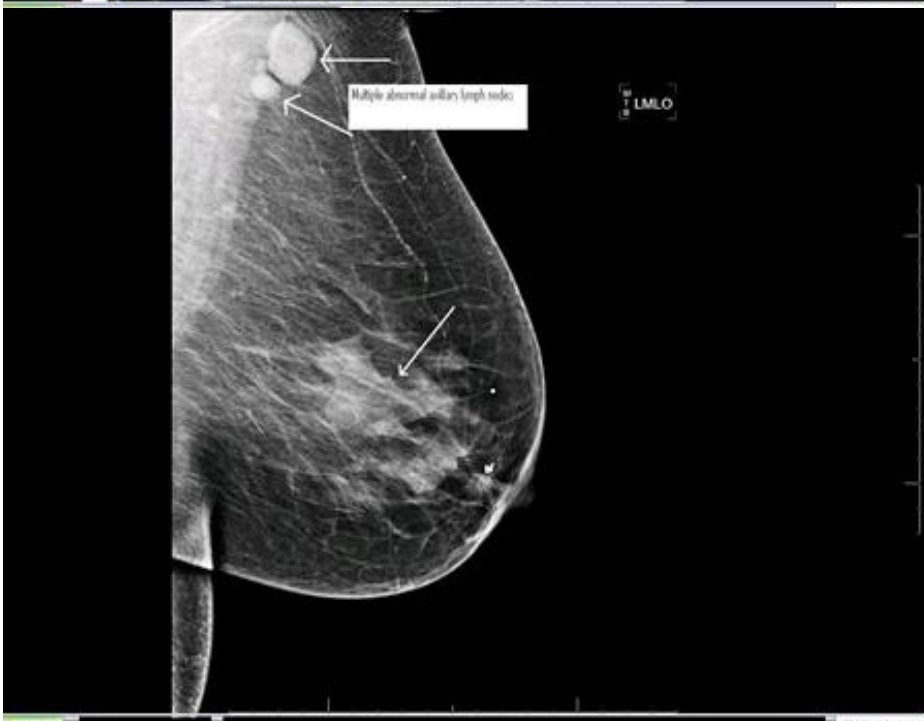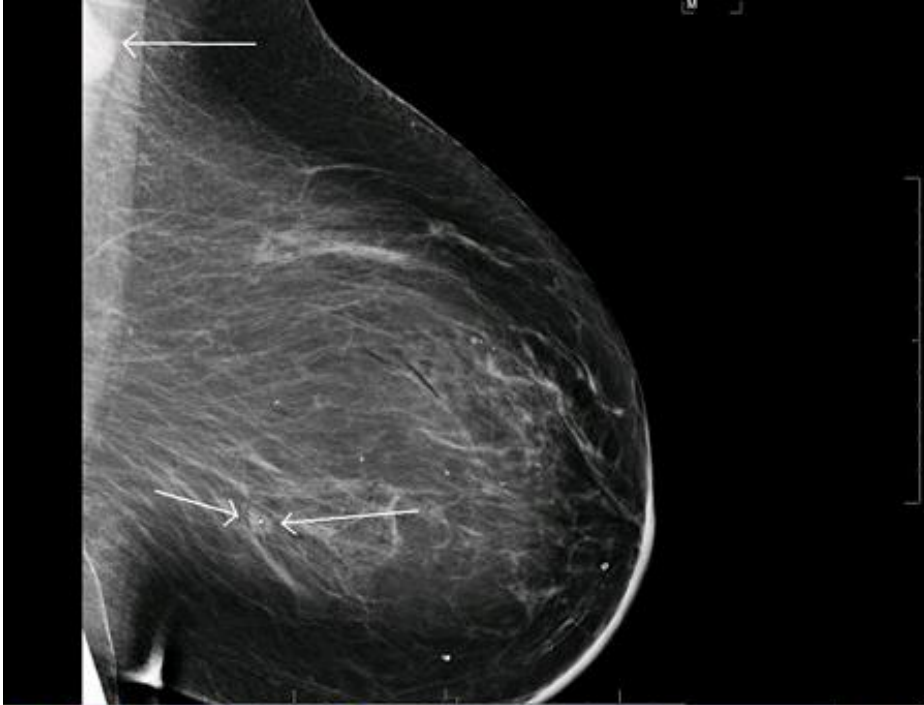
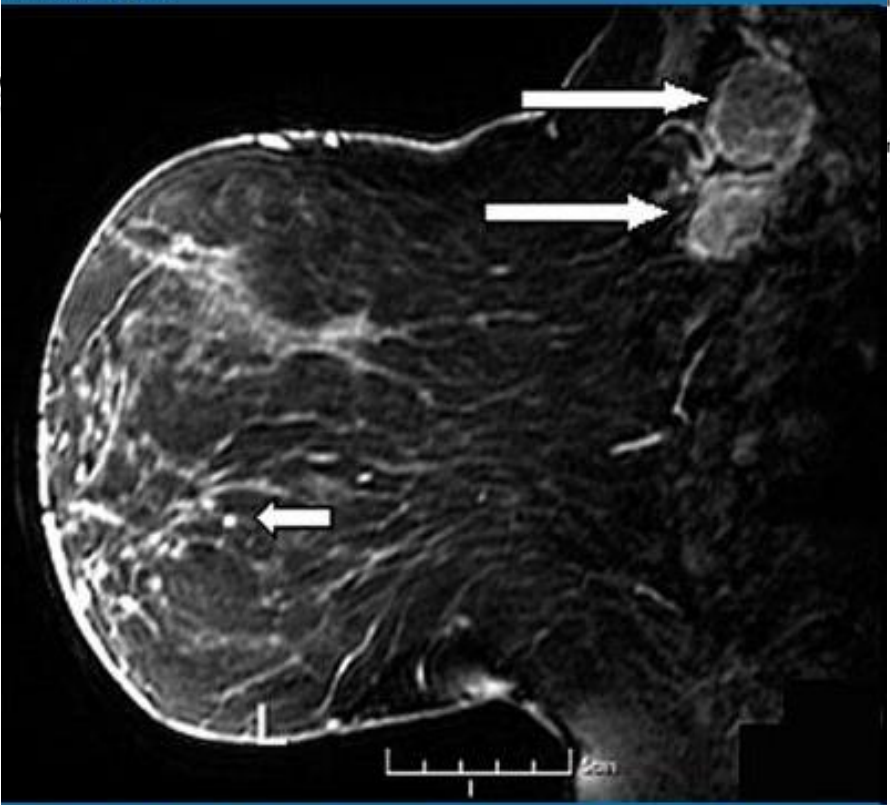




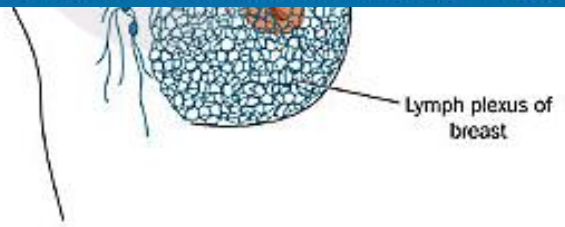
- 1 Endothoracic fascia
- 2 Parasternal l.n.
- 3 Pleural lymphatic network
- 4 Fascial plexus
- 5 Rib
- 6 Intercostal lymph vessels
- 7 Intercostal muscles
- 8 Subpectoral pathways
- 9 Serratus anterior muscle
- 10 Pectoralis minor muscle
- 11 Axillary l.n.'s
- 12 Pectoralis major muscle
- 13 Pectoral and axillary fascia
- 14 Interpectoral pathway
- 15 Interpectoral l.n.
- 16 Submammary l.n.
- 17 Cutaneous collectors
- 18 Intraglandular lymphatic plexus
- 19 Circumareolar plexus
- 20 Subareolar plexus
- 21 Areolar plexus
- 22 Superficial cutaneous plexus
- 23 Cutaneous network of the thoracic wall
- 24 Retinacula of the skin
- 25 Glandular tissue
- 26 Sternum



Medscape

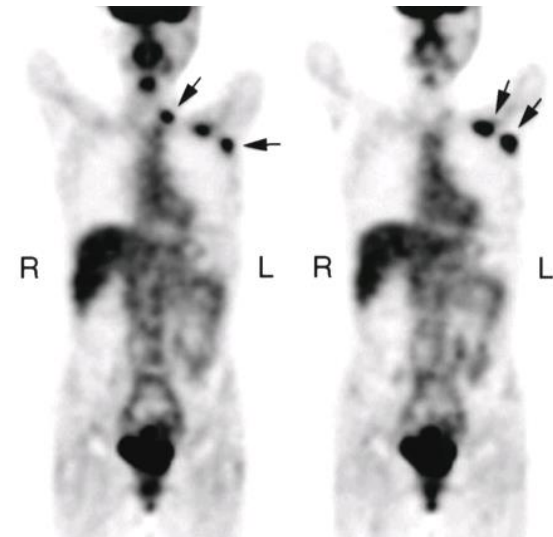
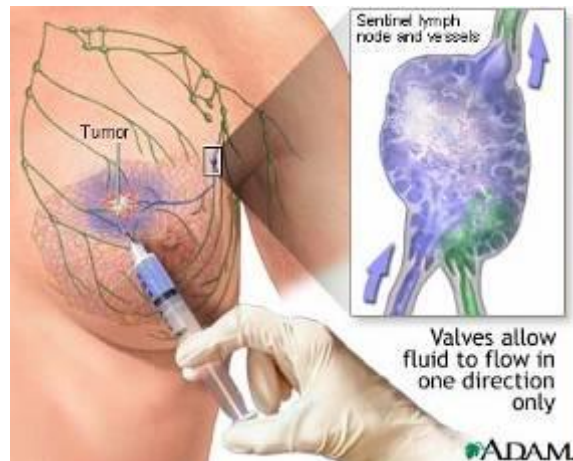
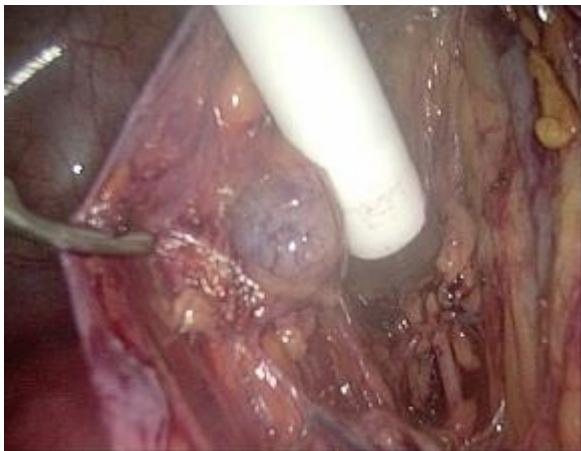

Source: Am J Roentgenol © 2009 American Roentgen Ray Society

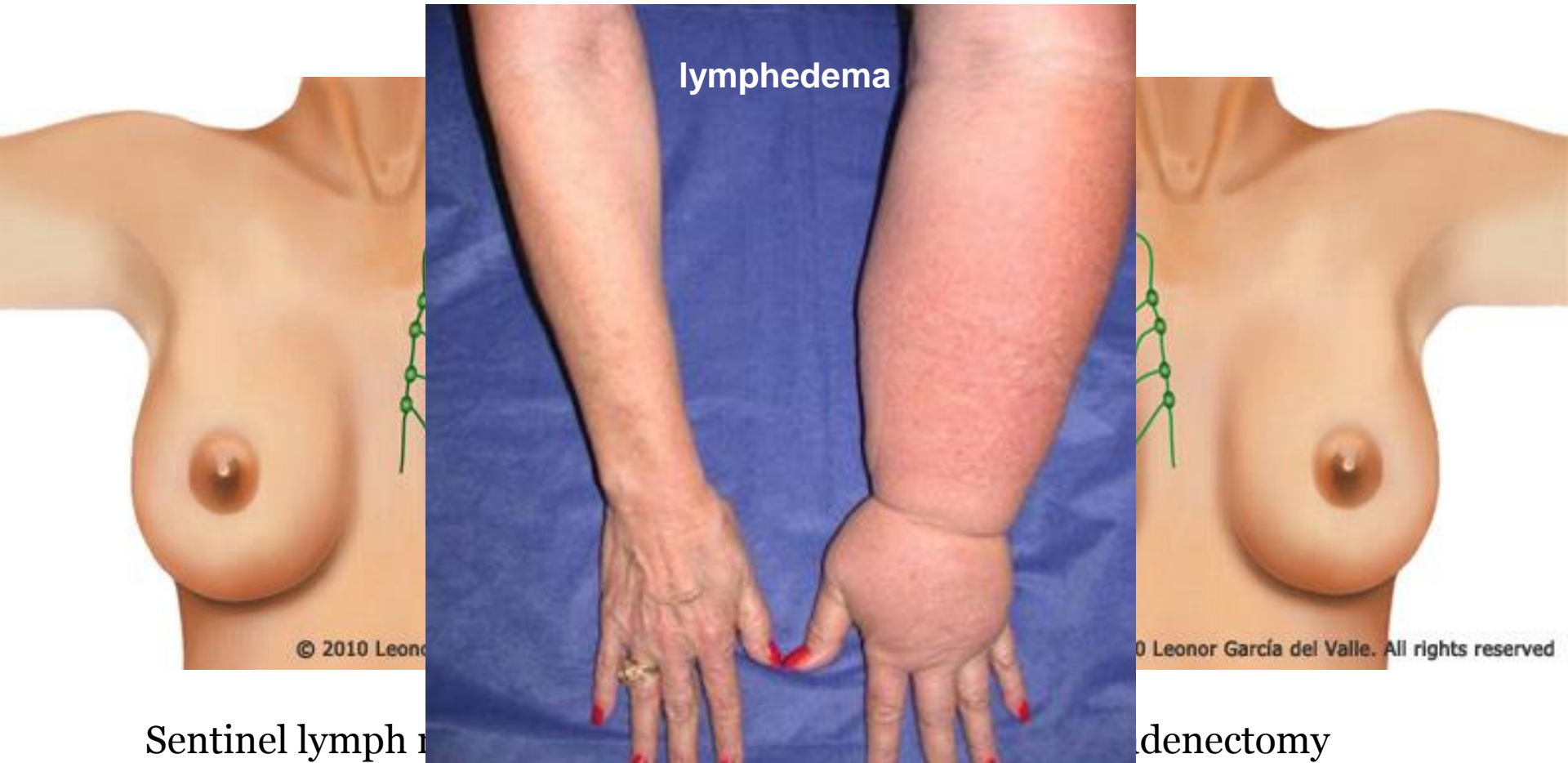


Axillary nodes – clinical relevance

- sentinel lymph node visualization
 - staining: application of 10 ml of blue stain (Patentblau, Evans blue) into tumour → after 10 minutes incision in axilla and dissection of sentinel lymph node → following coloured lymph vessels to coloured lymph node → aspection of vicinity (more coloured nodes)
 - radioactivity: injection of 60 MBq (0,2 ml) Tc-99m-nanocolloid → probe seeking after 2 hours (*lymphoscintigraphy*)



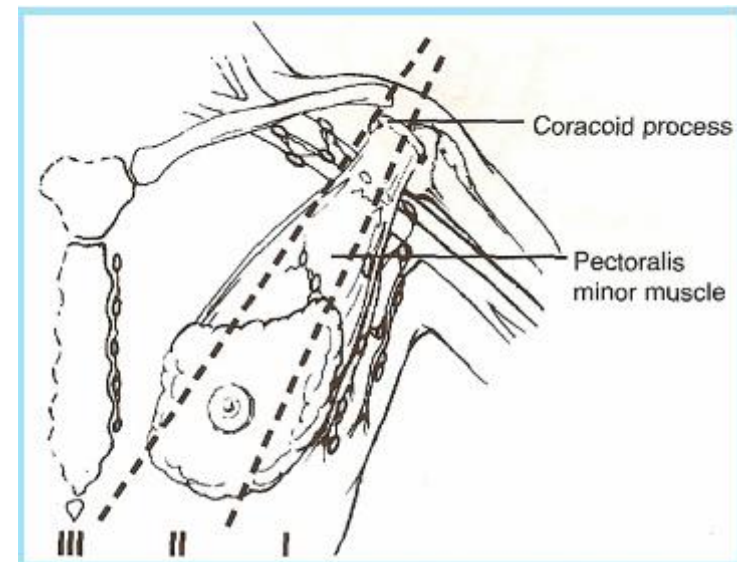
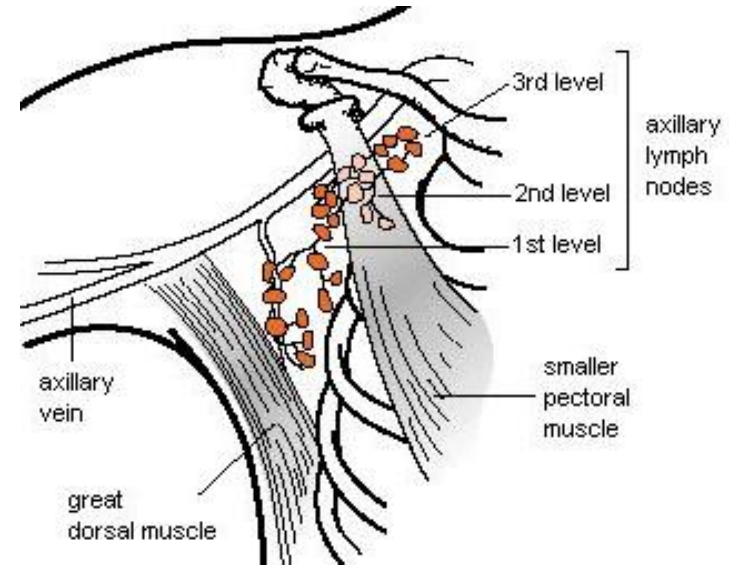
Axillary lymphadenectomy axilla exenteration



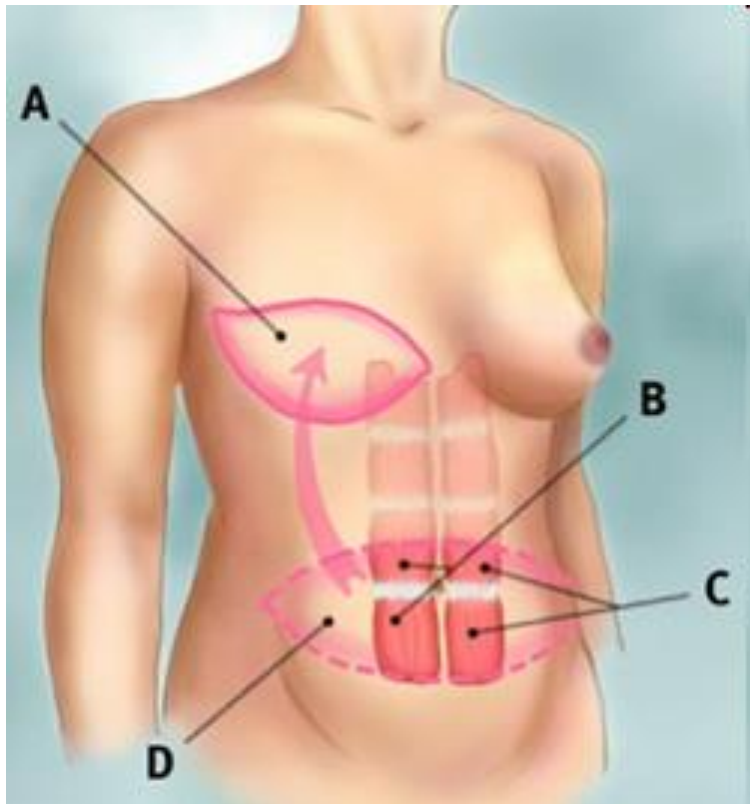
3 levels according to *Berg*

1. below m. pectoralis minor
 - n.l. pectorales (ant.)
 - n.l. subcapulares (post.)
 - n.l. humerales (lat.)
2. behind m. pectoralis minor
 - n.l. centrales, apicales (part)
 - n.l. interpectoriales (*Rotter*)
3. behind nerves and vessels
 - n.l. apicales

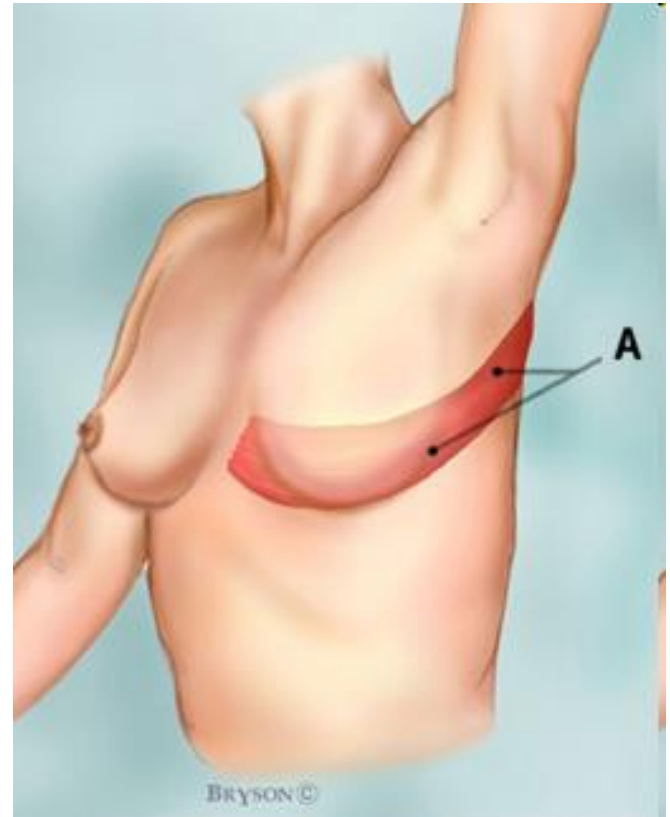
complete dissection of axillary lymph nodes of 1st and 2nd level = axilla exenteration (danger of elephantiasis!)



Trans-rectus abdominis muscle (TRAM)

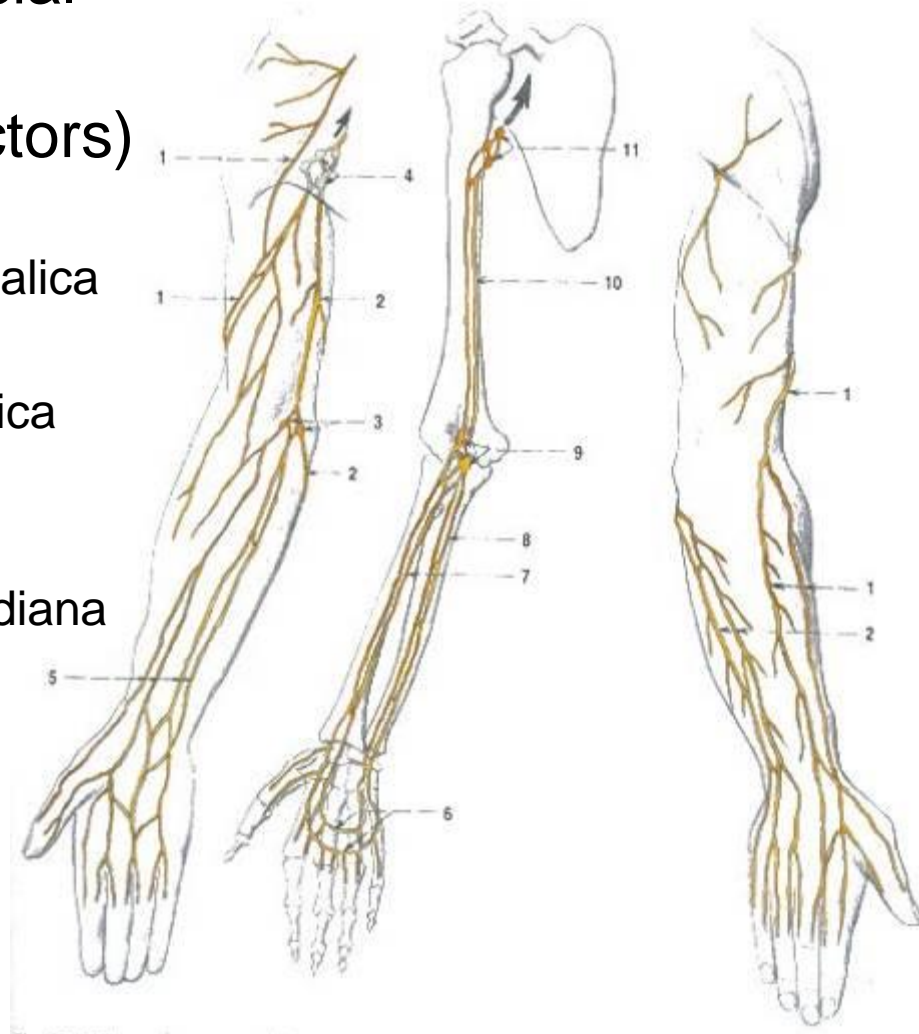


Latissimus dorsi muscle



Upper limb collectors

- deep
 - along deep vessels
- superficial
 - approximately along superficial veins
 - 3 collectors (groups of collectors)
 - lateral
 - into n.l.axillares along v. cephalica
 - medial
 - into n.l.axillares along v. basilica
 - interposed n.l. cubitales spf.
 - ventral
 - into n.l. cubitales along v. mediana antebrachii
- n.l. brachiales
- n.l. cubitales
 - n.l. supratrochleares



Upper limb

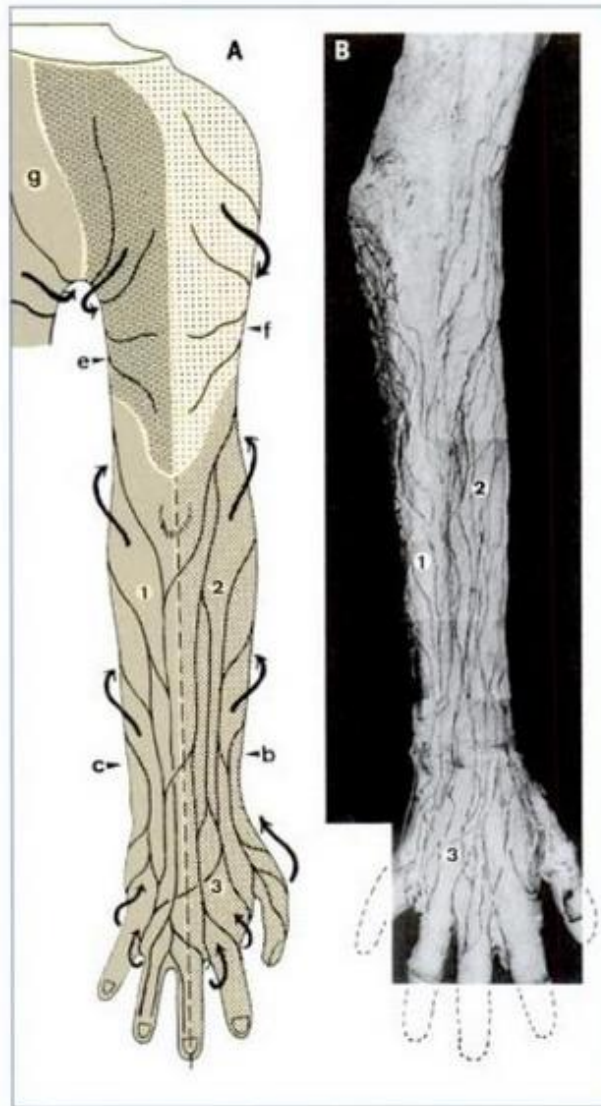


Fig. 1.113 Lymph vessel bundles and lymph territories on the dorsal side of the upper extremity. **A** Schematic diagram of the lymph territories **B** Injection specimen (fetus, 20 cm crown-rump length)
1 Ulnar bundle **2** Radial bundle **3** Long cross-collateral between radial and ulnar collectors of the dorsum of the hand **b** Territory of the radial bundle **c** Territory of the ulnar bundle **e** Dorsomedial territory of the upper arm **f** Dorsolateral territory of the upper arm territory **g** Upper territory of the trunk [M 124]

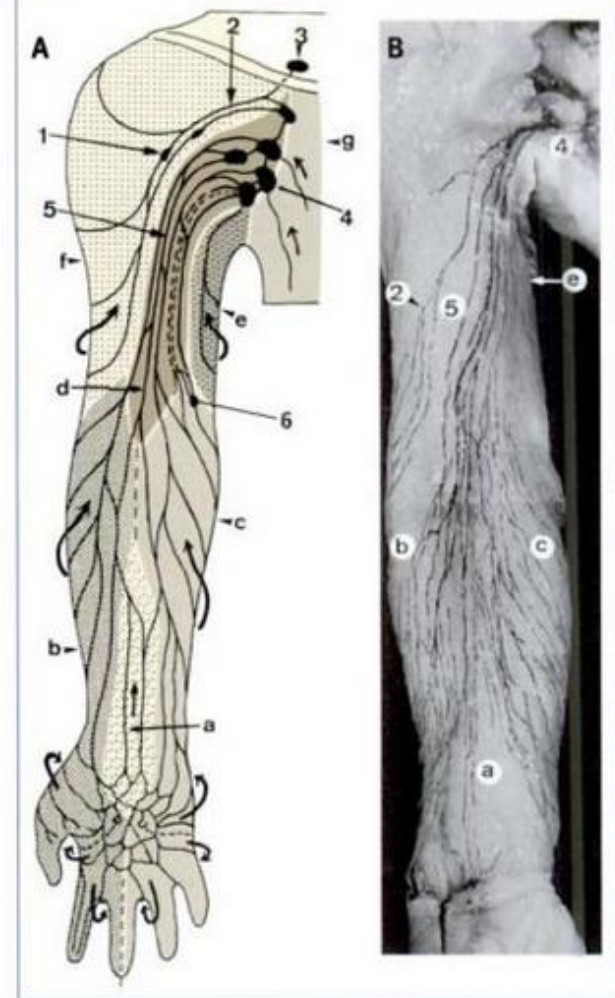
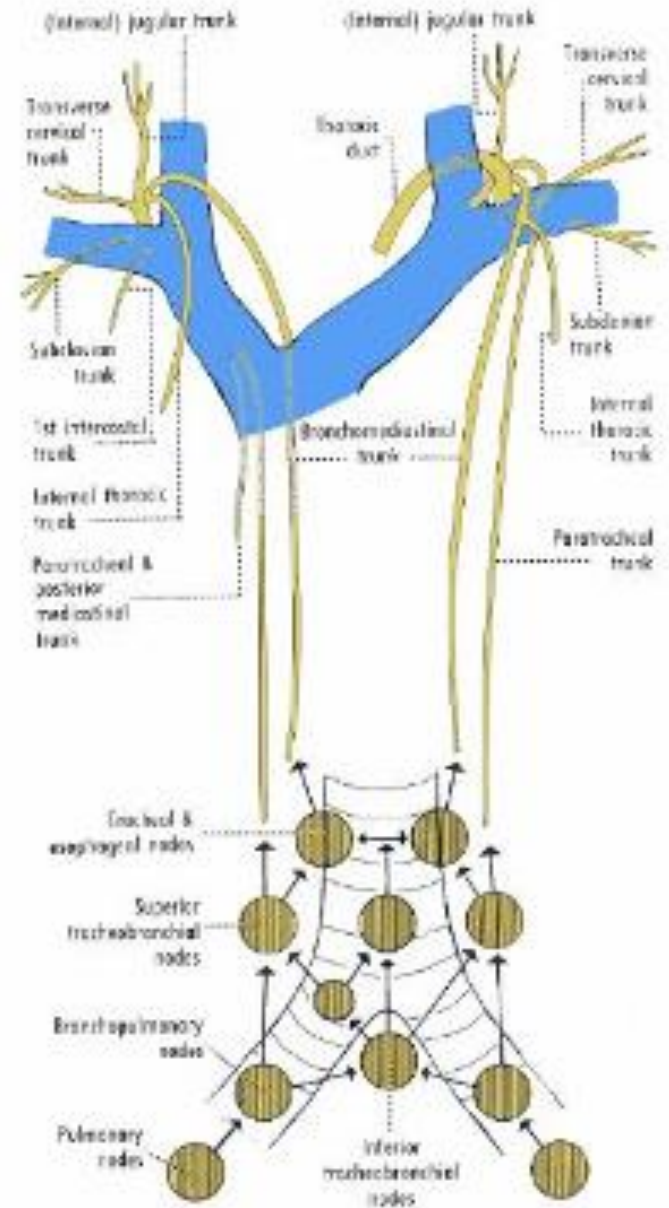


Fig. 1.114 Lymph vessel bundles and lymph territories of the upper extremity (palmar view). **A** Schematic diagram of the lymph territories with the lymphatic drainage divides that separate them **B** Injection specimen (fetus, 20 cm crown-rump length).
a Middle territory of the forearm with median forearm bundle **b** Territory of the radial bundle **c** Territory of the ulnar bundle **d** Middle territory of the upper arm **e** Dorsomedial territory of the upper arm **f** Dorsolateral territory of the upper arm and shoulder **g** Upper territory of the trunk **1** Deltoideopectoral l.n.'s **2** Lateral upper arm or deltoid bundle (short type) **3** Supraclavicular l.n. **4** Axillary l.n.'s **5** Median bundle of the upper arm **6** Superficial cubital l.n. [M 124]

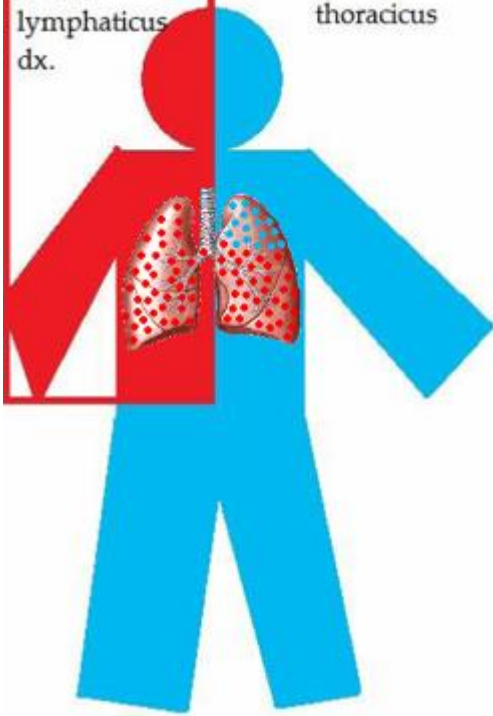
Lungs

- superficial subpleural plexus
- deep plexus along vessels and bronchi
- pulmonary alveoli possess no lymph vessels within walls
- **all lymph to the right side** into truncus lymphaticus dexter
- **to the left side only** upper 3 segments of left lung !

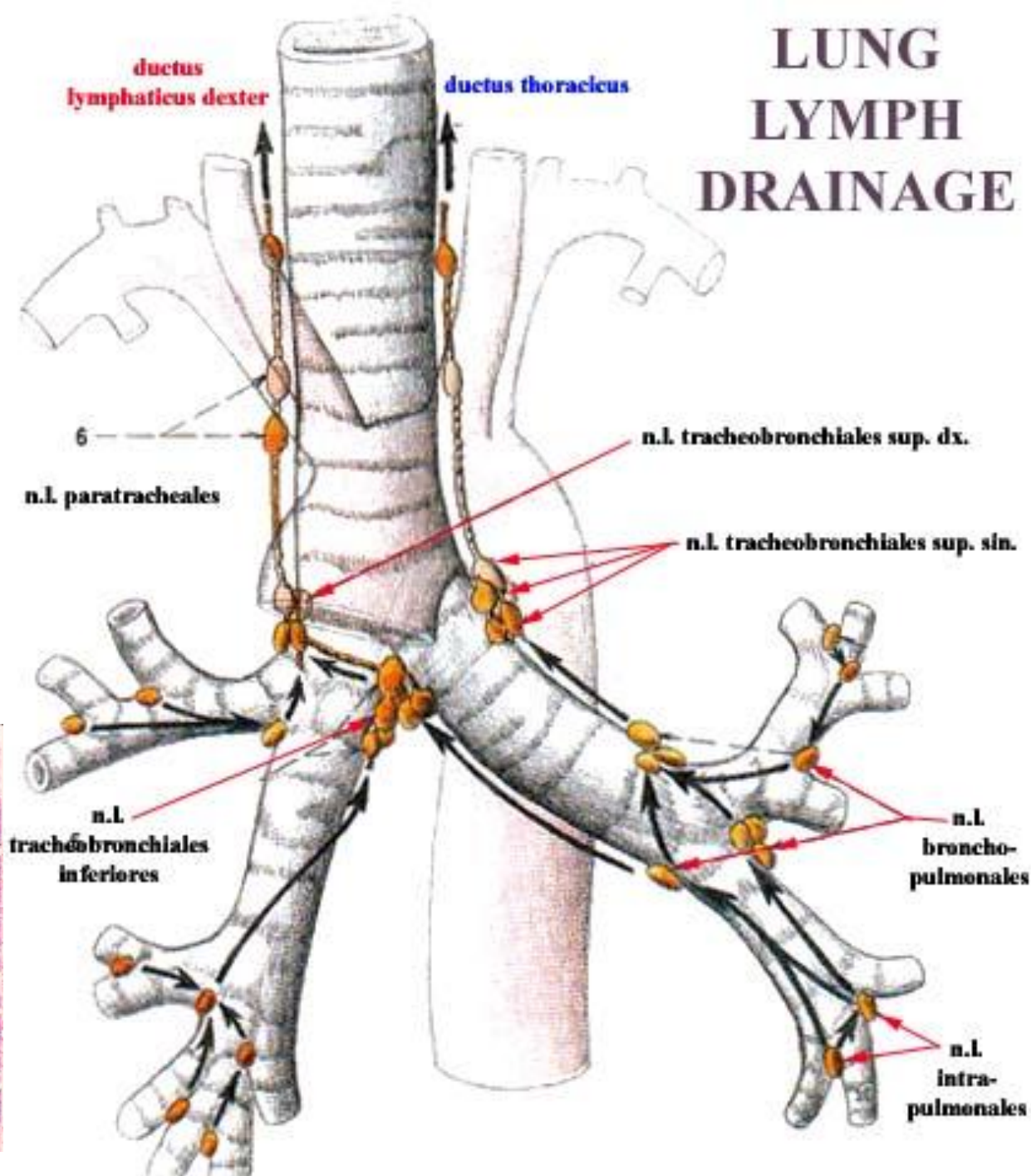


ductus
lymphaticus
dx.

ductus
thoracicus



LUNG LYMPH DRAINAGE



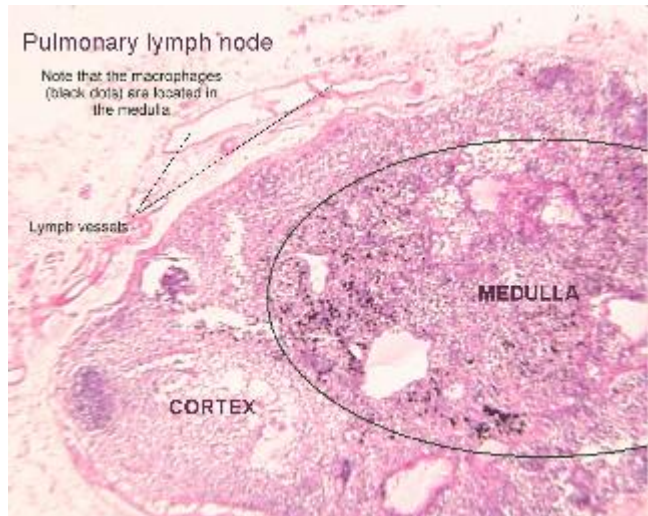
Pulmonary lymph node

Note that the macrophages
(black dots) are located in
the medulla.

Lymph vessels

MEDULLA

CORTEX



Lungs

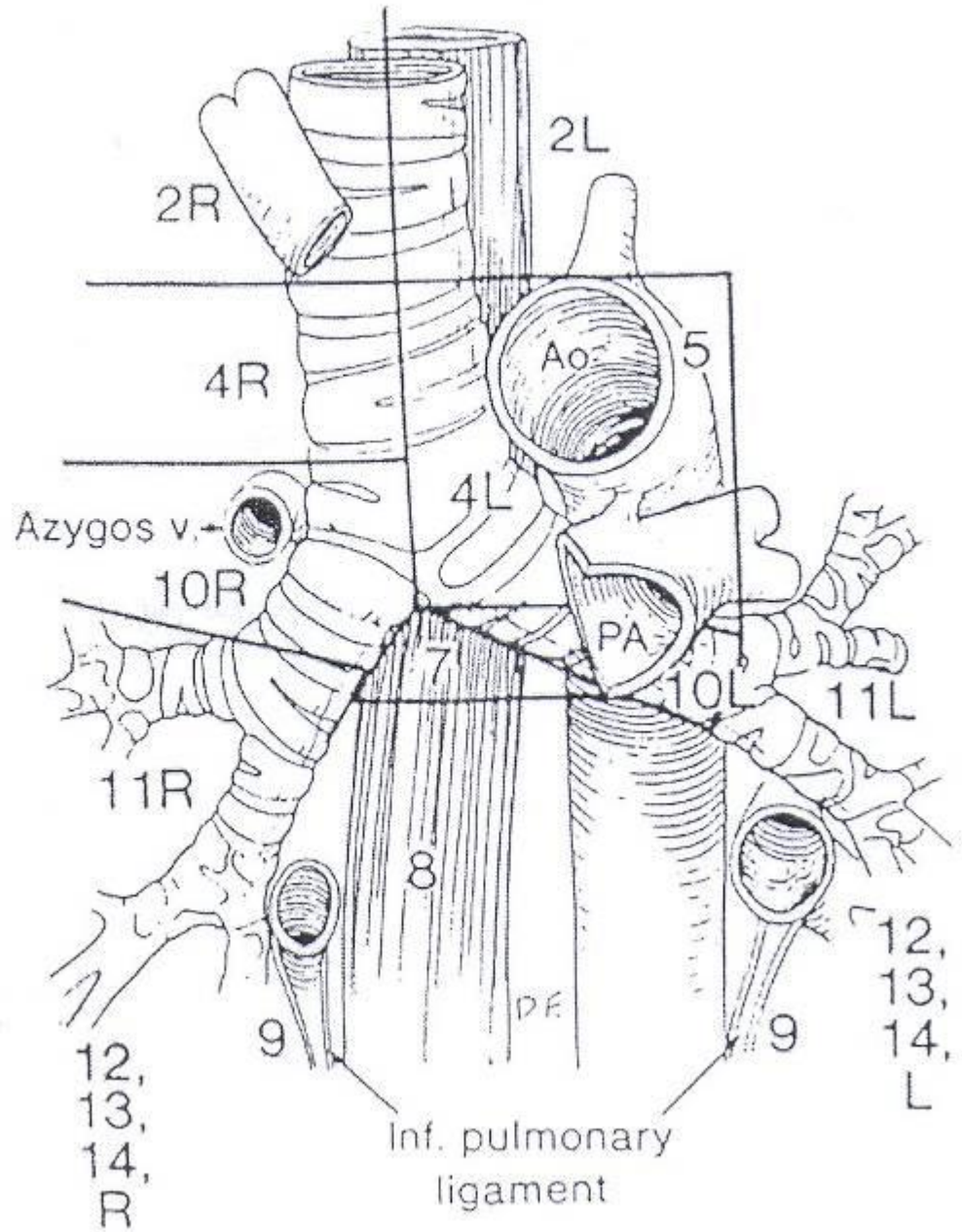
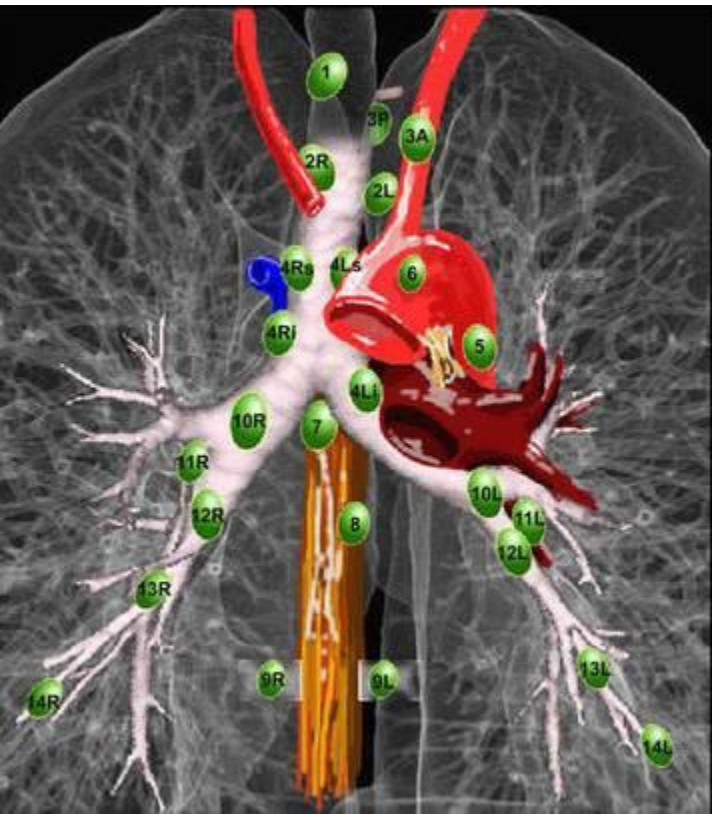
n.l. intrapulmonales (septa) → n.l. bronchopulmonales (hilum):

- *both lungs except upper 3 left segments I+II, III* → n.l. tracheobronchiales inferiores → n.l. tracheobronchiales sup. dx. → truncus bronchomediastinalis dx. → ductus lymphaticus dexter → angulus venosus dx. → veins of neck
- *I+II, III segments on the left* → n.l. tracheobronchiales sup. sin. → truncus bronchomediastinalis sin. → ductus thoracicus → angulus venosus sin. → veins of neck

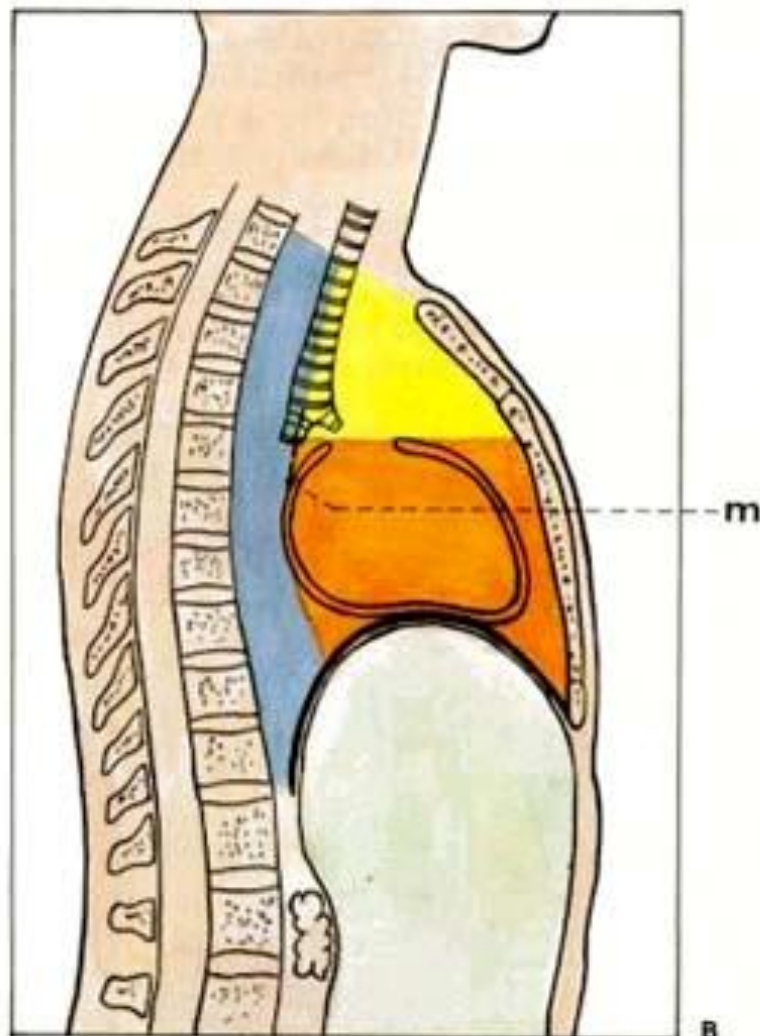
Lungs

surgical classification of lymph nodes

LYMPH NODE CLASSIFICATION

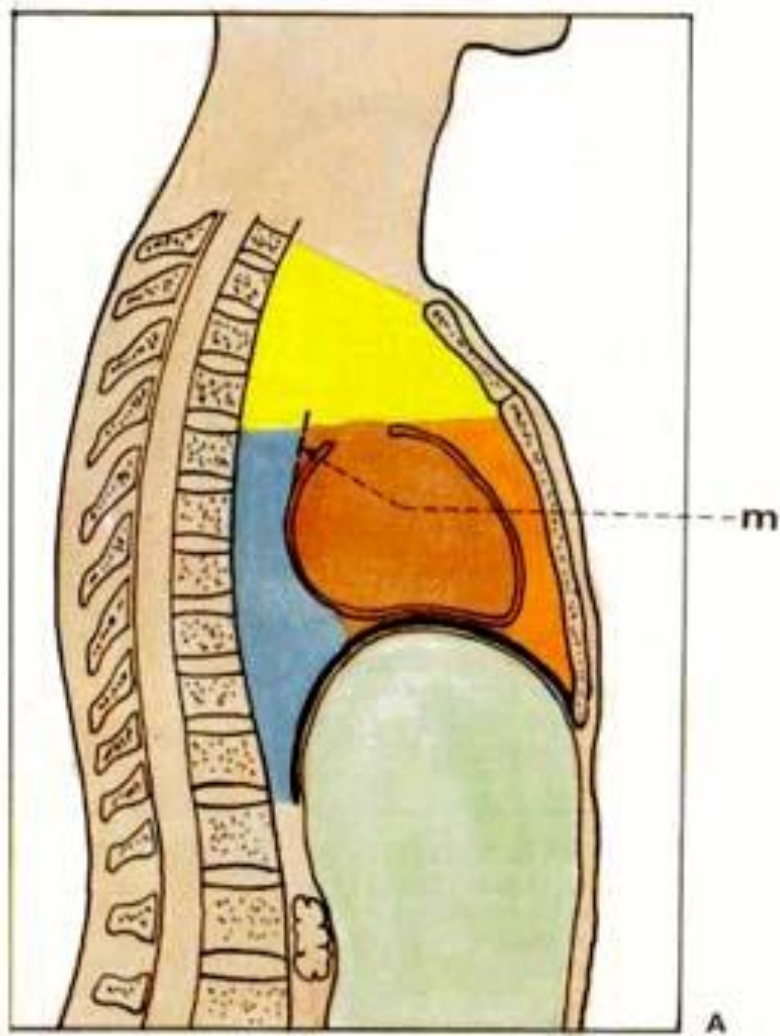


Chirurgické dělení



ZJEDNODUŠENÉ ROZDĚLENÍ respektující souvislost zadního mediastina
modře / zadní mediastinum
žlutě a oranžově / přední mediastinum
žlutě / přední horní mediastinum
oranžově / přední dolní mediastinum
m / membrana bronchopericardiaca

Anatomické dělení



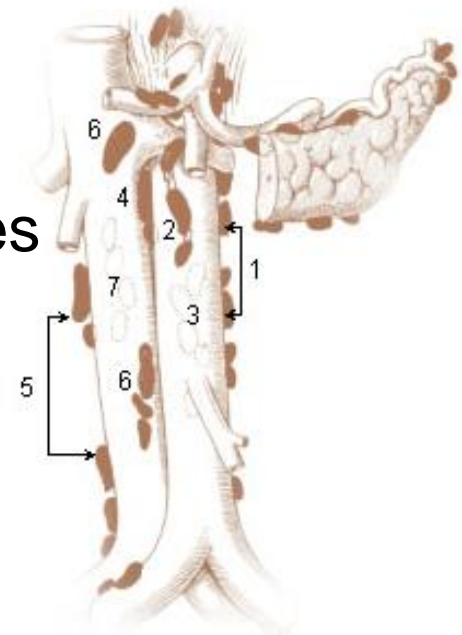
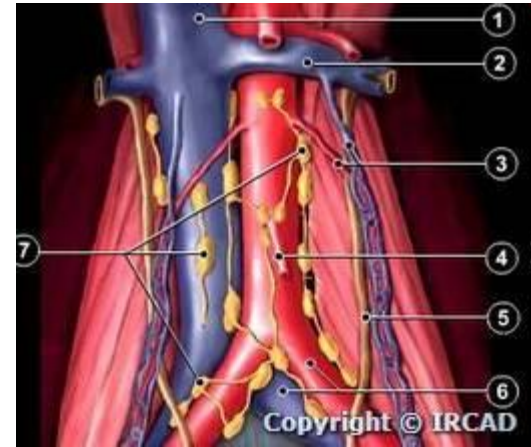
PROSTORY MEDIASTINA A MOŽNOST ŠÍŘENÍ INFEKCE (schéma)
A. ROZDĚLENÍ MEDIASTINA podle nomina anatomica
žlutě / horní mediastinum
oranžově / přední mediastinum
červeně / střední mediastinum
modře / zadní mediastinum
m / membrana bronchopericardiaca

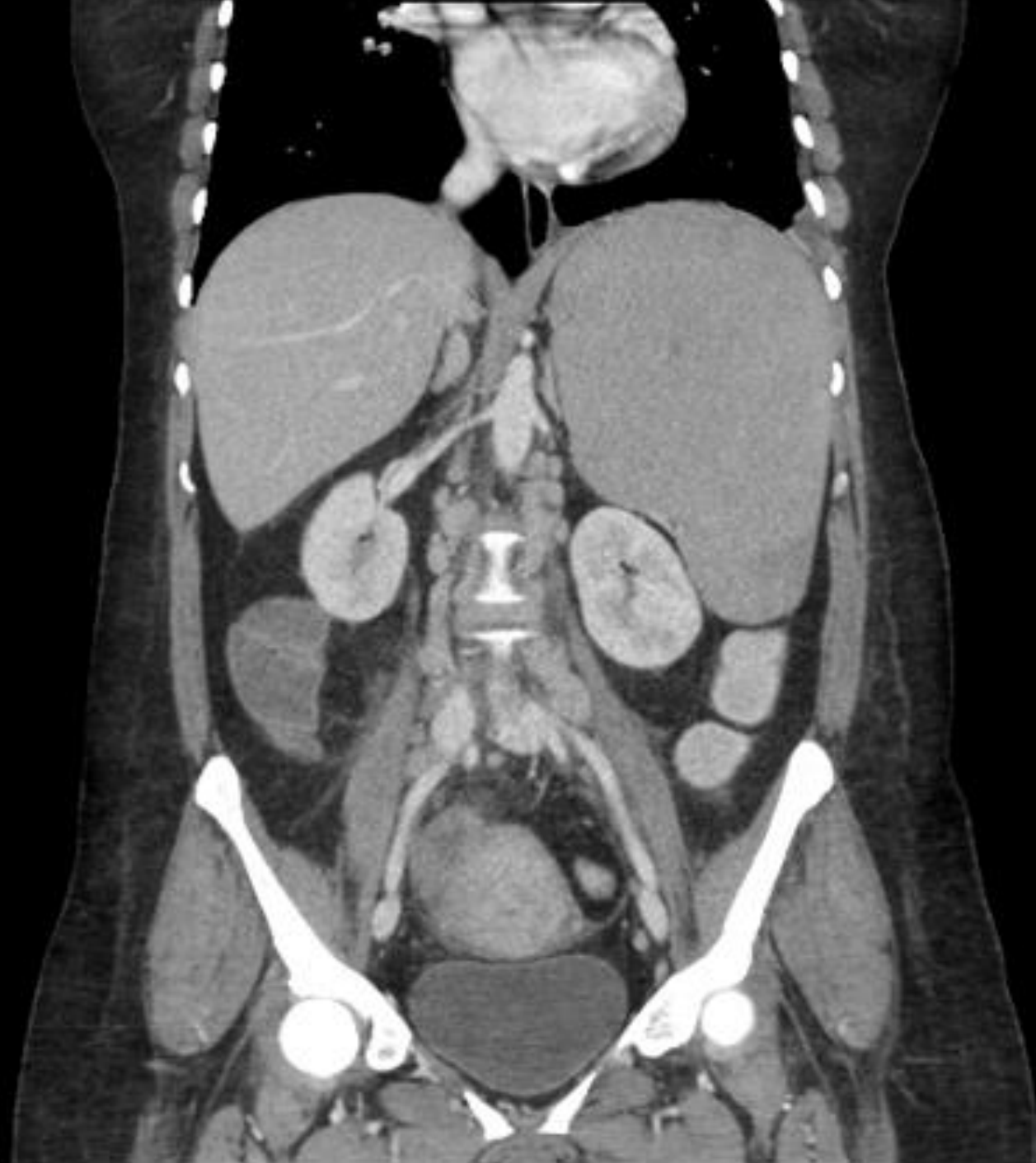
Mediastinum

- anterior: n.l. paramammarii + parasternales + intercostales + phrenici sup. + prepericardiaci (= n.l. "**mediastinales ant.**")
- middle: n.l. bronchopulmonales + tracheobronchiales inf. + pericardiaci lat.
- posterior: n.l. juxtaoesophagei + prevertebrales (= n.l. "**mediastinales post.**")
- superior: n.l. tracheobronchiales sup. + paratracheales

Abdomen

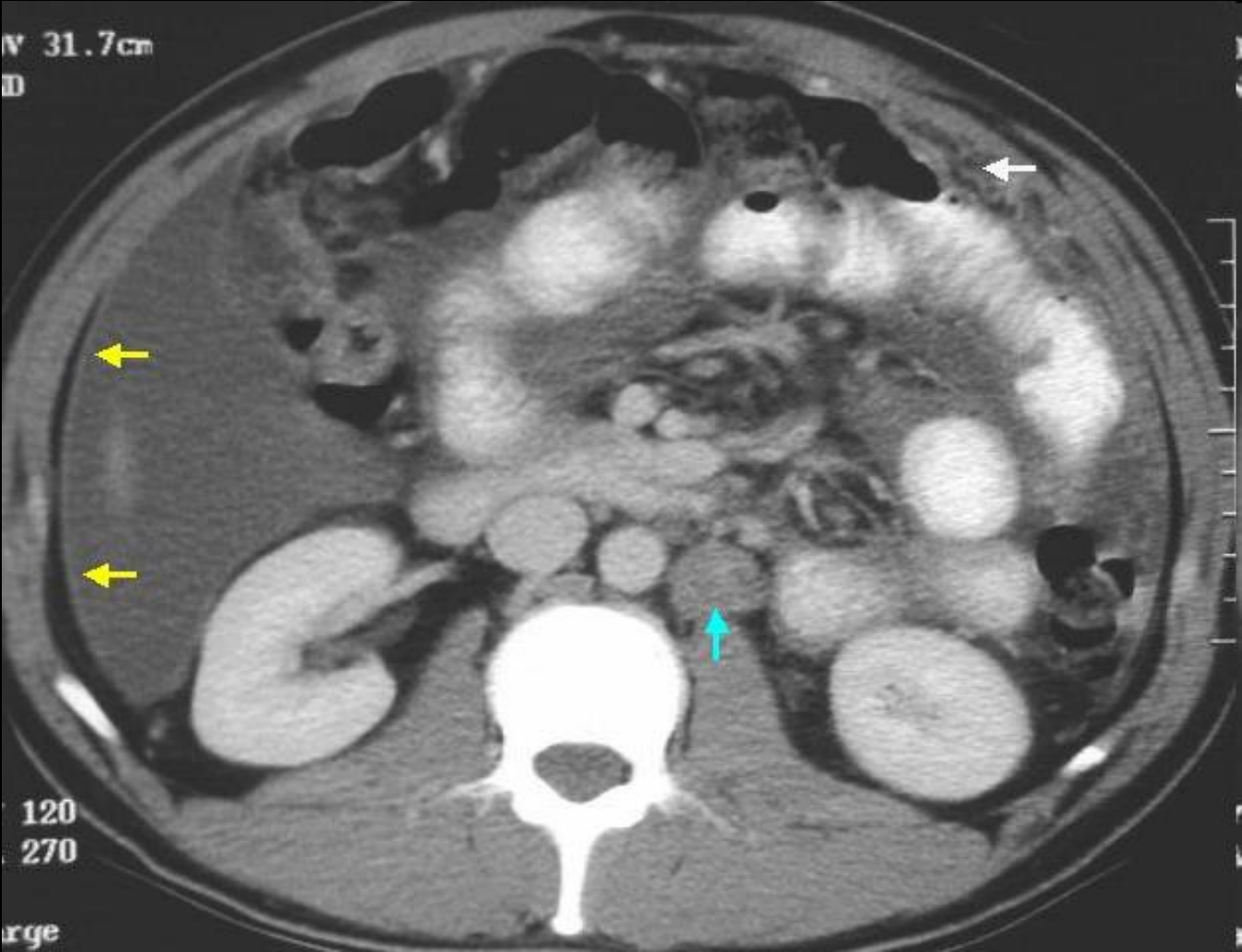
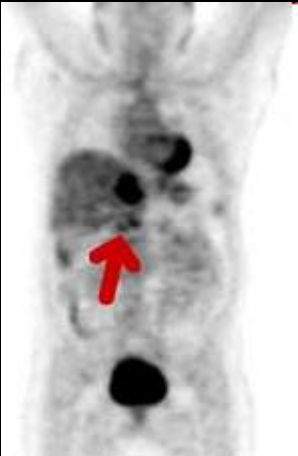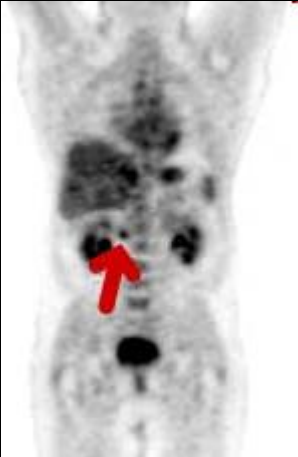- origin of ductus thoracicus (cisterna chyli)
 - L1, between crura diaphragmatis
- n.l. parietales
 - n.l. lumbales sinistri
 - n.l. aortici lat., preaortici, retroaortici
 - n.l. lumbales intermedii
 - n.l. lumbales dextri
 - n.l. cavales lat., precavales, retrocavales
- = „paraaortal nodes“
- n.l. phrenici inf., epigastrici inf.





Colorectal metastasis

Tuberculosis

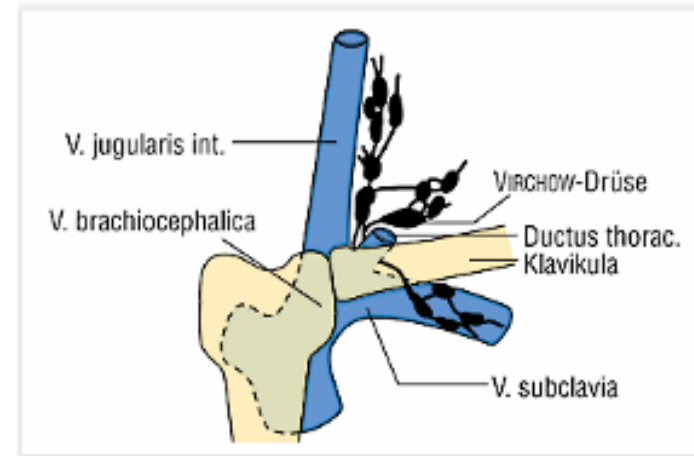


Abdomen

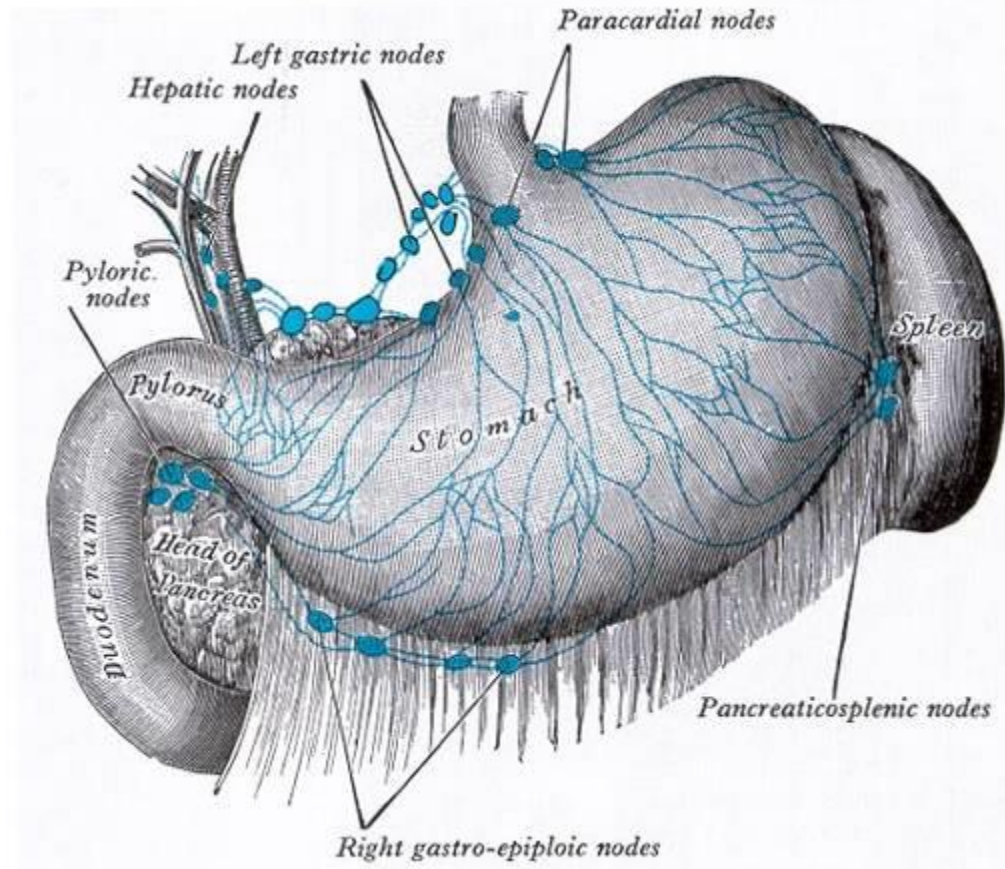
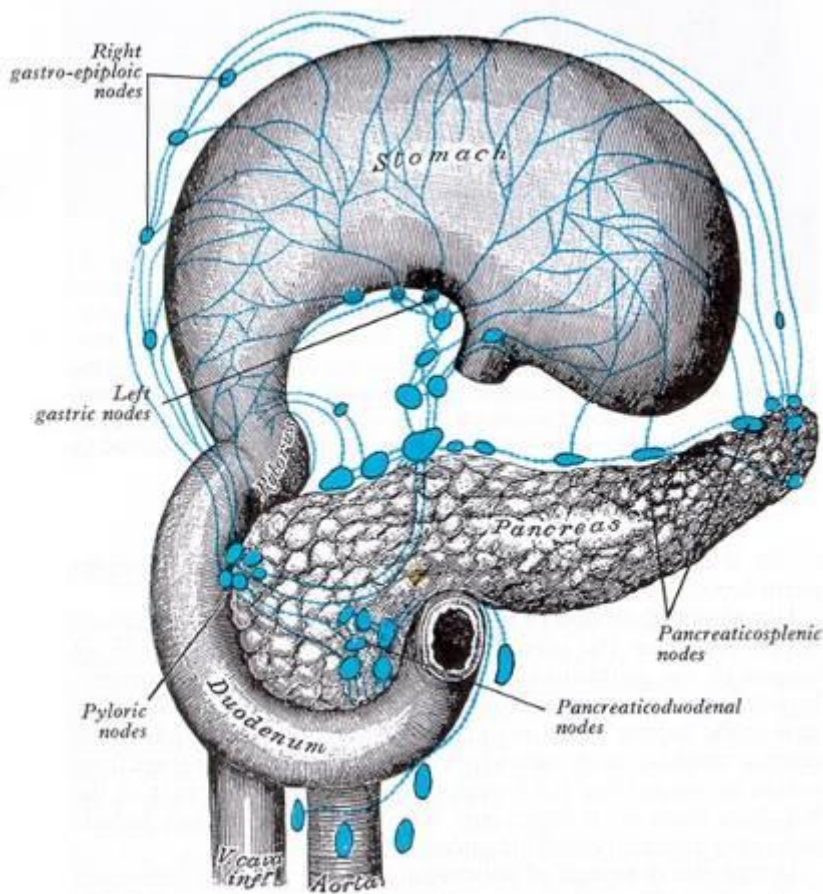
- n.l. viscerales
- lymph nodes of all organs → n.l. **coeliaci**
 - 2-3 trunci intestinales → cisterna chyli
 - n.l. gastrici, gastromentales, pylorici, pancreaticoduodenales
 - pancreatici, splenici
 - hepatici
 - mesenterici sup. (juxtaintestinales, sup. centrales; ileocolici, pre + retrocaecales, appendiculares, mesocolici /paracolici, colici dx. + medii + sin./)
 - mesenterici inf. (sigmoidei, rectales sup.)

Stomach

- 5 groups of regional nodes
 - n.l. gastrici dextri + sinistri
 - n.l. gastromentales dextri + sinistri
 - n.l. pylorici
 - + anulus lymphoideus cardiae
- all lymph then into n.l. coeliaci → trr. intestinales
- metastases can spread into n.l. supraclaviculares sin. (Virchow-Troisier's nodes)
 - ***left side!***



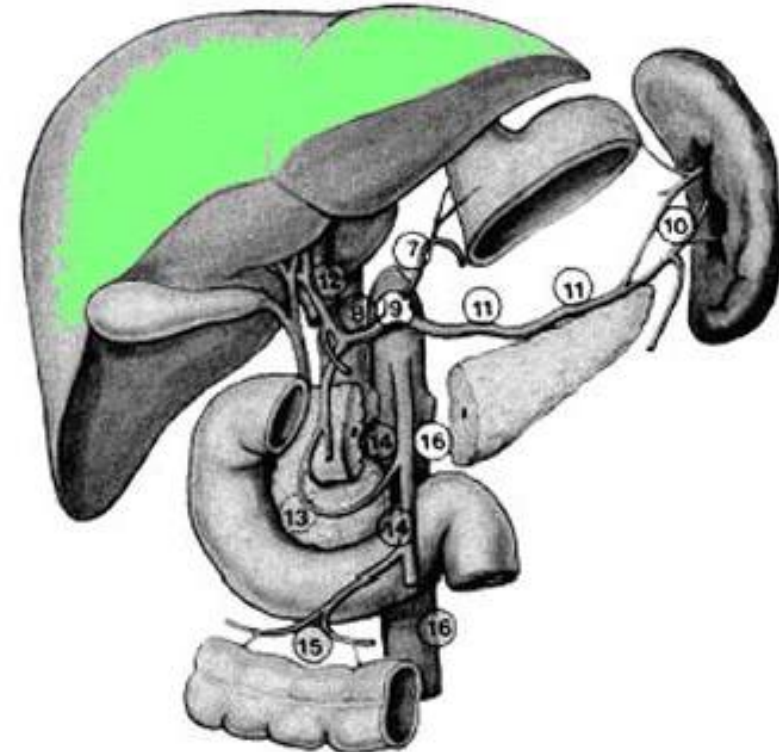
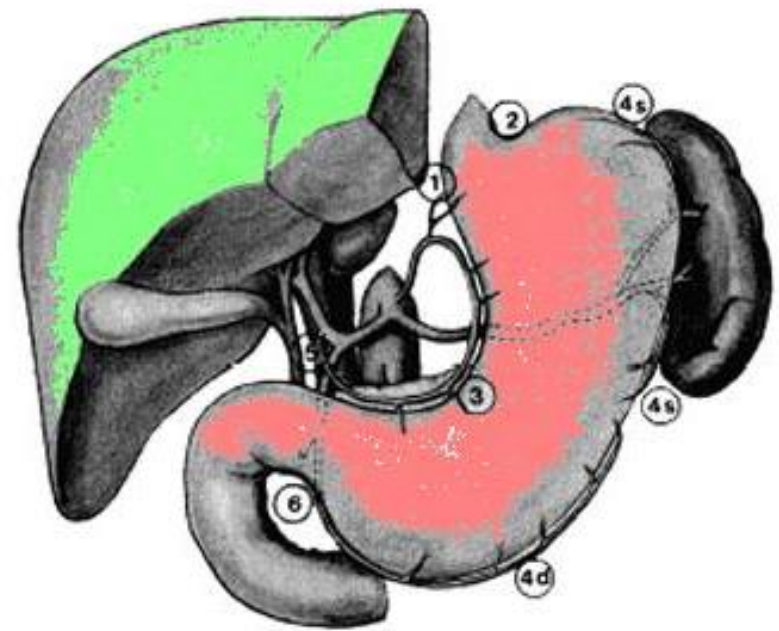
Stomach



Stomach

surgical classification

- 1, right cardial nodes
- 2, left cardial nodes
- 3, nodes along the lesser curvature
- 4, nodes along the greater curvature
- 5, suprapyloric nodes
- 6, infrapyloric nodes
- 7, nodes along the left gastric artery
- 8, nodes along the common hepatic artery;
- 9, nodes around the celiac axis
- 10, nodes at the splenic hilus
- 11, nodes along the splenic artery
- 12, nodes in the hepatoduodenal ligament;
- 13, nodes at the posterior aspect of the pancreas head
- 14, nodes at the root of the mesentery
- 15, nodes in the mesocolon of the transverse colon
- 16, para-aortic nodes



Karcinom žaludku a D2 lymfadenektomie – technika, možné komplikace

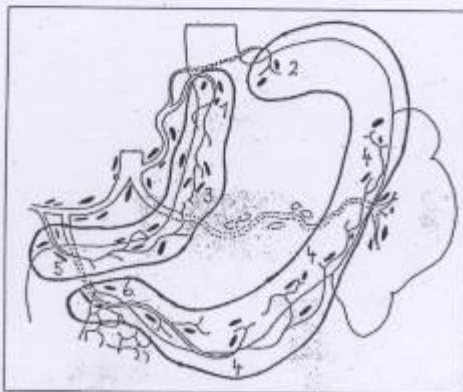
Šimša J.¹, Leffler J.¹, Hoch J.¹, Schwarz J.¹, Bavor P.¹

Chirurgická klinika 2. LF UK a FN Motol, Praha, přednosta doc. MUDr. J. Hoch, CSc.

Tab. 1. Klasifikace spádových lymfatických uzlin žaludku, rozdělení do jednotlivých kompartmentů (I-III) a oblastí (1-16)

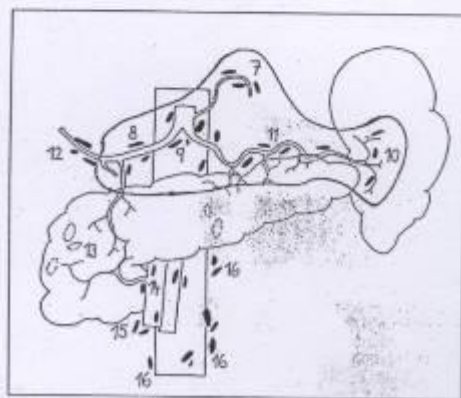
Tab. 1. Classification of catchment lymphatic nodes of the stomach, division into individual compartments (I-III) and areas (1-16)

Kompartiment	Číslo oblasti	Lokalizace lymfatických uzlin
I.	1	LU parakardiální – při malém zakřivení
	2	LU parakardiální – při velkém zakřivení
	3	LU podél malého zakřivení
	4	LU podél velkého zakřivení
	5	Suprapylorické LU
	6	Infrapylorické LU
II.	7	LU podél a. gastrica sin.
	8	LU podél a. hepatica communis
	9	LU v oblasti truncus coeliacus
	10	LU v hilu sleziny
	11	LU podél a. lienalis
III.	12	LU v oblasti lig. hepatoduodenale
	13	LU retropankreaticky v oblasti hlavy slinivky
	14	LU podél a. et v. mesenterica superior
	15	LU podél a. et v. colica media
	16	LU podél abdominální aorty



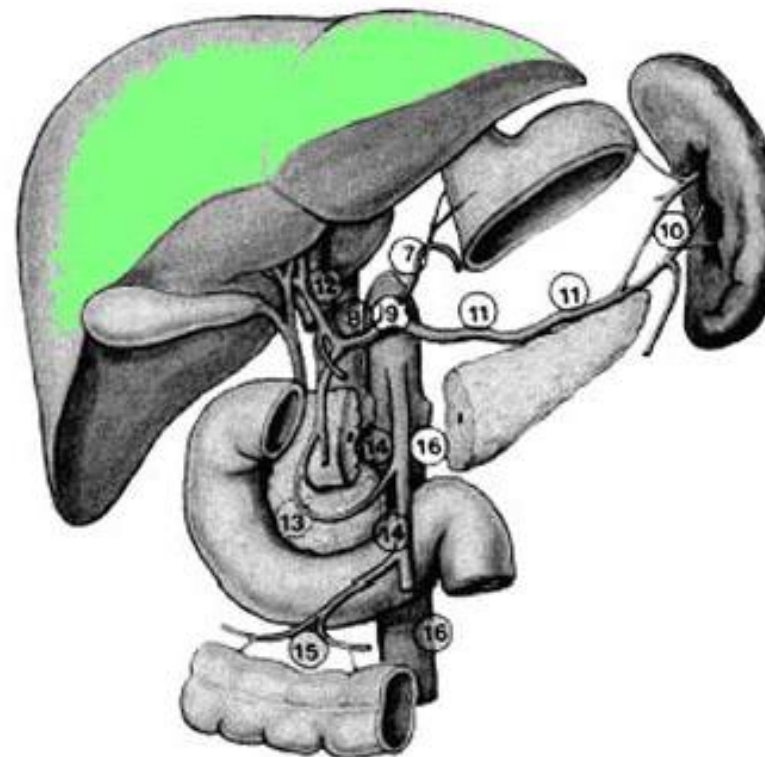
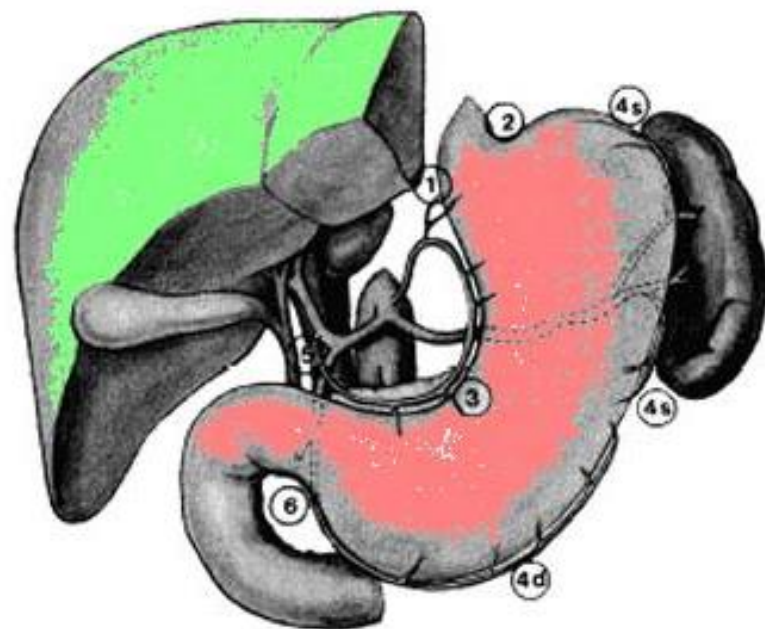
Obr. 1. Spádové lymfatické uzliny žaludku.

Fig. 1. Catchment lymphatic nodes of stomach.



Obr. 2. Spádové lymfatické uzliny žaludku.

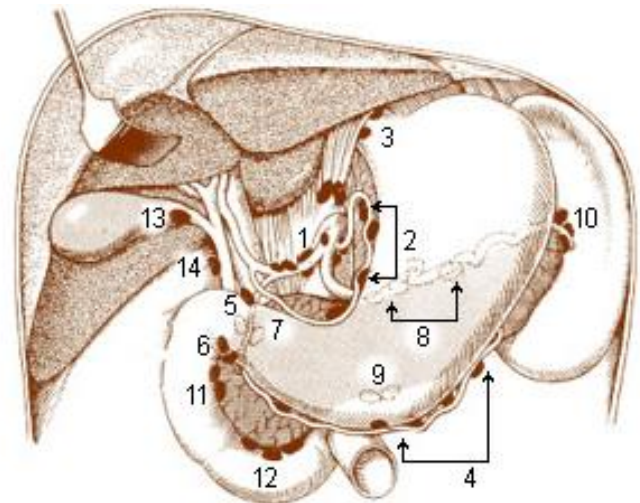
Fig. 2. Catchment lymphatic nodes of stomach.



Liver and biliary tree

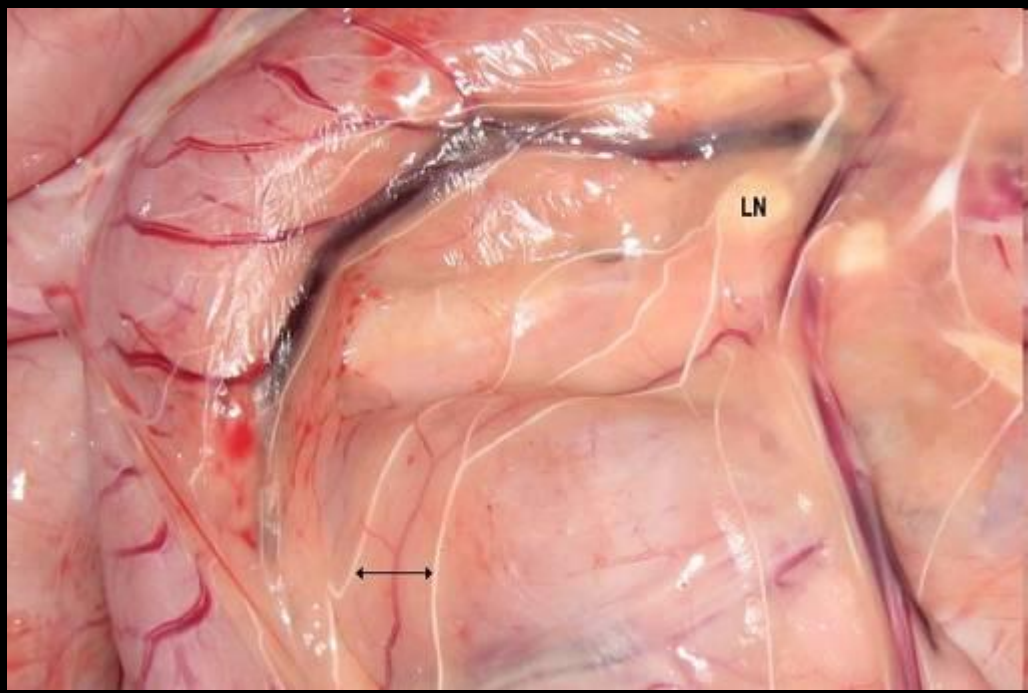
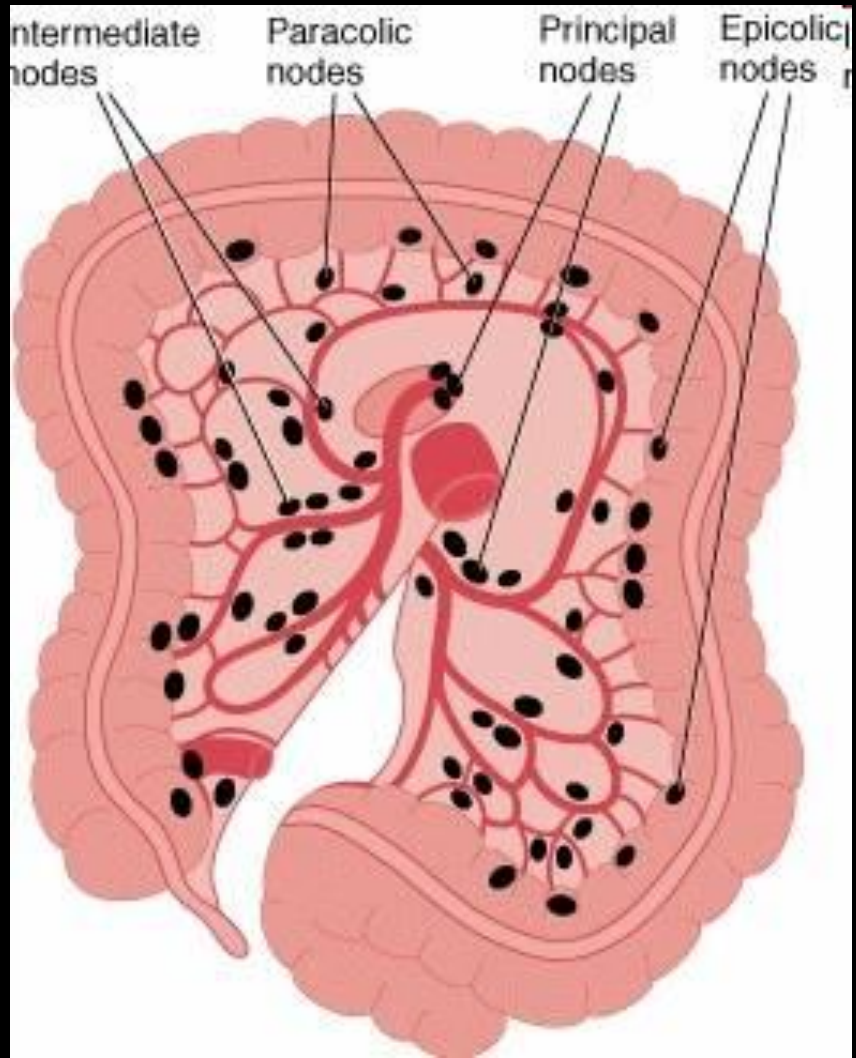
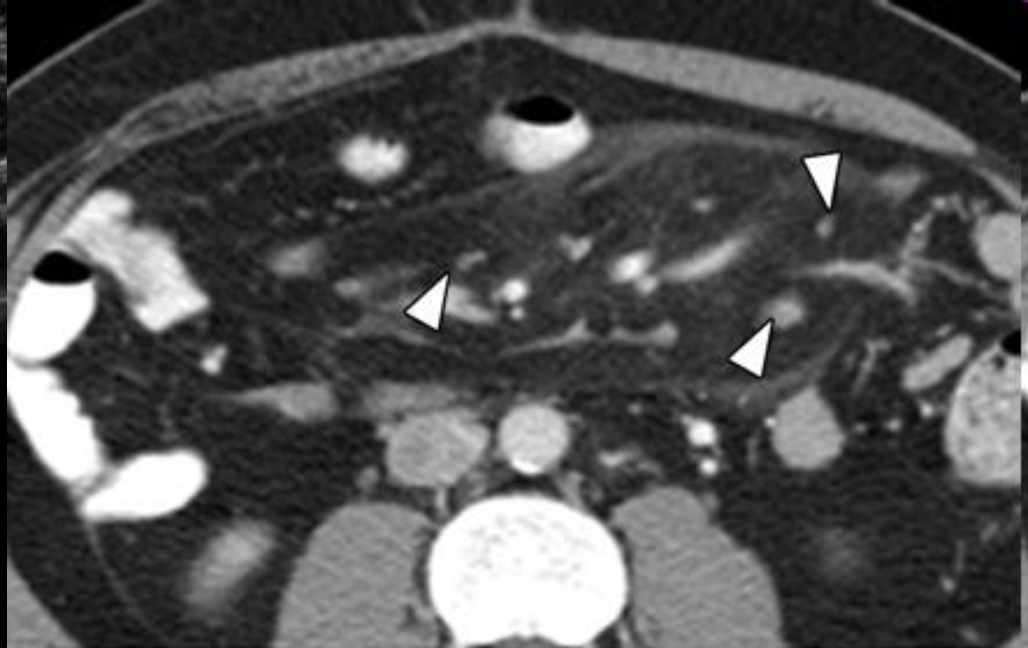
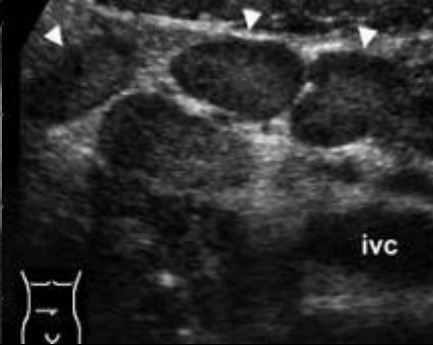
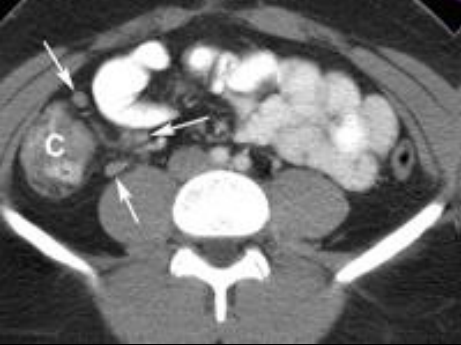
n.l. hepatici

- along a. hepatica communis + propria (3-6)
- lymph from stomach, spleen, duodenum, pancreas and liver
- n.l. foraminalis (at foramen omentale)
- n.l. cysticus (within recess of collum vesicae biliaris in site of ductus cysticus et hepaticus communis junction)

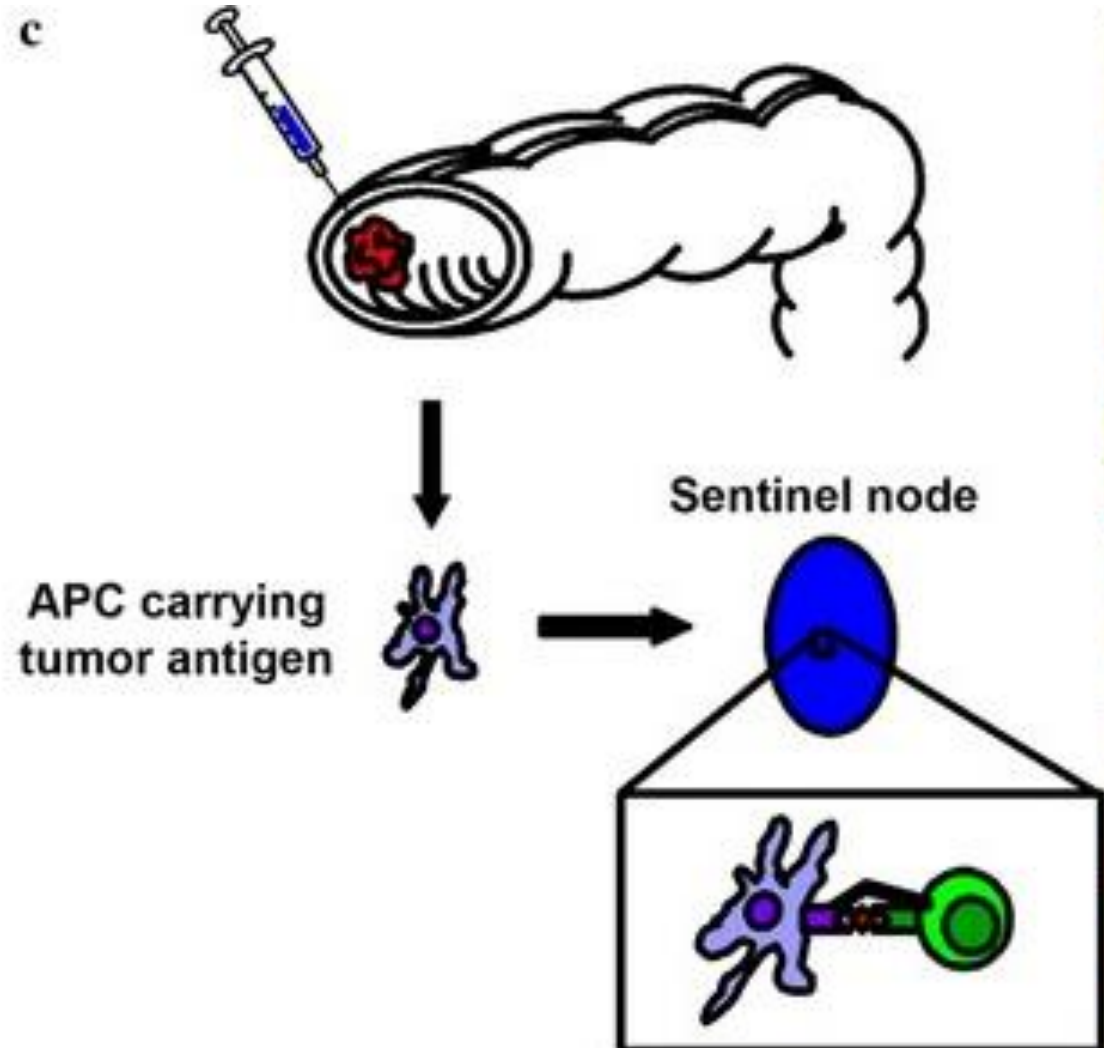
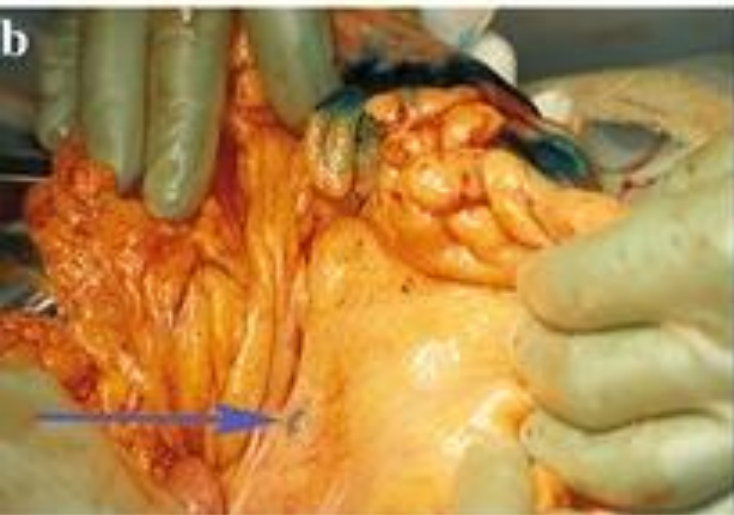
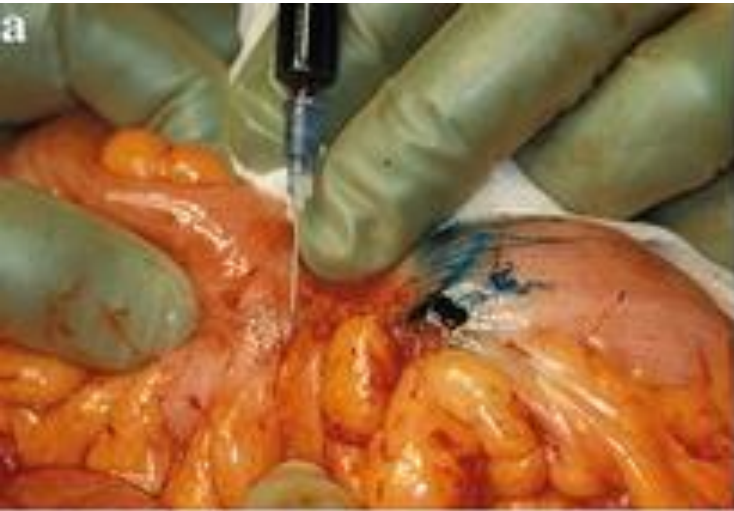
Gut

- **3 rows** → nodi coeliaci, nodi lumbales
- small intestine
 - n.l. juxtaintestinales (at intestinal wall)
 - (n.l. intermedii)
 - n.l. mesenterici superiores centrales (within radix mesenterii at trunk of AMS)
- **large intestine**
 - within mesocolon and behind peritoneum parietale
 - n.l. epicolici (by intestinal wall)
 - n.l. paracolici (along vasa marginalia coli)
 - n.l. intermedii
 - n.l. mesenterici inferiores centrales
 - *tumour metastases via venous blood into liver !!!*



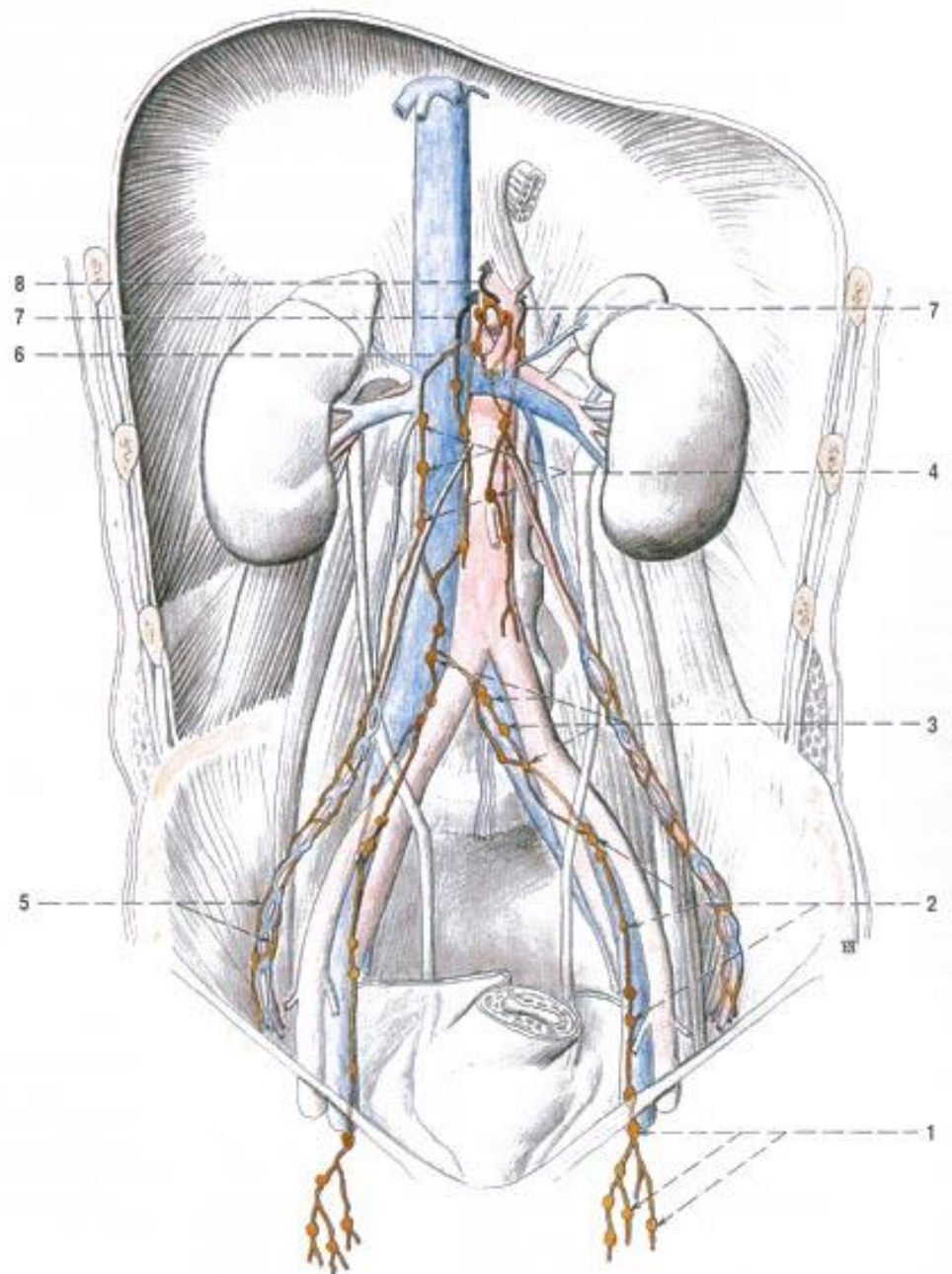
Sentinel lymph node – *Patent blue*



Testis ♂

Ovary ♀

- **n.l. lumbales**
 - L2 – development
 - scrotum → n.l. inguinales superficiales
- ! *no puncture* !**



Ohr. 138. NODI ILIACI EXTERNI ET NODI LUMBALES

1 nodi inguinales superficiales et profundi
2 nodi iliaci externi
3 nodi iliaci communes
4 nodi lumbales

5 mízní kolektory z varle / ovaria, jdoucí podél vasa testicularia / ovarica do nodi lumbales
6 nodi coeliaci
7 odtok mízy cestou truncus lumbalis do cisterna chyli
8 odtok mízy cestou truncus lumbalis do cisterna chyli

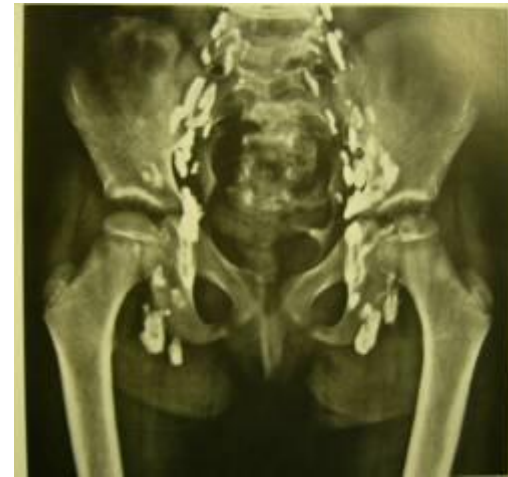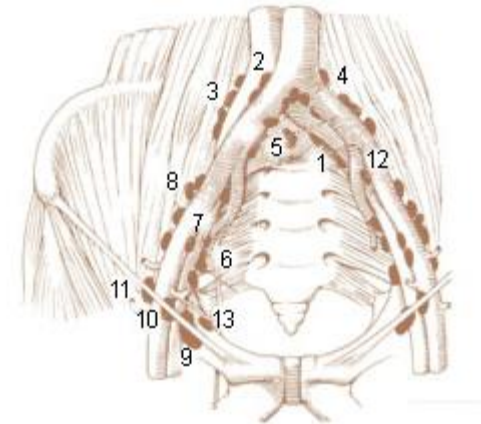
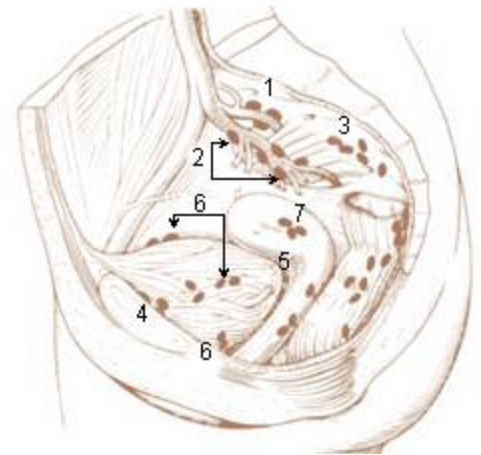
Pelvis

- n.l. parietales

- communes
- externi (obturatorii)
- interni
 - glutei sup.+inf.
 - sacrales (rectum, prostata, cervix uteri vaginae)

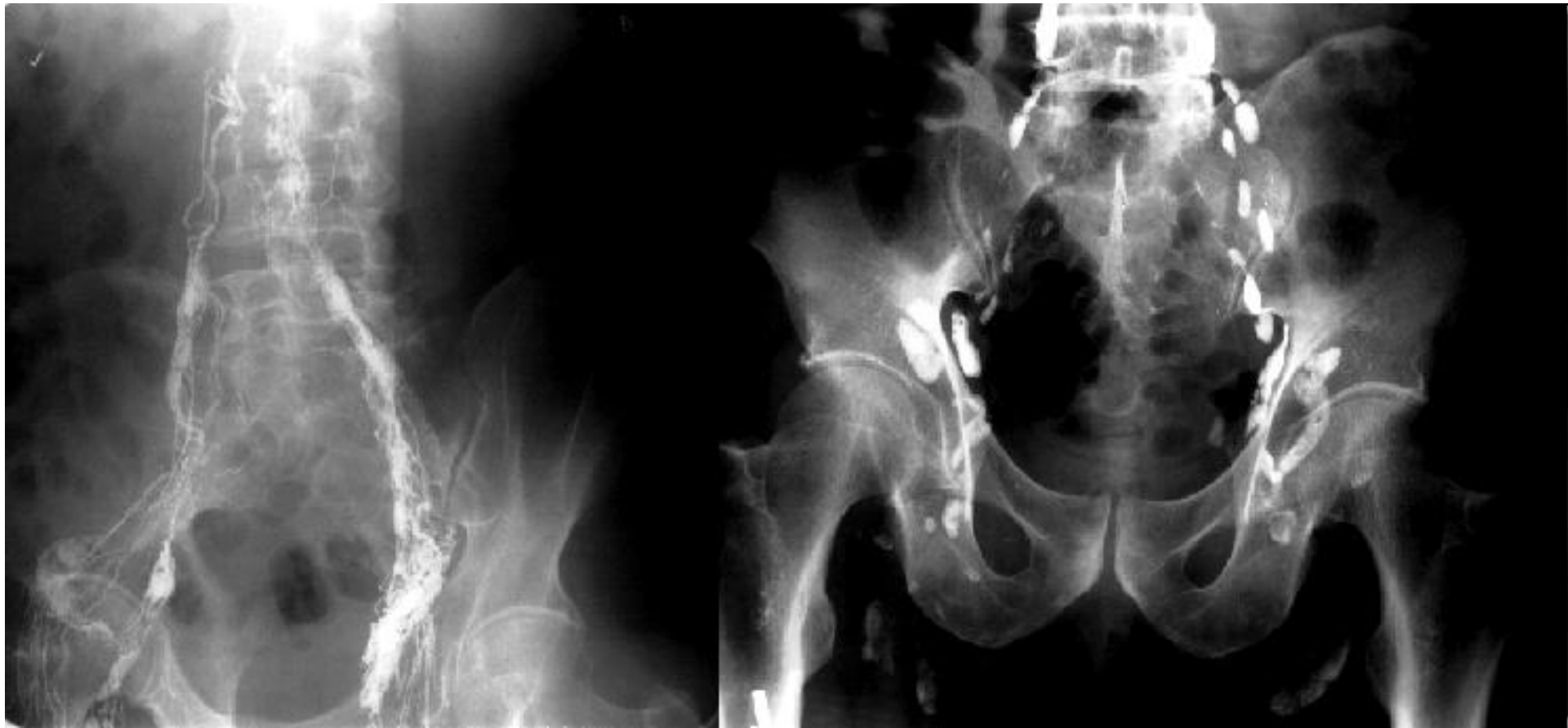- n.l. viscerales

- paravesicales
- parauterini ♀, paravaginales ♀
- pararectales



Abdomen and pelvis – clinical relevance

- lymphography
- para-aortal lymphadenectomy
- pelvic lymphadenectomy
 - classical (open) approach x laparoscopic



Uterus

anatomical classification:

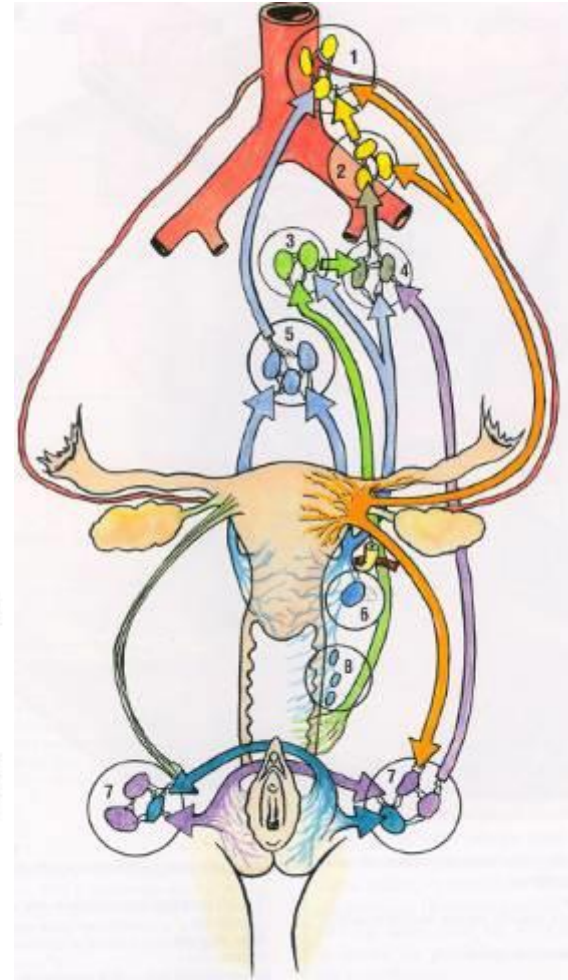
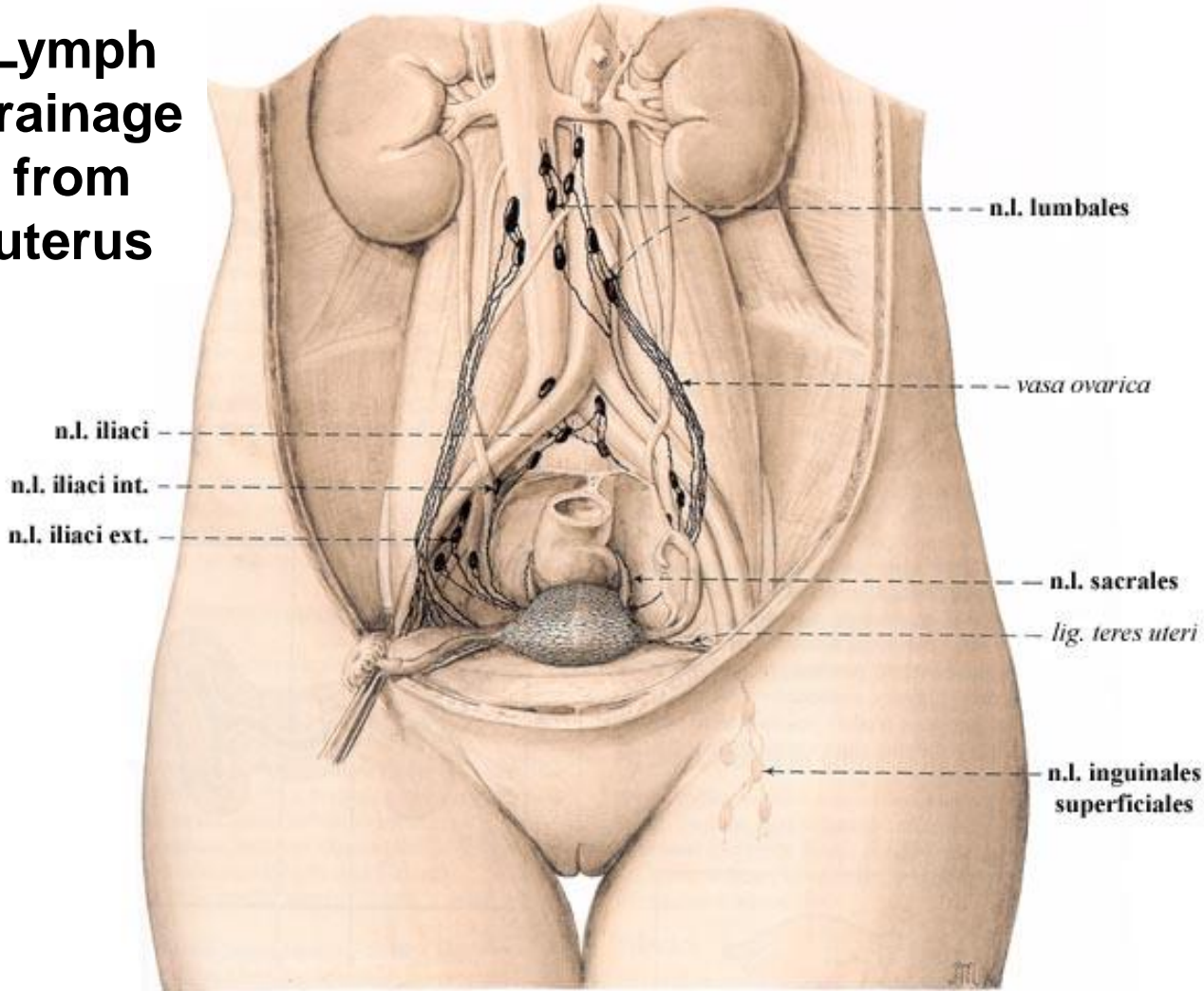
- n.l. lumbales ← fundus + corpus
- n.l. iliaci interni (iliaci externi, iliaci communes, obturatorii) ← corpus, isthmus + cervix
- n.l. sacrales ← isthmus, cervix
- n.l. inguinales superficiales ← margines + cornua (*rare!*)

clinical classification: according to corpus and cervix cancer

- corpus uteri → n.l. iliaci int.+ lumbales + (inguinales superficiales)
- cervix uteri → n.l. iliaci int.+ sacrales

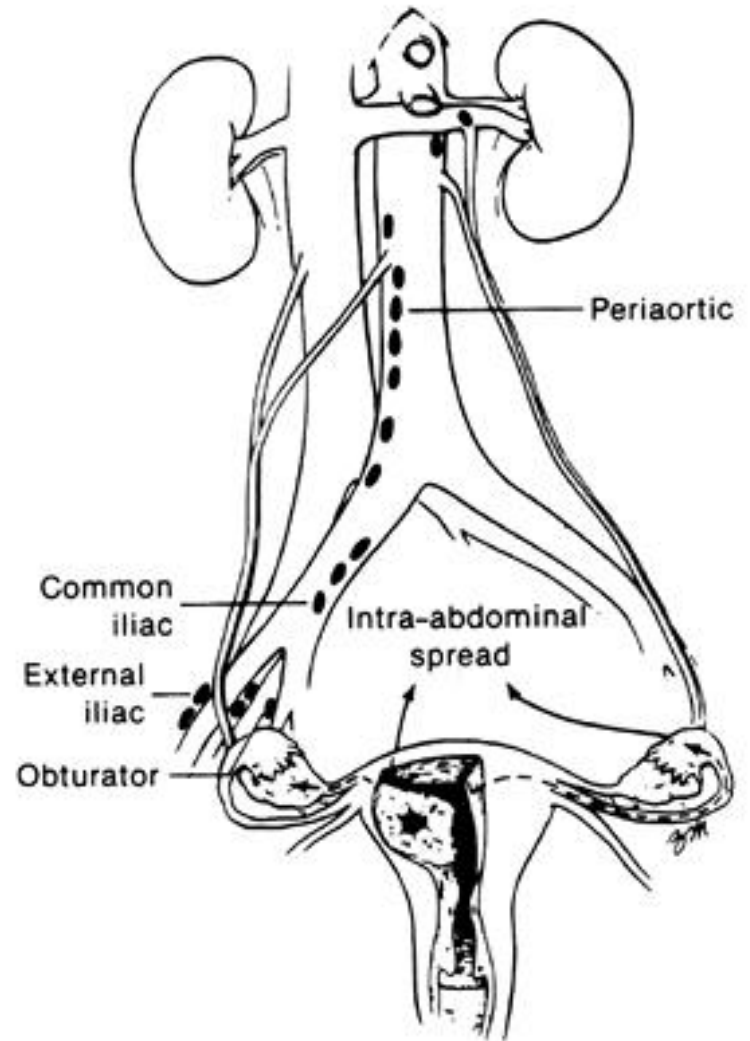
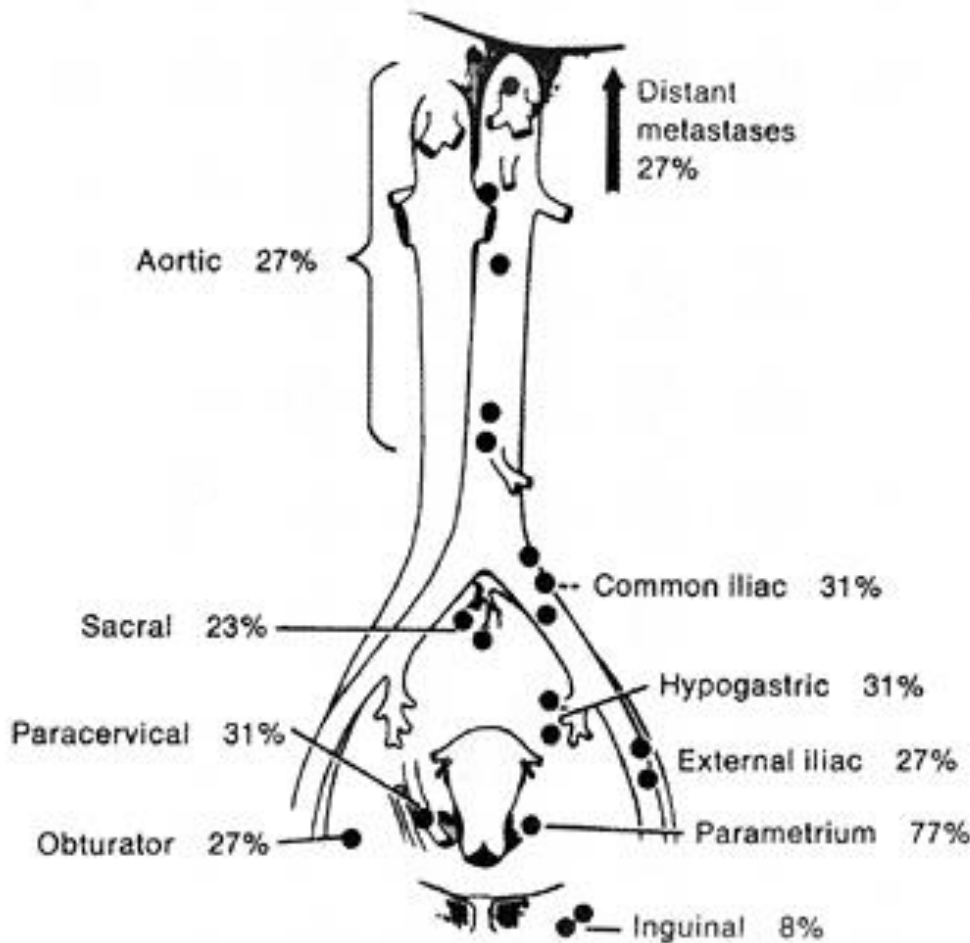
Uterus

Lymph drainage from uterus



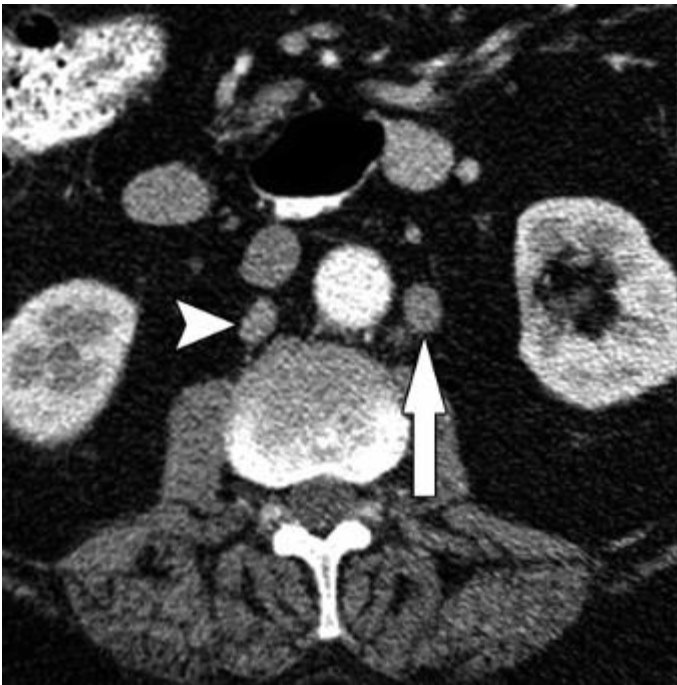Cervix cancer

Lymph nodes involvement

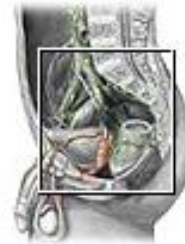

Prostate

- n.l. iliaci int. + ext.
- n.l. sacrales



Lymph vessels and nodes of pelvis

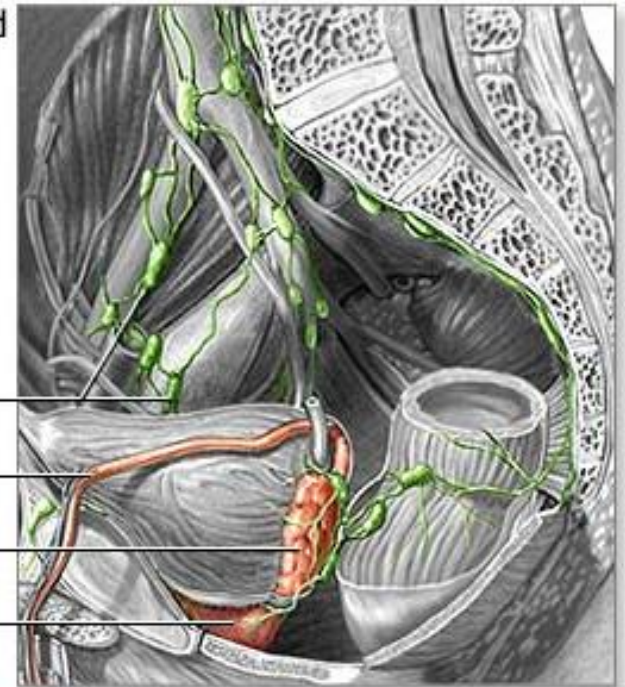


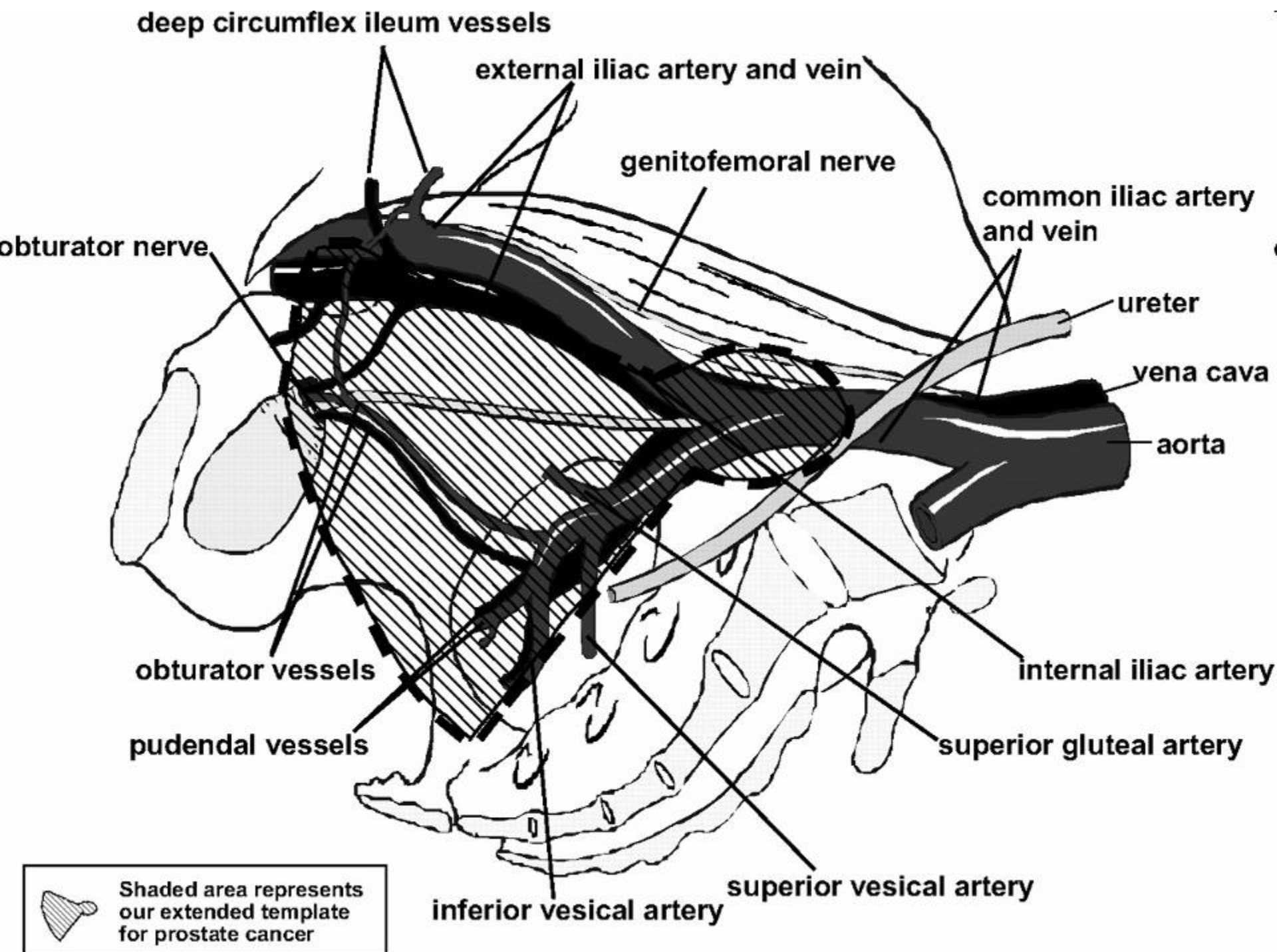
Lymph nodes

Vas deferens

Seminal vesicle

Prostate gland





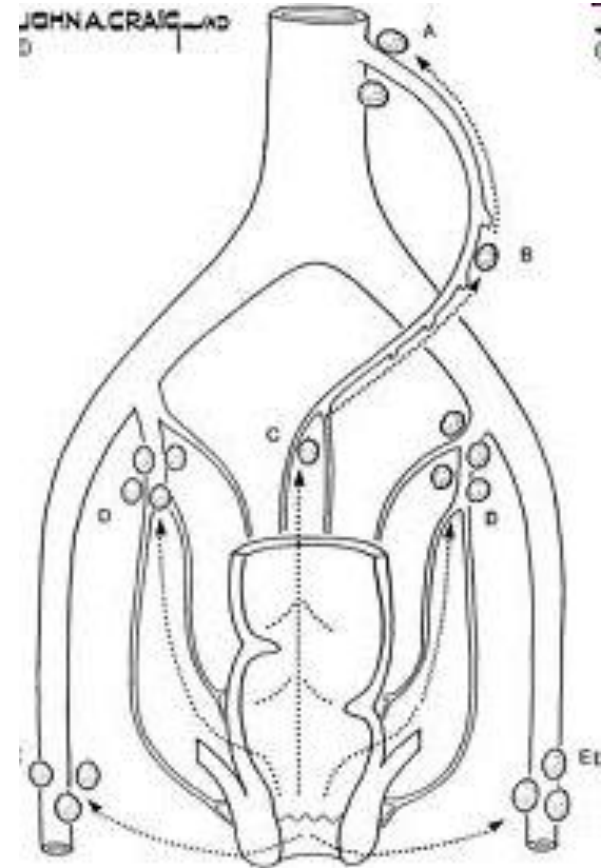
Rectum + anal canal

- ampulla

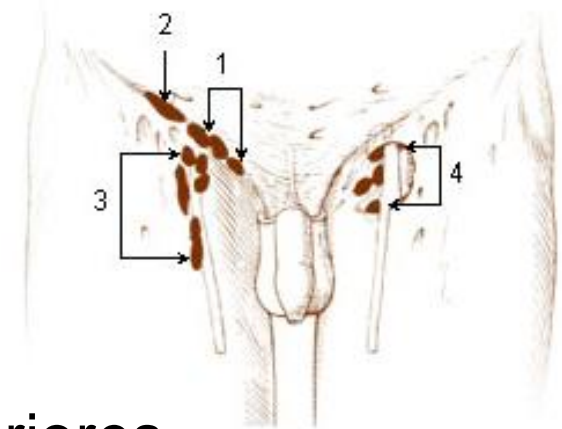
- oral part: → n.l. rectales sup.
→ n.l. mesenterici inf.
- aboral part: → n.l. pararectales → n.l. iliaci interni
- *n.l. obturatorii, sacrales*

- canalis analis

- n.l. pararectales + n.l. inguinales superficiales



Groins (*Inguen*)



- n.l. inguinales

- trigonum inguinales + fossa iliopectinea

- superficiales (8-12)

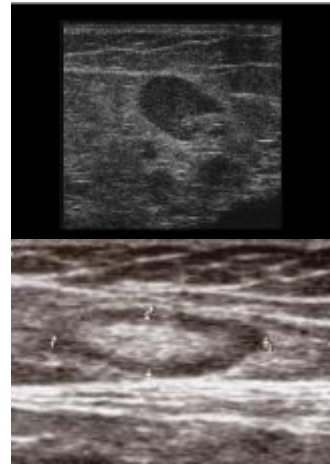- superomediales, superolaterales, inferiores
- whole lower limb without posterior side of leg
- surrounding skin, hypodermis of regio glutea, perineum, anus, penis/clitoris, vestibulum vaginae, scrotum/labia majora pudendi, lower ventral abdominal wall, cornua uteri

- Cabanas' node (superomedial) – sentinel for penis cancer

- profundi (2-5)

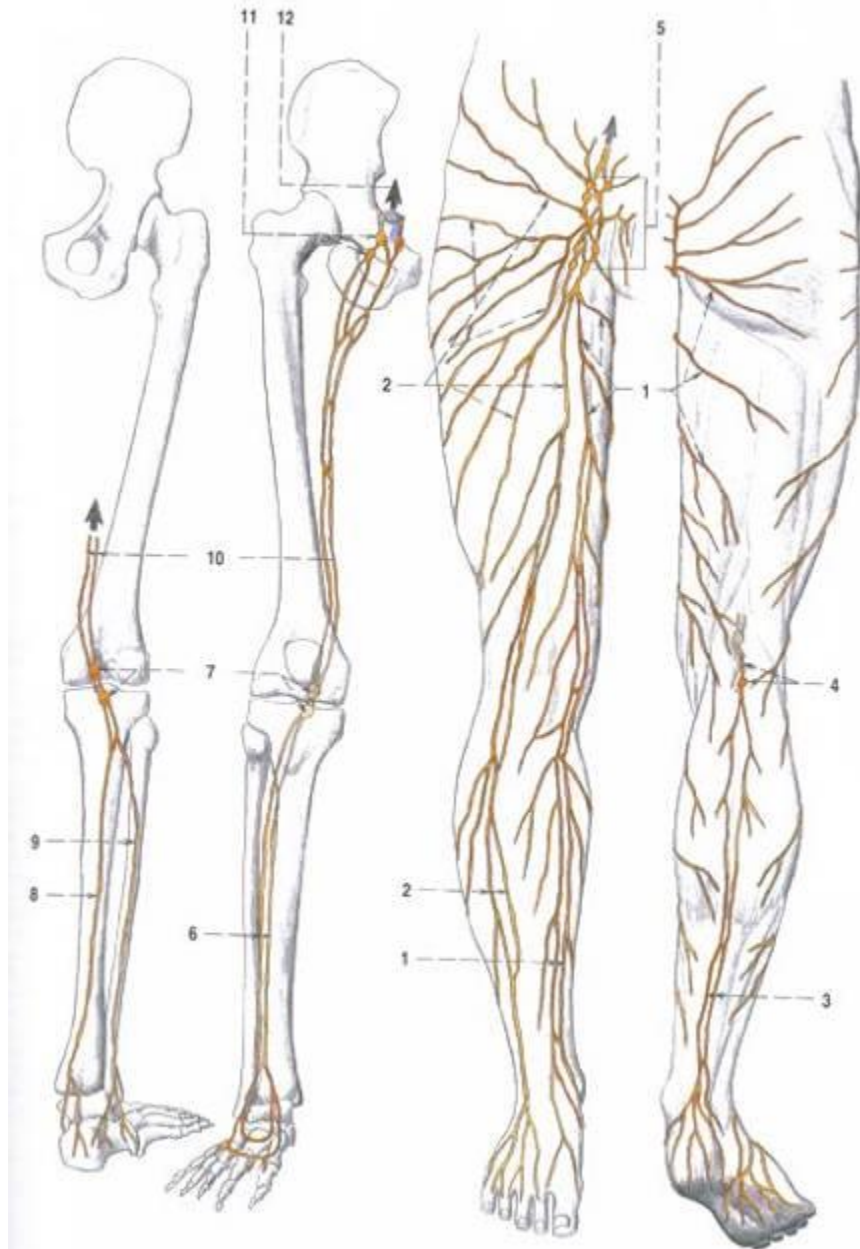
- Cloquet-Rosenmüller's node – nodus proximalis within lacuna vasorum (CLOVAN)

- *bubonic from of pest* 😊



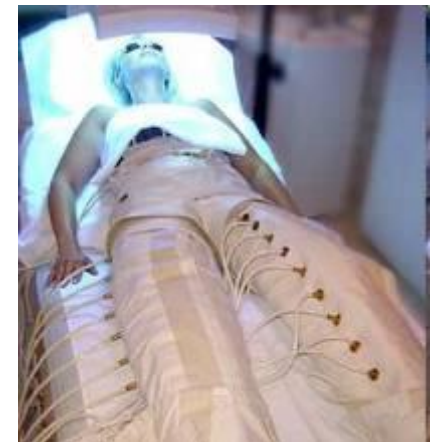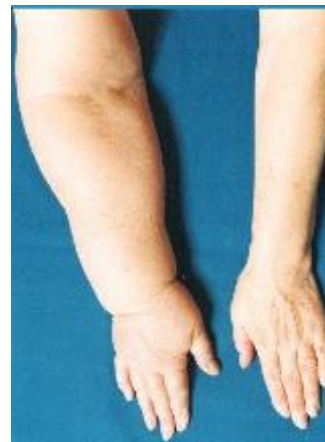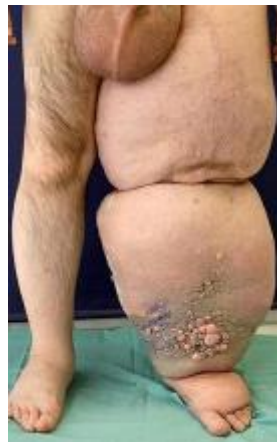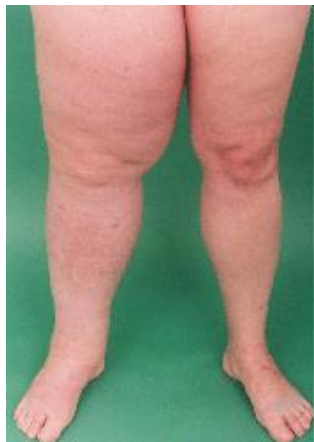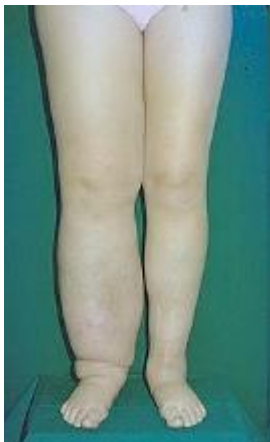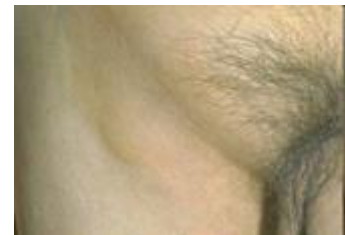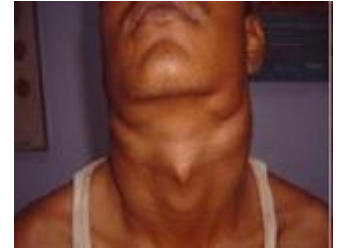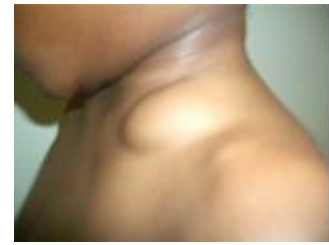- deep
 - along deep vessels
 - n.l. poplitei profundi → n.l. inguinales profundi
- superficial
 - approximately along superficial veins
 - 3 collectors (groups of collectors)
 - medial (10-15)
 - into n.l. inguinales superficiales along v. saphena magna
 - lateral (1-3)
 - into n.l. inguinales superficiales along tributaries of v. saphena magna
 - dorsal (2-3)
 - into n.l. poplitei superficiales along v. saphena parva
- n.l. poplitei
 - profundi
 - tibialis ant. + post., fibularis
 - superficiales

LL – collectors

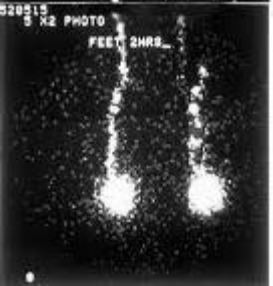
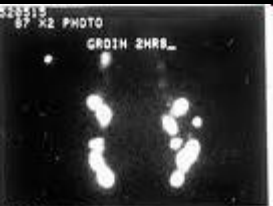
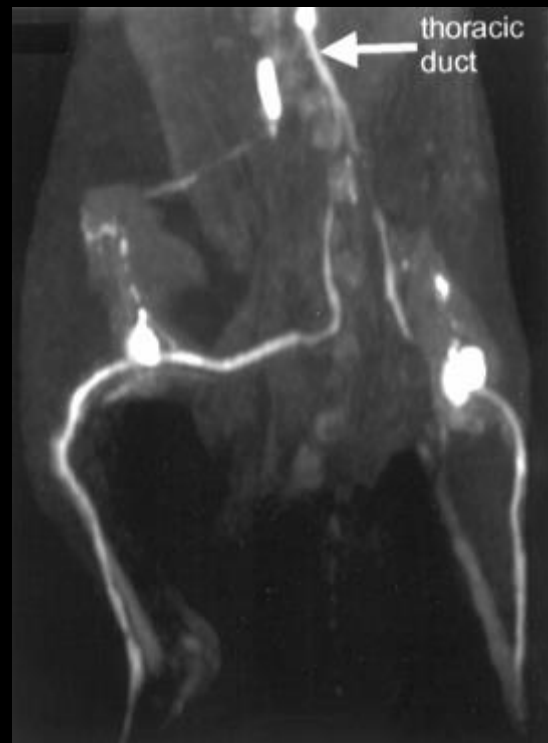
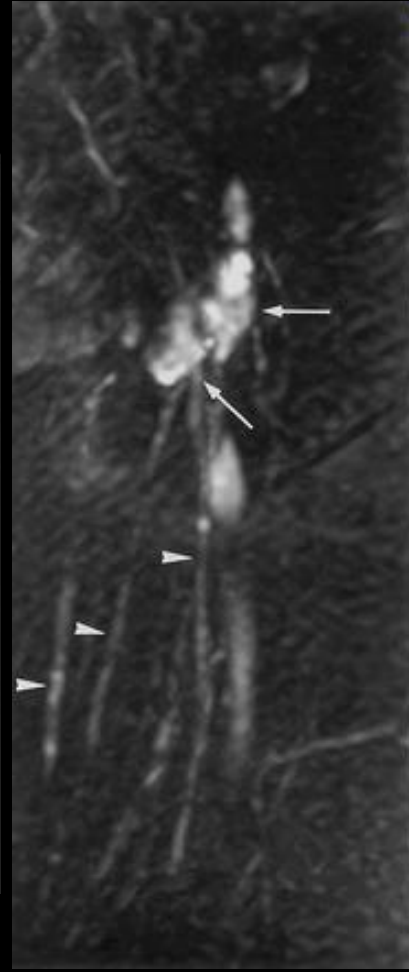
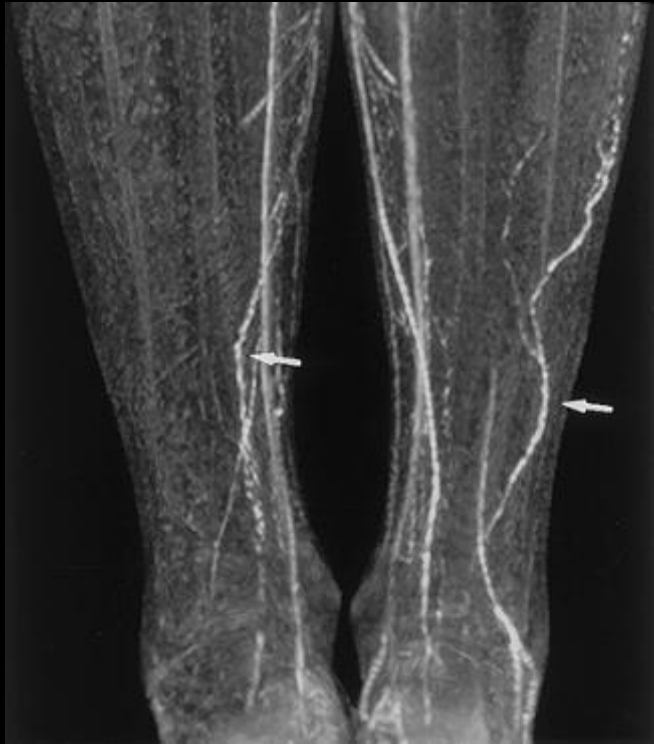
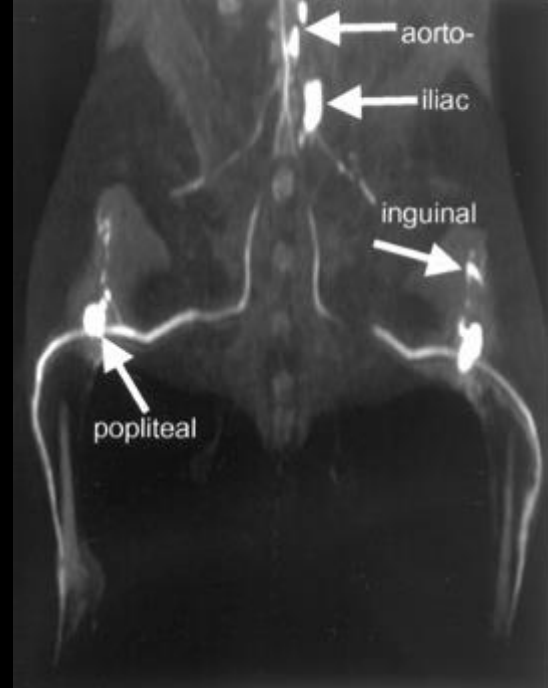
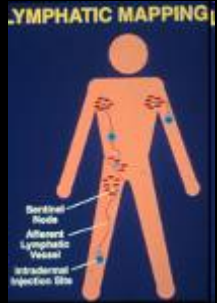Examination

- routine physical examination
 - cervical, axillary, inguinal
- *lymphadenopathy*
- *lymphadenitis*
- *lymphedema*
 - *tumour, postoperative, erysipiel, filariosis*



Lymphography Lymphoscintigraphy



Non-capsulated lymphoid tissue

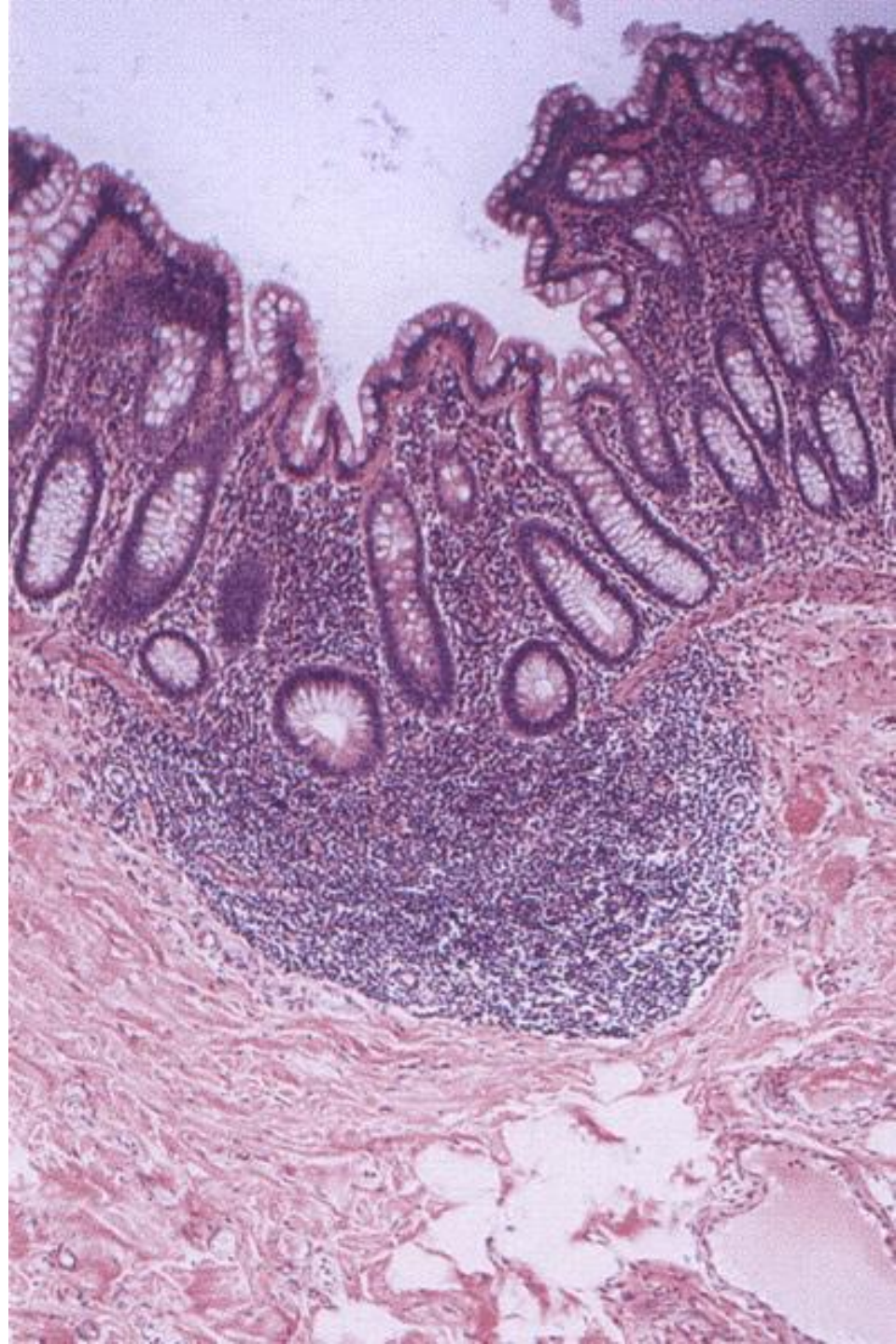
- **D-MALT** (diffuse mucosa-associated lymphoid tissue) – diffuse cells in GIT
- **O-MALT** (organized mucosa-associated lymphoid tissue)
 - **GALT** (gut-ALT) – n.l. in GIT
 - „gut is the largest immune organ“
 - nodi lymphoidei solitarii
 - nodi lymphoidei aggregati
 - ◆ agmina Peyeri – ileum
 - ◆ n.l. appendicis vermiformis caeci
 - **NALT** (nose-ALT) – nasal cavity
 - **BALT** (bronchus-ALT) – lower RT

Non-capsulated lymphoid tissue (O-MALT)

- **SALT/CALT** (skin/cutaneous-ALT) – keratinocytes, Langerhans' cells, mastocytes
- vesica urinaria
- vagina
- conjunctiva
- glandula mammaria

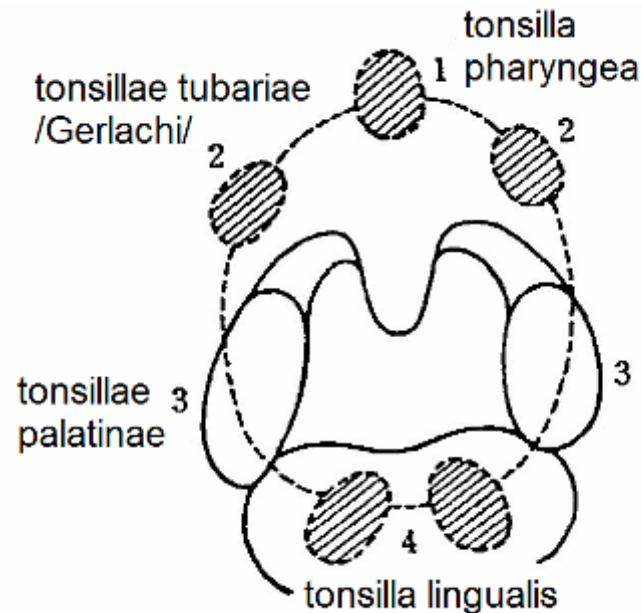
**Nodi
lymphoidei
aggregati
(ilei)**

seu
Agmina Peyeri



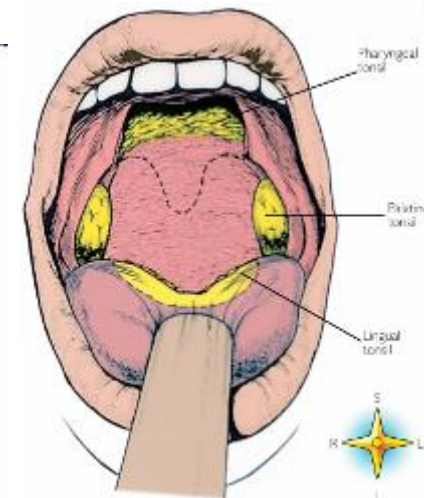
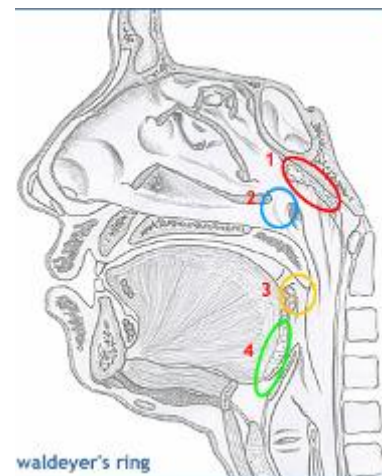
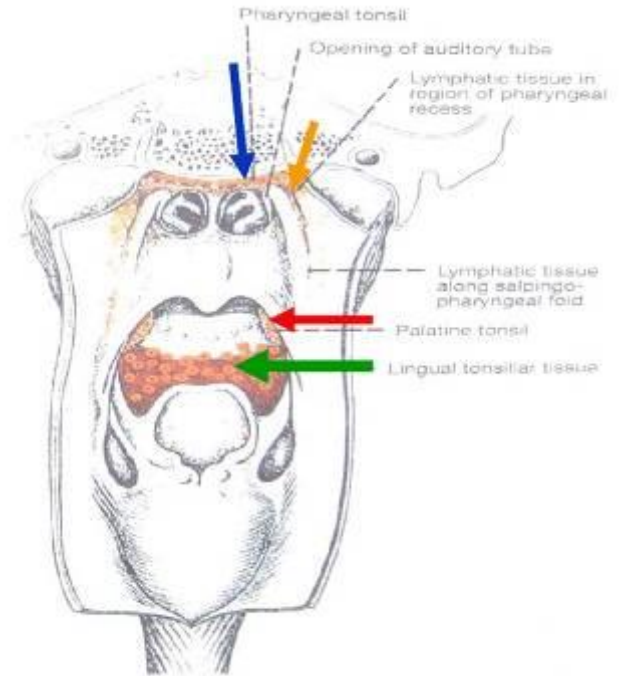
Tonsils (Tonsillae)

- aggregation of partially capsulated lymphoid tissue under epithelium
- frequent lymph nodules with germinal centers

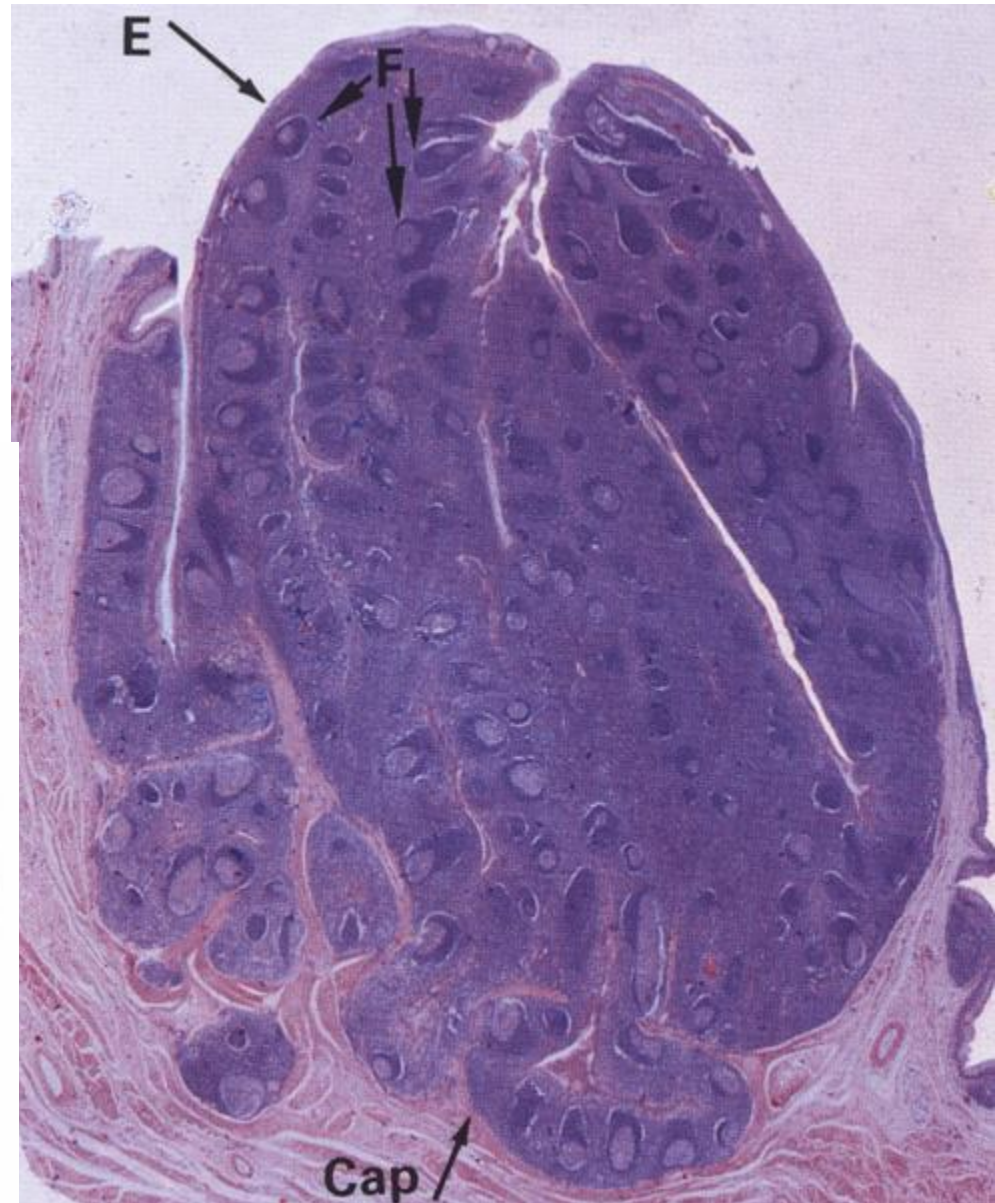
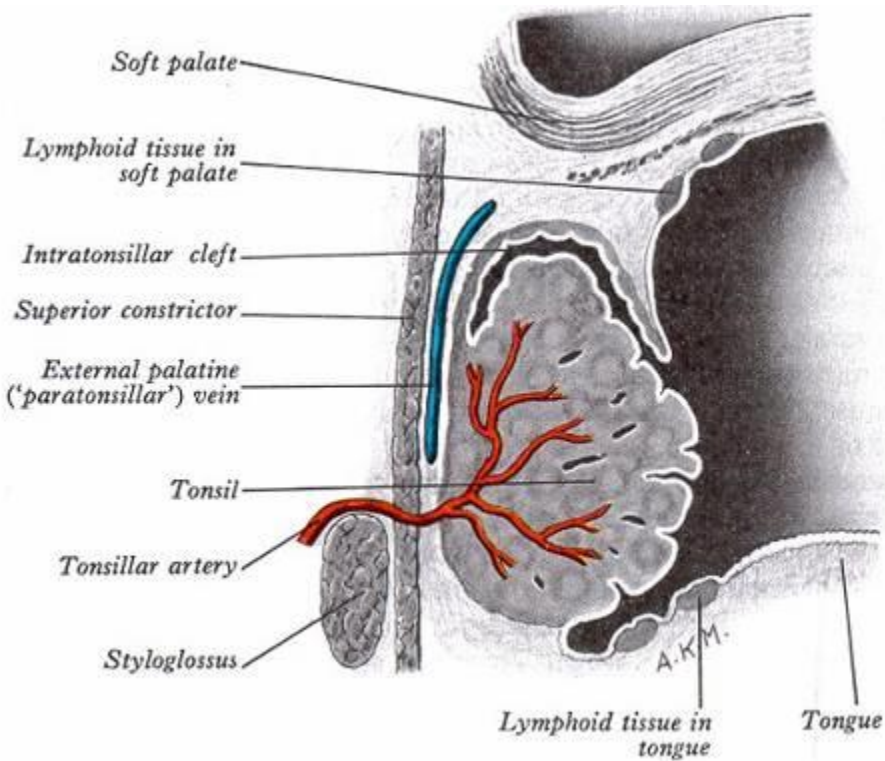


Anulus lymphoideus pharyngis Waldeyeri

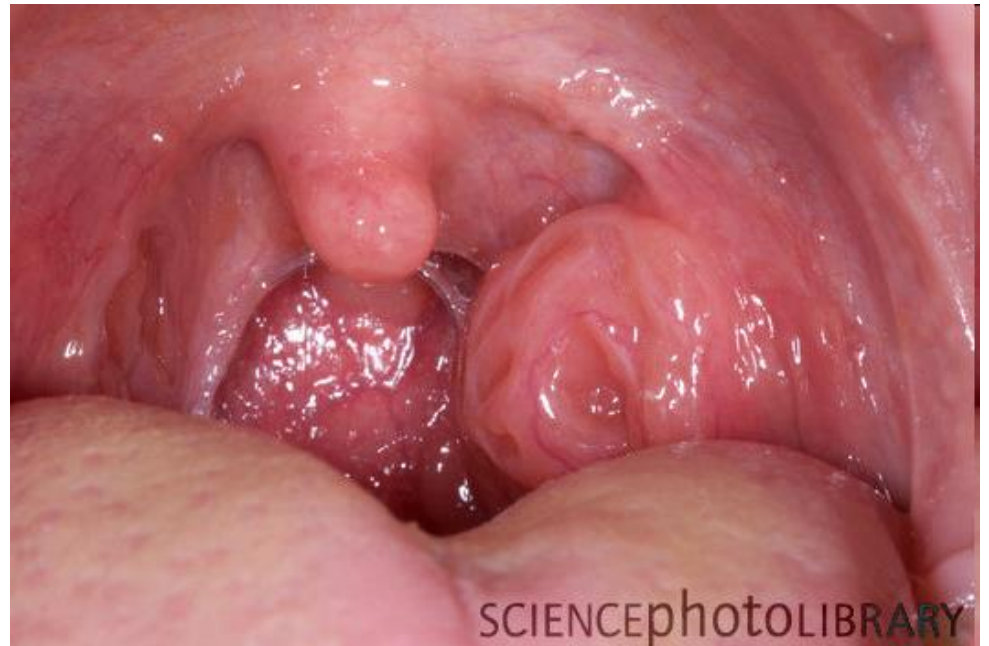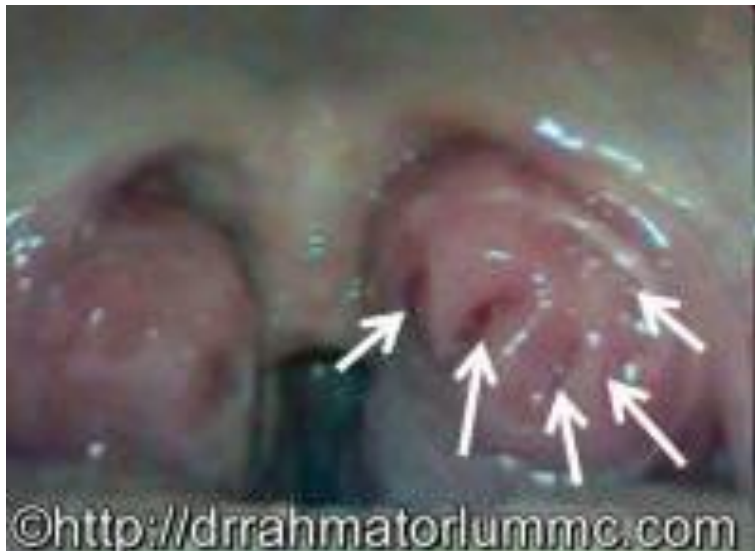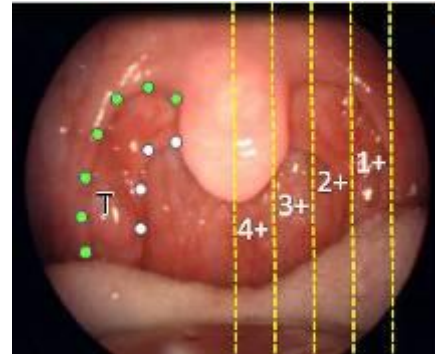
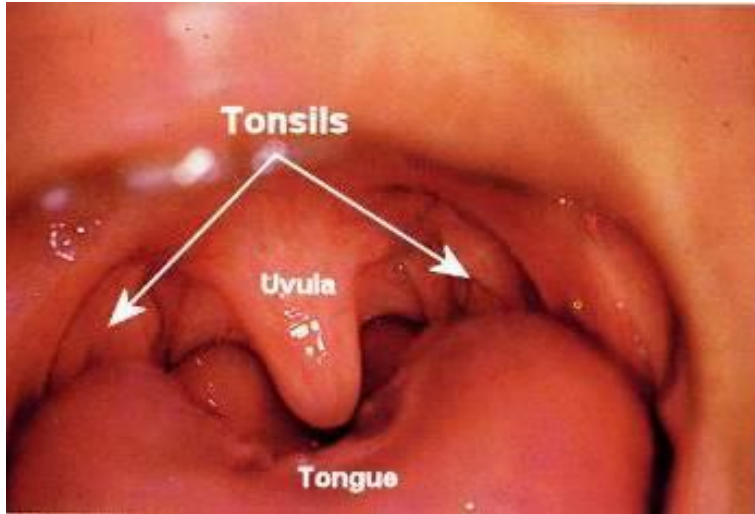
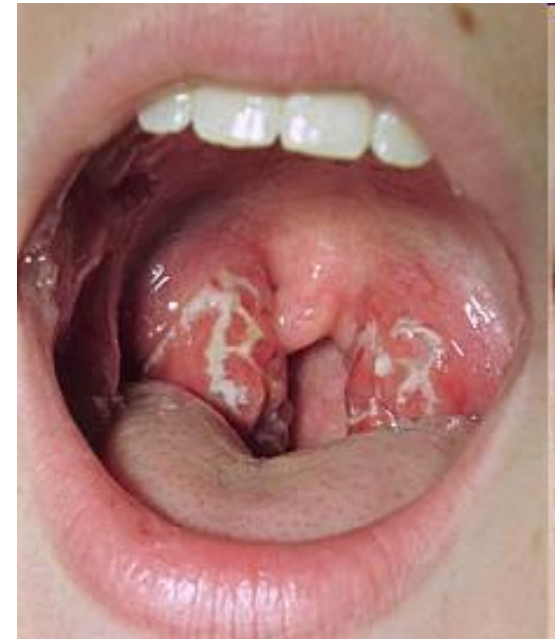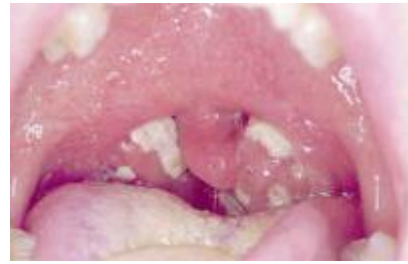- tonsilla **lingualis**
 - crypta, noduli
 - one lesser crypt
- tonsilla **palatina**
 - fossulae, cryptae, capsula
 - thick capsule
- tonsilla **pharyngea** = *adenoid vegetation*
 - fossulae, cryptae, noduli
 - no crypts, thin capsule
- tonsilla **tubaria** *Gerlachi*
 - cryptae

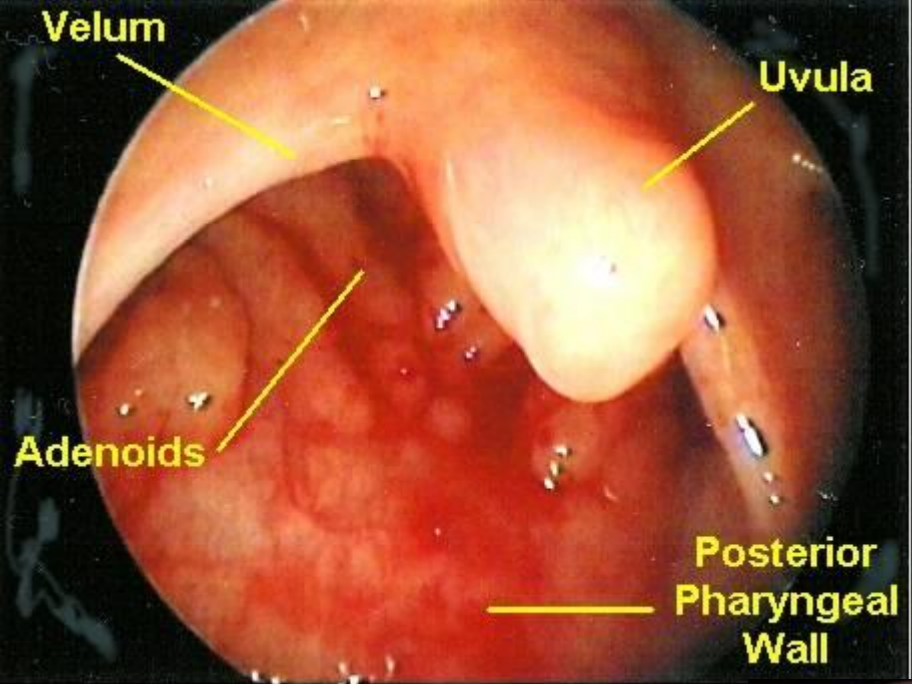


Tonsilla palatina

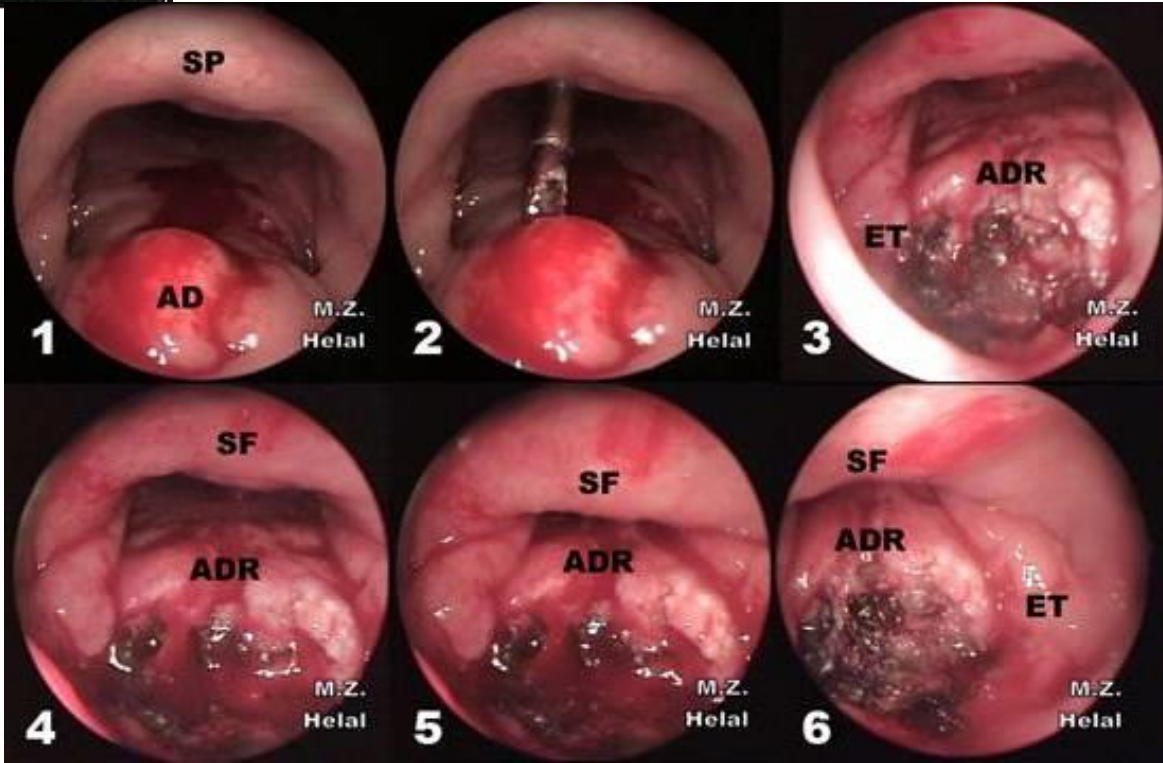
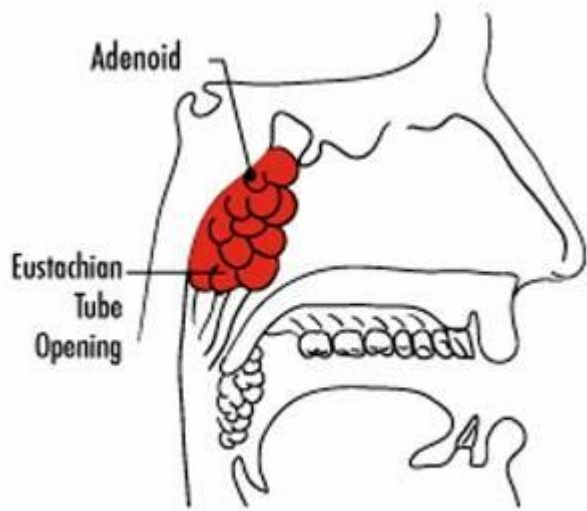


Tonsilla palatina

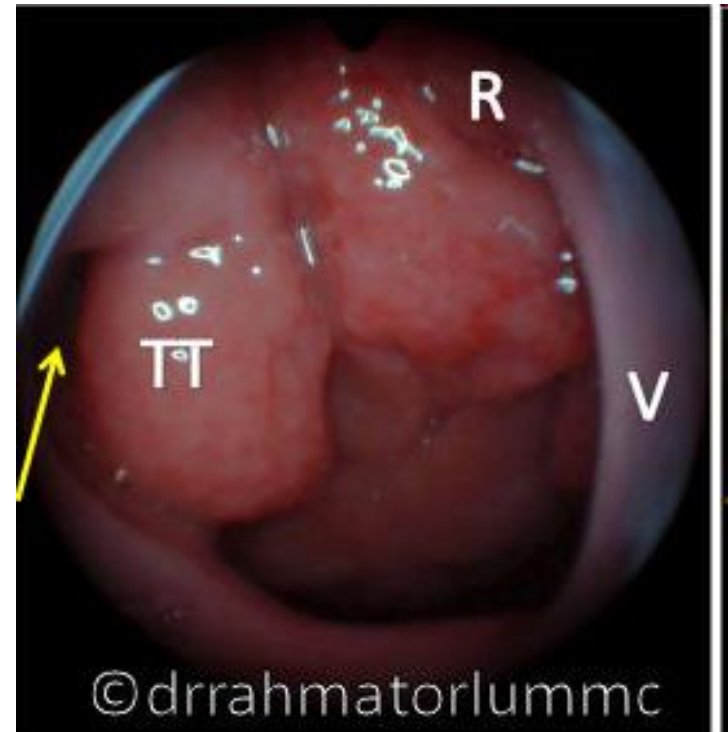
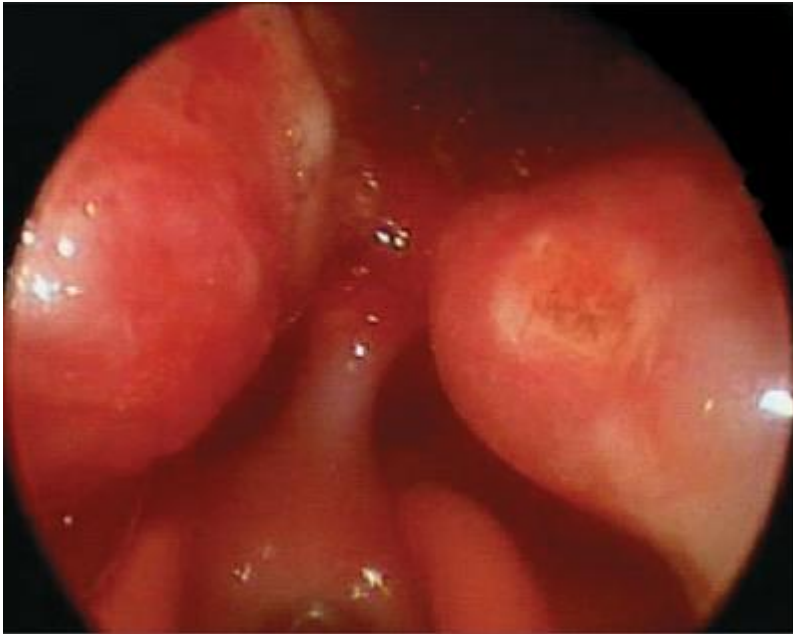



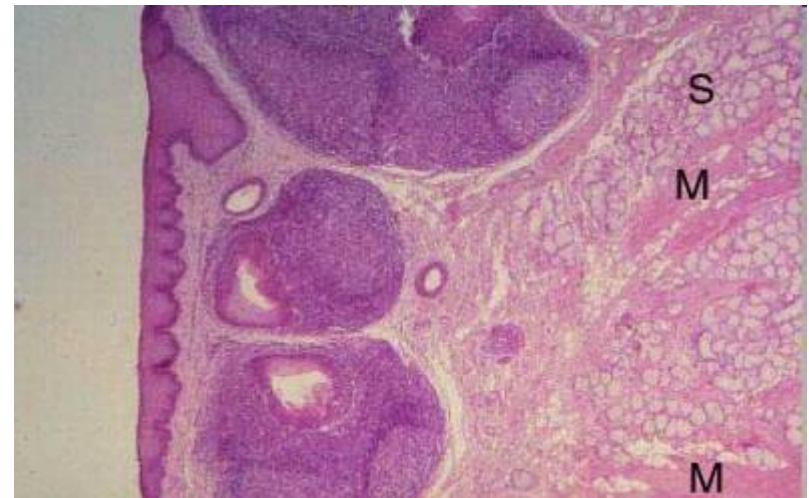
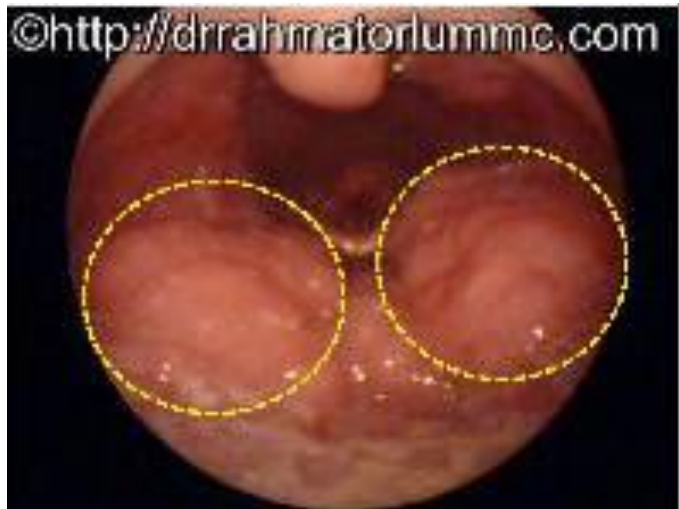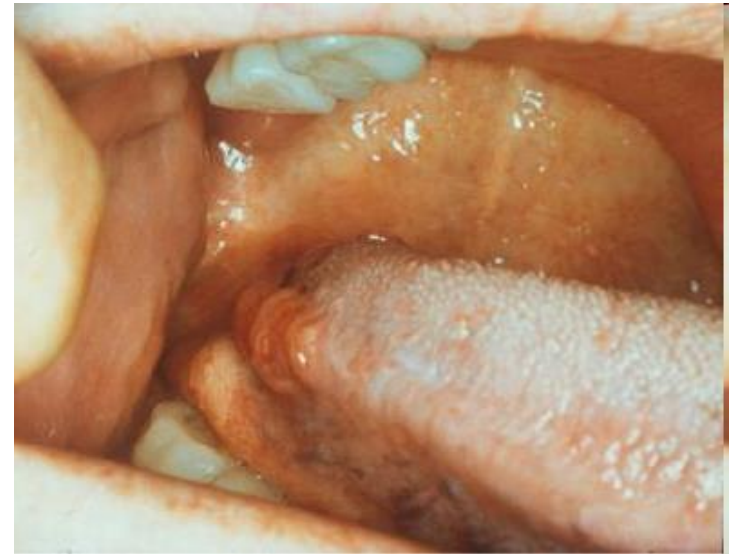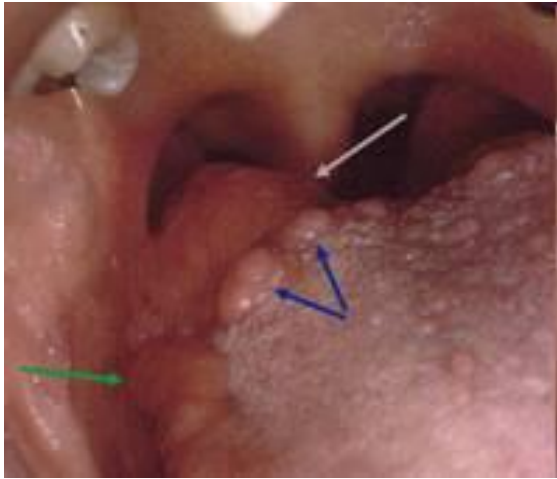
Tonsilla pharyngea



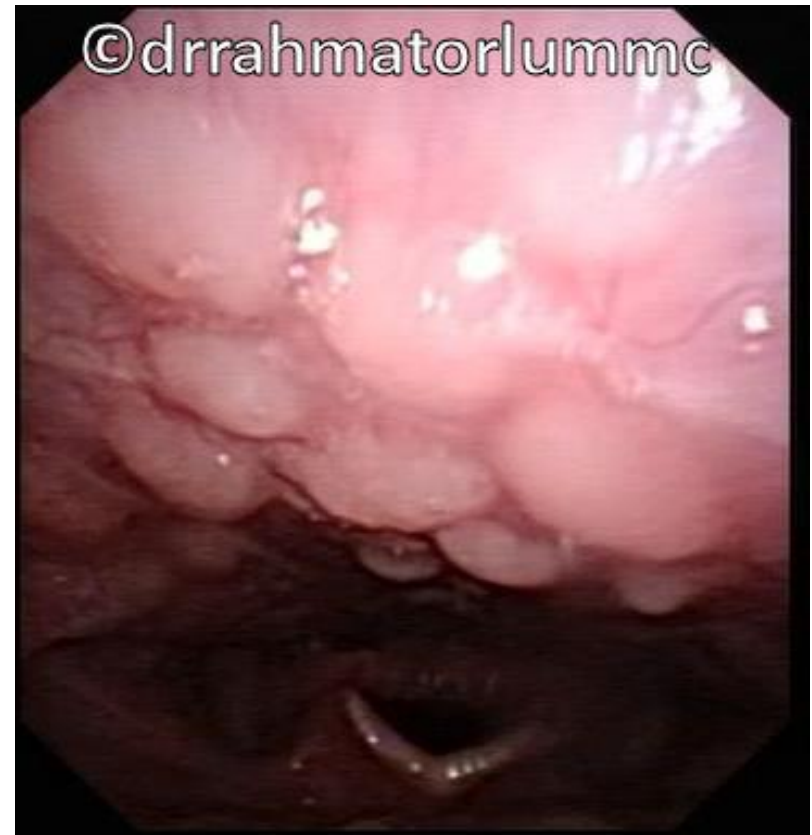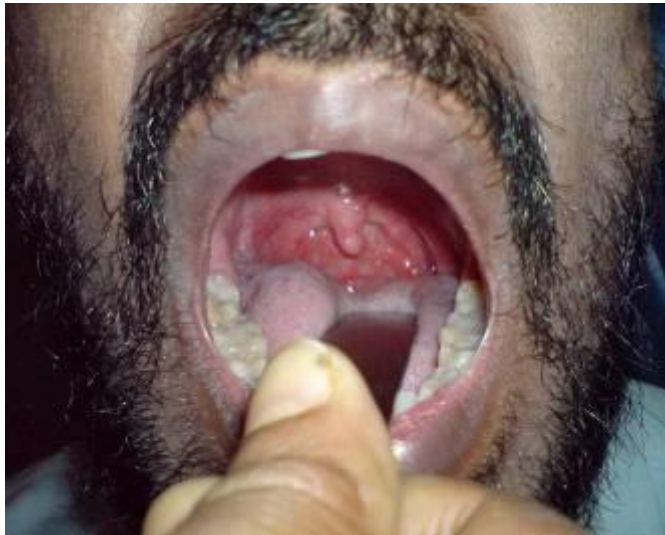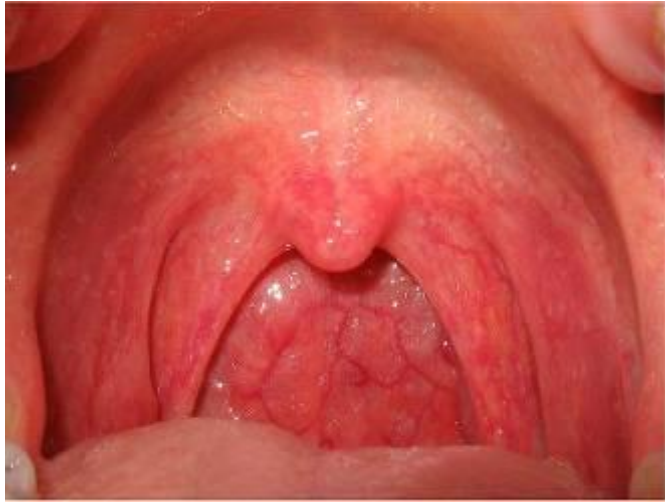Tonsilla tubaria



Tonsilla lingualis

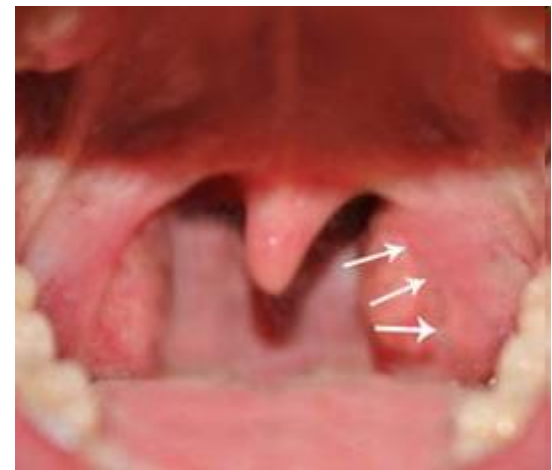

Lateral bands and posterior pharyngitis

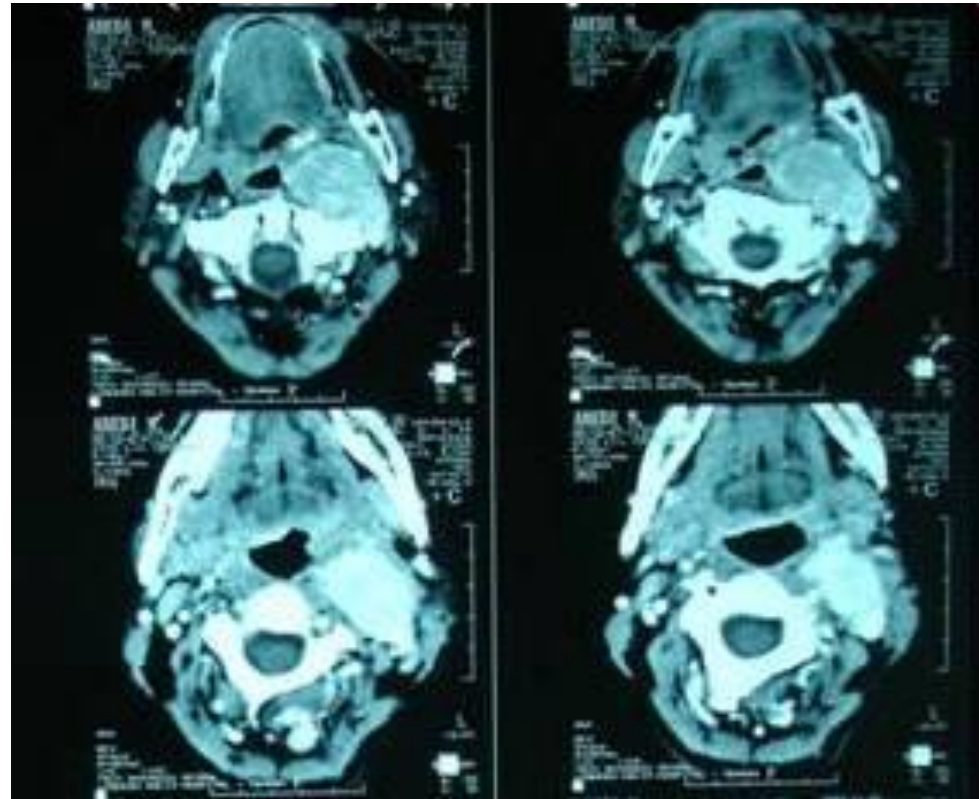
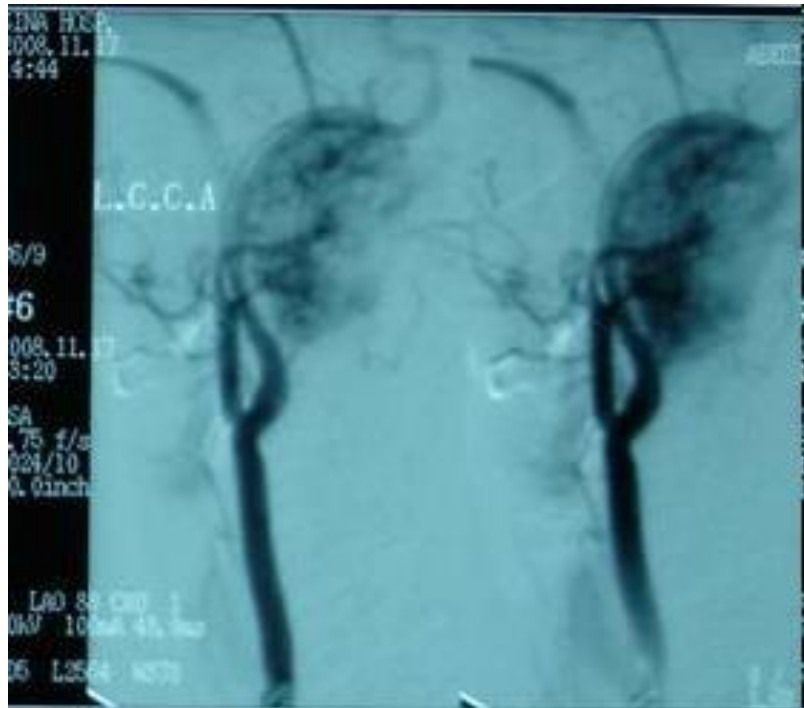


Case-report

- female, 41 years, Iran
- 8 month – dysphagia
- no inflammation in nasal cavity, oral cavity, pharynx, larynx
- no palpable lymph nodes in neck, no fever, no weight loss



Case-report



solution: **paraganglioma of n. X**