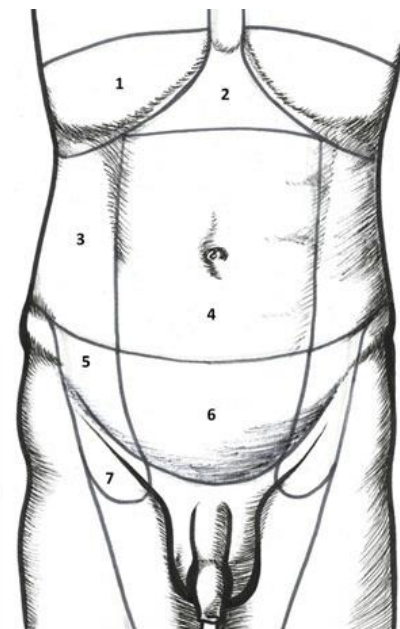
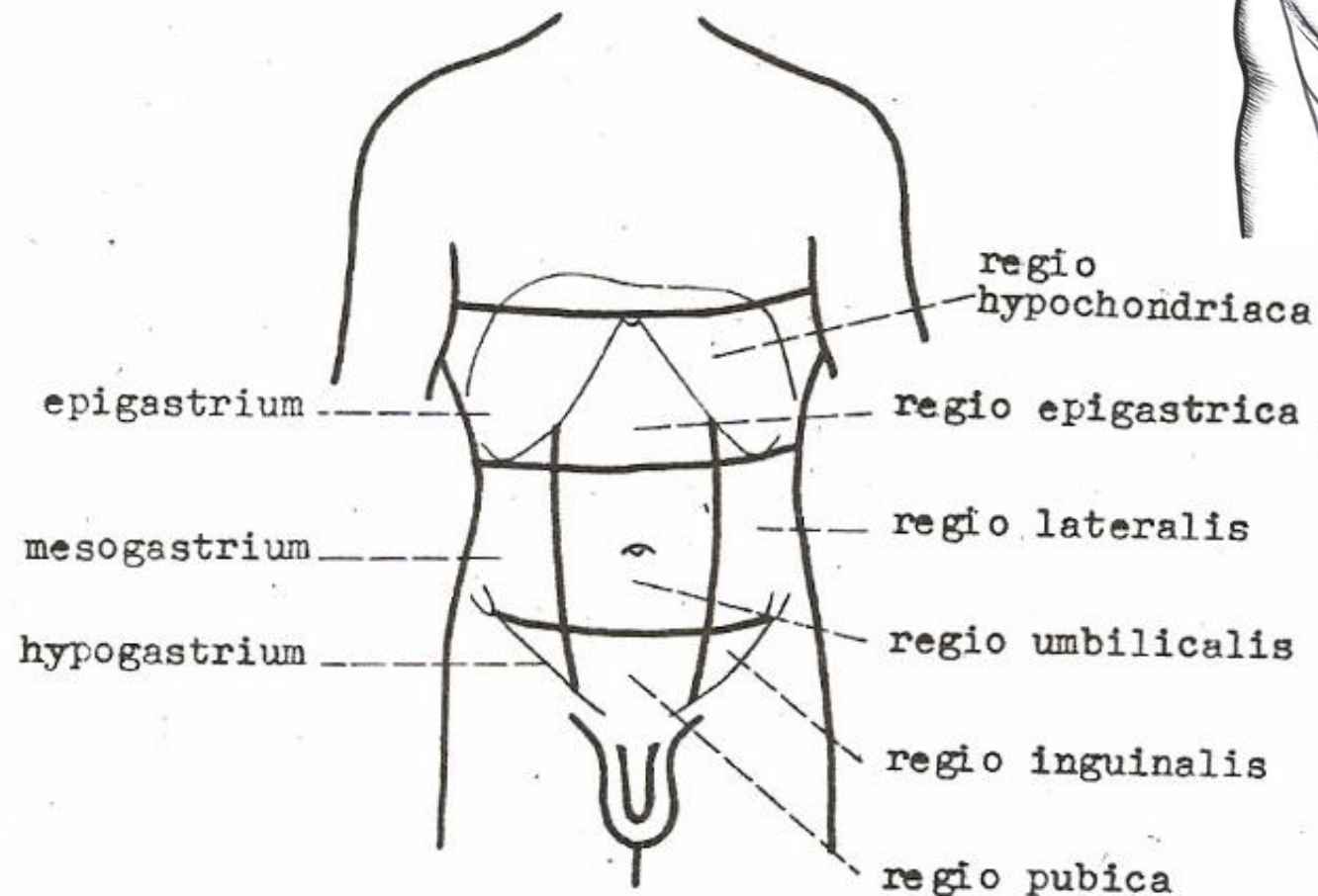


PERITONEUM

Regiones abdominis



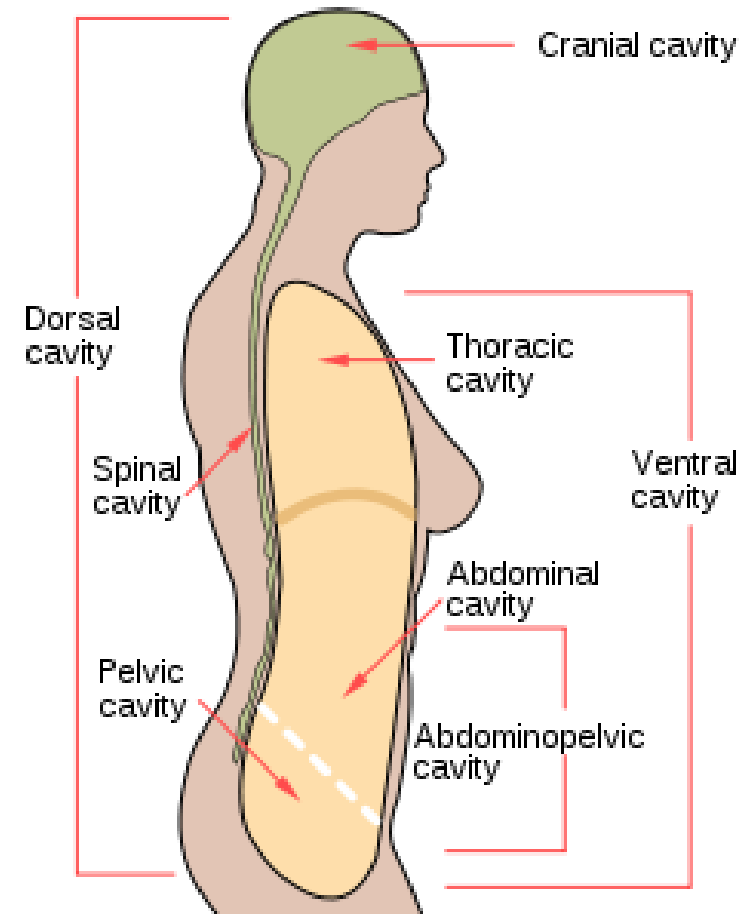
1. regio hypochondriaca dx.
2. regio epigastrica
3. regio lateralis dx.
4. regio umbilicalis
5. regio inguinalis dx.
6. regio pubica
7. regio subinguinalis dx.



Obr.49. Orientační čáry a krajiny na břiše.

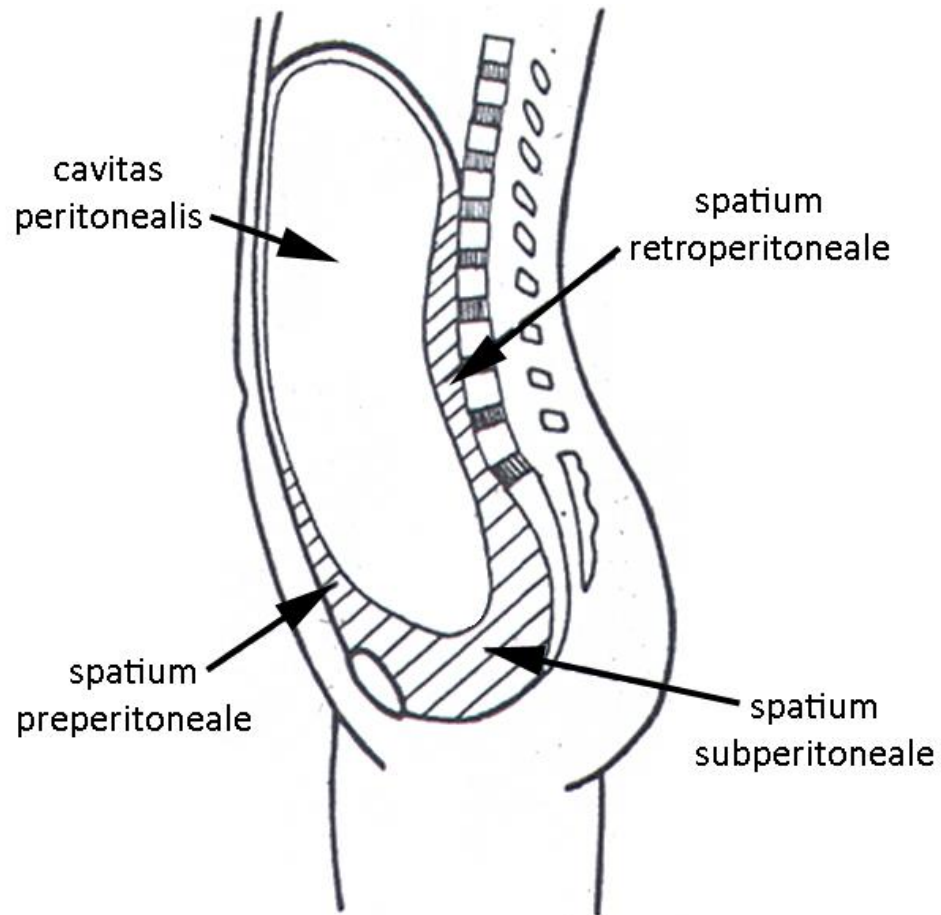
Principal division of abdominal cavity

- **cavitas abdominopelvica**
 - **cavitas abdominis**
 - **pelvis major**
(greater pelvis)
 - **cavitas pelvis = pelvis minor**
(lesser pelvis)



Principal division of abdominal cavity

- cavitas peritonealis
- spatium extraperitoneale
 - spatium retroperitoneale
 - spatium subperitoneale
 - spatium preperitoneale



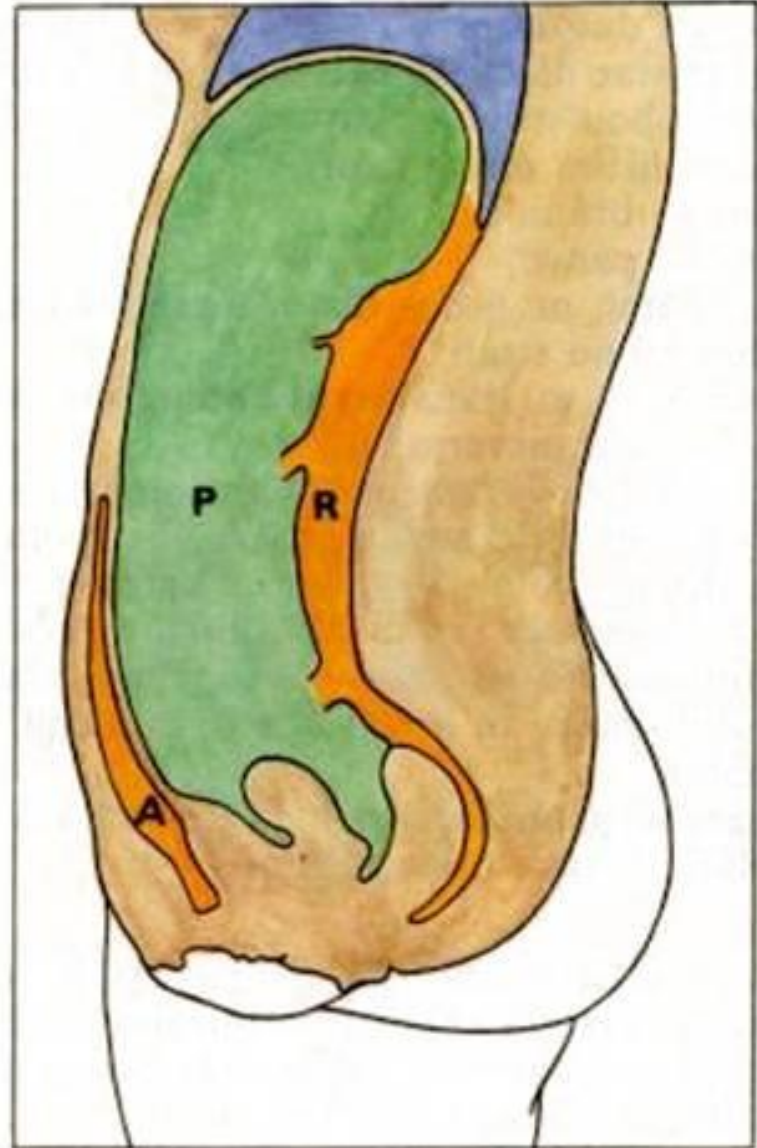
Shape of peritoneal cavity

Sagittal section – female

A – spatium preperitoneale

P – cavitas peritonealis

R – spatium retroperitoneale



Spatium retroperitoneale

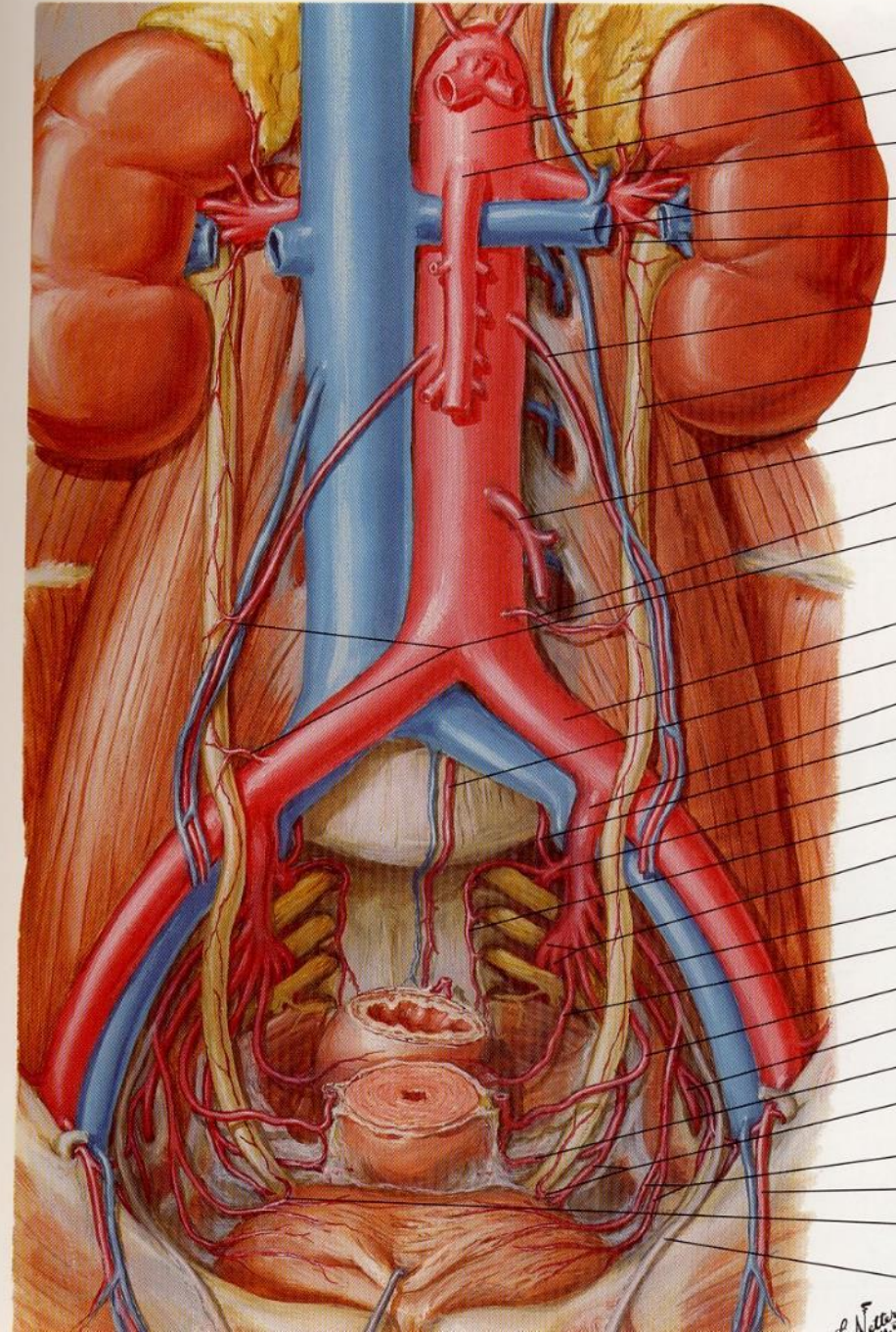
primary:

- large vessels (AoA+VCI)
- suprarenal glands
- kidneys
- ureters
- autonomic plexuses and ganglia
- lymph nodes and lymphatic trunks
- retroperitoneal fat pad

secondary:

- duodenum
- pancreas
- colon ascendens et descendens

THE RETROPERITONEAL SPACE



Peritoneum

- the largest and most complex of the three serous membranes (*tunica serosa* = serosa)
- represents an empty and irregularly creased sac, lining the abdominopelvic cavity
- the surface area of the peritoneal coating is only slightly smaller than the body surface (0.5-2 m²)
- the thickness of the peritoneum is usually less than 1 mm and cannot be imaged in a healthy state by conventional imaging methods
- in male it is a completely closed cavity (*cavitas peritonealis* = peritoneal cavity)
- in female, the lateral ends of the uterine tubes open through their *ostium abdominale tubae uterinae* into the peritoneal cavity and form a connection with the external environment through the internal female genital organs

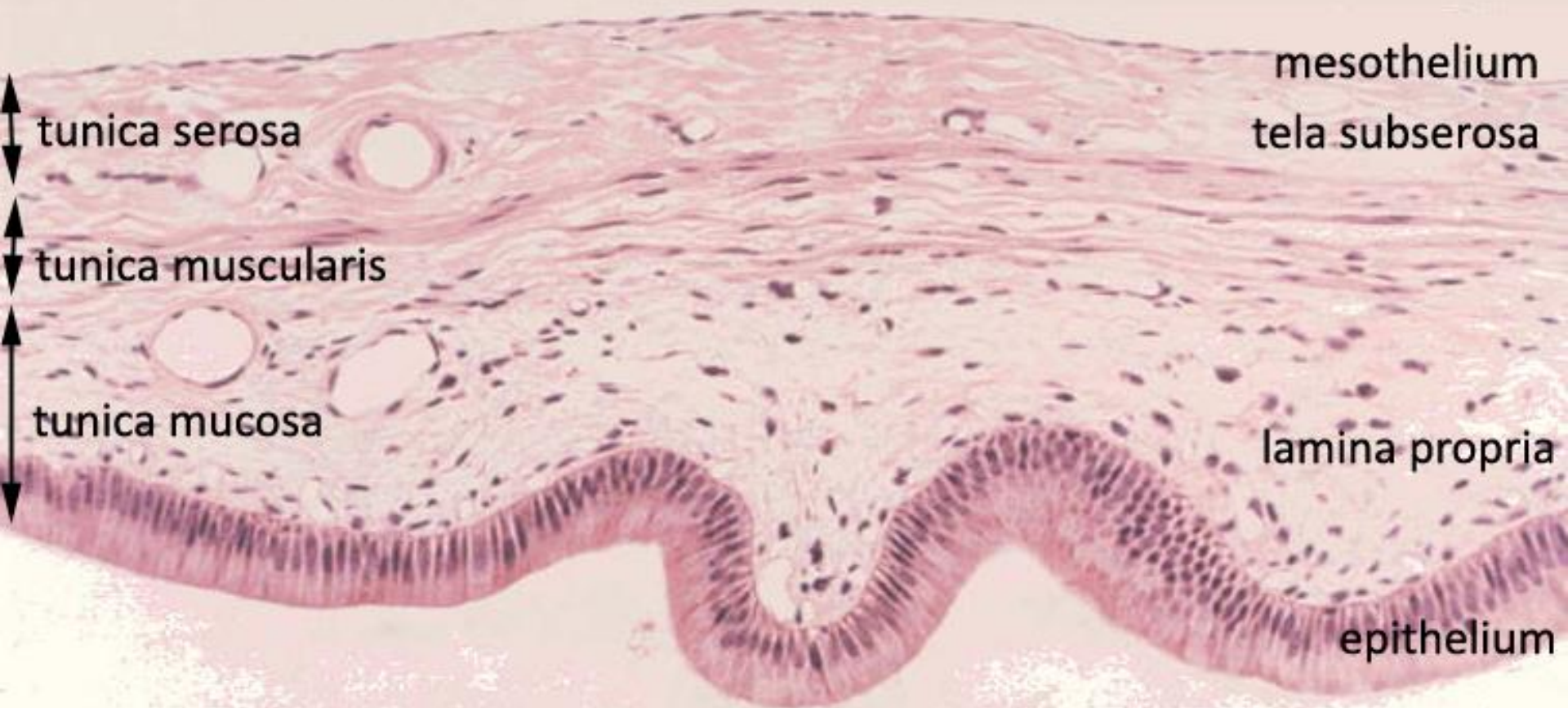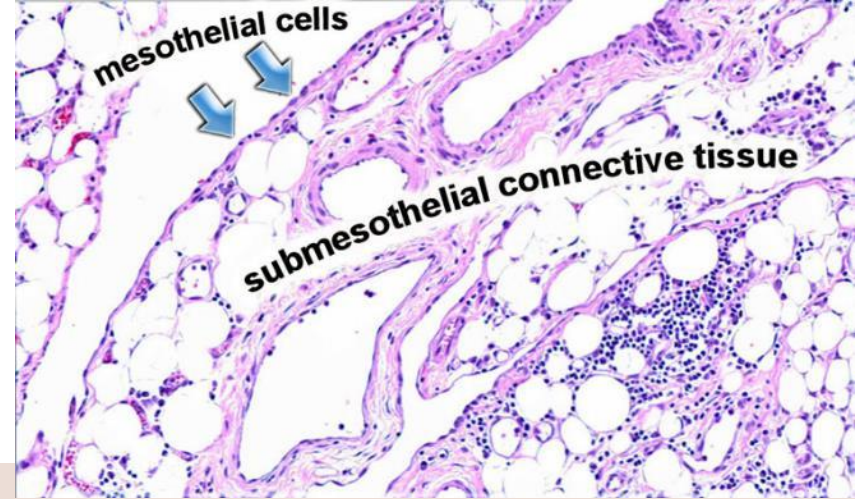
Peritoneum

- in places where it lies on the abdominal wall (superior, anterior, lateral, posterior), it is called the ***peritoneum parietale*** = parietal peritoneum
- in places where it covers the organs and bends around their margins, it is called the ***peritoneum viscerale*** = visceral peritoneum
- is developmentally derived from the coelomic cavity
- its lining is also formed by a derivative of the mesoderm – ***mesothelium*** (simple squamous epithelium)
- the mesothelium is underlain by a thin layer of sparse connective tissue (**tela subserosa**)

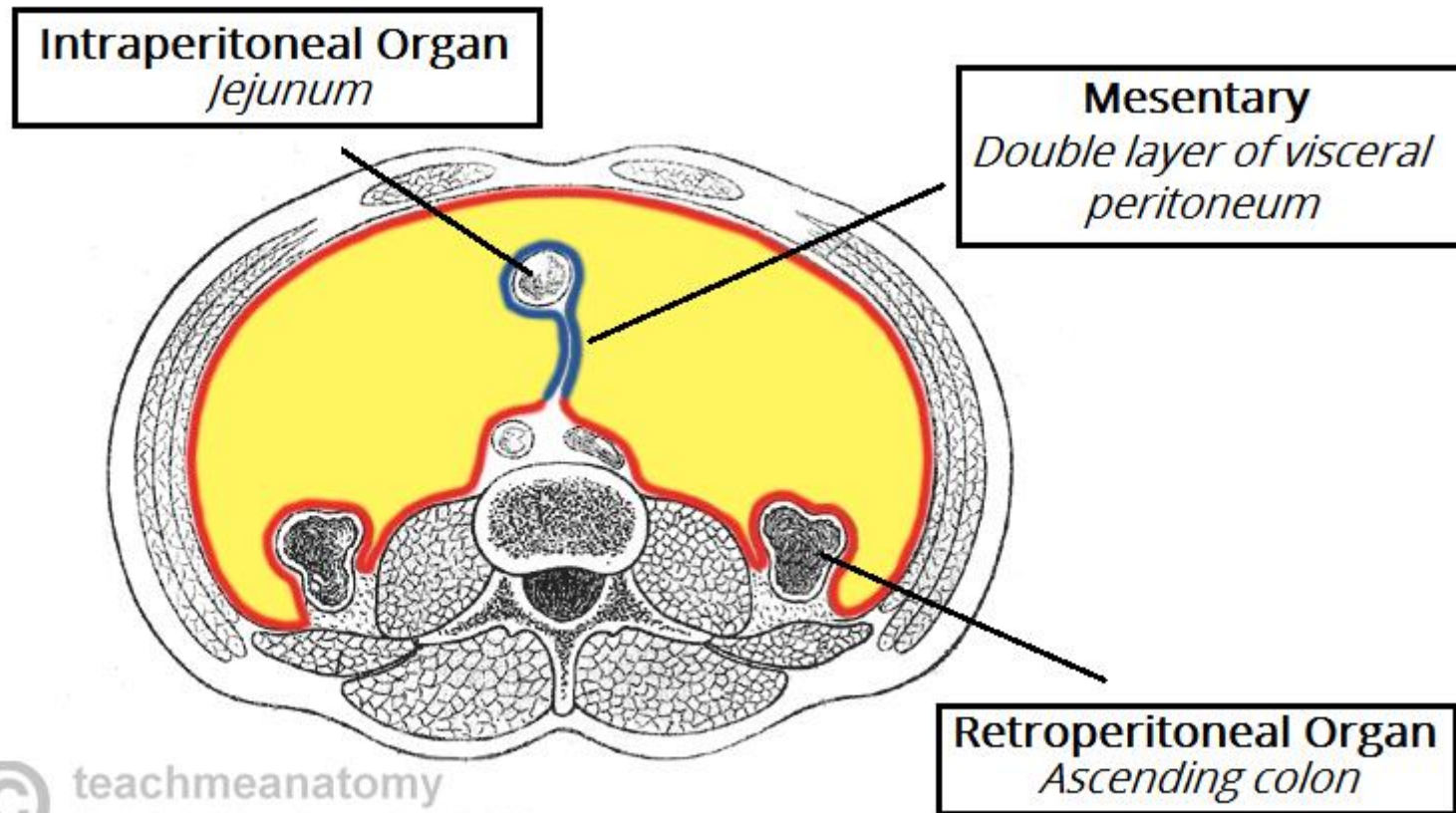
Peritoneum – function

- production of peritoneal fluid – *liquor peritonei*
- absorption of fluids – e.g. physiological solution, antibiotics
- absorption (resorption) of bacterial toxins in inflammation (peritonitis)
- rich sensory innervation – *nn. intercostales*
 - the parietal peritoneum hurts!
 - the visceral peritoneum **does not hurt!**

Peritoneum histology



Relation of organs and peritoneum



Intraperitoneal organ

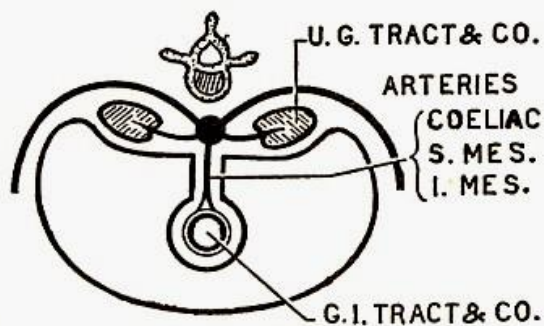
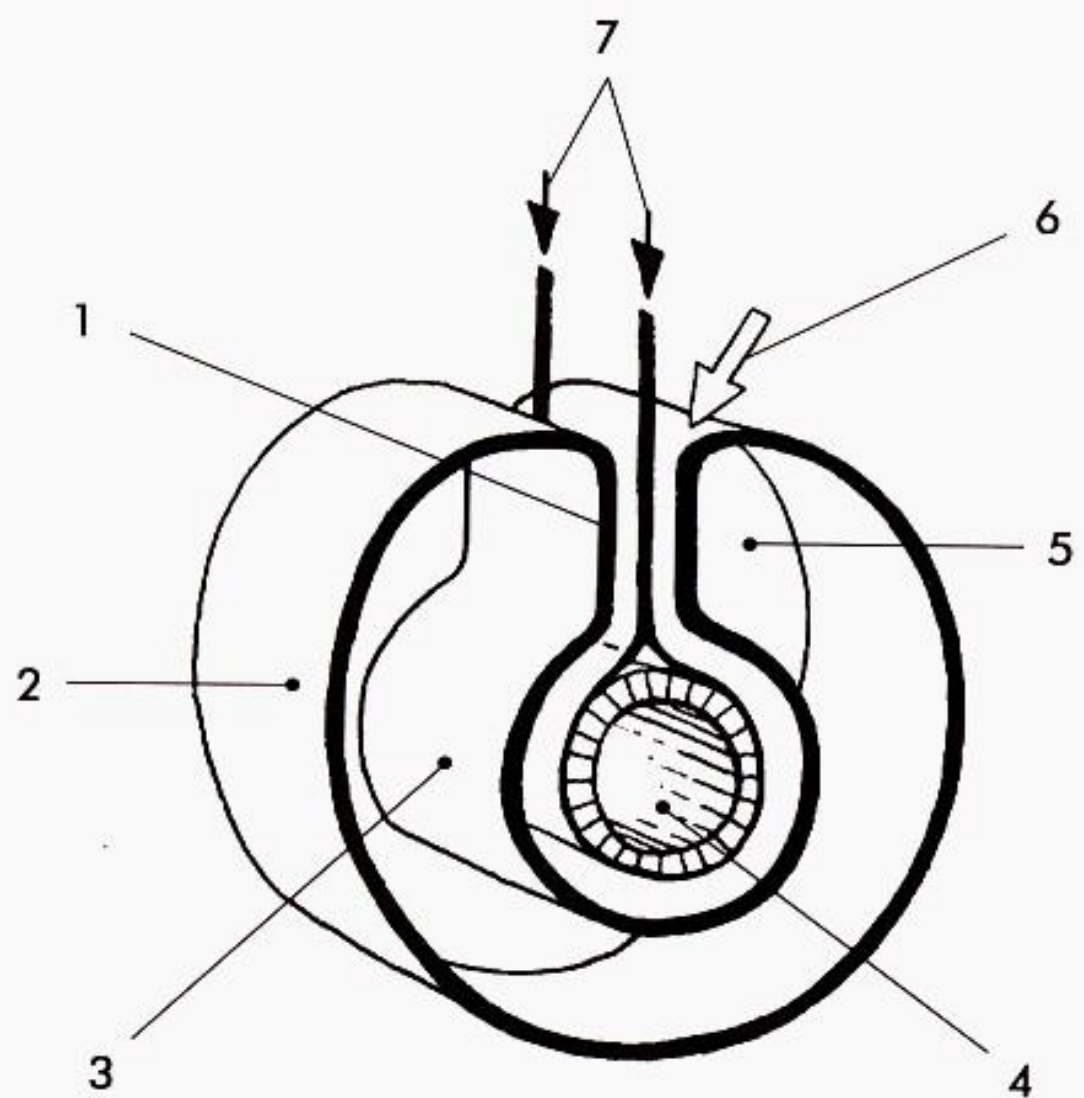


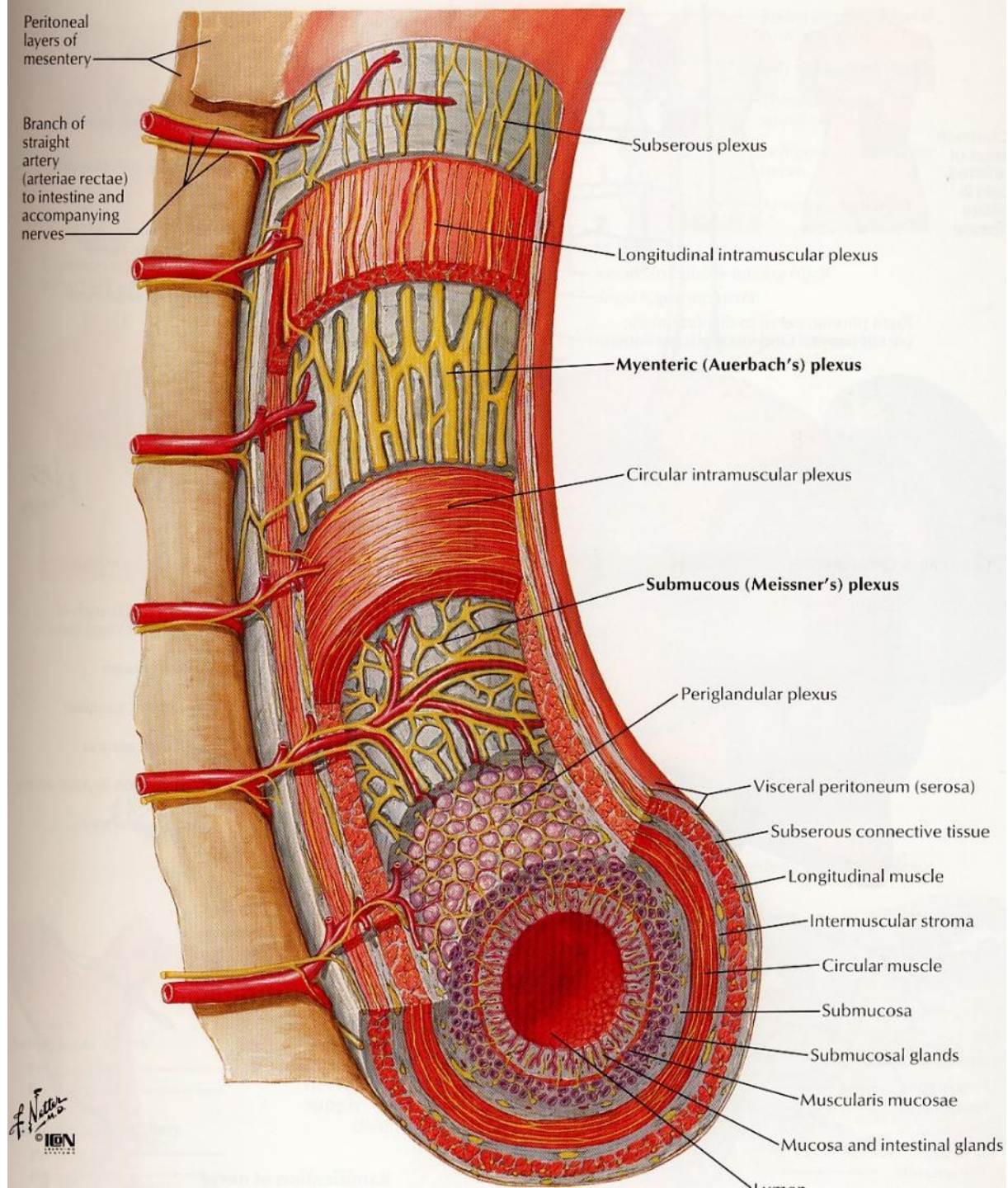
FIG. 263. Transverse section of the abdomen of an embryo (schematic).



Obr. 5.38. Schéma vztahu peritonea k intraperitoneálním orgánům. 1 – mezenterium, 2 – parietální list peritonea, 3 – viscerální list peritonea, 4 – trávicí trubice, 5 – cavitas peritonealis, 6 – radix mesenterii, 7 – aa. et vv. mesentericae

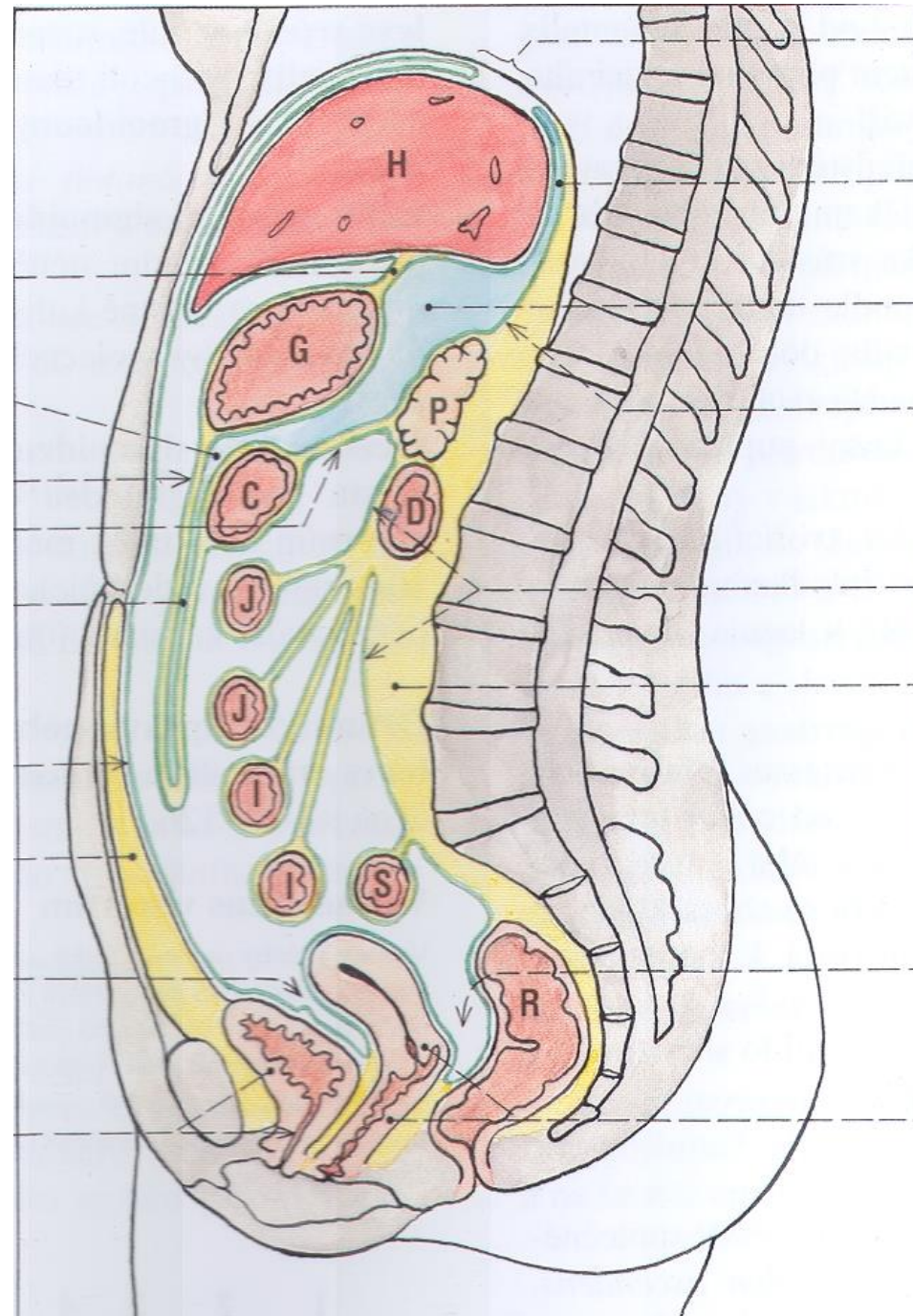
Mesentery contents

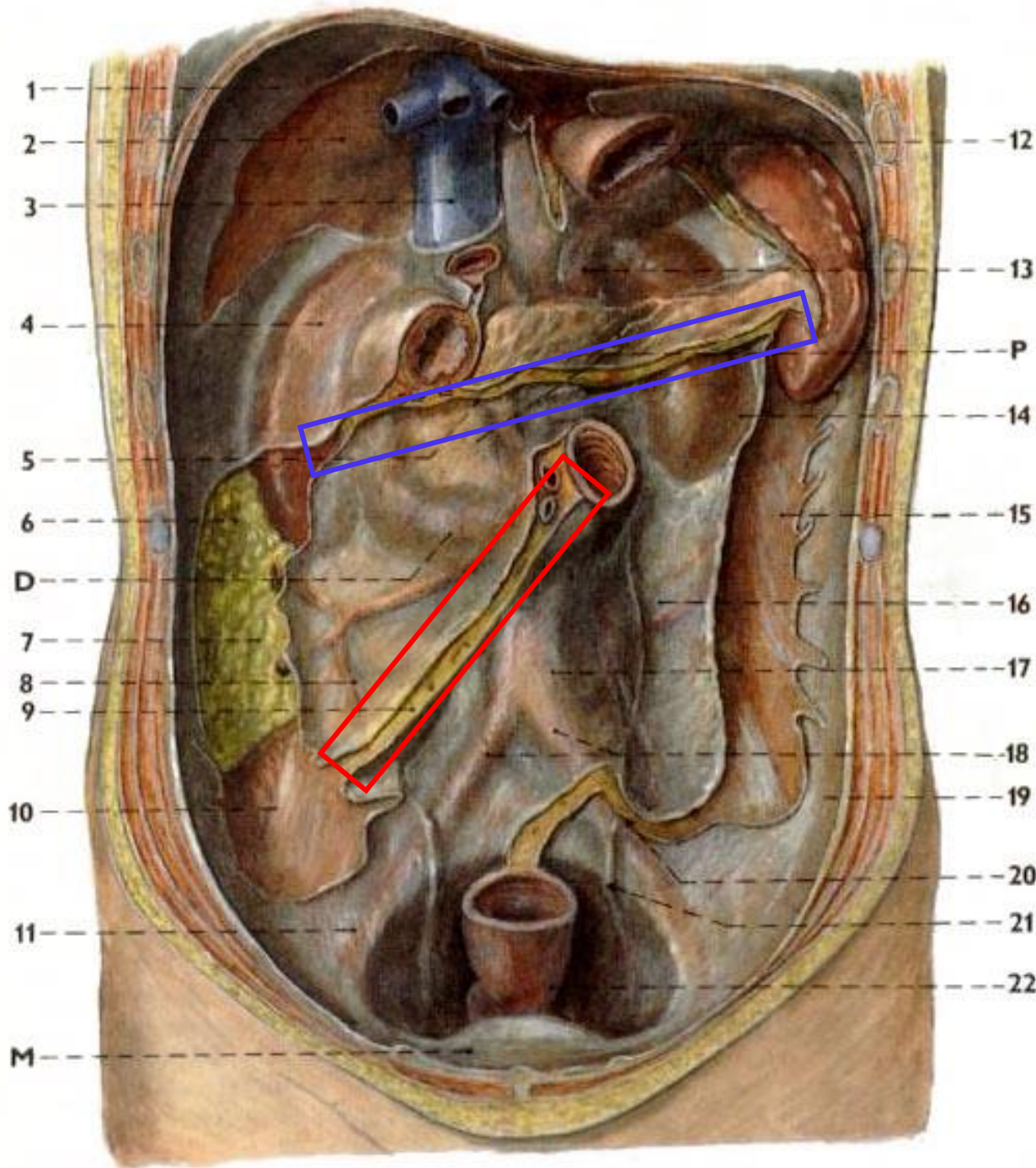
- adipose tissue
- arteries and veins
- lymphatic vessels and lymph nodes
- periarterial autonomic plexuses



Cavitas peritonealis

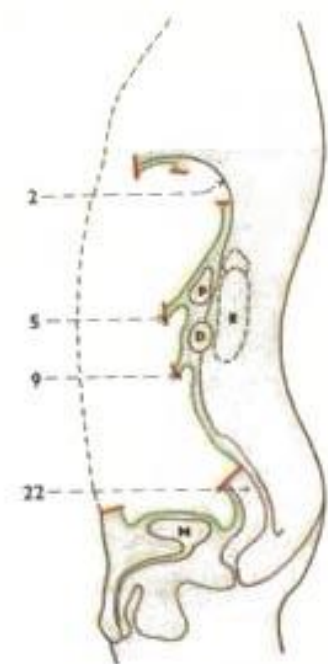
- **pars supramesocolica (supramesocolic compartment)**
 - bursa omentalis
- **pars inframesocolica (inframesocolic compartment)**
 - right and left paracolic spaces
 - radix mesenterii
 - excavatio rectouterina
Douglasi + excavatio vesicouterina ♀
 - excavatio rectovesicalis
Prousti ♂

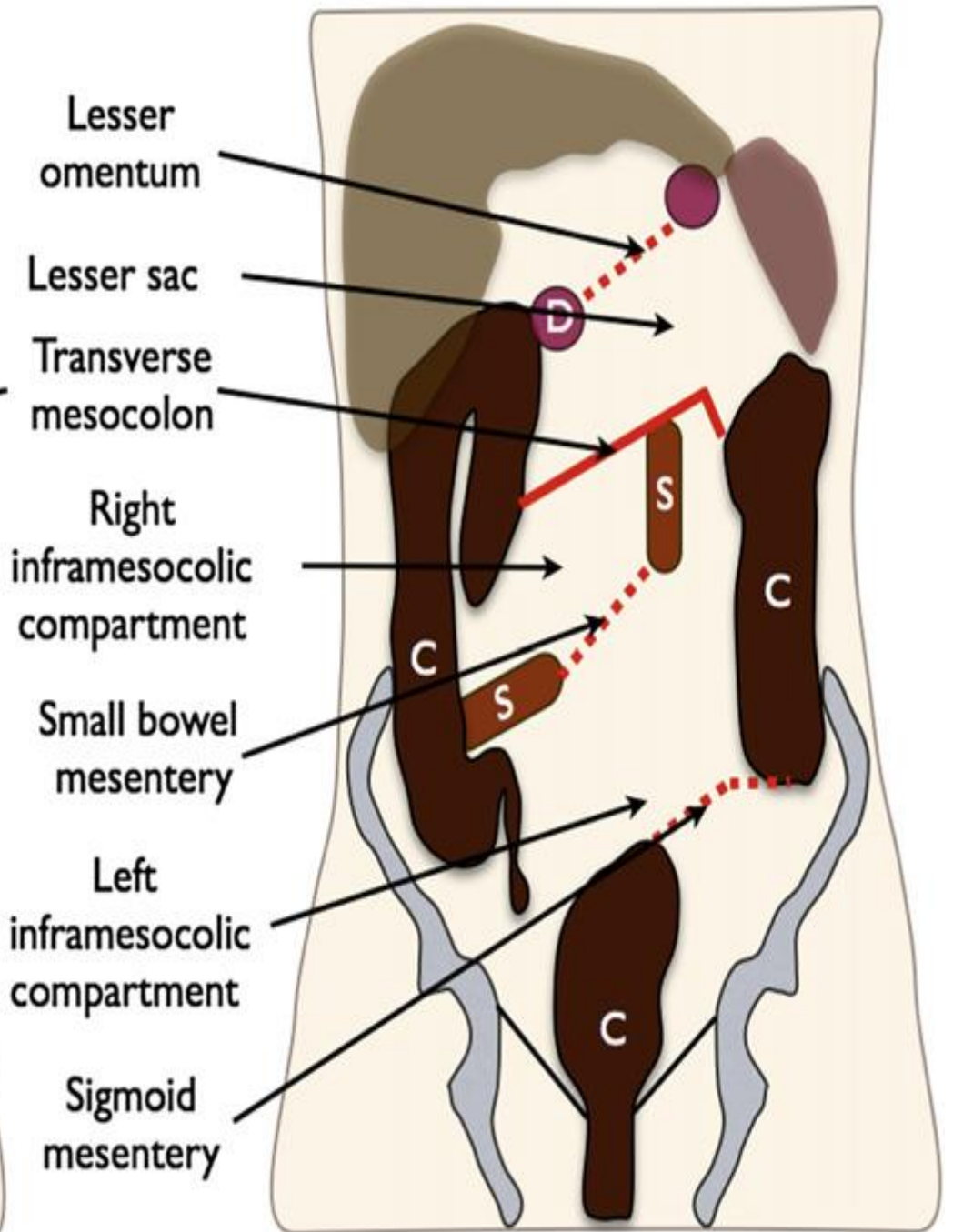
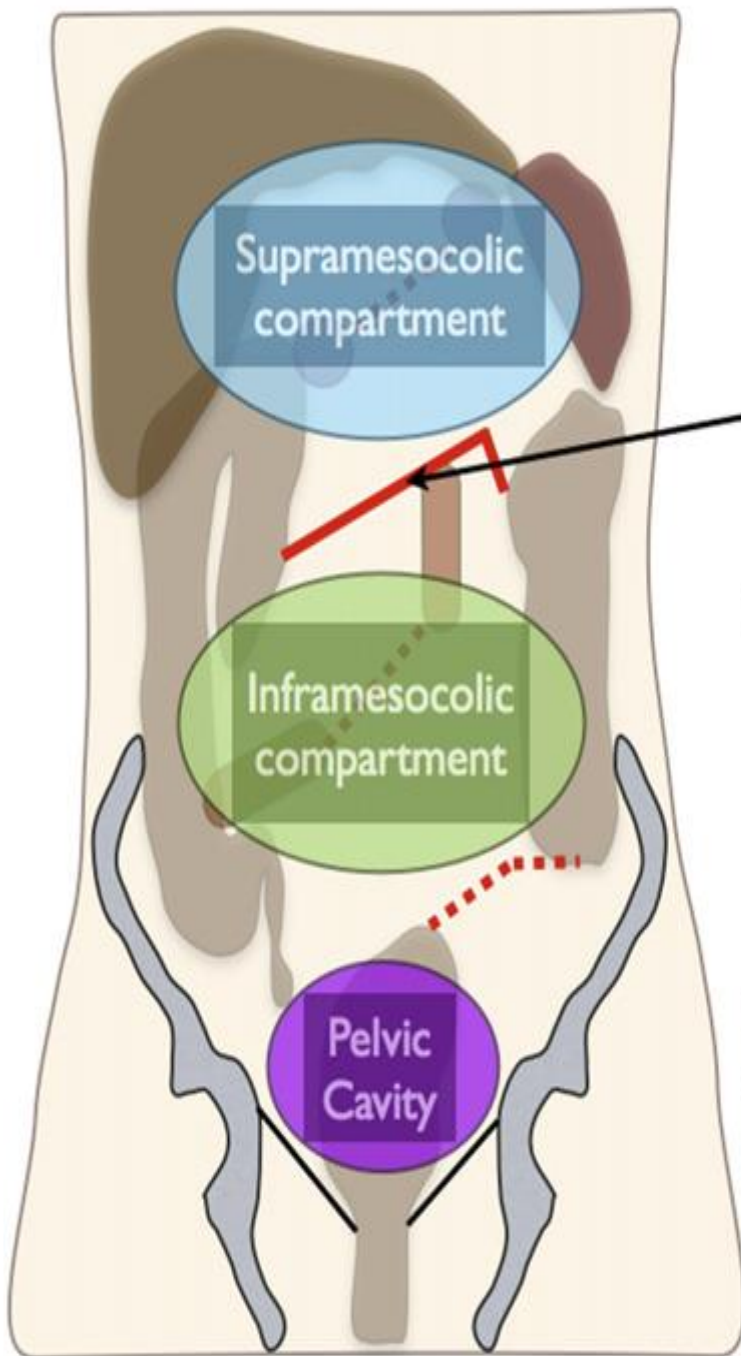




Radix
mesocoli
transversi

Radix
mesenterii

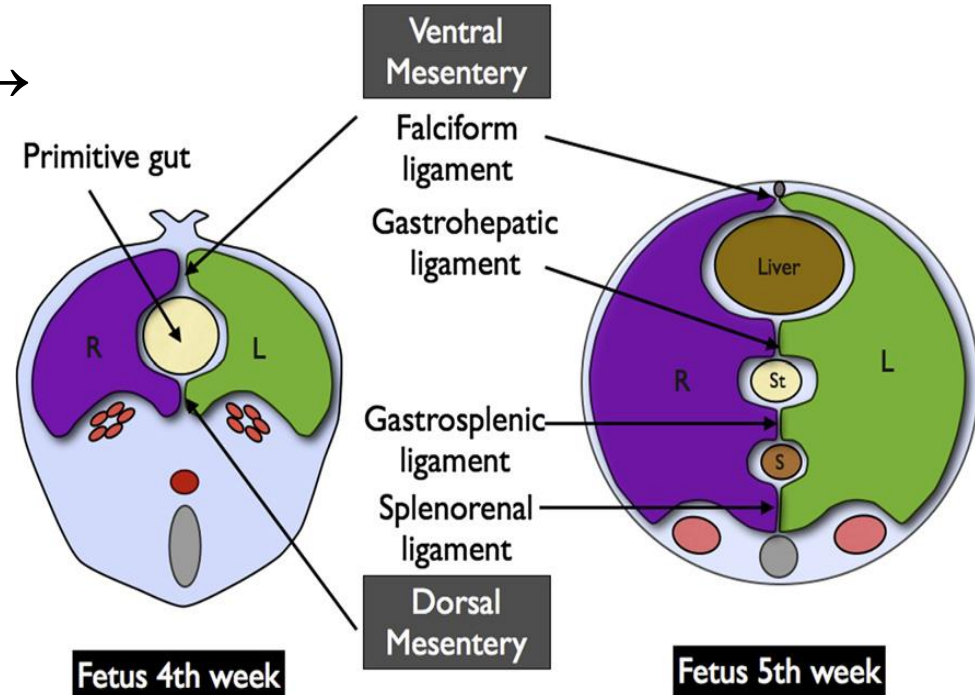




Mesos – pars supramesocolica

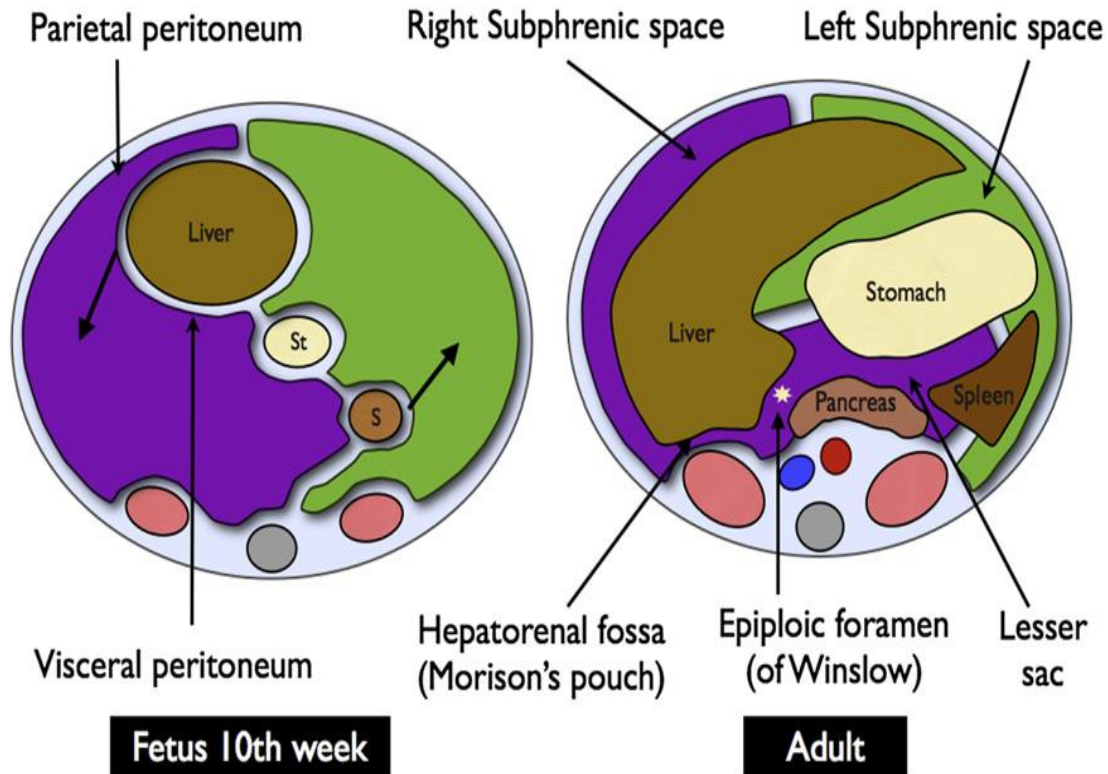
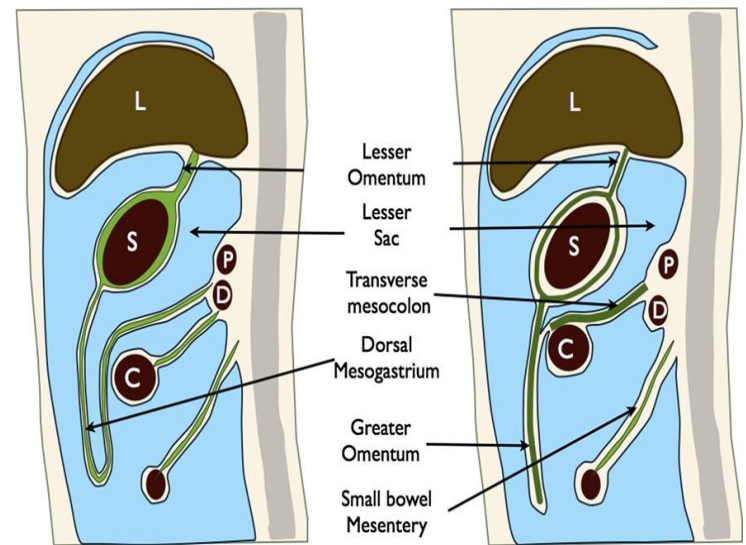
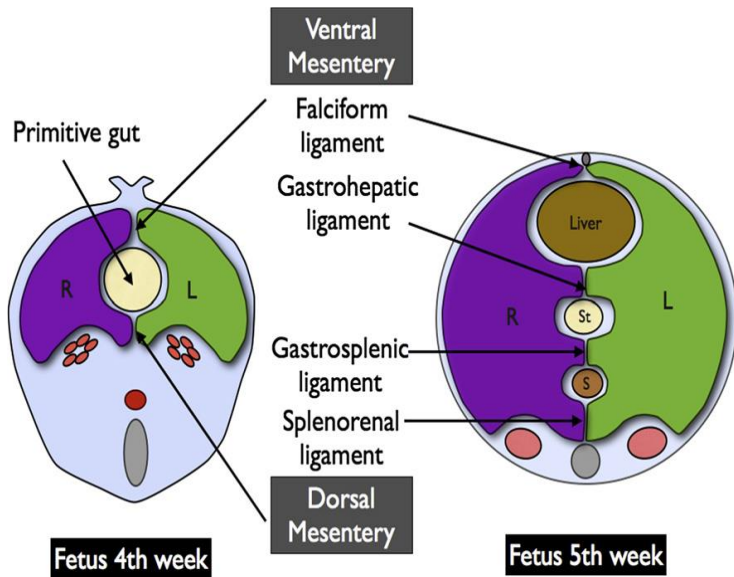
- mesogastrium **ventrale** →

- lig. falciforme
- omentum minus
 - lig. hepatoduodenale
 - lig. hepatogastricum
 - lig. hepatoesophageum
 - lig. hepatophrenicum



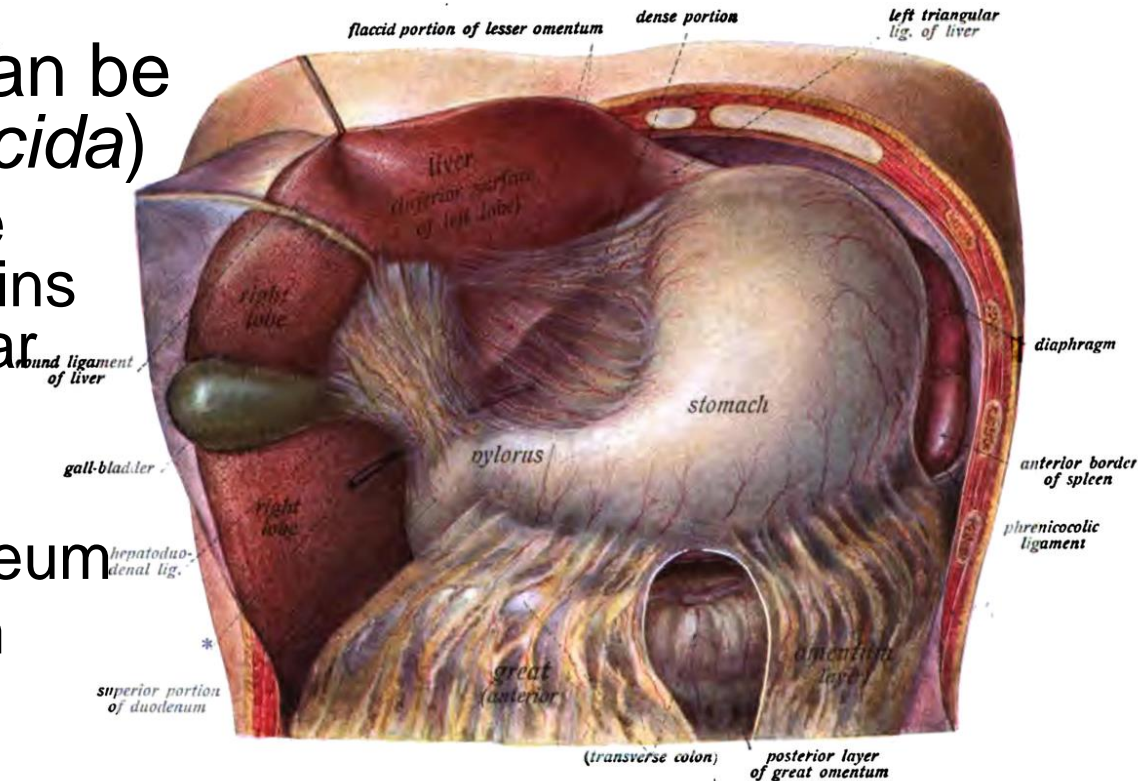
- mesogastrium **dorsale** →

- lig. phrenicosplenicum, gastrophrenicum, gastrosplenicum
- lig. gastrocolicum
- omentum majus



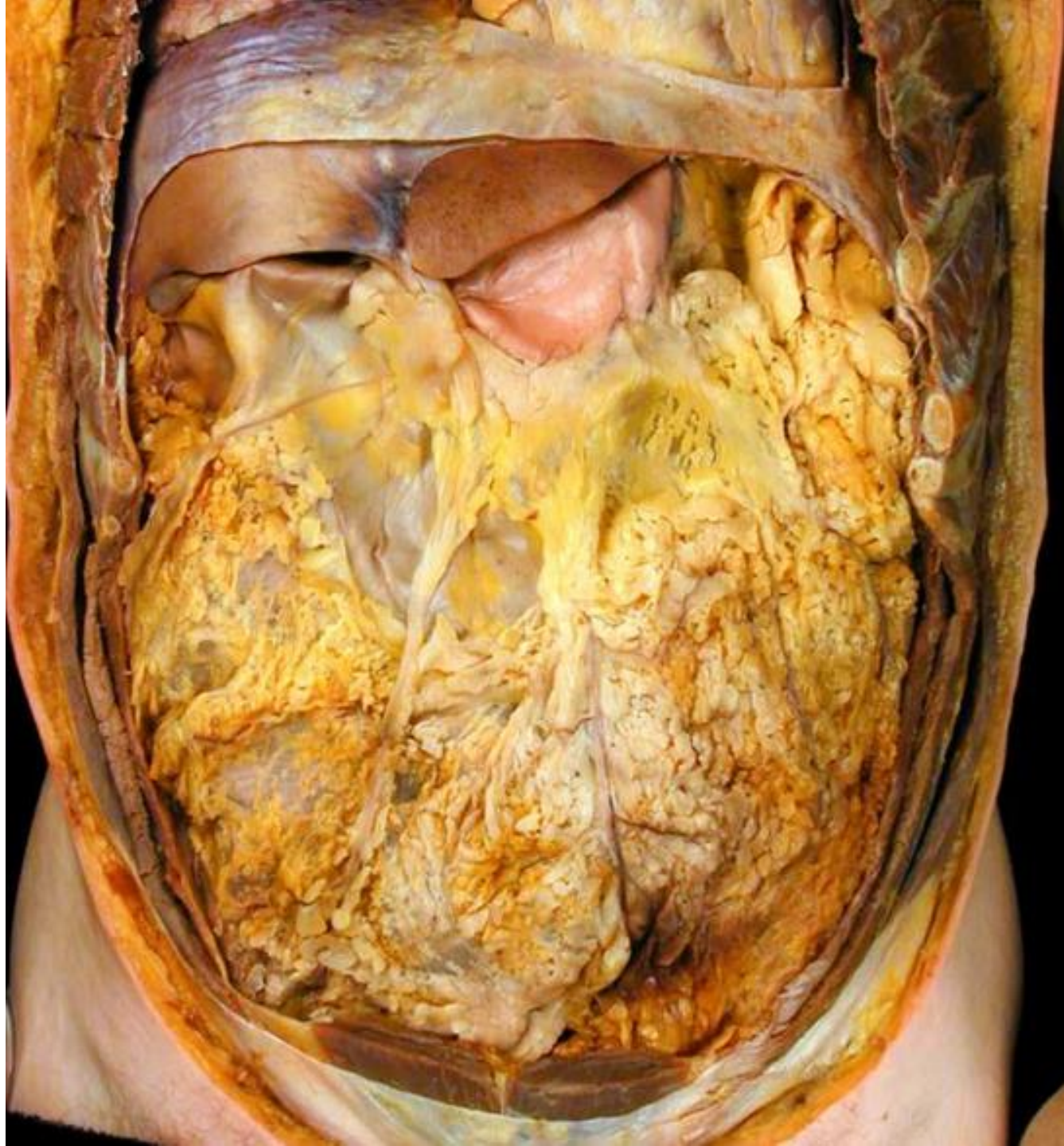Omentum minus (Lesser omentum)

- broad peritoneal fold (duplication of the peritoneum)
- developmental remnant of the most dorsal part of the mesogastrium ventrale
- continues onto the anterior and posterior surfaces of the stomach and oral 2 cm duodenum
- weaker on the left, can be perforated (*pars flaccida*)
 - lig. hepatoduodenale – right margin, contains hepatic neurovascular bundle + bile duct
 - lig. hepatogastricum
 - lig. hepatoesophageum
 - lig. hepatophrenicum



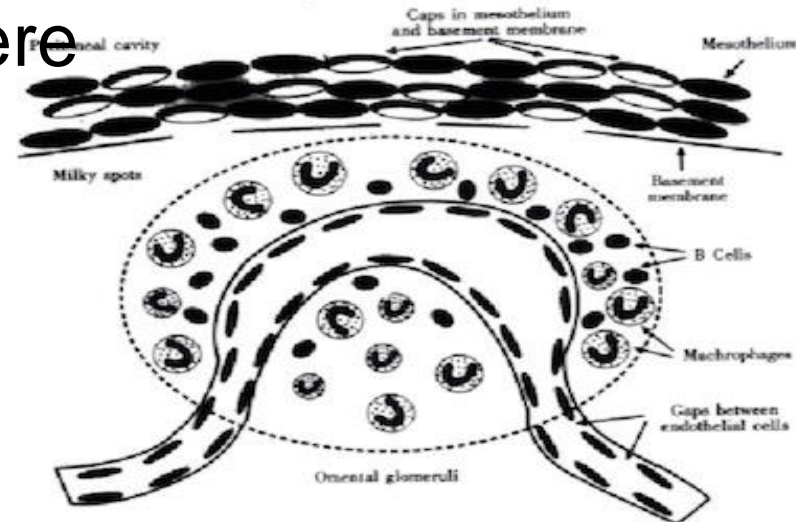
Omentum majus (Greater omentum)

- the largest fold of the peritoneum (duplication of the peritoneum)
- developmental remnant of *mesogastrium dorsale*
- formed by two layers and each with two more layers (a total of four layers of peritoneum)
- the anterior layer begins from the *curvatura major gastrici* and overlaps ventrally the transverse colon with which it merges = ***ligamentum gastrocolicum***
- the left margin continues upward smoothly as the *ligamentum gastrosplenicum*
- the right margin reaches up to the top of the duodenum



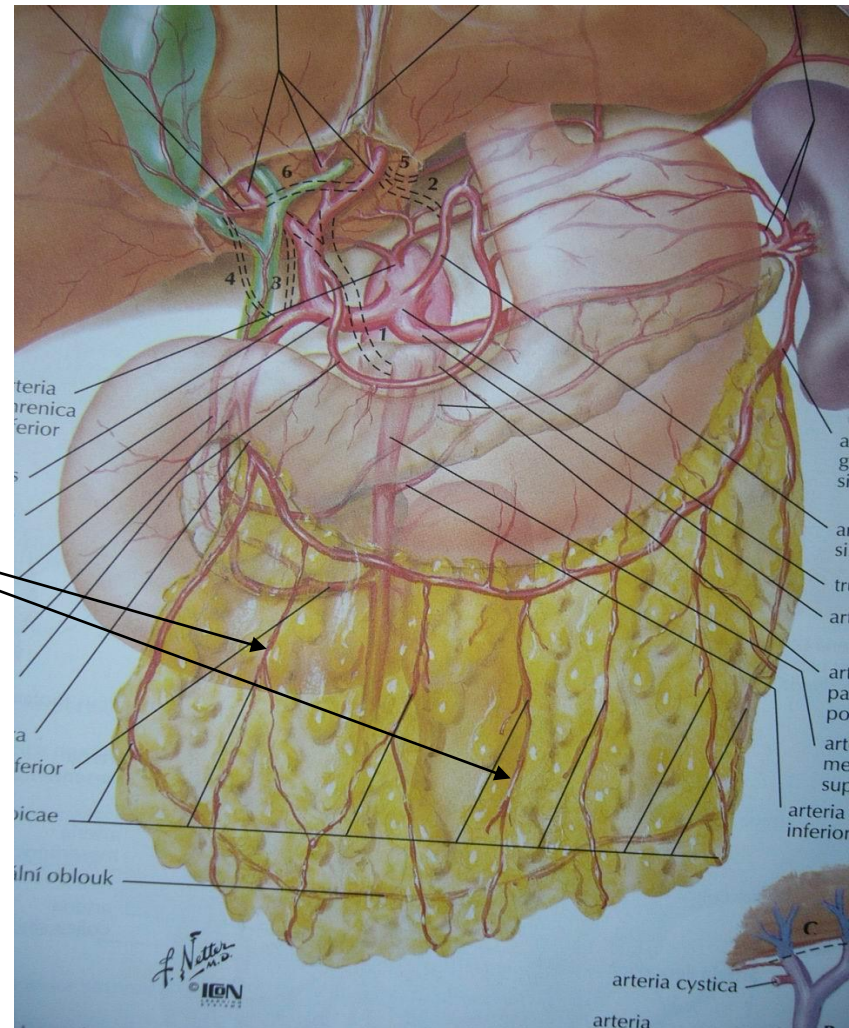
Milky spots*

- opalescent milk spots/maculae (0.5-4 mm)
- capillary pseudoglomerulus composed of macrophages and lymphocytes (monocytes, plasmatic cells, mast cells and reticular cells)
- newborn: 30–40 per 1 cm²
- adult: 2 per 1 cm²
- lymphatic capillaries begin here
- especially in the omentum majus, little in the mesentery and pelvic peritoneum, absent elsewhere



- **truncus coeliacus** → a. hepatica communis → a. gastroduodenalis → a. gastromentalis dextra
- **truncus coeliacus** → a. splenica → a. gastromentalis sinistra
- **arcus gastromentalis Hyrtli** = anastomosis between a. *gastromentalis dextra et sinistra* → rr. omentales anteriores
- (*arcus omentalis Barkowii*)
- *arteria mesenterica superior* → a. colica media → rr. omentales posteriores (thinner)

Arterial supply of omentum majus



AGoD

CMG

AOS

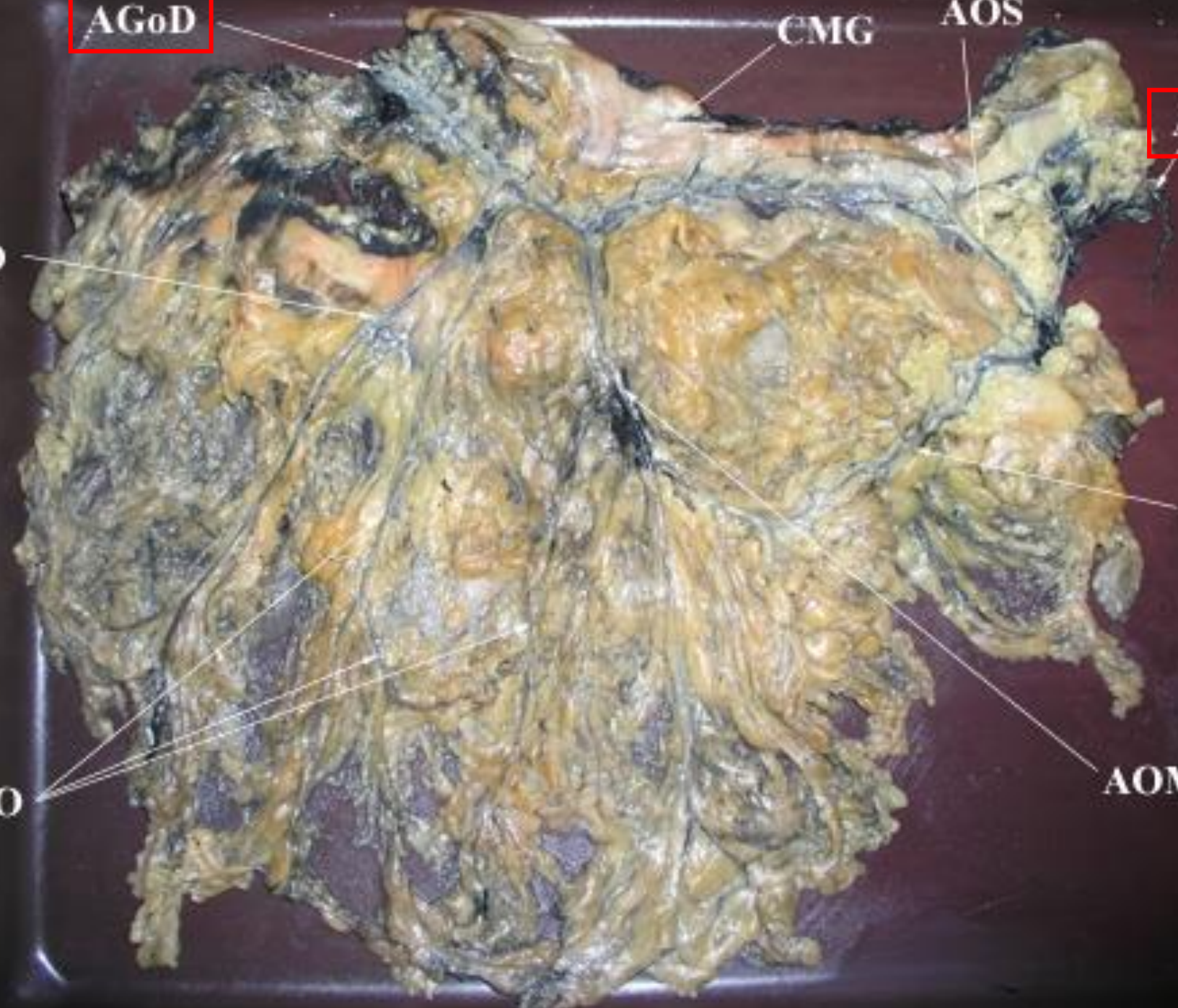AGoS

AOD

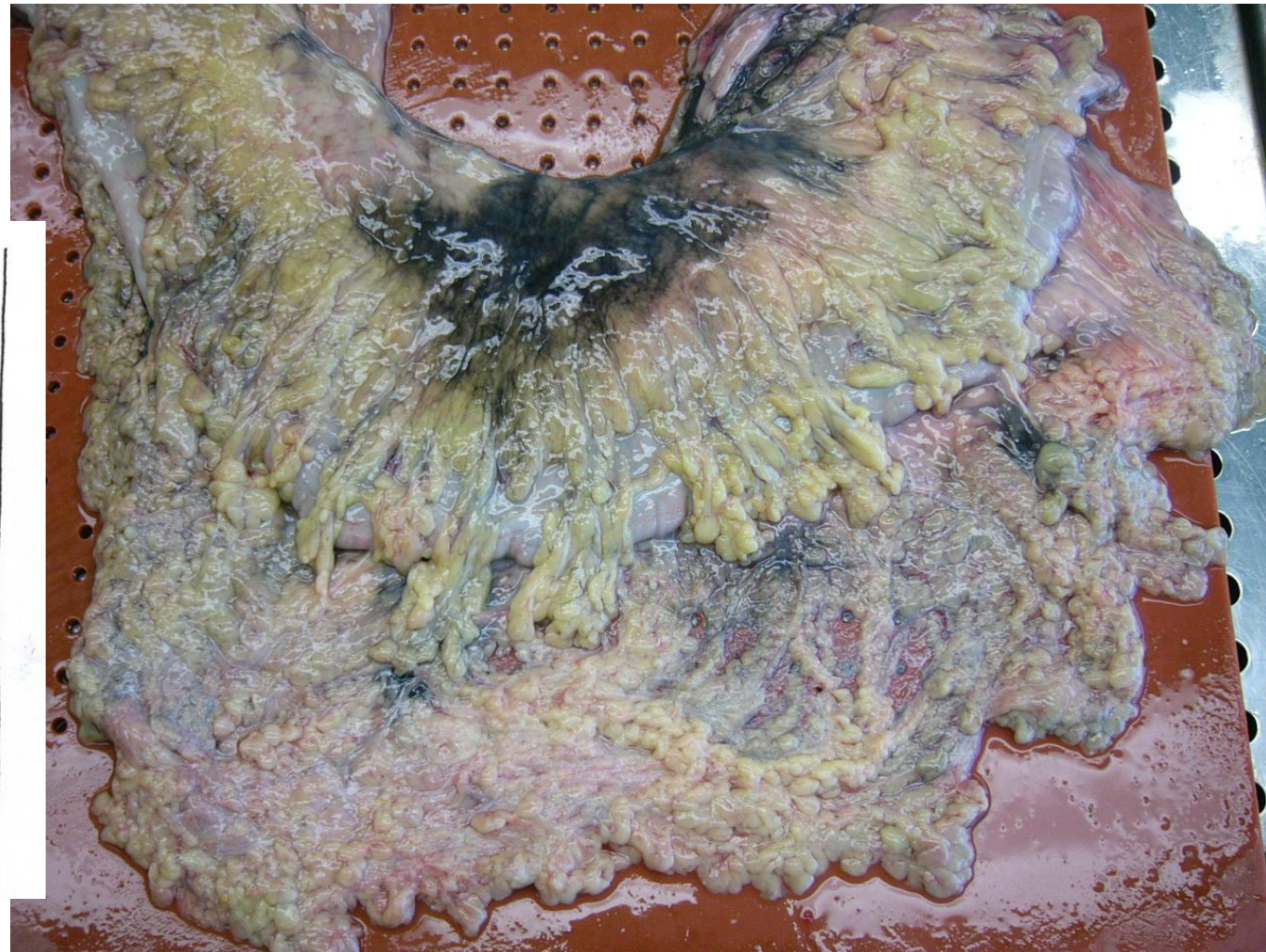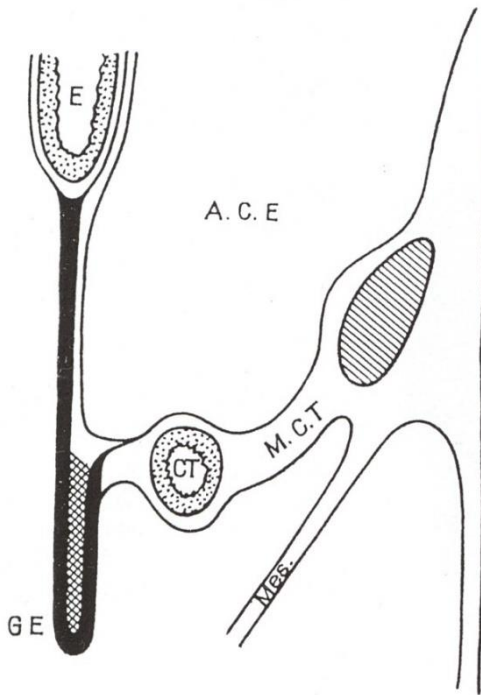
AO

AO

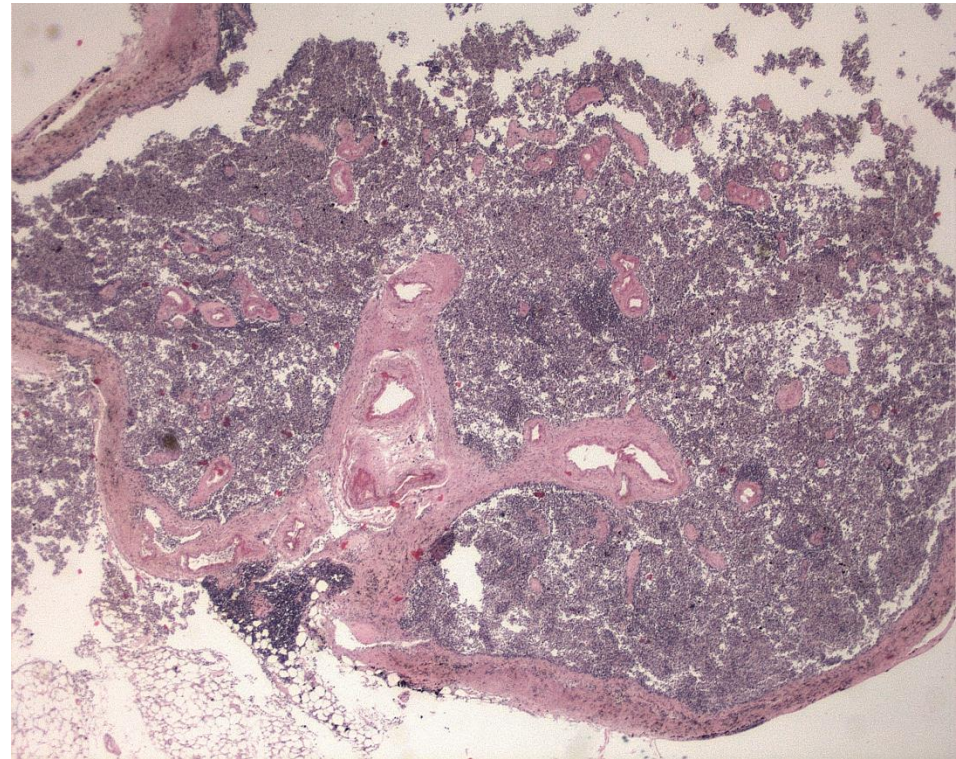
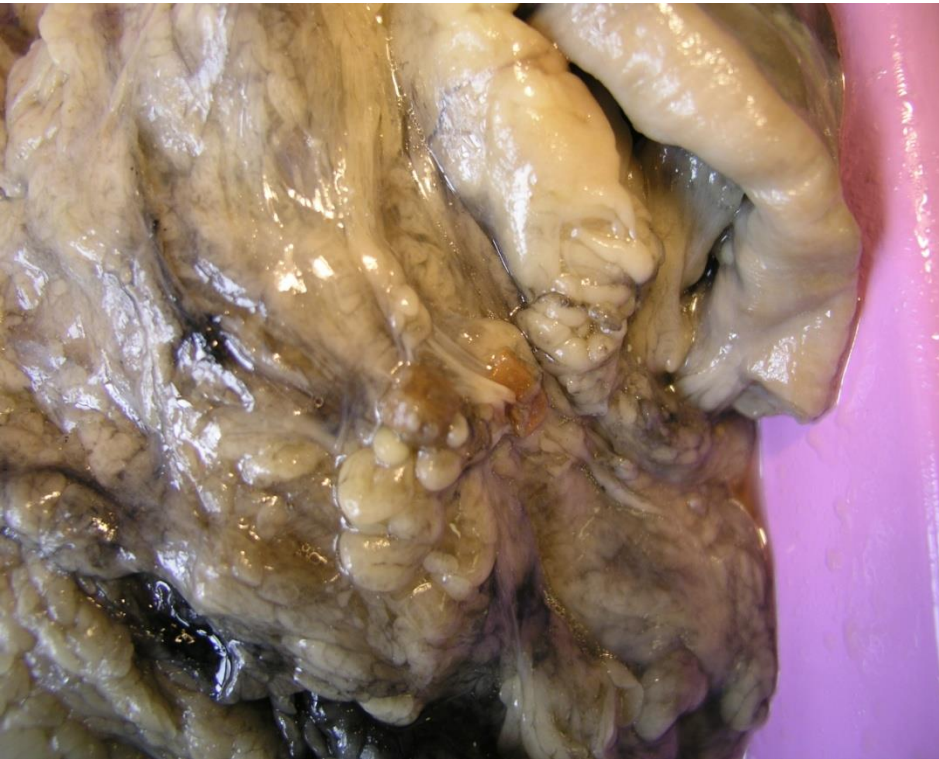AOM

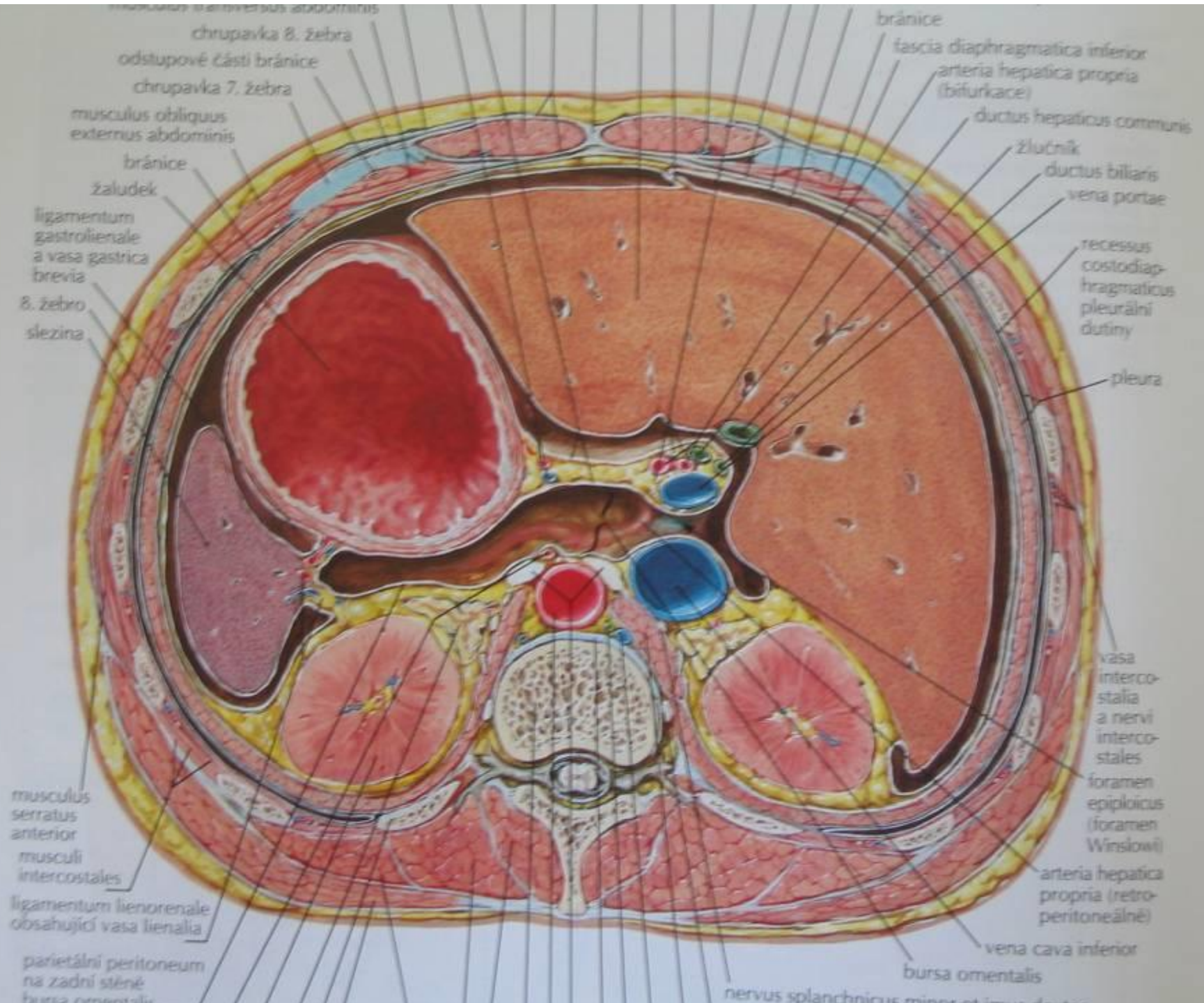


Relation between omentum majus and mesocolon transversum



Splen accessorius within omentum majus





chrupavka 8. žebra

odstupové části bránice

chrupavka 7. žebra

musculus obliquus externus abdominis

bránice

žaludek

ligamentum gastrolienale a vasa gastrica brevia

8. žebro

slezina

musculus serratus anterior

musculi intercostales

ligamentum lienorenale obsahující vasa lienalia

parietální peritoneum na zadní stěně bursy omentalis

bránice

fascia diaphragmatica inferior

arteria hepatica propria (bifurkace)

ductus hepaticus communis

žlučník

ductus biliaris

vena portae

recessus costodiaphragmaticus pleurální dutiny

pleura

vasa intercostalia a nervi intercostales

foramen epiploicus (foramen Winslowi)

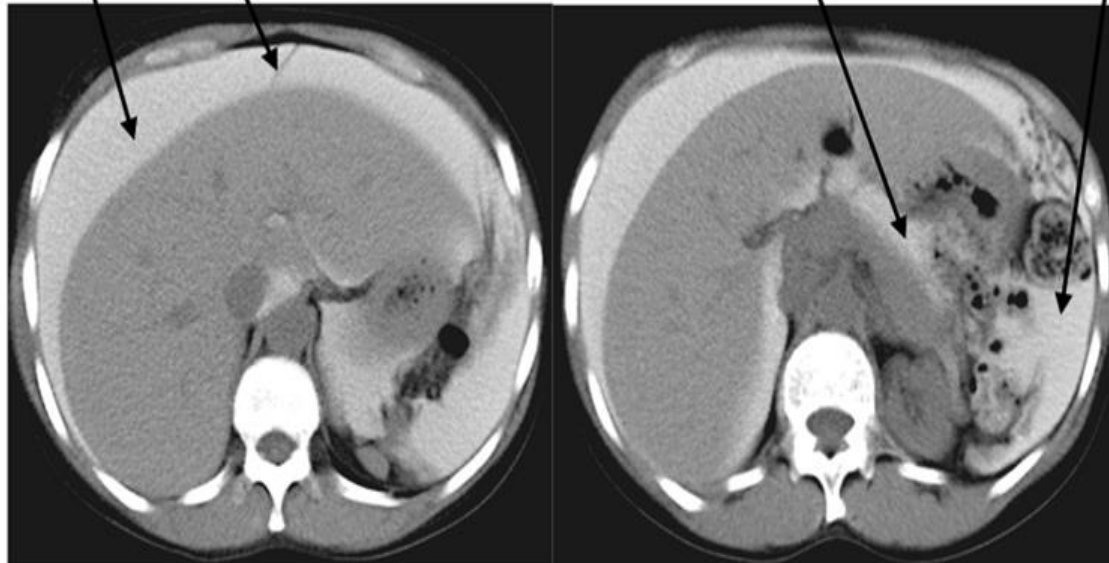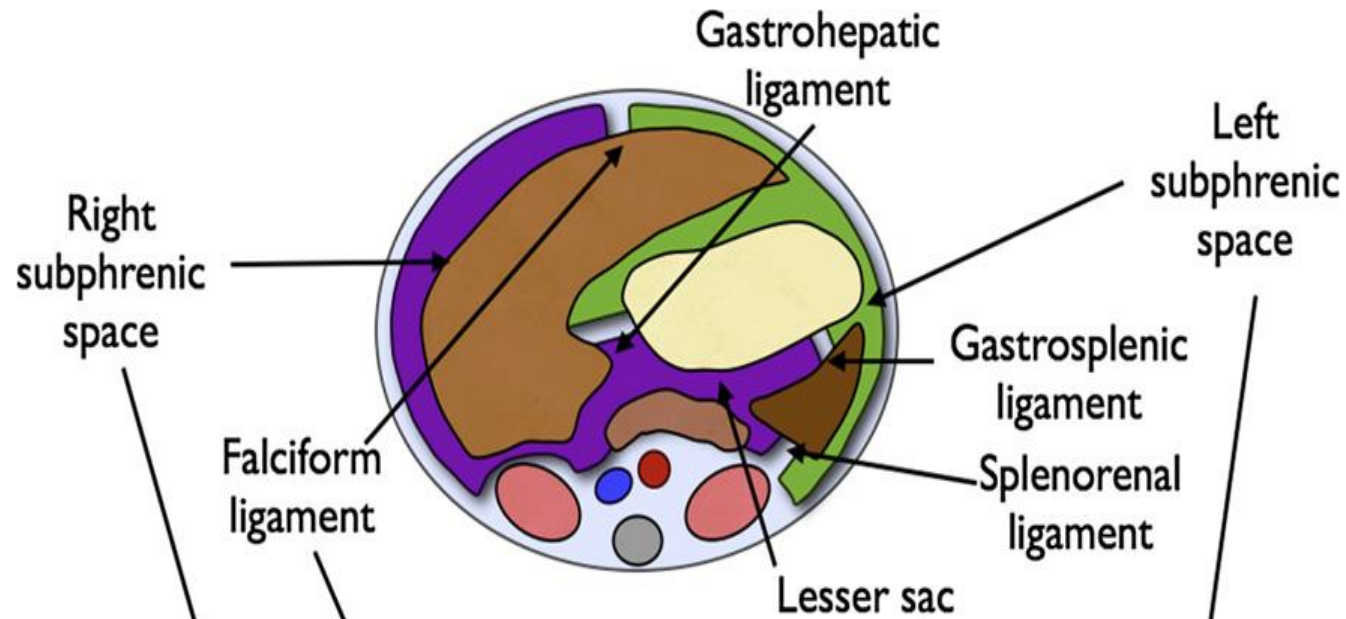
arteria hepatica propria (retroperitoneálně)

vena cava inferior

bursa omentalis

nervus splanchnicus minor et imus

Bursa omentalis (Lesser sac)



Bursa omentalis – boundaries

- ventrally: stomach, omentum minus, lig. gastrocolicum
- dorsally: peritoneum (top), peritoneum + pancreas, duodenum (middle), omentum majus – posterior layer (bottom)
- cranially: lobus caudatus hepatis, left diaphragmatic vault
- caudally: colon transversum, mesocolon transversum, omentum majus (sometimes containing recessus inferior b.o.)
- left: spleen, lig. gastrophrenicum, lig. gastrosplenicum, lig. splenorenal (contains vasa splenica + cauda pancreatis), lig. phrenicosplenicum, lig. splenocolicum

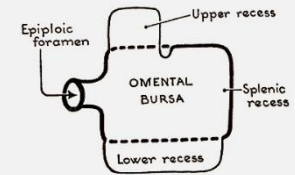


FIG. 246.1. Scheme of omental bursa

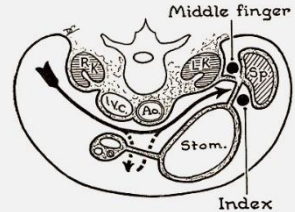
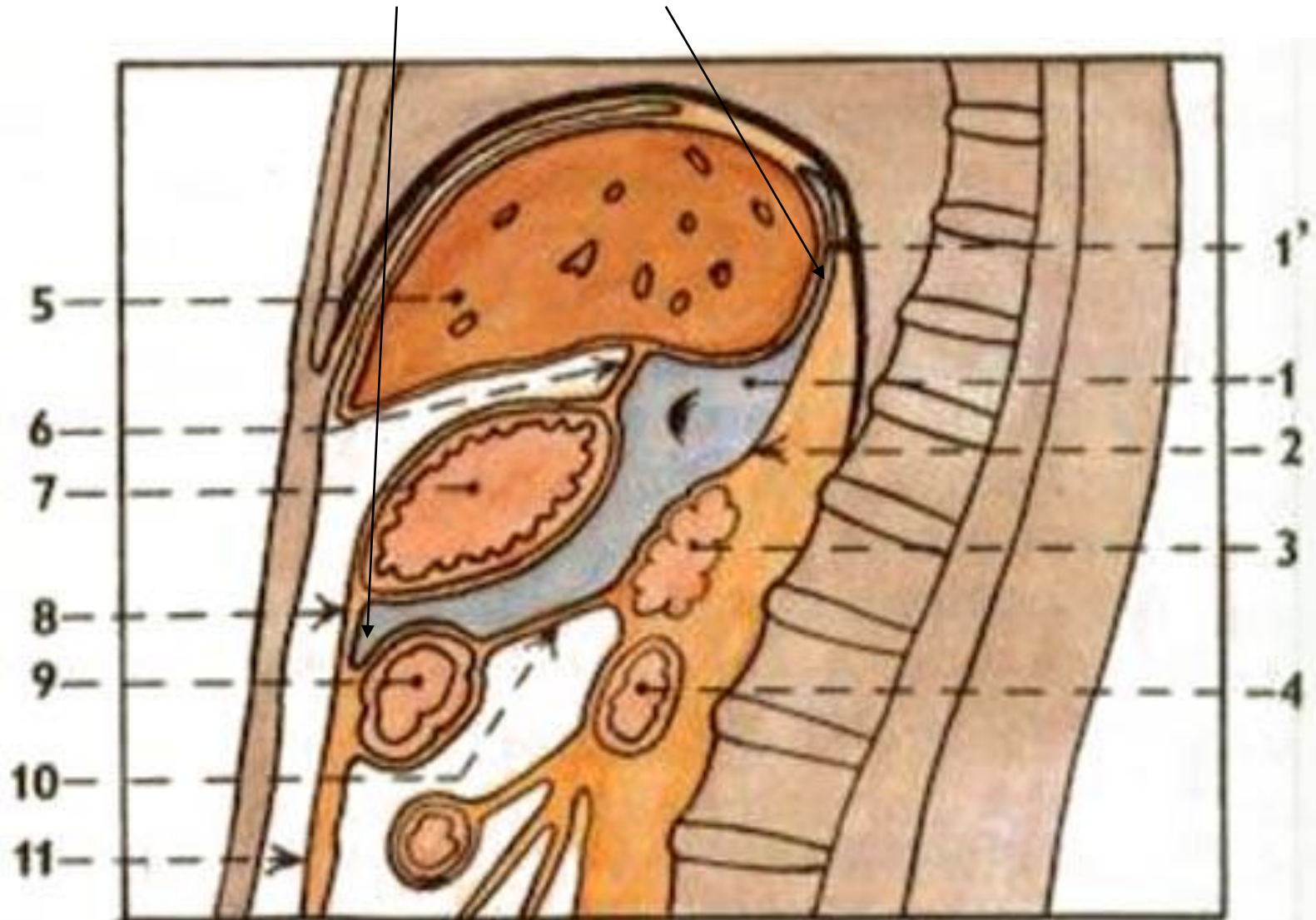


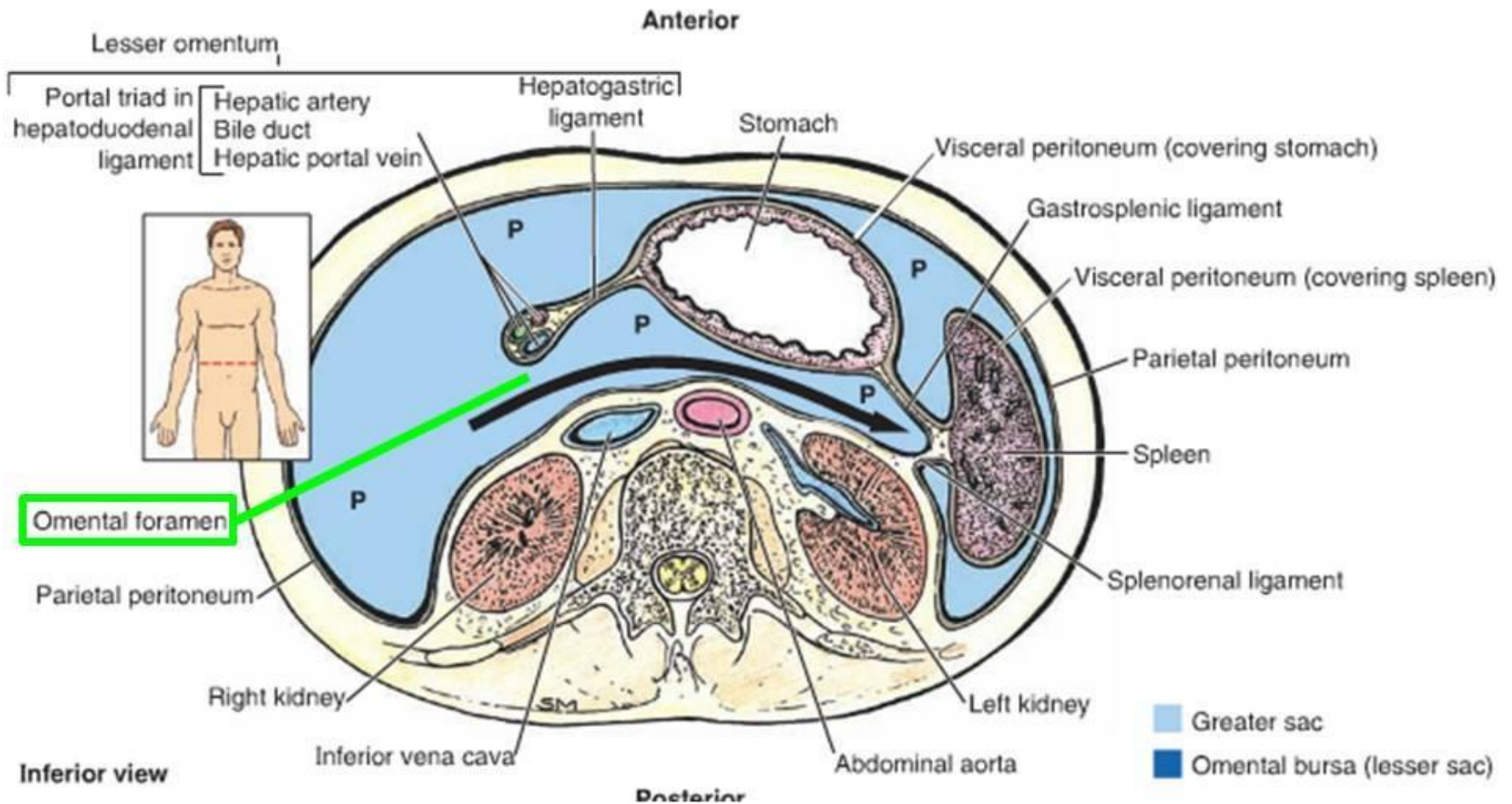
FIG. 247. Palpating the hilus of the spleen while its pedicle is clamped between two fingers of the right hand.

Bursa omentalis – záhyby

- recessus inferior, superior, splenicus



Foramen omentale (epiploicum seu Winslowi)

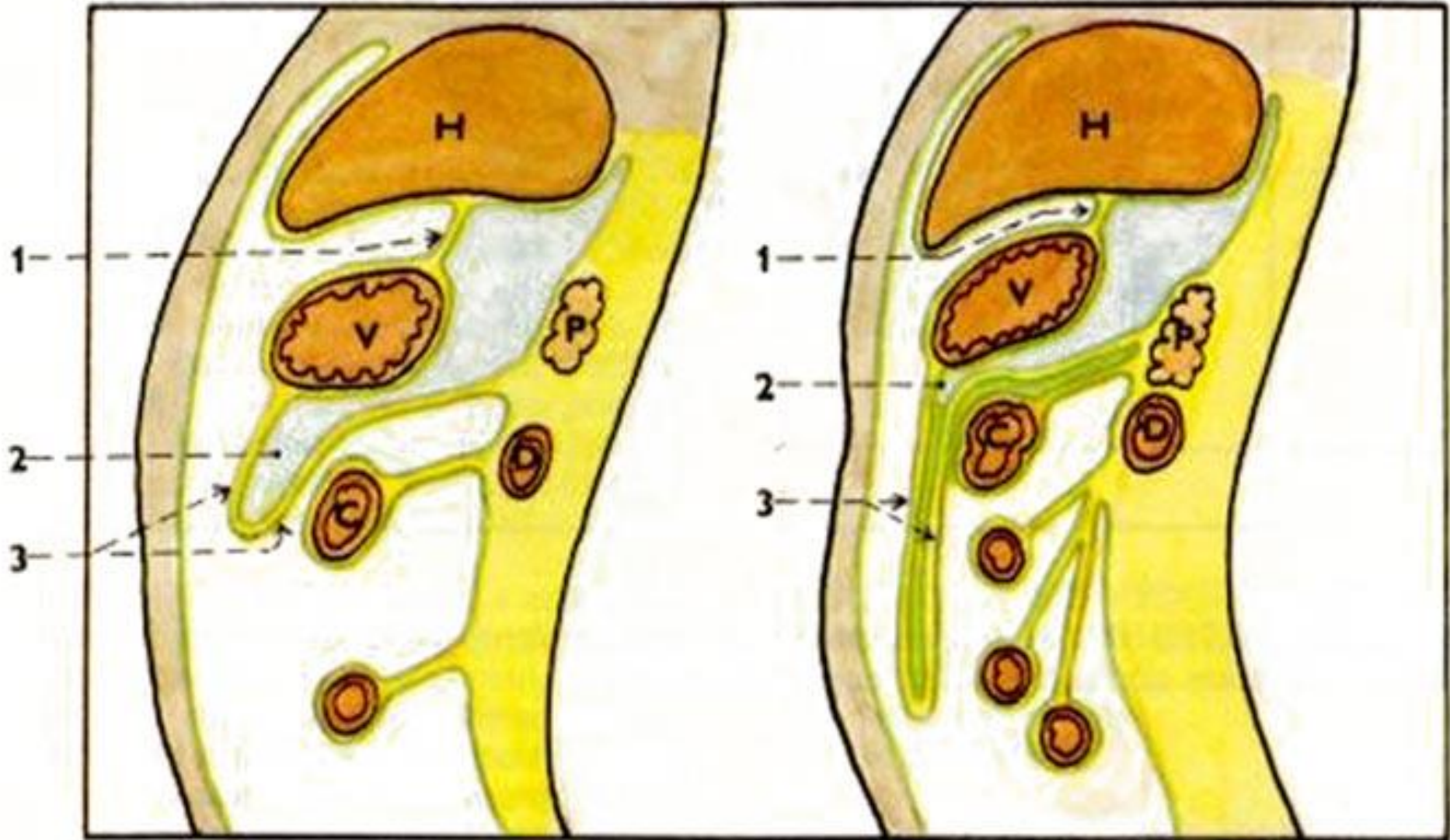


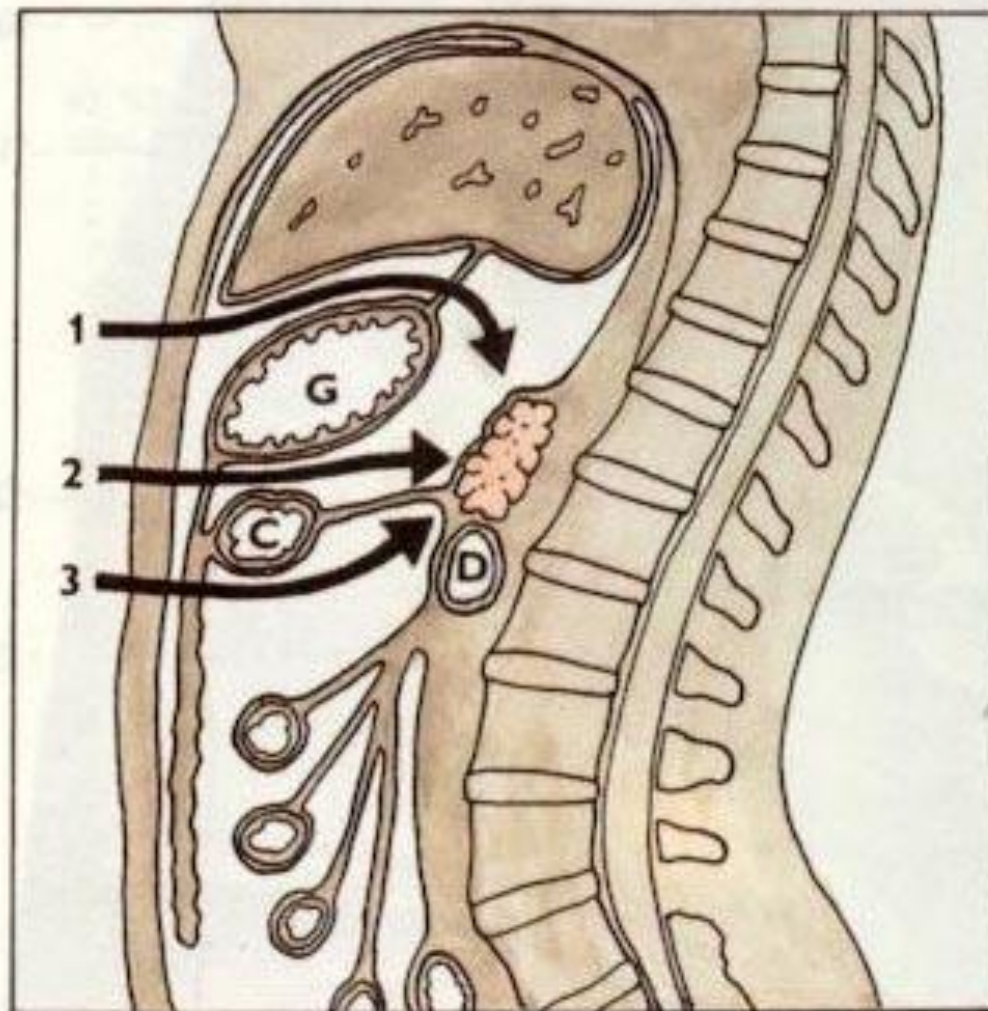
Foramen omentale (epiploicum seu Winslowi)

- entrance to the bursa omentalis from the right
- ventrally: omentum minus (lig. hepatoduodenale)
- dorsally: peritoneum (lig. hepatorenale)
- cranially: liver (processus caudatus lobi caudati)
- caudally: bulbus (ampulla) duodeni

foramen omentale → vestibulum → isthmus (tuber omentale pancreatis) → proper bursa

Bursa omentalis





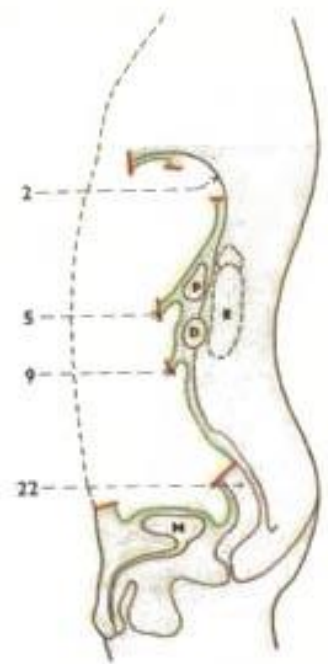
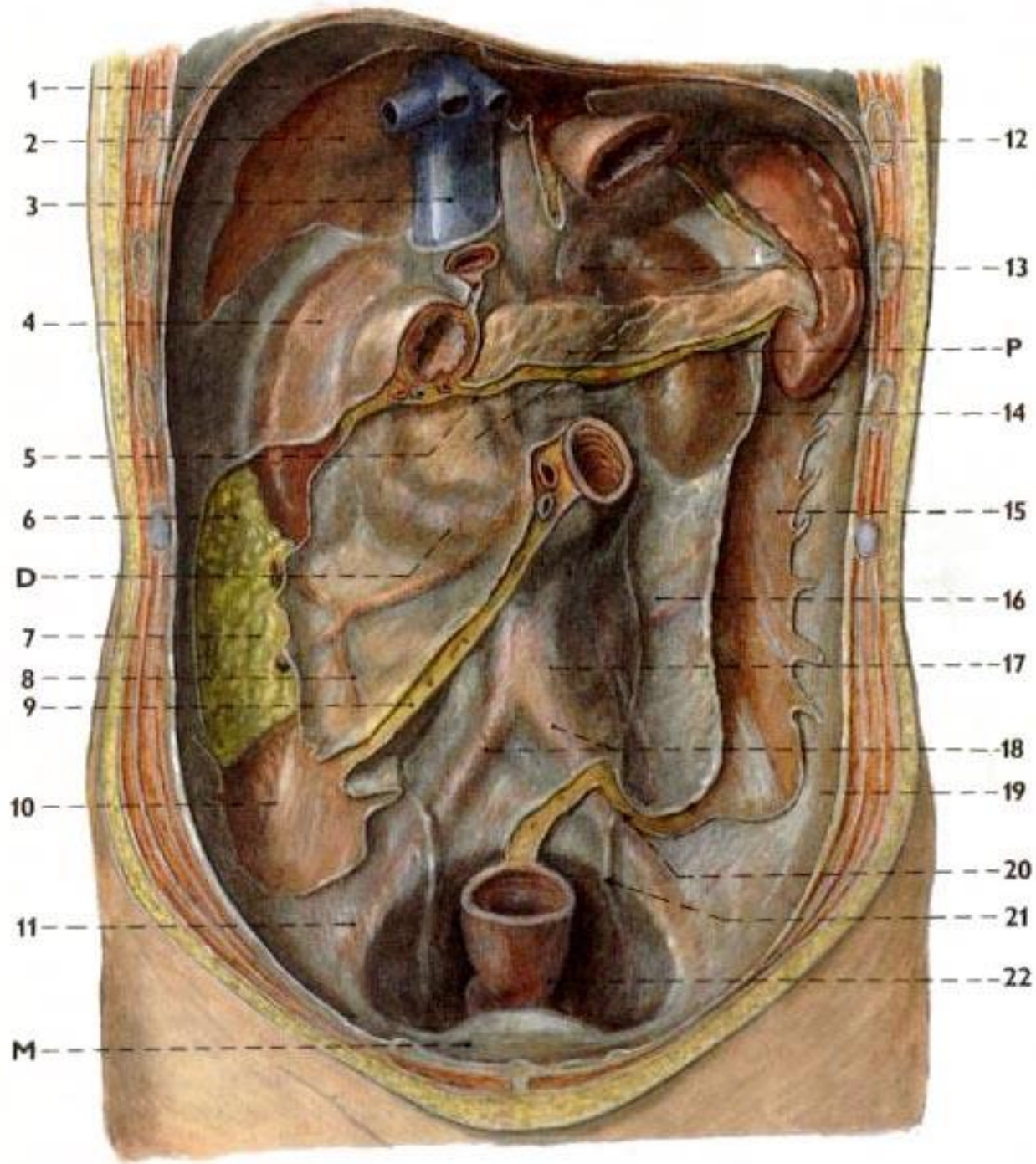
94. TŘI PREPARAČNÍ PŘÍSTUPY K PANKREATU
(schéma)

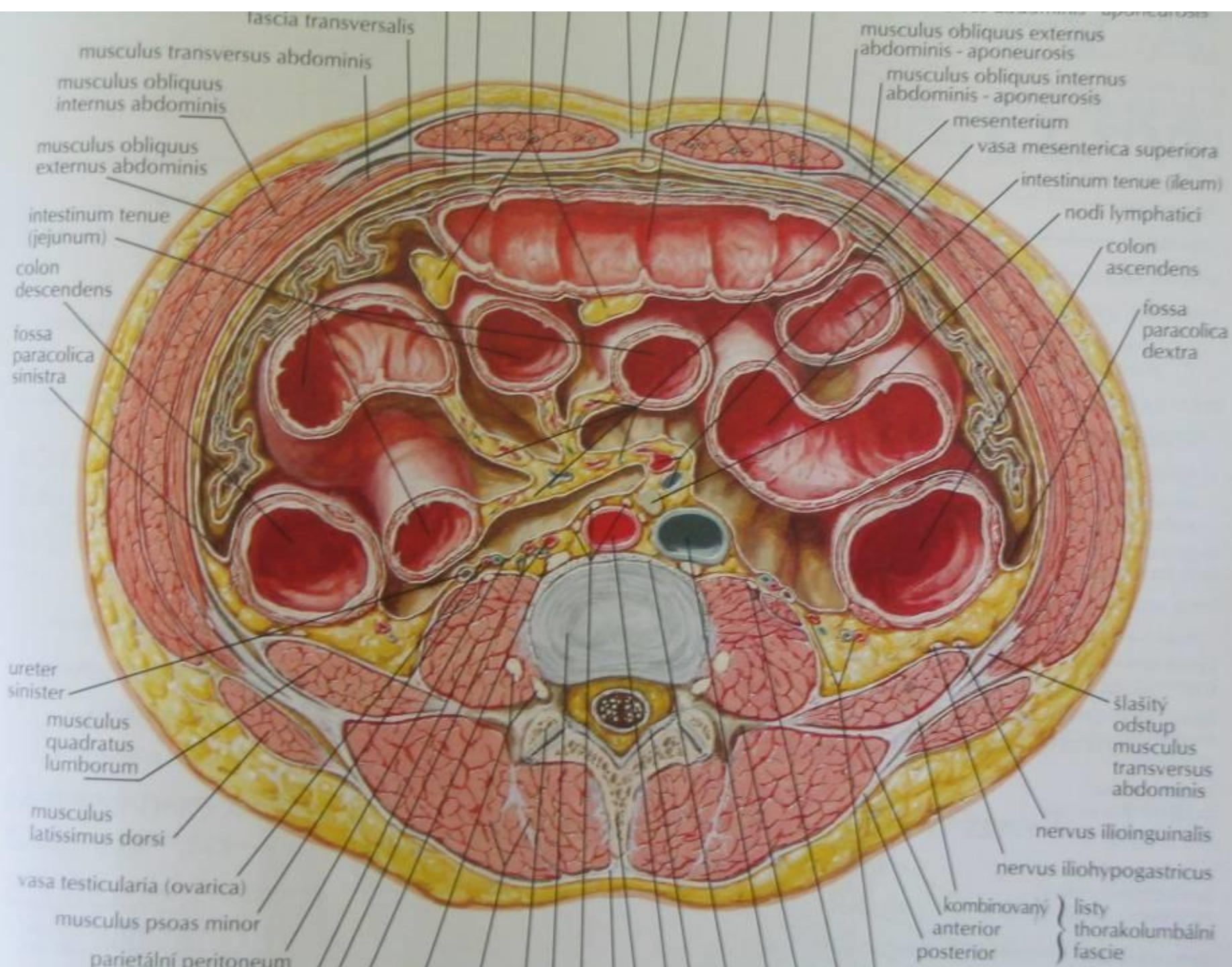
- 1 / horní přístup skrze omentum minus
- 2 / střední přístup skrze lig. gastrocolicum
- 3 / dolní přístup skrze mesocolon transversum
- G / žaludek
- C / colon transversum
- D / duodenum

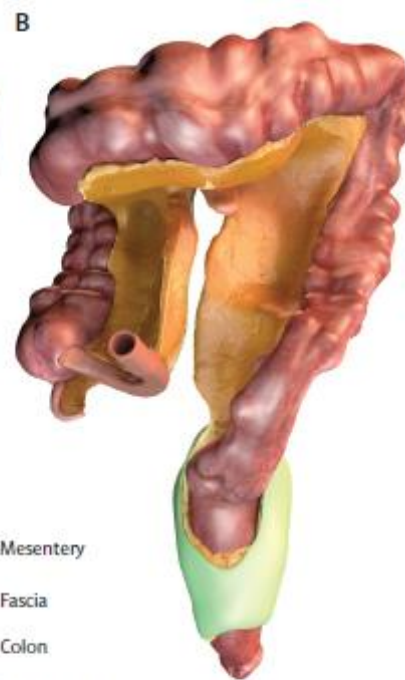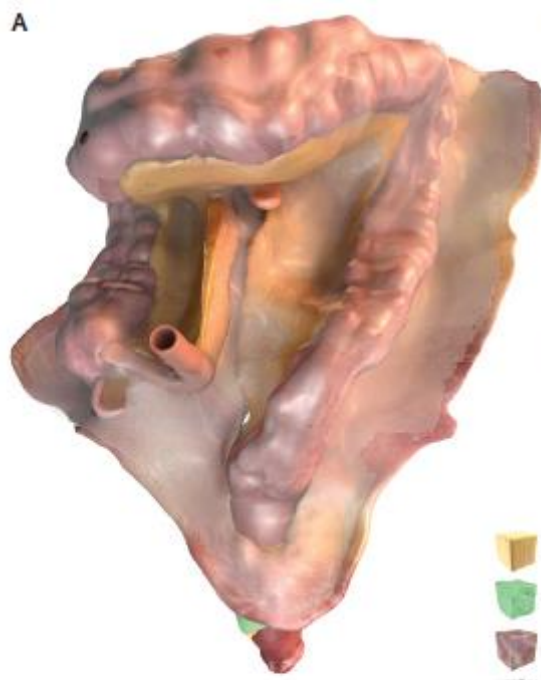Mesos – pars inframesocolica

- mesenterium
 - radix mesenterii
- mesoappendix
- mesocaecum – variable
- (*mesocolon ascendens + descendens*) → *disappeared*
- mesocolon transversum
 - radix mesocoli transversi – border between pars supramesocolica et inframesocolica cavitatis peritonealis
- mesocolon sigmoideum
 - radix mesocoli sigmoidei
- mesorectum – *krátké*

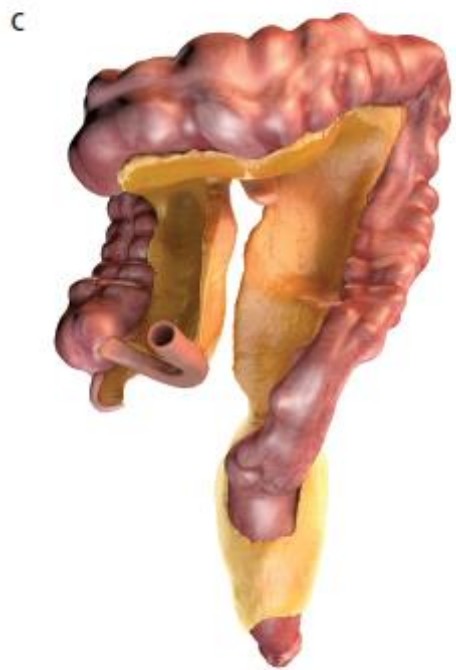- *mesovarium, mesosalpinx, mesometrium*
 - together constituting lig. latum uteri (broad lig. of uterus)



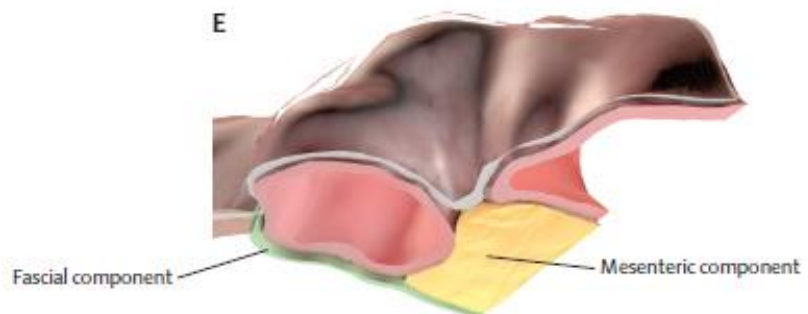
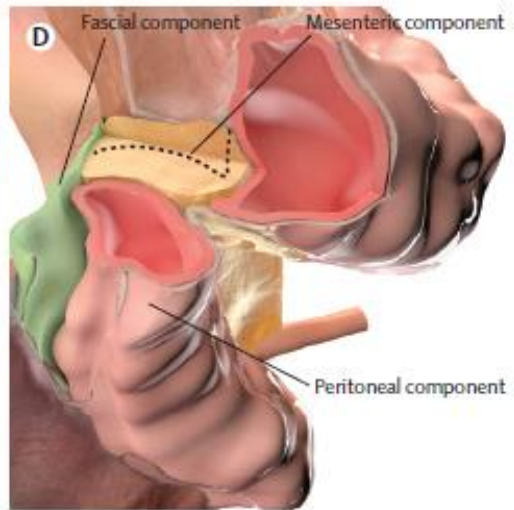
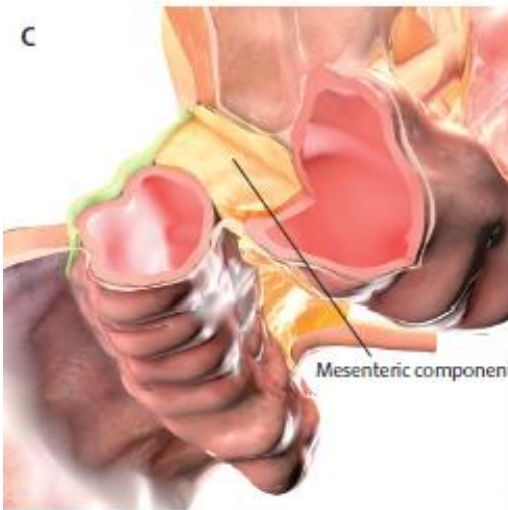
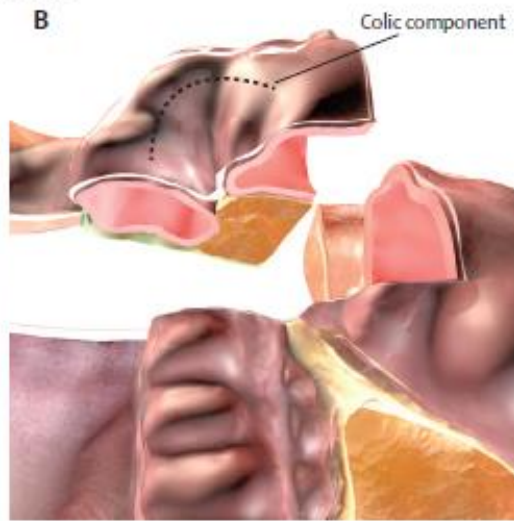
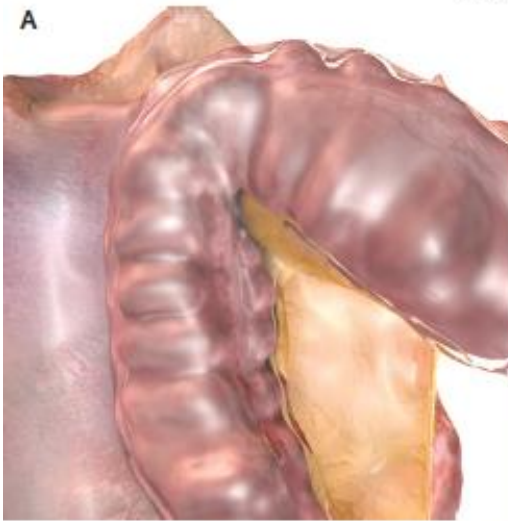


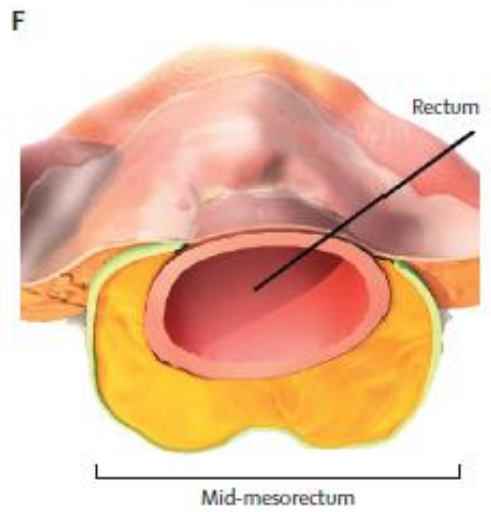
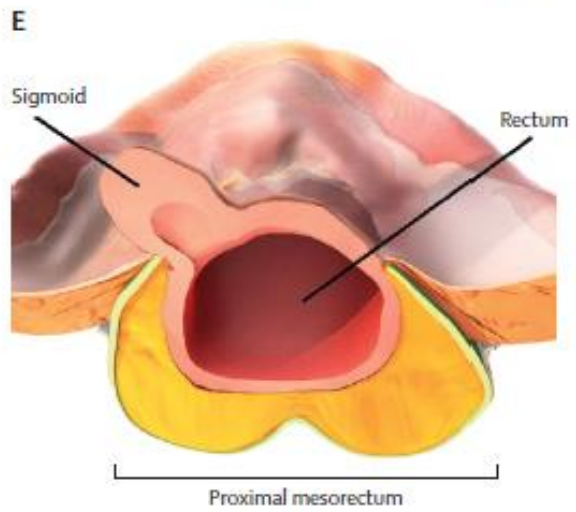
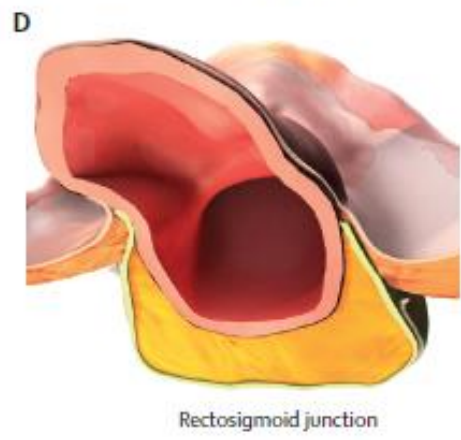
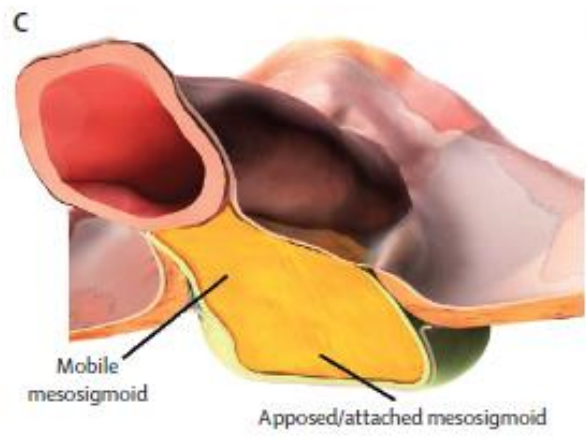
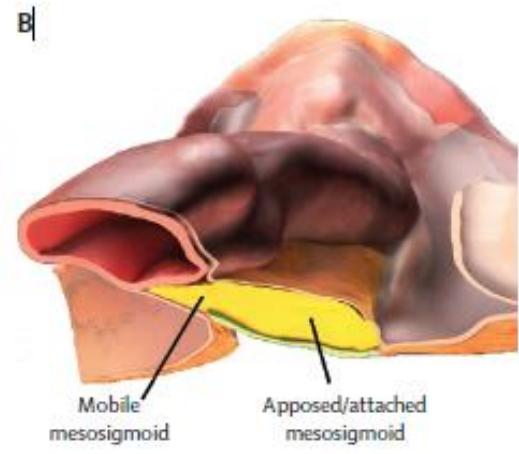
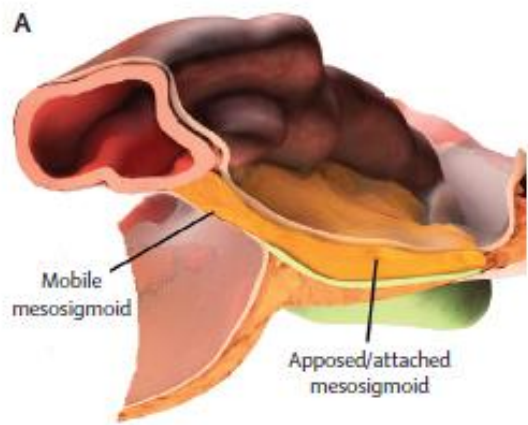


- Mesentery
- Fascia
- Colon
- Peritoneum

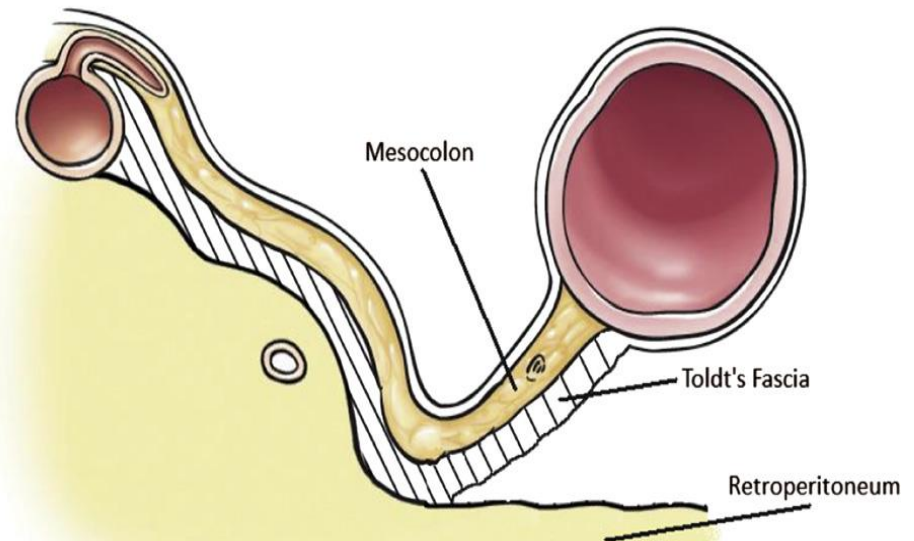
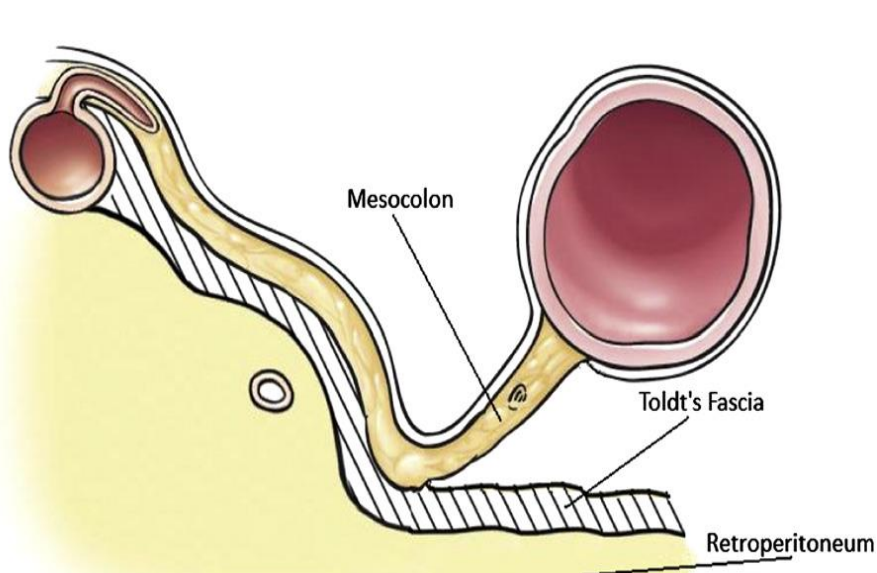
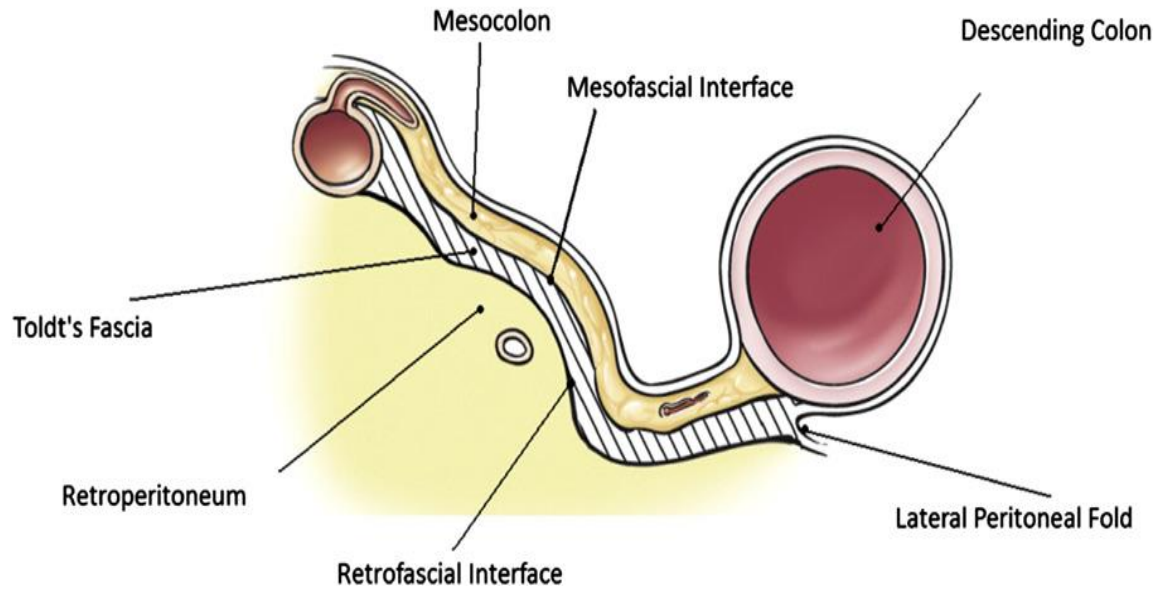


Hepatic flexure



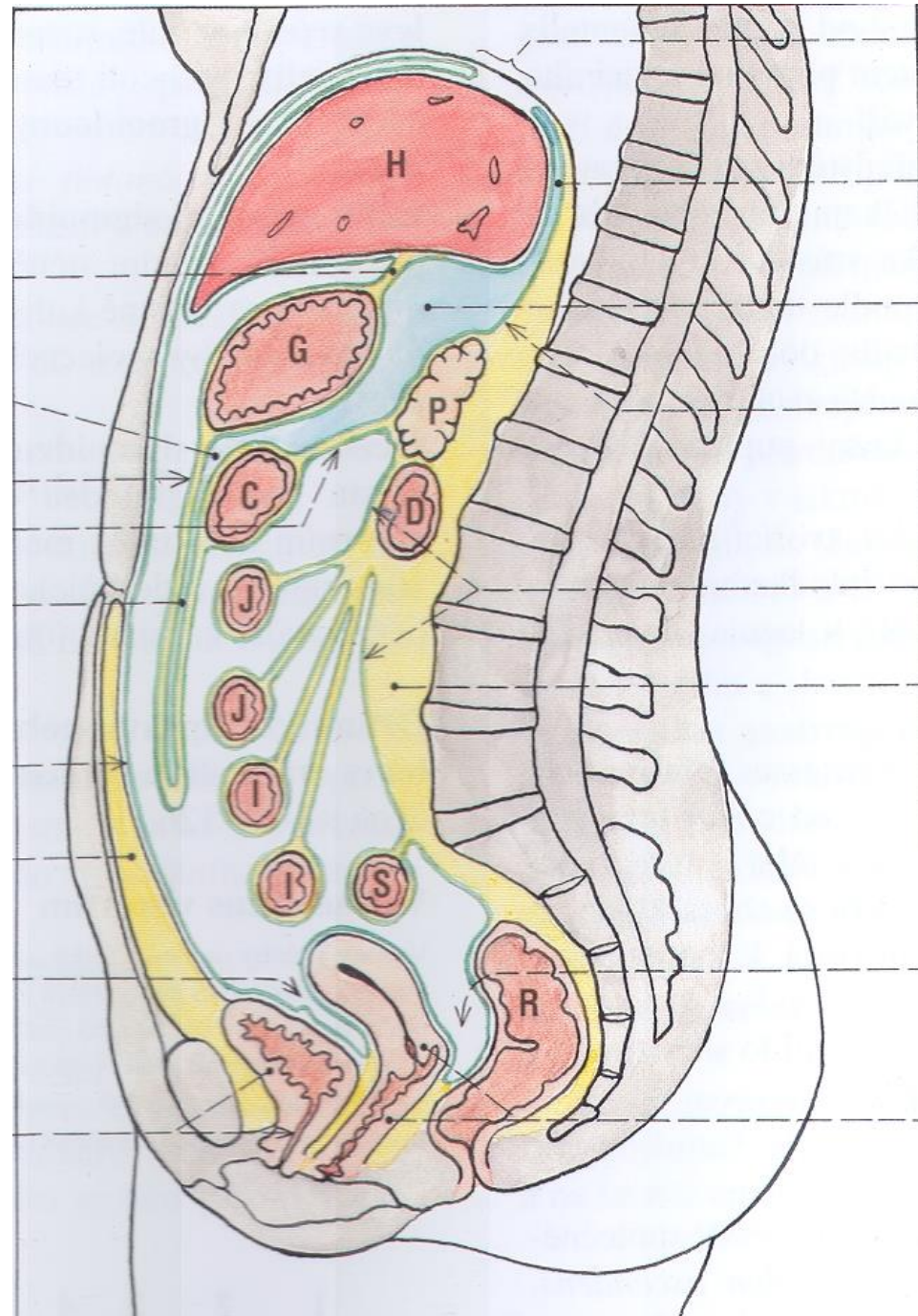


Fascia Toldt („fusion fascia“)



Recessus peritonei

- recessus subphrenicus sin.+ dx.
- recessus subhepaticus sin.+ dx.
(rec. hepatorenalis = Morisonův prostor)
- 4 at flexura duodenojejunalis
- 3 at ostium ileocaecale
- rec. intersigmoideus Treitzi
- 1 ♂ / 2 ♀ excavationes
- fossae paravesicales + pararectales
- sulci paracolici
- *others*



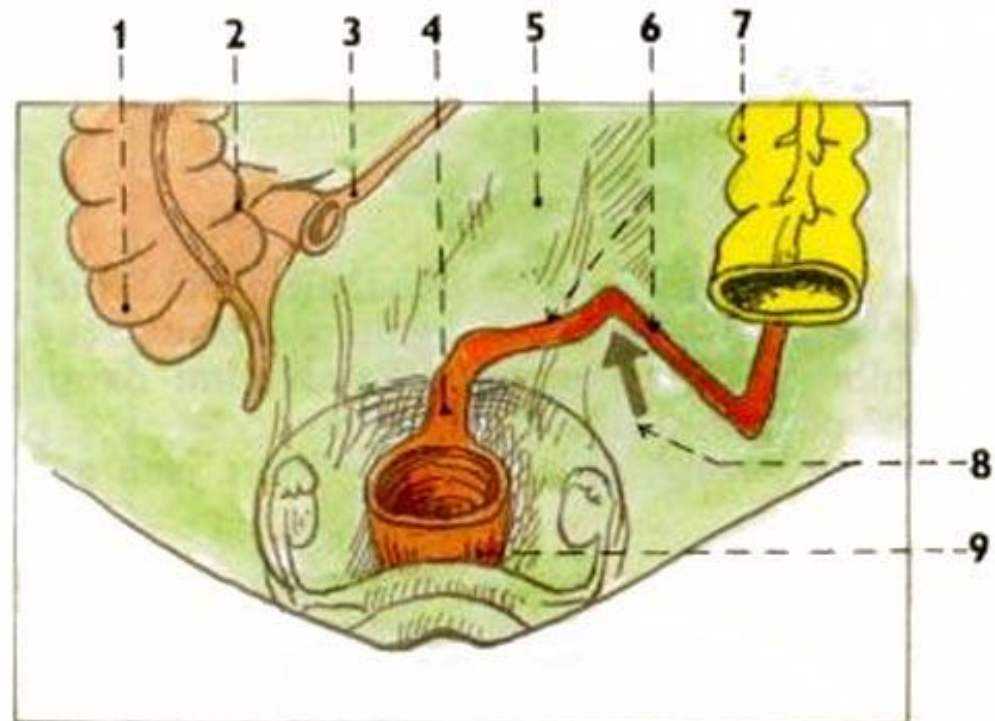
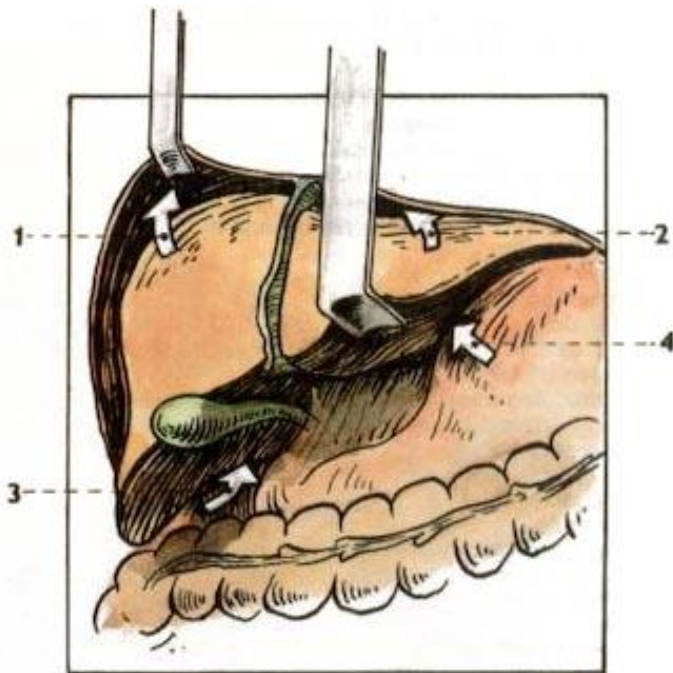
Recessus peritonei

- pars supramesocolica cavitatis peritonealis
 - **bursa omentalis** (recessus sup., inf., splenicus)
 - **recessus subphrenicus, subhepaticus** (hepatorenalis = spatium *Morisoni*)
- pars inframesocolica cavitatis peritonealis
 - recessus duodenalis sup., inf., paraduodenalis, retroduodenalis
 - recessus ileocaecalis sup., inf., retrocaecalis
 - **recessus intersigmoideus** (*Treitzii*)
 - **sulci paracolici**
 - **fossa supravesicalis, inguinalis med. et lat.**
 - **fossa paravesicalis, pararectalis**

 - female: **excavatio vesicouterina, rectouterina** (spatium *Douglasi*), fossa ovarica
 - male: **excavatio rectovesicalis** (spatium *Prousti*)

Recessus peritonei

- rec. subphrenicus dexter
 - rec. subphrenicus sinister
 - rec. subhepaticus dexter (spatium Morisoni)
 - rec. subhepaticus sinister
- rec. intersigmoideus (Treitzi)

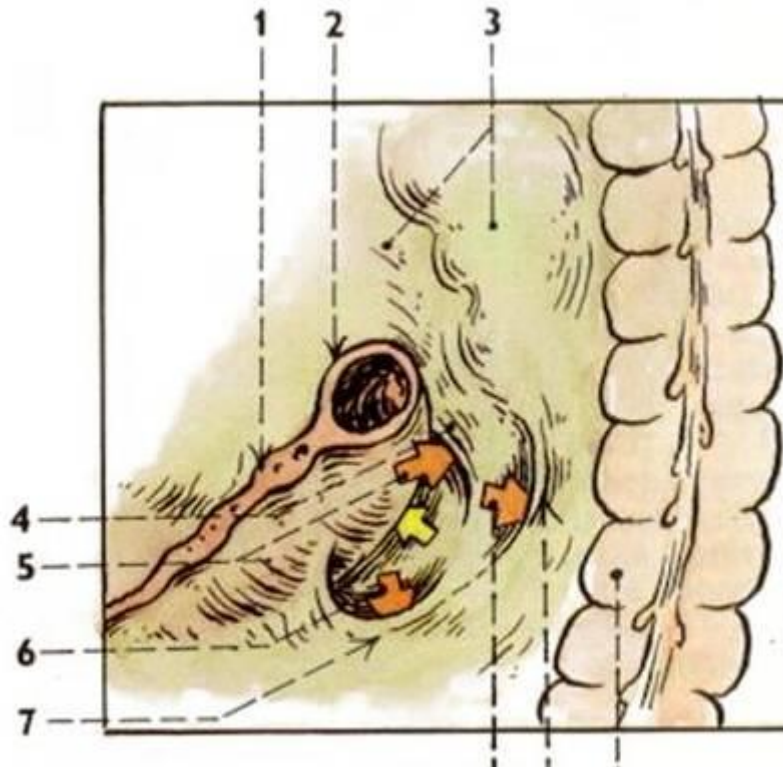



111. ŠTĚRBINY A ZÁHYBY PERITONEÁLNÍ DUTINY U JATER (schéma)

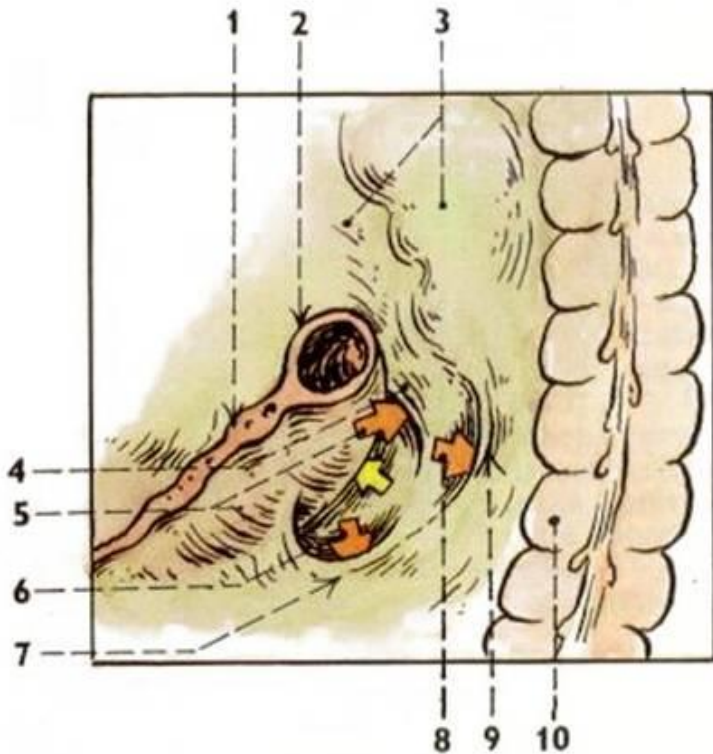
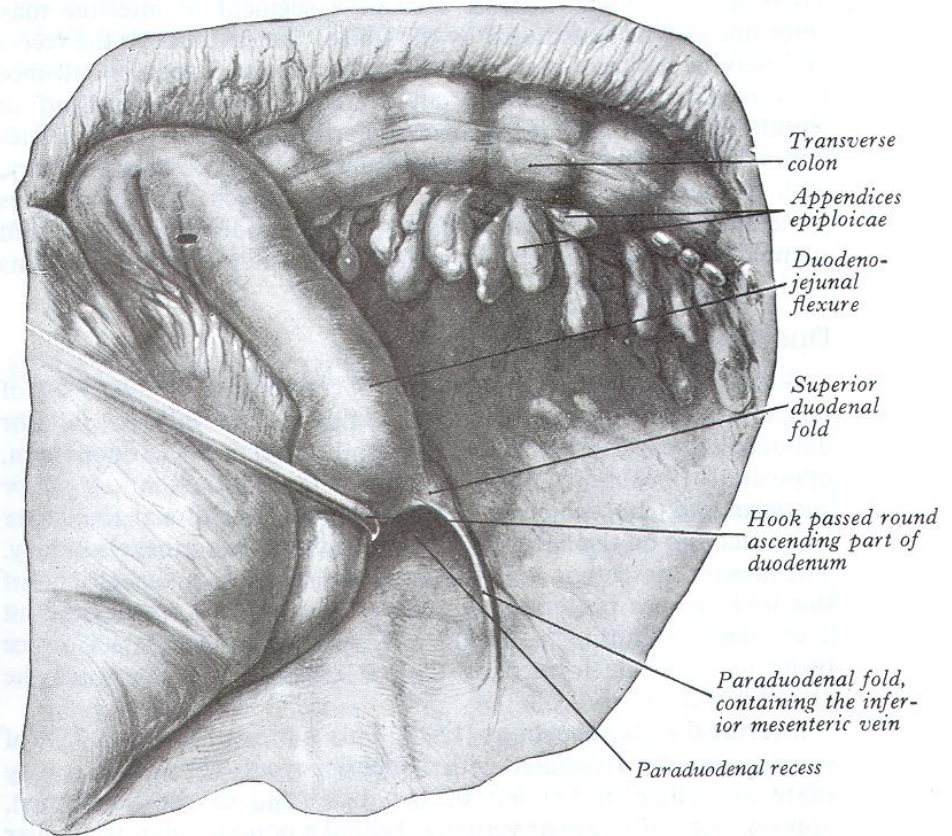
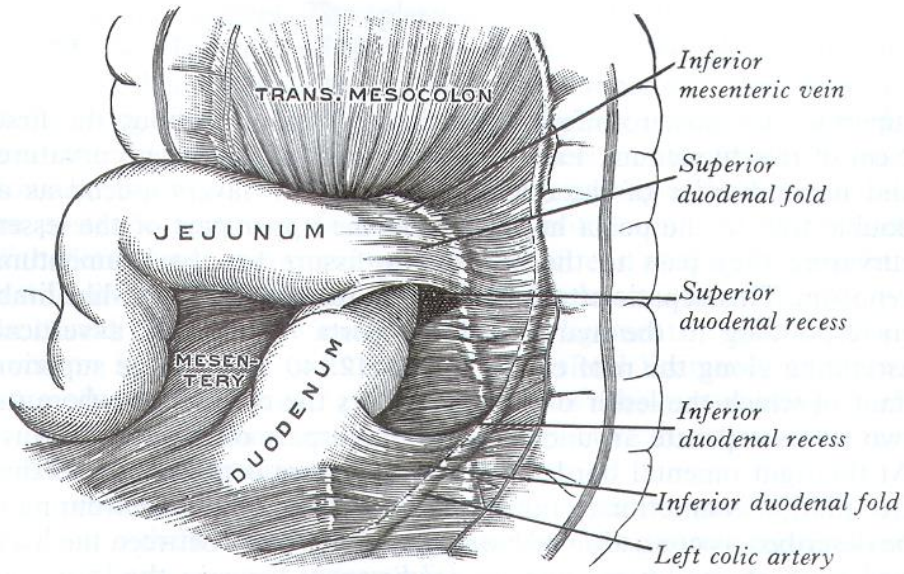
- 1 / recessus subphrenicus dexter
- 2 / recessus subphrenicus sinister
- 3 / recessus subhepaticus dexter
- 4 / recessus subhepaticus sinister

Recessus peritonei

- **rec. duodenalis superior** (30-50 %)
- **rec. duodenalis inferior** Tretzi (50-75 %)
- rec. paraduodenalis Landzerti (2 %)
- rec. retroduodenalis (1 %)
- rec. mesentericoparietalis Waldeyeri (1 %)
- rec. duodenalis posterior Gruberi
- rec. duodenojejunalis Brösikei (20 % - if present, others are absent)

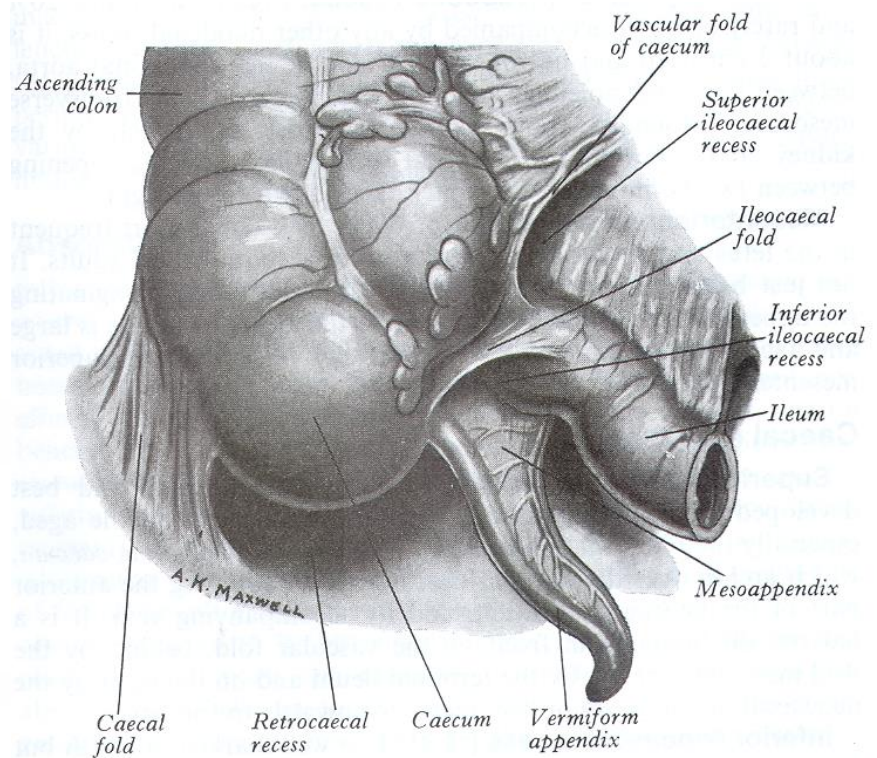
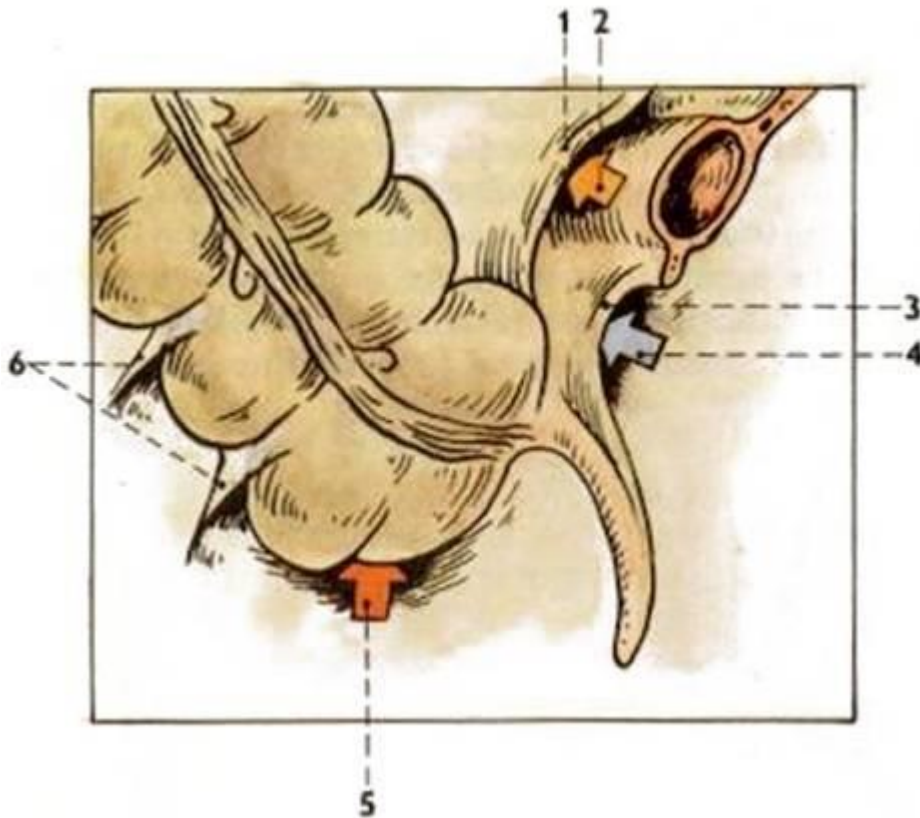


Recessus peritonei

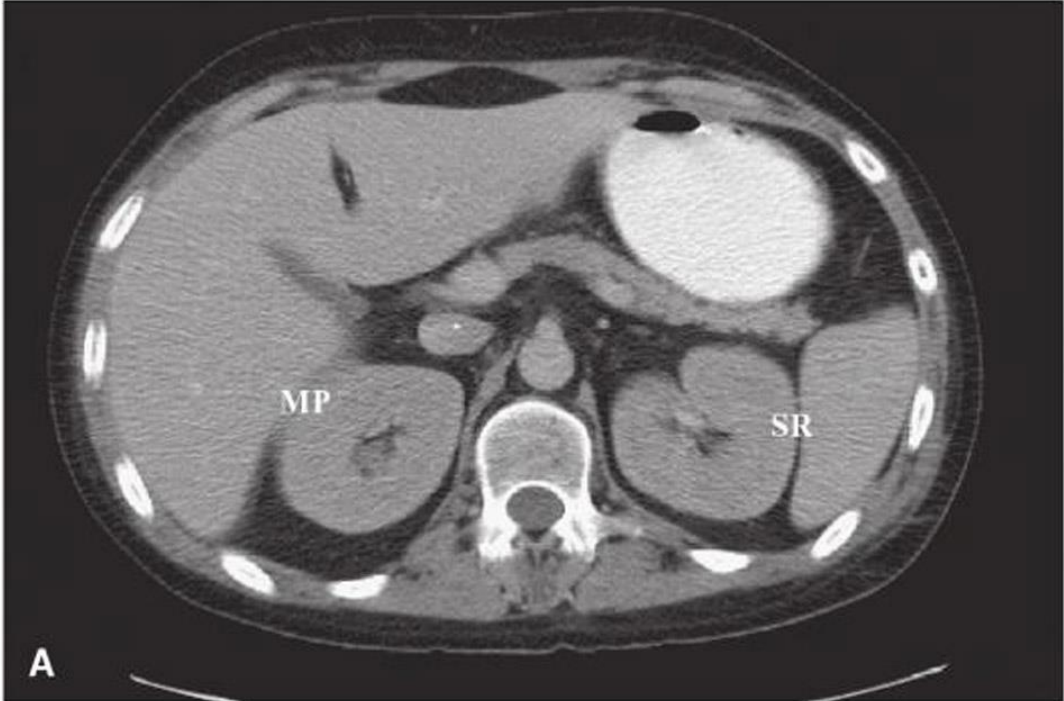
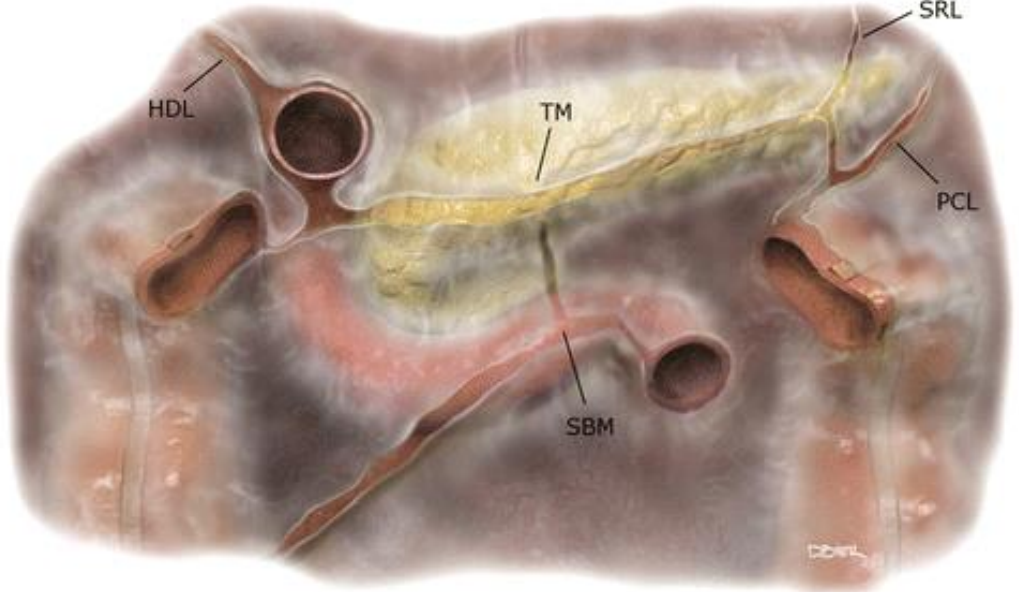


Recessus peritonei

- rec. ileocaecalis superior
- rec. ileocaecalis inferior
- rec. retrocaecalis

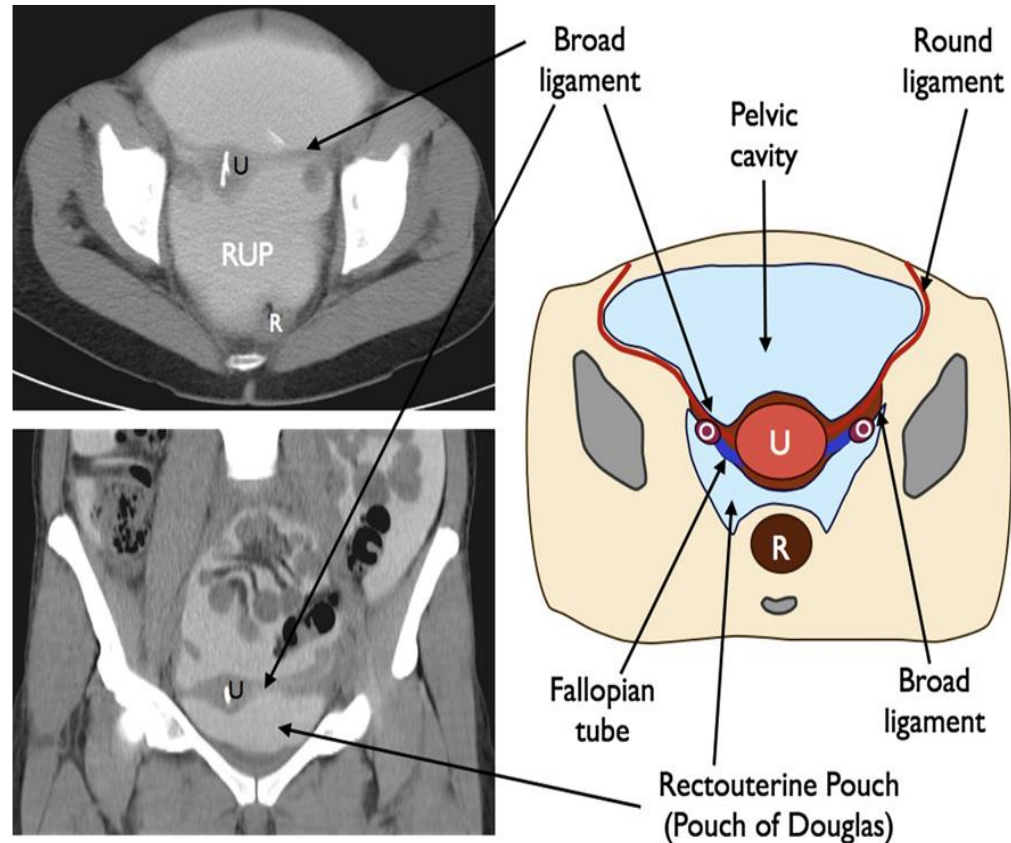


Recessus splenorenalis



Pelvic peritoneum

- lig. latum uteri
 - mesovarium
 - mesosalpinx
 - mesometrium
- plica rectouterina ♀
- plica sacrogenitalis ♂
- plica vesicalis transversa
- plica uterolumbalis
- plica ureterica



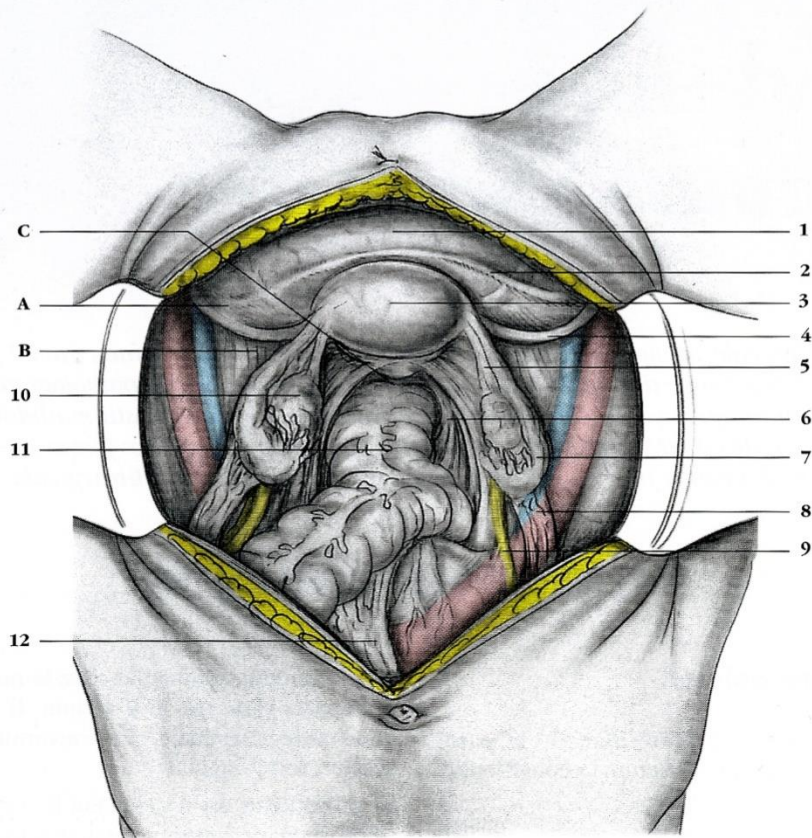


Fig. 3.1. Organes génitaux internes féminins (vue opératoire abdominale).

(KAMINA P., Anatomie clinique de l'appareil génital féminin. *Encycl. Méd. Chir. Gynécologie*, Elsevier, Paris, n° 10A10, II, 1993)

- | | | |
|----------------------------|----------------------------|--------------------------------|
| A. fosse paravésicale | 3. utérus | 8. lig. suspenseur de l'ovaire |
| B. fosse pré-ovarique | 4. ligament rond | 9. uretère |
| C. cul-de-sac recto-utérin | 5. lig. propre de l'ovaire | 10. ovaire |
| 1. vessie | 6. lig. utéro-sacral | 11. rectum |
| 2. pli vésical transverse | 7. trompe utérine | 12. mésosigmoïde |

– *Le mésosalpinx* est triangulaire lorsqu'on l'étale. Il est limité en haut par la trompe et latéralement, par le ligament infundibulo-ovarique. Habituellement large, il se rabat en arrière avec la trompe et recouvre plus ou moins l'ovaire.

rique de l'ovaire (hile de l'ovaire). Il contient les vaisseaux et nerfs de l'ovaire.

– *La fosse préovarique*¹ est limitée par le pli funiculaire en avant, et le mésosalpinx en arrière. Elle forme un triangle dont la base laté-

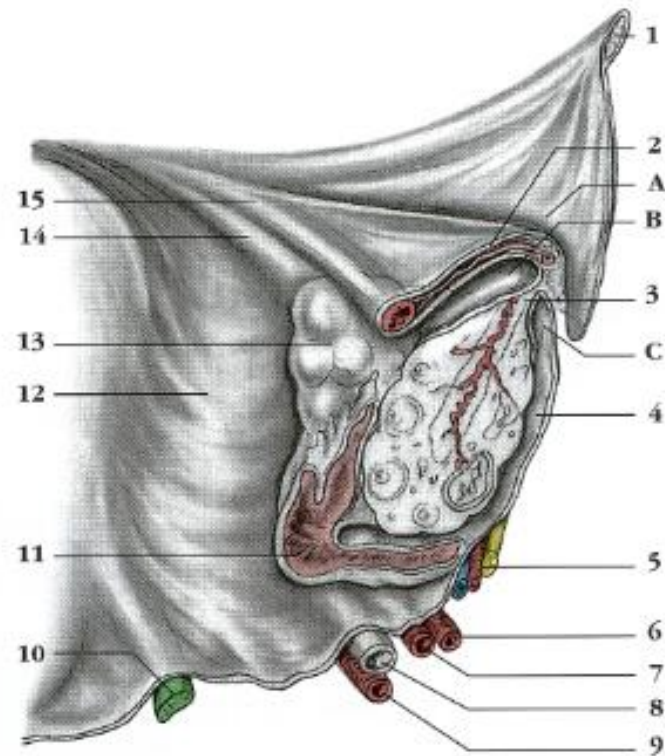


Fig. 3.3. Récessus ovariens (coupe sagittale au niveau de la fosse ovarique).

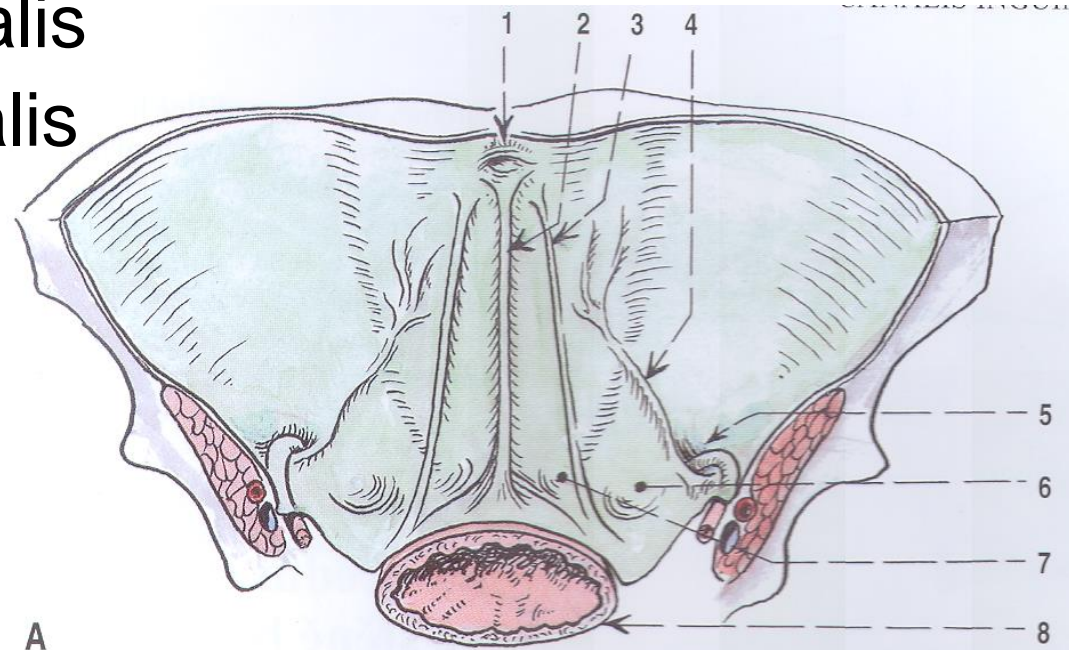
(KAMINA P. Anatomie clinique de l'appareil génital féminin. *Encycl. Méd. Chir. Gynécologie*, Elsevier, Paris, n° 10A10, II, 1993)

- | | |
|----------------------------|-----------------------------|
| A. fosse préovarique | 7. a. utérine |
| B. récessus tubo-ovarique | 8. uretère |
| C. récessus ovaro-pariétal | 9. a. vaginale |
| 1. lig. rond | 10. lig. utéro-sacral |
| 2. mésosalpinx | 11. frange ovarique |
| 3. mésovarium | 12. mésomètre |
| 4. fossette ovarique | 13. ovaire |
| 5. pédicule obturateur | 14. lig. propre de l'ovaire |
| 6. a. ombilicale | 15. trompe utérine |

Anterior abdominal wall peritoneum

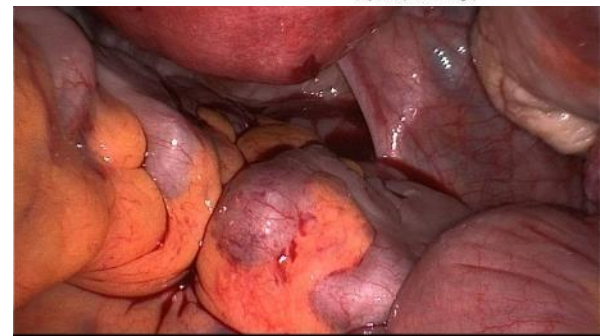
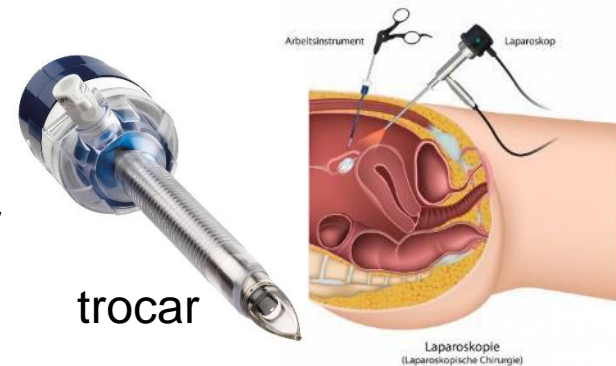
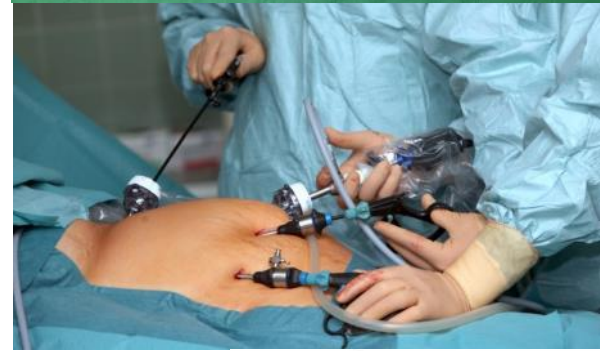- plica umbilicalis mediana
- fossa supravesicalis
- plica umbilicalis medialis
- fossa inguinalis medialis (at trigonum inguinale *Hesselbachi*)
- plica umbilicalis lateralis
- fossa inguinalis lateralis (at anulus inguinalis profundus)

heriae inguinales



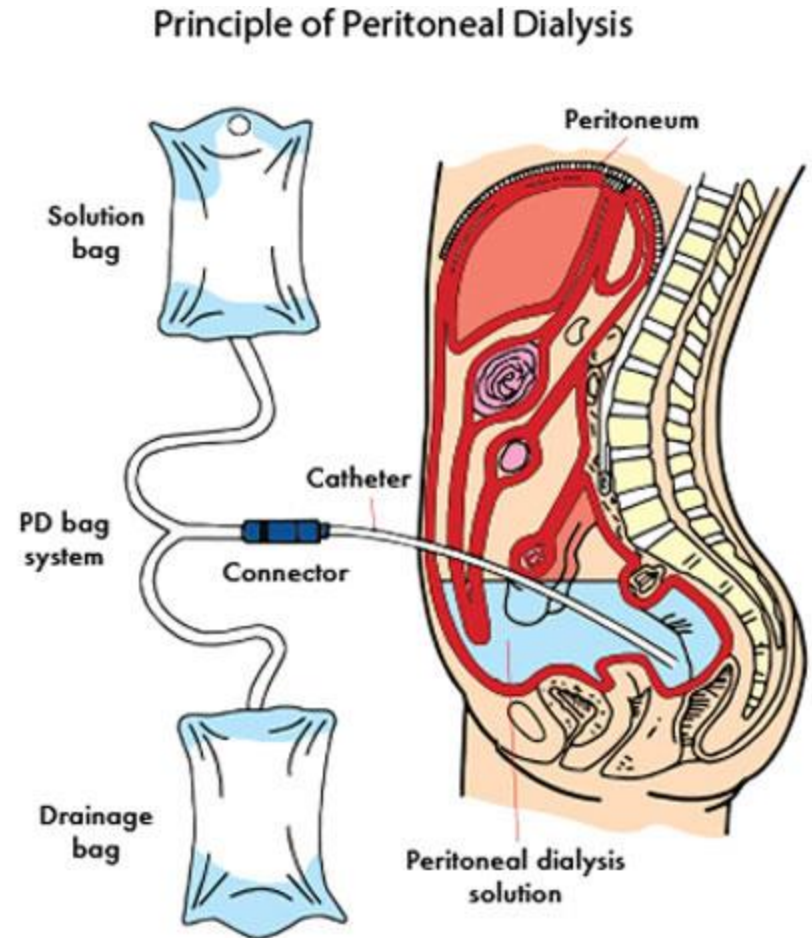
Laparoscopy

- establishment of capnoperitoneum
 - using a Veress needle (insufflation cannula), the abdominal cavity is filled with CO₂ to a pressure of 8-15 mmHg depending on the type of operation)
- insertion of a laparoscope
 - most often around the umbilicus (above / below)
 - a trocar is inserted and then a laparoscope (cold light camera based on optical fibers, with a tilt of the field of view of the camera of 30 °, which allows the operator to "see around the corner")
- introduction of other tools
 - trocars with laparoscopic instruments are introduced under the control of the camera

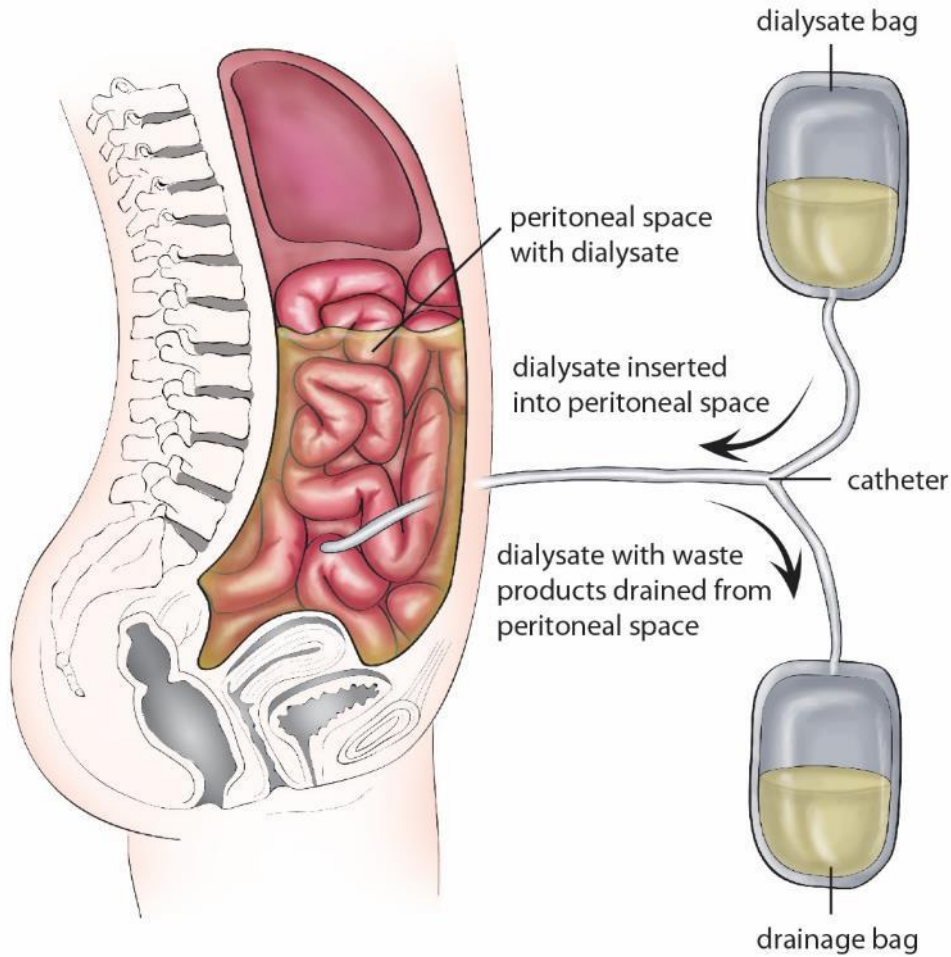


Peritoneal dialysis

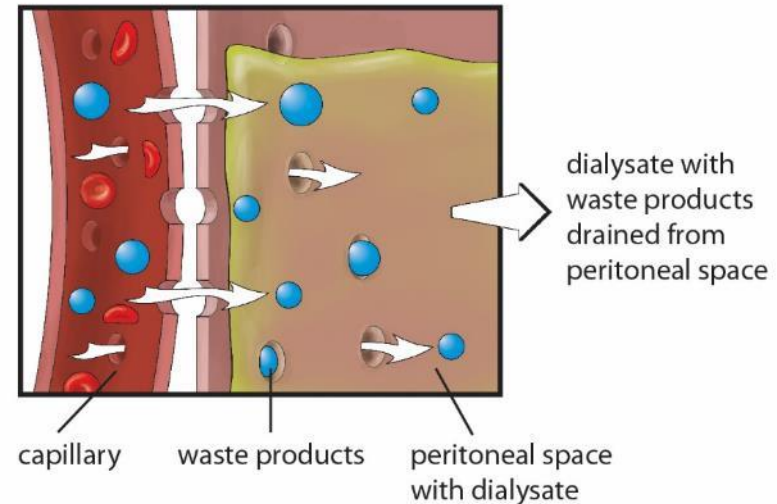
- purification of blood in case of kidney failure by repeated regular filling of dialysis fluid into the peritoneal cavity
- the patient usually does it himself
- at night for about 10 hours (4-5 complete exchanges)
- 90% visceral vessel, 10% parietal vessel
- blood flow 50-100 ml / min



Peritoneal dialysis



waste products cross the semipermeable membranes into the peritoneal space





Development of digestive tube

<https://www.youtube.com/watch?v=cBSyOgjTGVU>

https://www.youtube.com/watch?v=AscKR_cQExY

Abdominal vessels

Aorta abdominalis

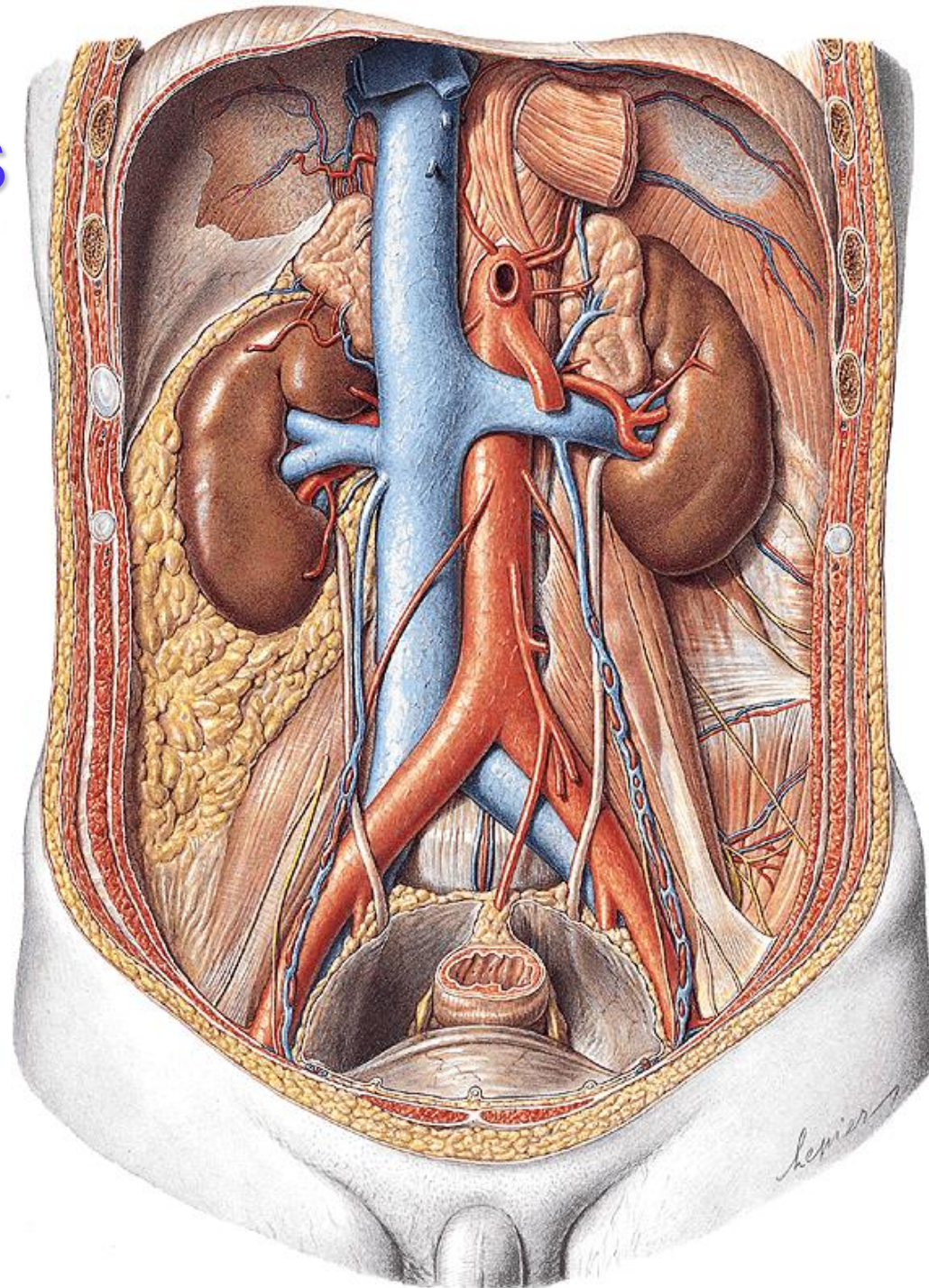
origin: hiatus
oesophageus
diaphragmatis

end: bifurcatio aortae L4

- retroperitoneum, midly left to vertebral column
- on the right: v. cava inferior + ductus thoracicus

branches:

- paired/unpaired
- parietal/visceral



Aorta abdominalis

Parietal branches: *paired*

- a. phrenica inferior
- aa. lumbales 1.- 4.
- rr. retroperitoneales (6-7)

Visceral branches: *paired*

- a. suprarenalis media
- a. renalis
- a. renalis accessoria (30%)
- a. testicularis♂ / ovarica♀

AORTA ABDOMINALIS

a. suprarenalis sup.

a. suprarenalis media

a. suprarenalis inf.

a. renalis

a. ovarica /
testicularis

a. phrenica inf.

truncus coeliacus

a. mesenterica sup.

a. mesenterica inf.

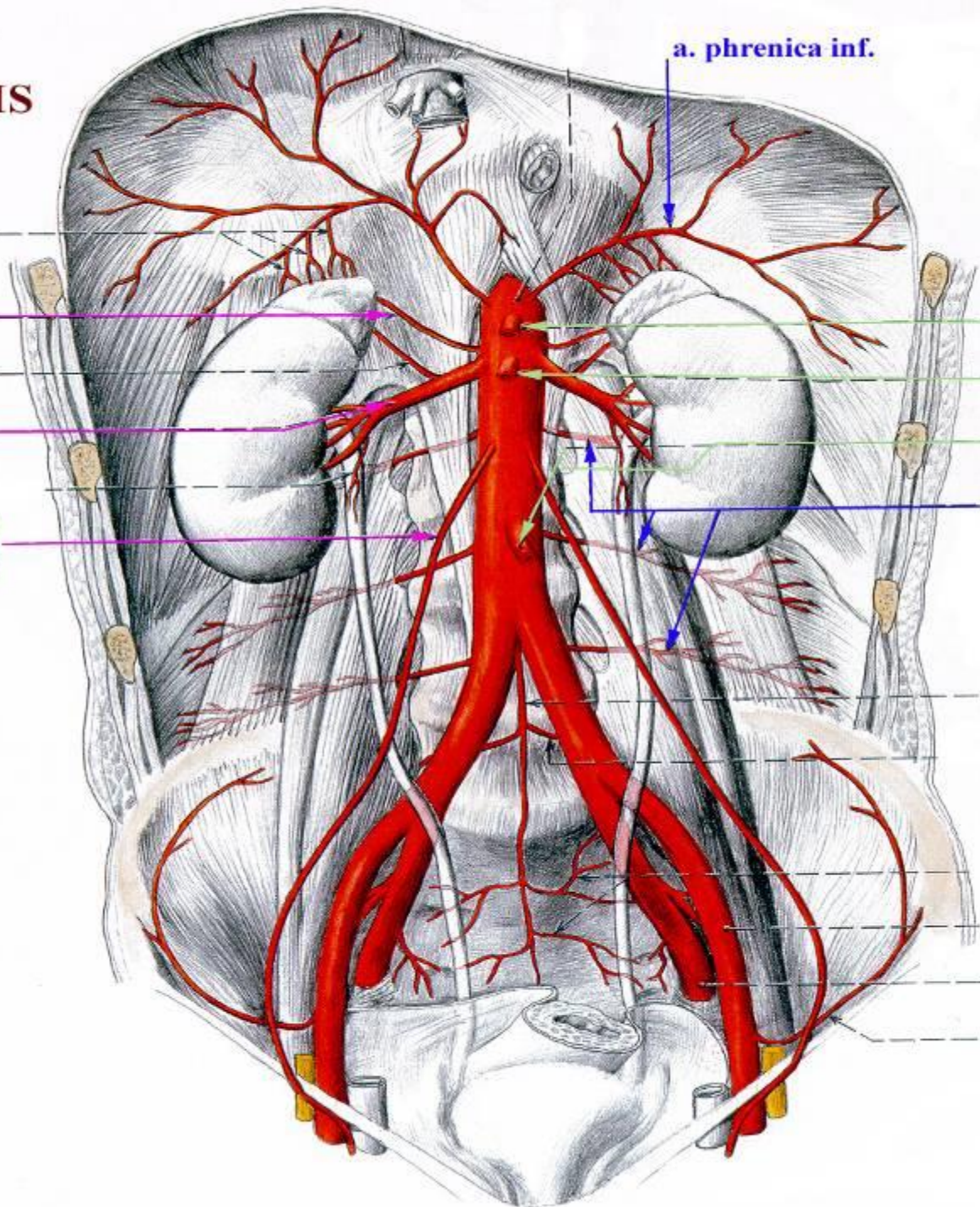
aa. lumbales

a. sacralis media

a. iliaca interna

a. iliaca externa

a. circumflexa
ilium profunda



Aorta abdominalis

Terminal branches: *paired*

- a. iliaca communis

Terminal branches: *unpaired*

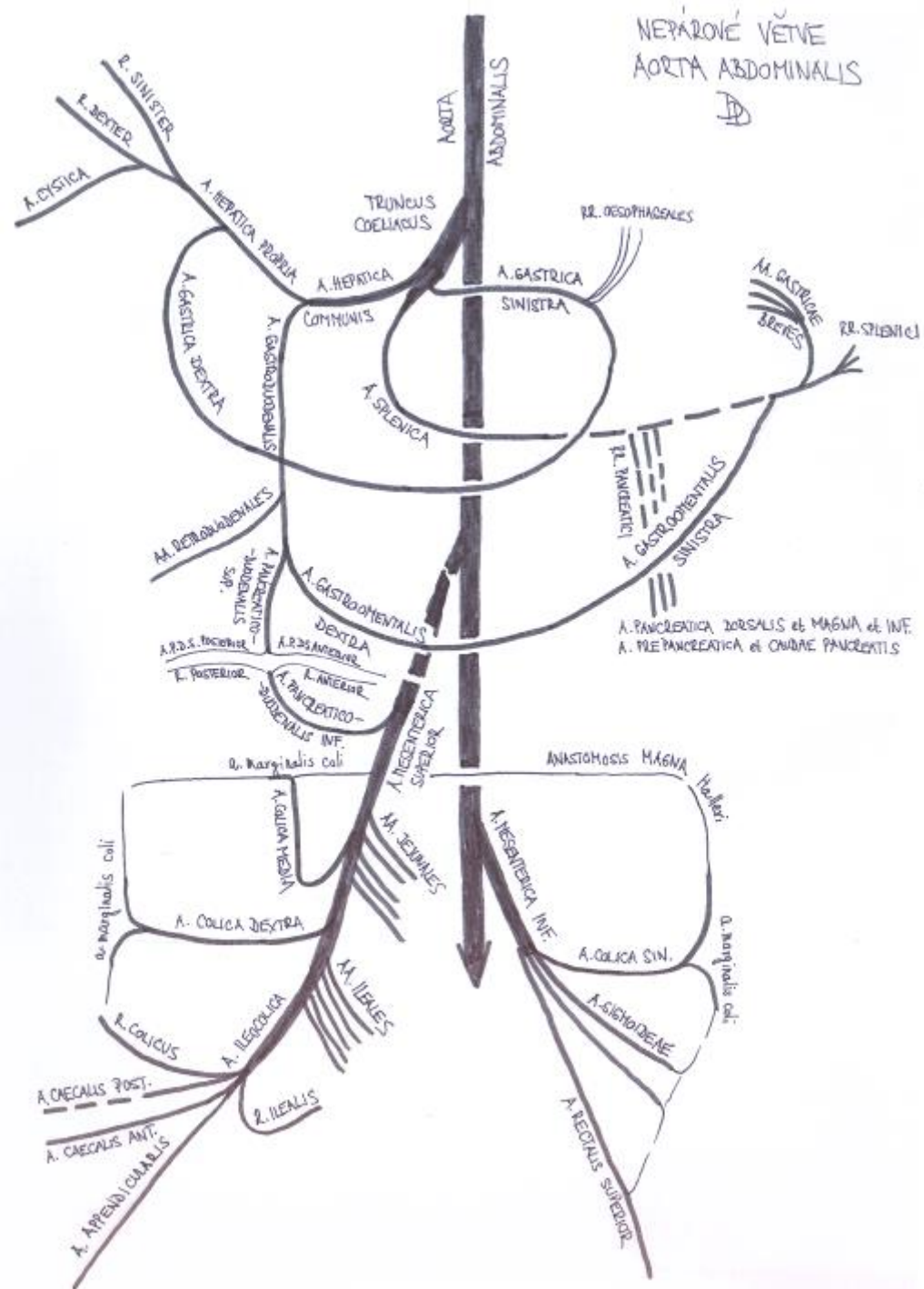
- a. sacralis mediana

Visceral branches: *unpaired*

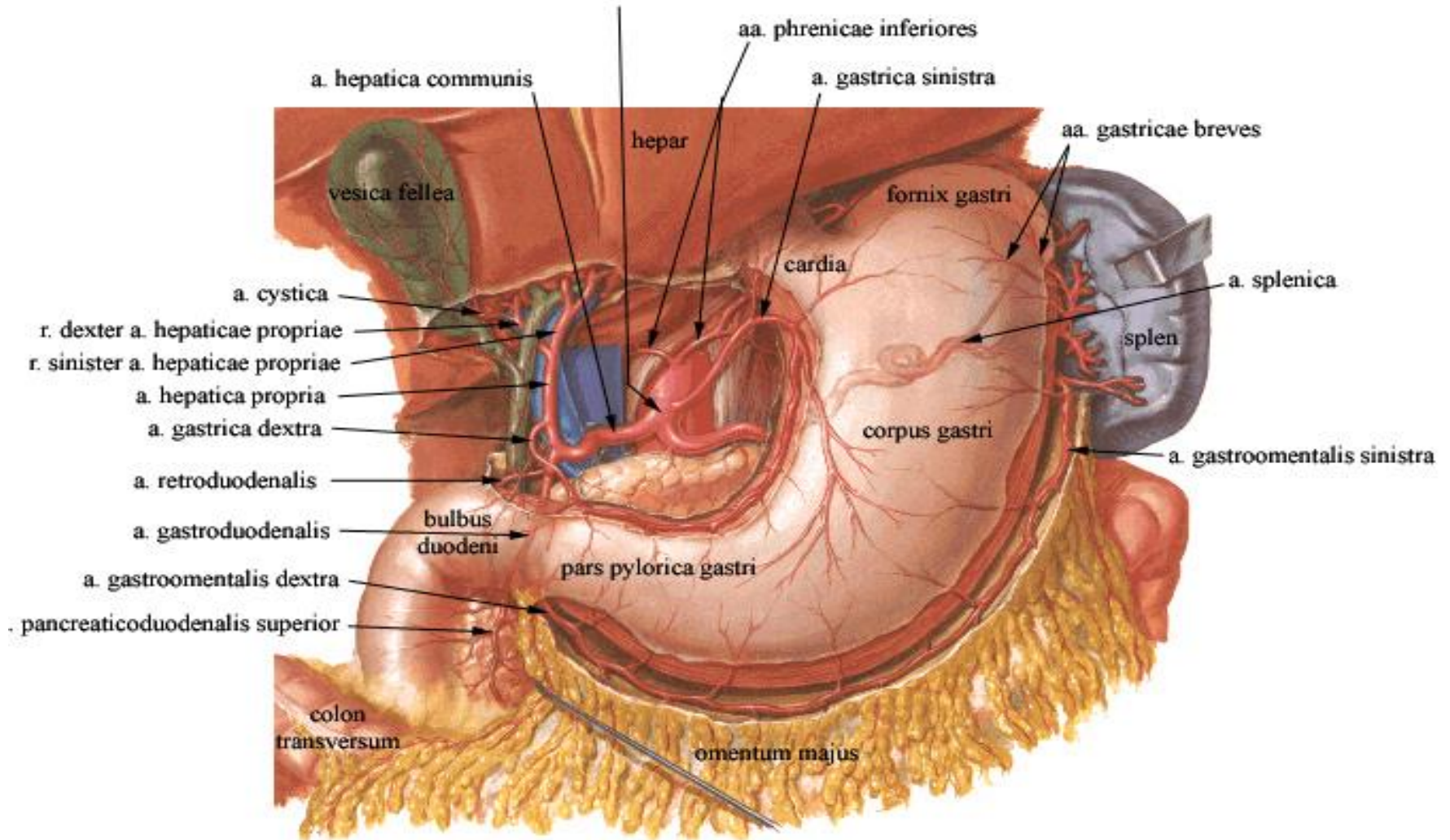
- truncus coeliacus
- a. mesenterica superior
- a. mesenterica inferior

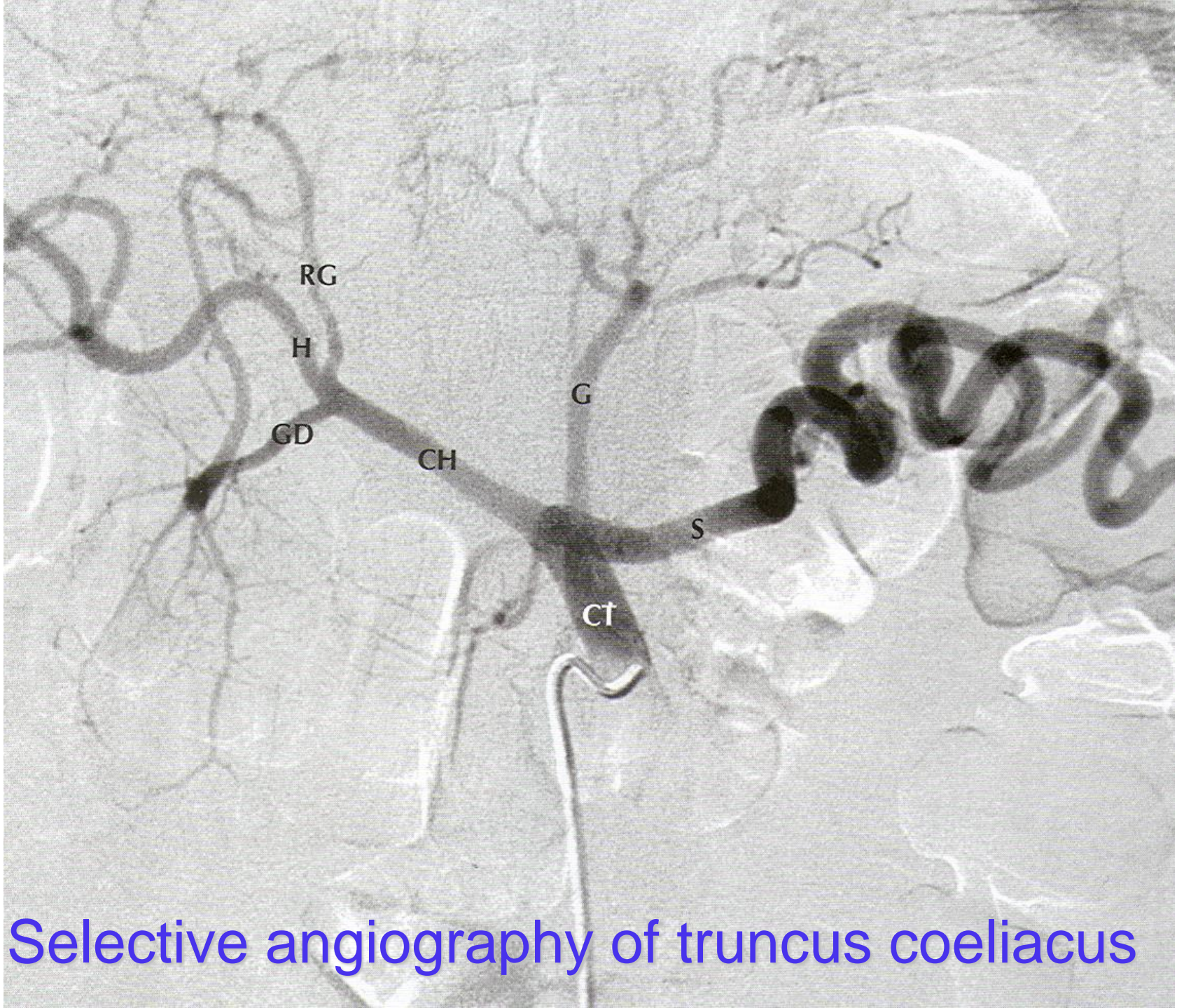
Unpaired visceral branches

- **truncus coeliacus**
→ foregut
- **a. mesenterica superior**
→ midgut
- **a. mesenterica inferior**
→ hindgut
- venous drainage via v. portae hepatis to liver
- *knowledge of individual organs' blood supply is necessary for performing resection and transplantation*



TRUNCUS COELIACUS





Selective angiography of truncus coeliacus

Stomach

truncus coeliacus

→ a. gastrica sin.

→ a. hepatica communis

→ a. hepatica propria → a. gastrica dx.

→ a. gastroduodenalis → a. gastromentalis dx.

→ a. splenica

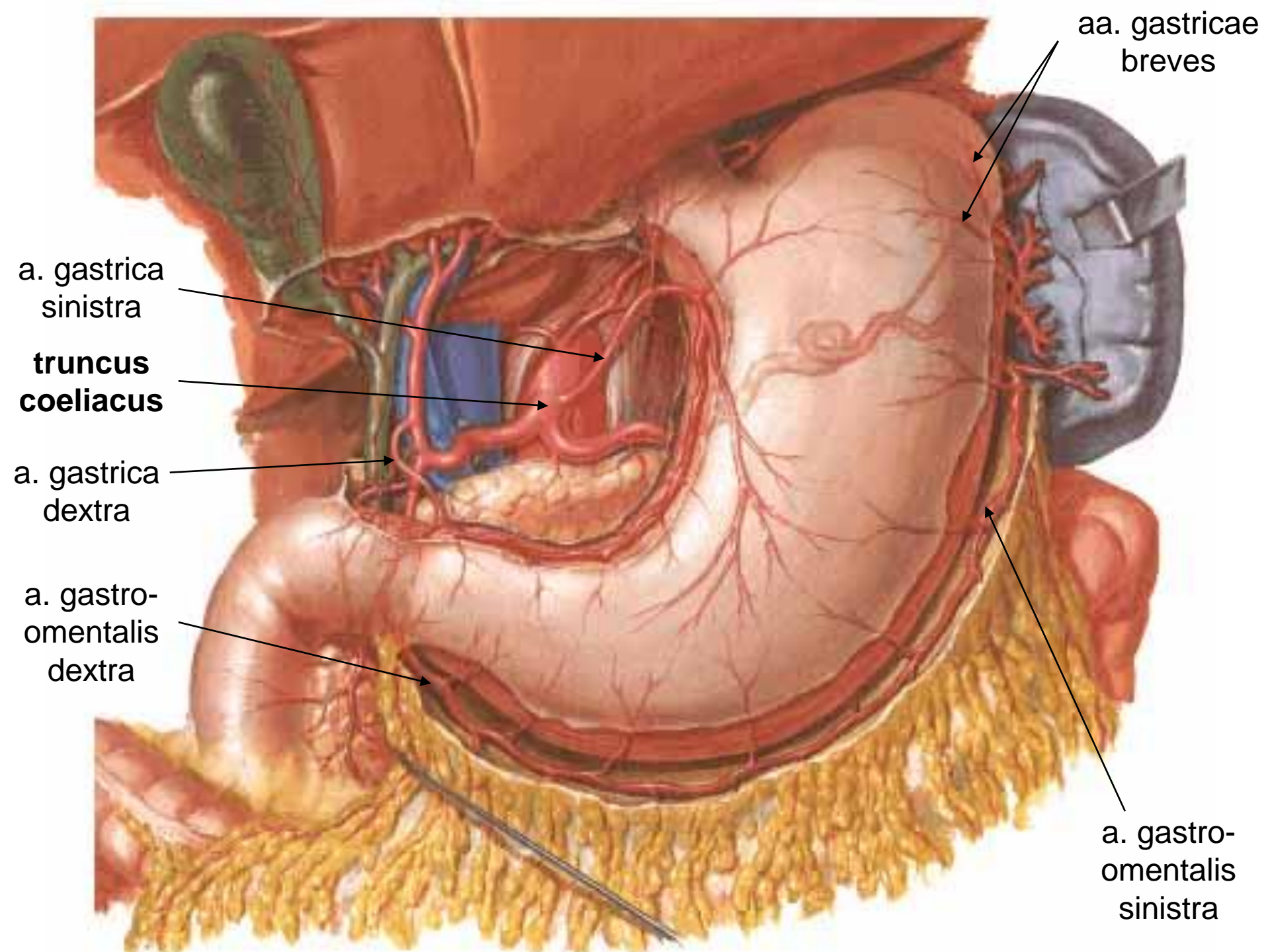
→ a. gastromentalis sin.

→ aa. gastricae breves (*fundus*)

→ a. gastrica posterior (80%)

arcus gastricus (curvatura minor)

arcus gastromentalis (curvatura major)



aa. gastricae
breves

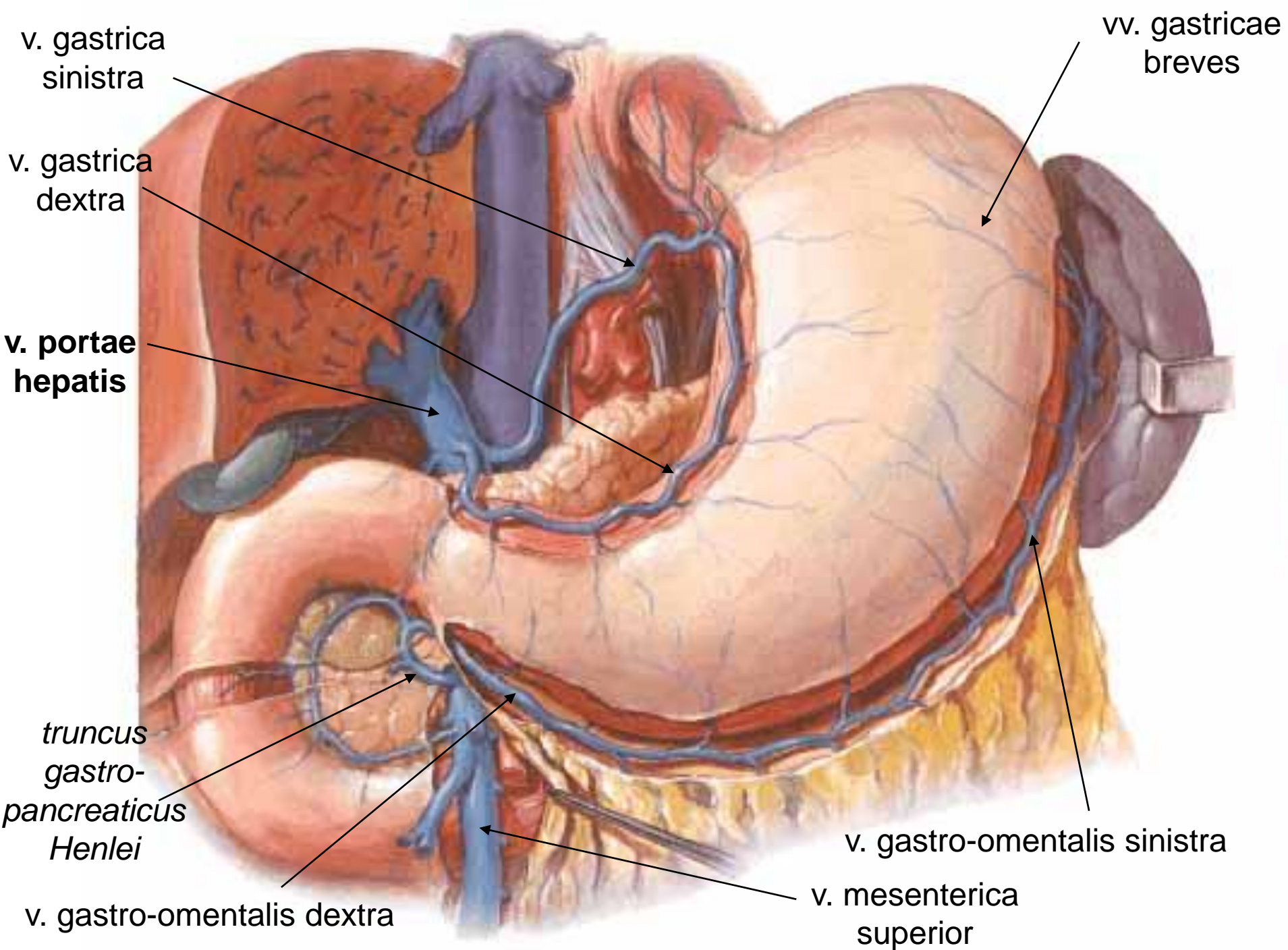
a. gastrica
sinistra

**truncus
coeliacus**

a. gastrica
dextra

a. gastro-
omentalis
dextra

a. gastro-
omentalis
sinistra



Duodenum

- **truncus coeliacus** → a. hepatica communis → a. gastroduodenalis → **a. pancreaticoduodenalis superior post. + superior ant. + aa. retroduodenales**
- **a. mesenterica superior** → **a. pancreaticoduodenalis inferior** → ramus ant. + r. post.

arcus pancreaticus anterior et posterior

Jejunum + ileum

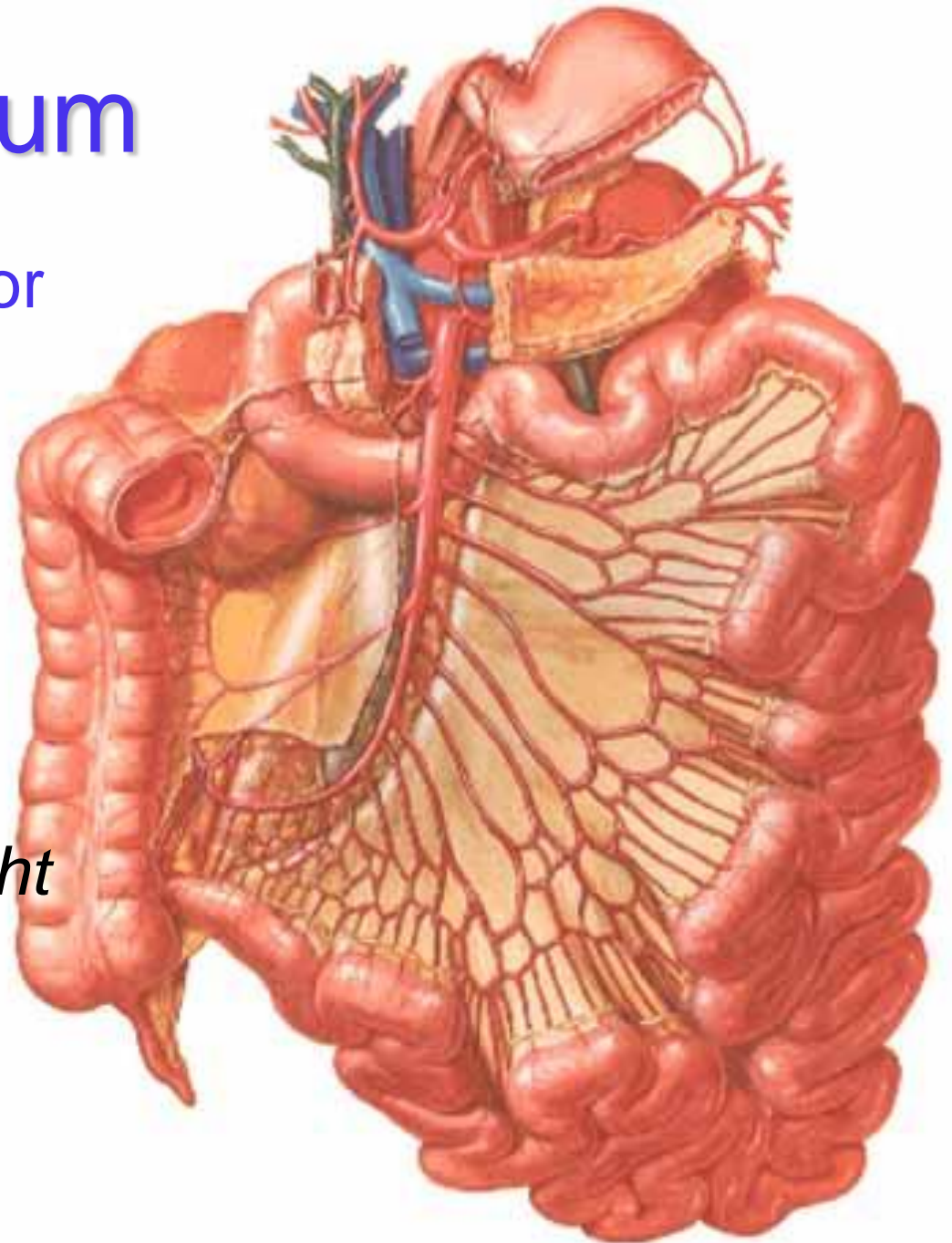
a. mesenterica superior

- aa. jejunales
- aa. ileales
- a. ileocolica

arcades

parallel artery of Dwight

→ arteriolarae rectae



Liver and gallbladder

truncus coeliacus → a. hepatica communis

→ a. hepatica propria → r. dx.+ sin.

(*porta hepatis*) → a. segmenti

r. dexter → a. cystica (*trigonum Caloti*)

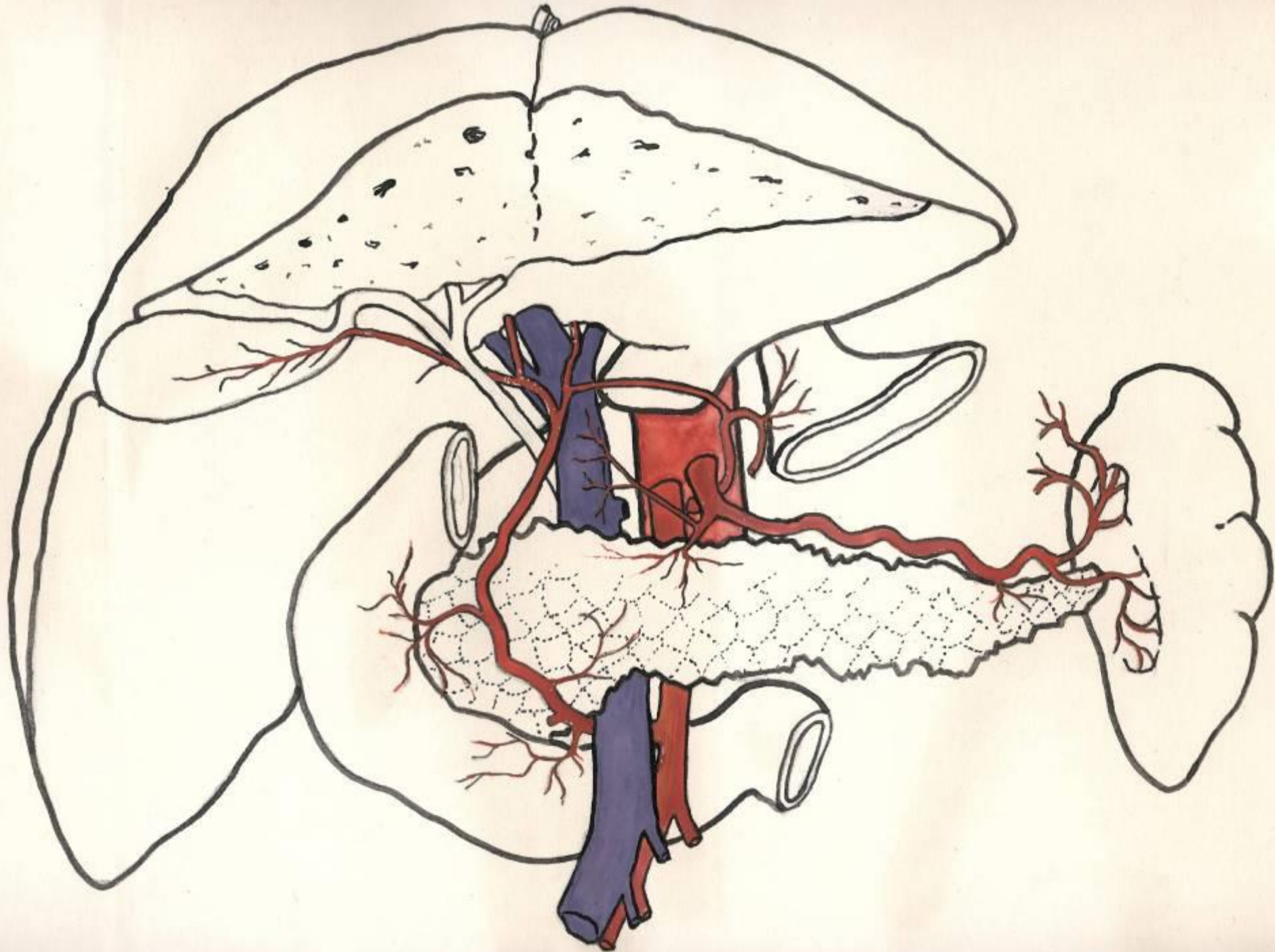
- r. hepaticus accessorius
 - branch from AMS
 - branch from AGS
- a. hepatica aberrans (2%)
 - branch from AMS

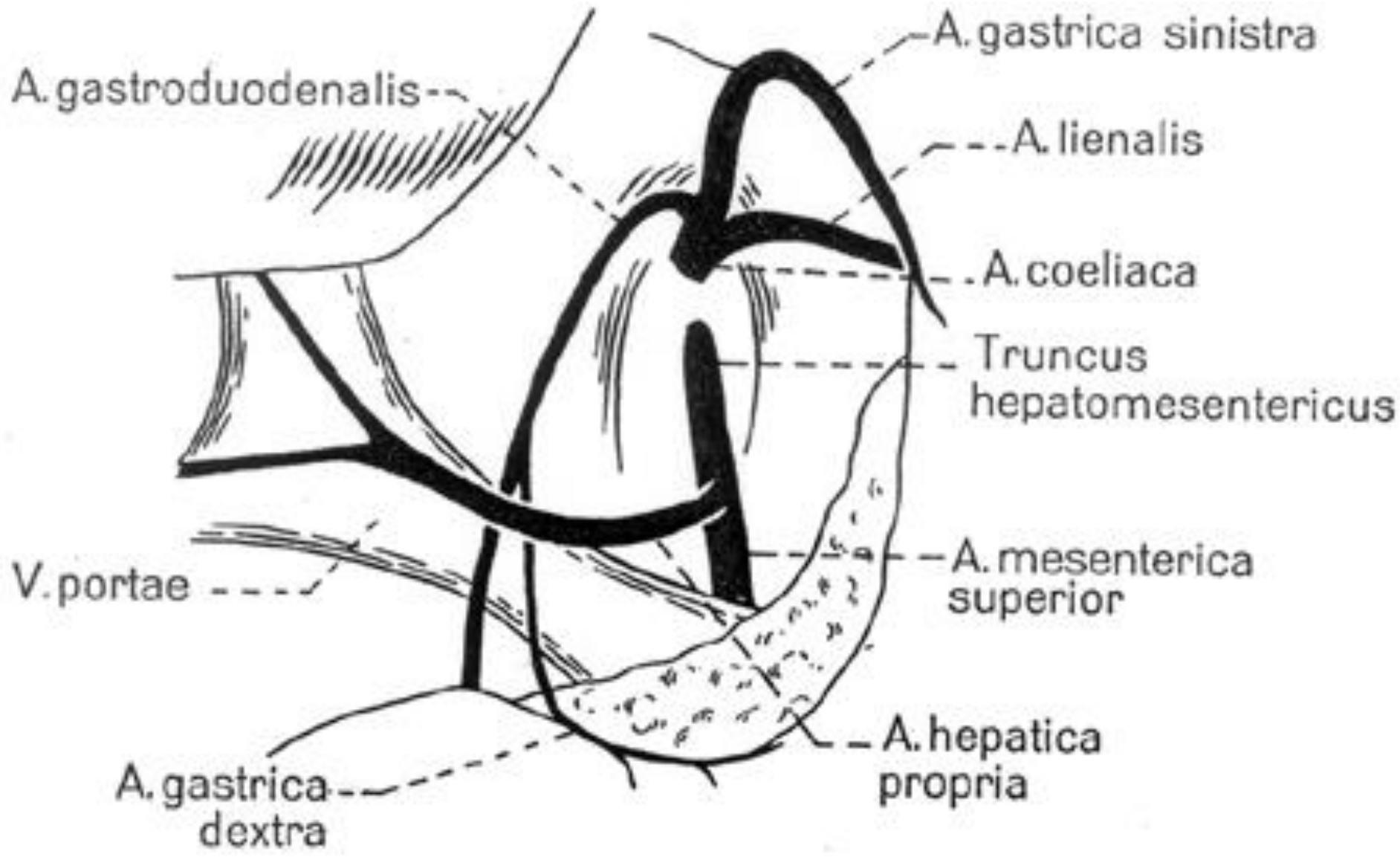
Arteria hepatica – variations

- normal anatomy – 75%

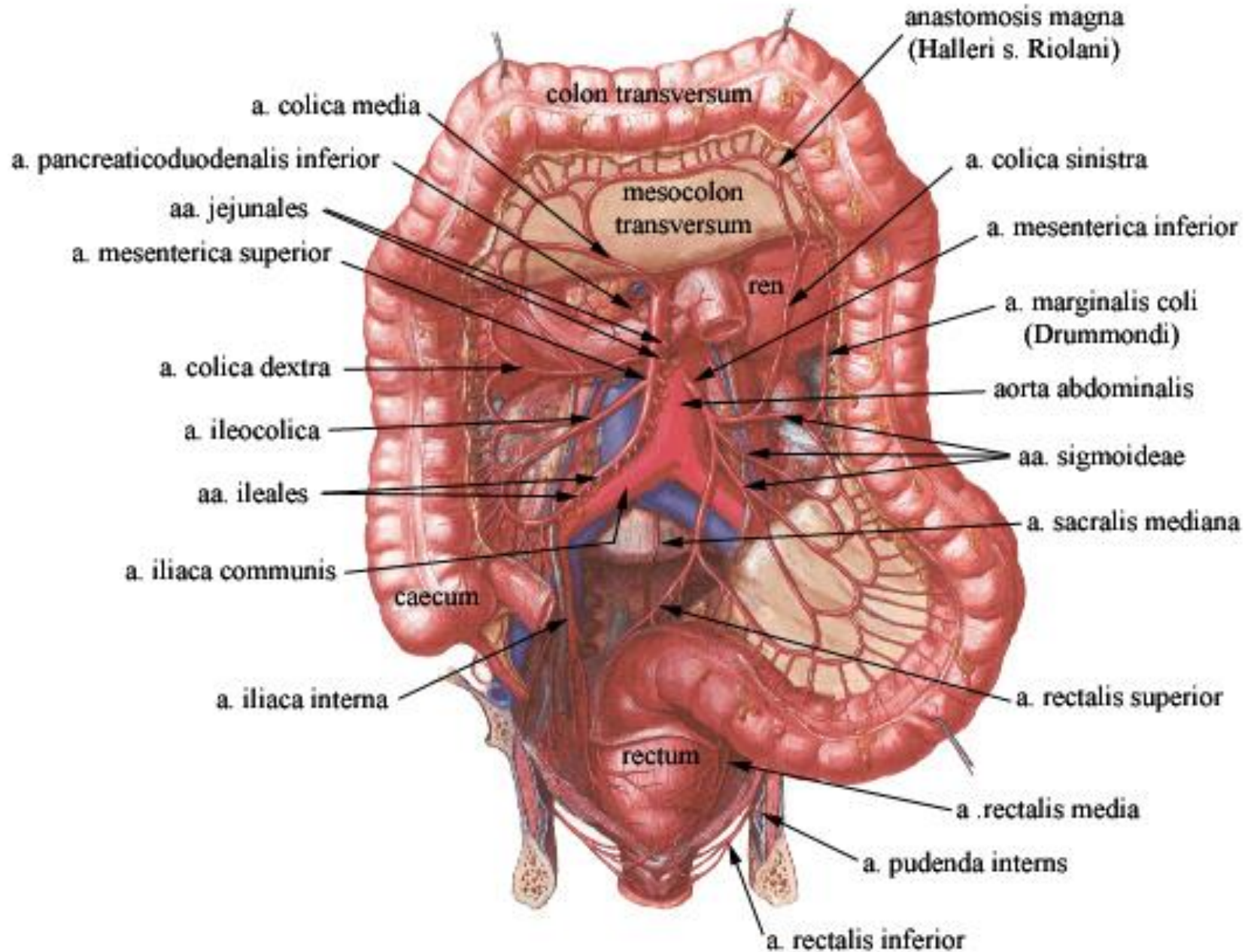
accessory x aberrant („replaced artery“)

- r. dx. accessorius / aberrans from AMS – 10%
- r. sin. accessorius / aberrans from AGS – 10%
- separate r. dx+sin. aberrans from AGS – 2%
- total AHC aberrans from AMS – 2%
- total AHC directly from TC – 1%



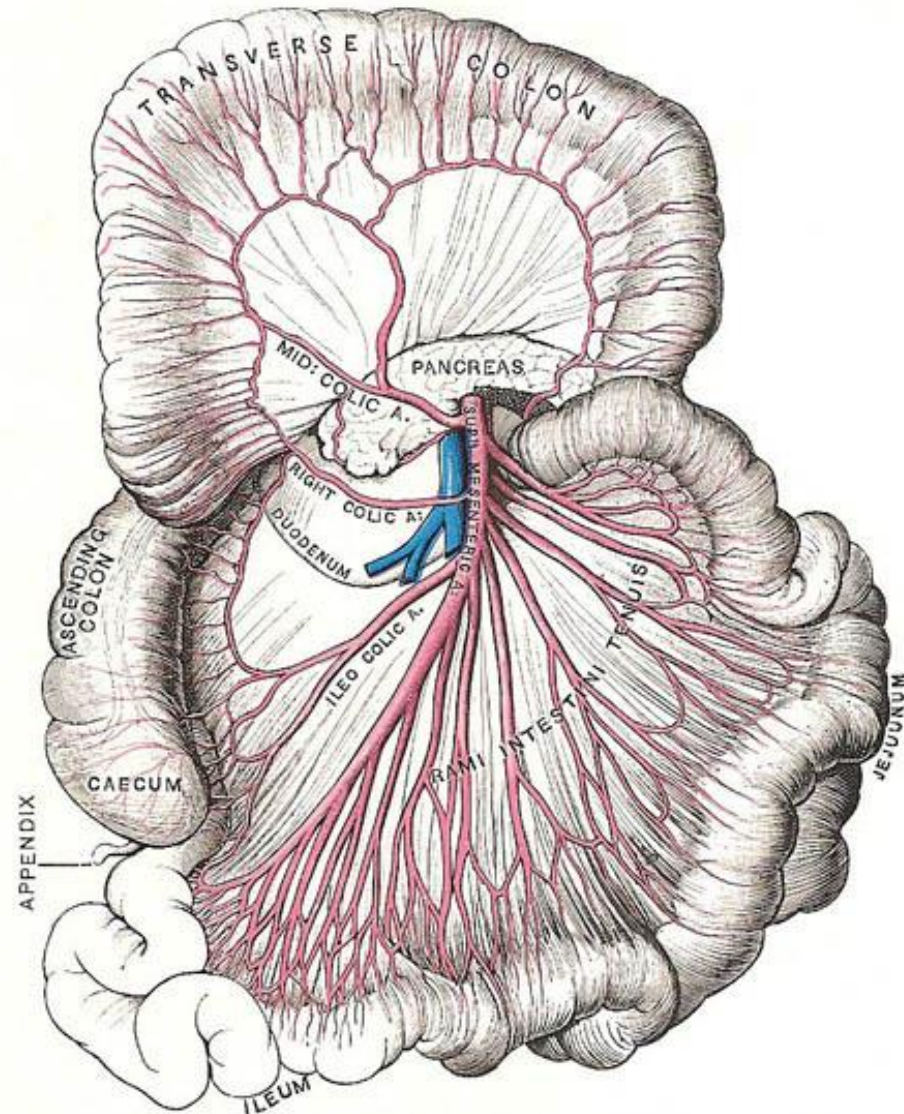


ARTERIAE MESENTERICAE

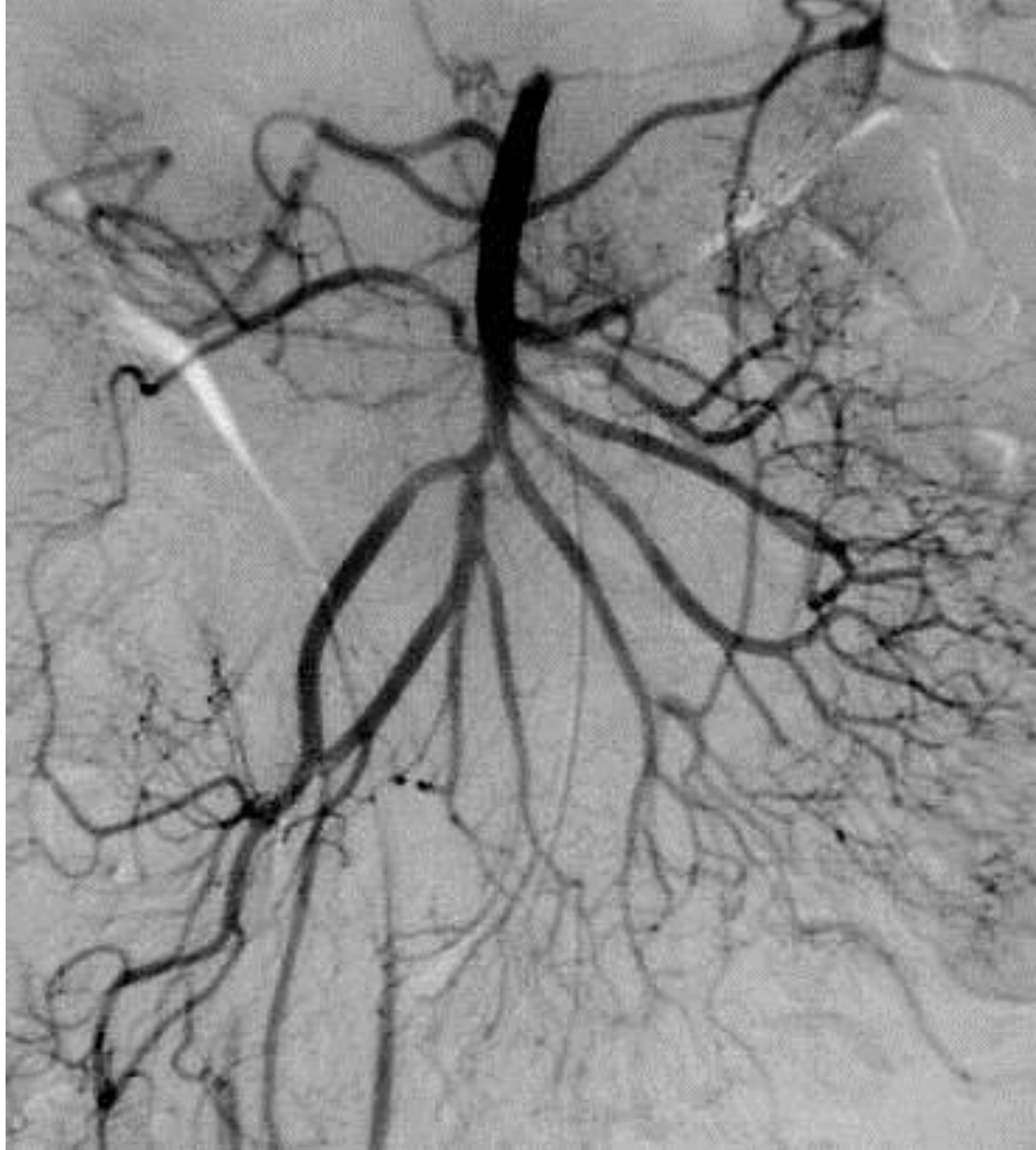


Arteria mesenterica superior

- L1, 1 cm below TC
ventrally: collum pancreatis
dorsally: aorta, v. renalis
sin., processus uncinatus,
pars inferior duodeni, oral
part of jejunum
- *abdominal angina = pain*
- *AMS syndrome =
compression of pars
inferior duodeni*
- *AMS closure → 80%
mortality*

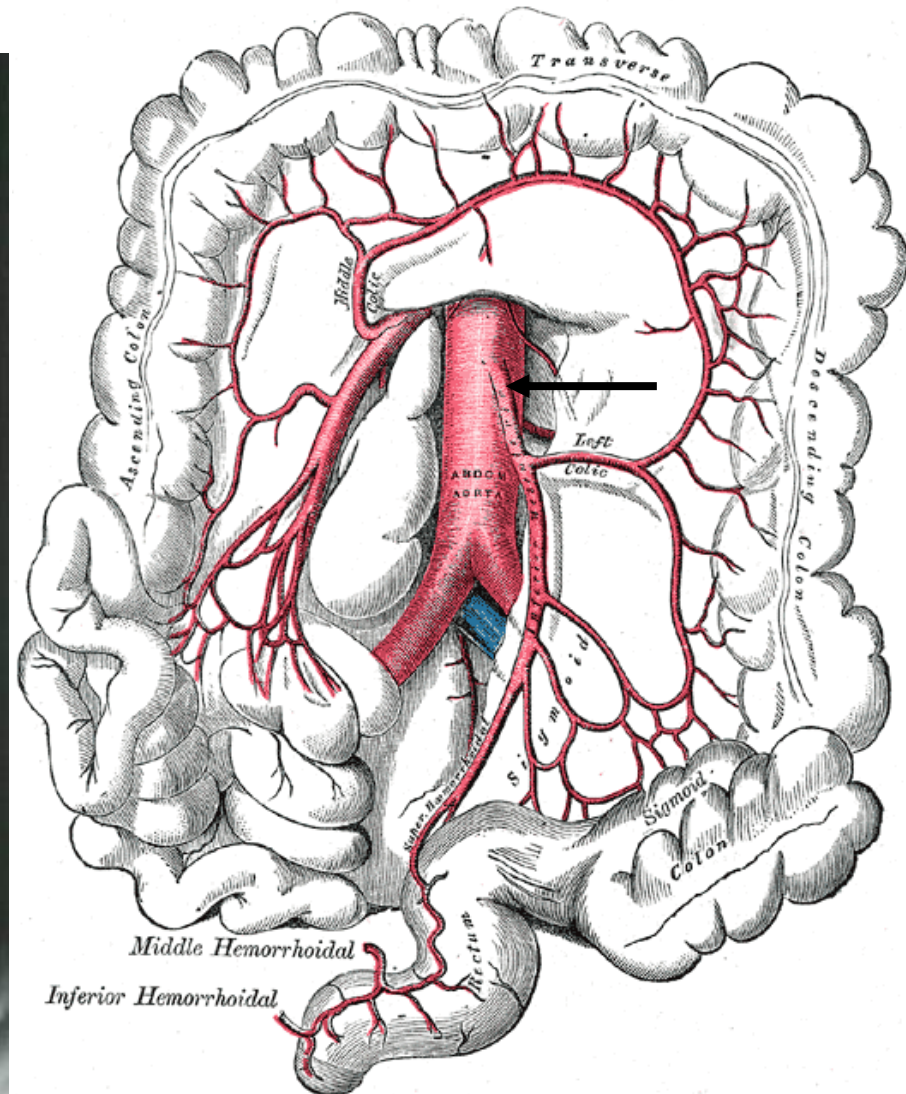
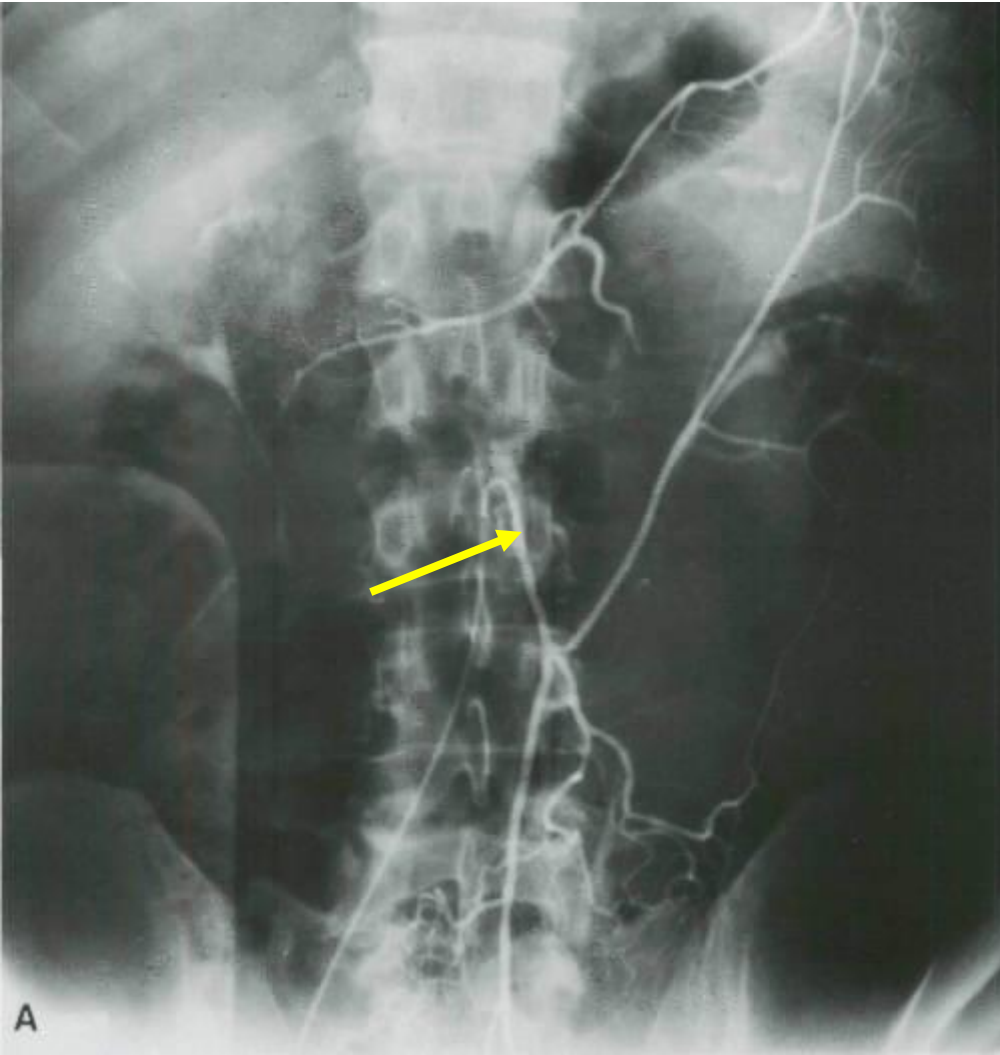


Arteriogram
of
arteria
mesenterica
superior



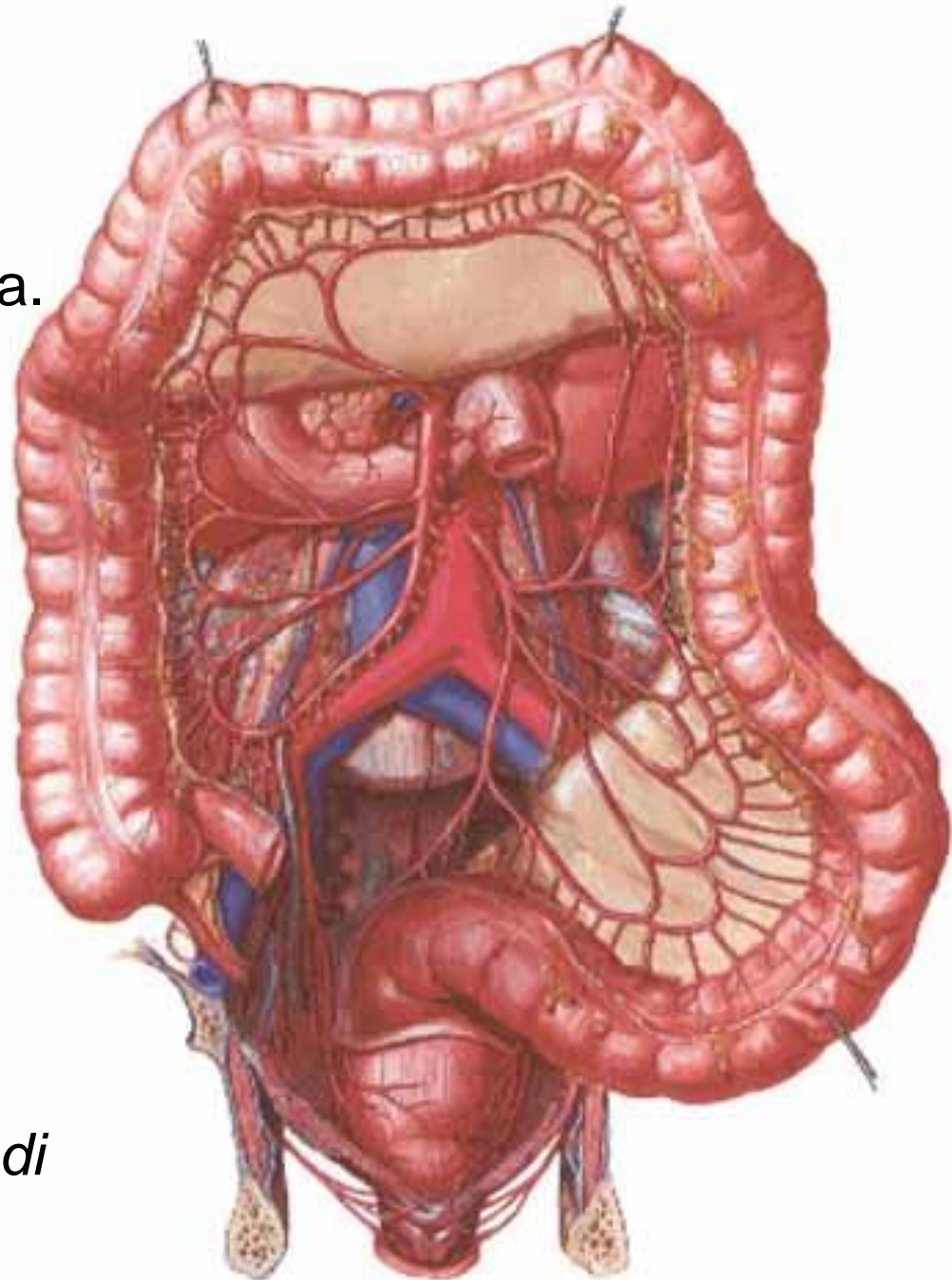
Arteria mesenterica inferior

- L3



Large intestine

- **a. mesenterica sup.**
 - a. ileocolica → r. colicus, a. caecalis ant. + post., a. appendicularis
 - a. colica dx. (*colon ascendens*)
 - a. colica media (*colon transversum*)
- **a. mesenterica inf.**
 - a. colica sin. (*colon descendens*)
 - aa. sigmoideae (3-4)
 - a. rectalis sup. (*rectum*)

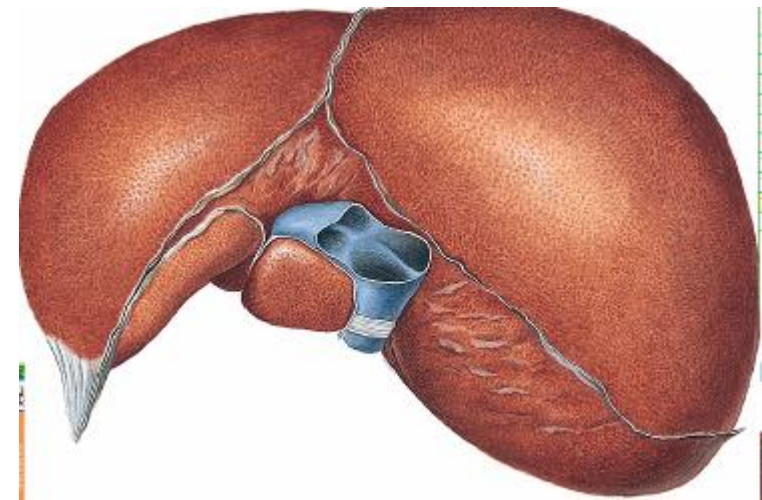
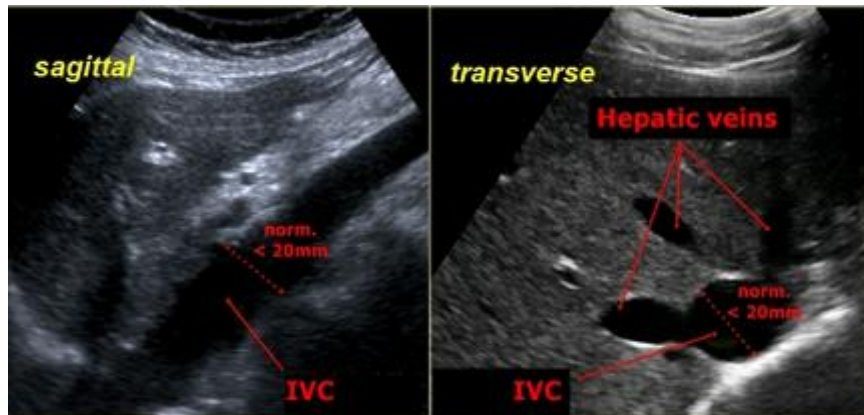


arteria marginalis coli *Drummondii*

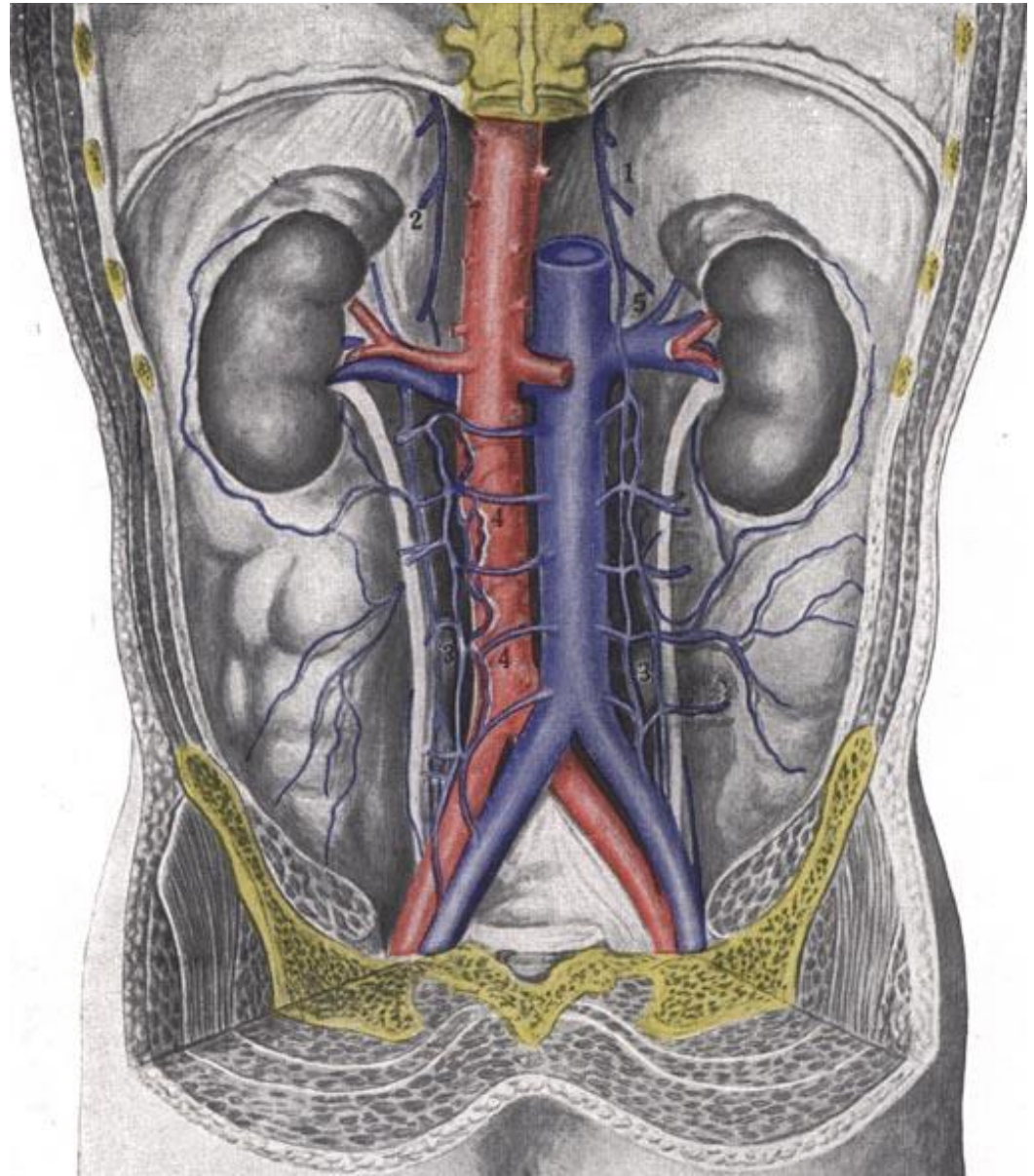
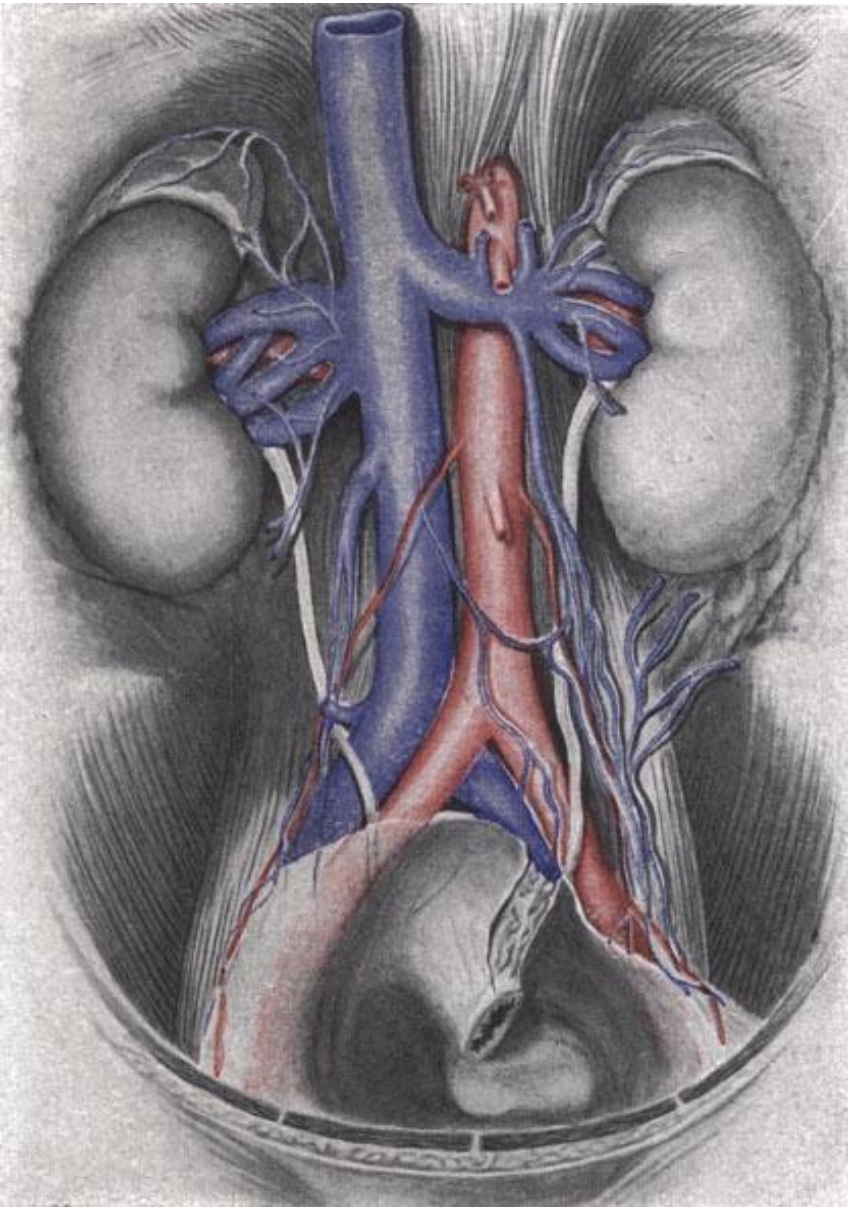
anastomosis magna *Halleri* =
arcus Riolani

Vena cava inferior

- origin: confluence of vv. iliacaе communes (L4)
- right to aorta abdominalis, within retroperitoneum
- no valves, rarely doubled parts
- sulcus venae cavae hepatis
- foramen venae cavae diaphragmatis
- caliber: 2 cm below liver, 3,5 cm above liver
- end: atrium dextrum (T8)



Vena cava inferior

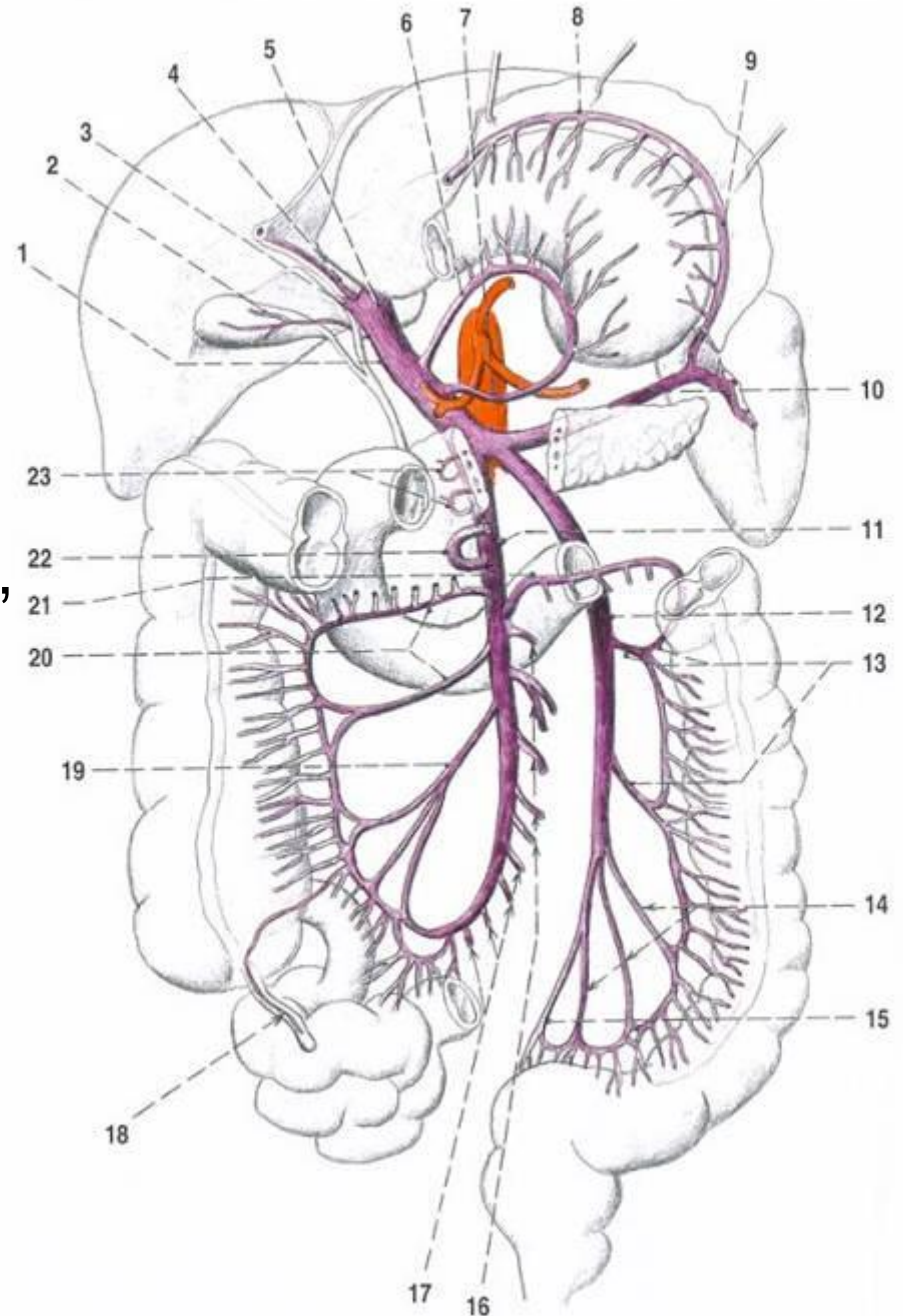


Vena cava inferior – tributaries

- variable arrangement
- parietal:
 - vv. iliacae communes, vv. lumbales I-IV (*propojeny přes v. lumbalis ascendens*), vv. phrenicae inf., v. sacralis mediana
- visceral:
 - vv. renales
 - v. testicularis ♂ / ovarica dx. ♀ (originating as plexus pampiniformis)
 - v. suprarenalis dx.
 - vv. hepaticae: dextra, intermedia, sinistra (ductus venosus *Aranzii*)

Vena portae hepatis (Hepatic portal vein)

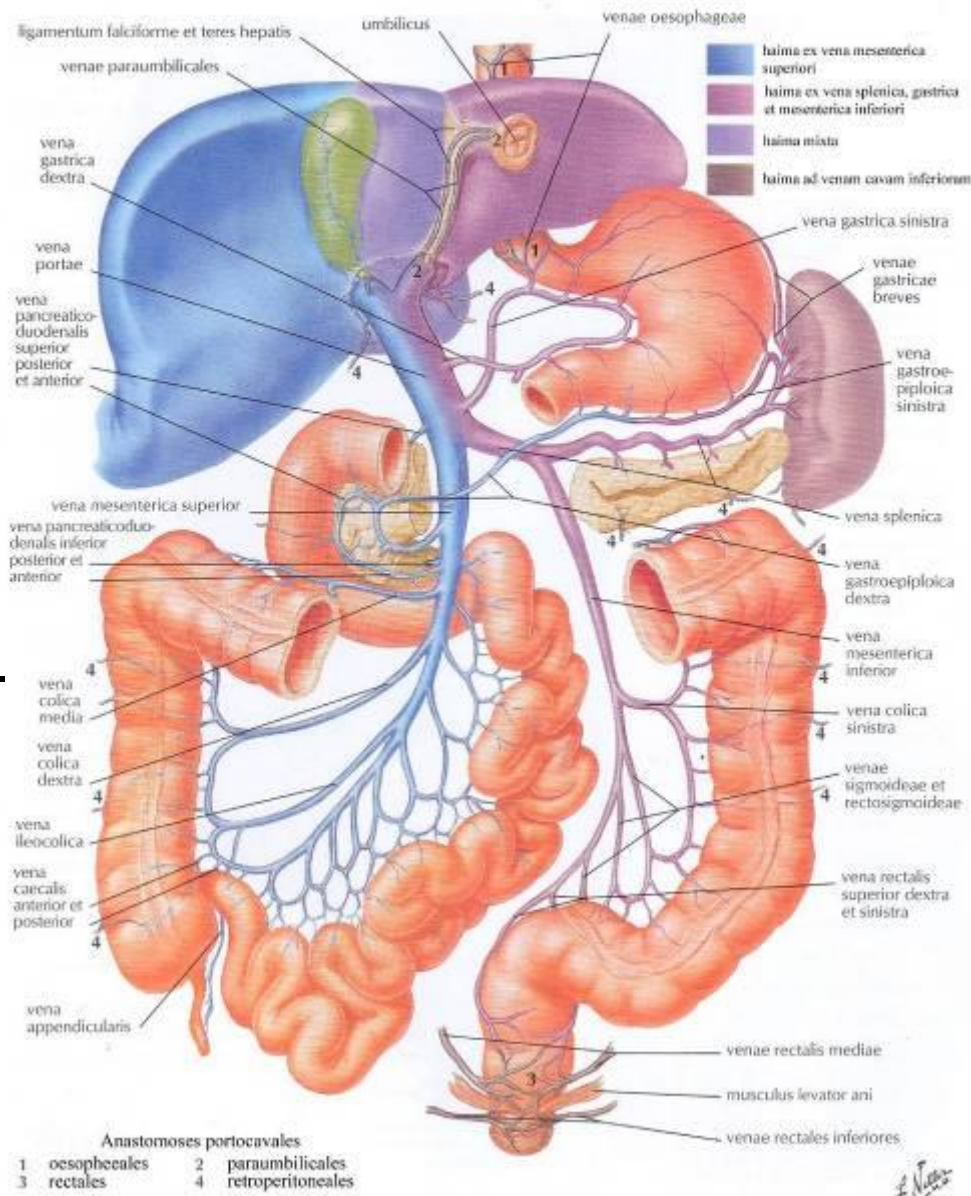
- collects blood from unpaired abdominal organs
- no valves
- origin: confluence of v. splenica + v. mesenterica sup., behind caput pancreatis
- v. mesenterica inf. drains in 50% into the VS, in 40% into the VMS and in 10% into the confluence
- end: v. portae bifurcates into r. dx. + sin. and further to the liver segments branches
- portocaval anastomoses: 7

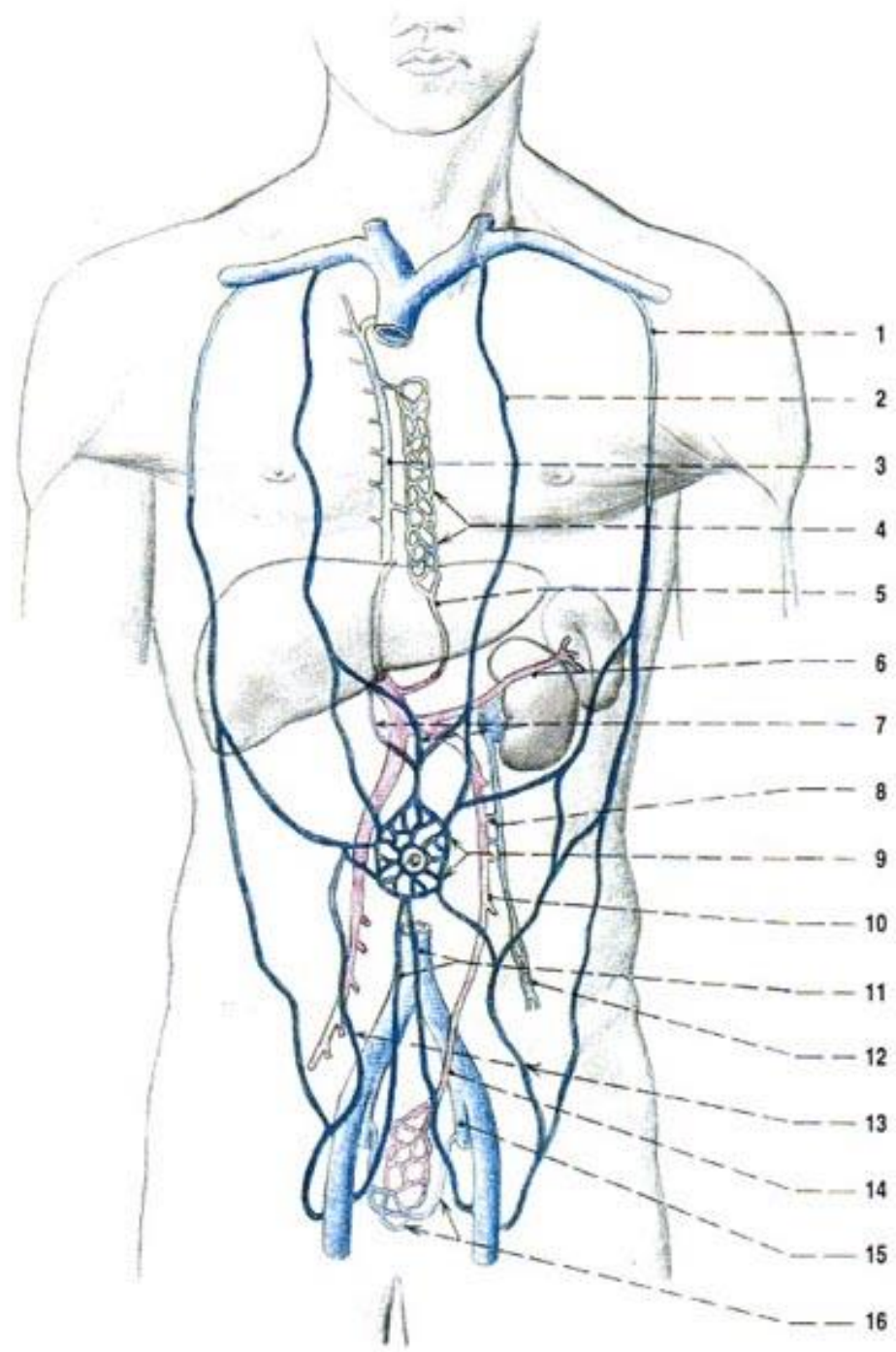
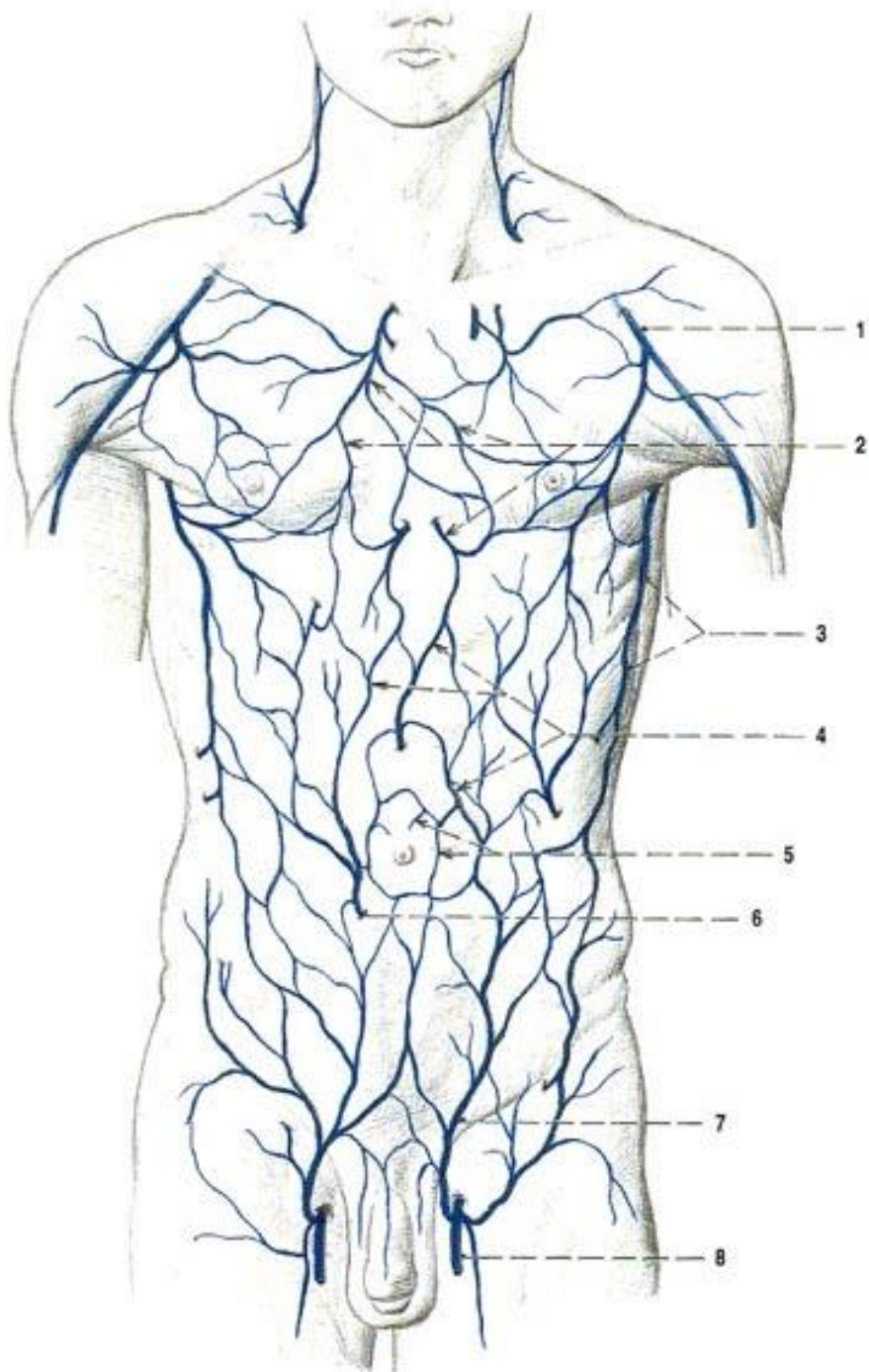


Portocaval anastomoses

VENA PORTAE et ANASTOMOSES PORTOCAVALES

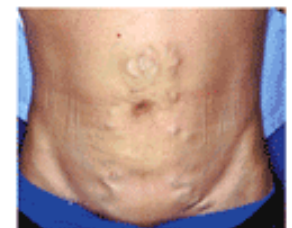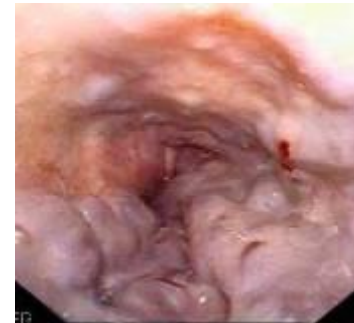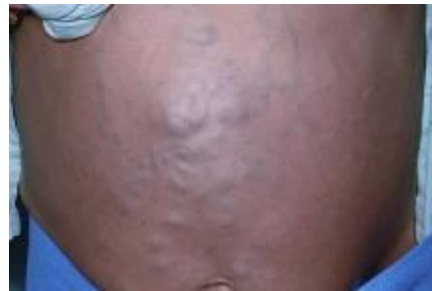- vv. gastricae – vv. oesophageae (*oesophageal varices*) – *within tunica submucosa*
- vv. gastricae – vv. paraoesophageae – *within tunica adventitia*
- plexus venosus rectalis
- vv. paraumbilicales – subcutaneous veins around umbilicus (*caput Medusae*) and:
 - v. epigastrica sup. + inf.
 - v. epigastrica superficialis + vv. thoracoepigastricae
- vv. paraumbilicales – plexus venosus vesicalis (*Burow's veins*)
- subcapsular veins of liver – veins of diaphragm
- retroperitoneal veins (*Retzius' vein*)
- recanalized ductus venosus





Portocaval anastomoses – clinical notes

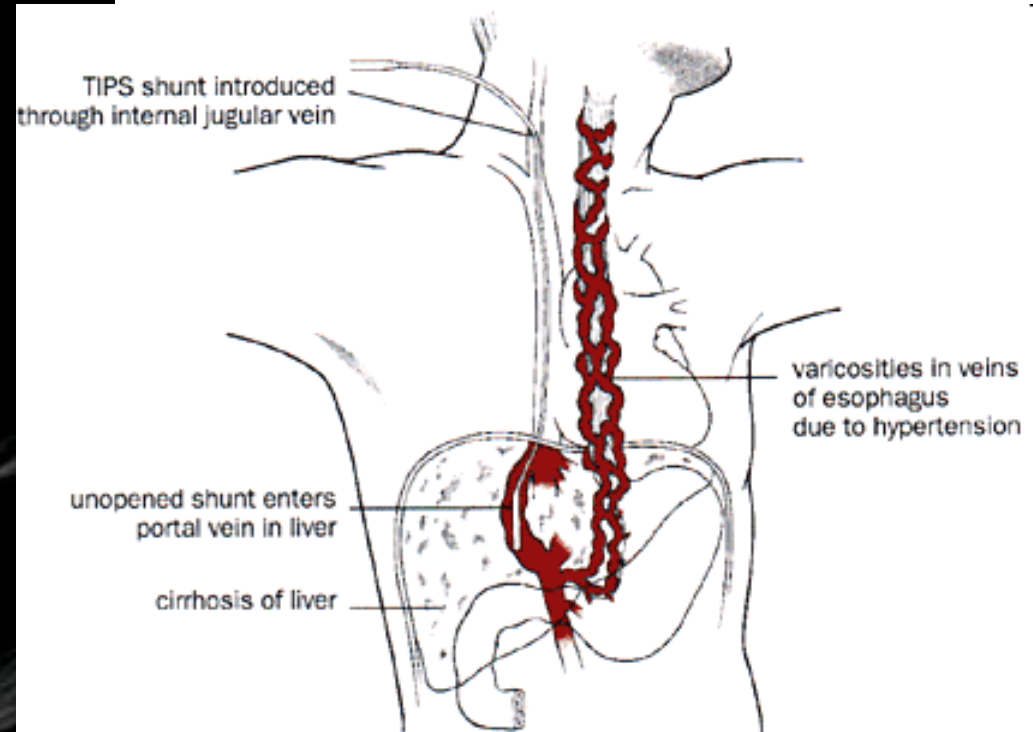
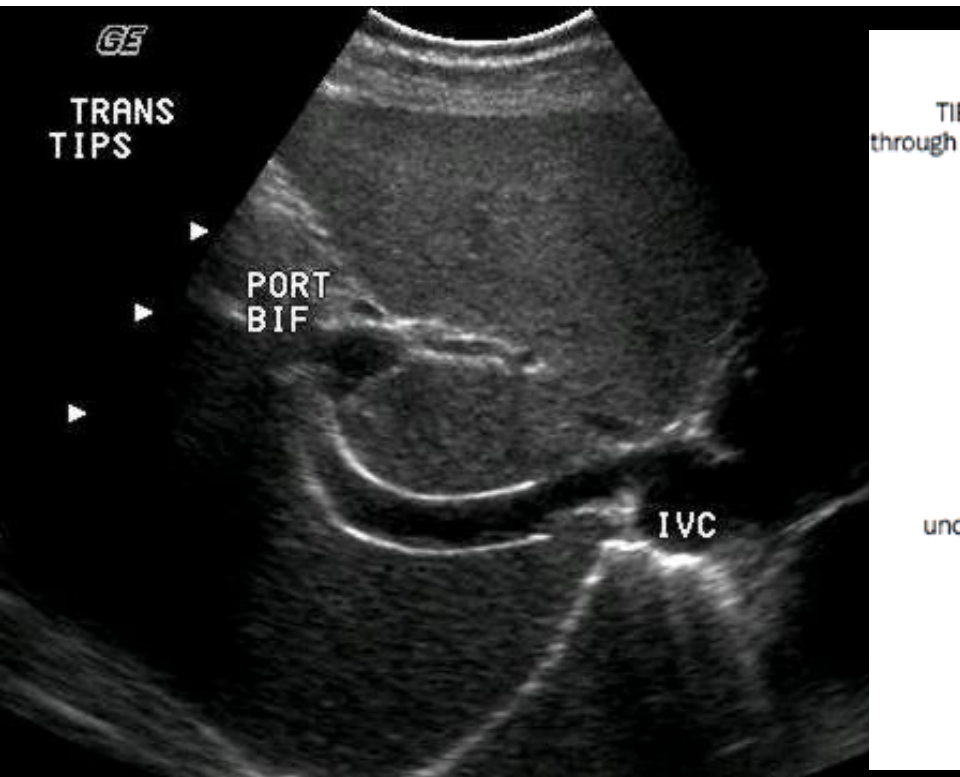
- portal hypertension (prehepatic – thrombosis; hepatic – cirrhosis; posthepatic – thrombosis)
- collateral circulation
- oesophageal varices – bleeding
- caput Medusae – rare (children at umbilicus, adult at flanks)
- hemorrhoids
- ascites
- splenomegaly
- hepatic encephalopathy (ammonia in the CNS)



Portocaval anastomoses – treatment

- TIPS

= transjugular intrahepatic portosystemic shunt



Cavocaval anastomoses

VCI

VCS

- vv. lumbales – v. azygos + hemiazygos
- v. epigastrica inf. – v. epigastrica sup.
- v. epigastrica spf. – vv. thoracoepigastricae
- plexus venosi vertebrales (of *Batson*)

