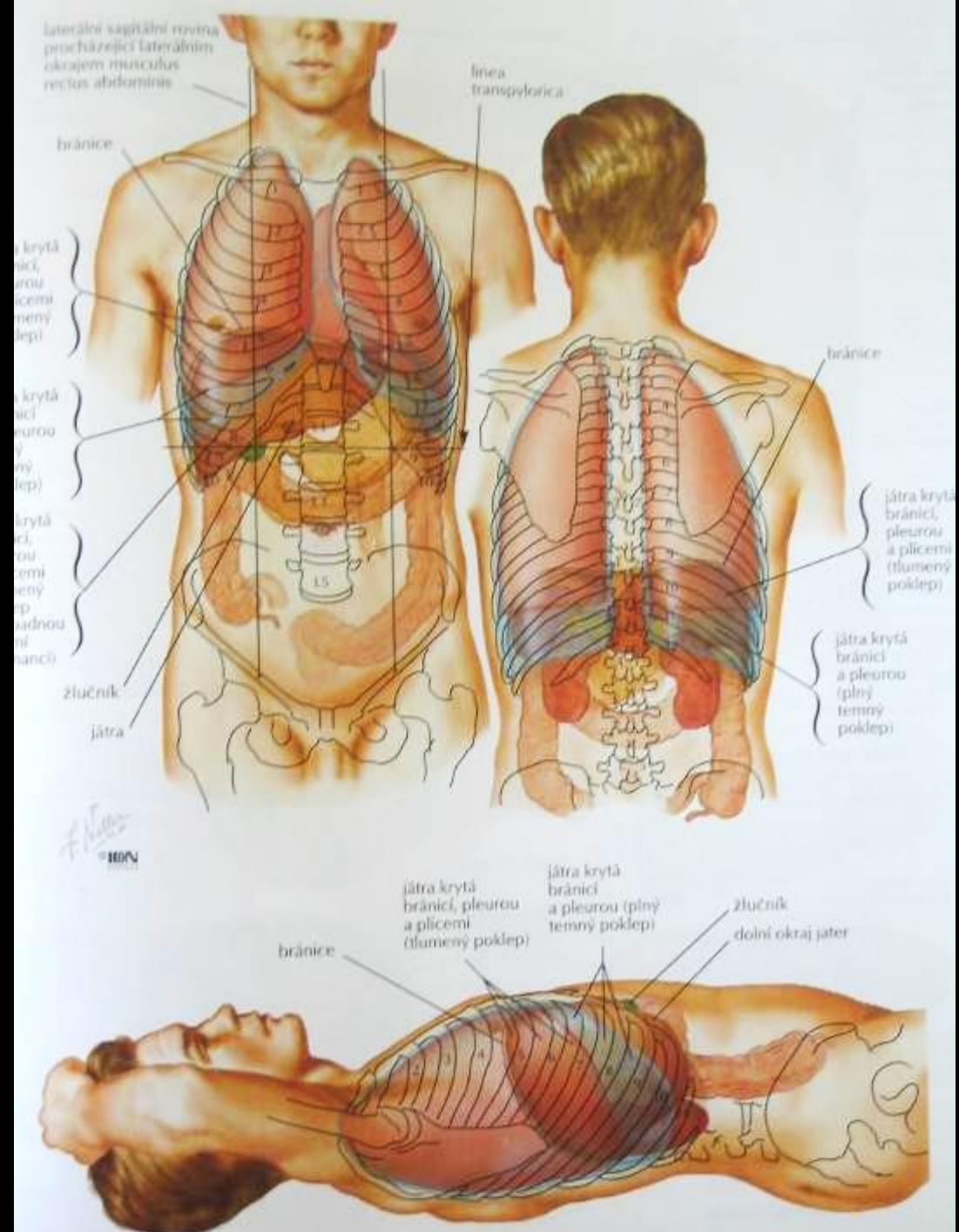


Játra (iecur, hepar)

Lokalizace

regio
hypochondriaca
dextra

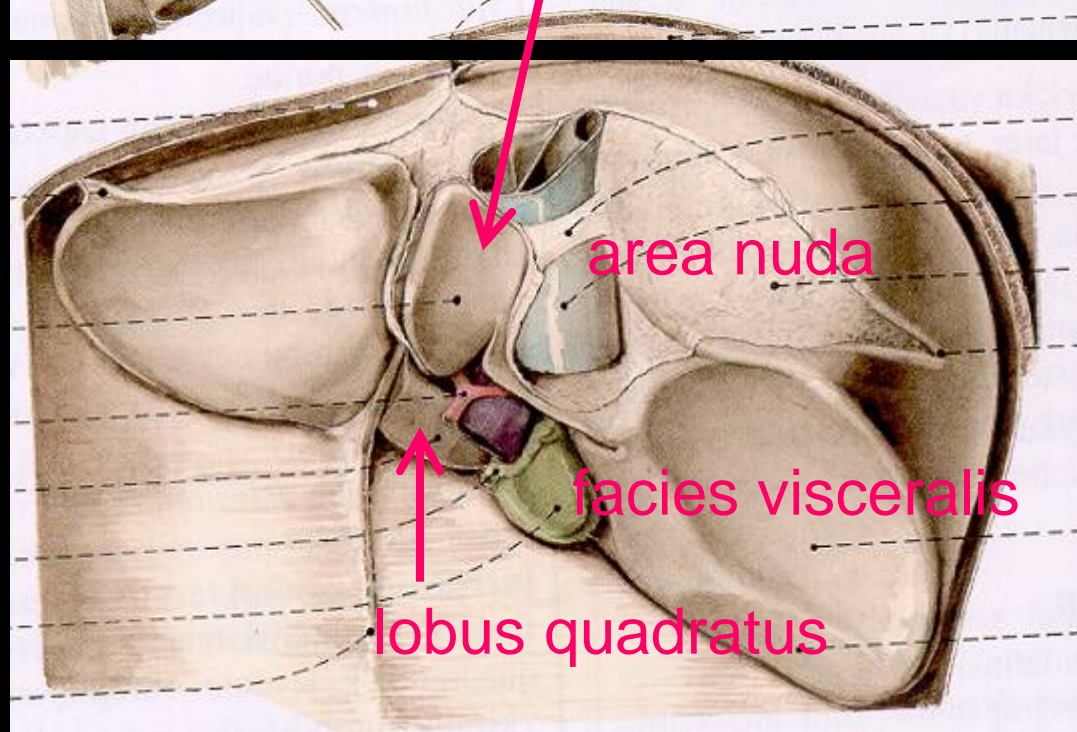
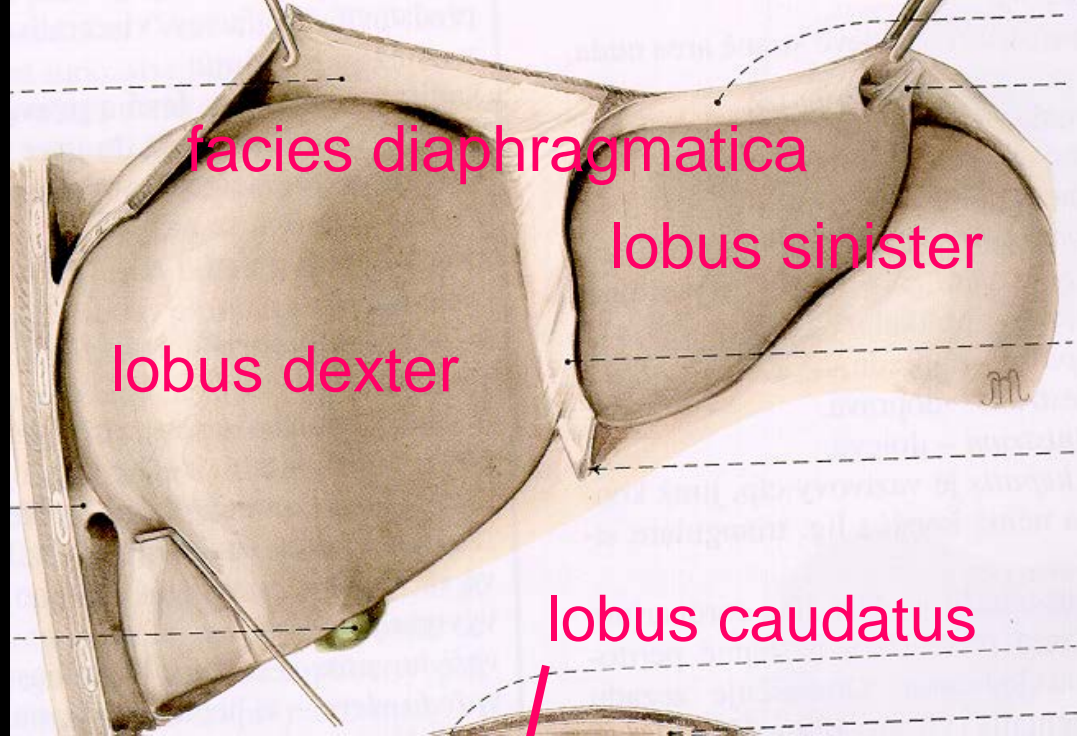
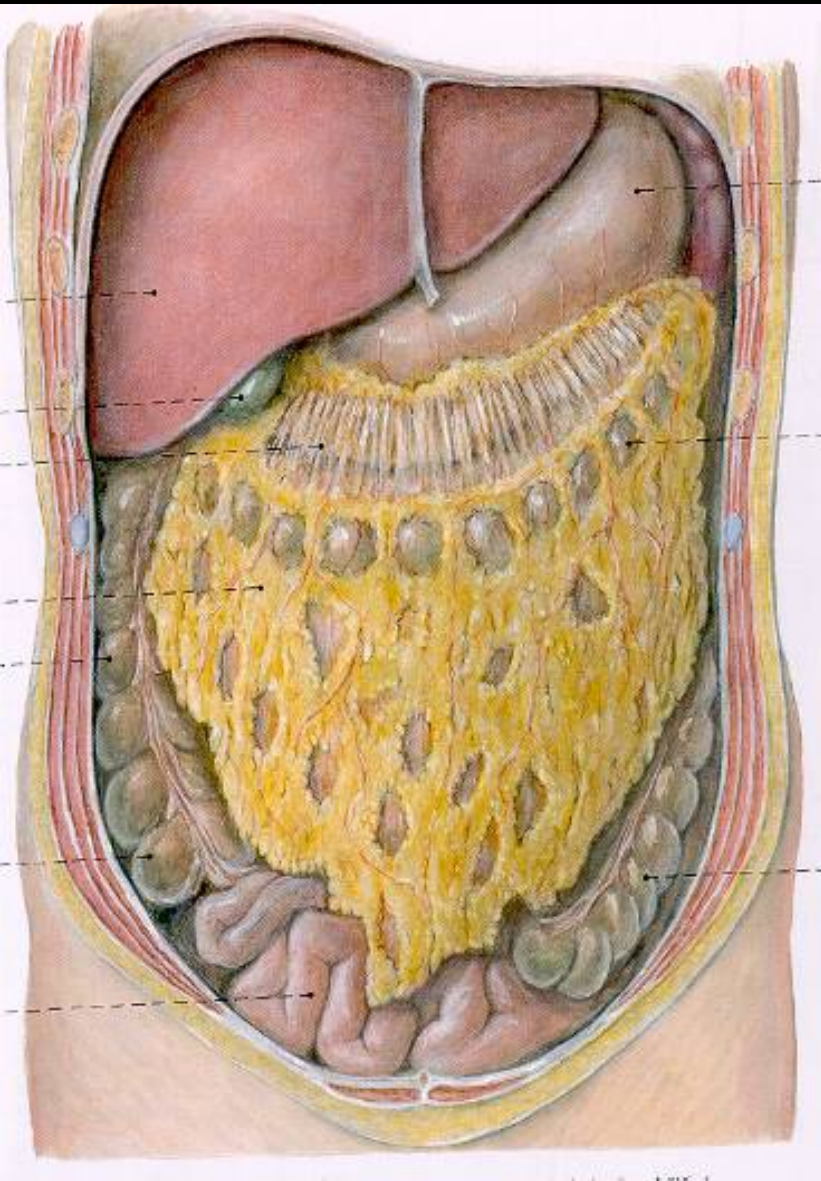


Játra – popis a dělení

- facies diaphragmatica
 - area nuda, impressio cardiaca
- facies visceralis – otisky 6 orgánů
 - žaludek, jícen, ledvina, nadledvina, dvanáctník, pravé tračnickové ohbí
- margo inferior – obvykle nehmatný

dělení:

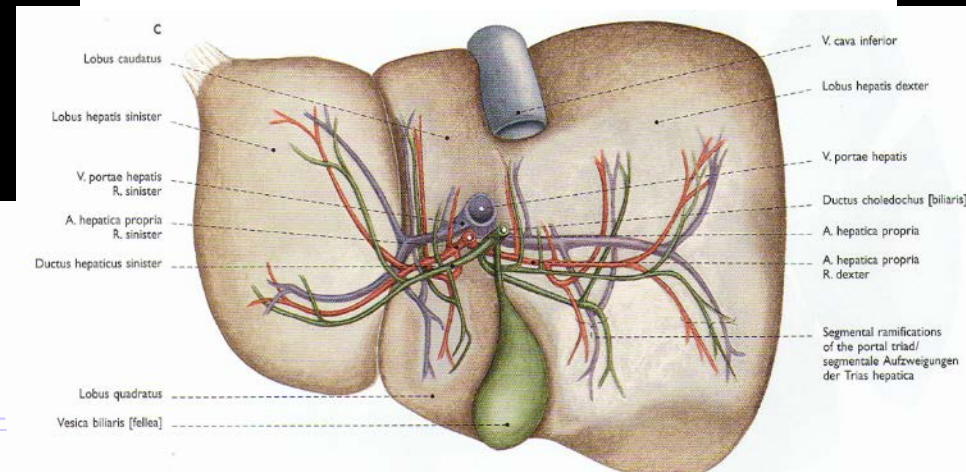
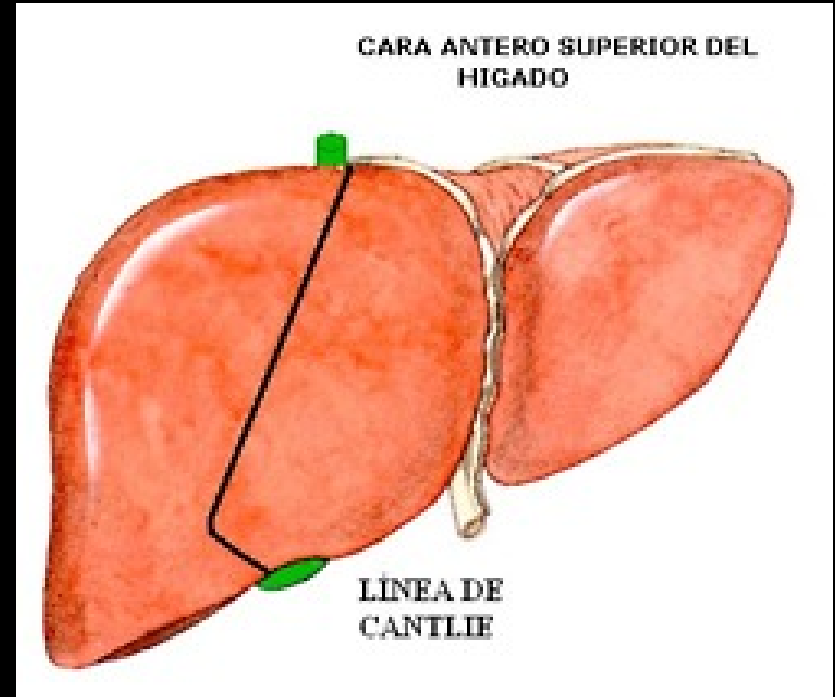
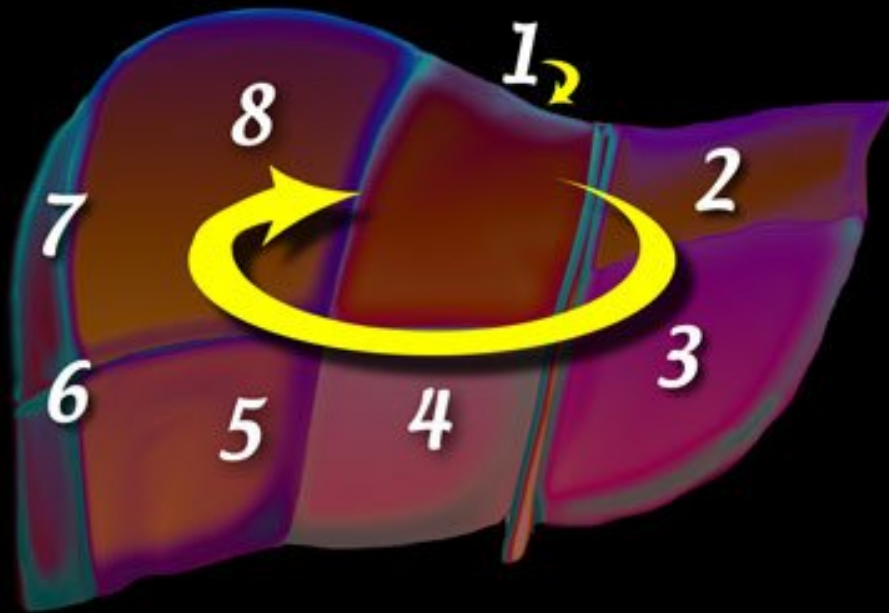
- 4 laloky popisné
 - lobus dx., sin., caudatus, quadratus
- 8 segmentů dle cév



Játra – Segmenty (Dílce)

- segment má ve středu svoji tepnu, žílu (větev z v. portae) a žlučovod
- mezi segmenty jsou vv. hepaticae
- rovina podél v. hepatica media dělí játra na pravý a levý (klinický) lalok
 - na povrchu jako Rexova-Cantlieho čára (spojnice středu fossa vesicae biliaris – v. cava inf.)
- v. hepatica dx. dělí pravý (klinický) lalok na přední (V+VI) a zadní segmenty (VII+VIII)
- v. hepatica sin. dělí levý (klinický) lalok na laterální (II+III) a mediální (IV) segment
- *podle hodinových ručiček*

Játra – Segmenty (Dílce)



Části jater (Claude Couinaud 1957)

Dílec (Segmentum)

Pars hepatis sinistra

Divisio lateralis sinistra

Segmentum posterius laterale sinistrum

II

Segmentum anterius laterale sinistrum

III

Divisio medialis sinistra

Segmentum mediale sinistrum

IV

Pars posterior hepatis; Lobus caudatus

Segmentum posterius; Lobus caudatus Spigeli

I

Pars hepatis dextra

Divisio medialis dextra

Segmentum anterius mediale dextrum

V

Segmentum posterius mediale dextrum

VIII

Divisio lateralis dextra

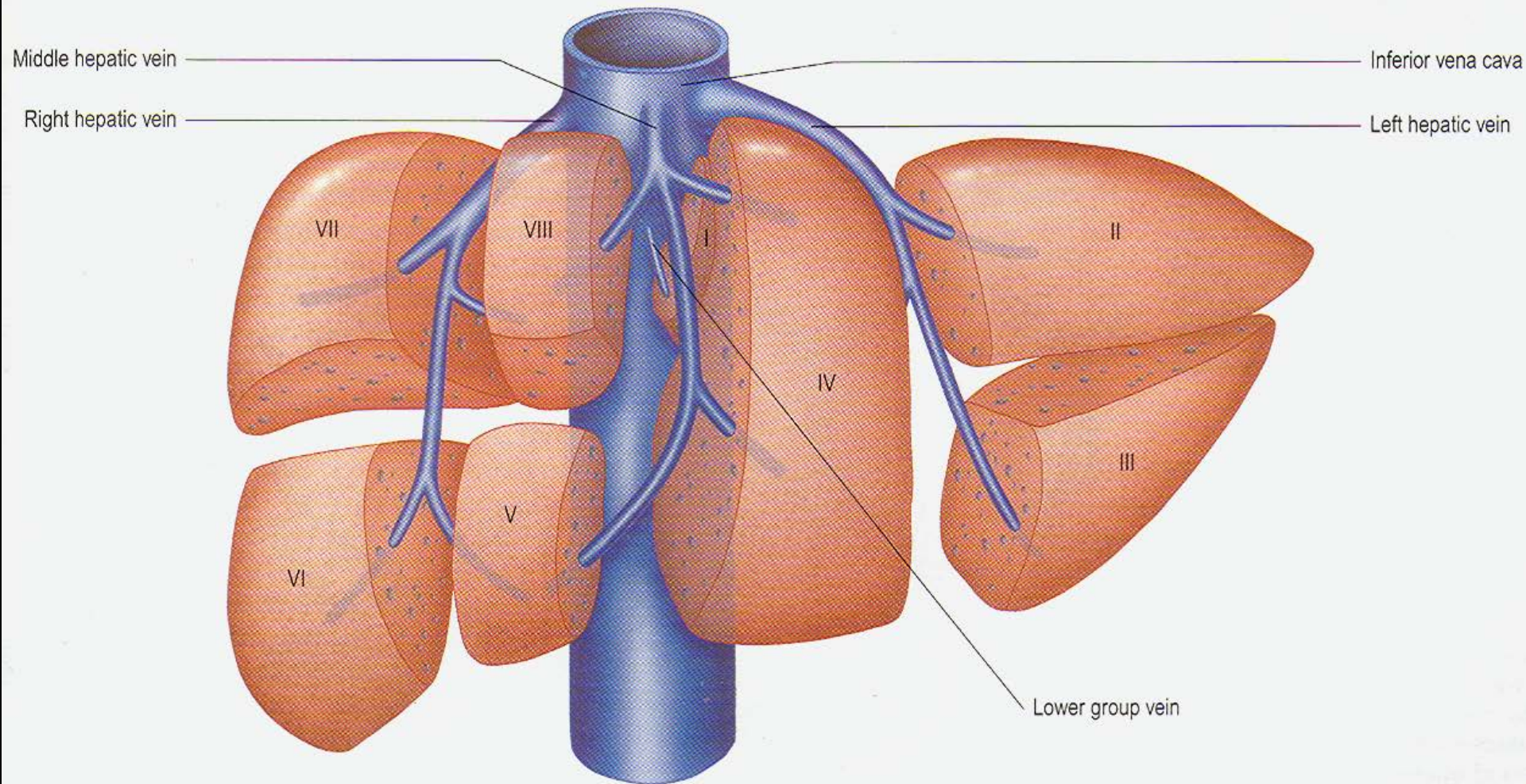
Segmentum anterius laterale dextrum

VI

Segmentum posterius laterale dextrum

VII

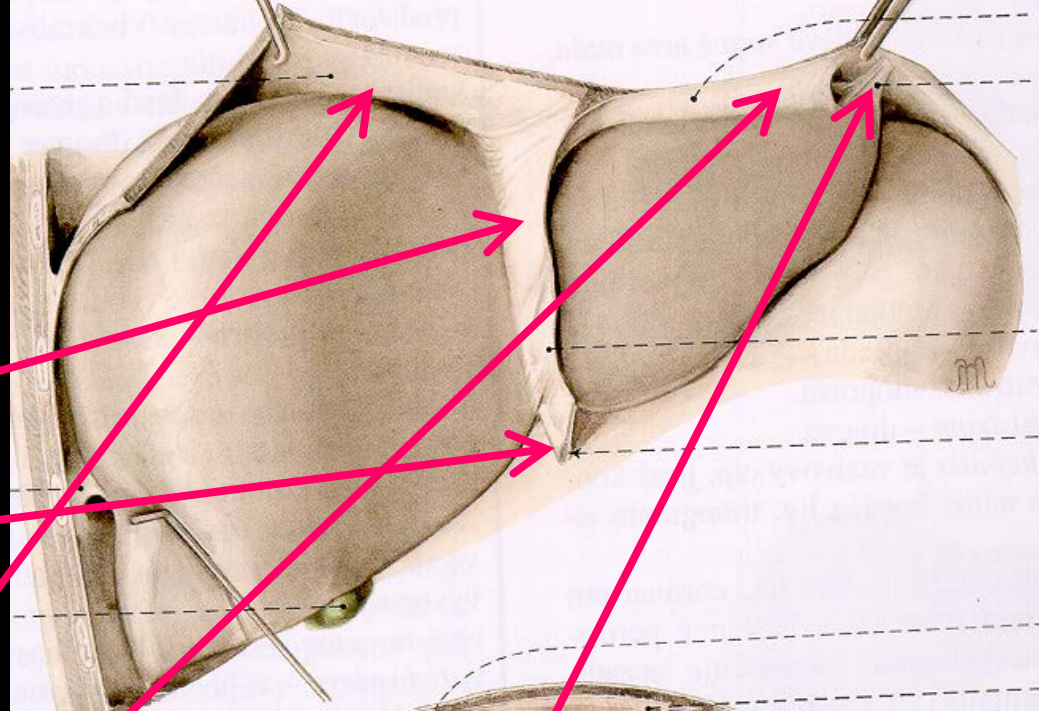
Játra – Segmenty (Dílce)



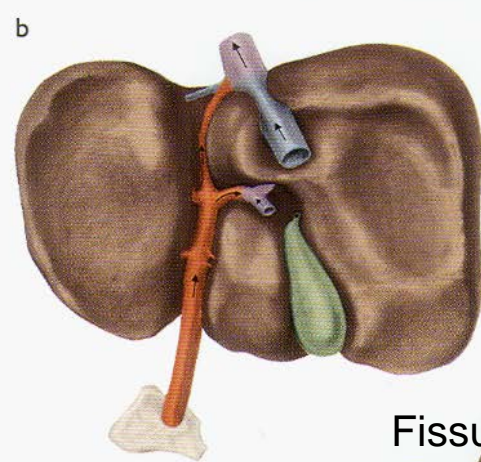
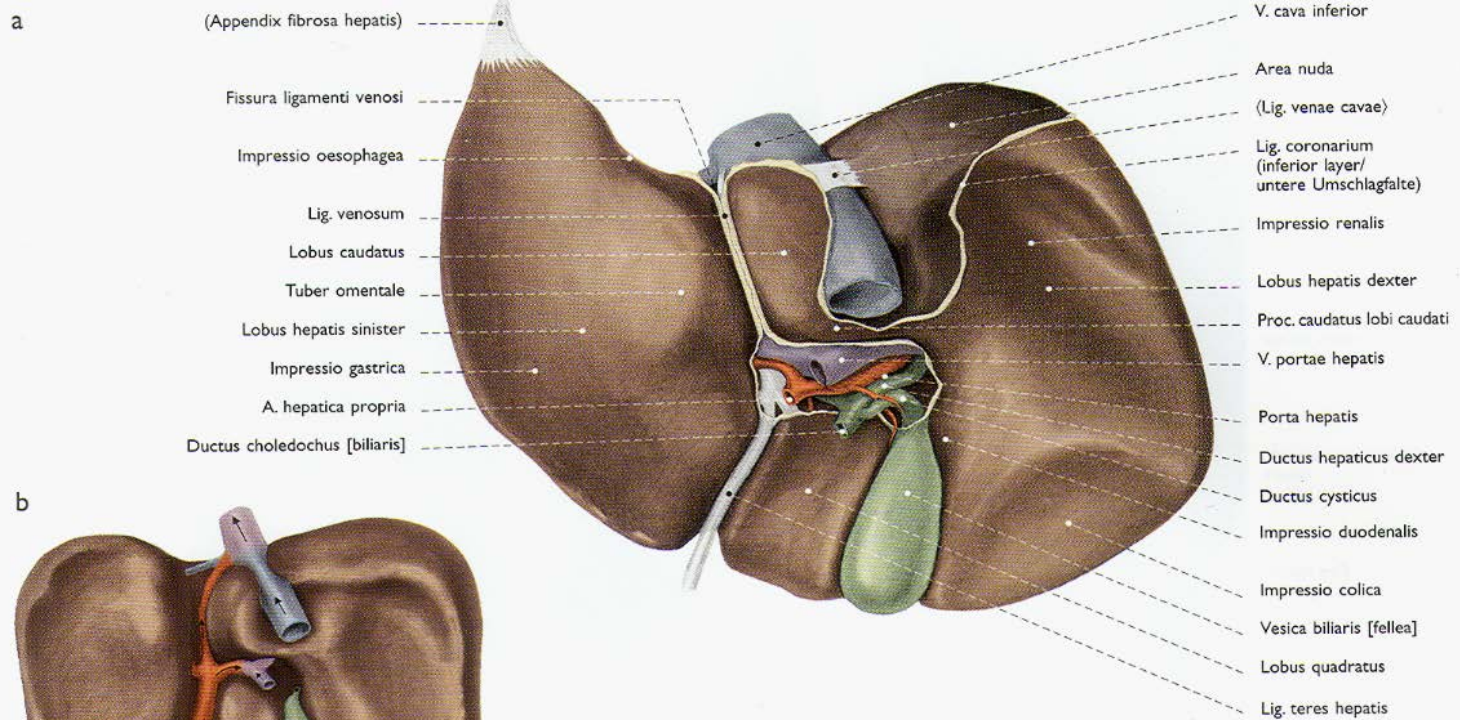
Játra

vazy a fixace

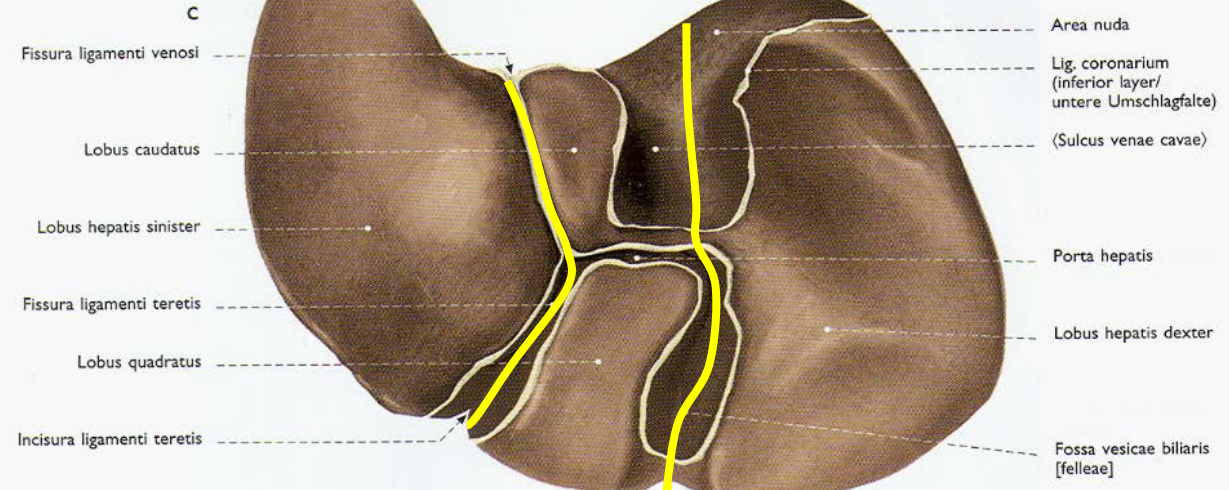
- lig. falciforme
- lig. teres hepatis
- lig. venosum
- lig. coronarium dx.+sin.
- lig. triangulare dx.+sin., appendix fibrosa hepatis
- lig. hepatorenale; lig. venae cavae



Fixace: závěs na v. cava inf., srůst s bránicí, břišní orgány, lig. teres hepatis

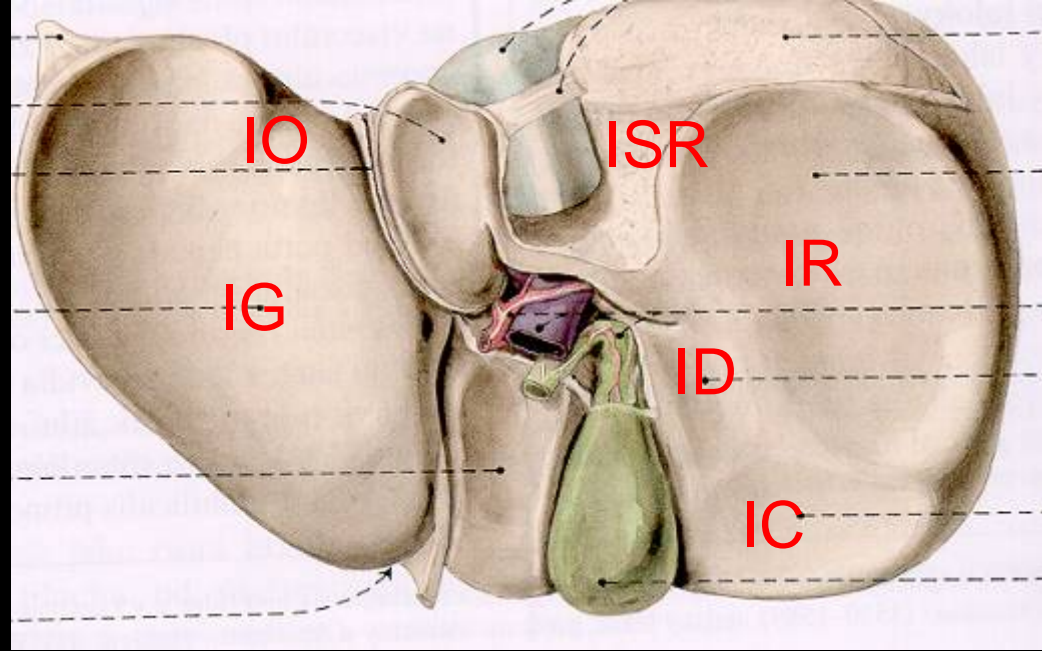


Fissura sagittalis sin. et dx.



Játra

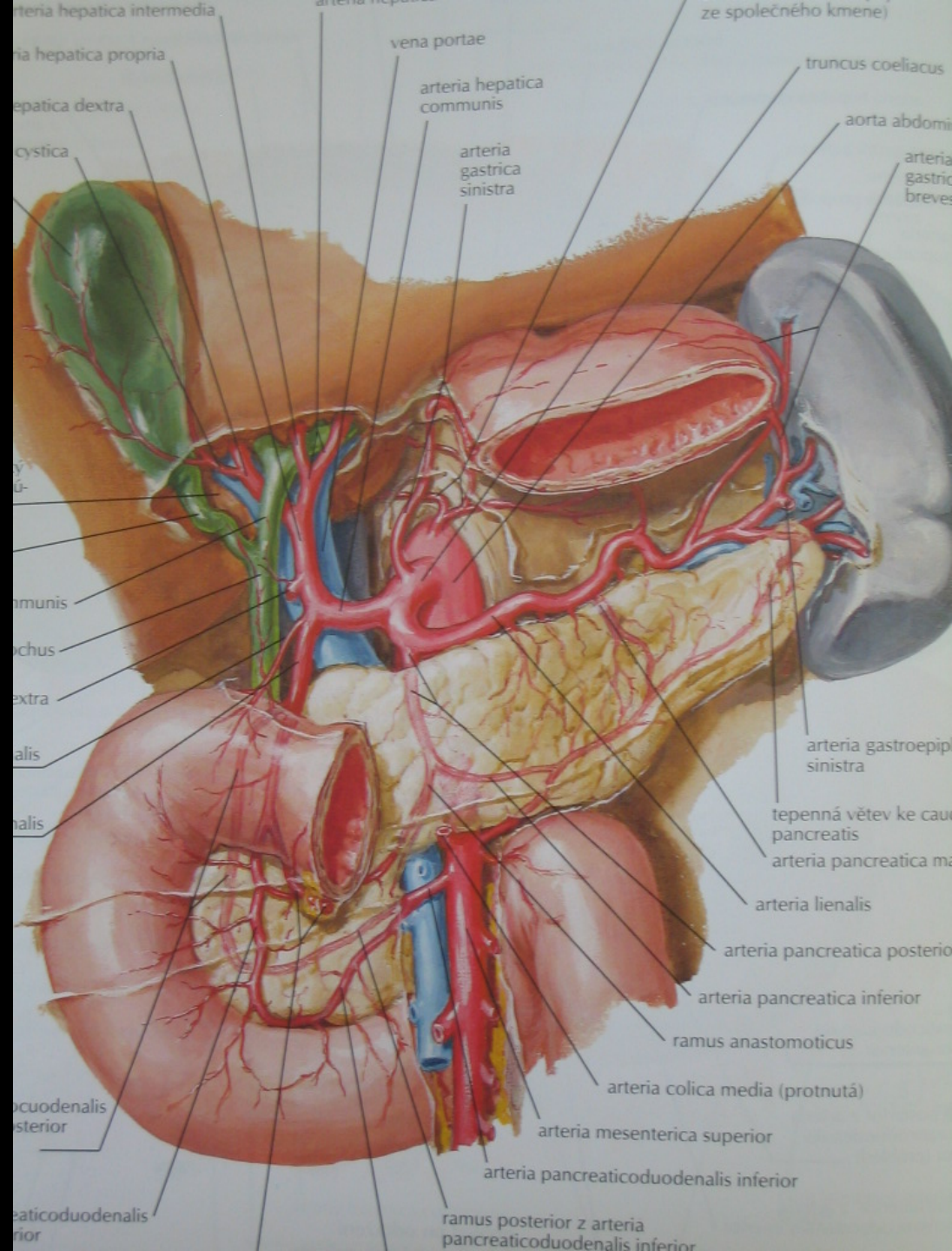
facies visceralis



- porta hepatis:
 - v. portae
 - a. hepatica propria
 - ductus hepaticus dx. et sin.
 - mízní cévy + nervy
- fissura lig. venosi + fissura lig. teretis
- sulcus venae cavae
- fossa vesicae biliaris

Porta hepatis Jaterní branka

- **v. portae** (vrátnice)
→ r. dx. et sin.
– *dorzálně*
- **a. hepatica propria**
→ r. dx. et sin.
– *ventromediálně*
- **ductus hepaticus**
dx. et sin.
– *ventrolaterálně*
- mízní cévy
- nervy



Játra – cévní zásobení

2 oběhy

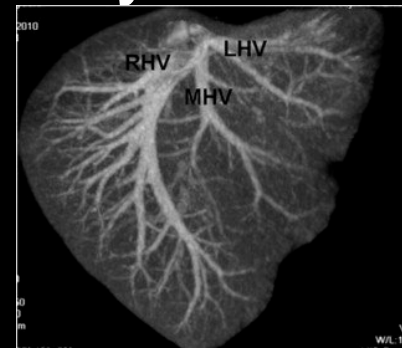
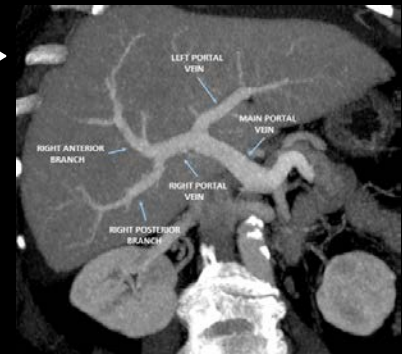
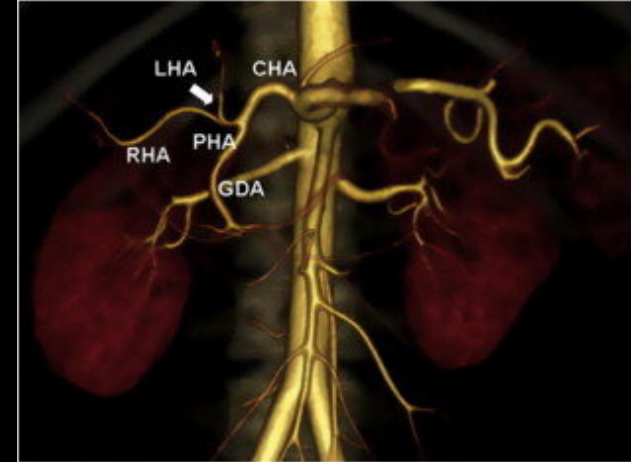
- nutritivní (tepny) – 25 % krve

truncus coeliacus → a. hepatica communis →
a. hepatica propria (+ a. hepatica accessoria)
→ r. dx.+ sin. → aa. interlobulares →
sinusoidy

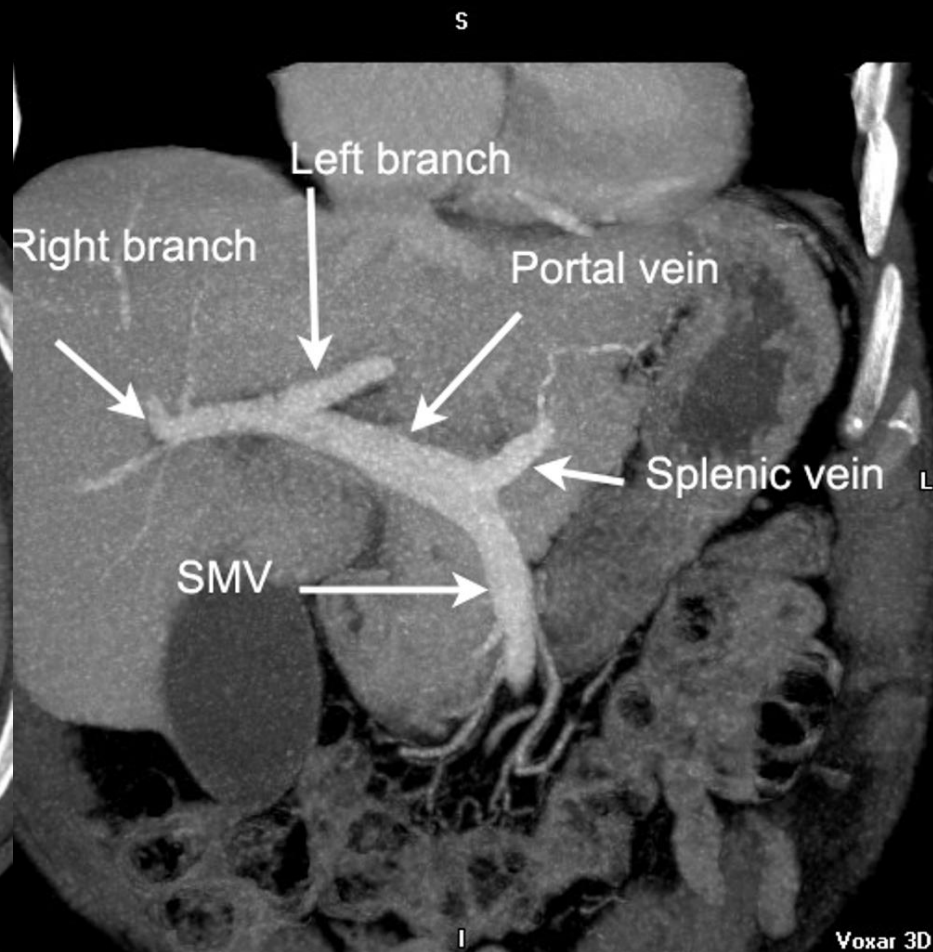
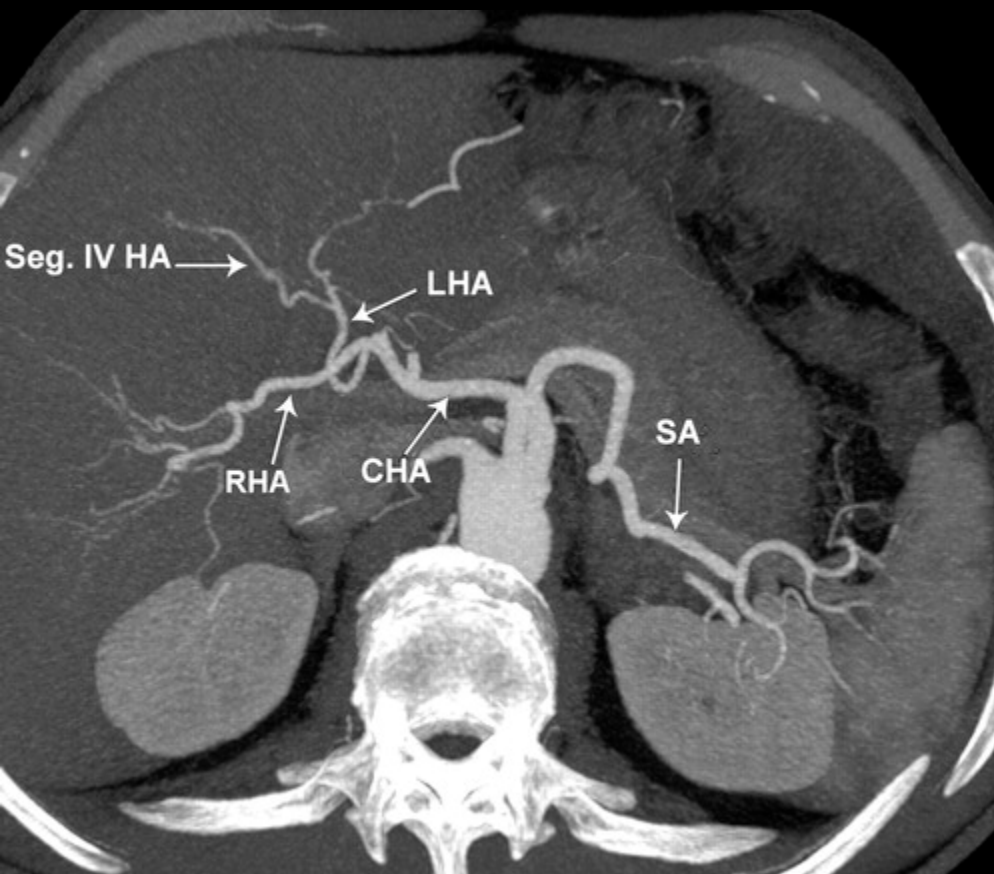
- funkční (žíly) – 75 % krve

v. portae → vv. interlobulares → sinusoidy

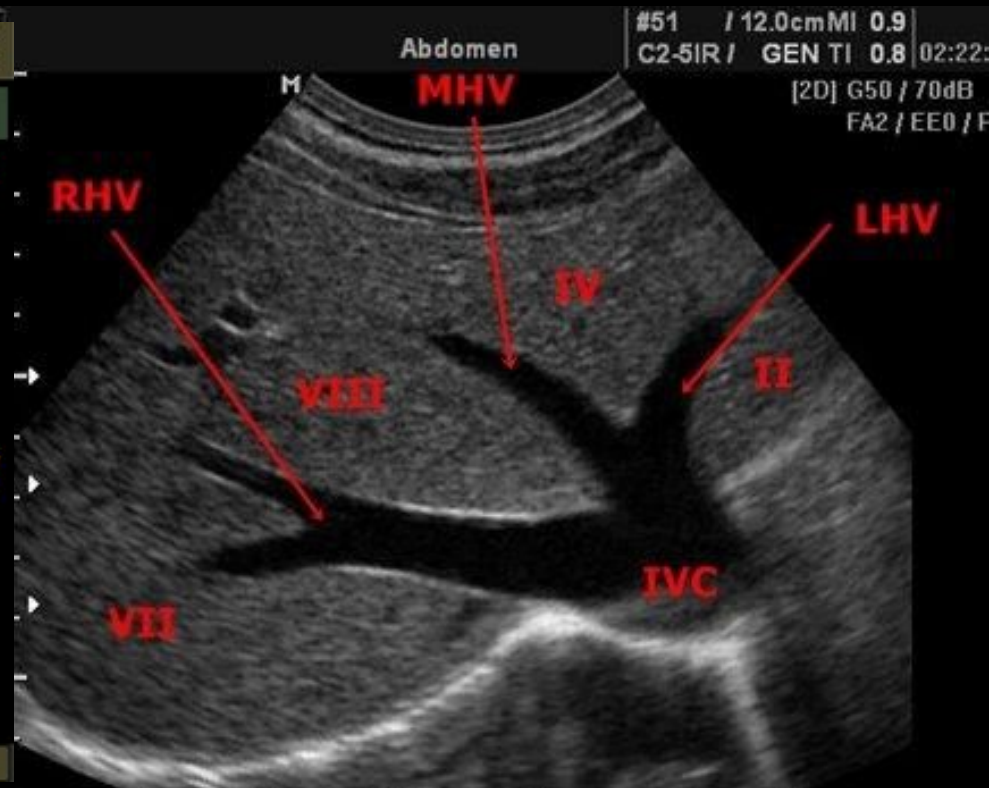
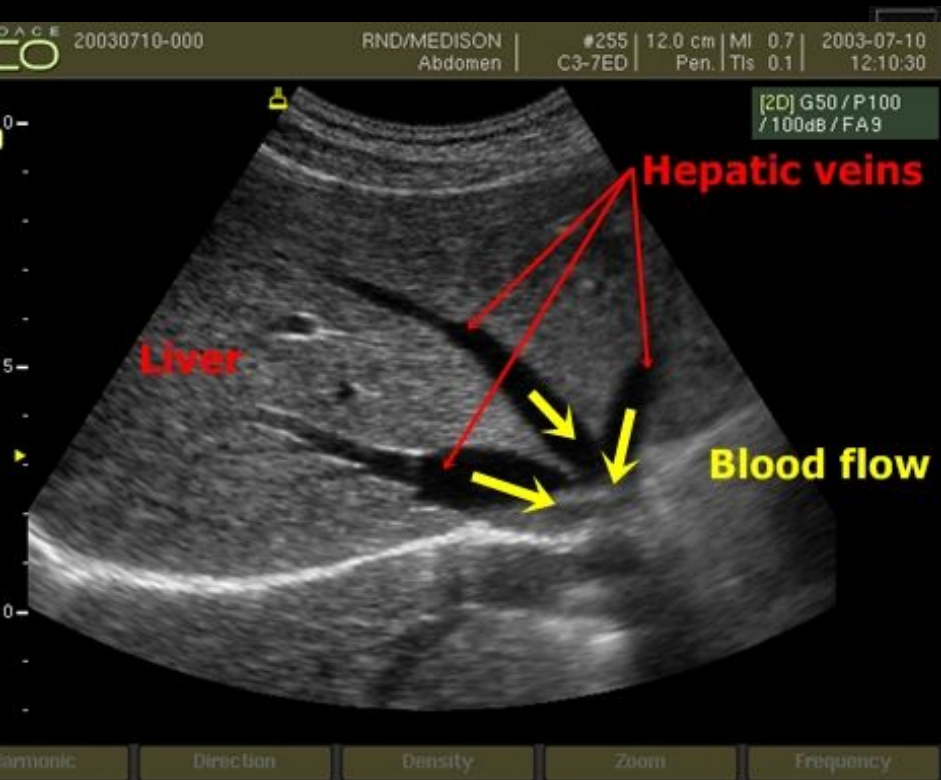
společný odtok: → vv. centrales →
v. hepaticae (dx.+ media + sin.) →
v. cava inf.



Játra – cévy



Ultrazvukové vyšetření jater – cévy



Játra – míza a nervy

Míza: 3 směry

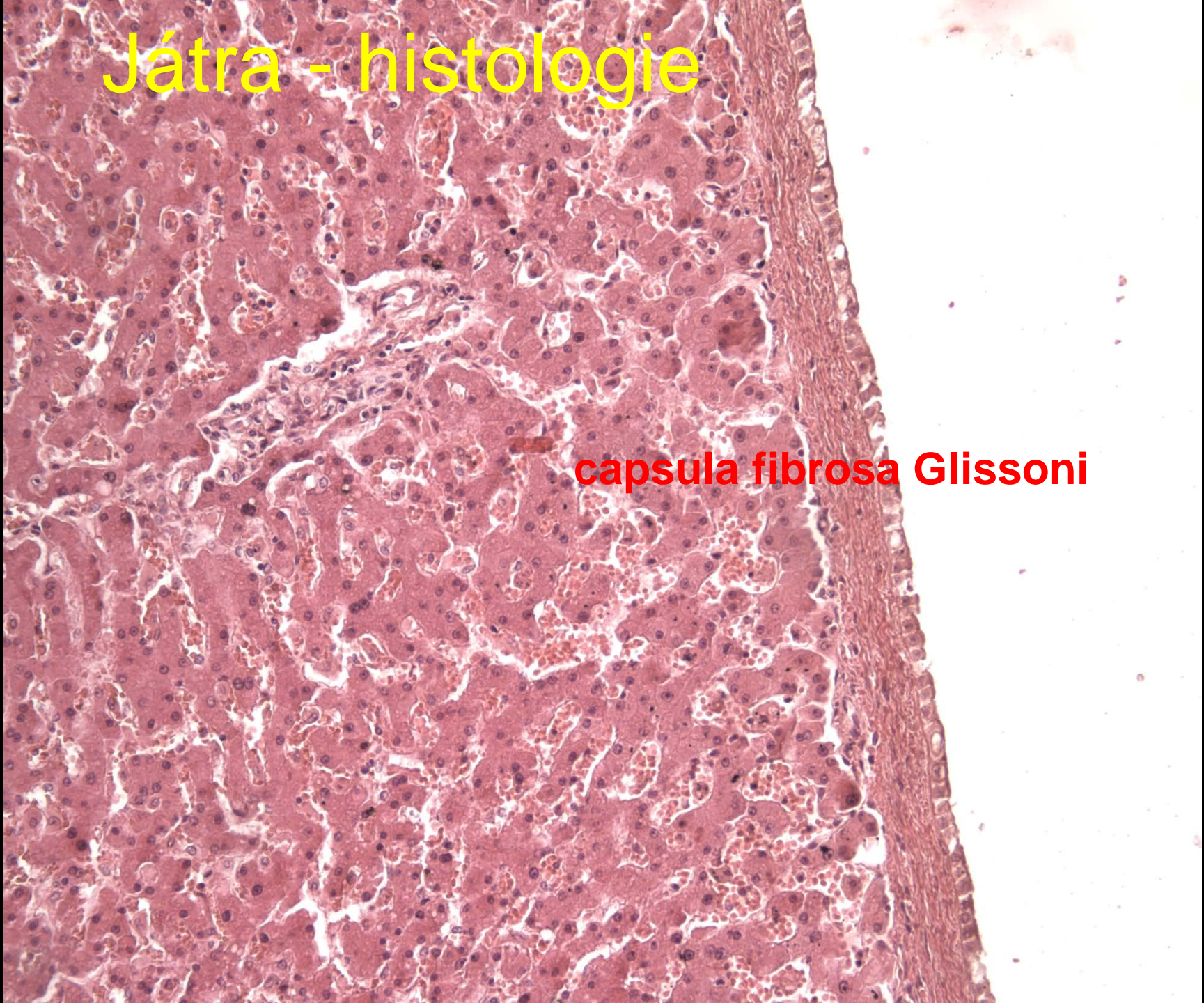
- **n.l. coeliaci**
- n.l. mediastinales ant.
- n.l. mediasitnales post.

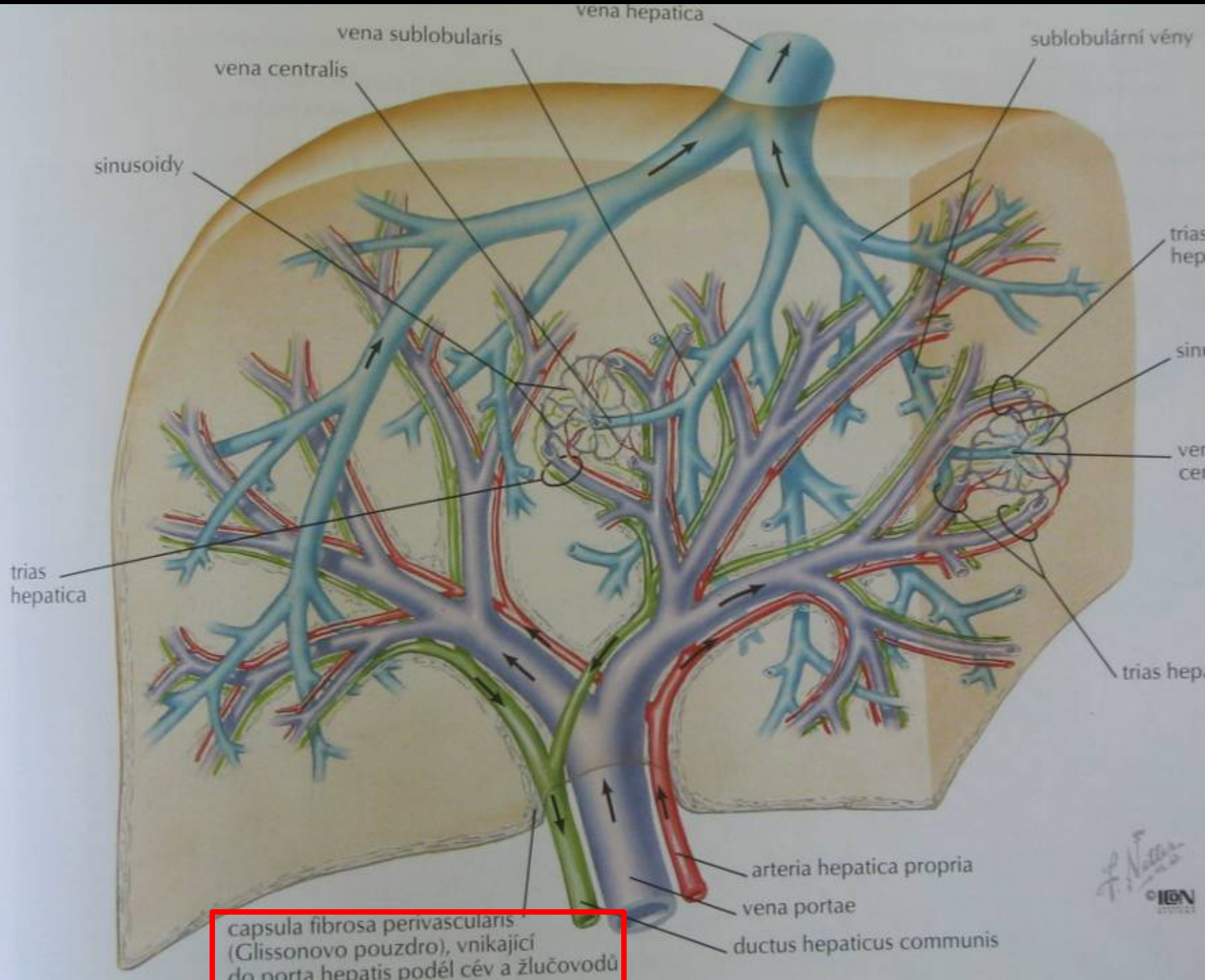
Nervy:

- parasympatikus – **n. X**
- sympatikus – **truncus sympathicus** → nn. splanchnici thoracici → plexus coeliacus → plexus hepaticus
- senzitivní – **n. phrenicus**
 - pobřišnice pod játry až ke žlučníku !!!

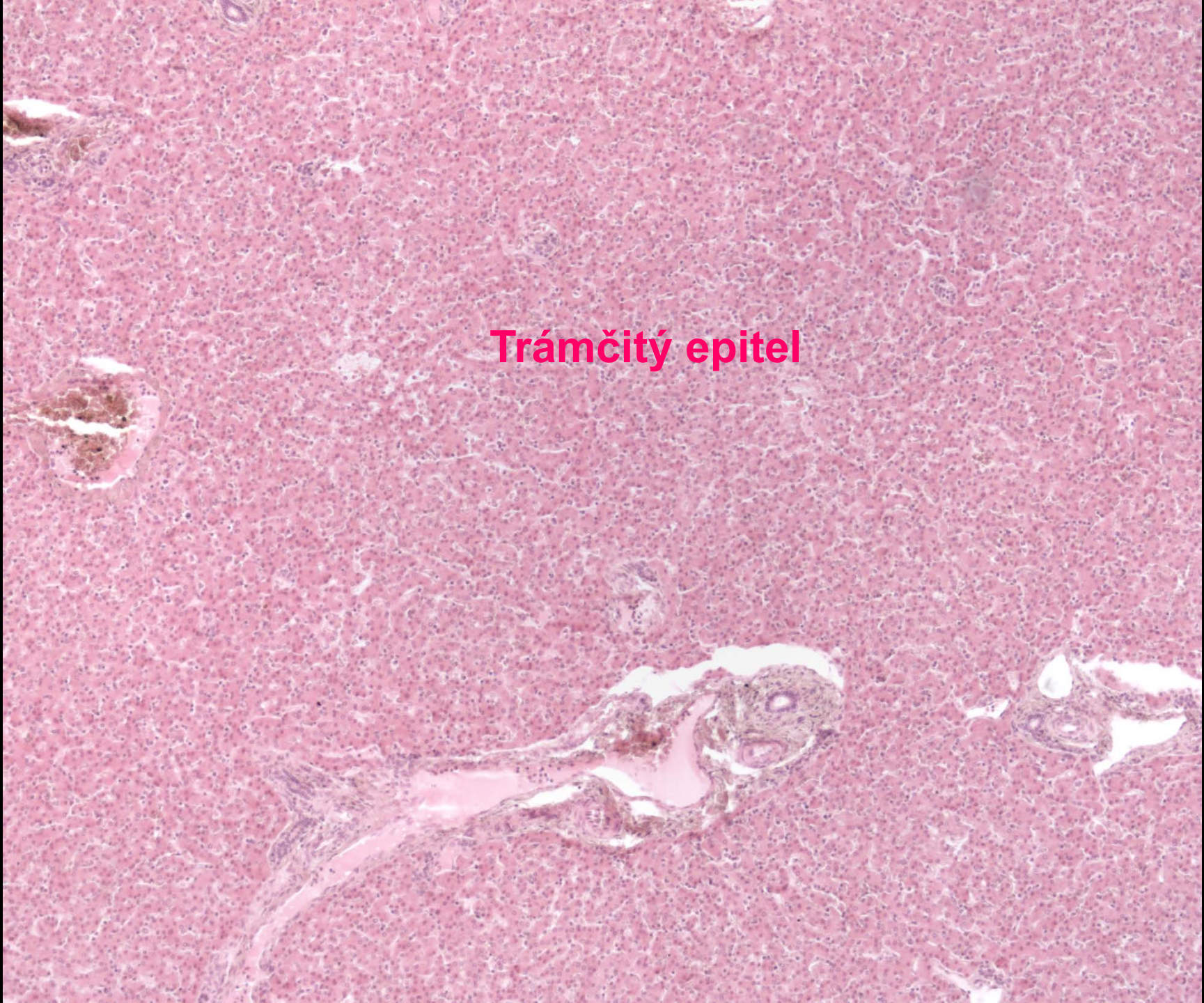Játra - histologie

capsula fibrosa Glissoni



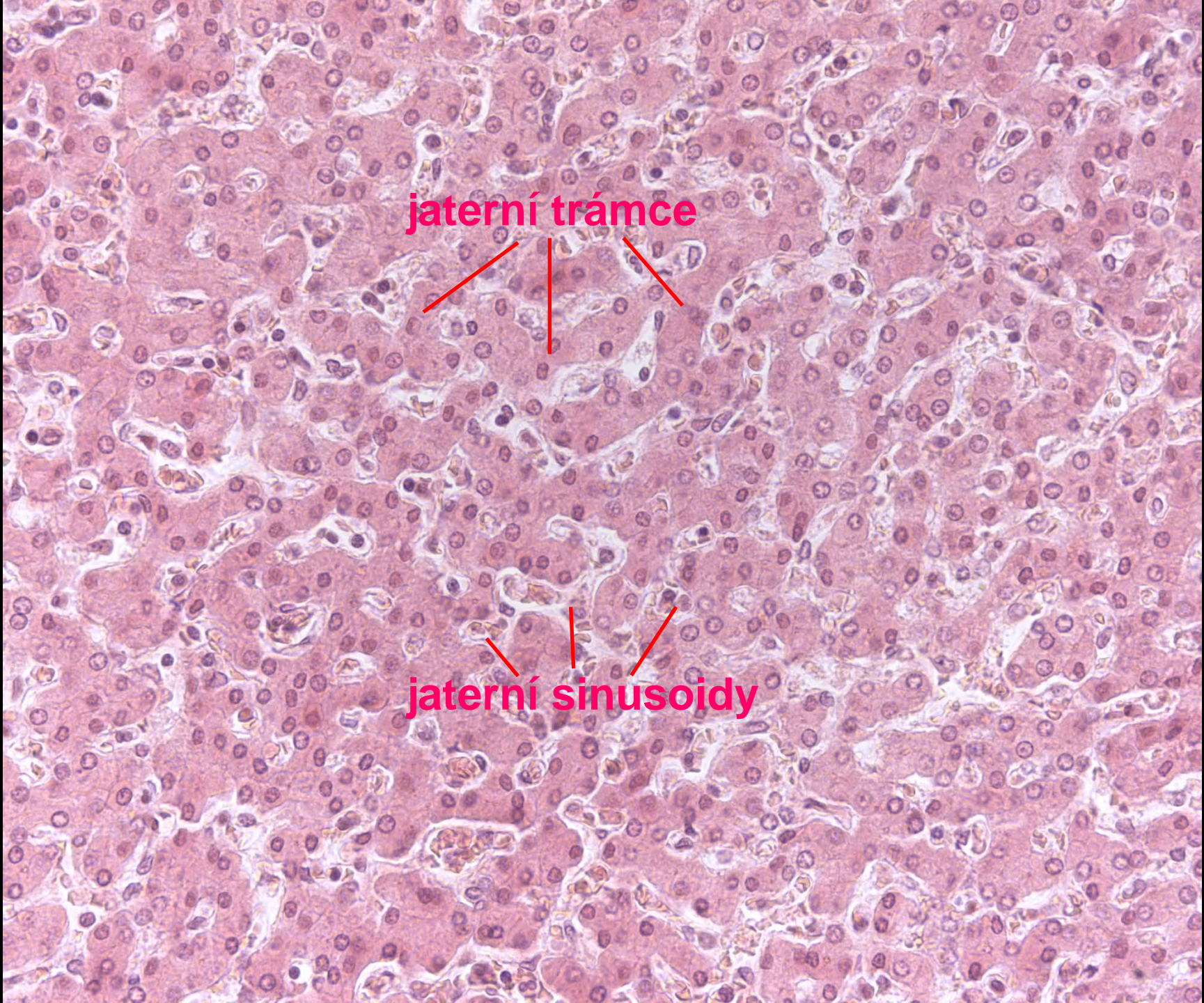


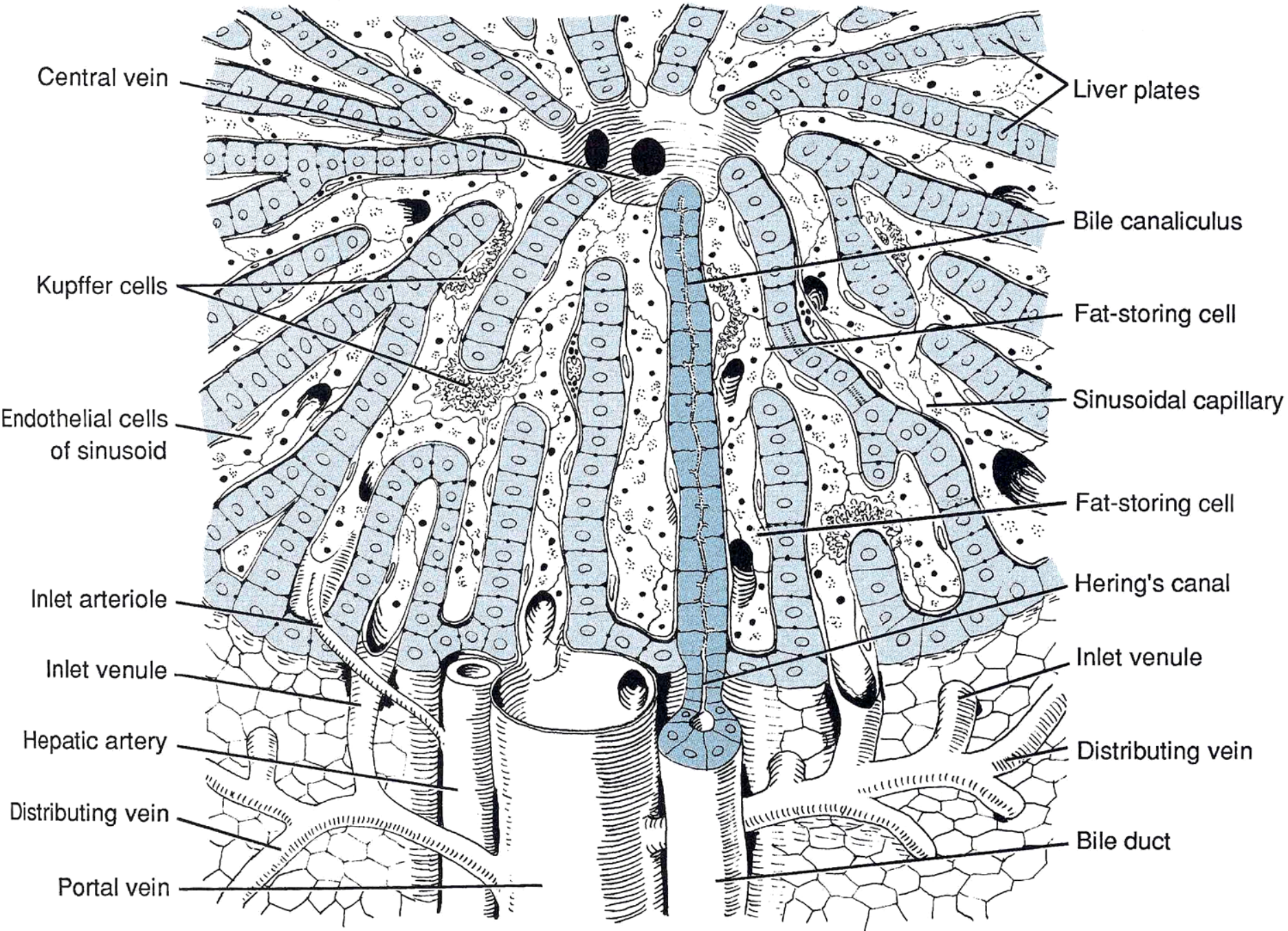
Trámčitý epitel



jaterní trámce

jaterní sinusoidy





Central vein

Liver plates

Kupffer cells

Bile canaliculus

Endothelial cells of sinusoid

Fat-storing cell

Inlet arteriole

Sinusoidal capillary

Inlet venule

Fat-storing cell

Hepatic artery

Hering's canal

Distributing vein

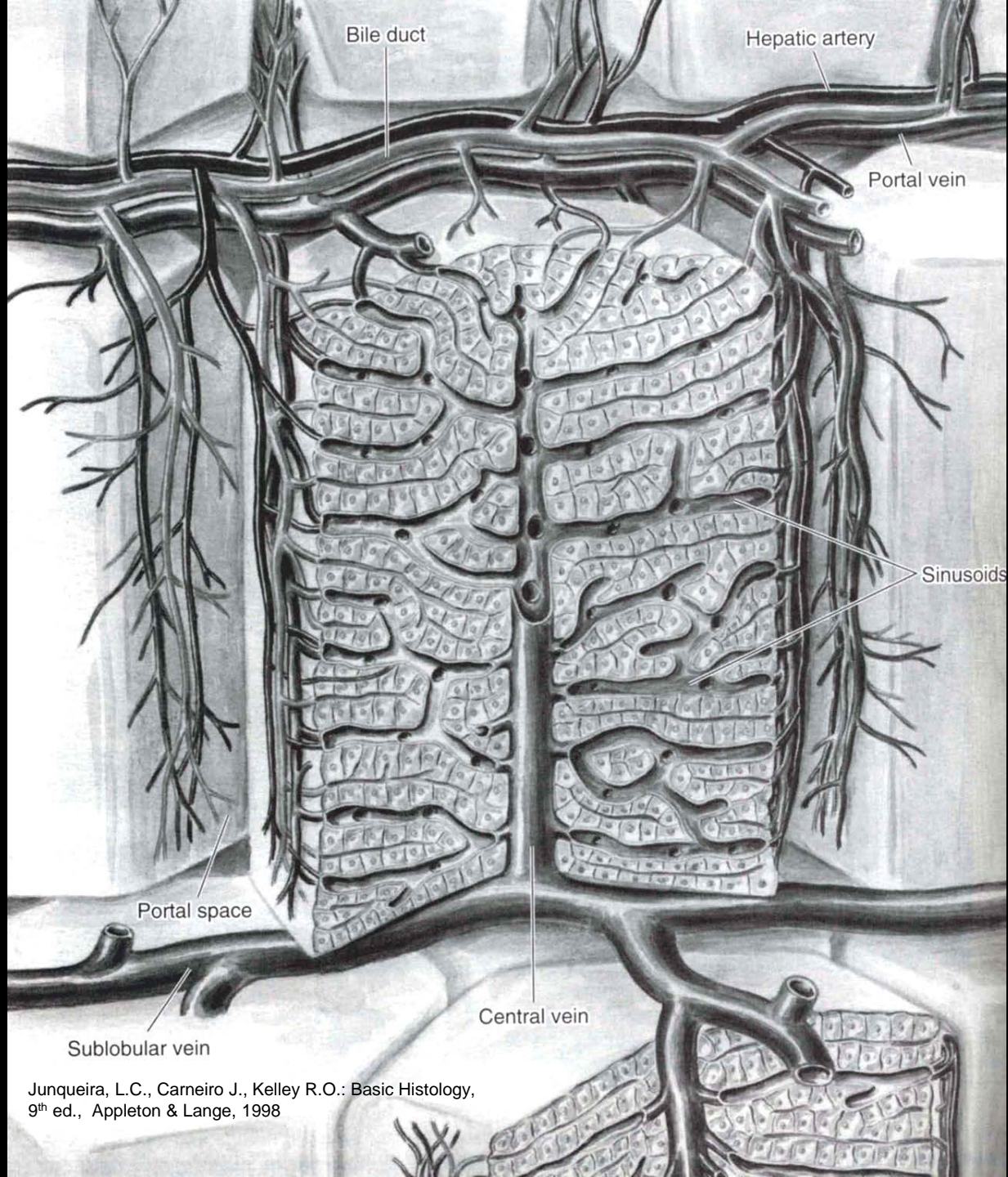
Inlet venule

Portal vein

Distributing vein

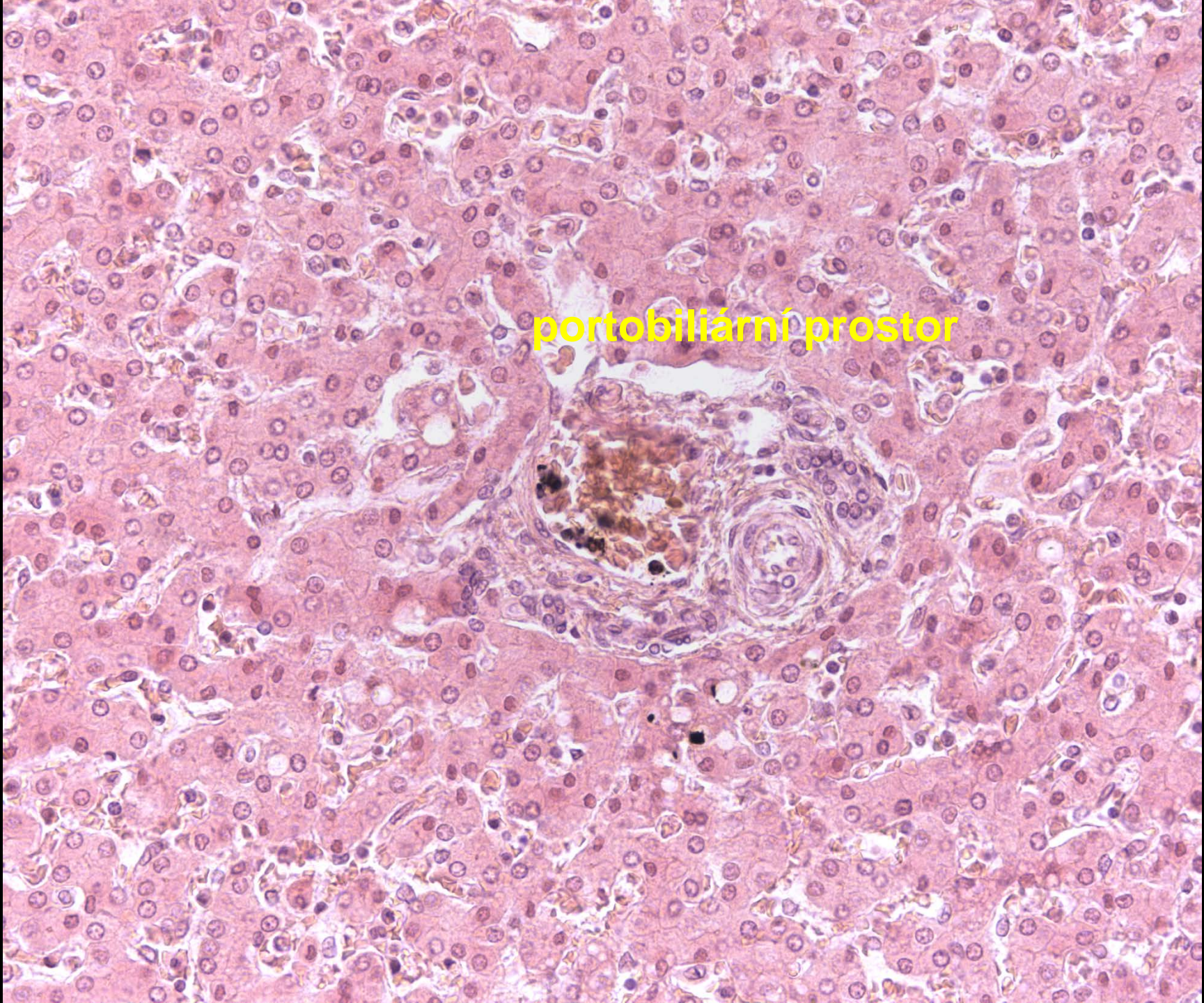
Bile duct

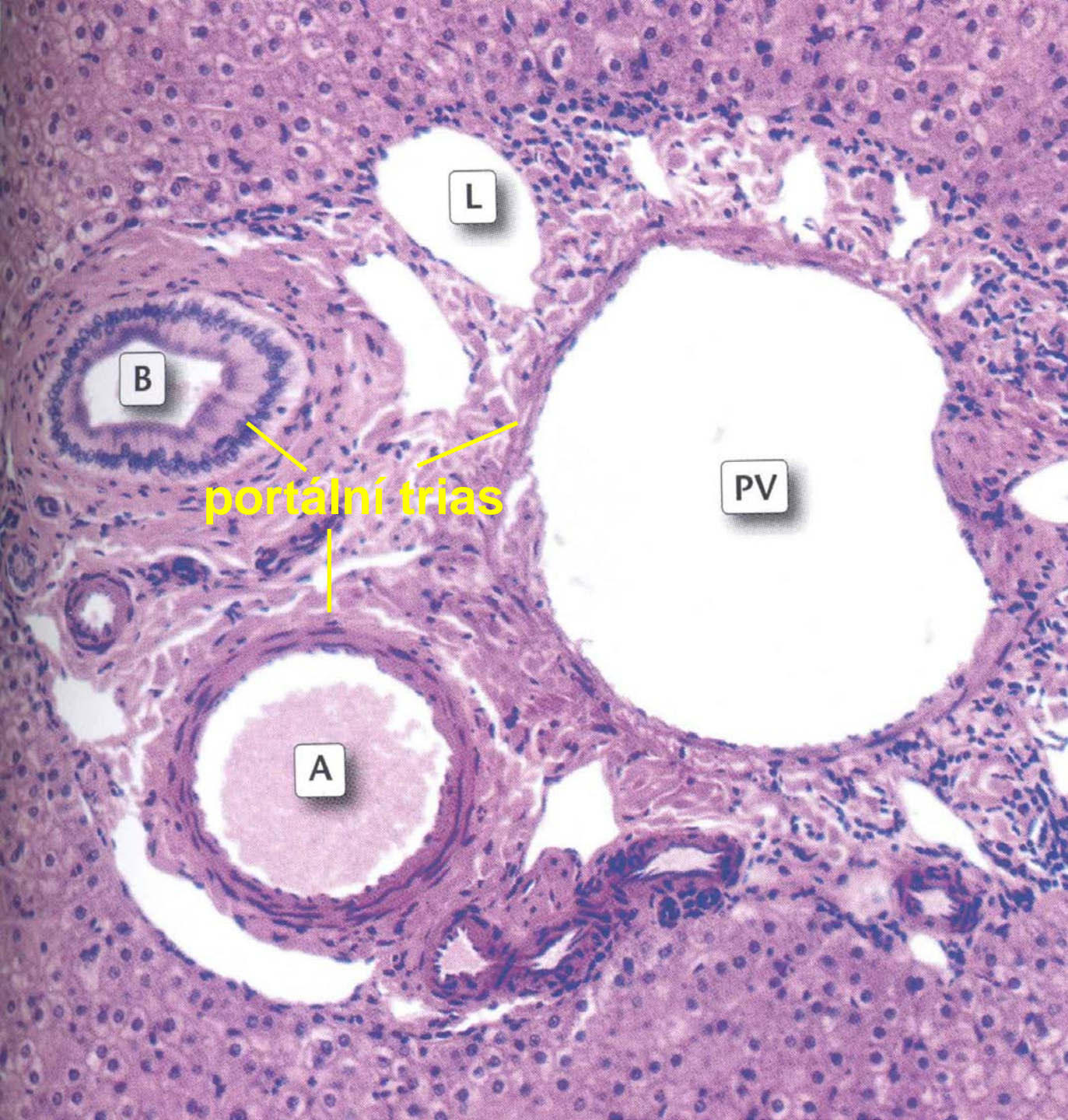
Cévní zásobení



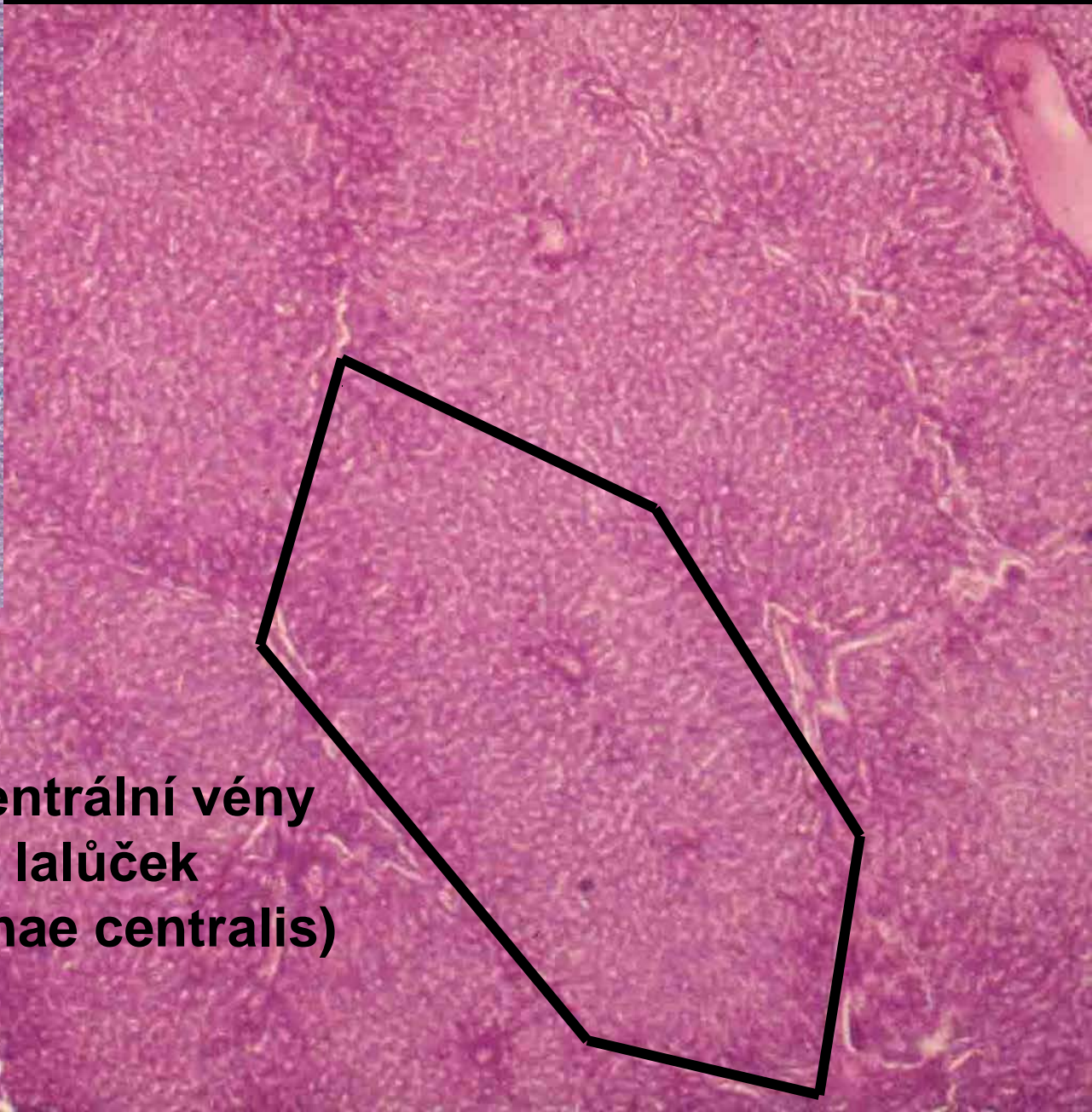

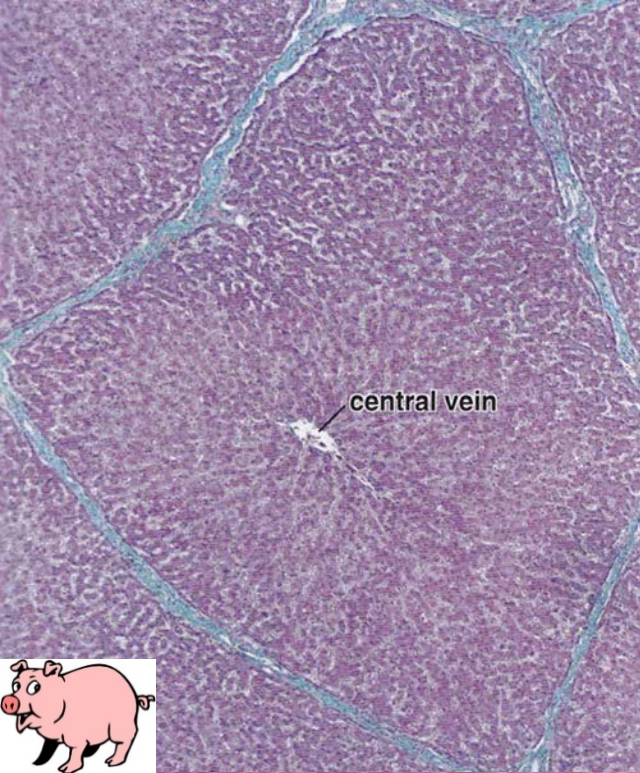
Junqueira, L.C., Carneiro J., Kelley R.O.: Basic Histology, 9th ed., Appleton & Lange, 1998

portobiliární prostor



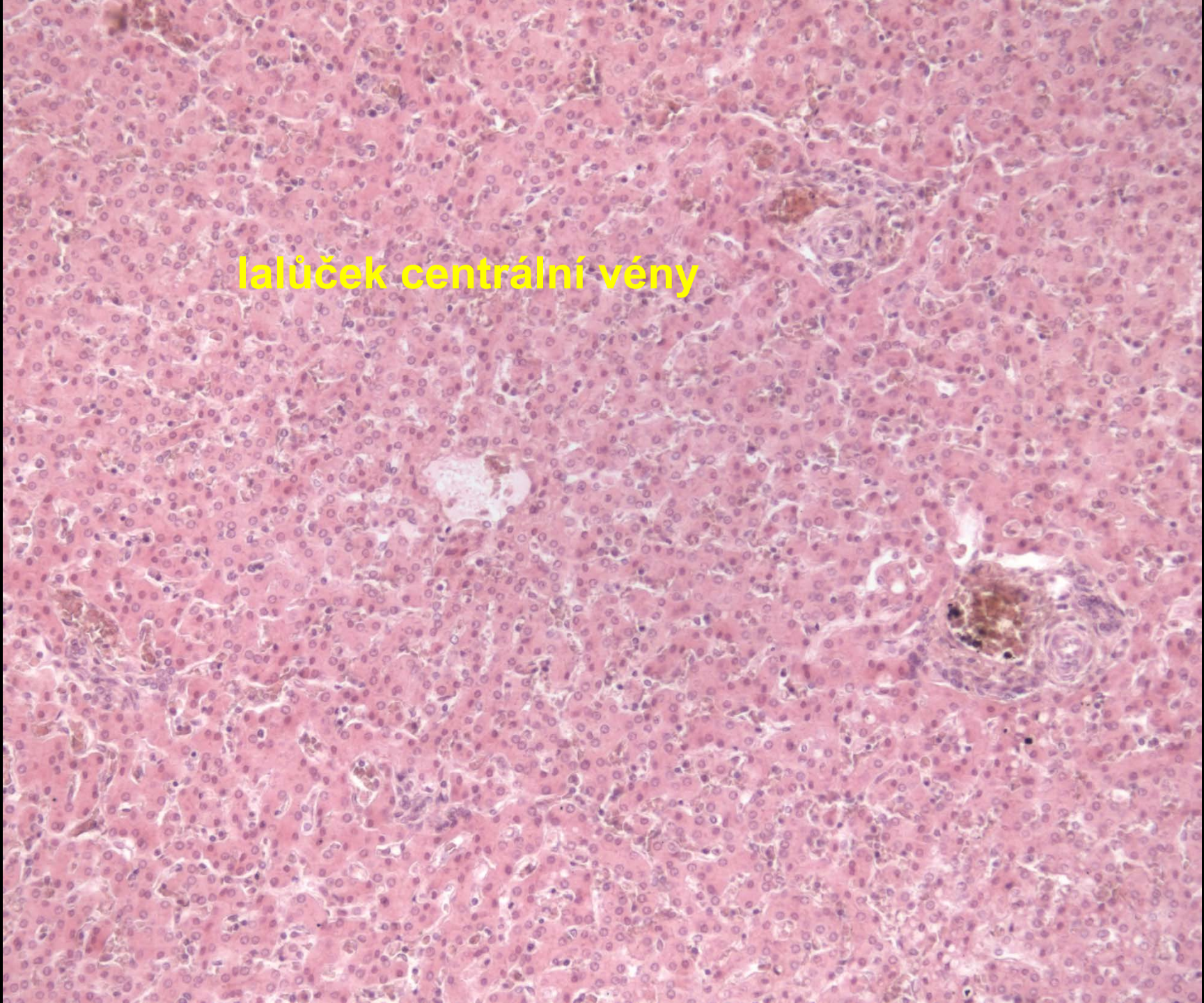


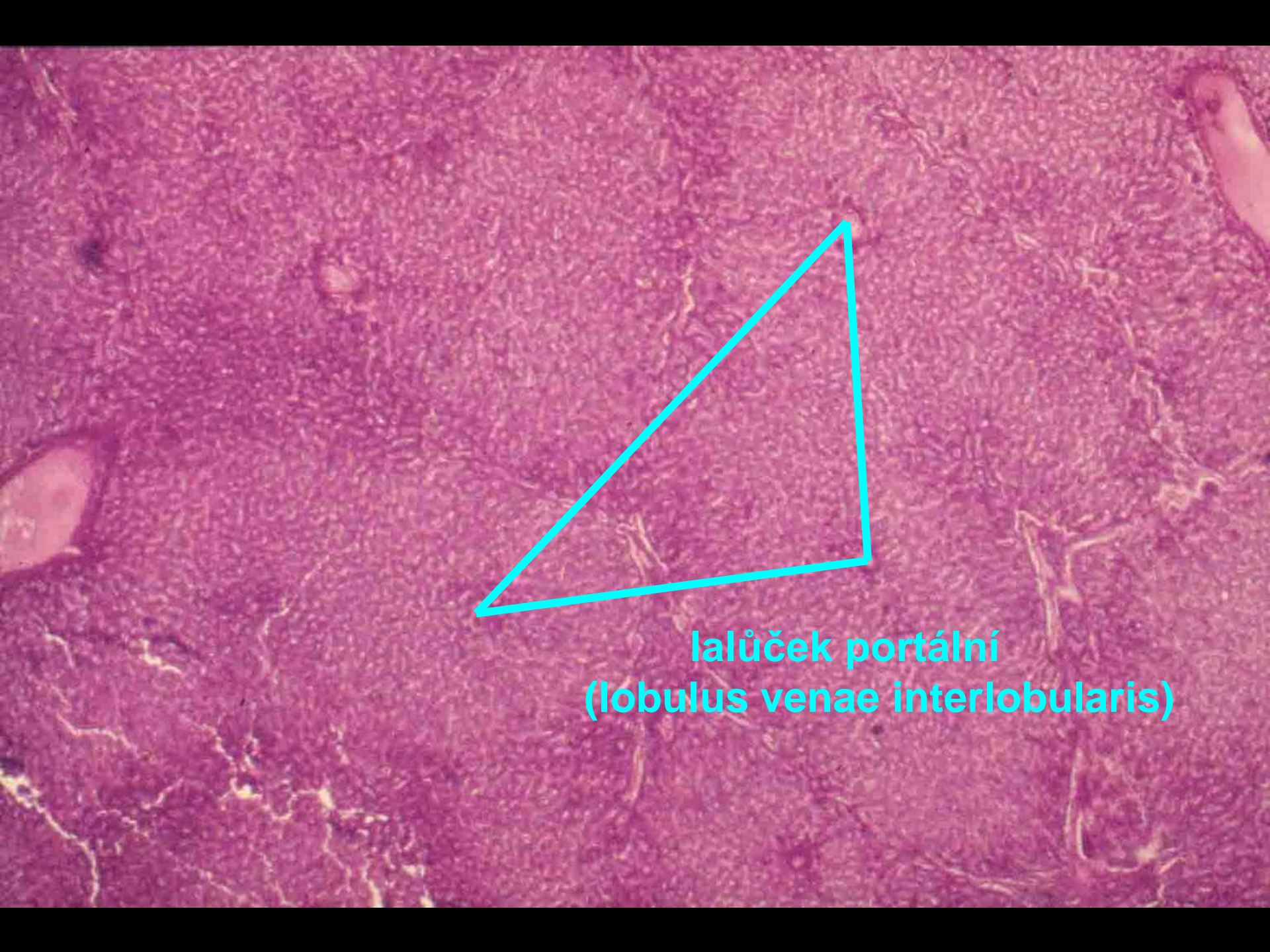
portální trias



**lalůček centrální vény
jaterní lalůček
(lobulus venae centralis)**

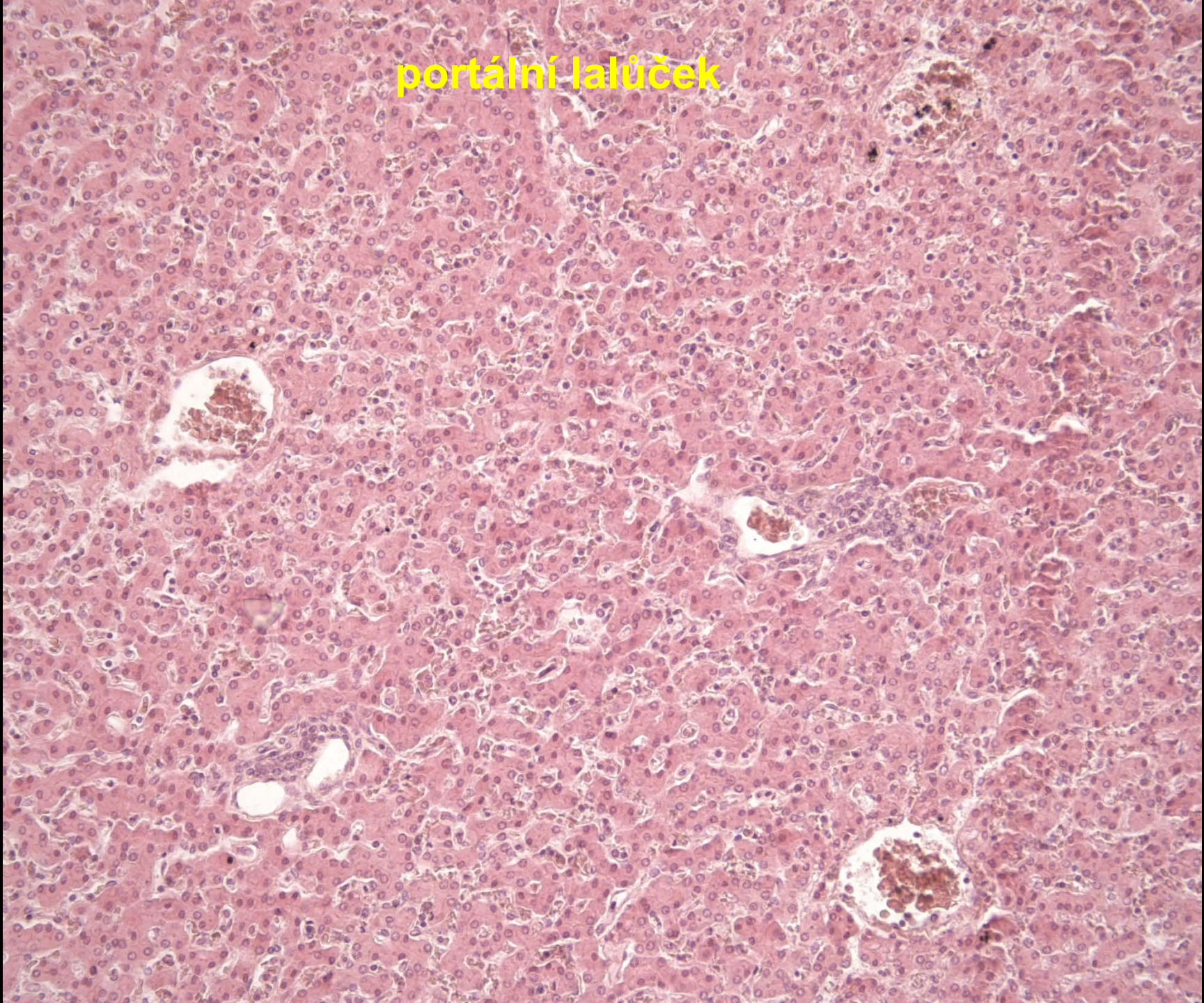
lalůček centrální věny



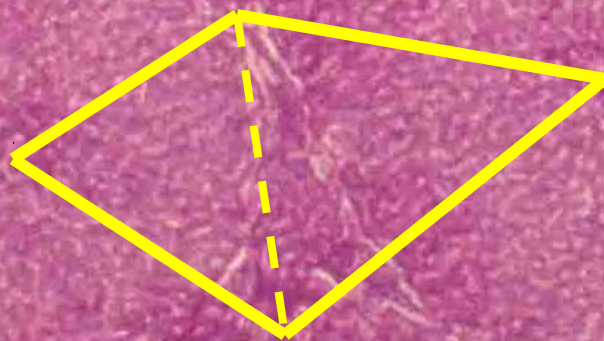


**lalůček portální
(lobulus venae interlobularis)**

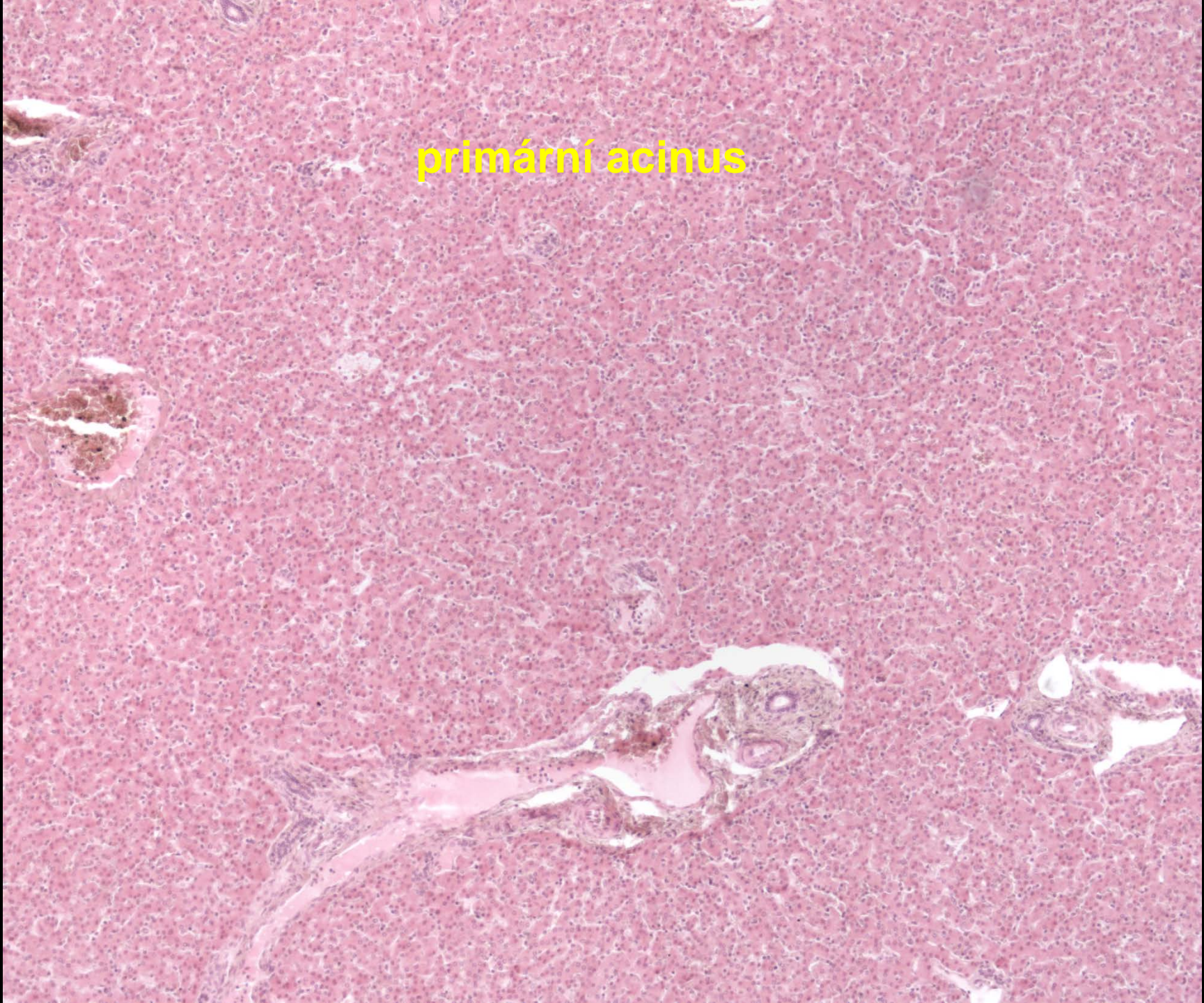
portální lalůček



**primární acinus
(acinus venae circumlobularis)**



primární acinus



a CLASSIC HEPATIC LOBULE

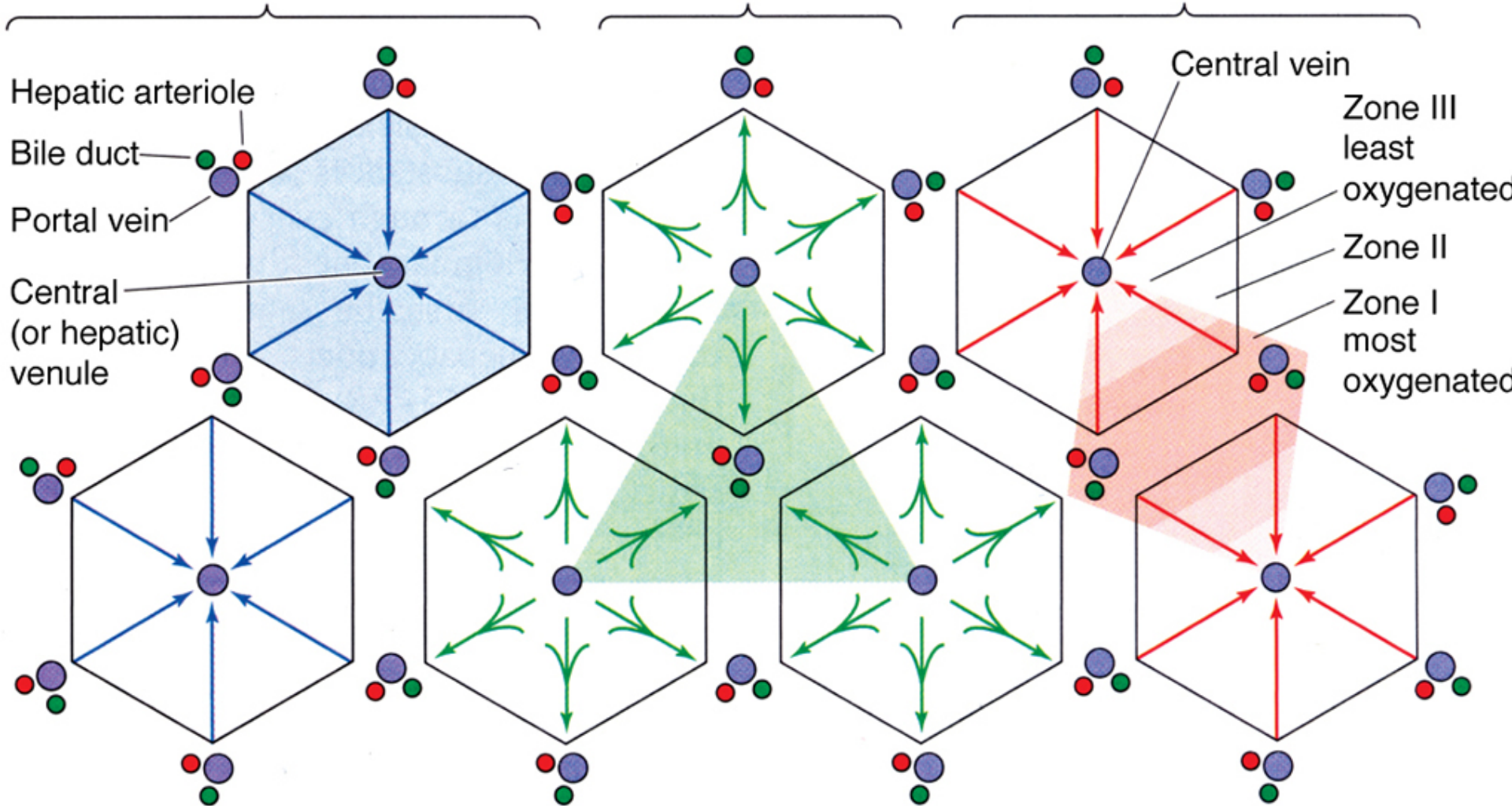
Drains blood from the portal vein and the hepatic artery to the hepatic or the central vein

b PORTAL LOBULE

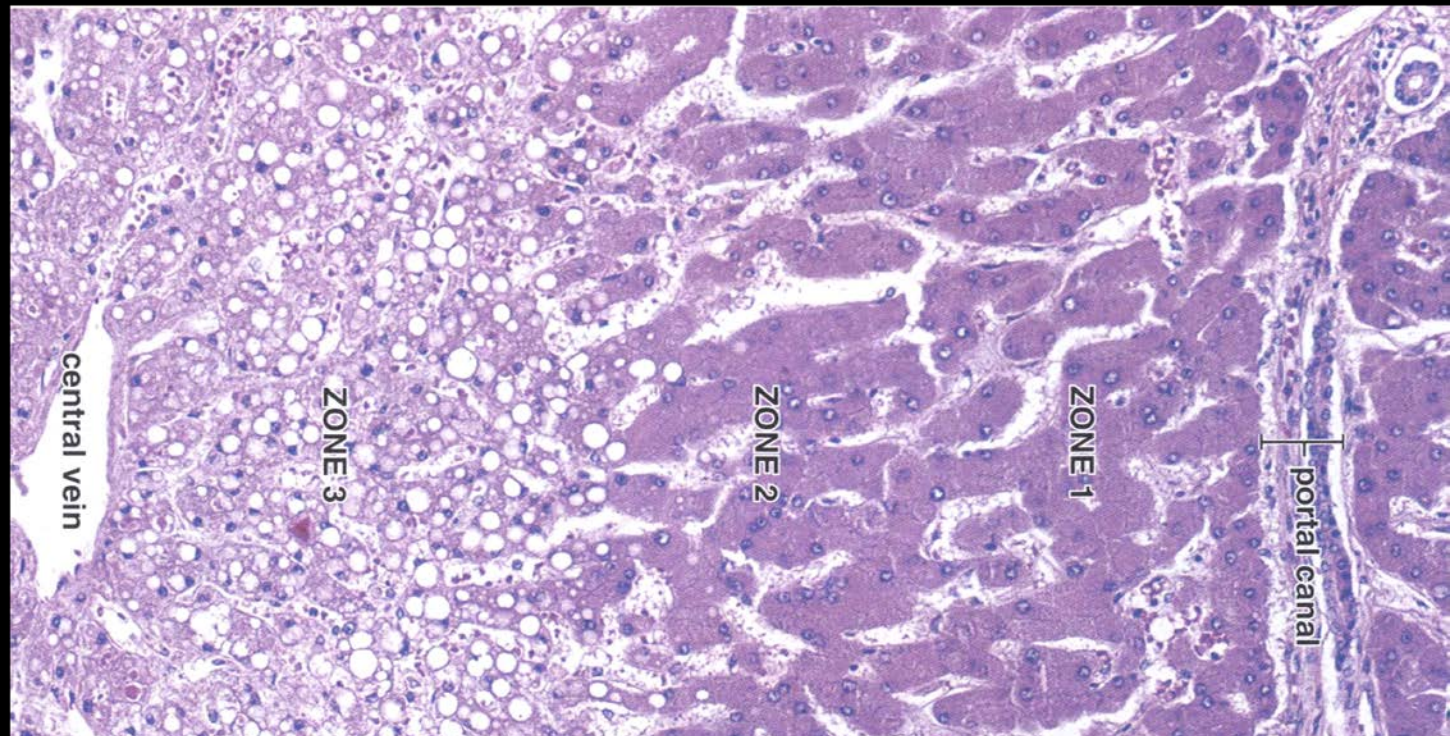
Drains bile from hepatocytes to the bile duct

c PORTAL ACINUS

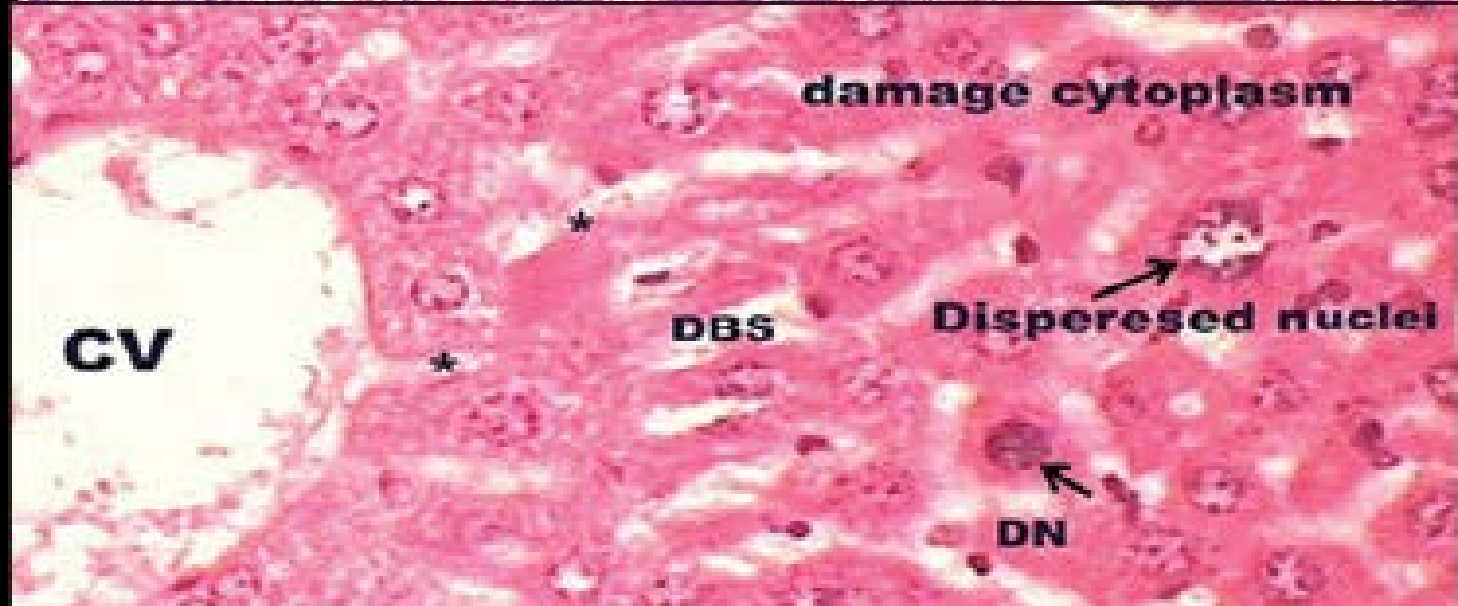Supplies oxygenated blood to hepatocytes



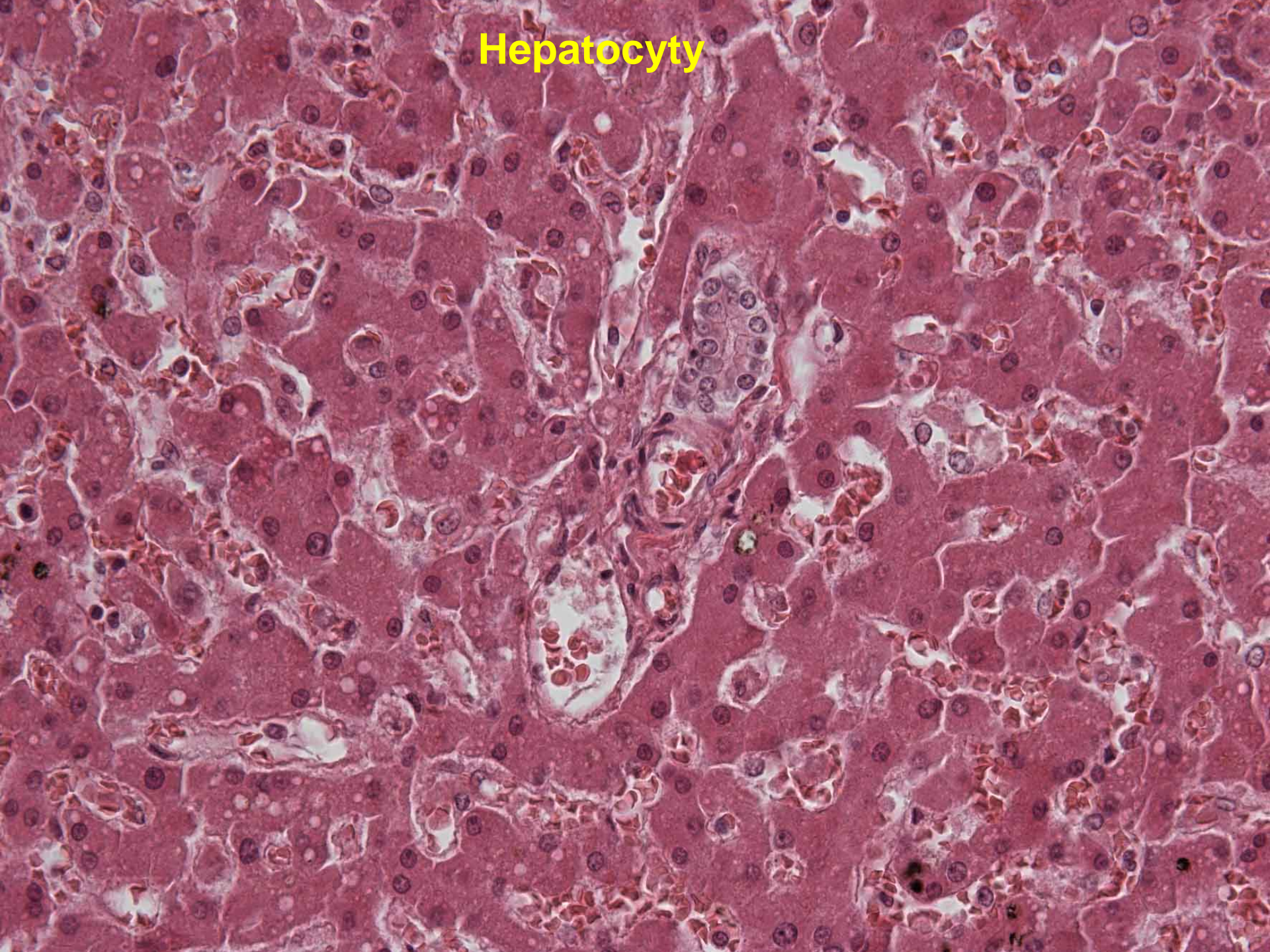
hypoxické
poškození
jaterního
lalůčku

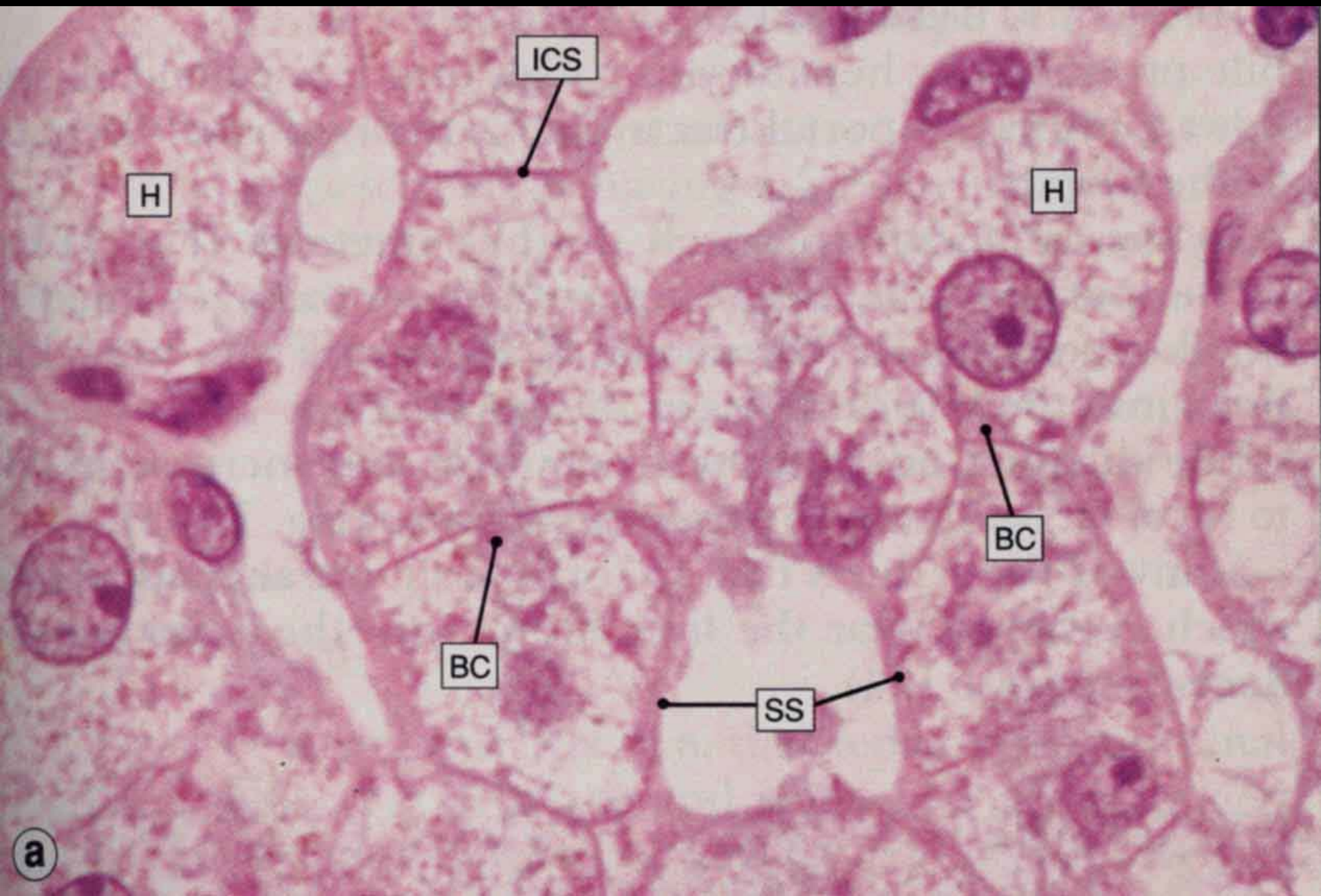


toxické
poškození
jaterního
lalůčku

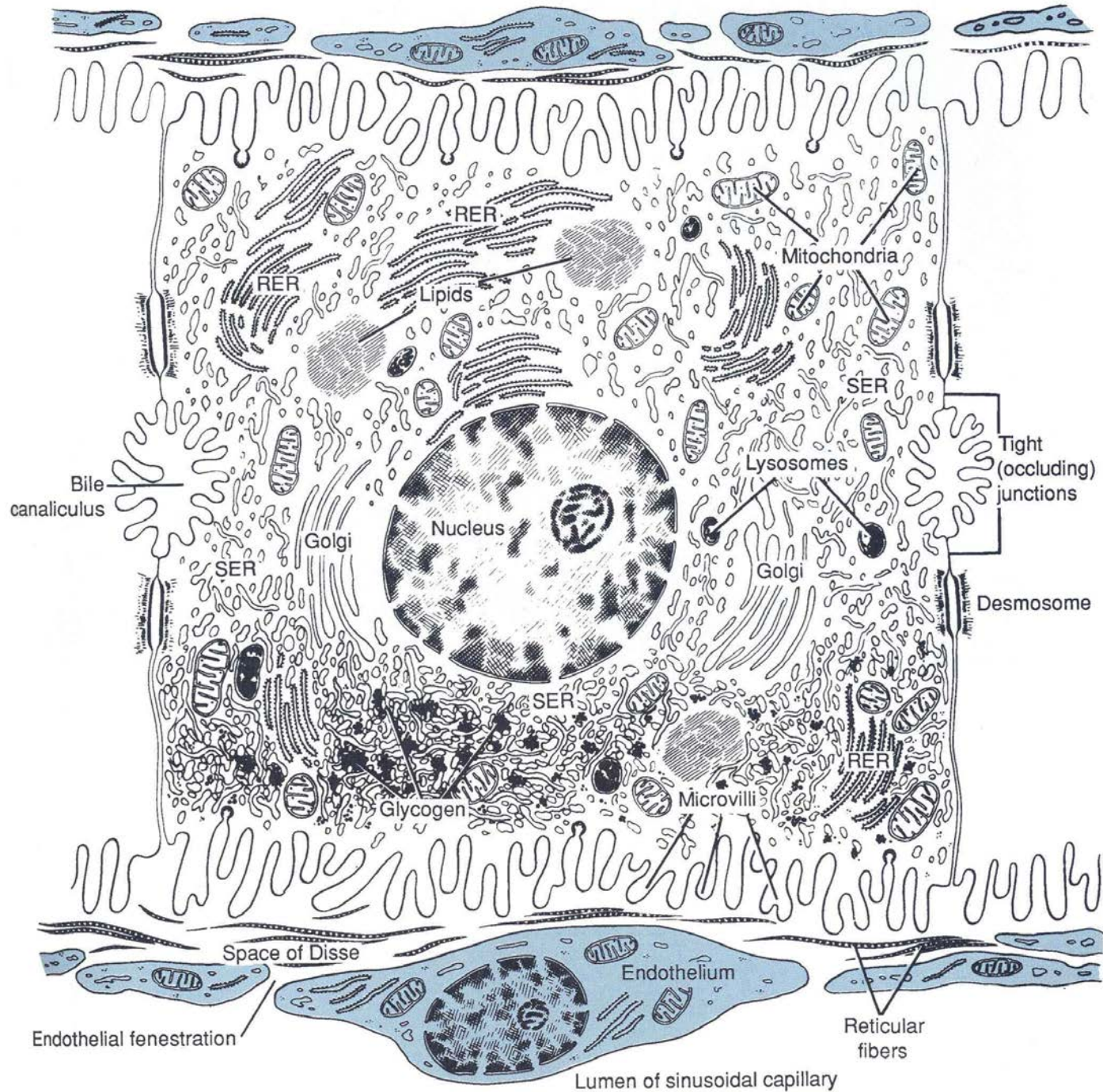


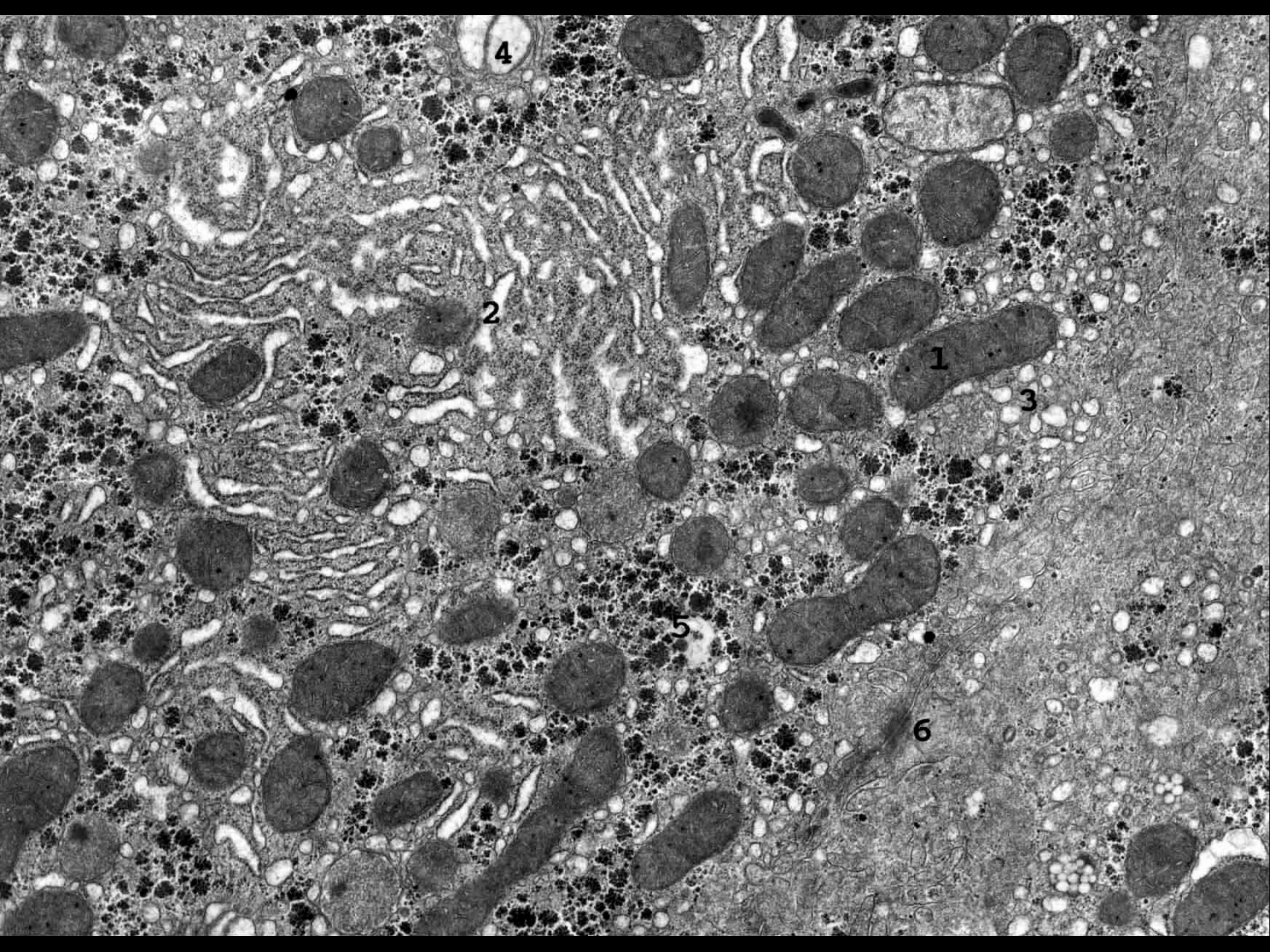
Hepatocytty

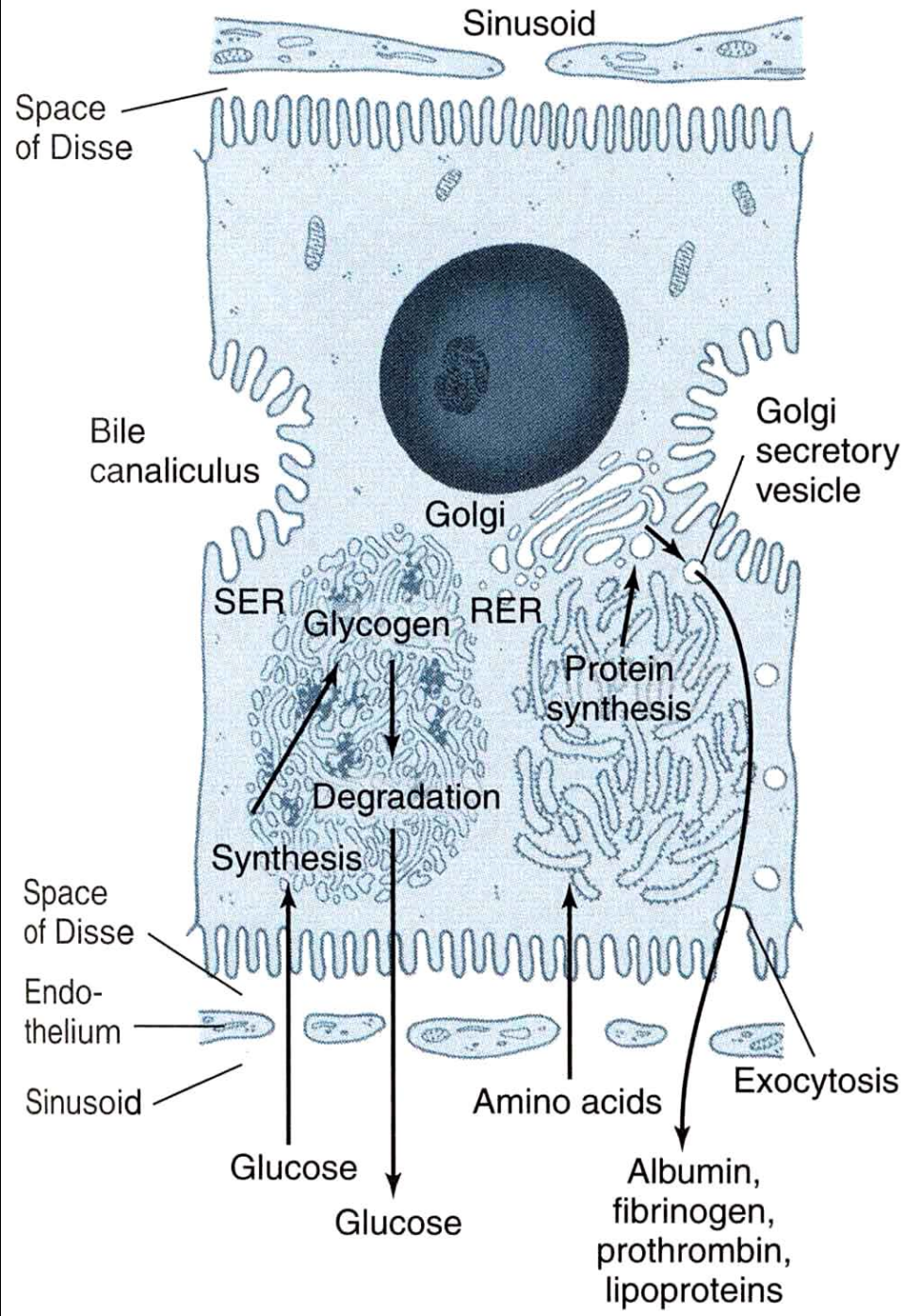


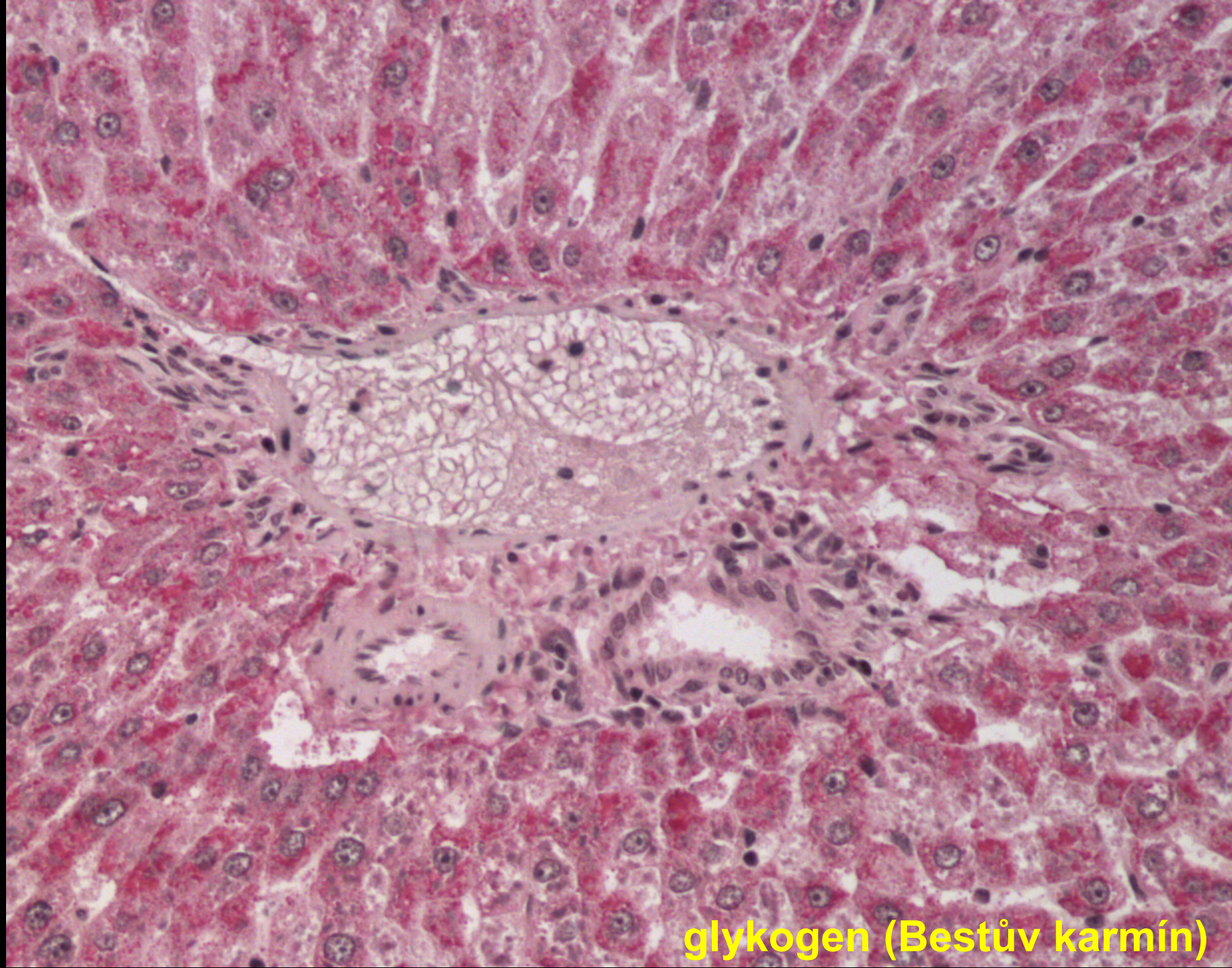


a

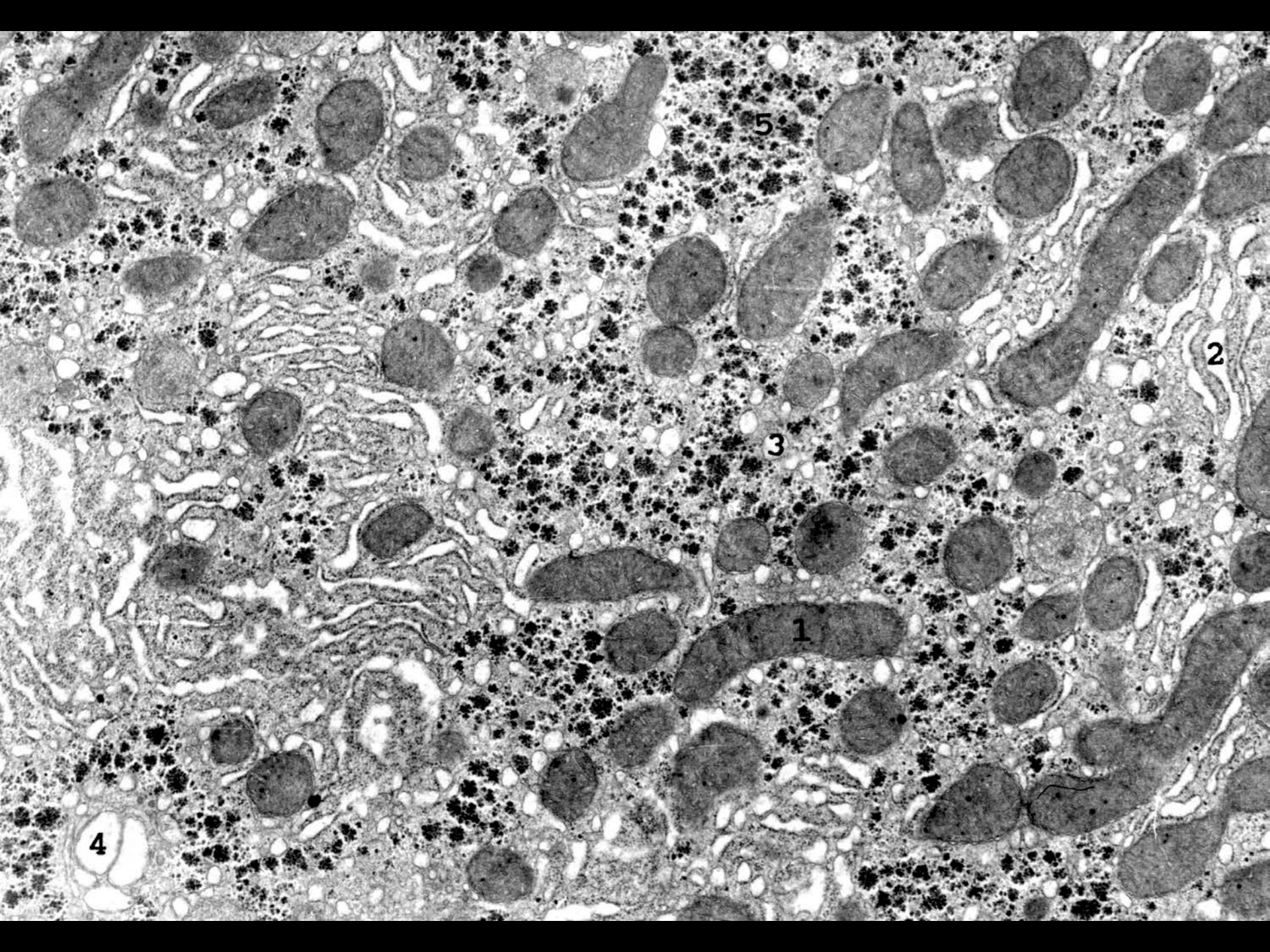


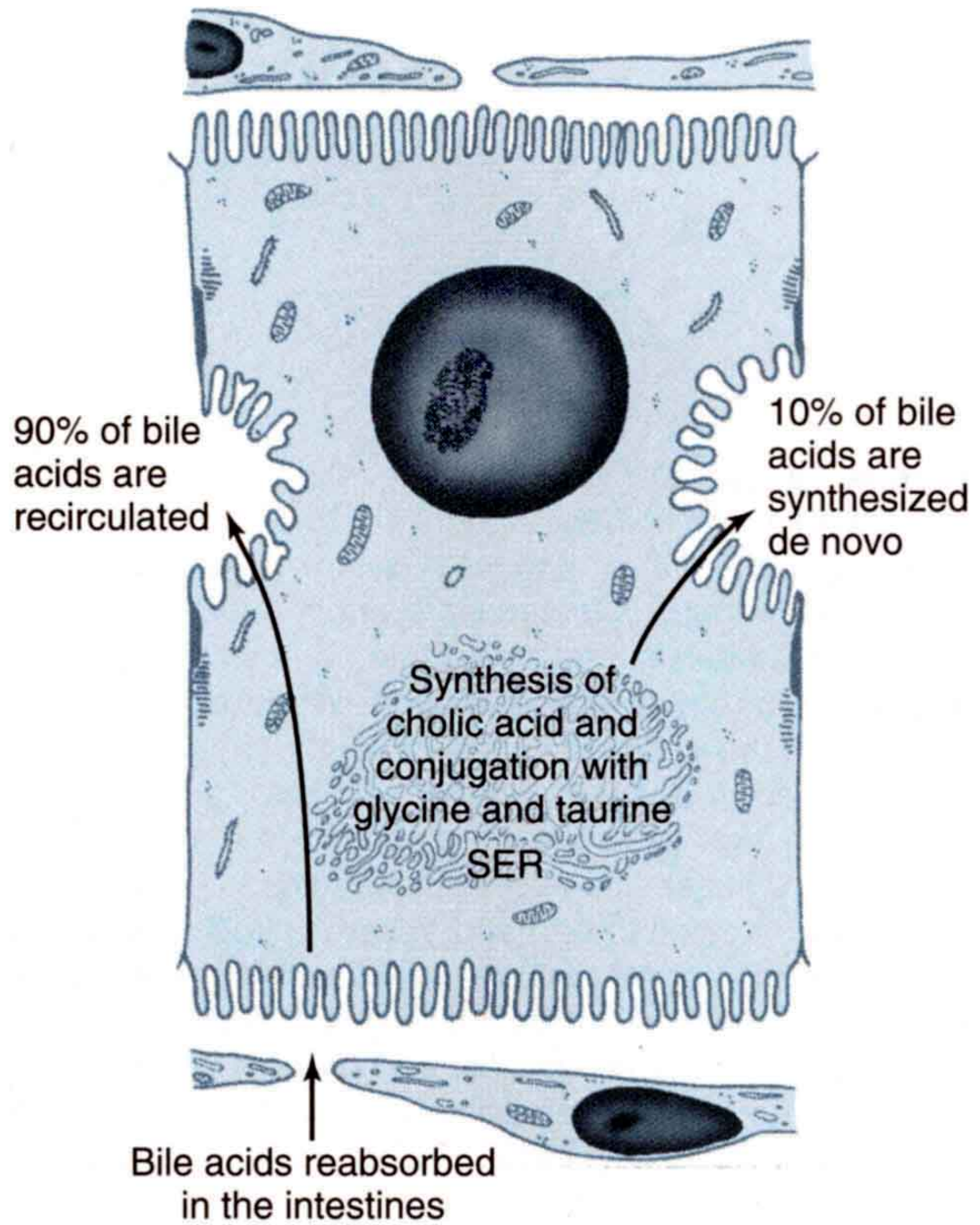






glykogen (Bestüv karmín)





90% of bile acids are recirculated

10% of bile acids are synthesized de novo

Synthesis of cholic acid and conjugation with glycine and taurine
SER

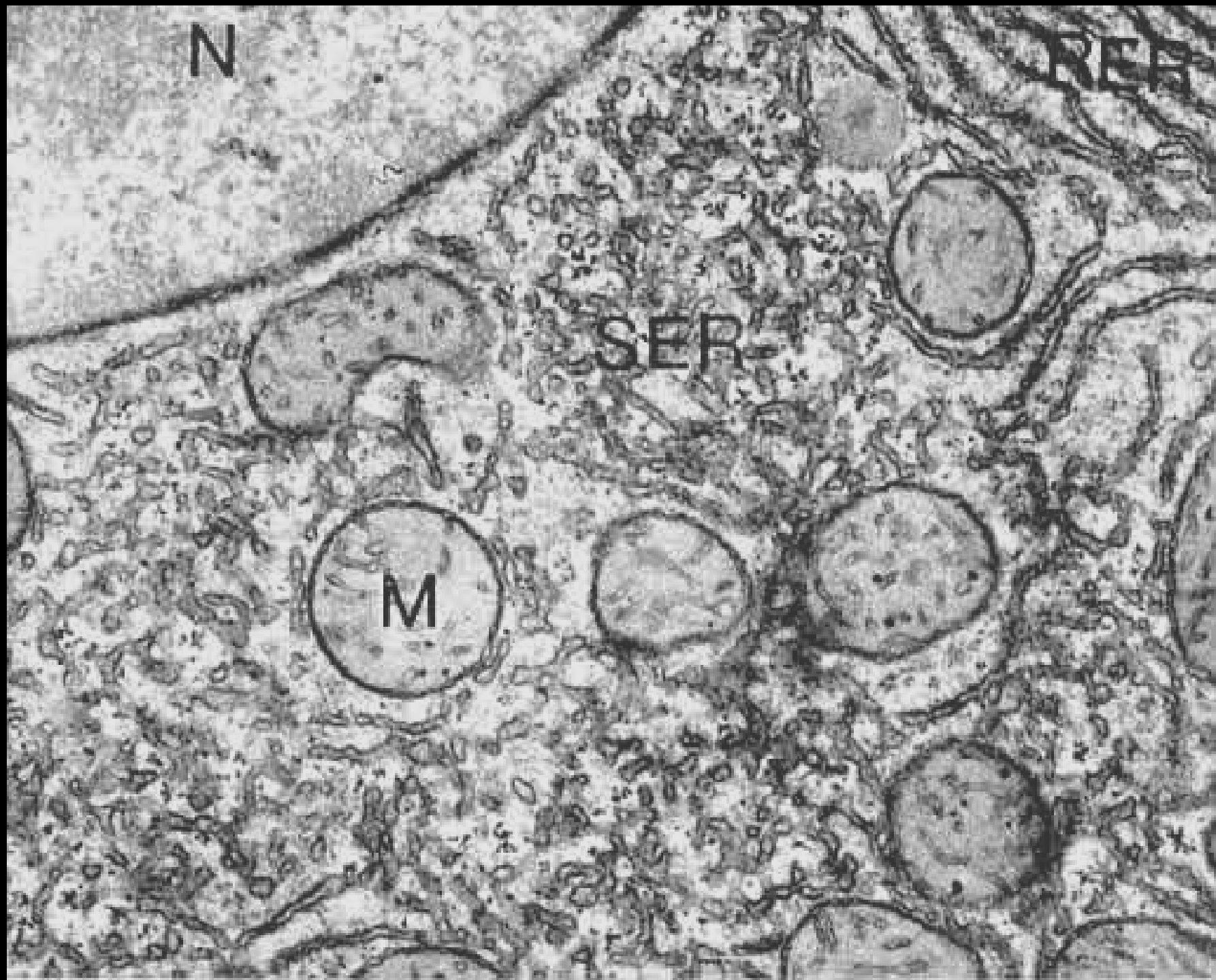
Bile acids reabsorbed in the intestines

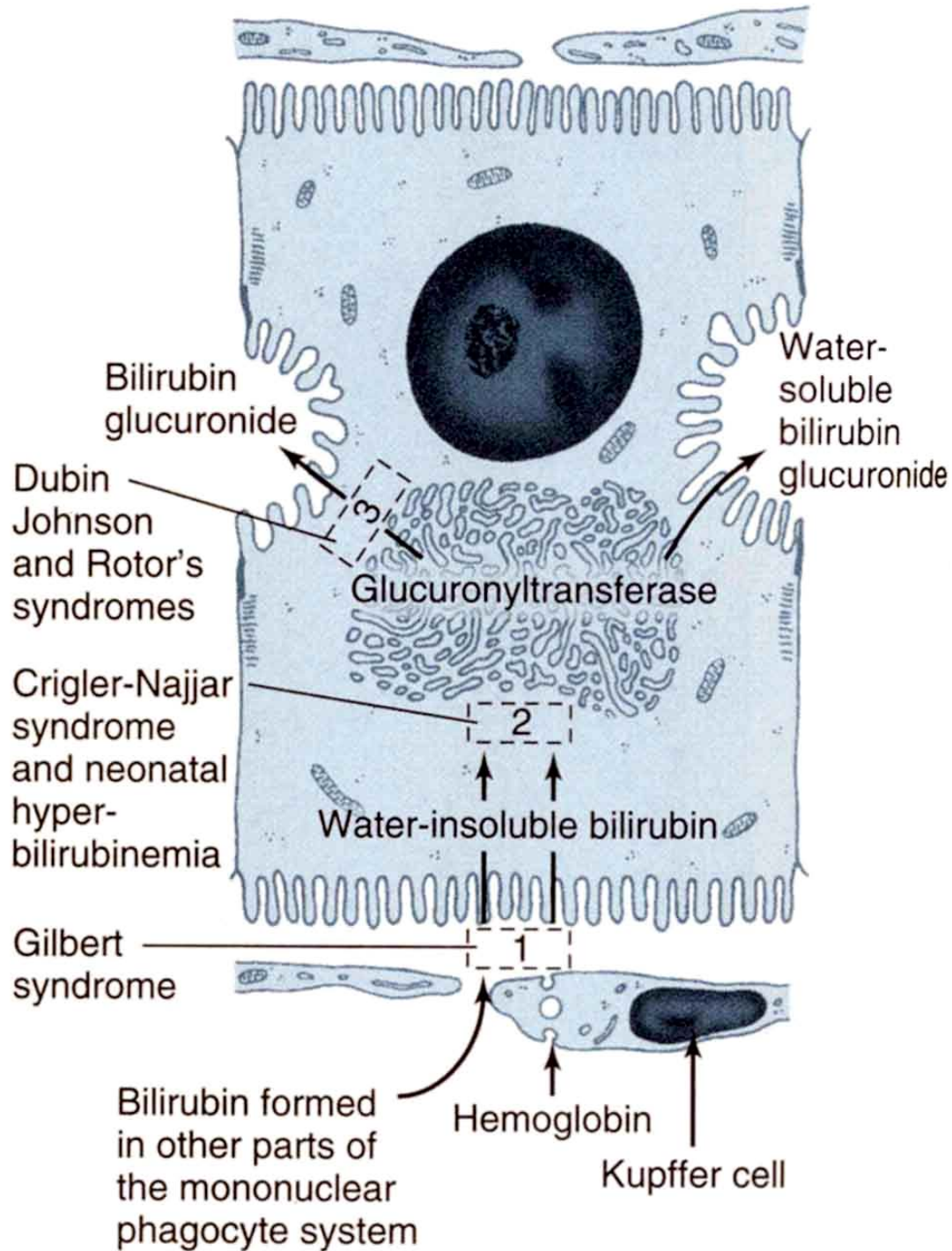
N

RET

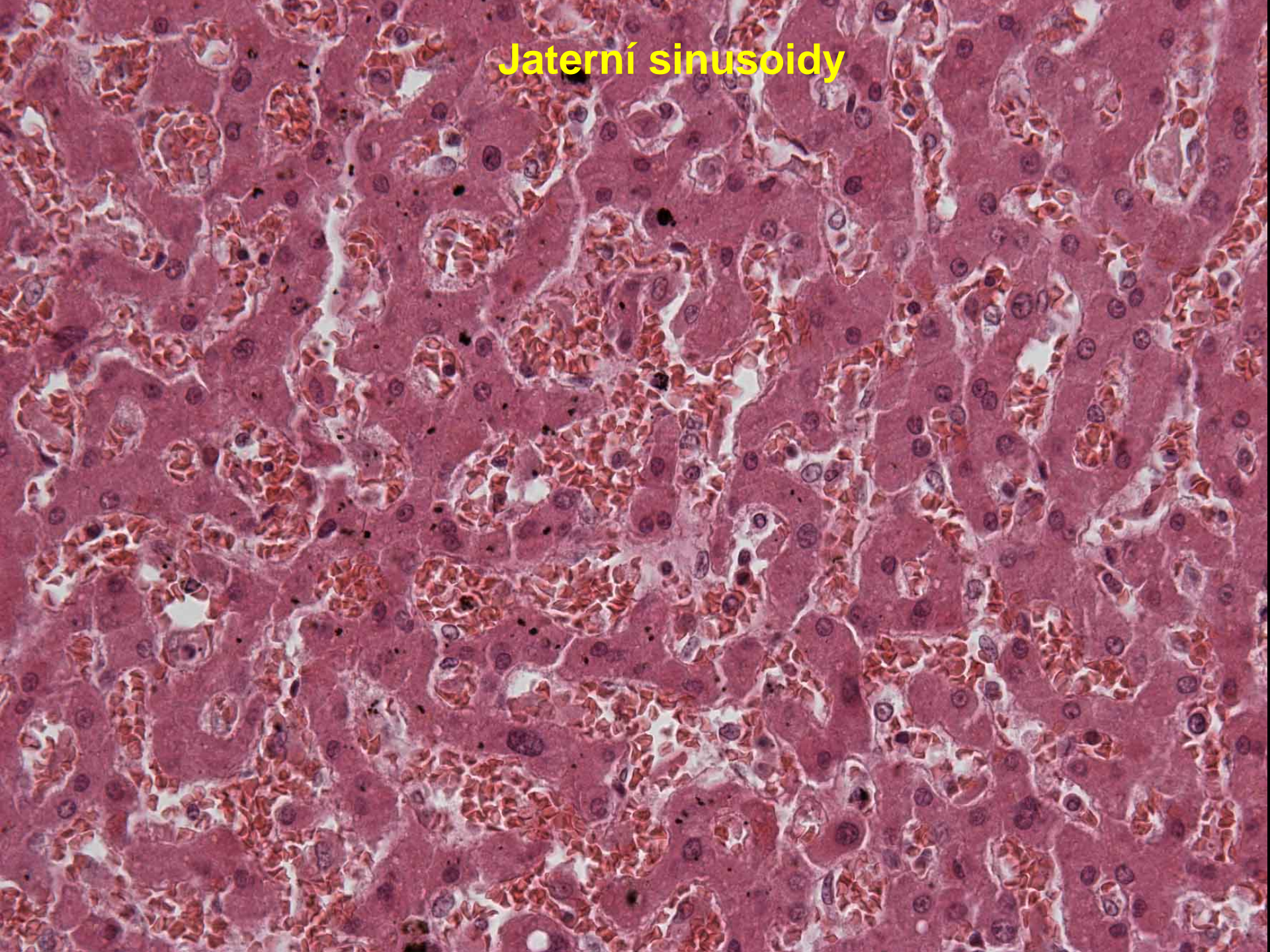
SER

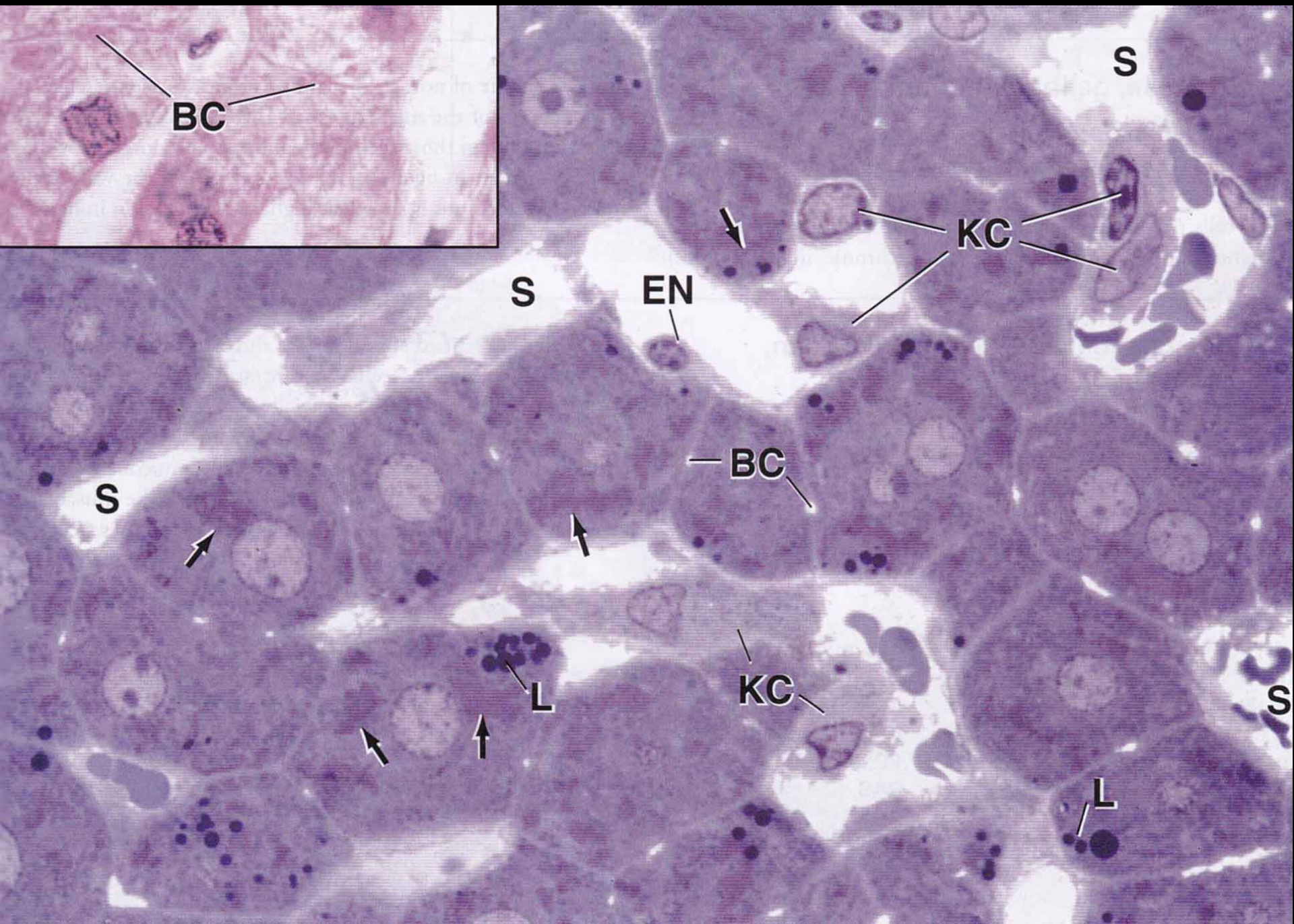
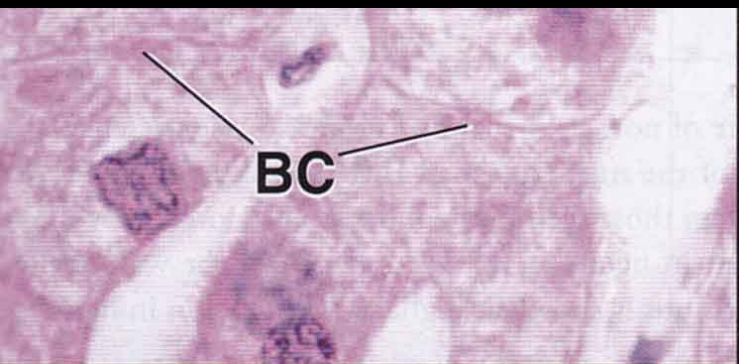
M

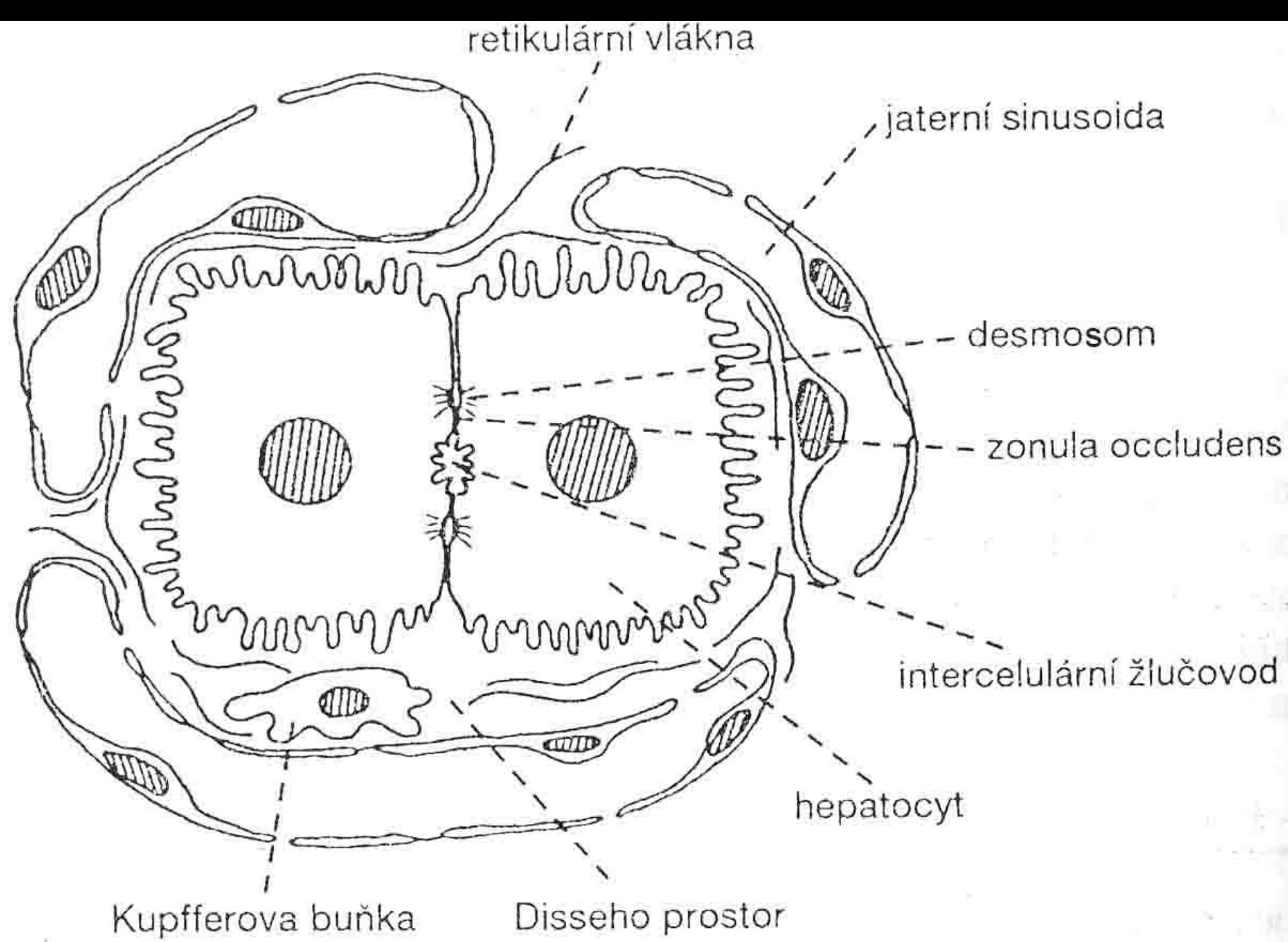


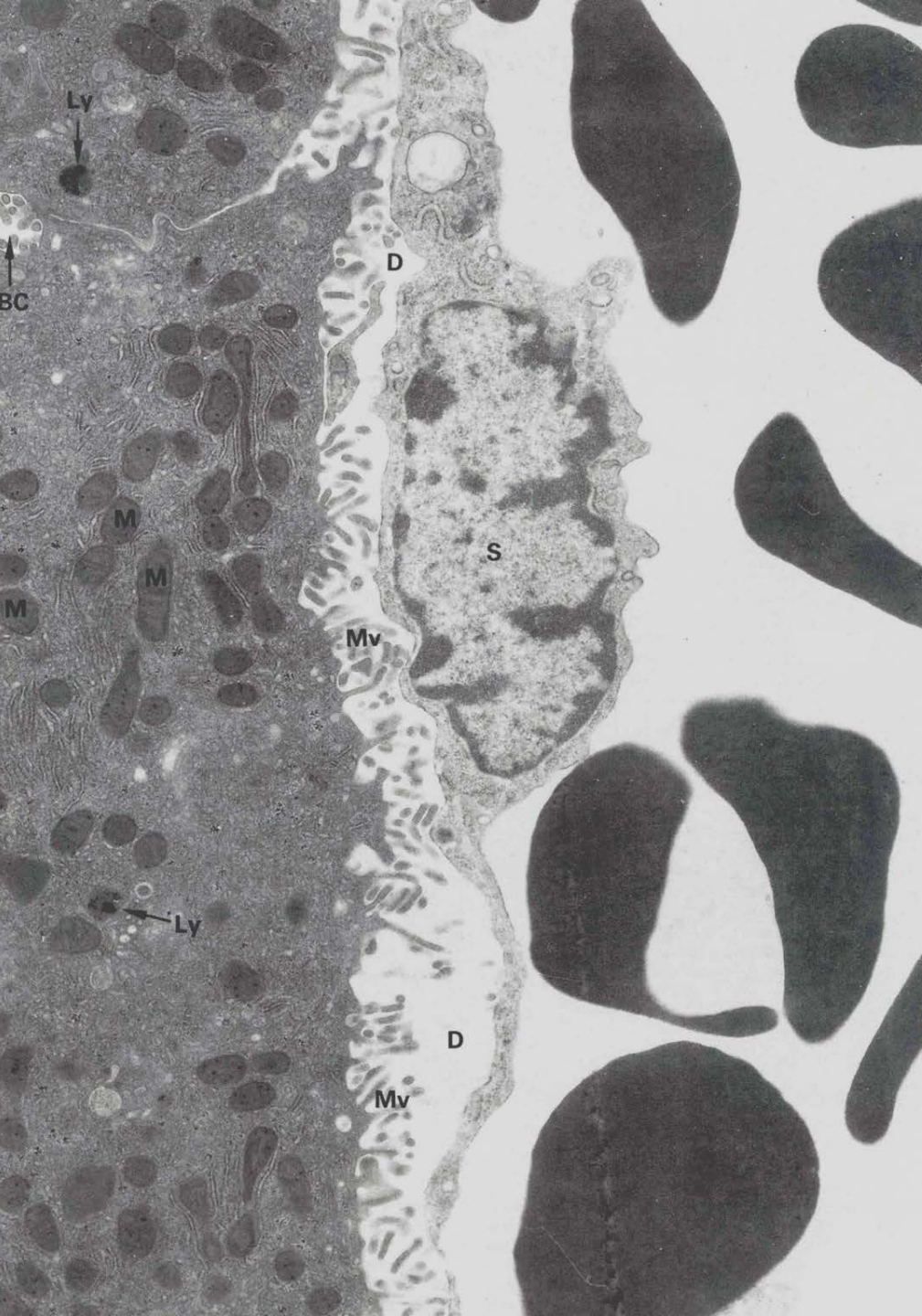
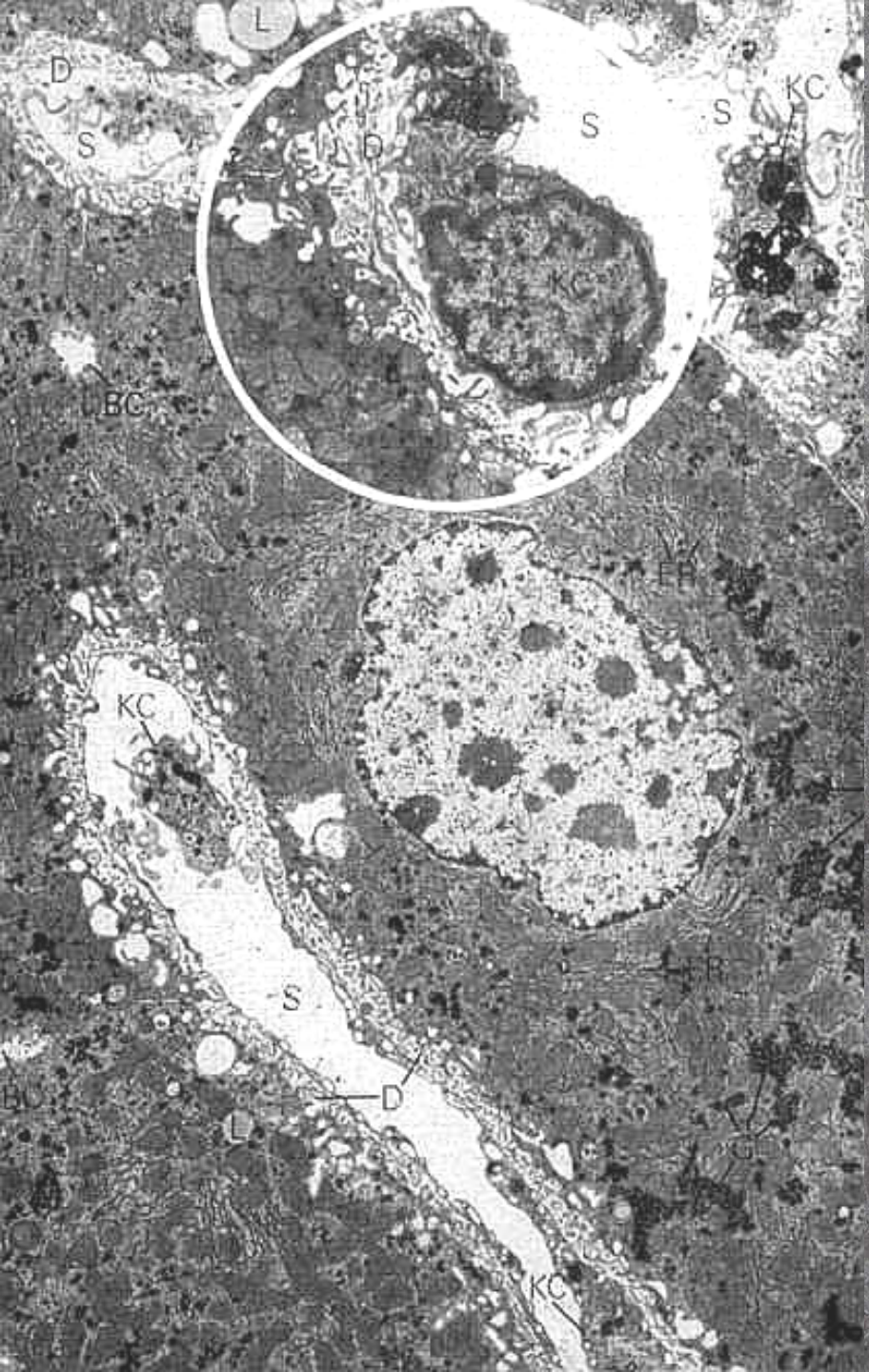

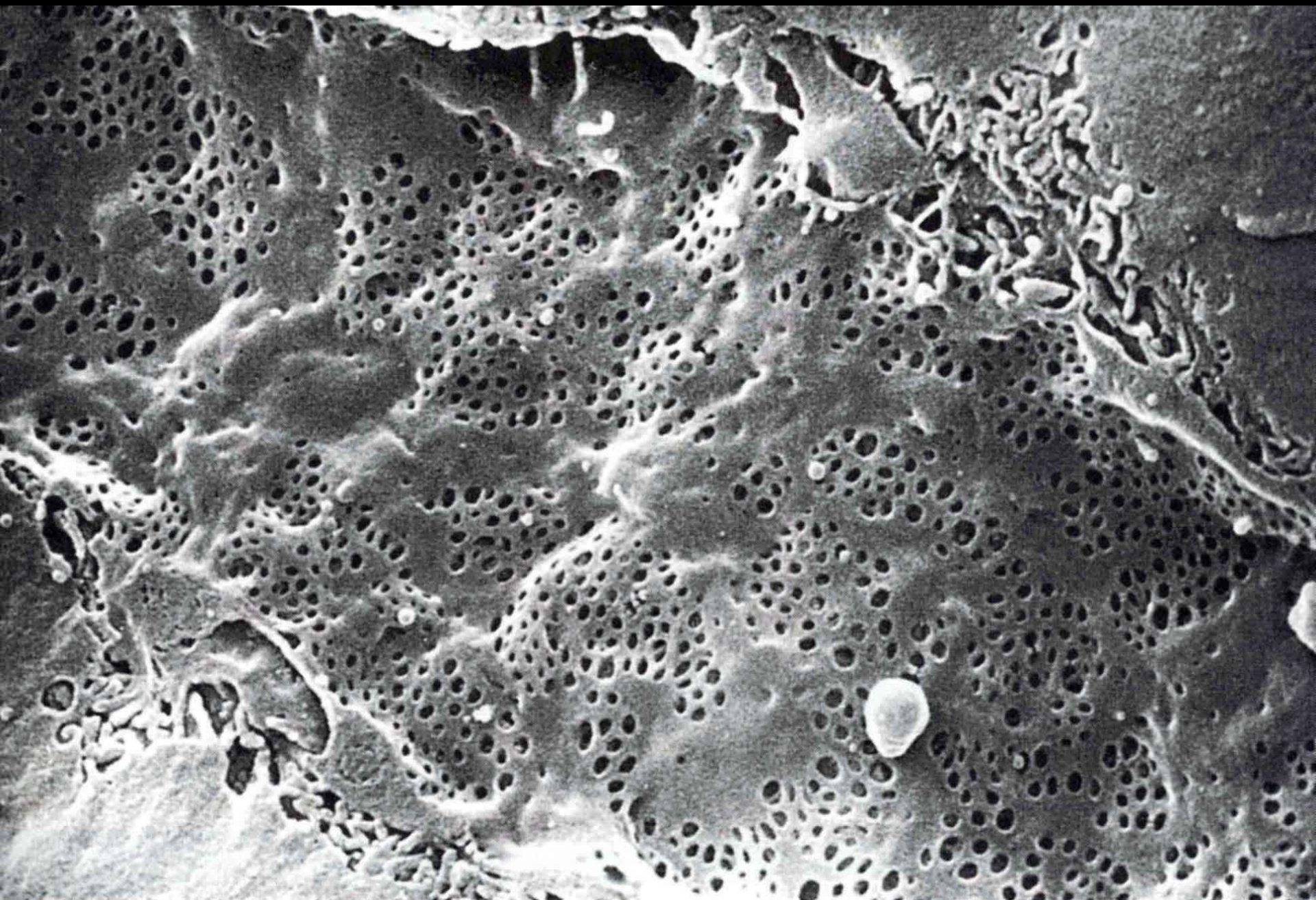
Jaterní sinusoidy



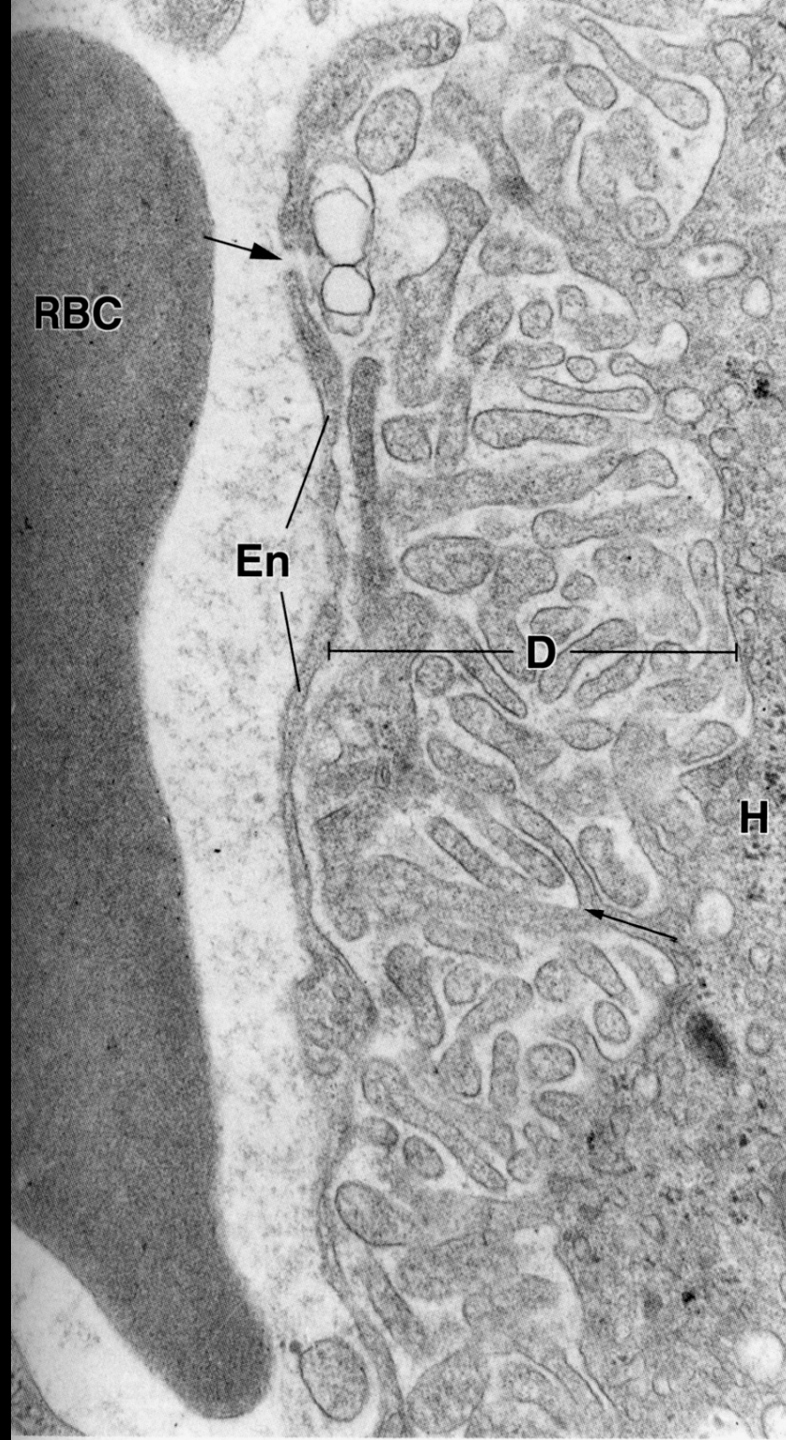




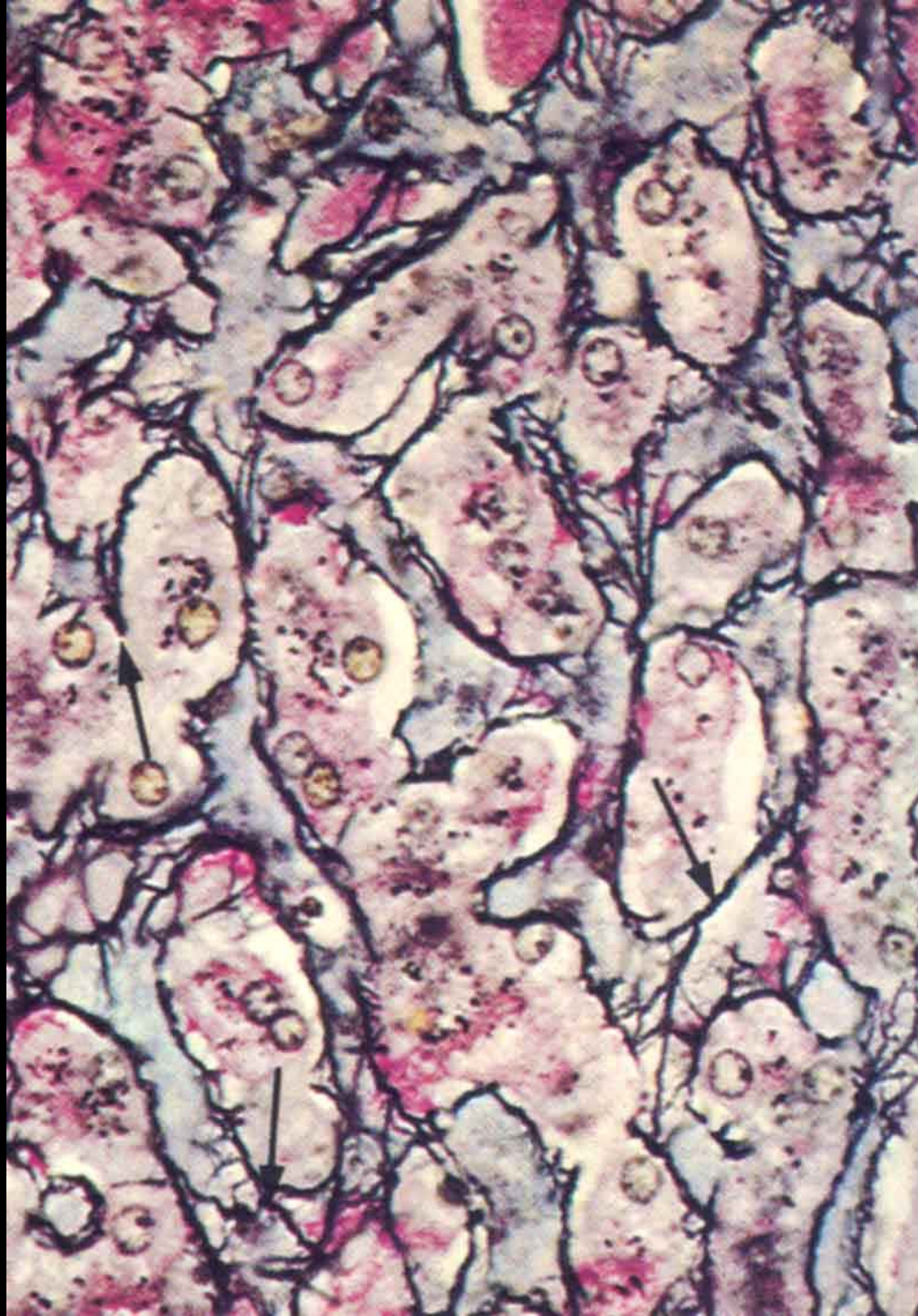




Disseho prostor

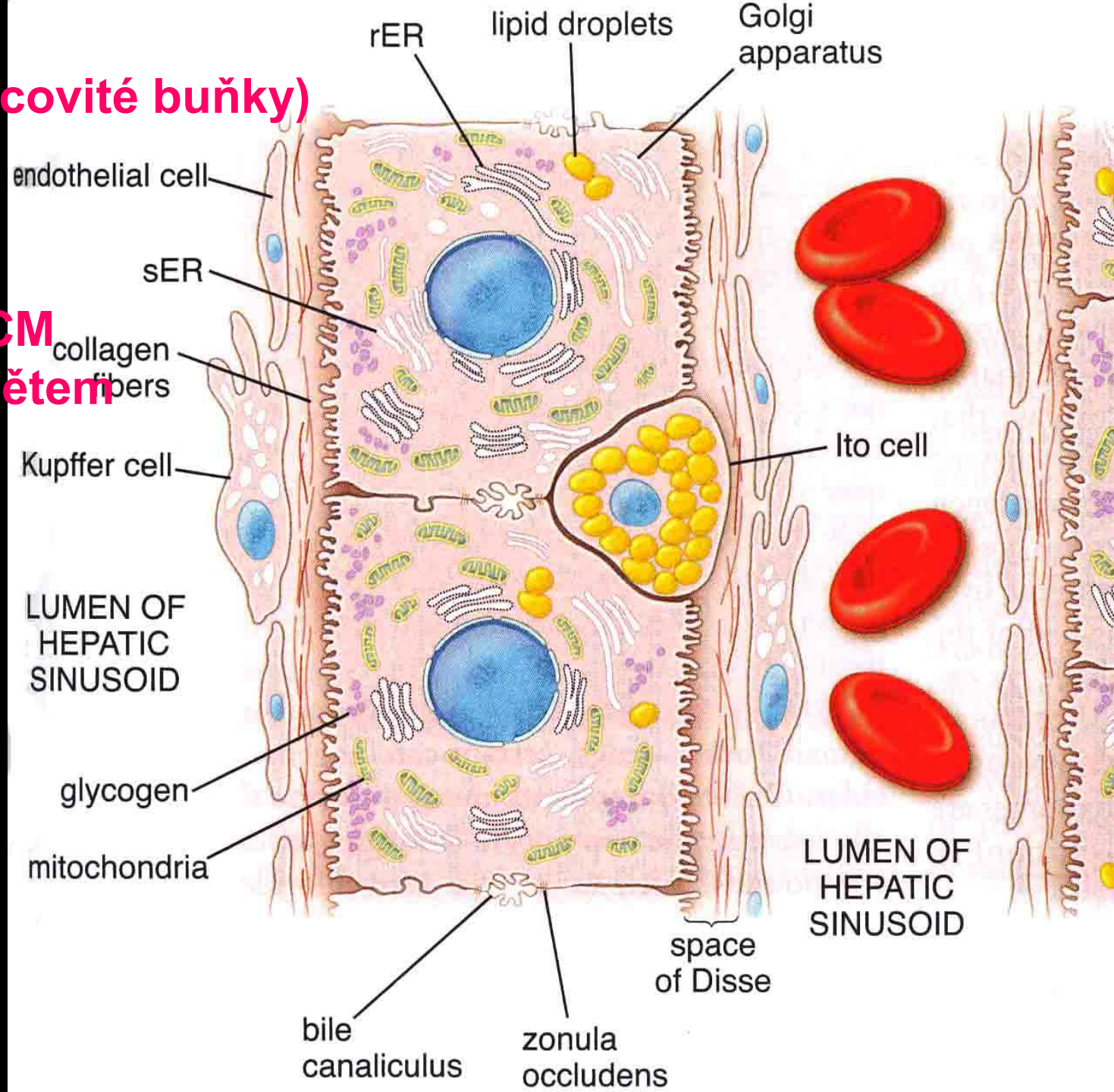


**impregnace
retikulárních
vláken**

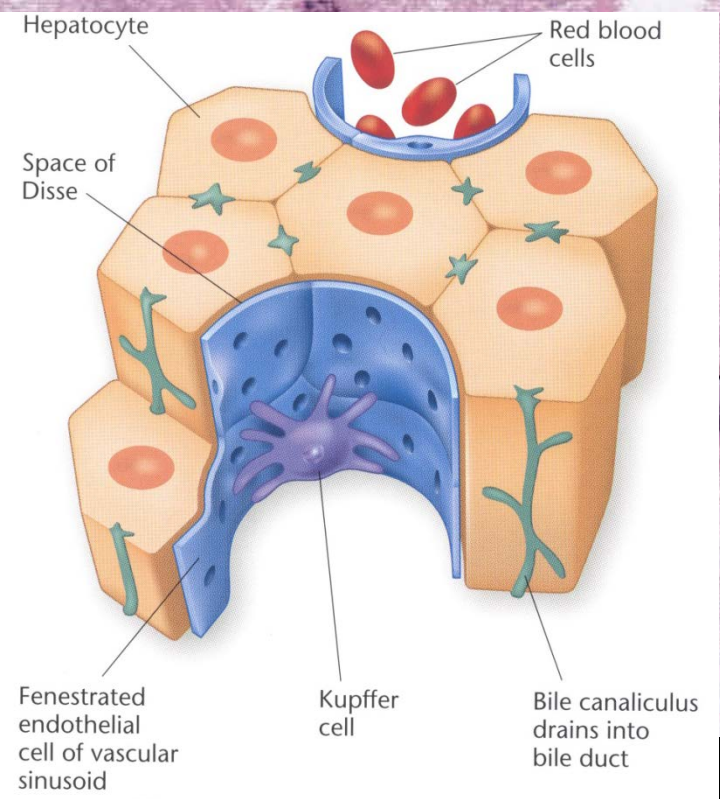
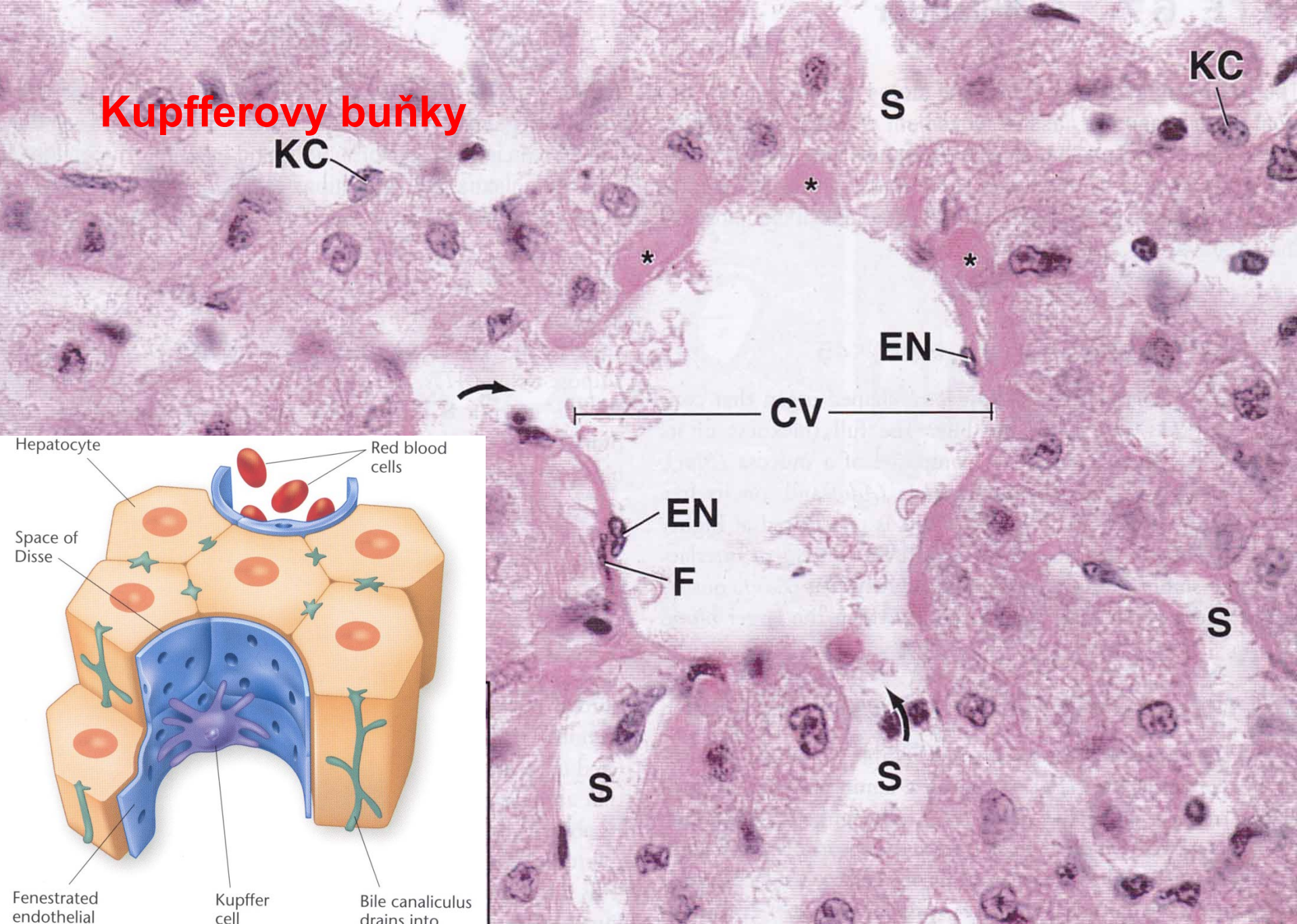


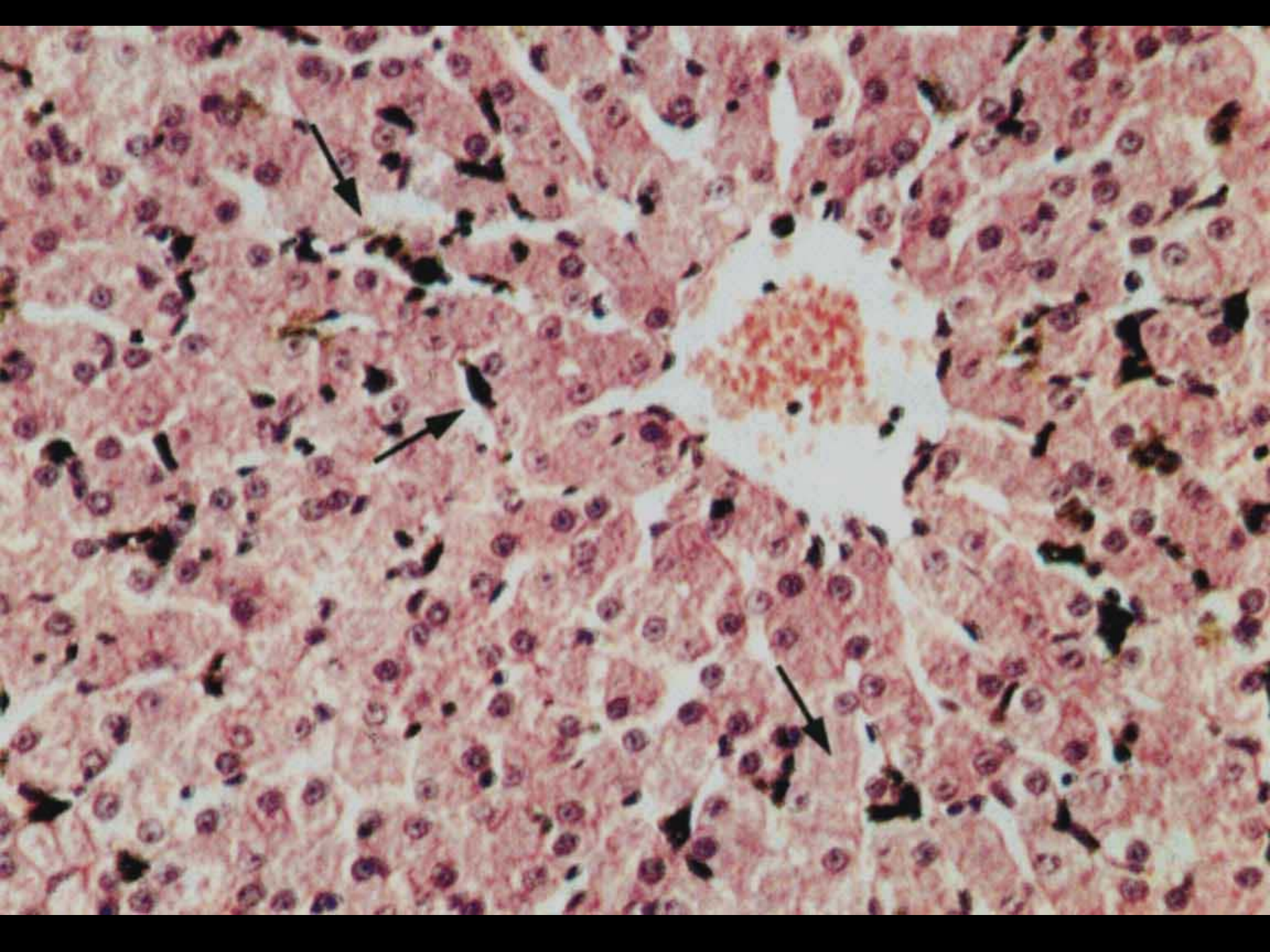
Itovy buňky (jaterní hvězdčovitě buňky)

- vitamin A
- lipidy
- kontraktilita
- produkce ECM
- aktivace zánětem



Kupfferovy buňky





Játra – funkce

- syntéza proteinů (kontinuálně uvolňovány do krve)
 - albumin, fibrinogen, protrombin, transferrin, lipoproteiny,...
- sekrece žluči
 - voda, ionty, žlučové kyseliny, fosfolipidy, cholesterol, bilirubin
- metabolické funkce
 - střádání metabolitů: triacylglyceroly, glykogen, vitamín A
 - glukoneogeneze, glykogenolýza, deaminace AK
 - detoxikace: oxidace, metylace, konjugace
- tvorba tepla
- krvetvorba – za vývoje

Žlučové cesty, žlučník

Nitrojaterní (intrahepatální) žlučové cesty

intercelulární žlučovody (*canaliculi biliferi*,
žlučové vlásečnice)

– nemají vlastní stěnu (průsvit 0,5 μm)

→ intralobulární žlučovody (Heringovy
kanálky; *canales (ductuli) biliferi*)

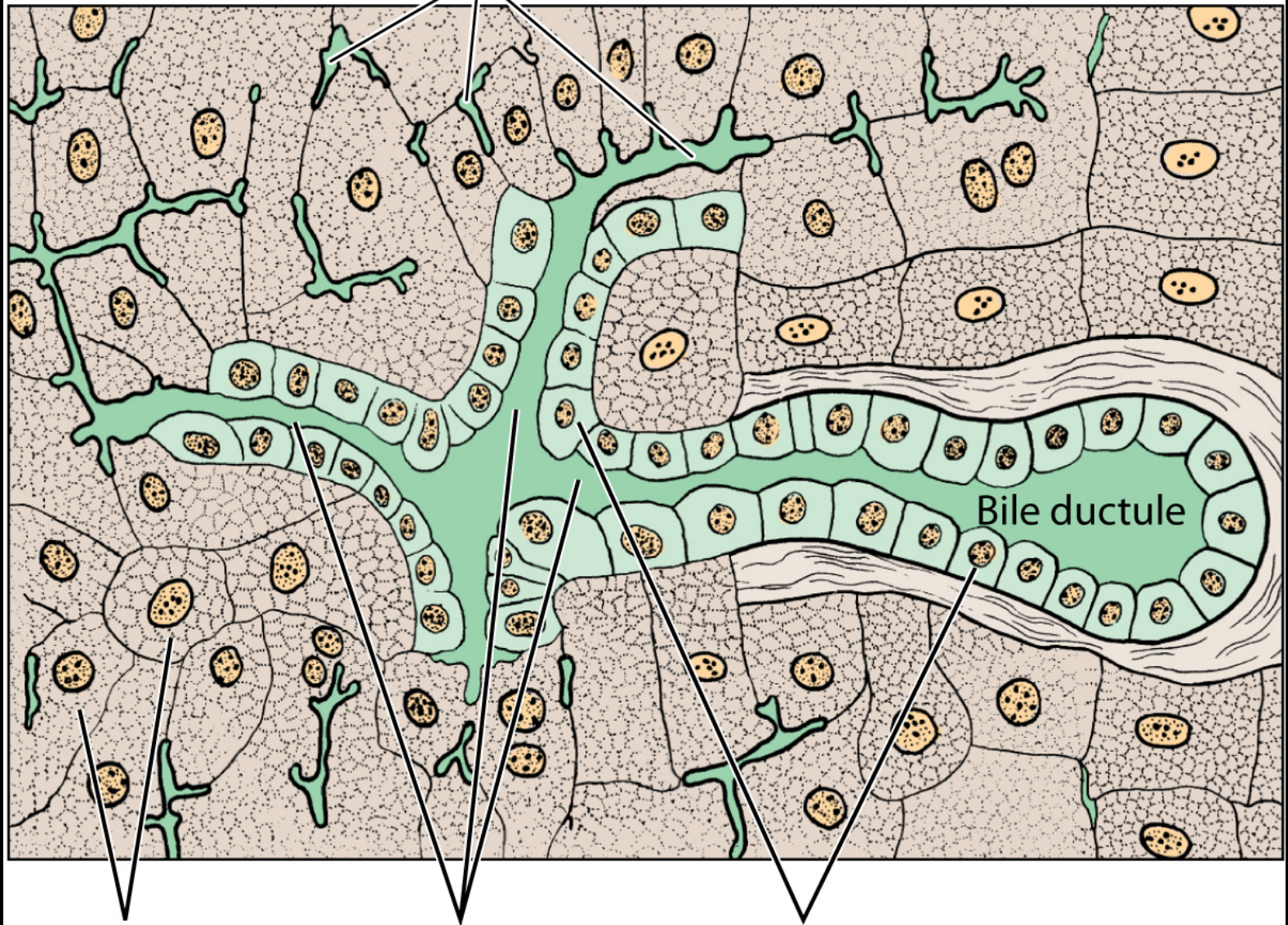– stěnu tvoří hepatocyty a cholangiocyty

→ interlobulární žlučovody (*ductus biliferi
interlobulares*) – v portální triádě

– cholangiocyty, zvenku vazivová pochva

→ **ductus hepaticus dx. et sin.**

Bile canaliculi

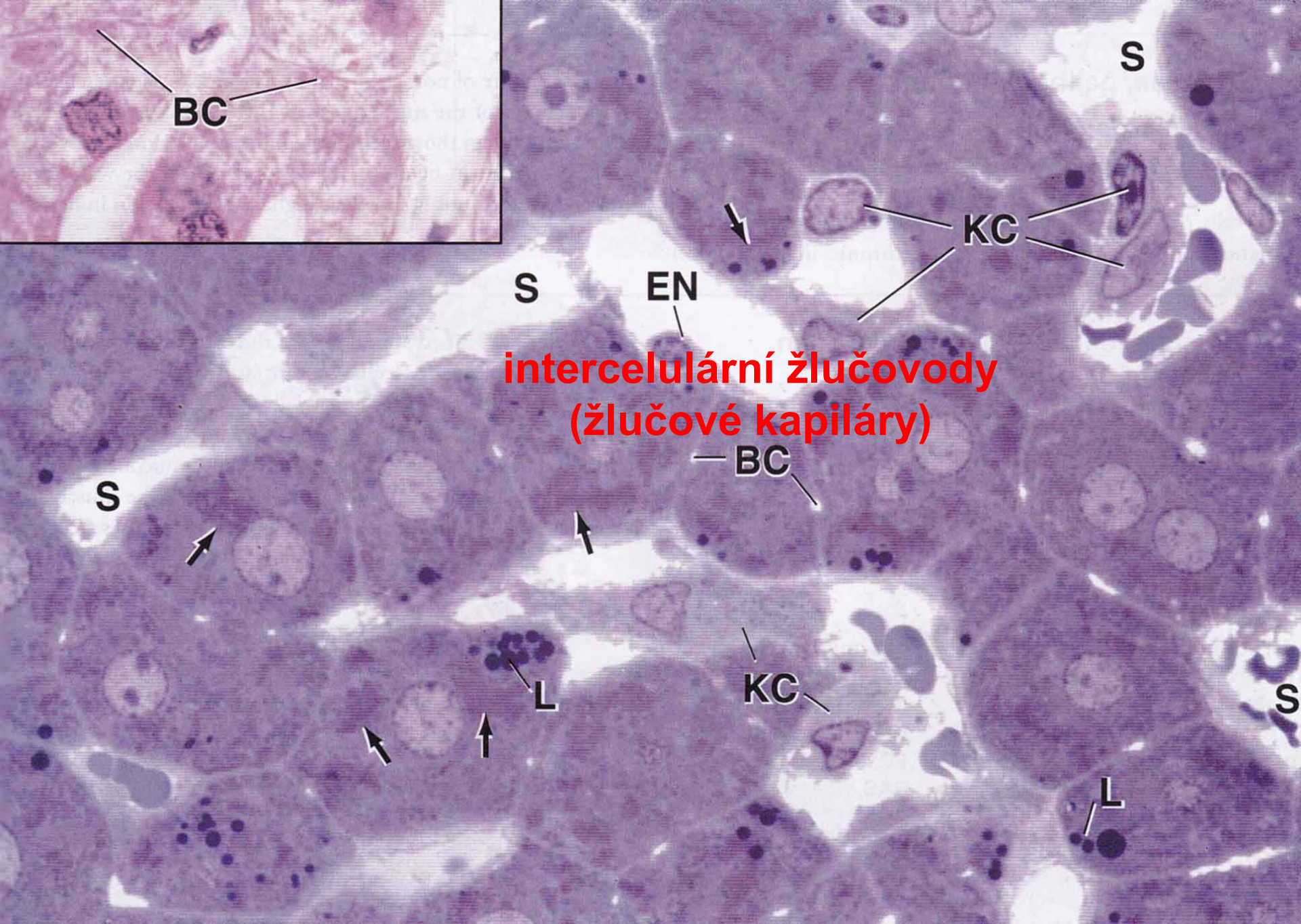
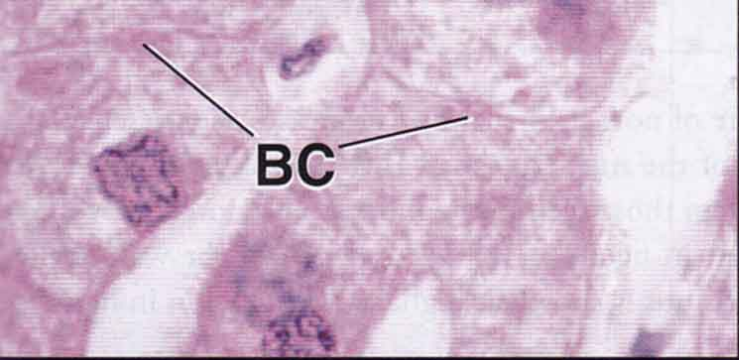


Bile ductule

Hepatocytes

Bile canals
of Hering

Cholangiocytes



BC

S

KC

EN

S

intercelulární žlučovody
(žlučové kapiláry)

BC

S

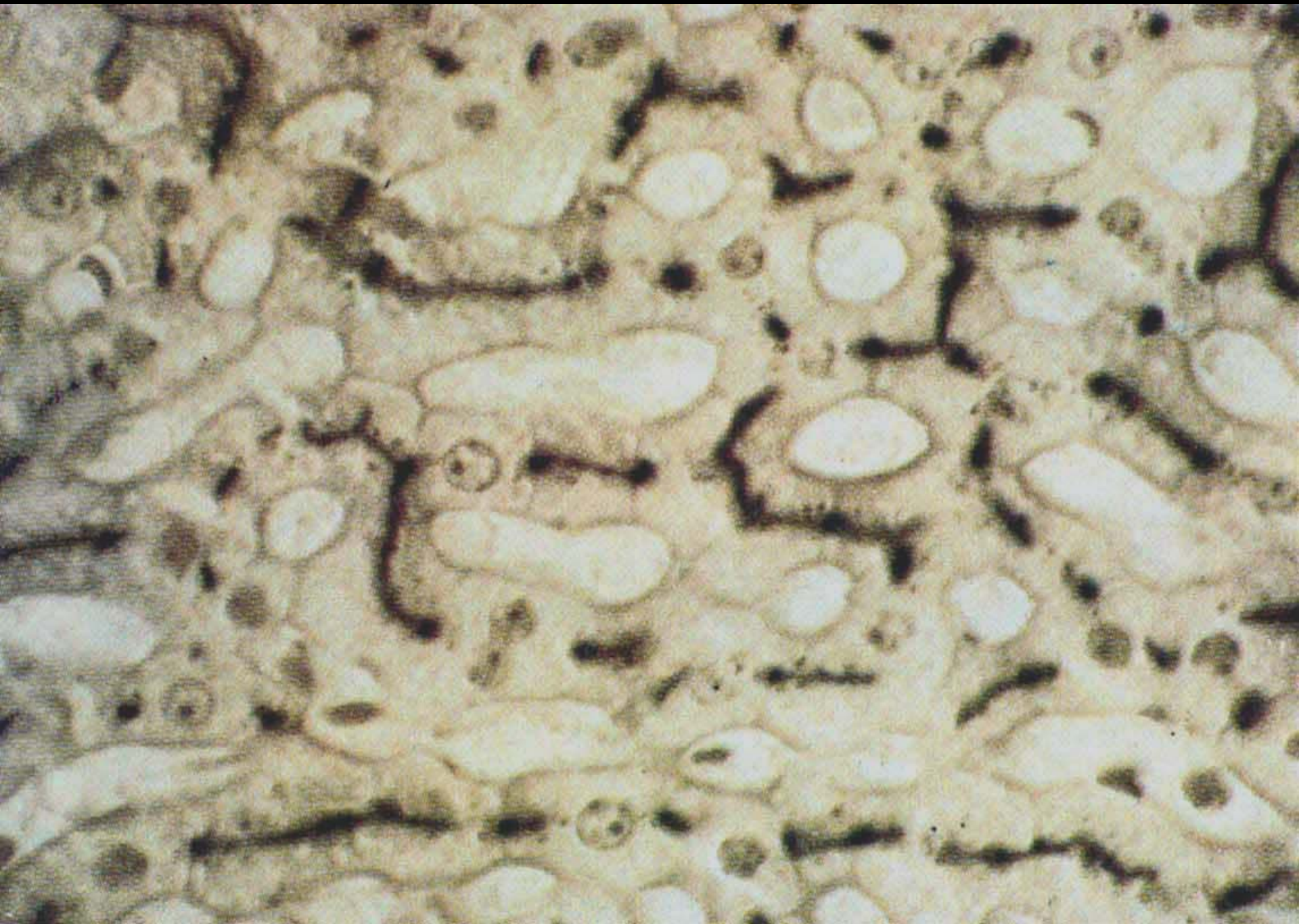
L

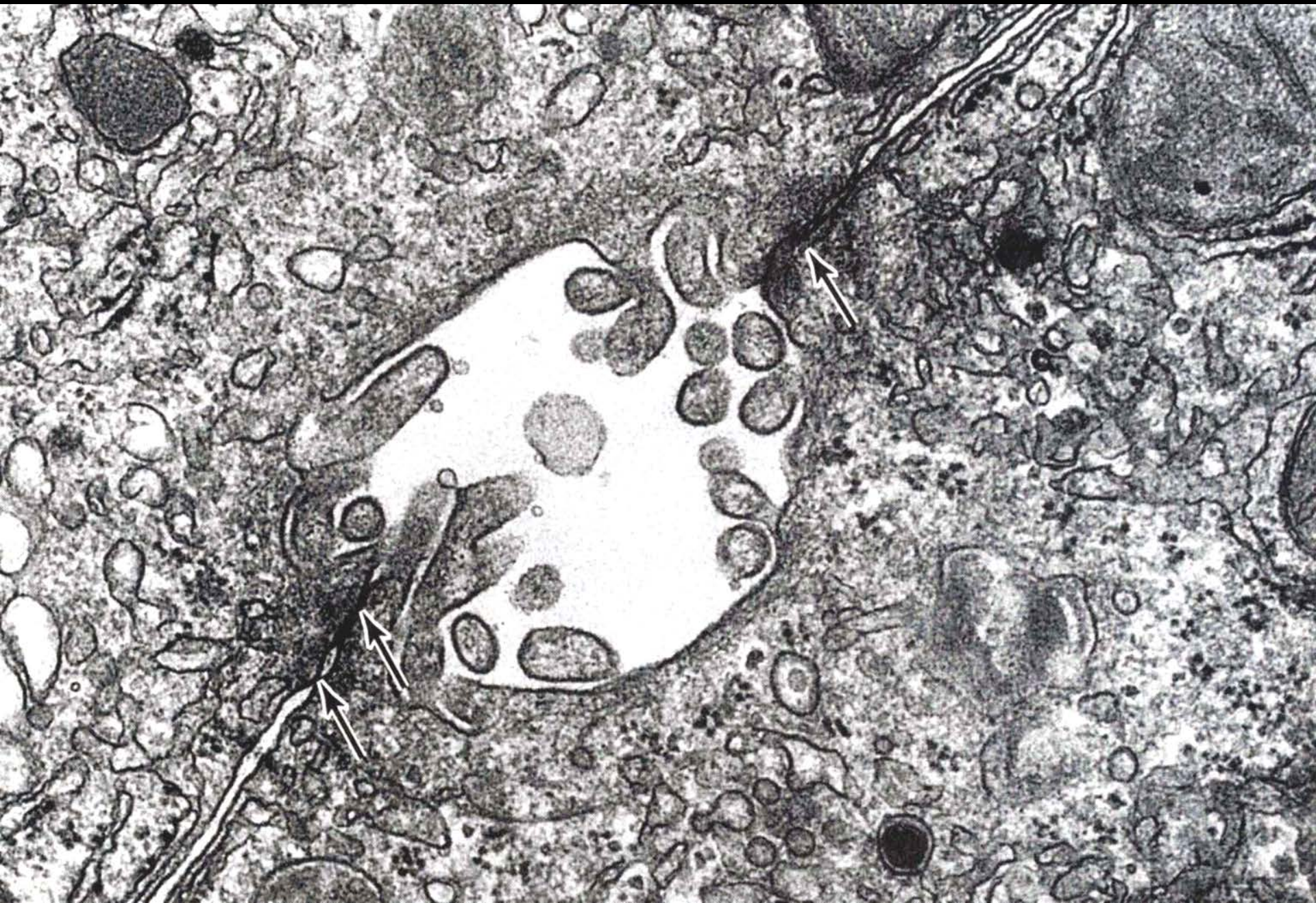
KC

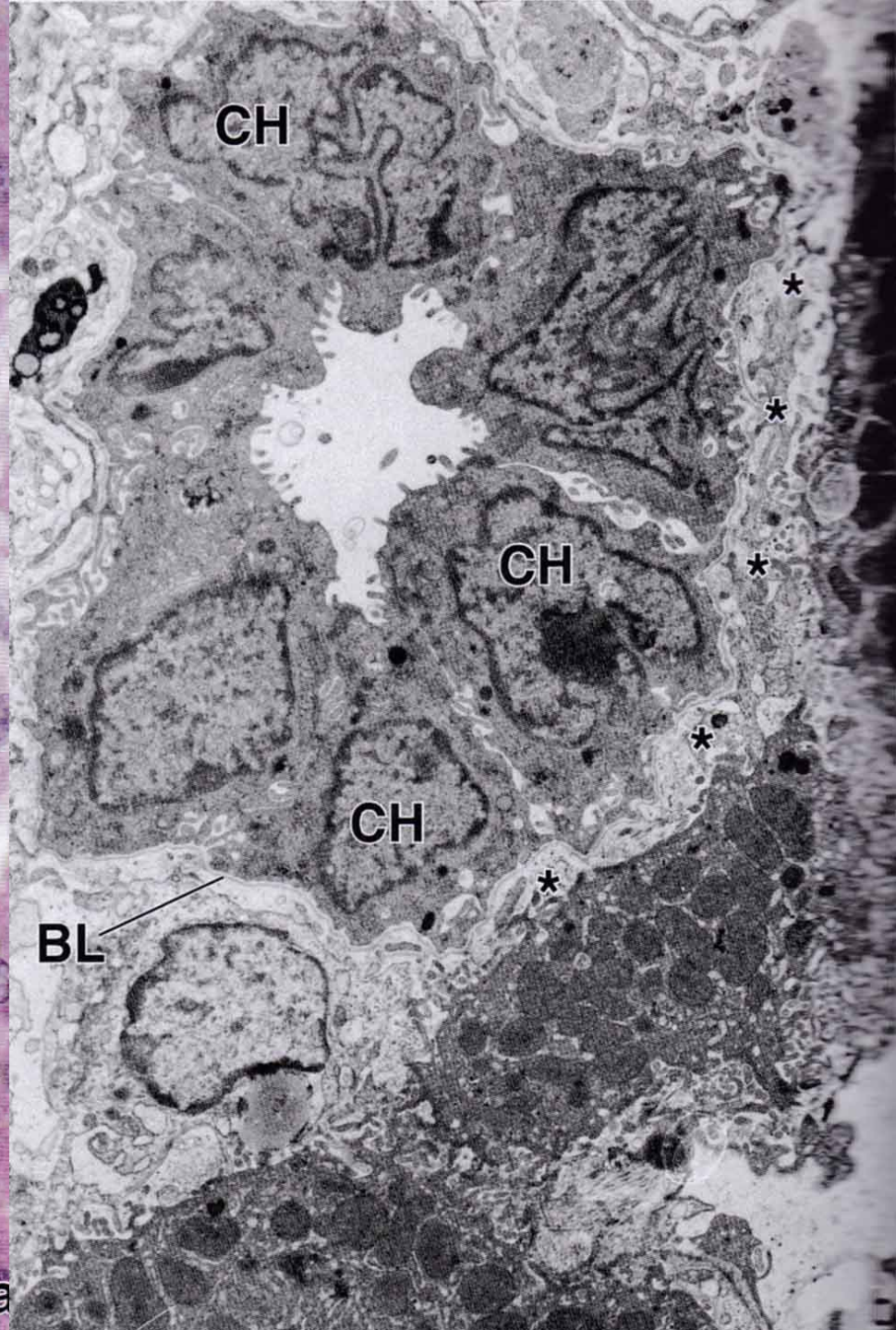
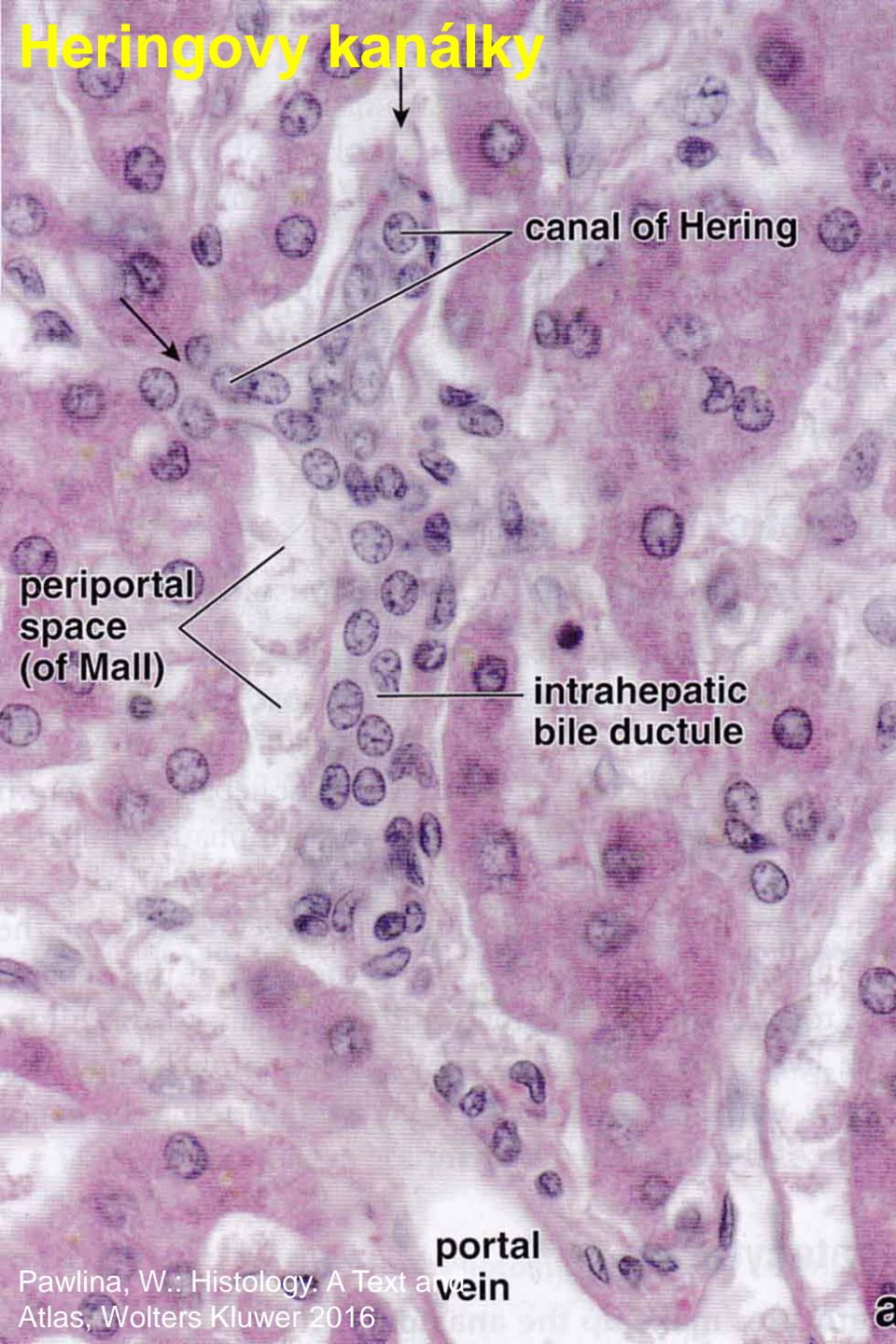
L

S

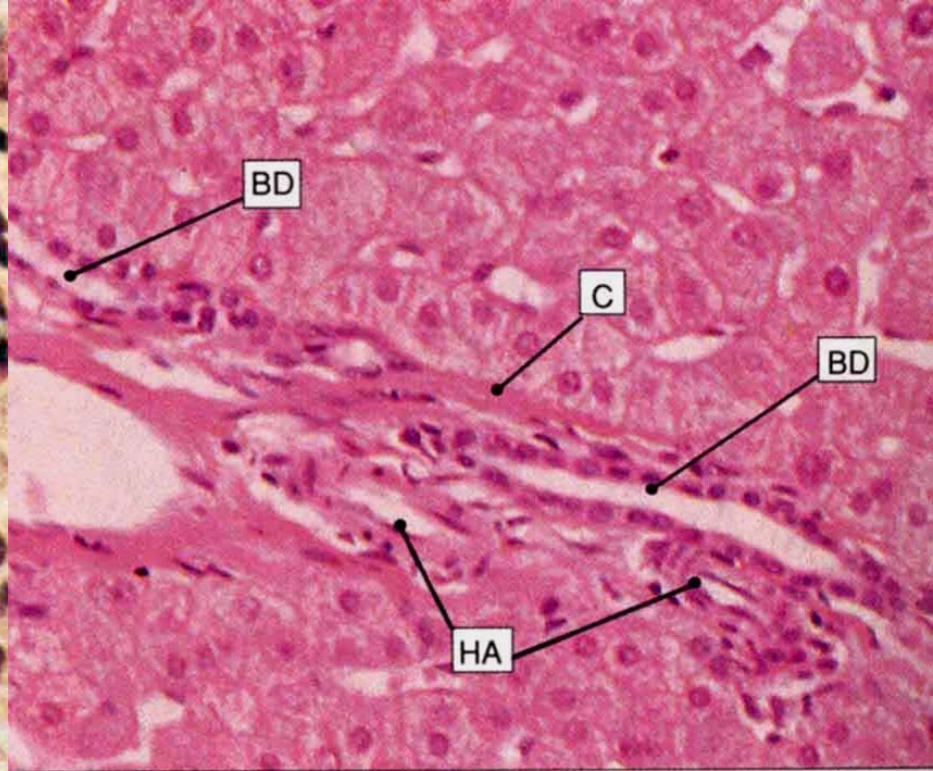
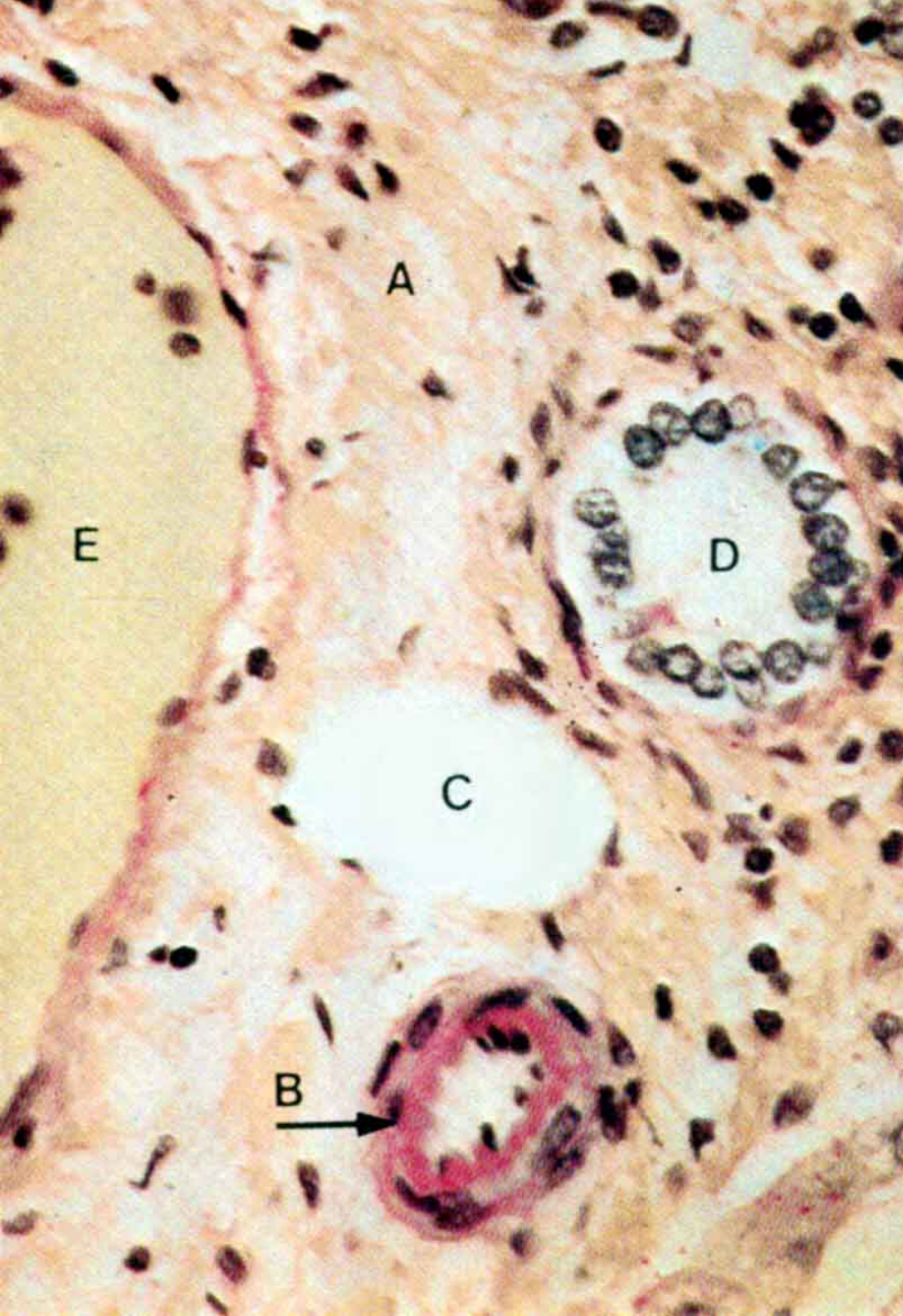
průkaz alkalické fosfatázy



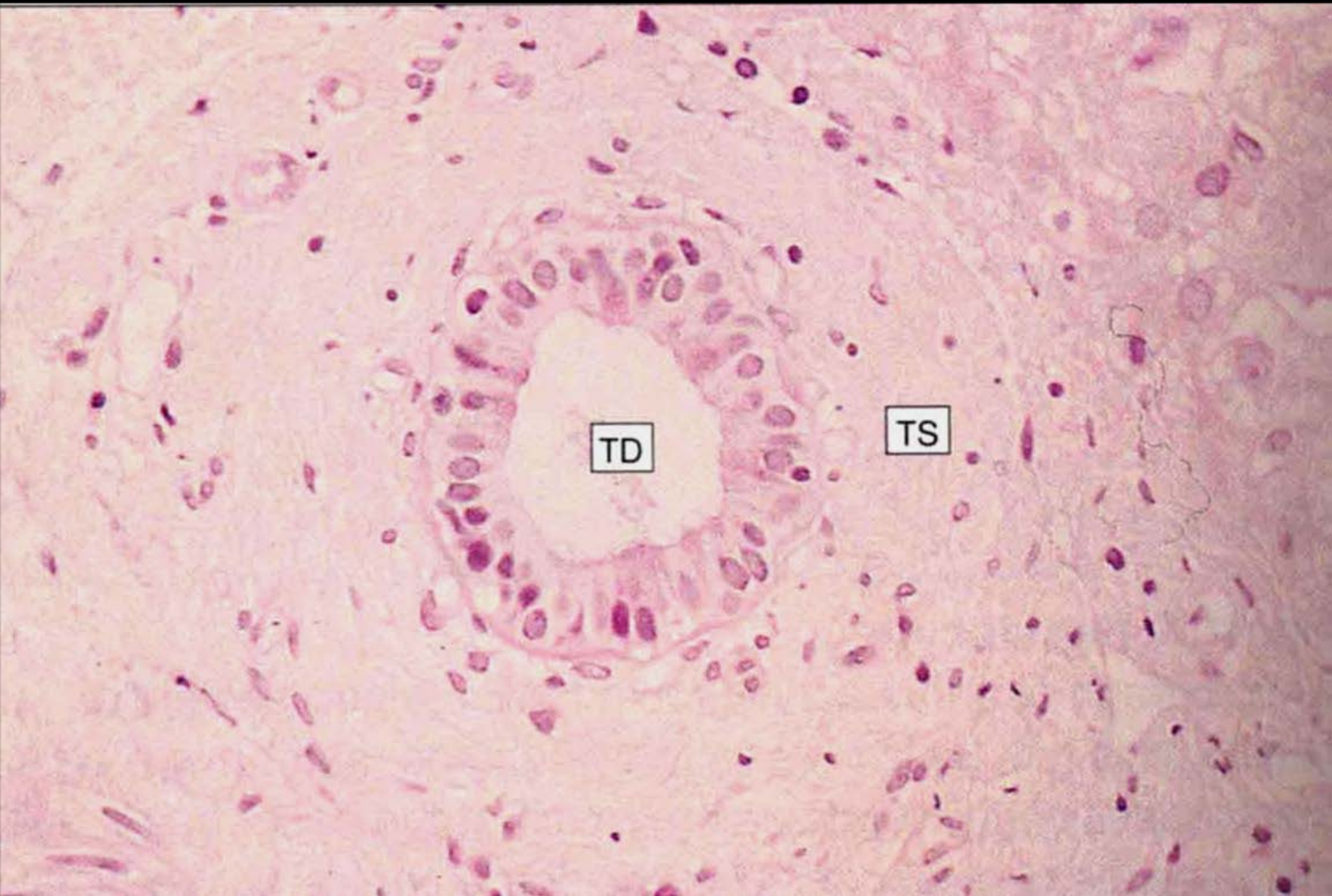



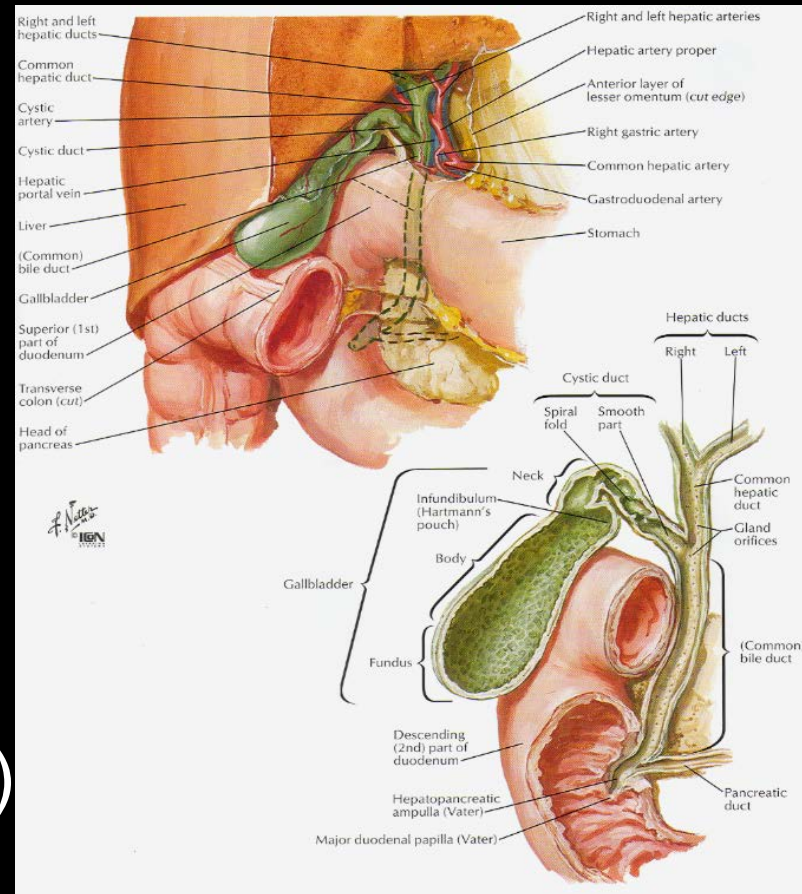
Interlobulární žlučovody



větší intrahepatální žlučovod



Mimojaterní (extrahepatální) žlučové cesty



nitrojaterní žlučové cesty

→ ductus hepaticus dx. et sin.
(přibírají vývod z lobus caudatus)

→ ductus hepaticus communis

po spojení s ductus cysticus → ductus choledochus (m.
sphincter ductus choledochi)

→ ampulla hepatopancreatica (m. sphincter ampullae
Oddi) → dvanáctník (na papilla duodeni major Vateri)

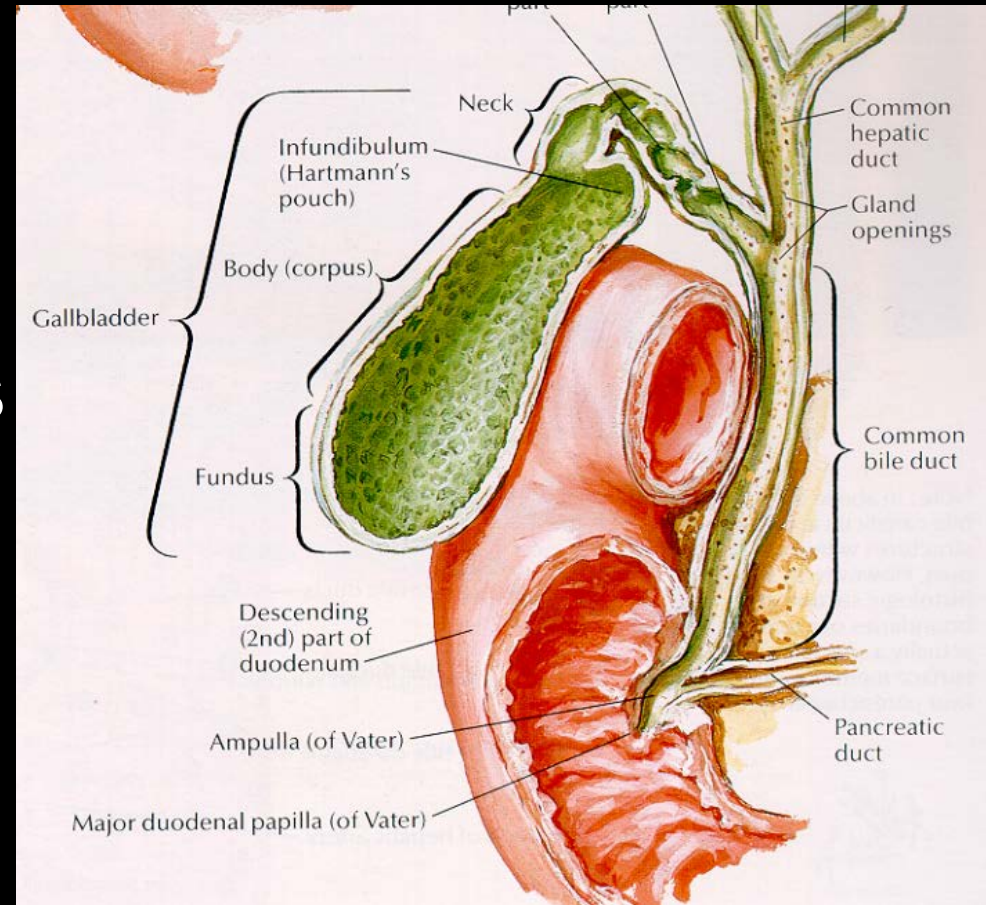
Mimojaterní žlučové cesty – stavba

- jednovrstevný cylindrický epitel
 - cholangiocyty
 - roztroušené pohárkové buňky
- glandulae ductus choledochi – mucinózní
- stěna tvořena zejména vazivem
- chybí spojitá vrstva svaloviny

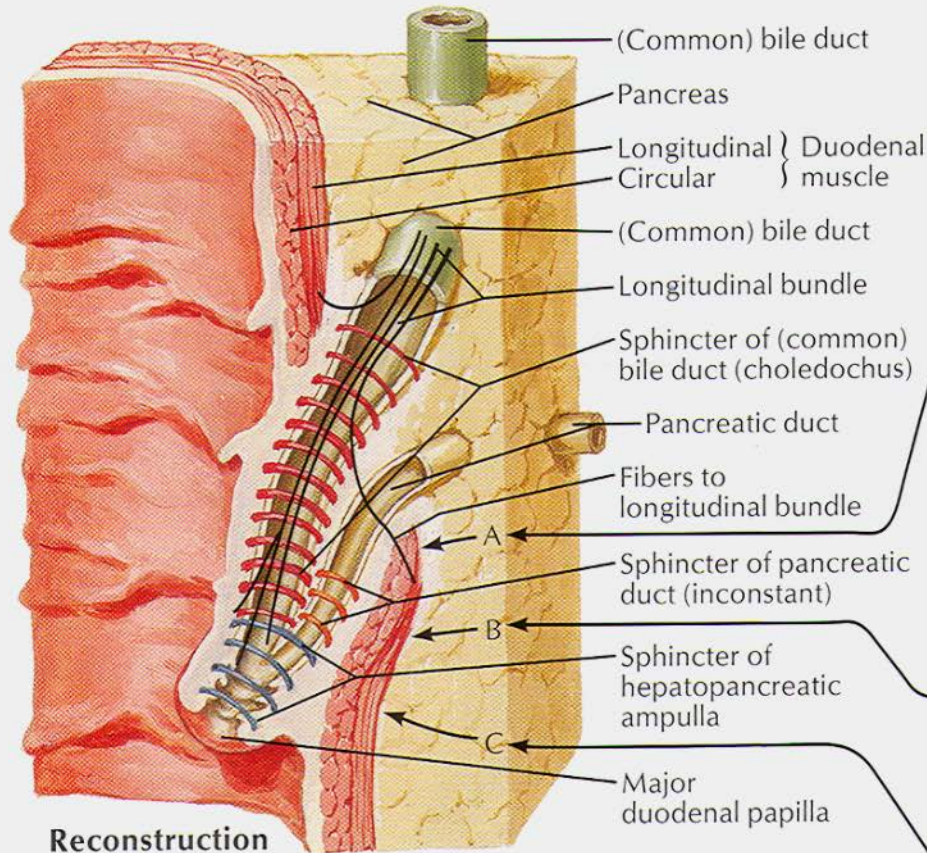
- *tenká stěna snadno utlačitelná zvenku → žloutenka (ikterus)*

Ductus choledochus – žlučovod

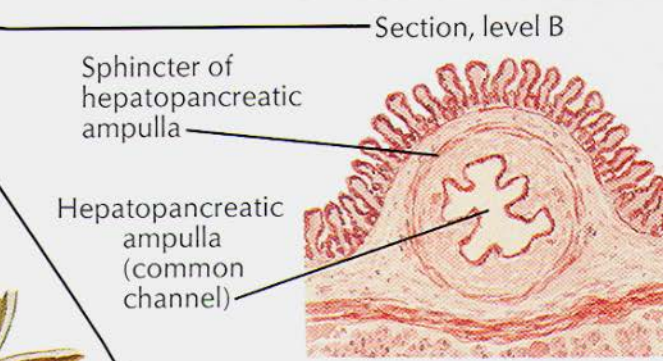
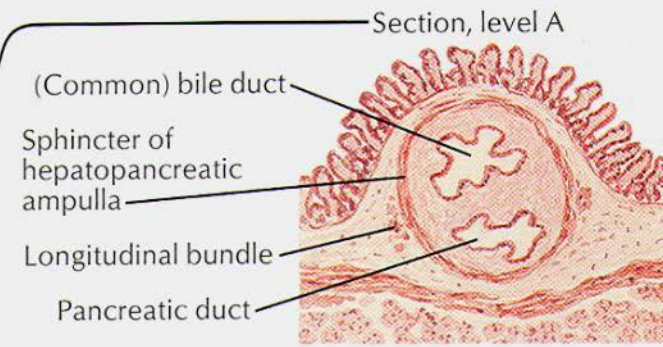
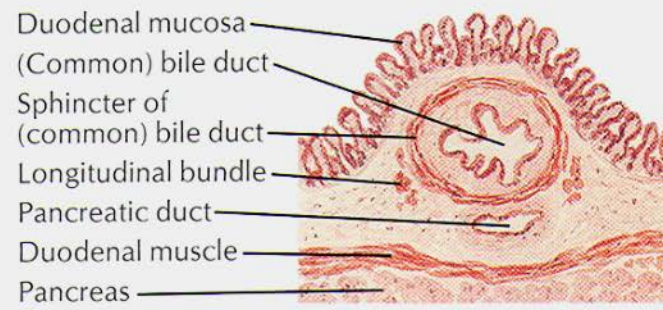
- 6–9 cm dlouhý
- 8–9 mm široký
- pars supraduodenalis
- pars retroduodenalis
- pars pancreatica
- pars intramuralis
- ampulla
hepatopancreatica (77 %)



Žluč = fel, bilis, cholé

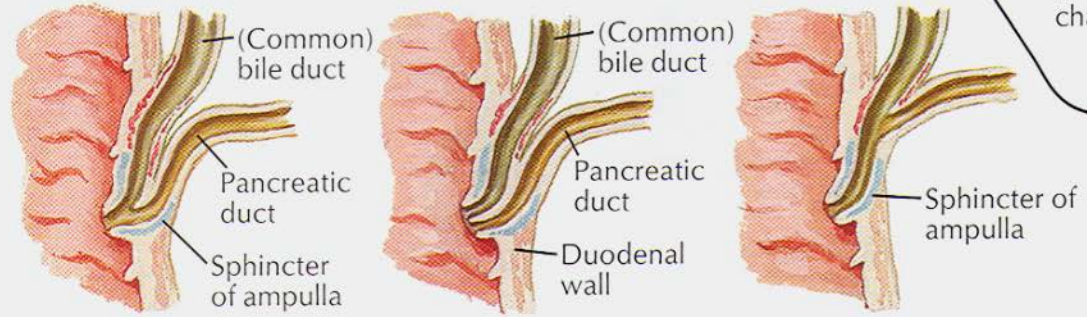


Reconstruction



Section, level C

Variations in union of bile and pancreatic ducts



Short common channel

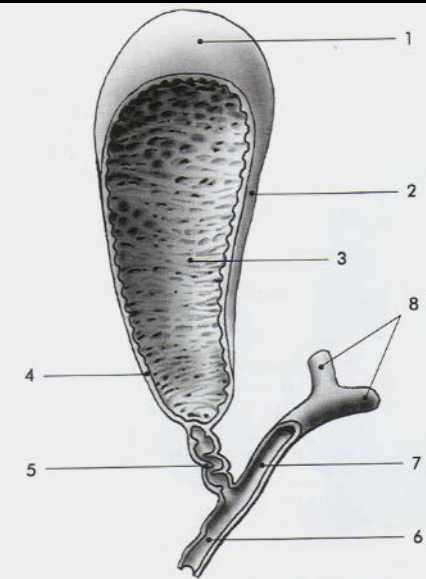
No common channel

Long common channel

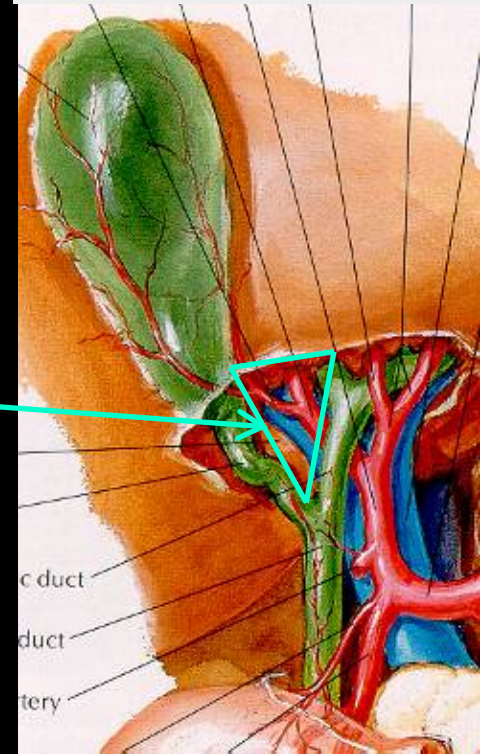
Vesica biliaris / fellea

Žlučník

- 7-10 cm, objem 30-50 ml
- fundus, corpus, infundibulum (+ Hartmannova výchlípka), collum
- ductus cysticus
 - 2-5 cm dlouhý, 3-5 mm široký
 - plica spiralis *Heisteri*
- trigonum cystohepaticum *Caloti*
- intraperitoneální orgán
 - široce přisedlý k játrům („lůžko žlučníku“)

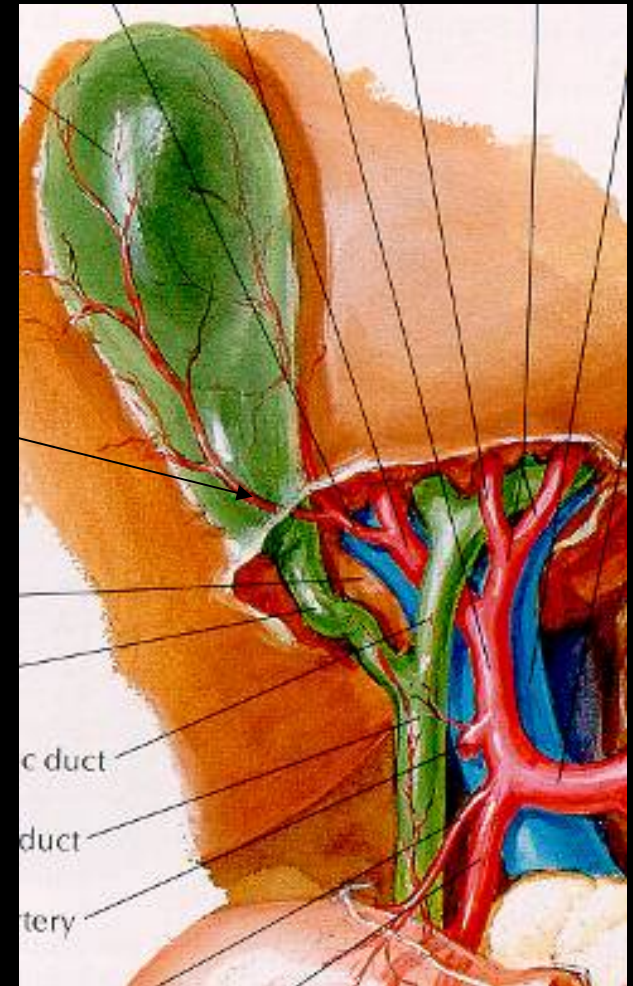


Obr. 5.33. Vesica biliaris a ductus cysticus. 1 – fundus, 2 – corpus, 3 – plicae mucosae, 4 – collum, 5 – ductus cysticus, 6 – ductus choledochus, 7 – ductus hepaticus communis, 8 – ductus hepaticus dx. et sin.



Žlučník – zásobení

- tepny: truncus coeliacus
→ a. hepatica communis
→ a. hepatica propria →
r. dx. → **a. cystica**
– **podvaz v trigonum
cystohepaticum *Caloti***
- žíly odpovídají tepnám
→ v. portae
- míza: n.l. hepatici



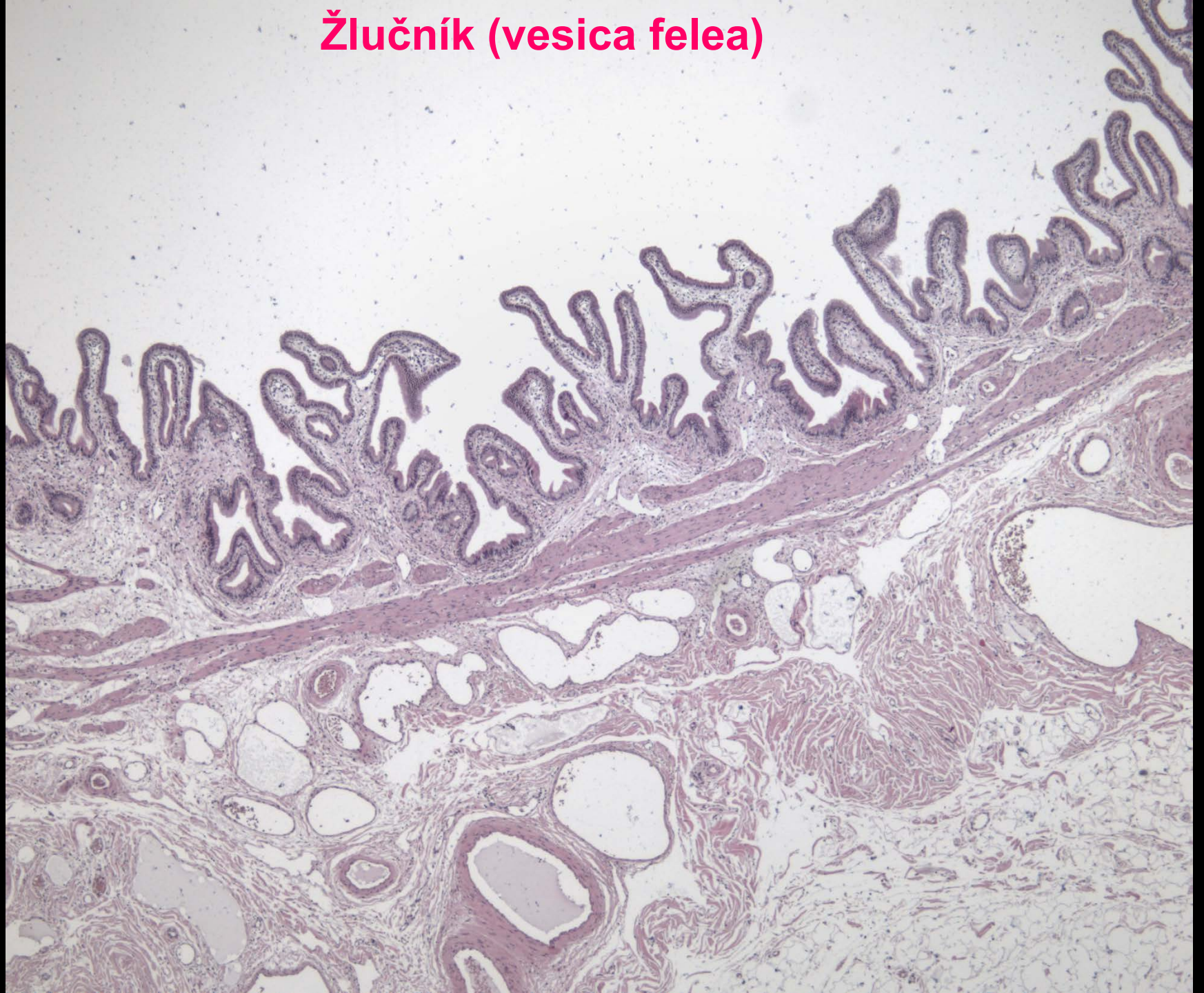Žlučník – *stavba*

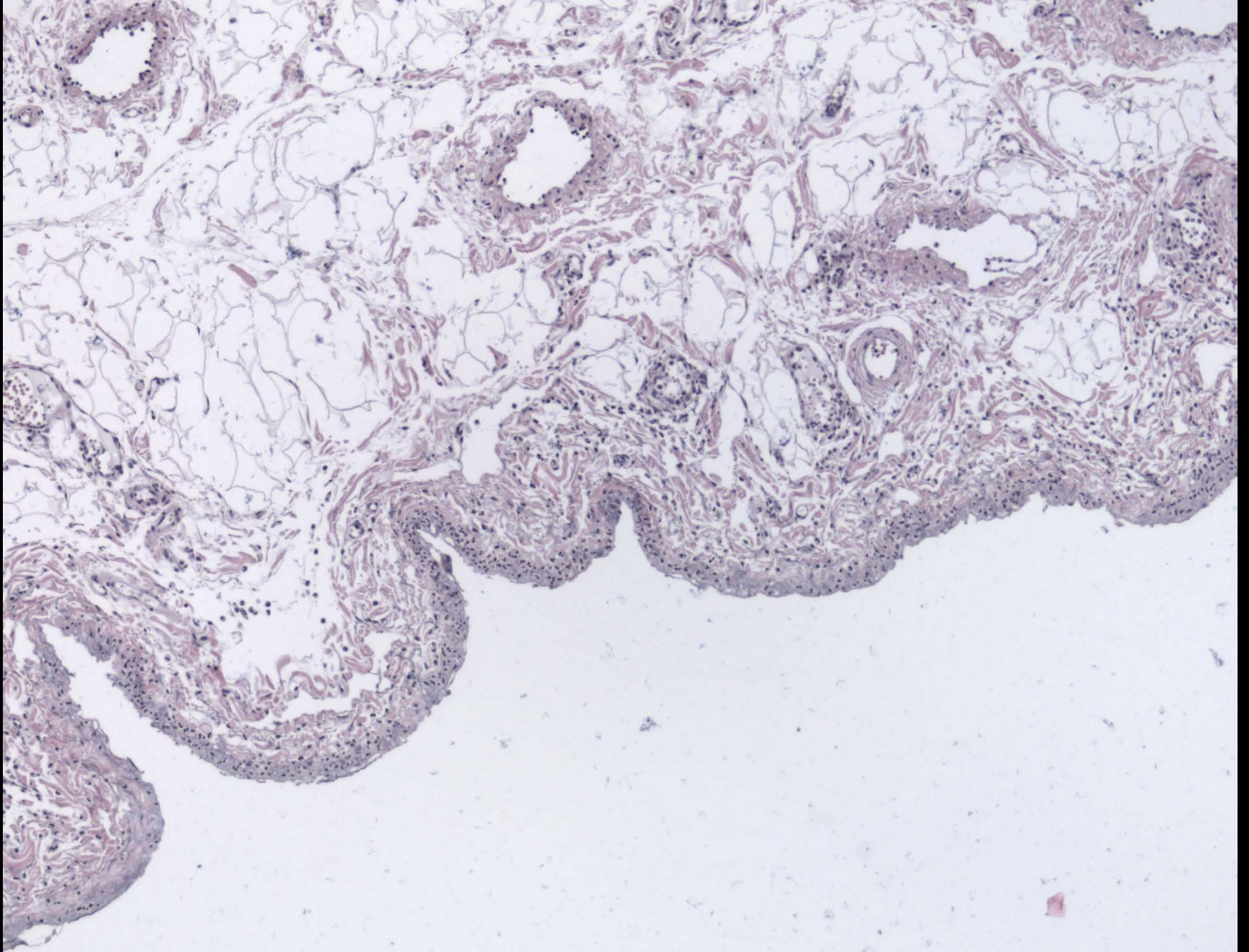
- tunica mucosa
 - jednovrstevný cylindrický epitel s mikrovlyčky
 - tvoří četné řasy
 - chybí lamina muscularis mucosae
 - v krčku tubulózní žlázy → hlen
 - vchlípeniny sliznice až do svaloviny = Aschoffovy-Rokitanskeho sinusy
- *chybí tela submucosa*

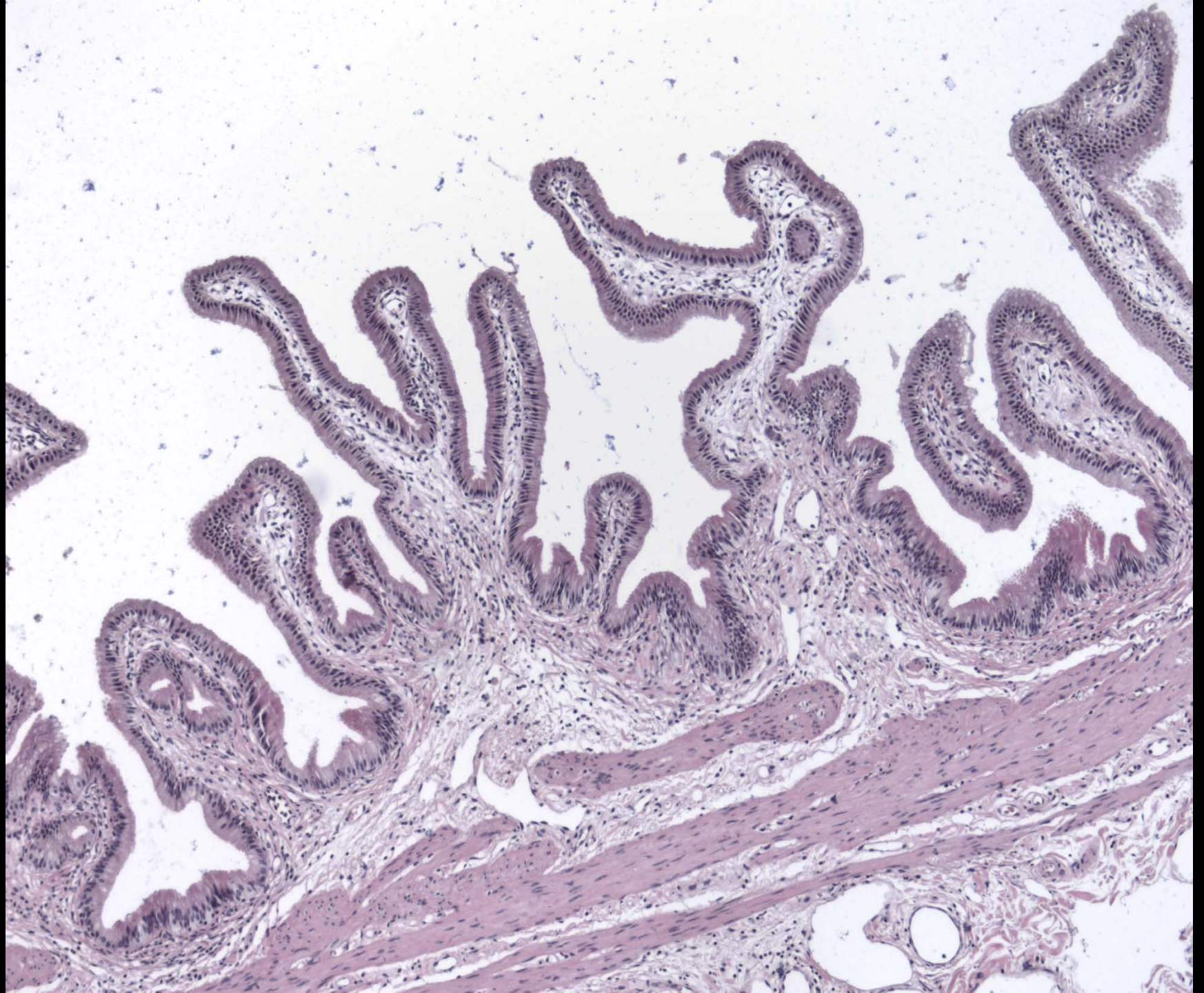
Žlučník – stavba

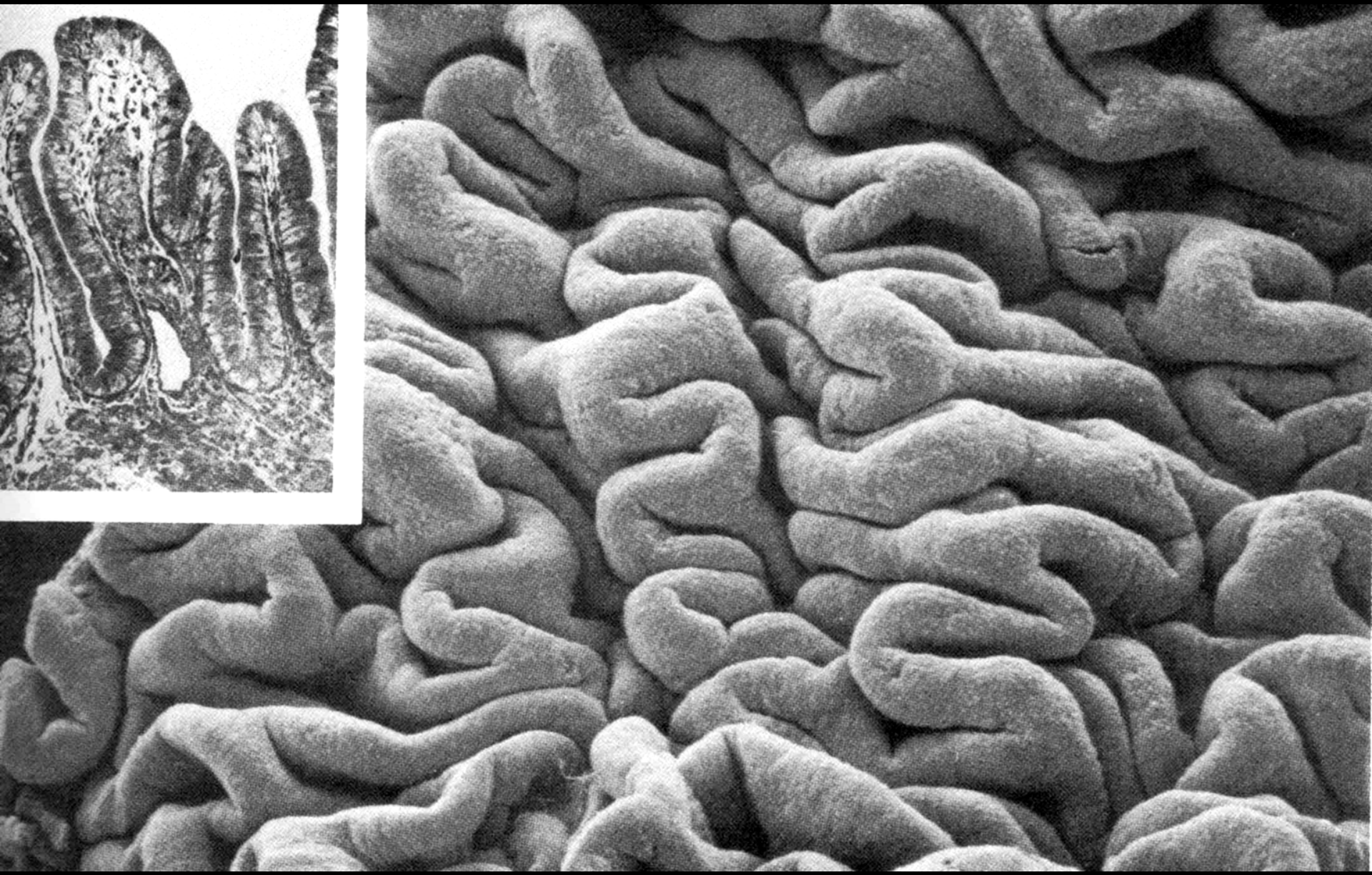
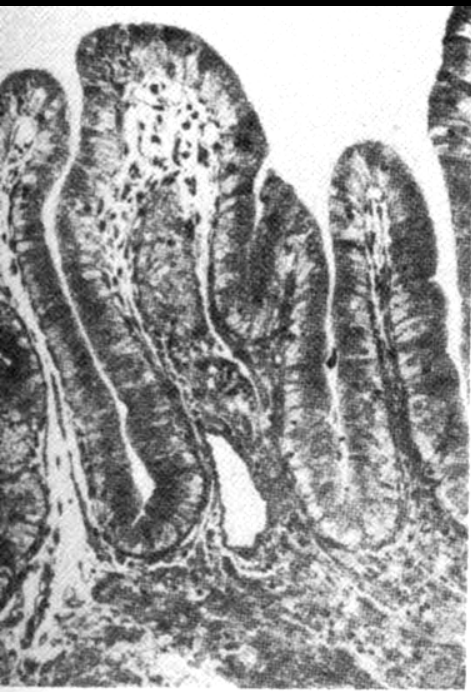- tunica muscularis
 - síťovitá svalovina
 - cholecystokinin a ANS → stahy
- tunica serosa
 - silná tela subserosa
 - široce přisedlý k játrům ve fossa vesicae biliaris („lůžko žlučníku“)
- funkce:
 - střídat a koncentrovat žluč (absorpce vody na 10 %) → při nerovnováze koncentrací látek vznikají kameny (**cholelithiasis**)
 - obsah 30-50 ml

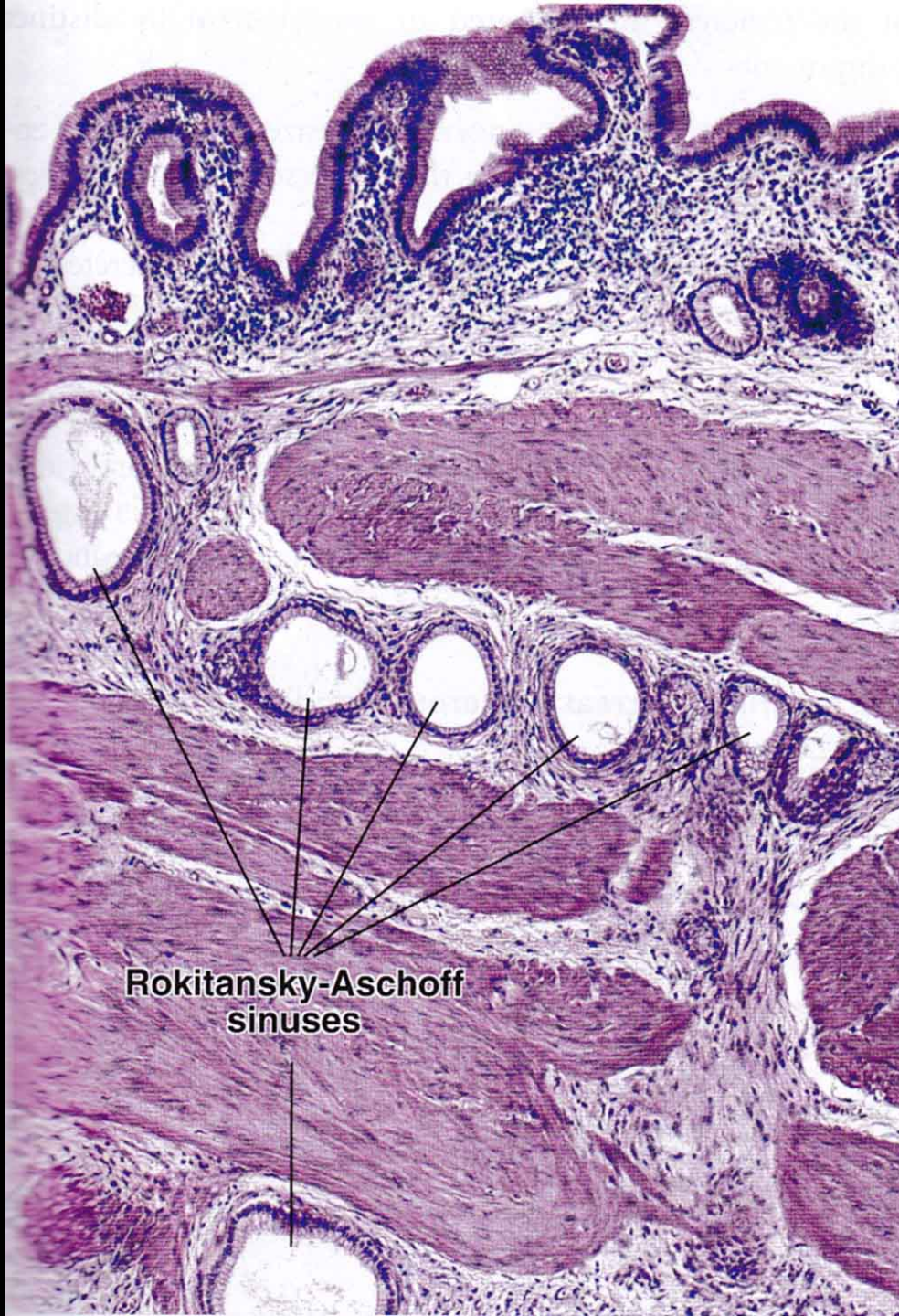Žlučník (vesica felea)



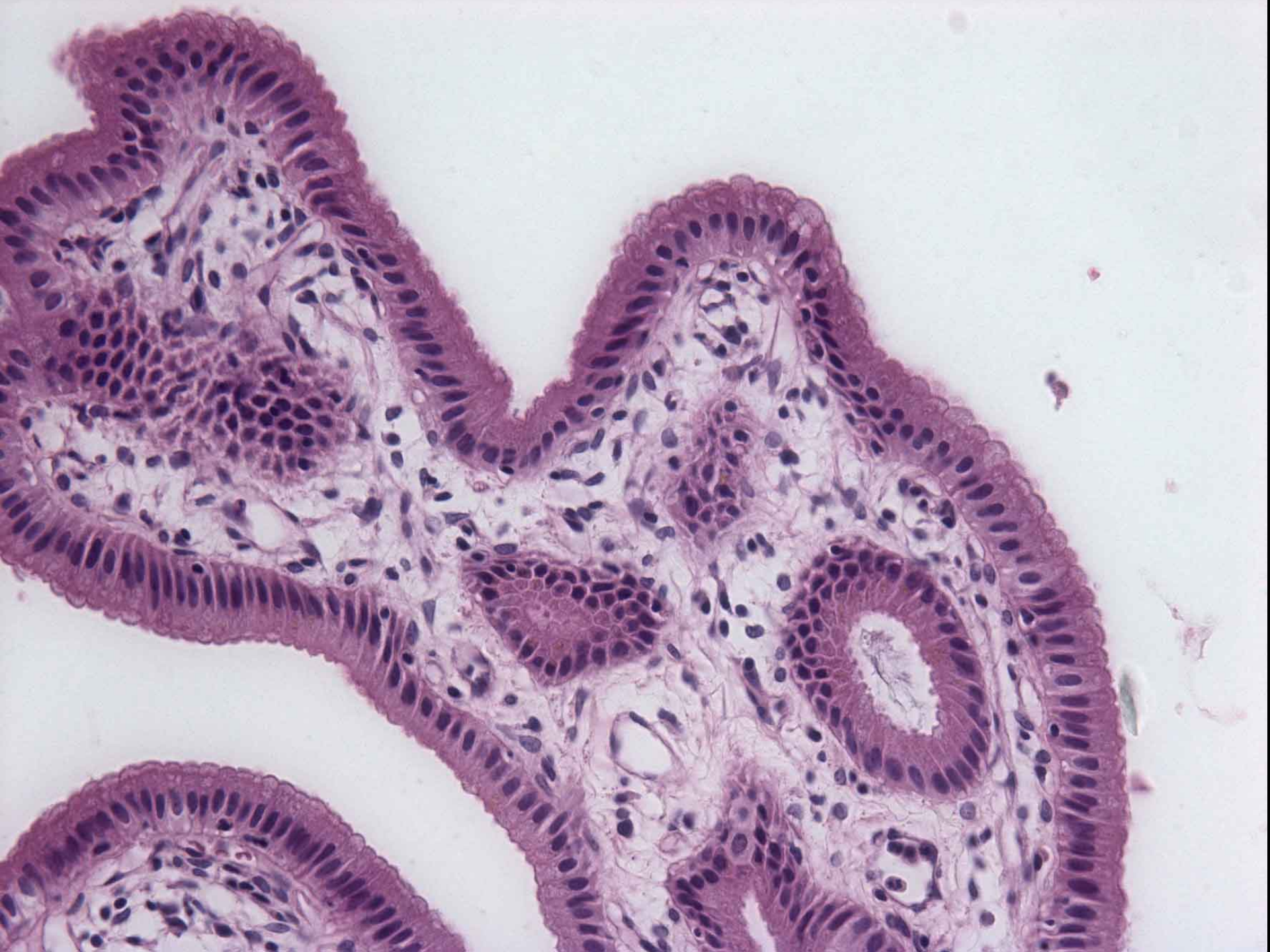




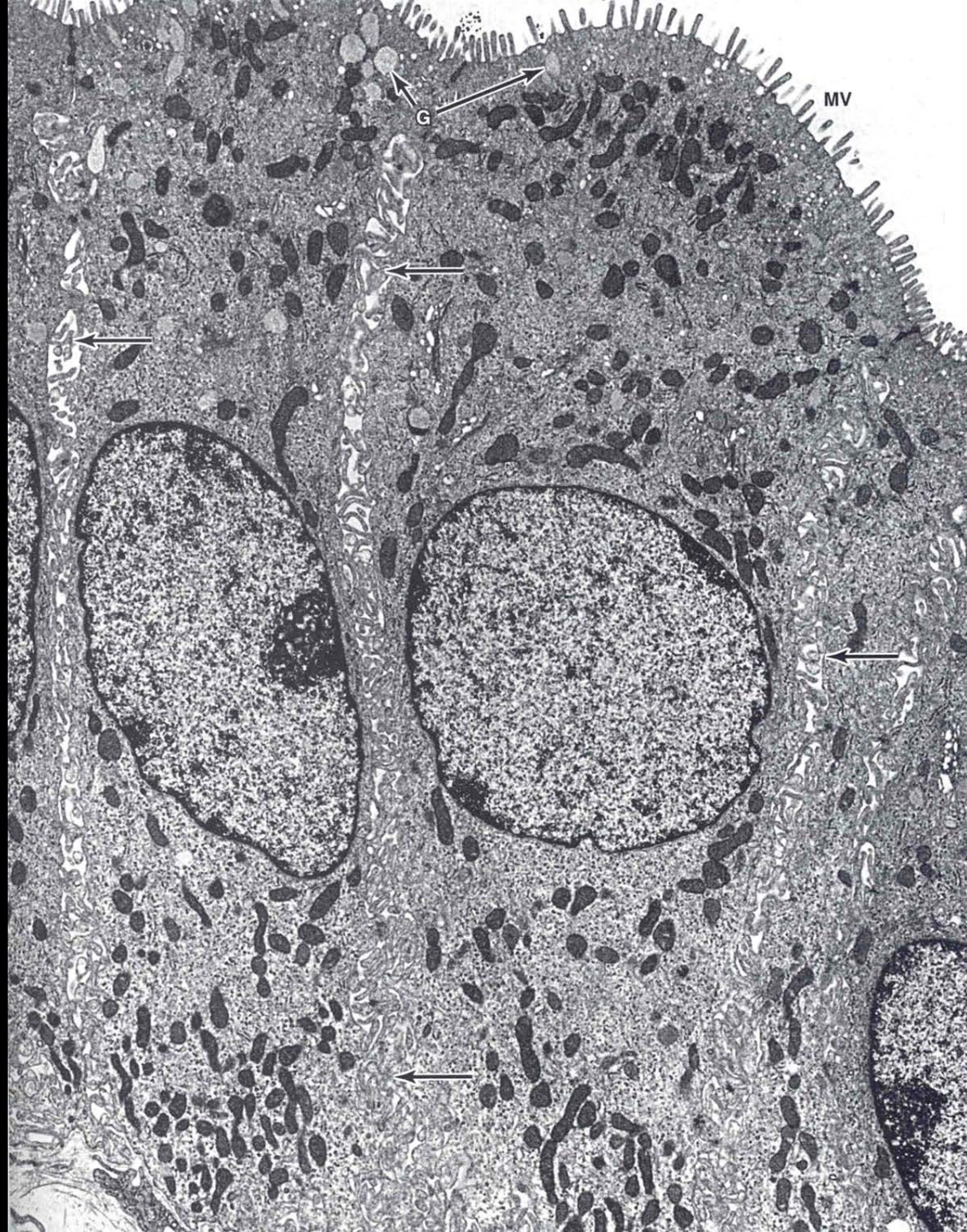




Rokitansky-Aschoff
sinuses

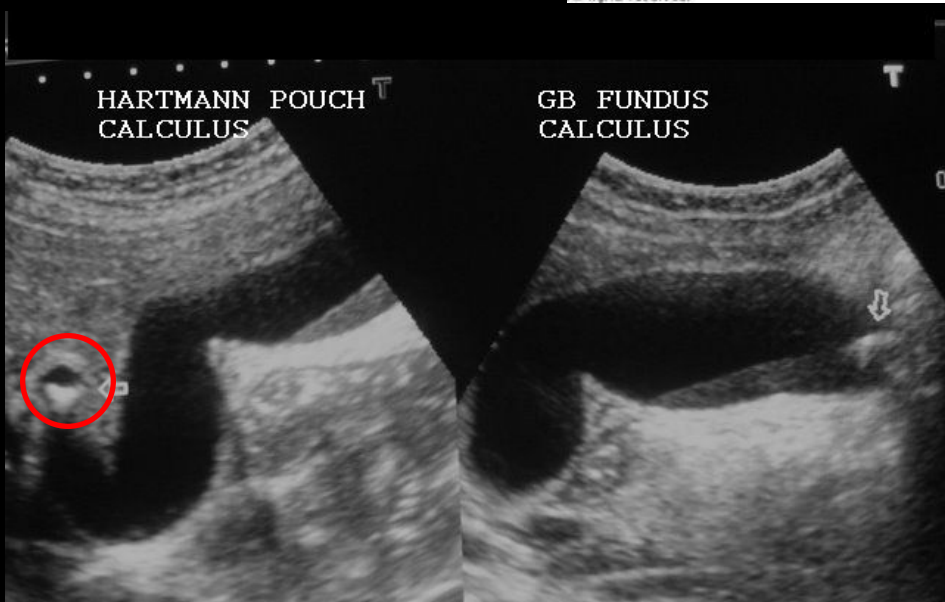
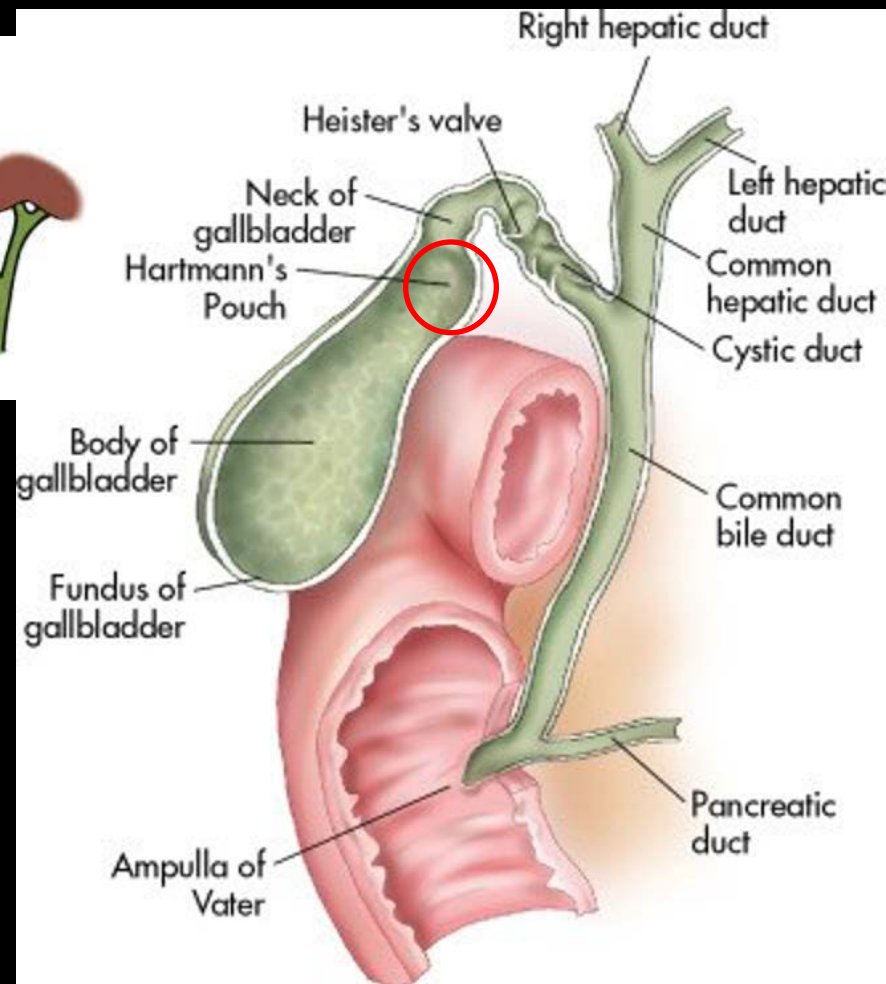
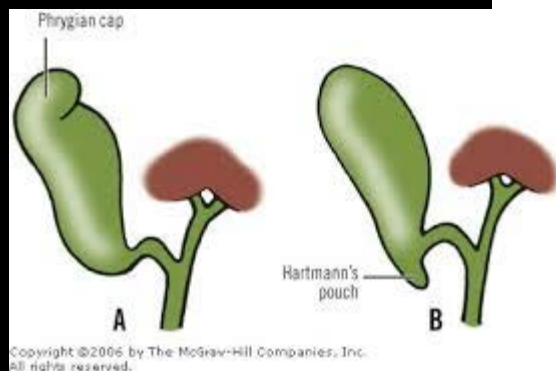


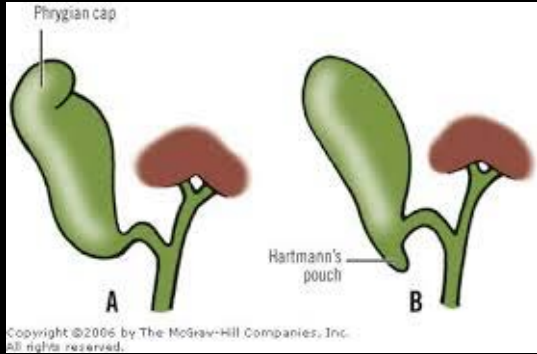




Hartmannova výchlípka – *variabilní*

- na hranici infundibula a krčku žlučníku
- predispoziční místo pro ukládání žlučových kamenů

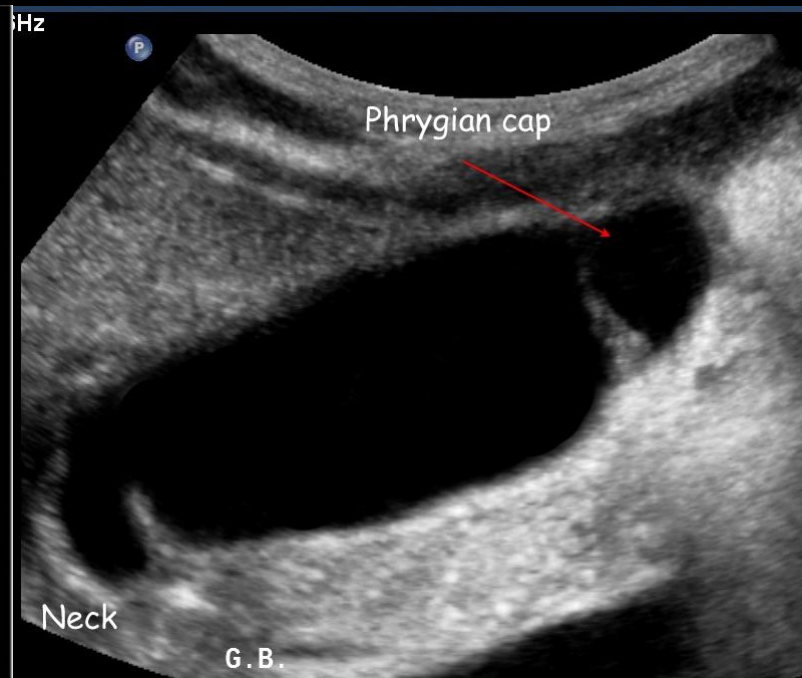
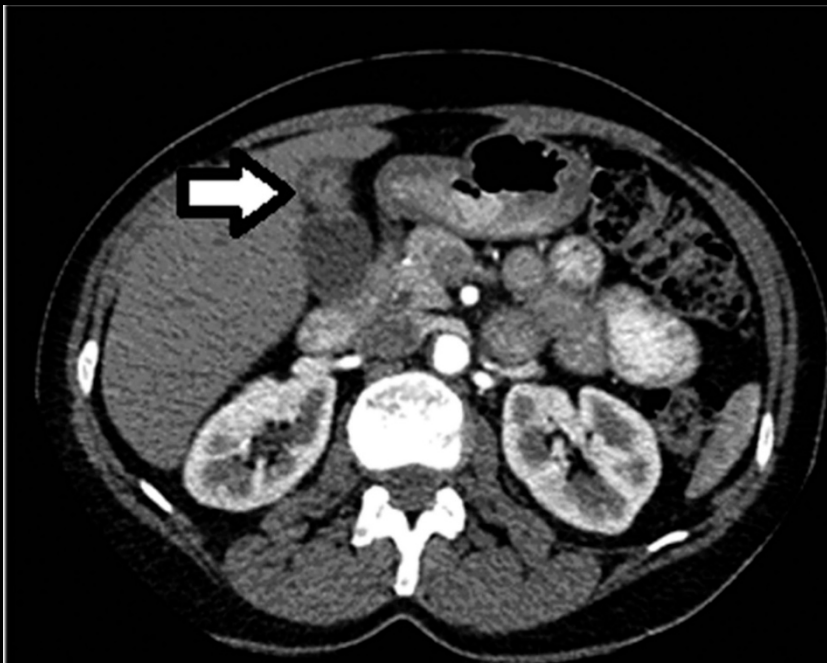




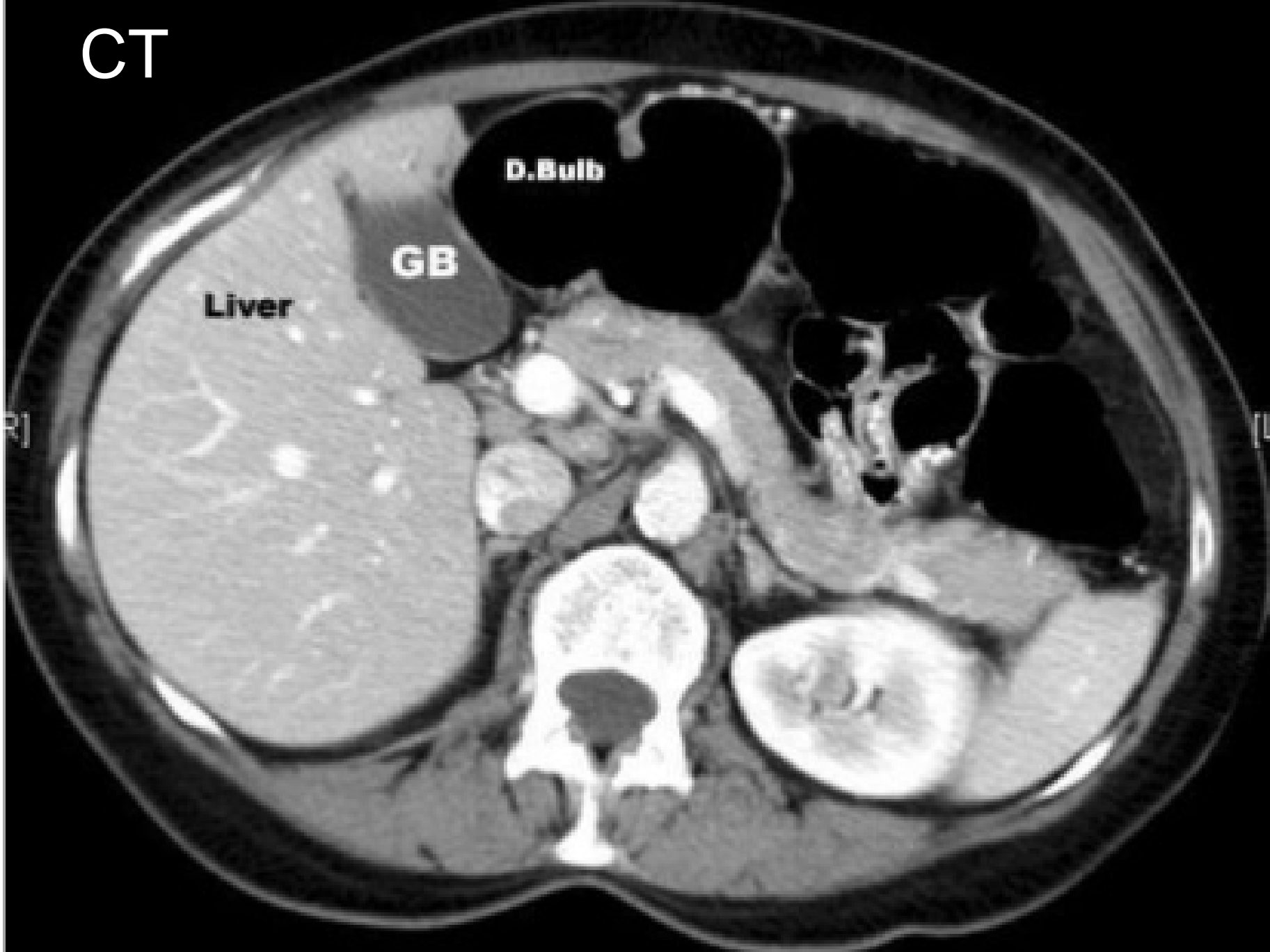„Phrygian cap“



- záhyb žlučníku na hranici fundu a těla žlučníku (1-6 %)
- frygická čapka (fryžská čepice) = měkká kuželová čepice s vytaženou horní částí



CT



Liver

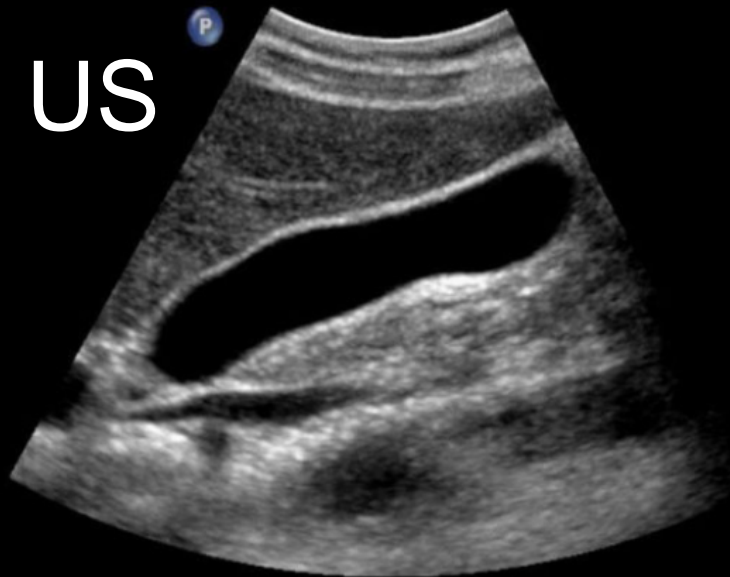
GB

D. Bulb

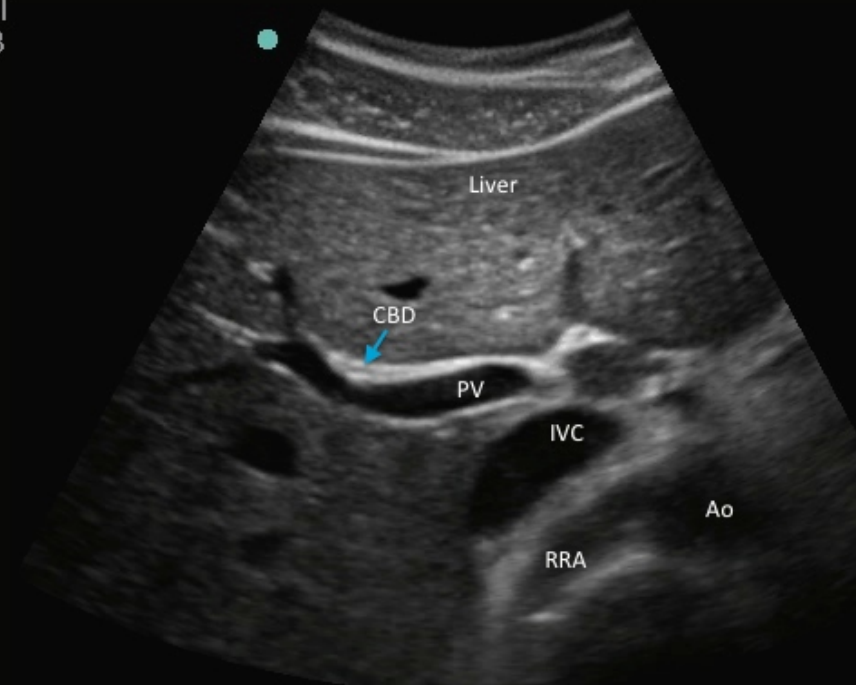R]

[L

US

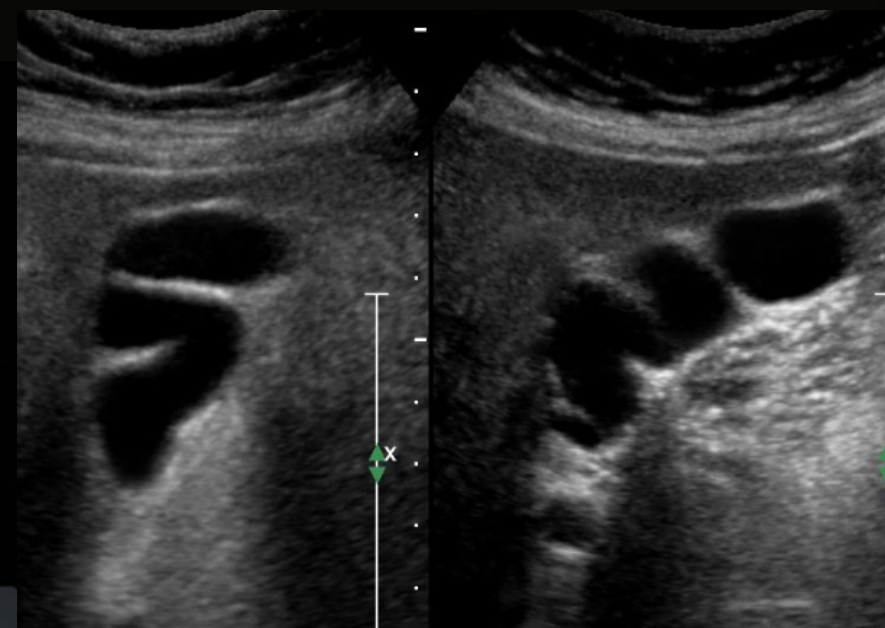
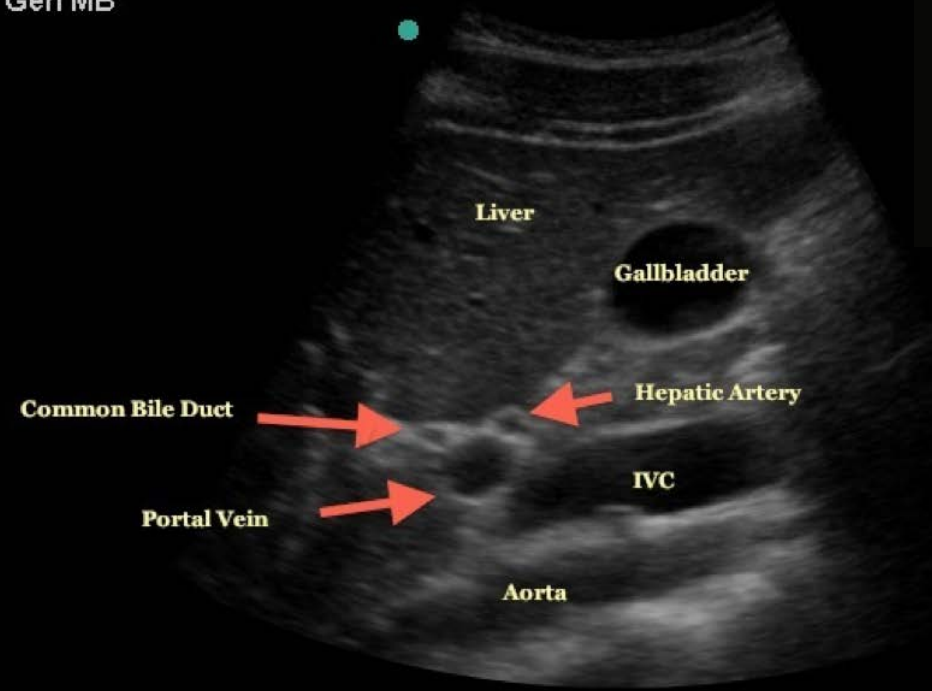


Gen S THI MB



Gen MB

Portal Vein - CBD



3D MR cholangiopankreatografie

