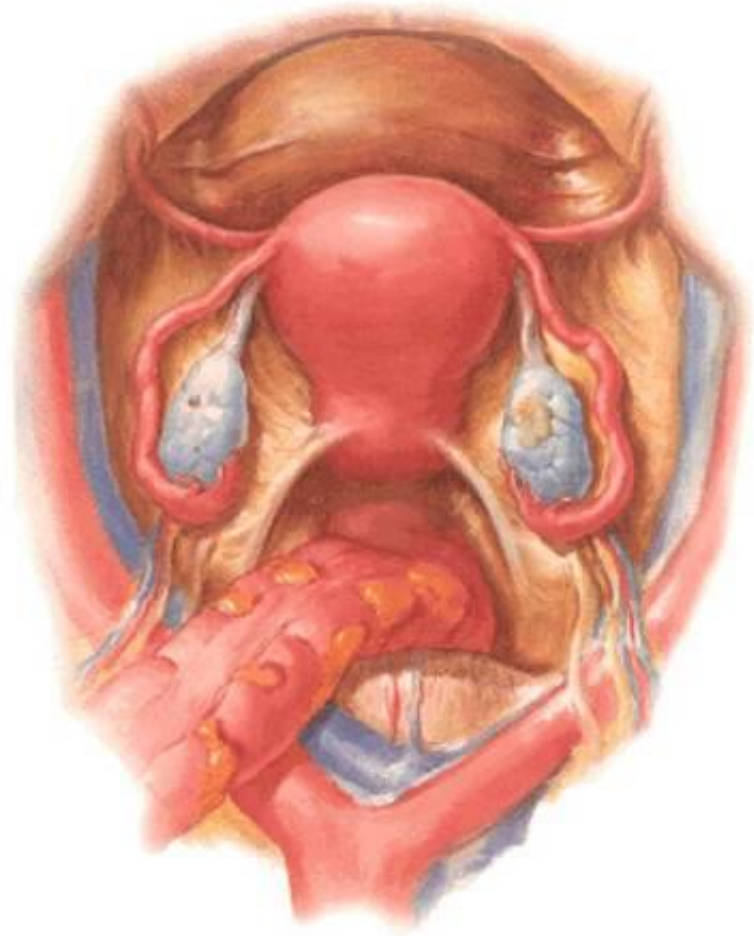


Female internal genital organs

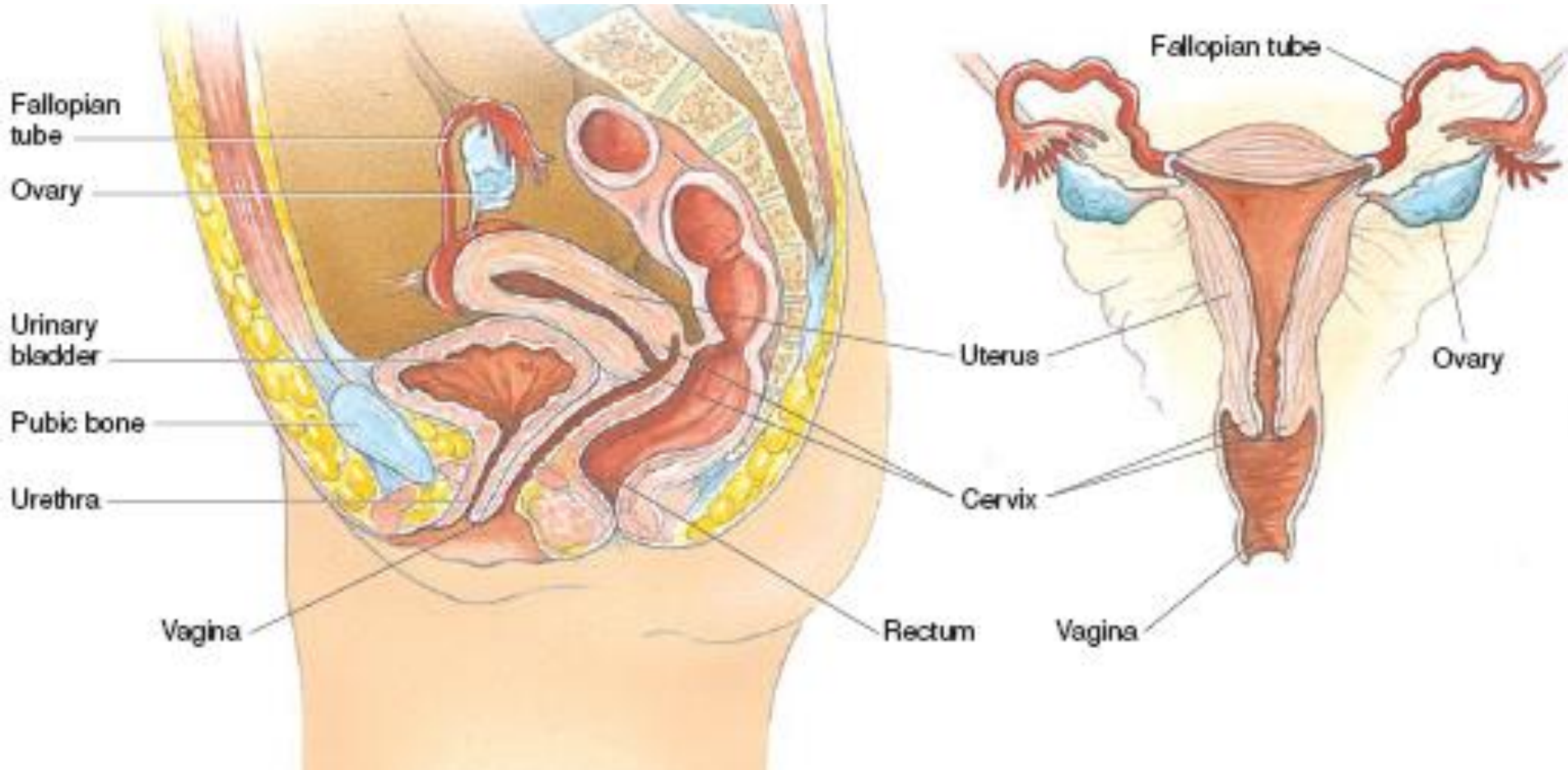
Organa genitalia feminina interna

- ovarium
- tuba uterina / salpinx =
uterine tube
- uterus
- vagina
- embryonal remnants
(epoophoron, paroophoron)

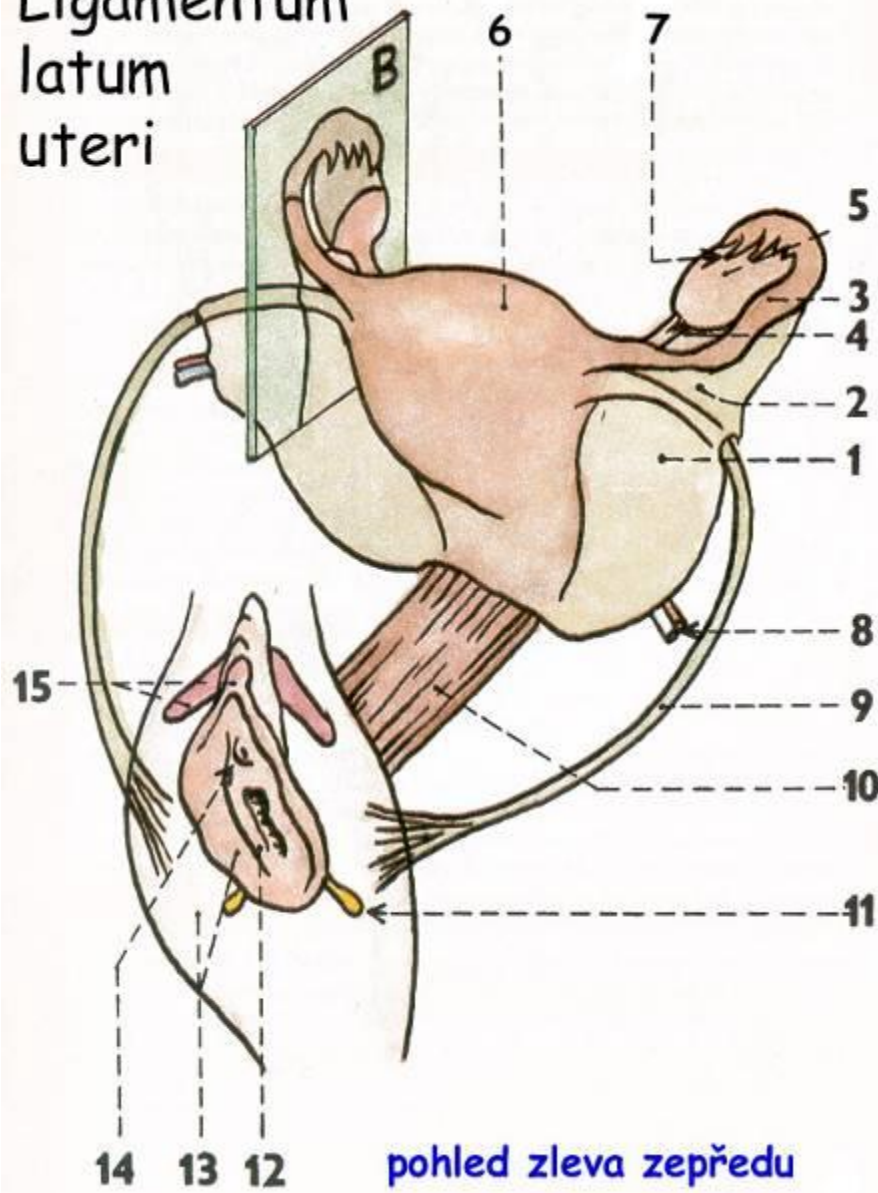


Female internal genital organs

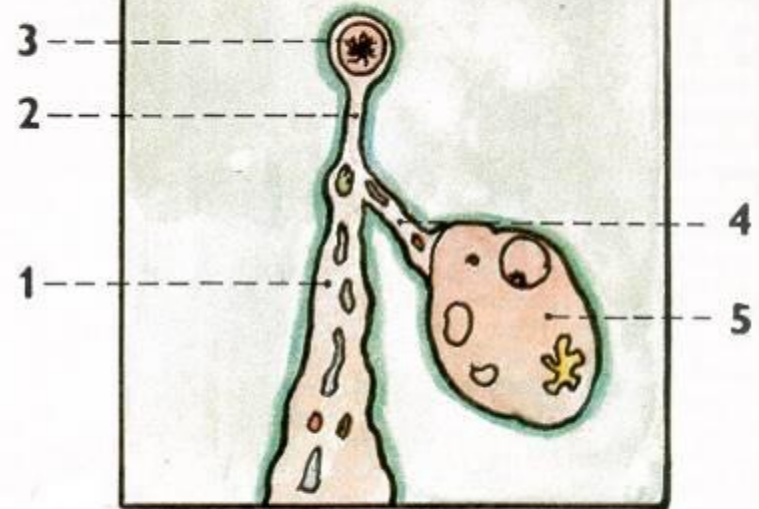
Organa genitalia feminina interna



Ligamentum
latum
uteri

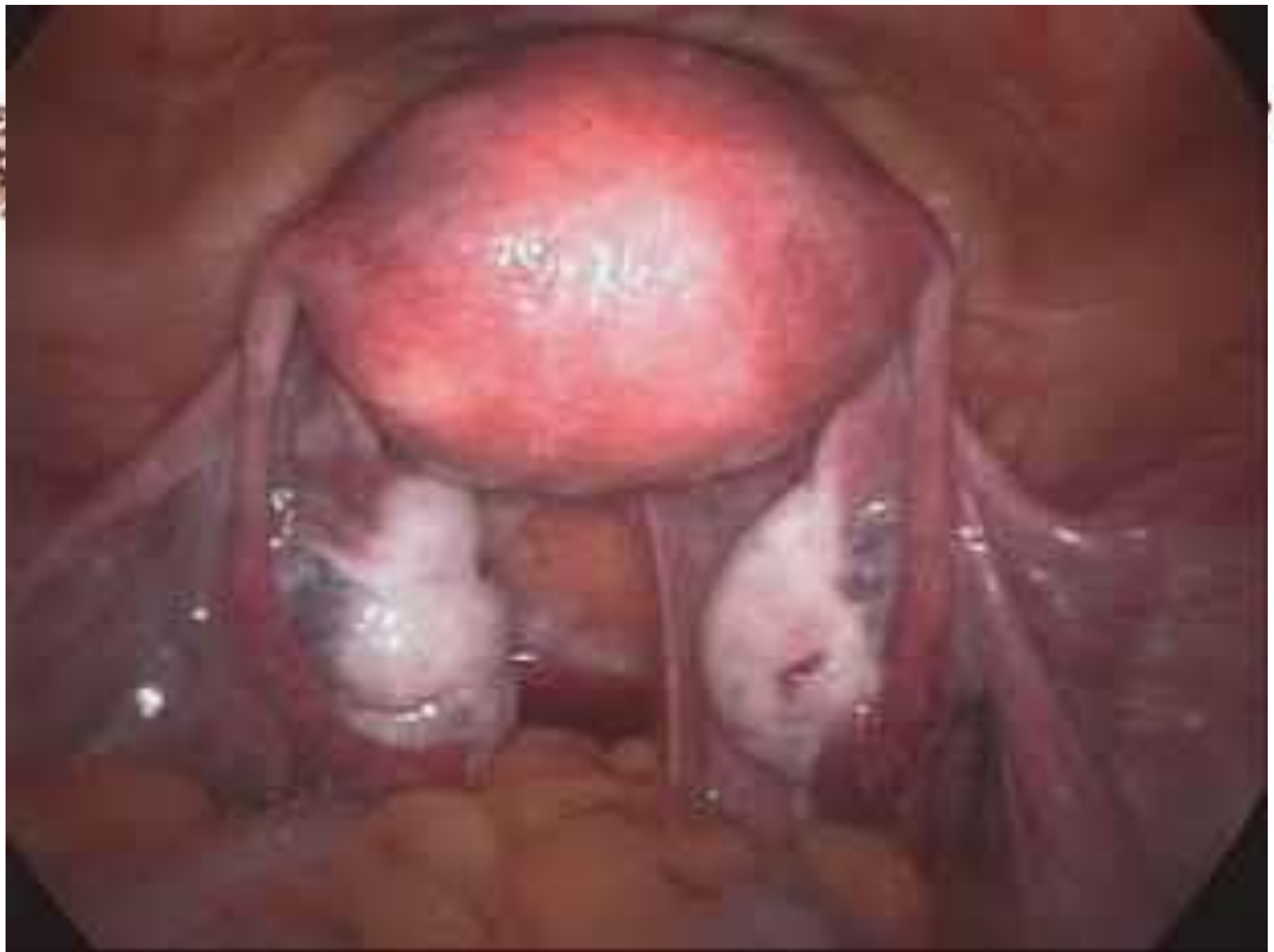

B - sagitální řez při
pohledu zleva



- 1 / ligamentum latum uteri
- 2 / mesosalpinx
- 3 / tuba uterina v mesosalpinx
- 4 / závěs ovaria — mesovarium
- 5 / ovarium
- 6 / uterus v lig. latum
- 7 / abdominální ústí tuba uterina
- 8 / a. et. v. uterina
- 9 / lig. teres uteri
- 10 / stěna vaginy
- 11 / glandula vestibularis major
- 12 / vestibulum vaginae
- 13 / labium pudendi majus et minus
- 14 / ostium urethrae externum
- 15 / clitoris

- double-layered peritoneal duplicature
- sagittally oriented plate



Ovarium; Oophoron

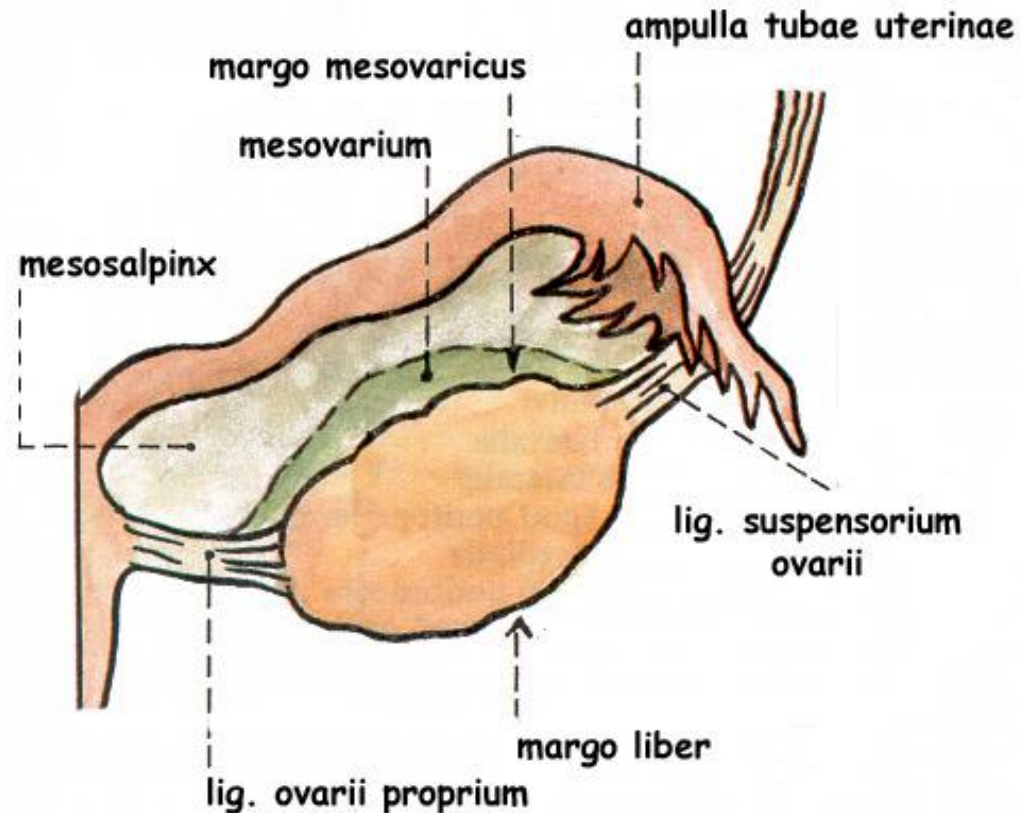
- 6-10 g, flattened shape, large 3 x 2 x 1 cm
- sex gland
 - maturation of ova (ootids)
 - secretion of sex hormones
- intraperitoneal organ
- posterior side of lig. latum uteri
- position: fossa ovarica (*nullipara*)
 - between vasa iliaca externa et interna

fossa of Claudius (*multipara*)

 - between vasa iliaca interna and os sacrum

Ovary – external structure

- extremitas tubaria
- extremitas uterina
- margo liber
- margo mesovaricus
- facies medialis
- facies lateralis
- hilum ovarii



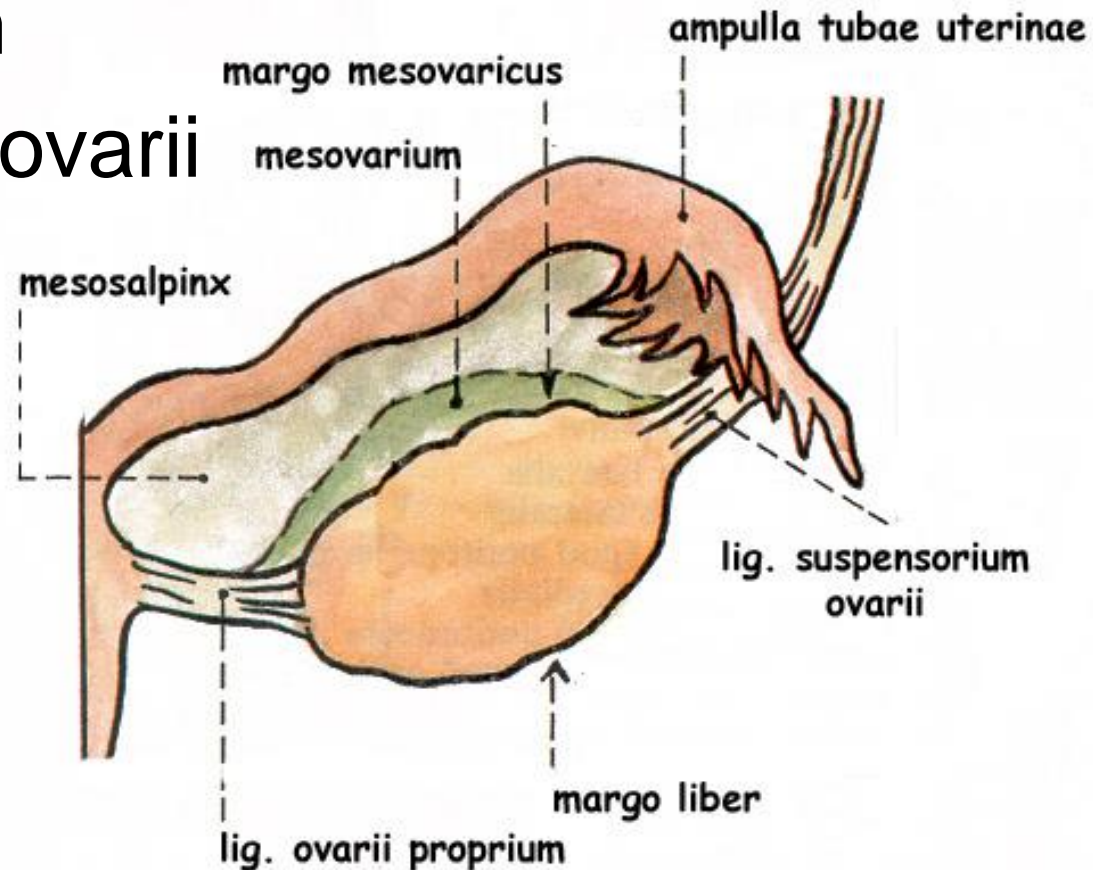
Peritoneal attachments of ovary and uterine tubes

Ovary:

- lig. ovarii proprium
- lig. suspensorium ovarii
- lig. latum uteri
- mesovarium

Uterine tube:

- lig. latum uteri
- mesosalpinx



Ovary – *blood supply*

all form/to the level of **L2**

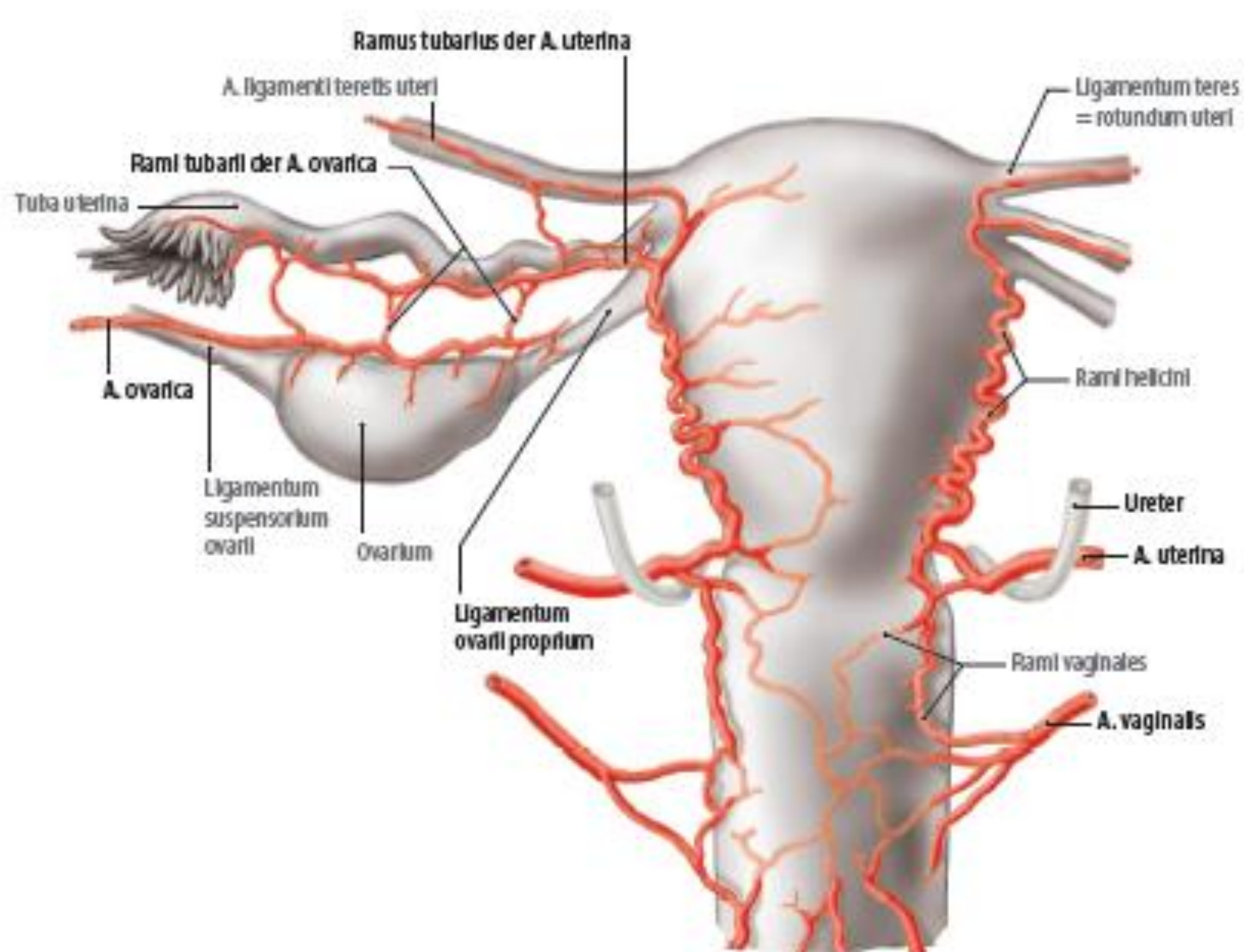
Arteries:

- aorta abdominalis → a. ovarica
- a. iliaca int. → r. ovaricus

arteries anastomoses to form the ovarian arcade

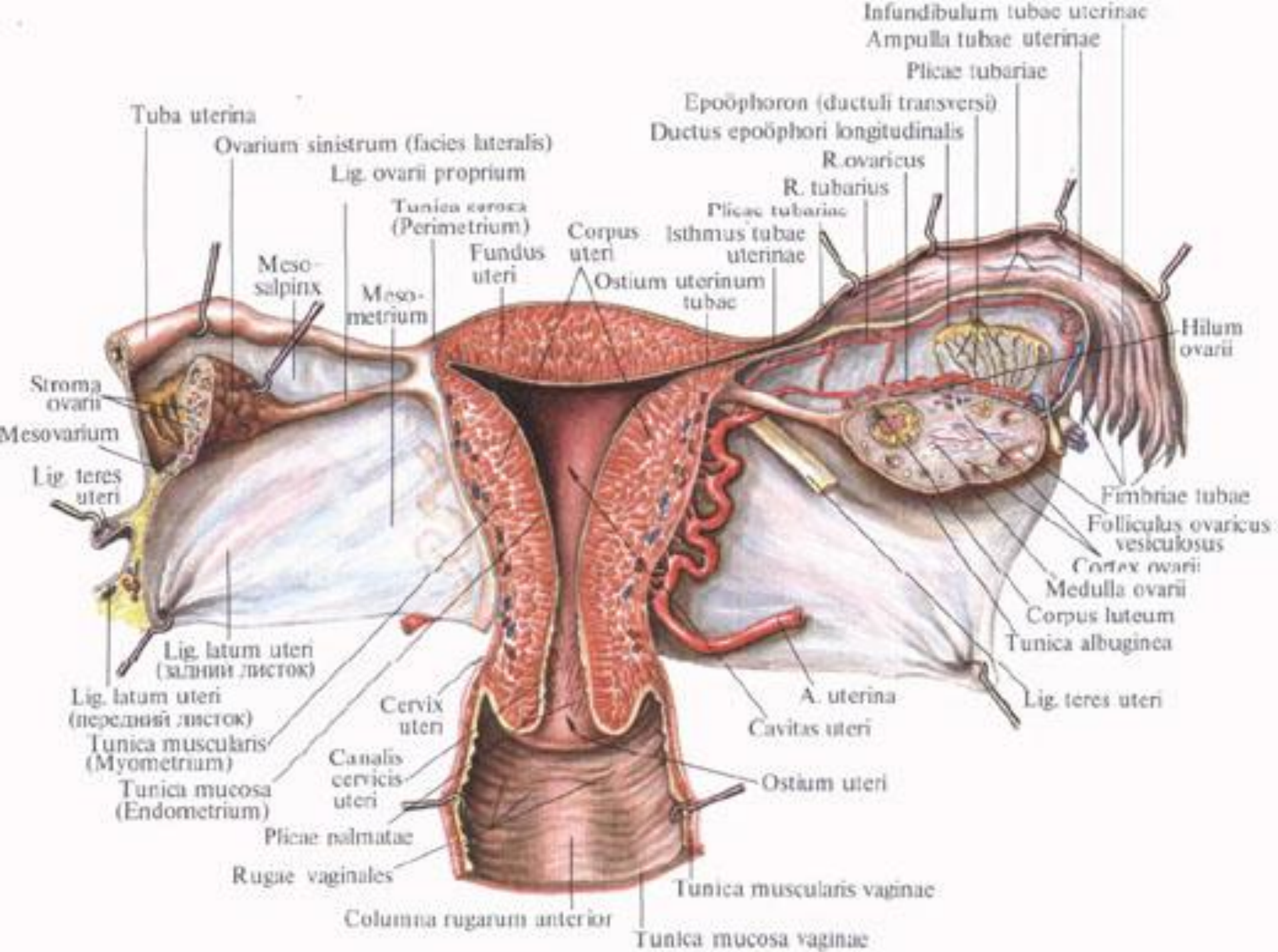
Veins: plexus pampiniformis (rudimentary) →
v. ovarica → v. cava inf. (dx.) / v. renalis
sin. (sin.)

Lymph: n.l. lumbales



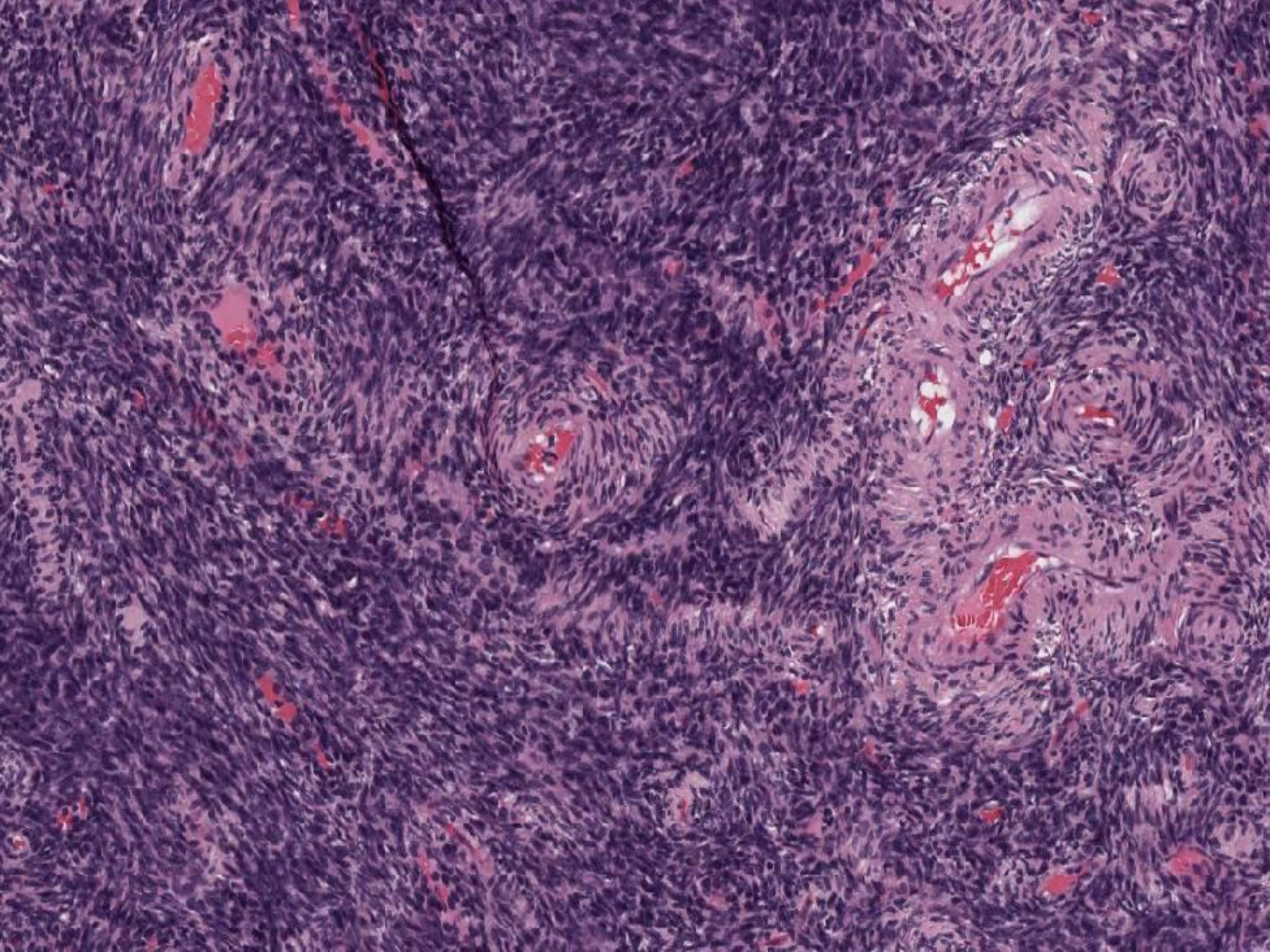
Ovary – *internal structure*

- superficial (Müllerian) epithelium – simple cuboidal with microvilli
 - original coelomic epithelium (*mesothelium ovaricum*)
 - borderline with mesothelium = linea of *Farre-Waldeyer*
- tunica albuginea
- stroma ovarii
 - connective tissue (collagen and reticular fibers, fibroblasts)
 - **cortex** – folliculi ovarici
 - corpus luteum, rubrum, albicans
 - **medulla**



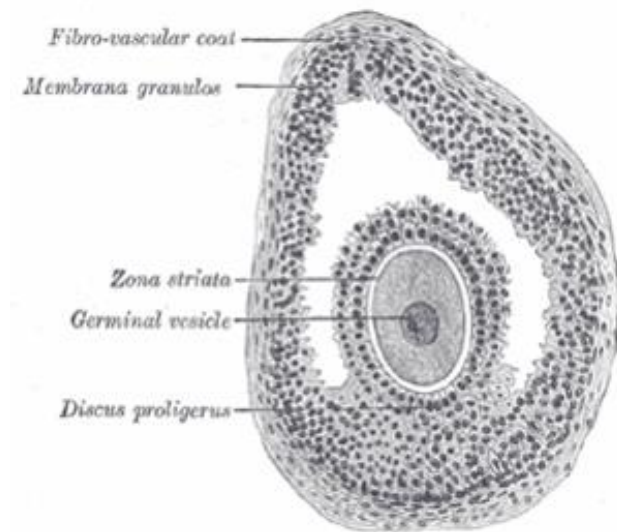
Ovary – *medulla*

- loose connective tissue
- nerves
- vessels
- groups of endocrine interstitial cells – hilar cells (*cellulae hili*)
 - developmental alternative of Leydig cells
 - produce androgens
- does **not** contain follicles



Follicles (*Folliculi*)

- one ovum (ootid; *ootidium, ovum*)
- surrounded by follicular somatic cells → granulosa cells
- in the late stages of development is formed capsule from stromal cells → theca cells
- development of ovum
- follicle maturation



Development of ovum = oogenesis 1.

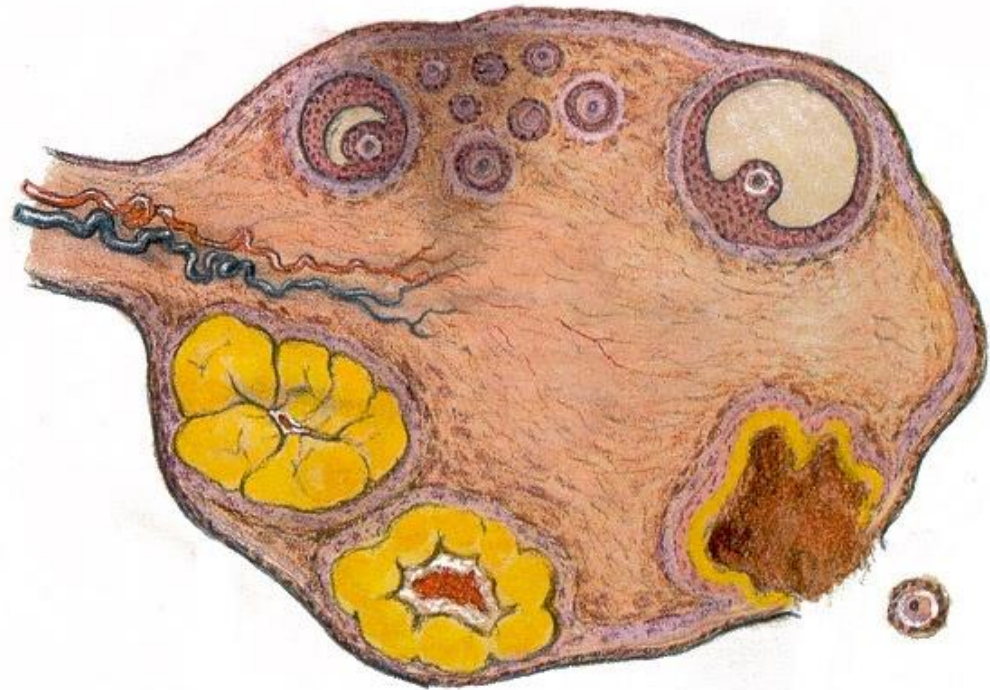
- two phases:
 - phase of division (mitotic divisions)
 - phase of maturation (meiotic divisions)
 - each ovum in different stage of development → various phases of maturing follicles in ovary
- germ cells proliferate in medullary cords and differentiate into oogonia
- before birth oogonia increase their volume and convert to primary oocytes
 - undergo 1. meiotic division before birth and are arrested at meiotic prophase

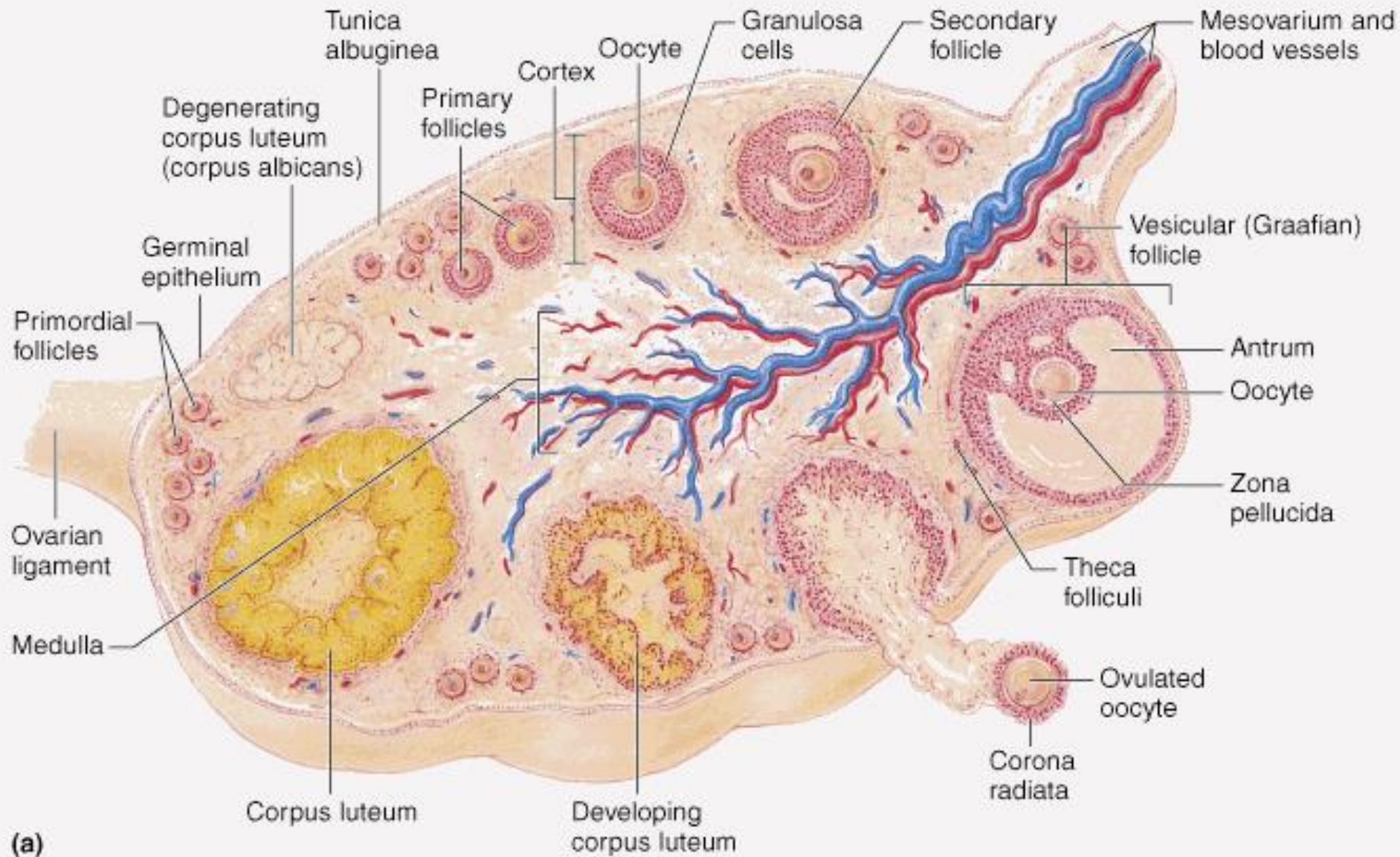
Development of ovum = oogenesis 2.

- postnatally from begin of puberty, one or more primary follicles continue in maturation per month
- just before ovulation is finished 1th meiotic division → secondary oocyte (+ second polar body / polocyte)
- during ovulation undegoes 2nd meiotic division arrested in metaphase
- if fertilization occurs the 2nd division is finished and mature ovum develops (+ second polar body / polocyte)

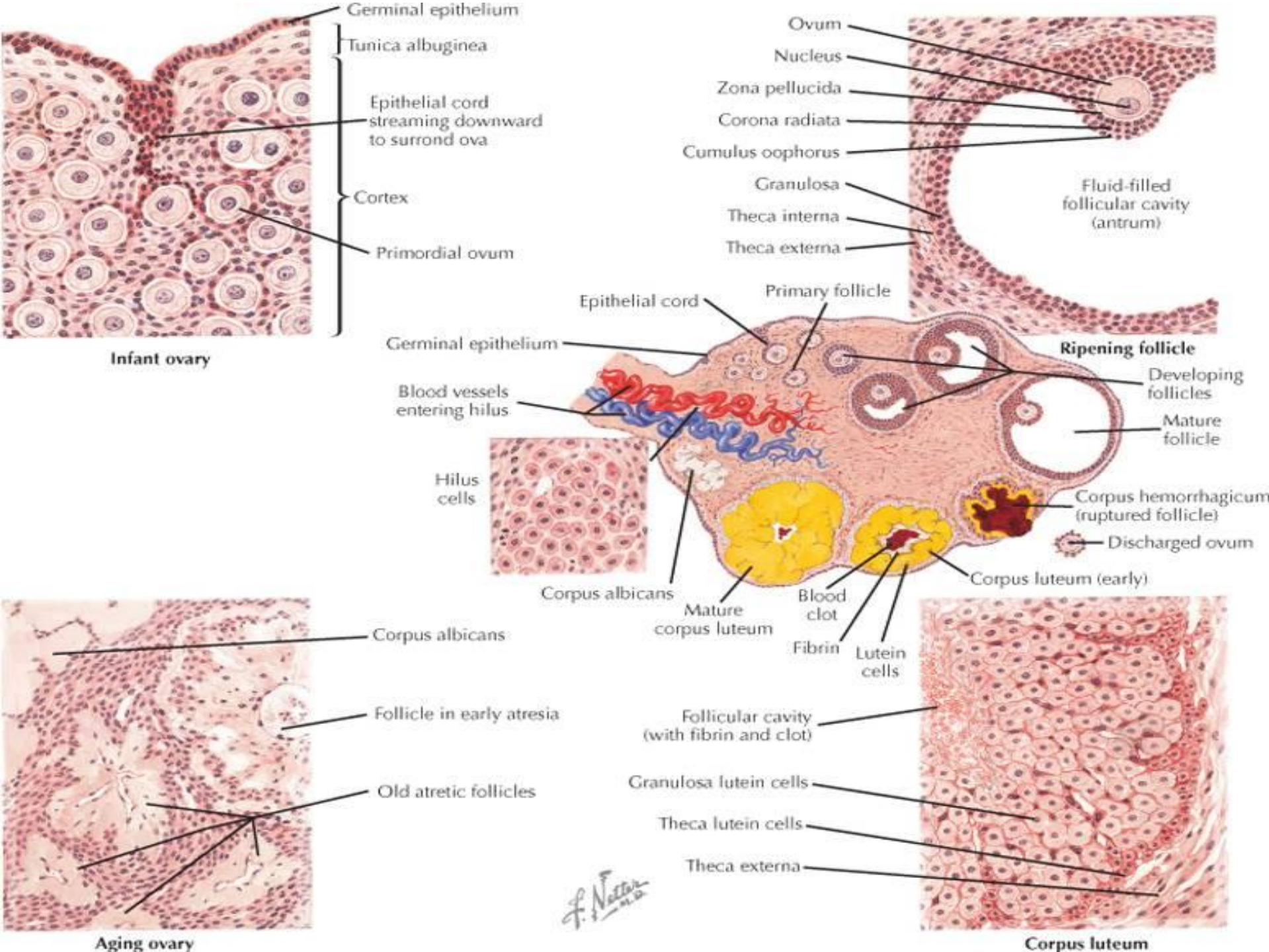
Follicle stages

- primordial follicle
- primary follicle
- secondary follicle
- tertiary follicle
- matured Graafian follicle



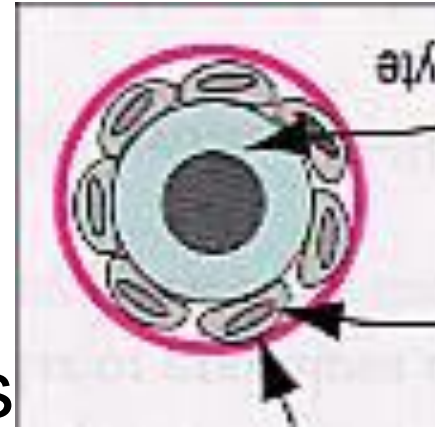


(a)

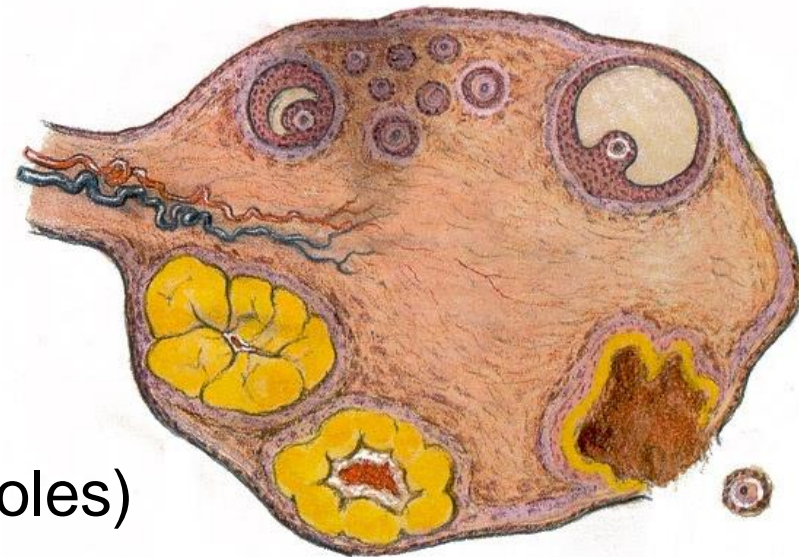


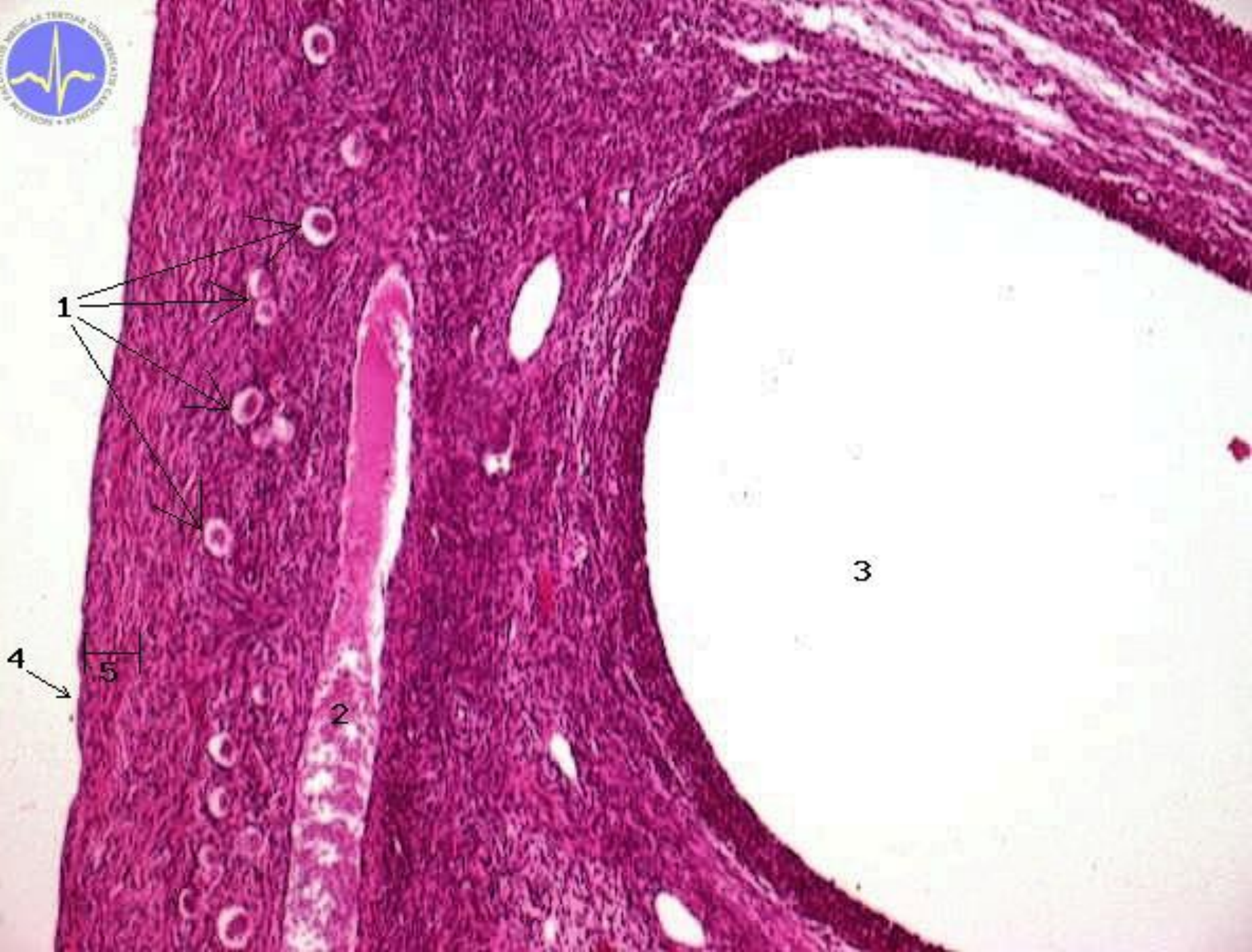
Folliculi ovarici primordiales

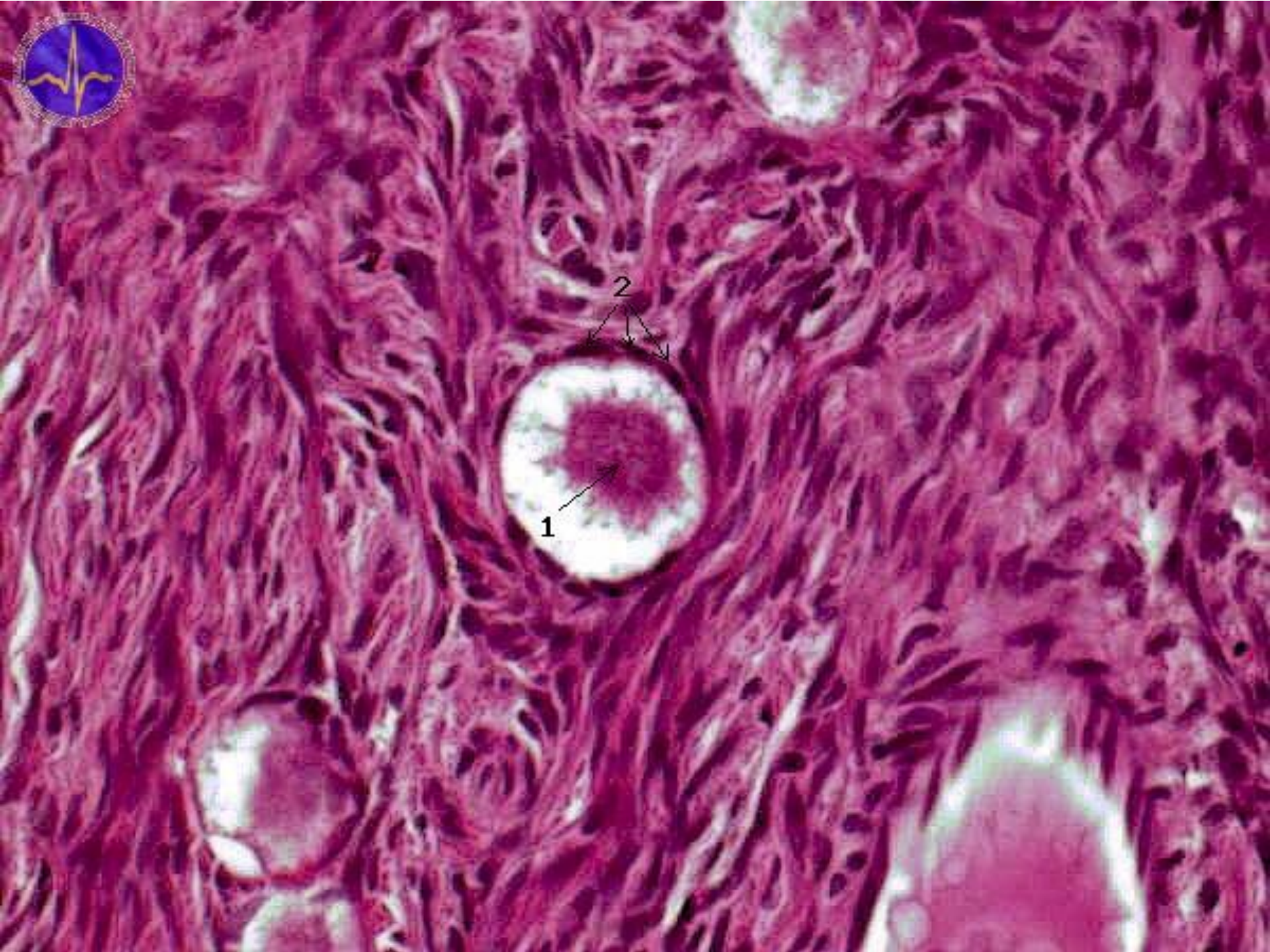
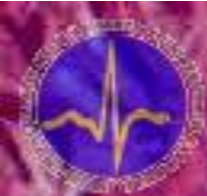Primordial follicles



- just below the ovarian surface
- **one layer of flattened follicular cells**
(*epitheliocyti folliculares; folliculocyti primordiales*)
= simple squamous epithelium (*epithelium simplex squamosum*)
- oocytus primarius
 - large eccentric nucleus and nucleolus
 - yolk nucleus (Golgi apparatus, mitochondria, inclusions, centrioles)





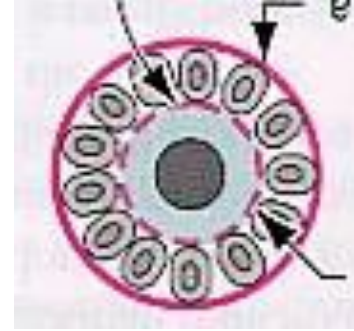


1

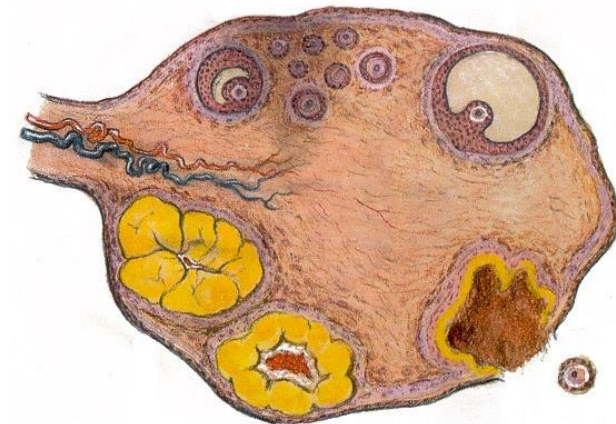
2

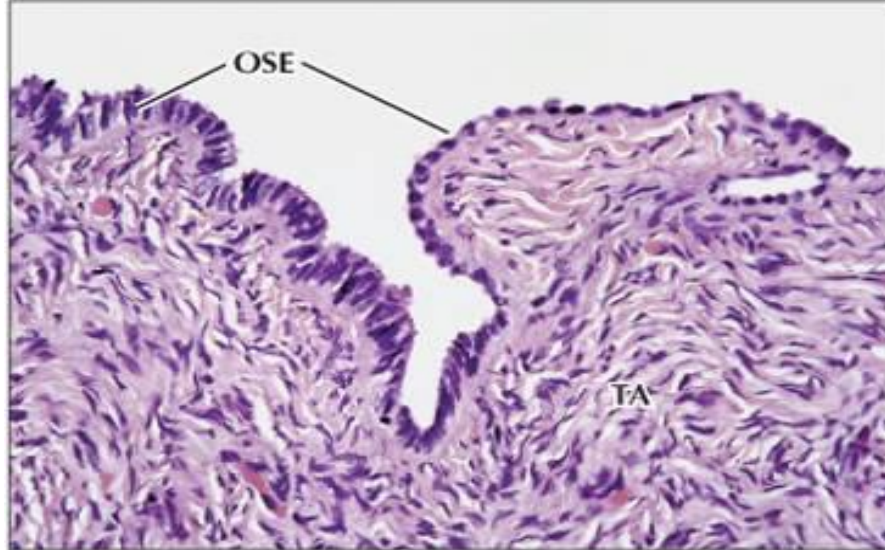
Folliculi ovarici primarii

Primary follicles

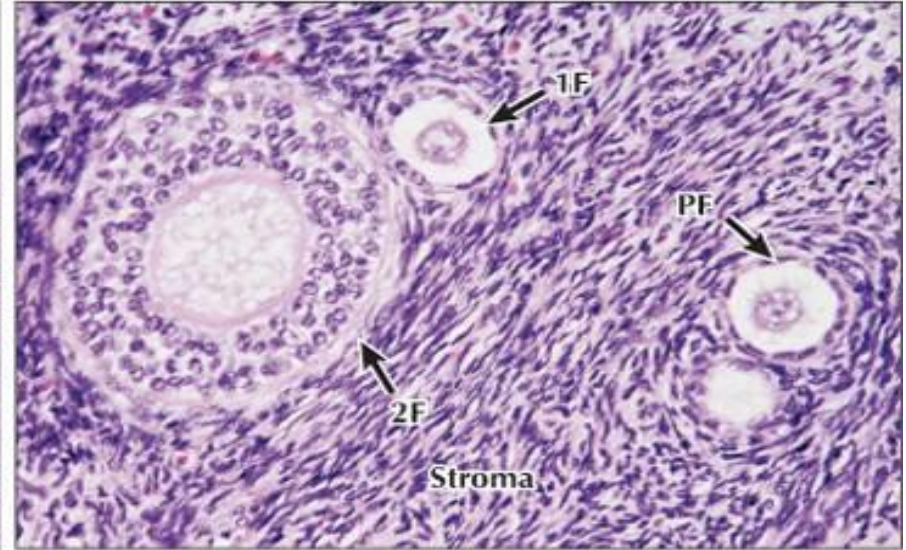


- follicular cells proliferate → **simple cuboidal to columnar** epithelium (*epithelium simplex cuboideum*)
 - increase of lipid granules → **granulosa** cells
- ***zona pellucida***
 - between cells and oocyte (glycoproteins produced by both populations)

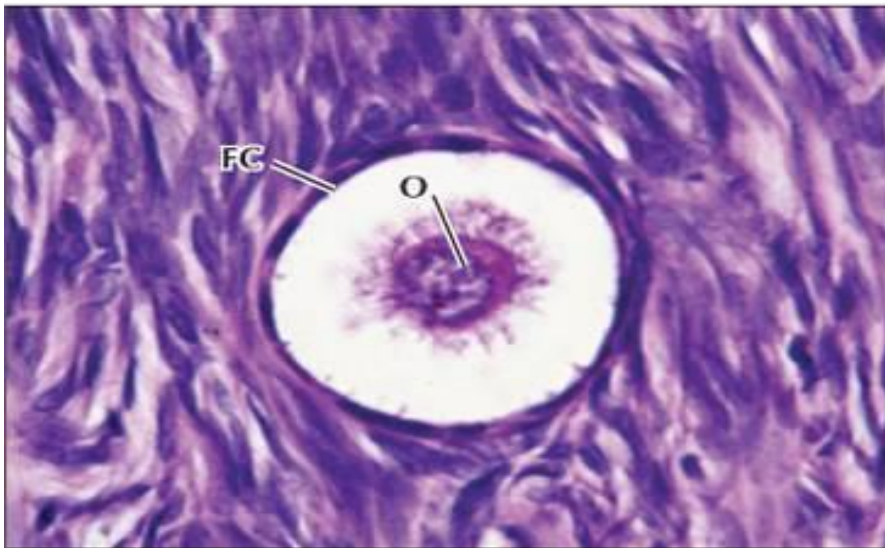




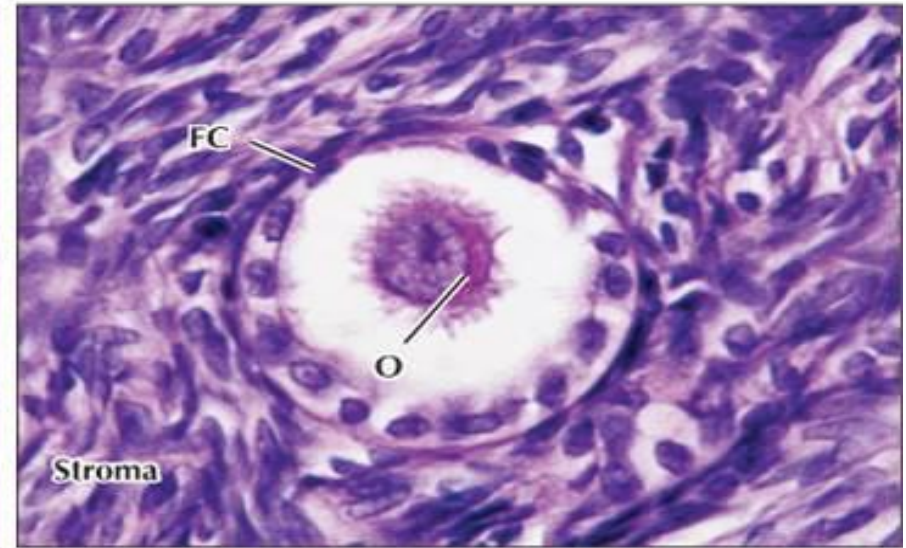
▲ **Light micrograph (LM) of the surface of the ovary.** The ovarian surface epithelium (**OSE**) consists of one layer of cuboidal to columnar cells. A basement membrane separates them from underlying tunica albuginea (**TA**). 390 \times . *H&E*.



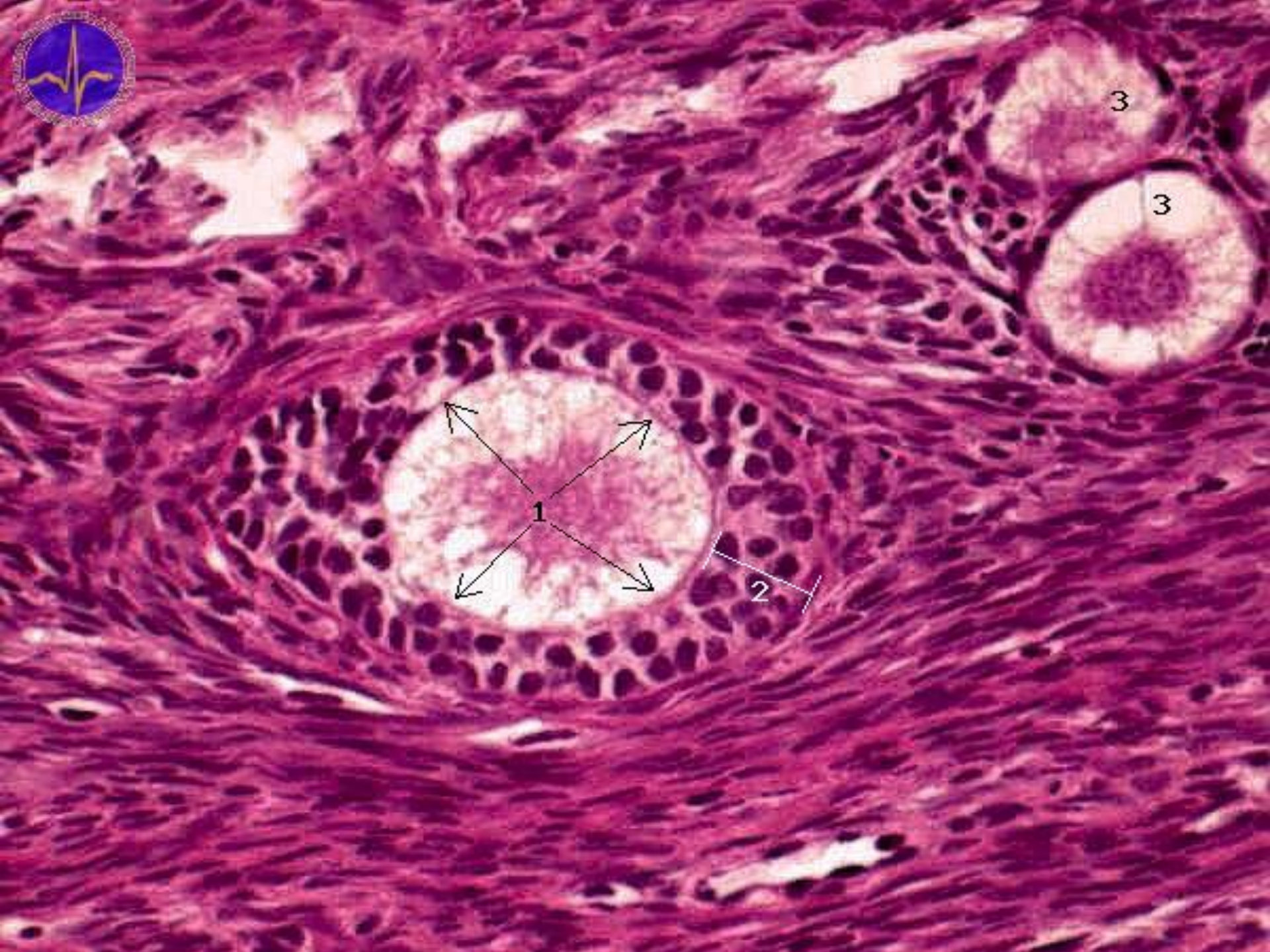
▲ **LM of part of the ovarian cortex.** Markedly cellular connective tissue stroma surrounds primordial (**PF**), primary (**1F**), and secondary (**2F**) ovarian follicles. 295 \times . *H&E*.



▲ **LM of a primordial follicle in the ovarian cortex.** One layer of squamous follicular cells (**FC**) surrounds a primary oocyte (**O**). The oocyte has a large vesicular nucleus. The clear space between oocyte and follicular cells is a cell shrinkage-related preparation artifact. 790 \times . *H&E*.

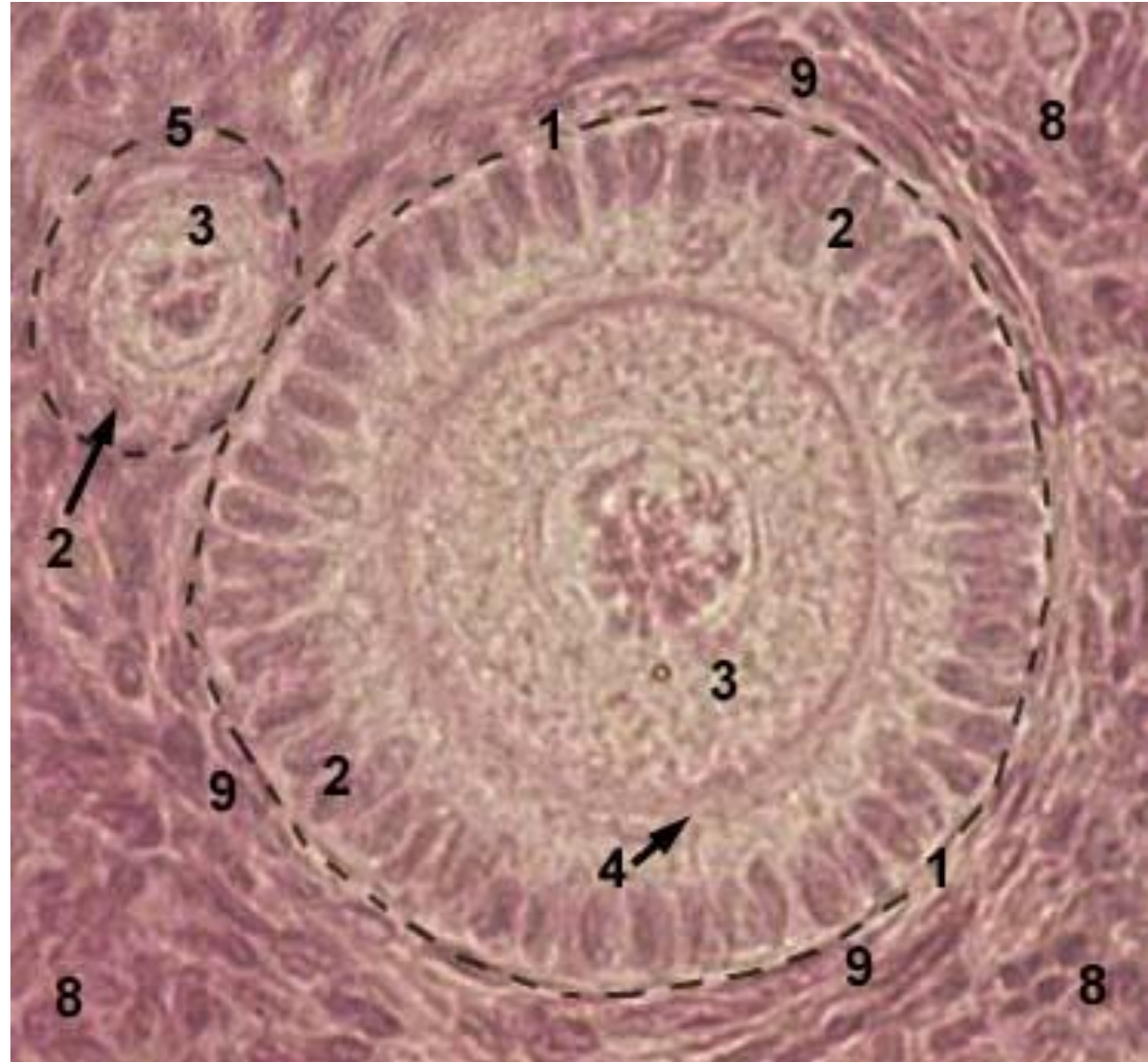

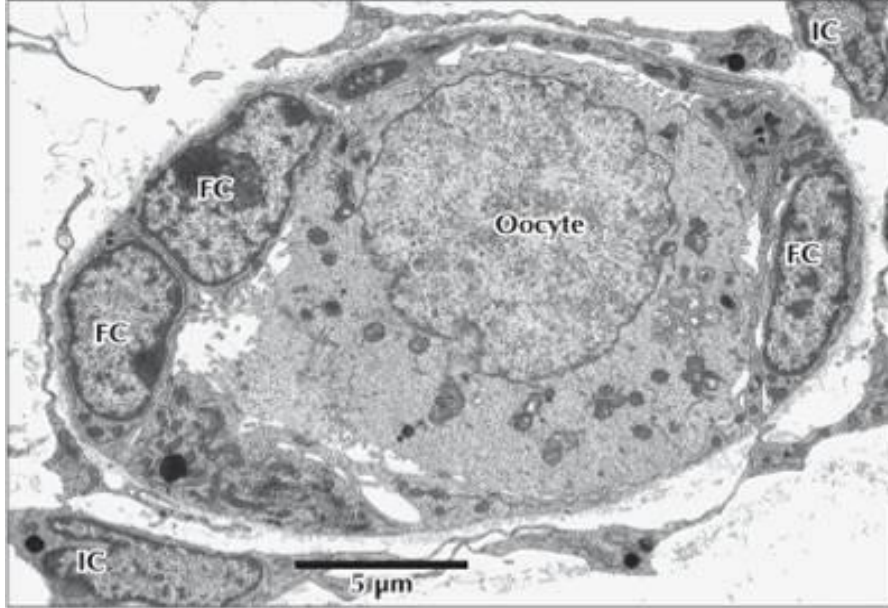
▲ **LM of a primary follicle.** One layer of cuboidal follicular cells (**FC**) envelops an oocyte (**O**). Surrounding stroma is highly cellular and contains elongated cells, some of which will become theca interna cells. The space between oocyte and follicular cells is a preparation artifact. 790 \times . *H&E*.



Primary follicle

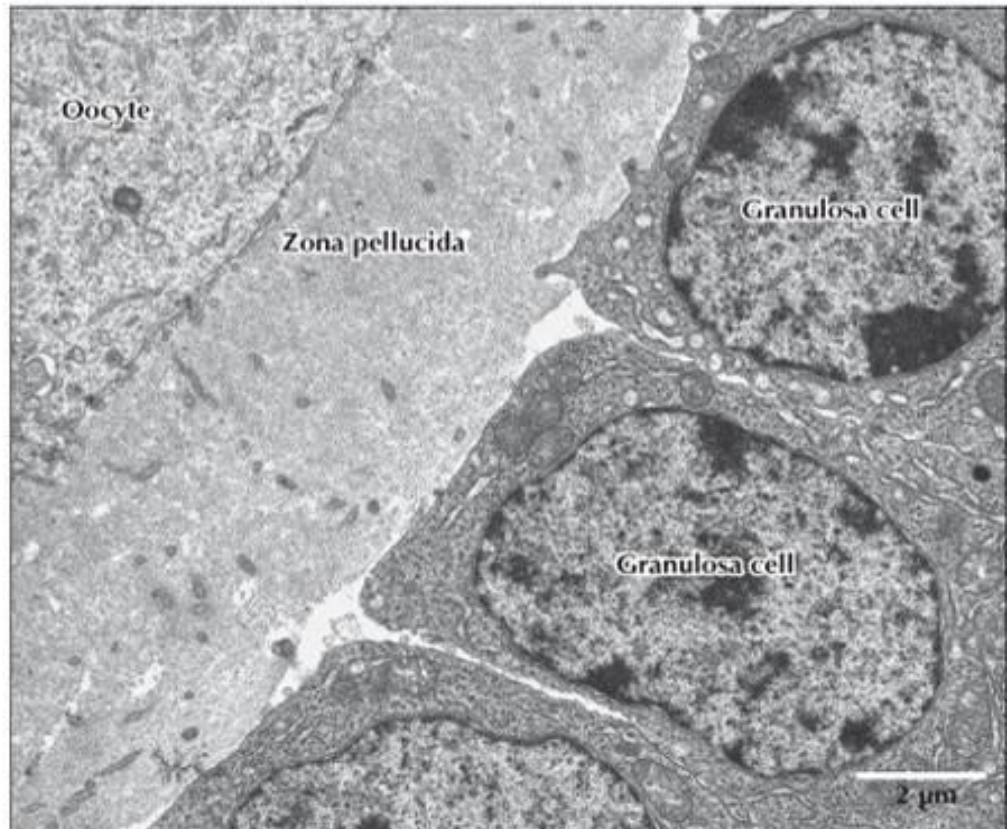
- 1 – folliculus primarius
- 2 – folliculocytum
- 4 – zona pellucida
- 5 – folliculus primordialis
- 8 – textus connectivus interstitialis
- 9 – theca folliculi





◀ **Electron micrograph (EM) of a primordial follicle in a mouse ovary.** Flattened follicular cells (FC) around an oocyte rest on a thin basal lamina; two interstitial cells (IC) are outside the follicle. The oocyte has a smooth surface with occasional small microvilli. Its large euchromatic nucleus has finely dispersed chromatin. A few mitochondria and vesicular structures are seen throughout the relatively pale cytoplasm. 3400×

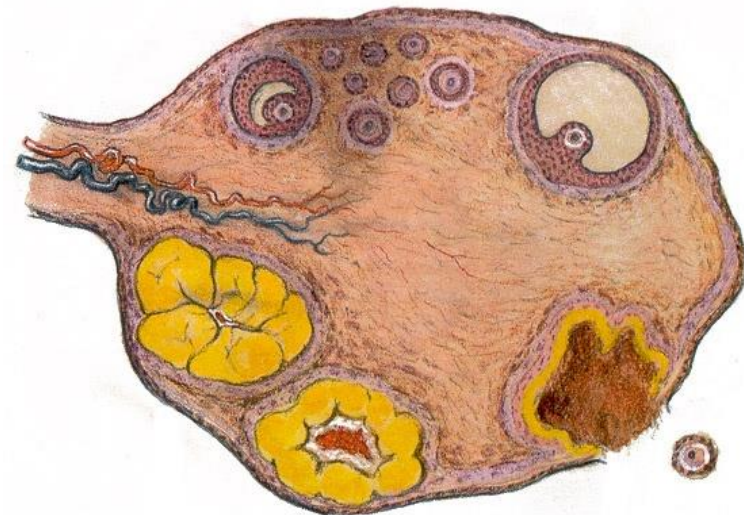
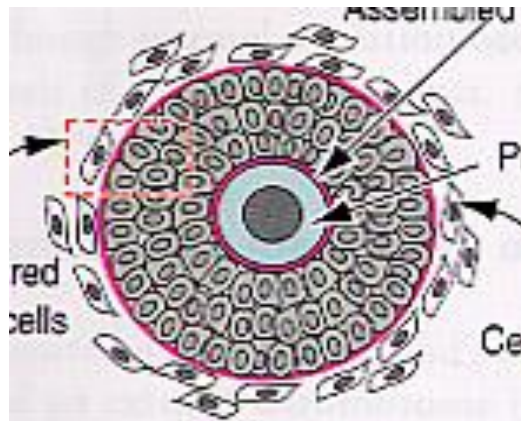
▶ **EM of part of a primary follicle.** The zona pellucida between the oocyte and granulosa cells consists of amorphous material rich in glycoproteins and proteoglycans. It contains profiles of small, irregularly shaped microvilli that emanate from granulosa cells and oocyte. Granulosa cells at this stage contain abundant ribosomes and RER. 6300×



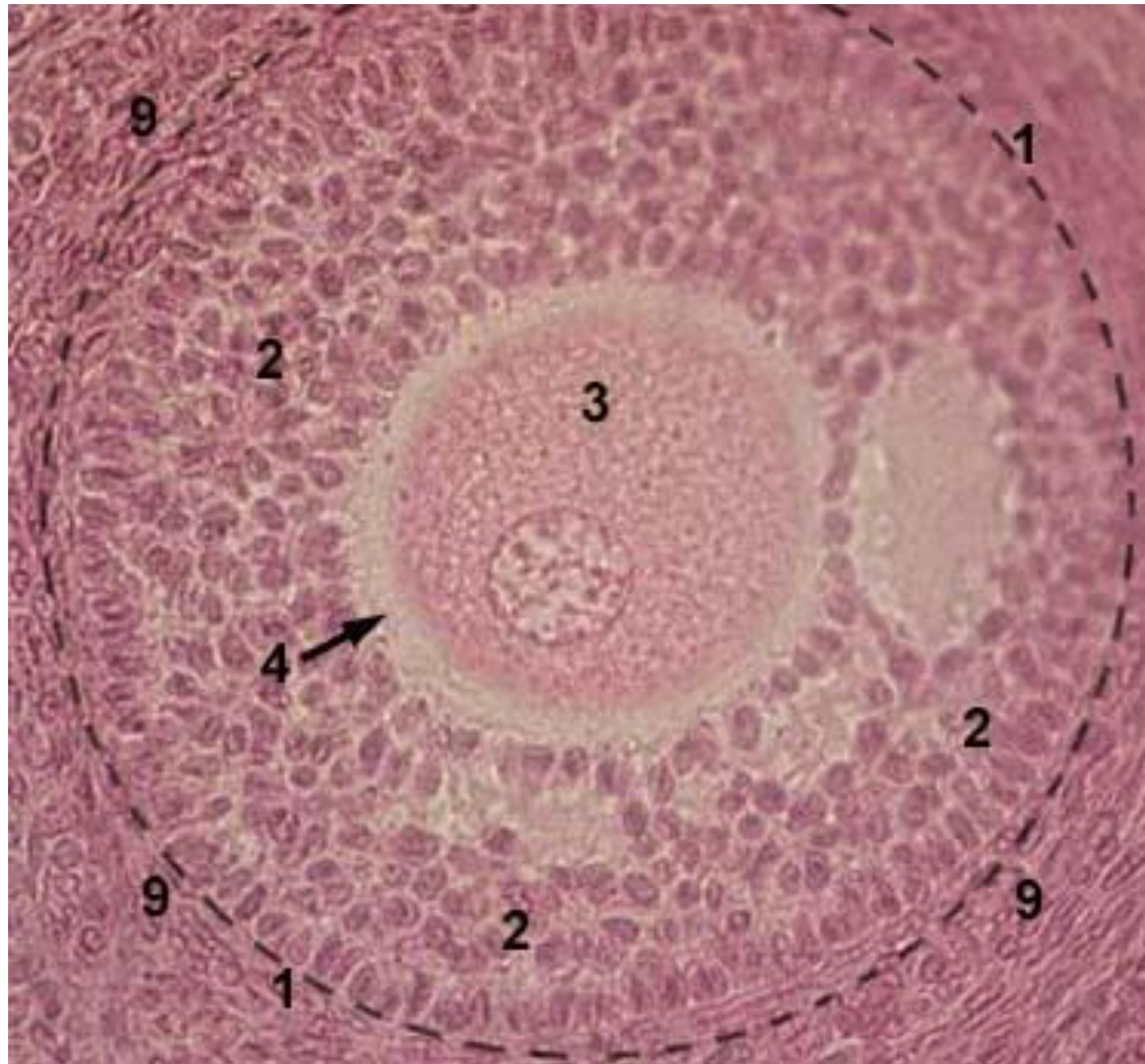
Folliculi ovarici secundarii

Secondary follicles

- **epithelium stratificatum cuboideum**
- prominent basal lamina and zona pellucida
- ***theca folliculi*** (follicular sheath)
 - thickening of adjacent connective tissue and stromal cells



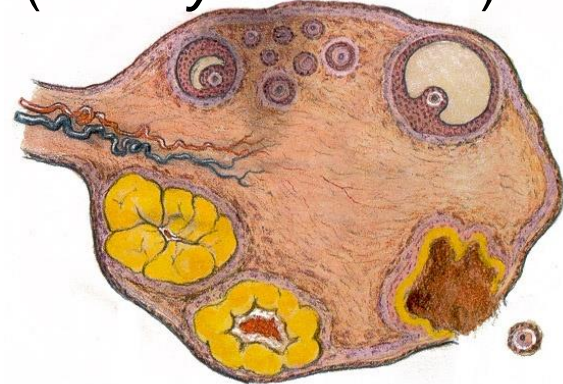
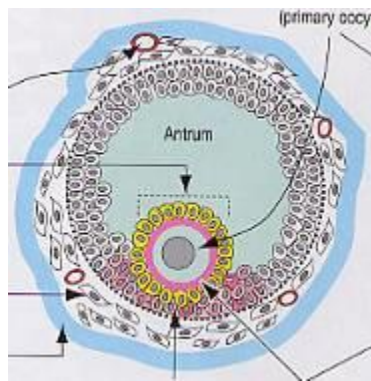
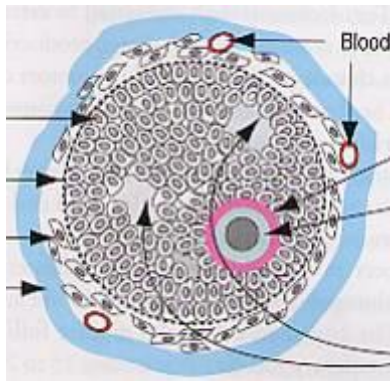
- 1 – folliculus secundarius
- 2 – folliculocytii
- 3 – oocytus
- 4 – zona pellucida
- 9 – theca folliculi

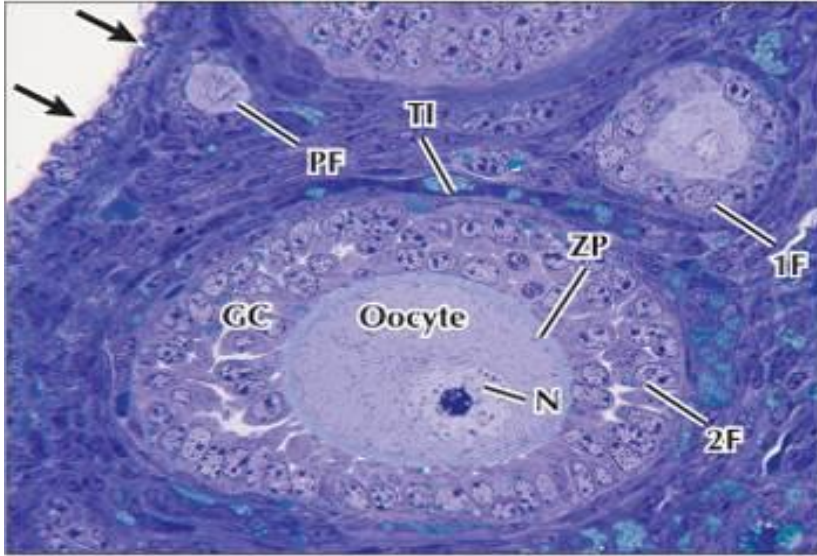


Folliculi ovarici tertiarii / vesiculosi

Tertiary follicles

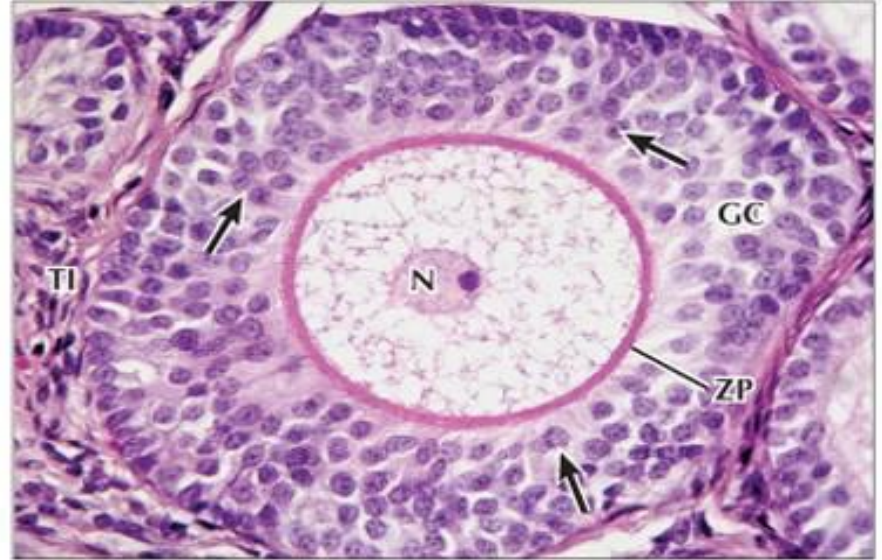
- 2-5 mm
- Call-Exner's bodies (*corpusculum intercellulare*) → cavities between follicular cells → coalesce to form one cavity (*antrum folliculi*) filled with fluid (*liquor folliculi*)
- granulosa cells (*epitheliocytii granulares; folliculocytii granulares*) form stratified epithelium = **granulosa**
- oocyte located peripherally (***cumulus oophorus***) surrounded by *zona pellucida* and outward by granulosa cells (***corona radiata***)
- theca folliculi differentiates into:
 - → **theca interna** → vessels + theca cells (*endocrinocytii thecales*) → estrogens
 - → **theca externa** – connective tissue (*fibrocytii thecales*)



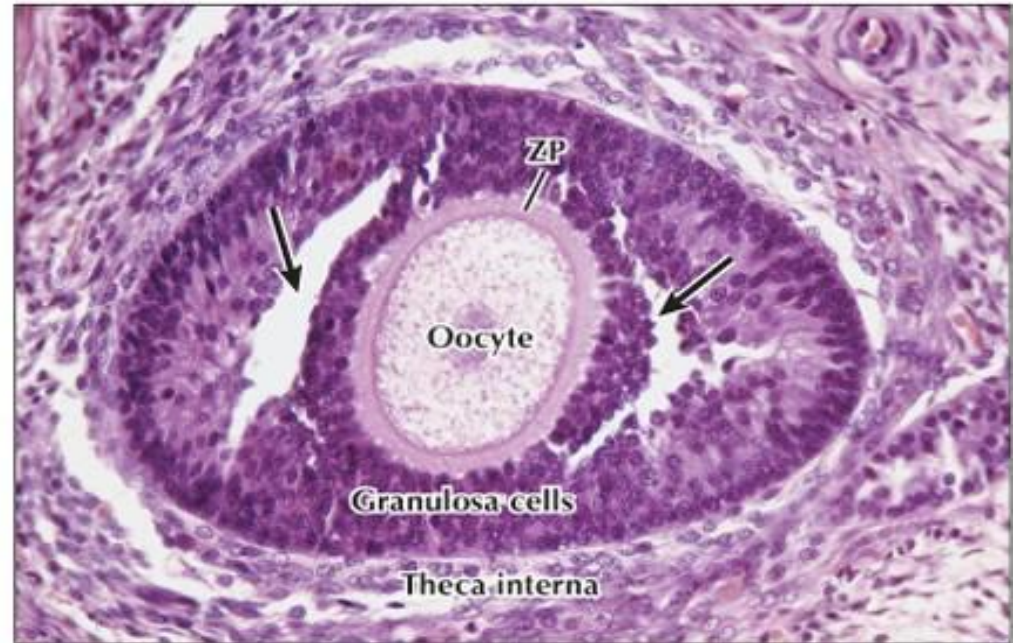

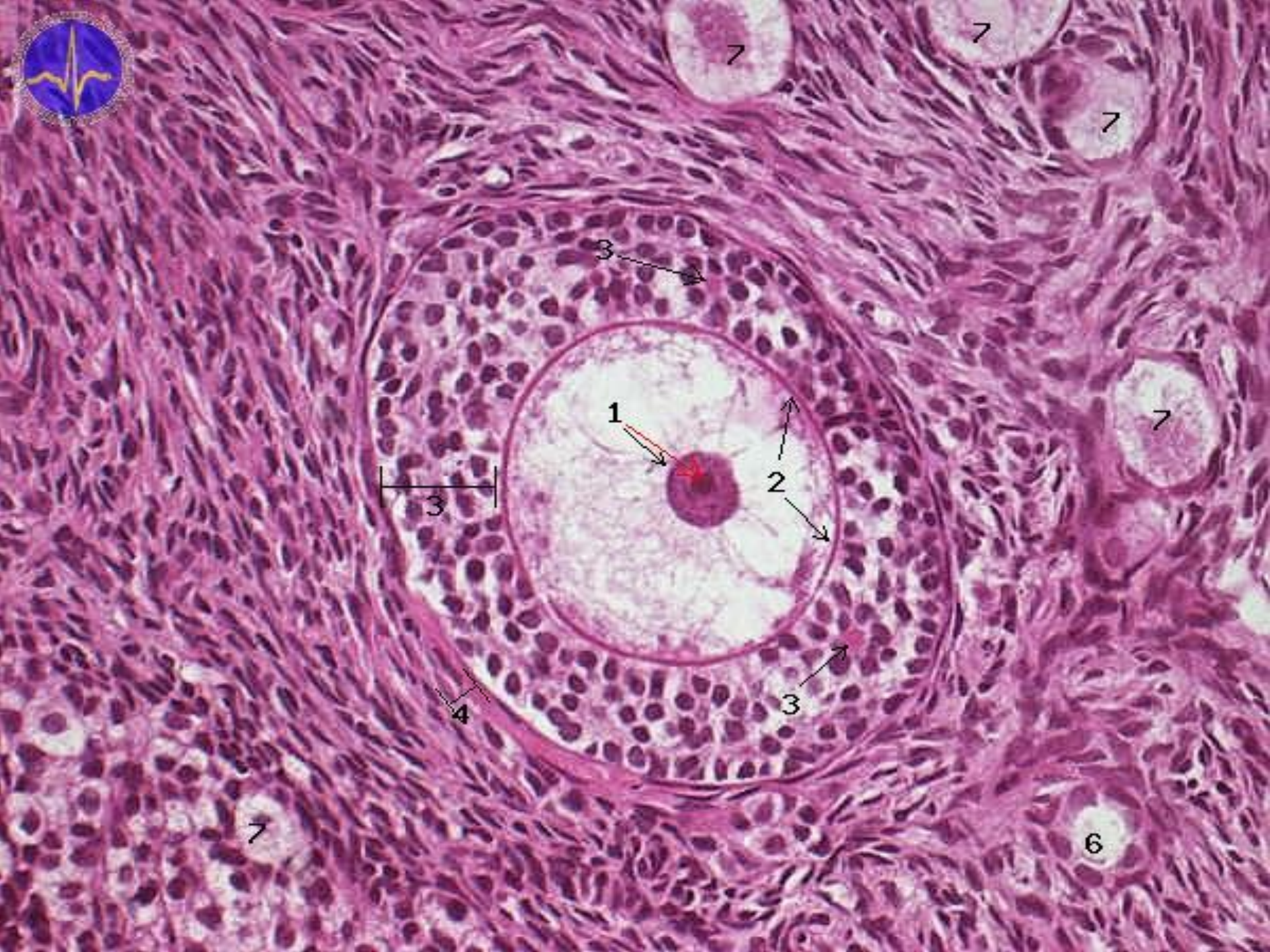
▲ **LM of the cortex of the mouse ovary.** Just under the ovarian surface epithelium (**arrows**) are parts of several follicles at different growth stages, with an oocyte in each follicle. A small primordial follicle (**PF**), a larger primary follicle (**1F**), and a multilaminar secondary follicle (**2F**) are seen. Granulosa cells (**GC**) of the secondary follicle form a stratified layer; those in the other two follicles form a single layer. The oocyte in the secondary follicle has an eccentric euchromatic nucleus (**N**) with a prominent nucleolus. A thin zona pellucida (**ZP**) surrounds the oocyte's plasma membrane. Theca interna (**TI**) cells with small clear lipid droplets are in surrounding stroma close to the follicles. 420 \times . Toluidine blue, semithin plastic section.

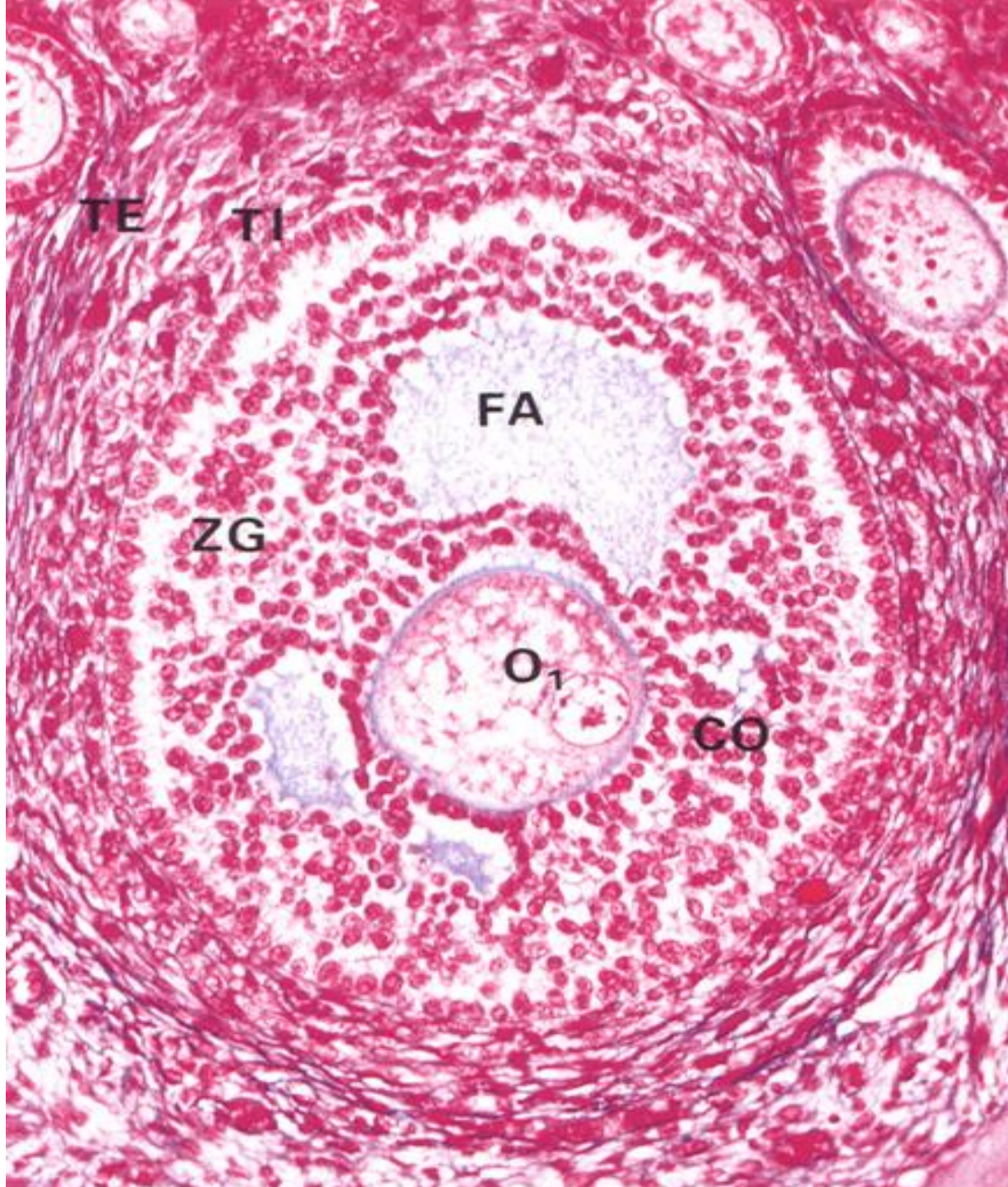
► **LM of a late-term secondary follicle.** Granulosa cells surround the oocyte and its zona pellucida (**ZP**). Next to the outer layer of granulosa cells is a sheath of stromal cells: the theca interna. Several irregular intercellular spaces, or antral lakes (**arrows**), are among the granulosa cells. As the spaces accumulate fluid, they enlarge, become confluent, and give rise to a cavity—the follicular antrum. 270 \times . H&E.

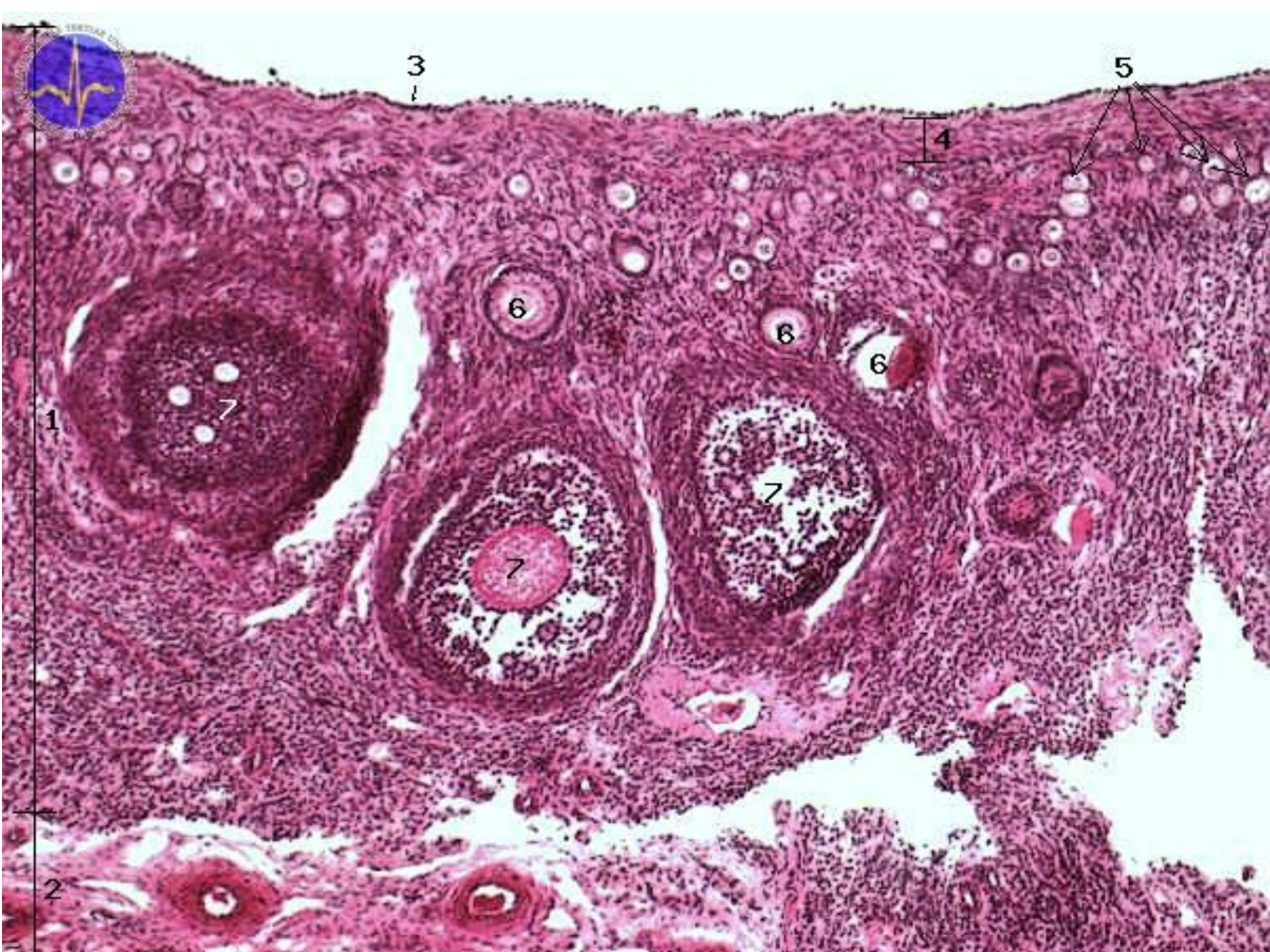


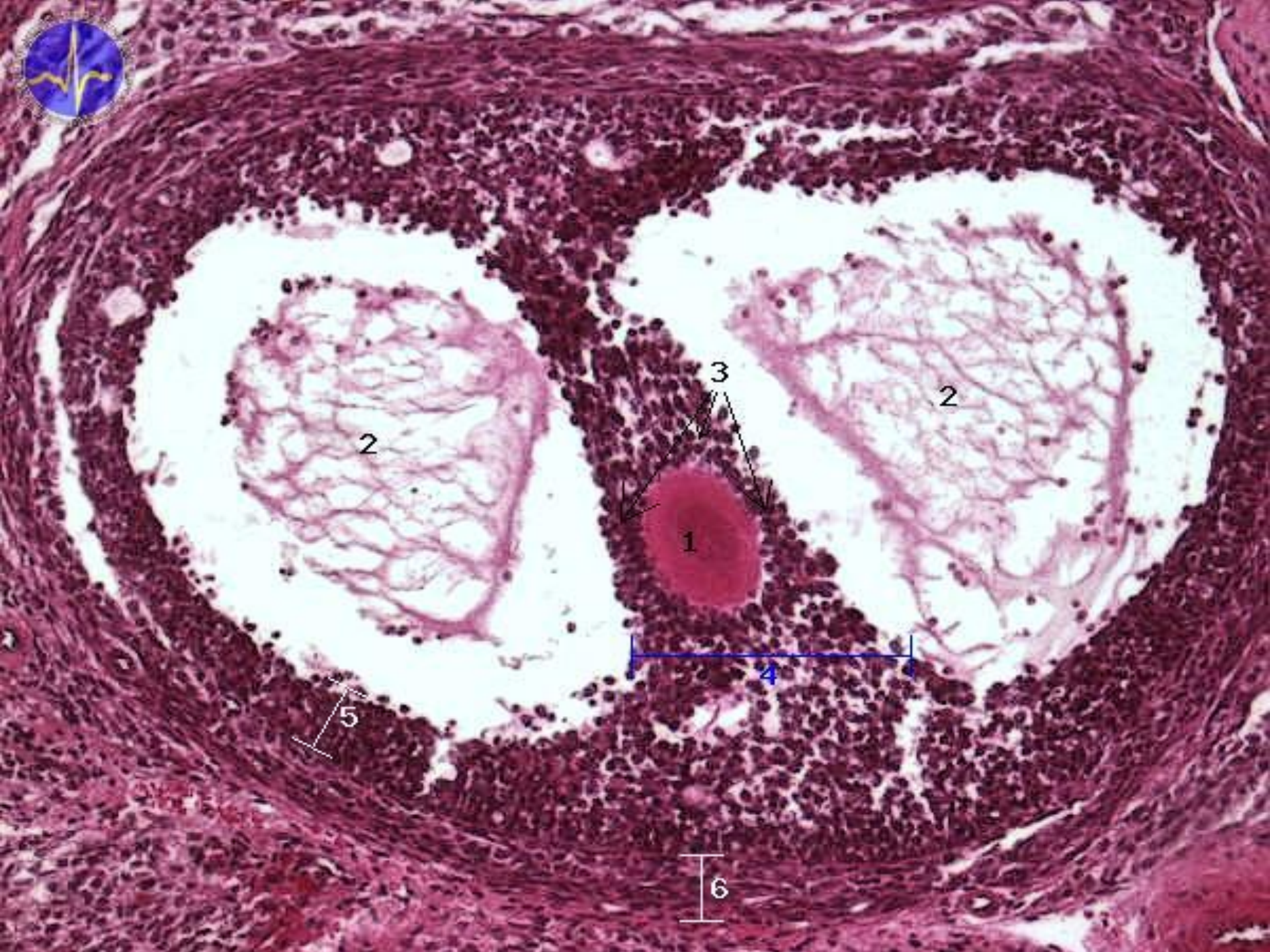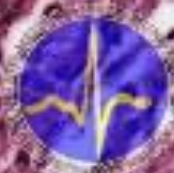▲ **LM of a preantral secondary follicle.** The euchromatic nucleus (**N**) of the oocyte has a small, prominent eccentric nucleolus. A densely stained, eosinophilic zona pellucida (**ZP**) surrounds pale vesicular cytoplasm. Several layers of granulosa cells (**GC**), some undergoing mitosis (**arrows**), lie concentrically around the oocyte. Surrounding stroma shows early organization into a theca interna (**TI**). 375 \times . H&E.

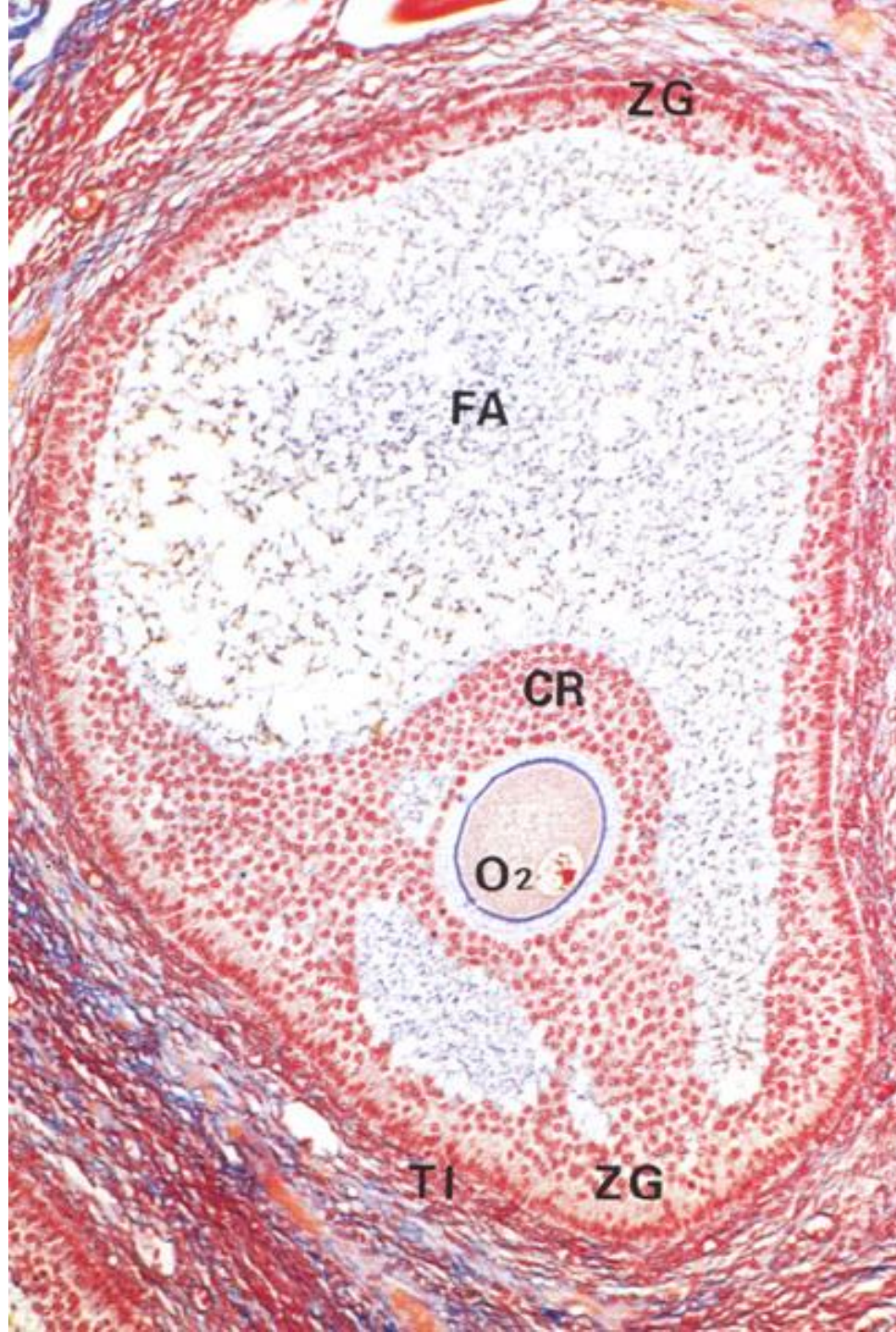


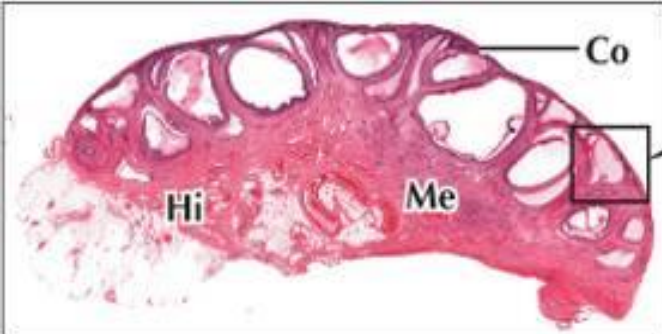




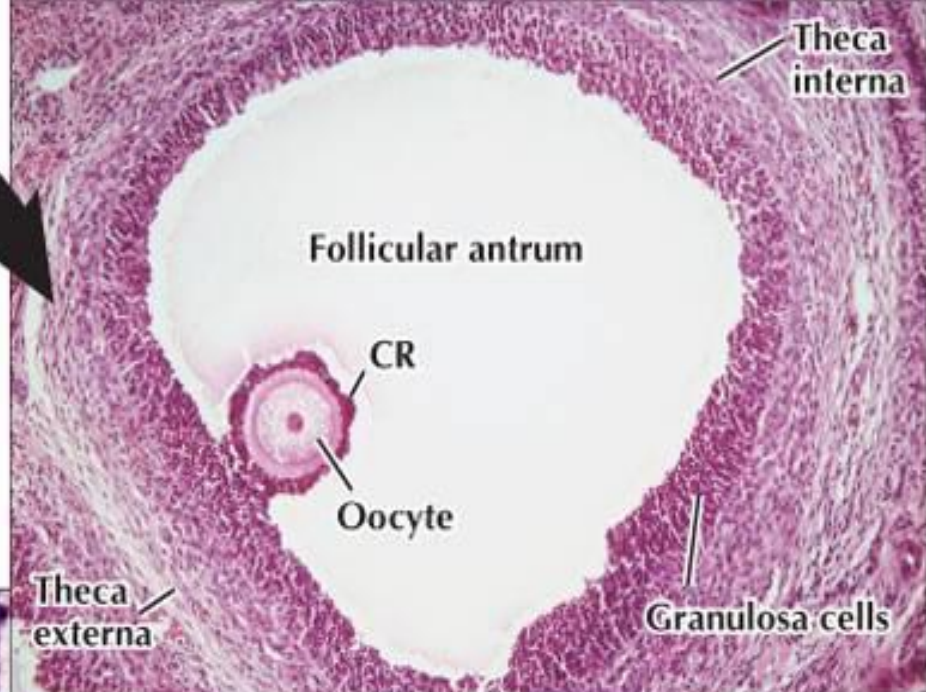


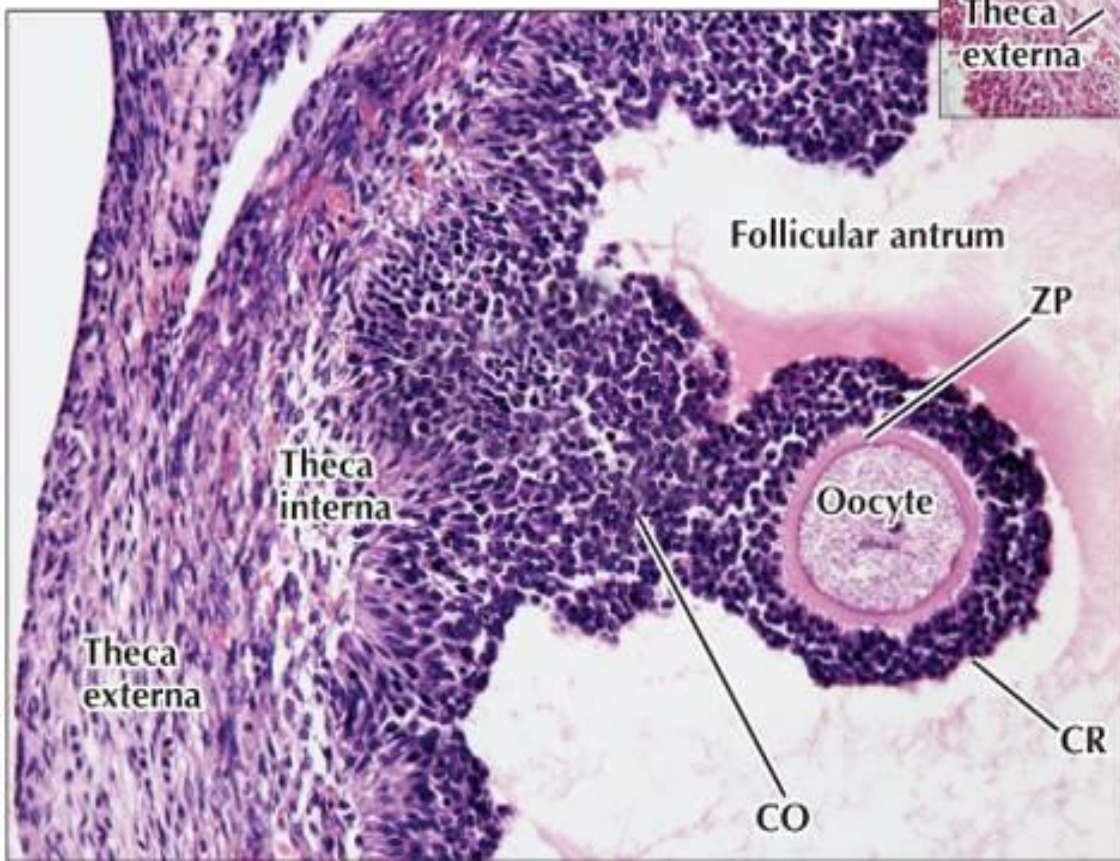




▲ **Low-magnification LM of a mature ovary from a dog.** The outer cortex (**Co**) shows follicles at different maturation stages. The inner medulla (**Me**) contains several blood vessels that enter and emerge from the hilum (**Hi**). 5×. H&E.



▲ **LM of a Graafian follicle.** On one side of the follicle is the oocyte, surrounded by a thin layer of granulosa cells—the corona radiata (**CR**). The oocyte and corona radiata protrude into a large follicular antrum. Around the antrum is a stratified epithelium of granulosa cells, which are enveloped by the thecae interna and externa. 100×. H&E.

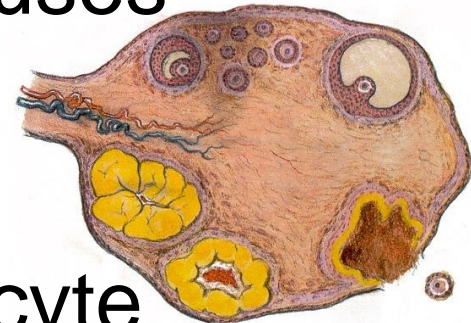


◀ **Higher magnification LM of part of a Graafian follicle.** The oocyte and zona pellucida (**ZP**) are surrounded by a corona radiata (**CR**) that protrudes into a large follicular antrum. The cumulus ophorus (**CO**) is a mass of granulosa cells. The surrounding theca has differentiated into two layers—interna and externa. The antrum contains some flocculent eosinophilic precipitate. 176×. H&E.

Folliculi ovaricia maturi

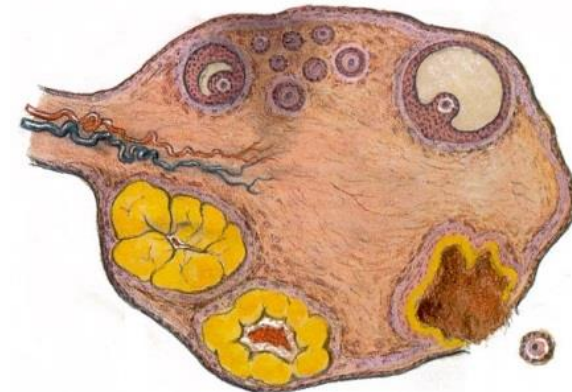
Matured follicles (Graafian)

- 2-2,5 cm
- oocyte located peripherally (***cumulus oophorus***) and adjacent *granulosa* forms ***corona radiata***
- protrudes on surface (*stigma folliculare*)
- thinned capsule and suppressed blood supply
- rapid increase of LH blood level causes rupture of follicle
- finishes 1st meiotic division and continues to the 2nd → secondary oocyte
- oocyte and corona radiata are released



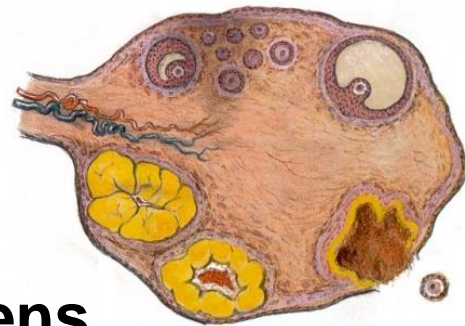
Luteogenesis

- haemorrhagic body (*corpus haemorrhagicum / rubrum*)
 - antrum folliculi filled with blood
- **corpus luteum**
 - corpus luteum **menstruationis**
 - 10-12 days (until 24th-26th day of menstrual cycle) → luteolysis → nothing 😊
 - corpus luteum **graviditatis**
 - grows under influence of **hCG** (produced from cytotrophoblast)
 - till the end of 4th month of pregnancy → corpus albicans
- corpus albicans
 - fibrous scar, uneven ovarian surface
 - remains for long time
 - after corpus luteum of pregnancy
 - or after degenerated follicles

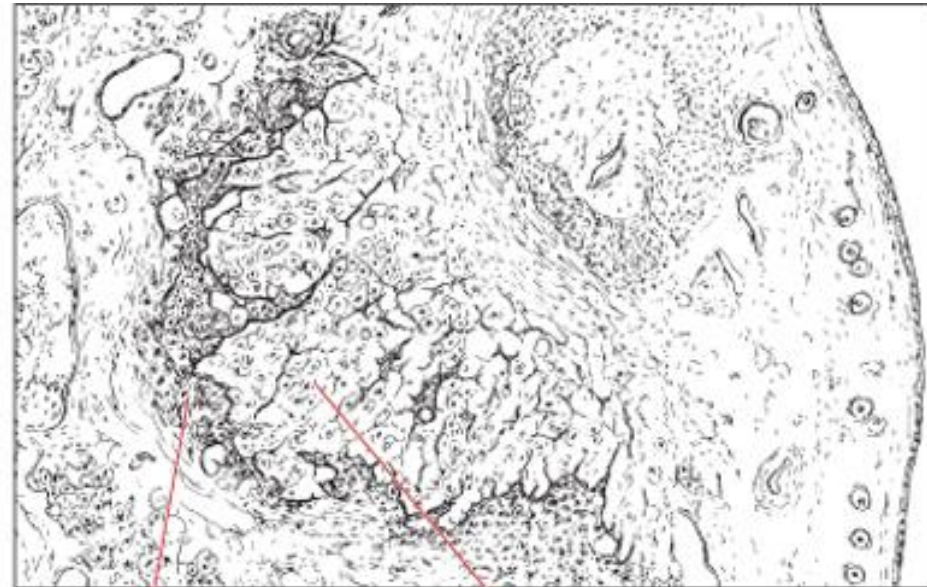
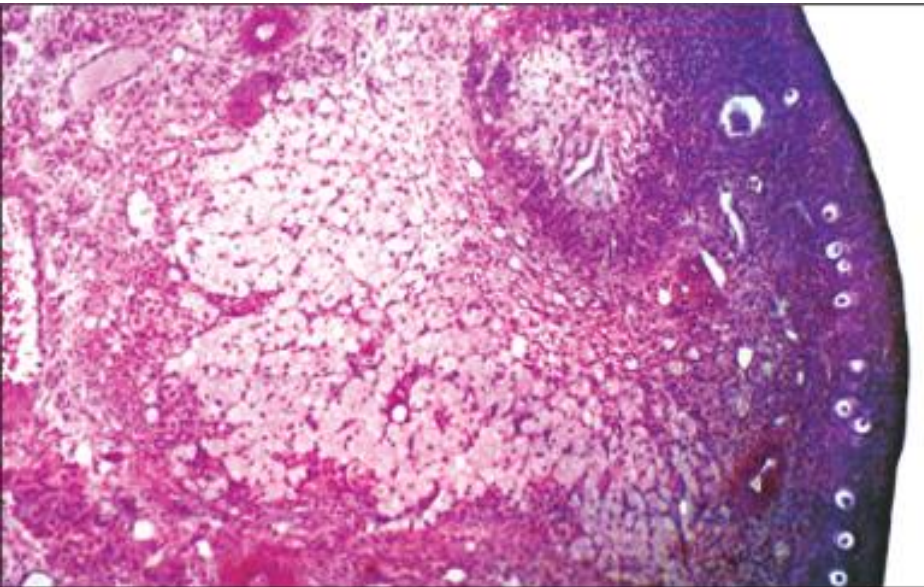


Corpus luteum

- one-time antrum folliculi contains blood coagulum → converts to the fibrous tissue and constricts remained parts of follicle change after ovulation
- expansion of vessels into granulosa (previously without vessels)
- granulosa lutein cells (*granulosoluteocytī*)
 - production of estrogens from androgens (using aromatase)
 - formation of receptors for LH
 - production of **progesterone**
- theca-lutein cells (*thecaluteocytī*)
 - production of **progesterones** and **androgens**
- progesterone necessary for differentiation of uterine mucosa and persistence of pregnancy
- fibrous capsule (*fibroblasti thecales*)



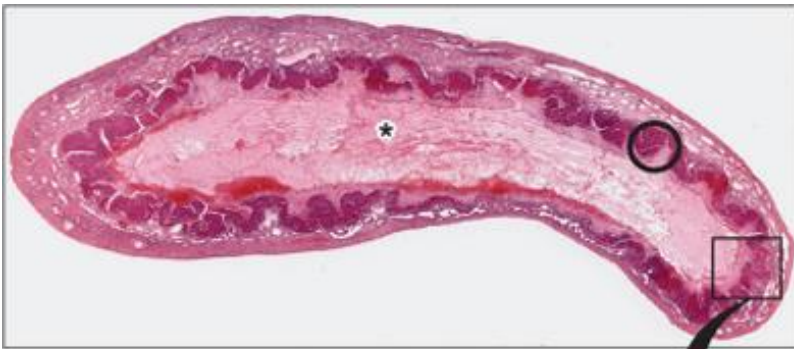Corpus luteum



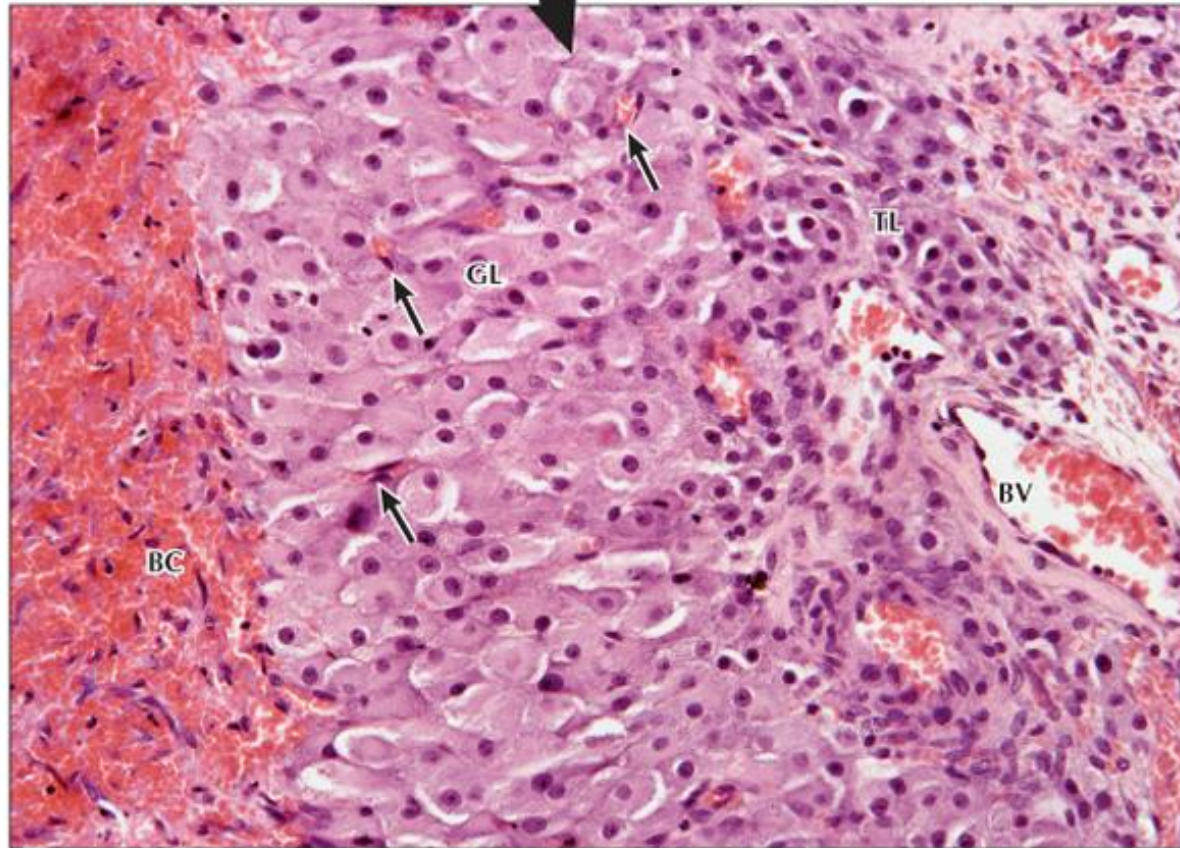
Theca lutein cells Granulosa lutein cells

Tallitsch: Histology: An Identification Manual.

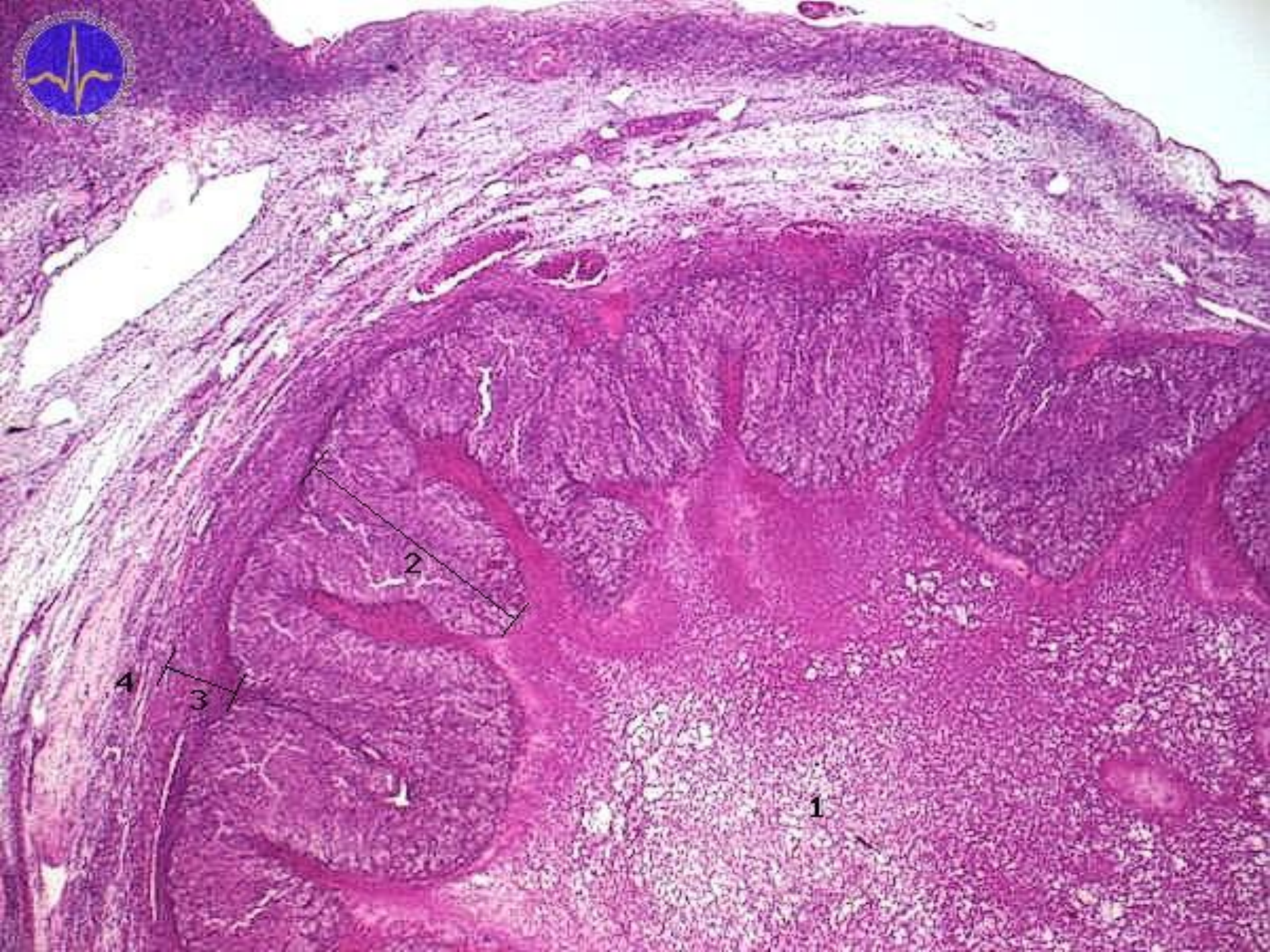Copyright © 2008 by Mosby, an imprint of Elsevier, Inc. All rights reserved.

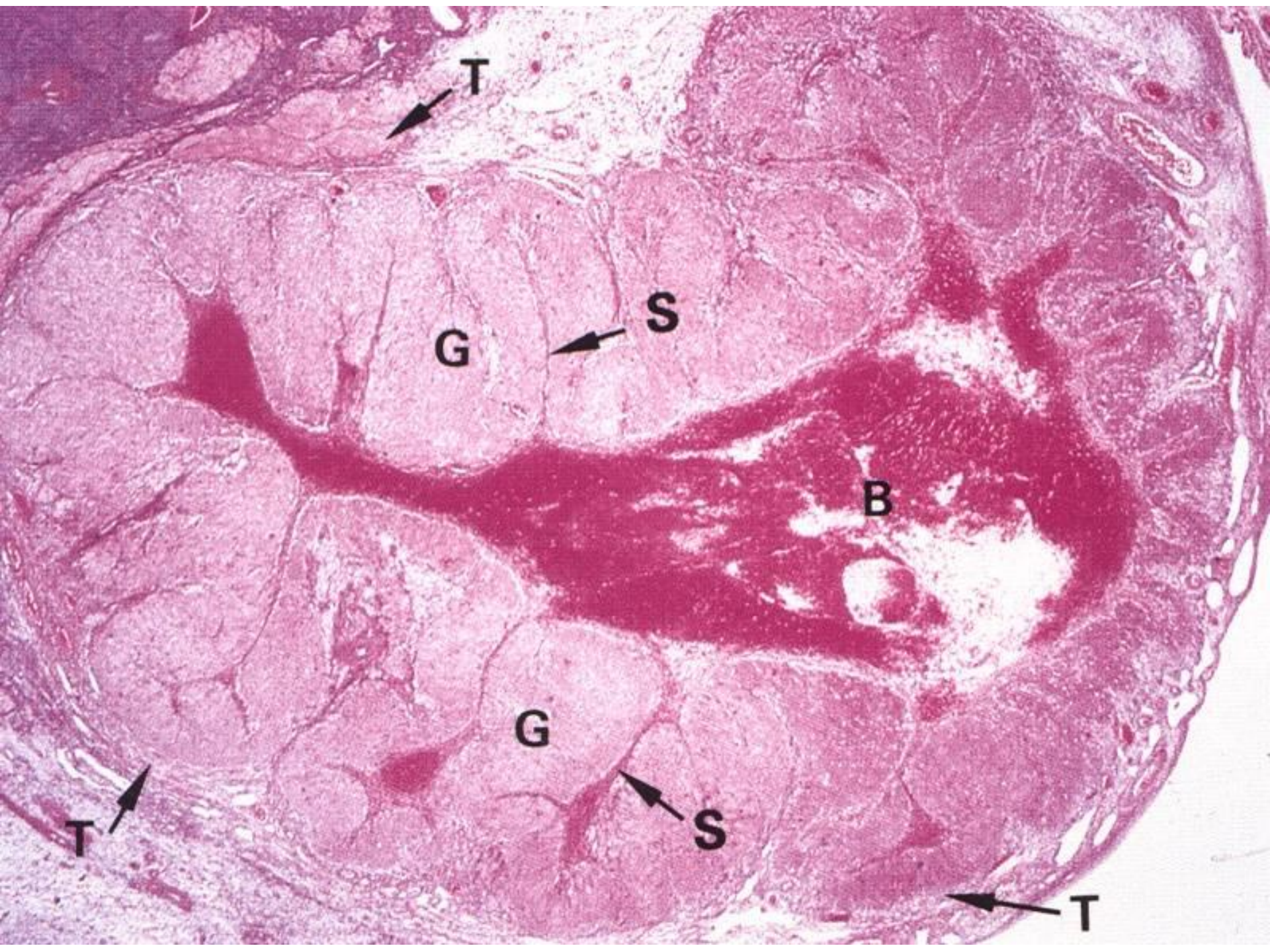


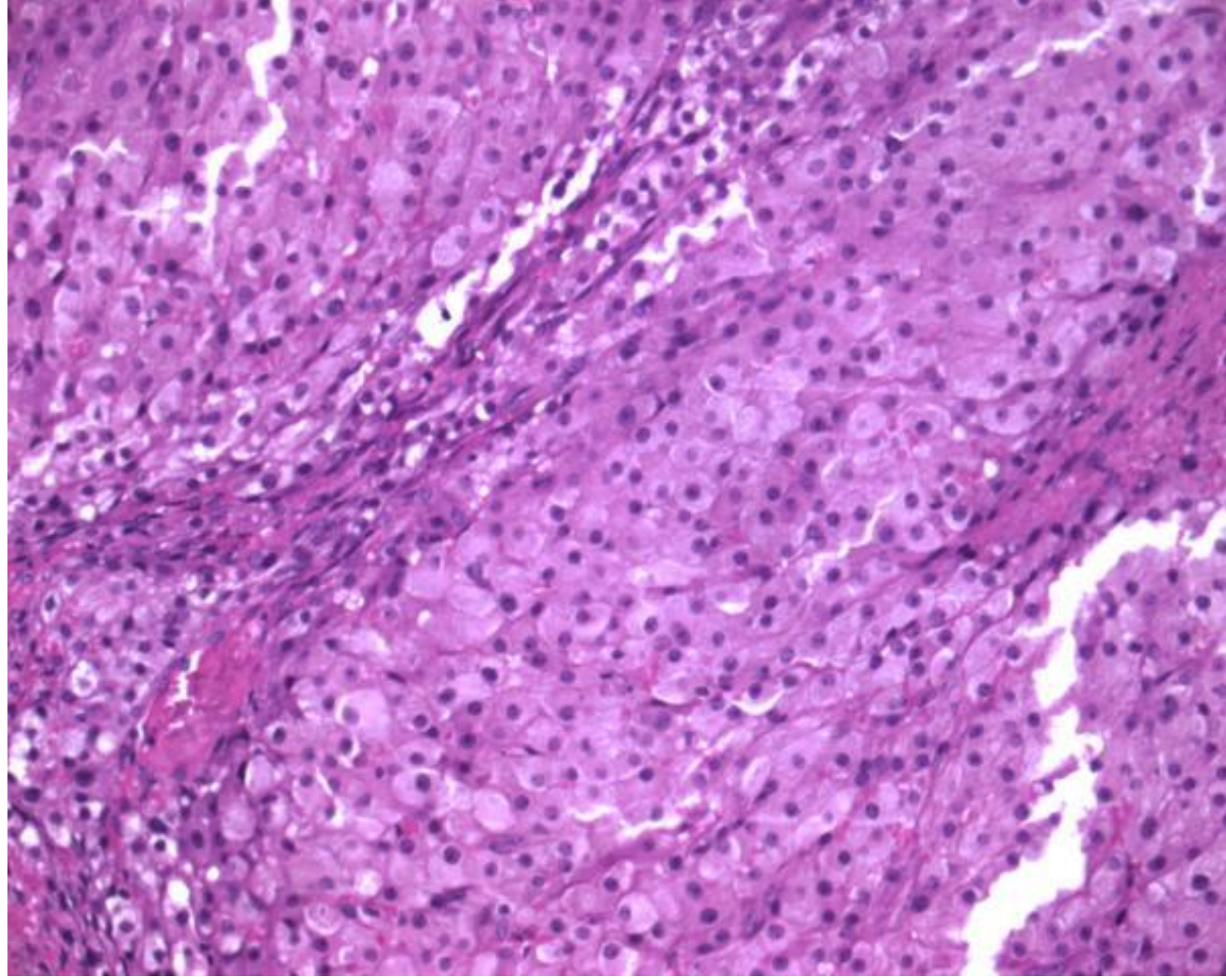
◀ **Low-power LM of the ovary.** The section passes through a corpus luteum. Its outer aspect is highly folded (**circle**) and contains tightly packed granulosa and theca lutein cells, which surround a central cavity (*) filled with coagulated blood and fibrous scar tissue. 6.5×. H&E.



▲ **LM of part of the corpus luteum.** The large, polyhedral granulosa lutein cells (GL) have round nuclei and pale-staining cytoplasm. The cells encroach on a fibrin-containing blood-filled cavity (BC). Peripherally aggregated theca lutein cells (TL) are smaller and have more darkly stained nuclei than do granulosa lutein cells. Blood vessels (BV) are abundant peripherally; capillaries (**arrows**) invade the granulosa layer. 250×. H&E.







Ovarian cycle

- follicular phase (1th-13th day)
 - maturation of follicles
- ovulation (14th day)
 - rupture of matured Graafian follicle
- luteal phase (15th-28th day)
 - corpus luteum period

Hormonal regulation

- **FSH** (follicle stimulating hormone)
 - anterior lobe of pituitary gland
 - growth of follicles, maturation of dominant follicle, estrogen production
- **LH** (luteinizing hormone)
 - final maturation of primary oocyte and begin of 2th division phase
 - induction of ovulation, gestagens production
- hormone production under control of **GnRH** (gonadotropin-releasing hormone)
 - hypothalamus

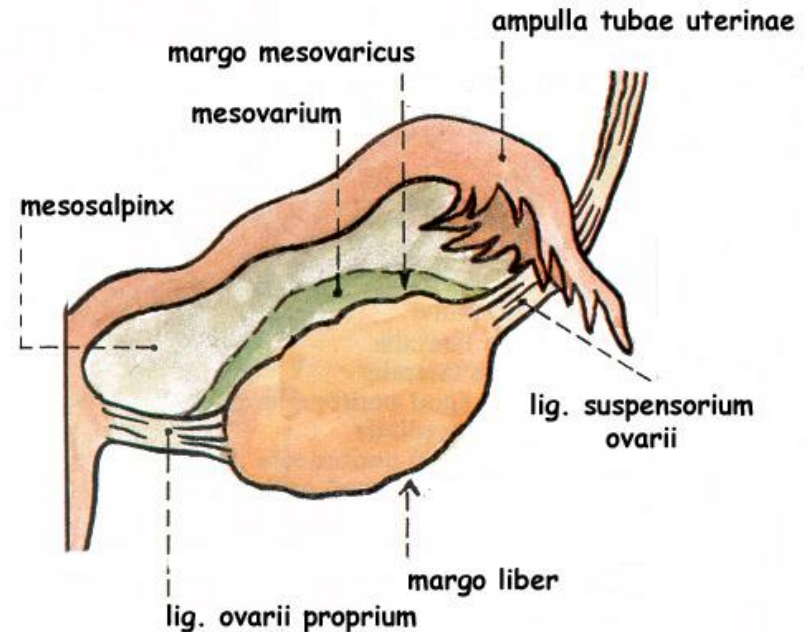
Follicle maturation

- follicle development (3-6 months) – from primordial to tertiary follicle (gonadotropin-independent)
- follicle maturation (gonadotropin-dependent)
 - theory of the dominant follicle
 - 10-20 early-stage tertiary follicles under influence of FSH mature → selected 1 (exceptionally 2) with higher sensitivity to FSH → estrogen production decreases by negative feedback the secretion of FSH + secretion of inhibin (decreases production of FSH) → decreasing level of FSH can maintain the most sensitive follicle, the rest degenerates
- atresia (degeneration) of follicles
 - 5th month: 7.000.000 follicles
 - birth: 1.000.000 follicles
 - puberty: 400.000 follicles
 - degeneration in adulthood: monthly 1.000 (after 35th year of age even more)
 - menopause: 1.000 follicles

Uterine tube

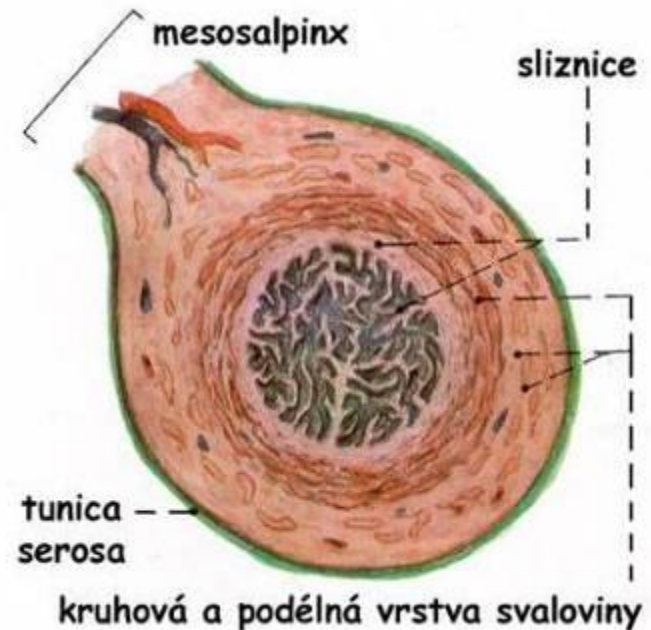
Tuba uterina Falloppii; Salpinx

- parts: ostium abdominale, infundibulum, ampulla, isthmus, pars uterina, ostium uterinum
- opened to the abdominal cavity
- fimbriae
 - the longest fimbria ovarica extends up to the ovary
- 15 cm
- fertilization and first developmental stages of embryo
- transport and nutrition of embrya (4 days)



Uterine tube – *structure* 1.

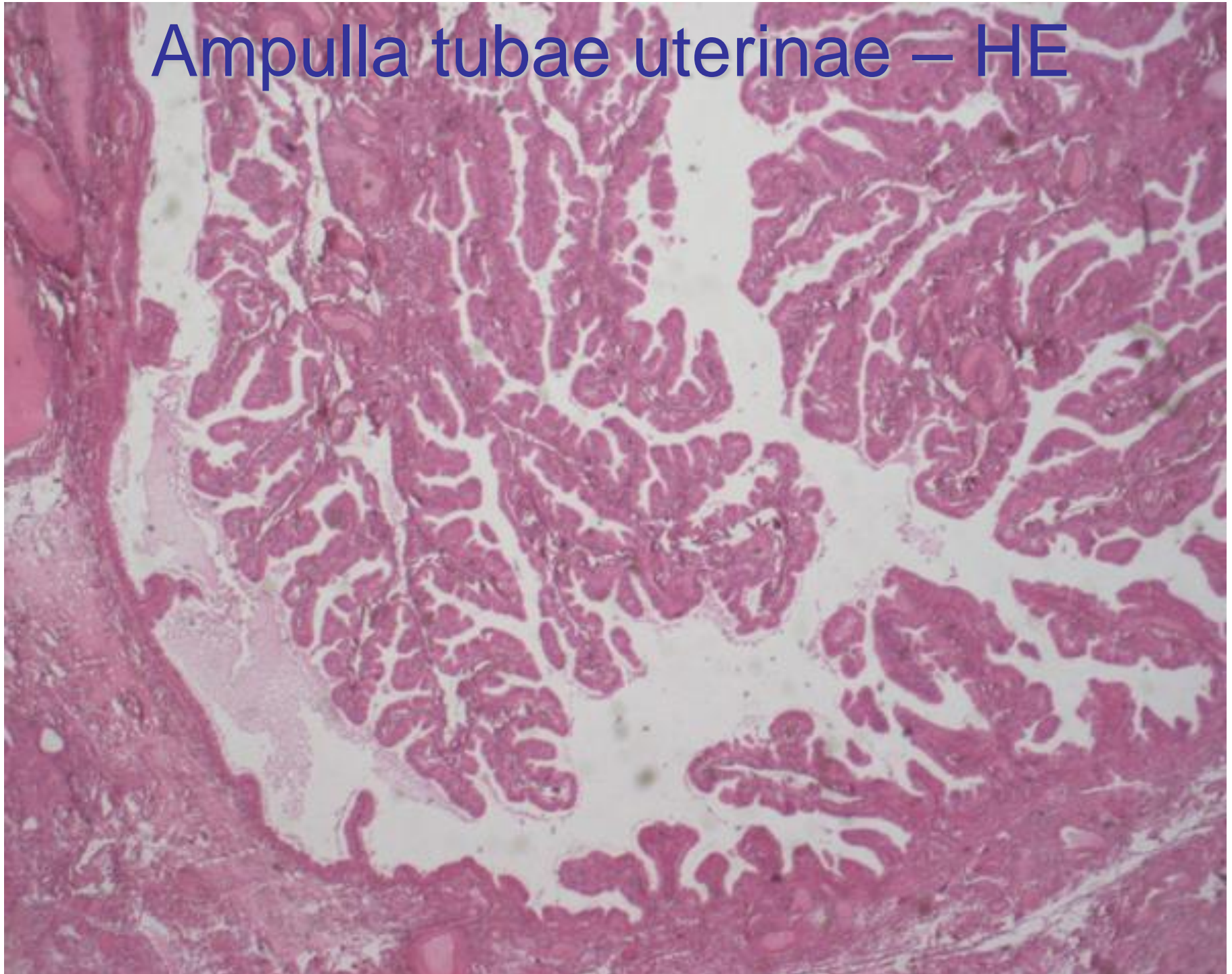
- tunica mucosa
 - simple columnar epithelium
 - folds (*plicae tubariae*), decreasing toward uterus
 - secretory cells (*epitheliocytus tubarius*)
 - protection and nutrition of ovum, production of tubar secretion
 - ciliated cells (*epitheliocytus ciliatus*)
 - movement of secretion and ovum toward uterus
- tunica muscularis: increases
 - inner – circular
 - outer – longitudinal
- tunica serosa (= peritoneum)
 - intraperitoneal organ

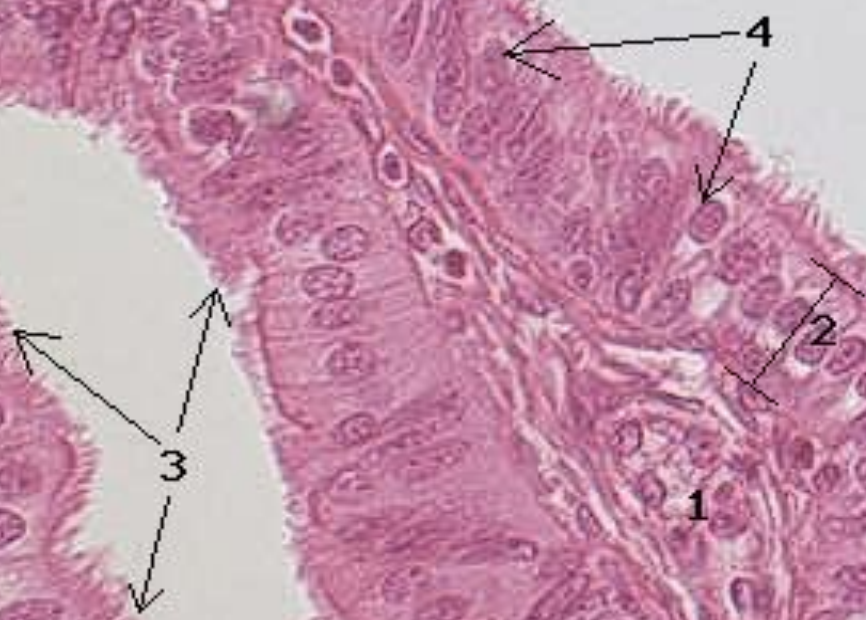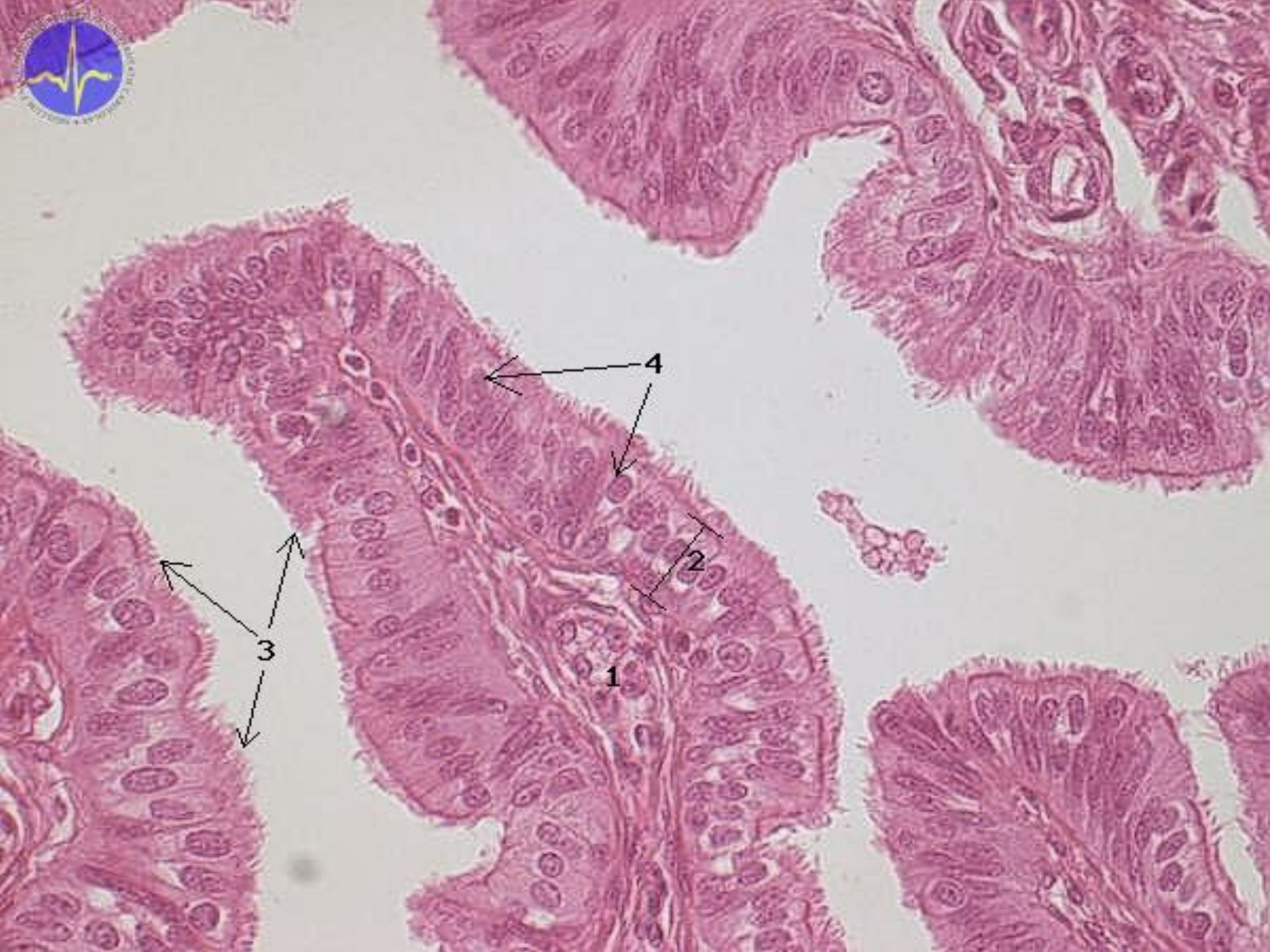

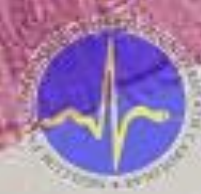
Uterine tube – *structure 2.*

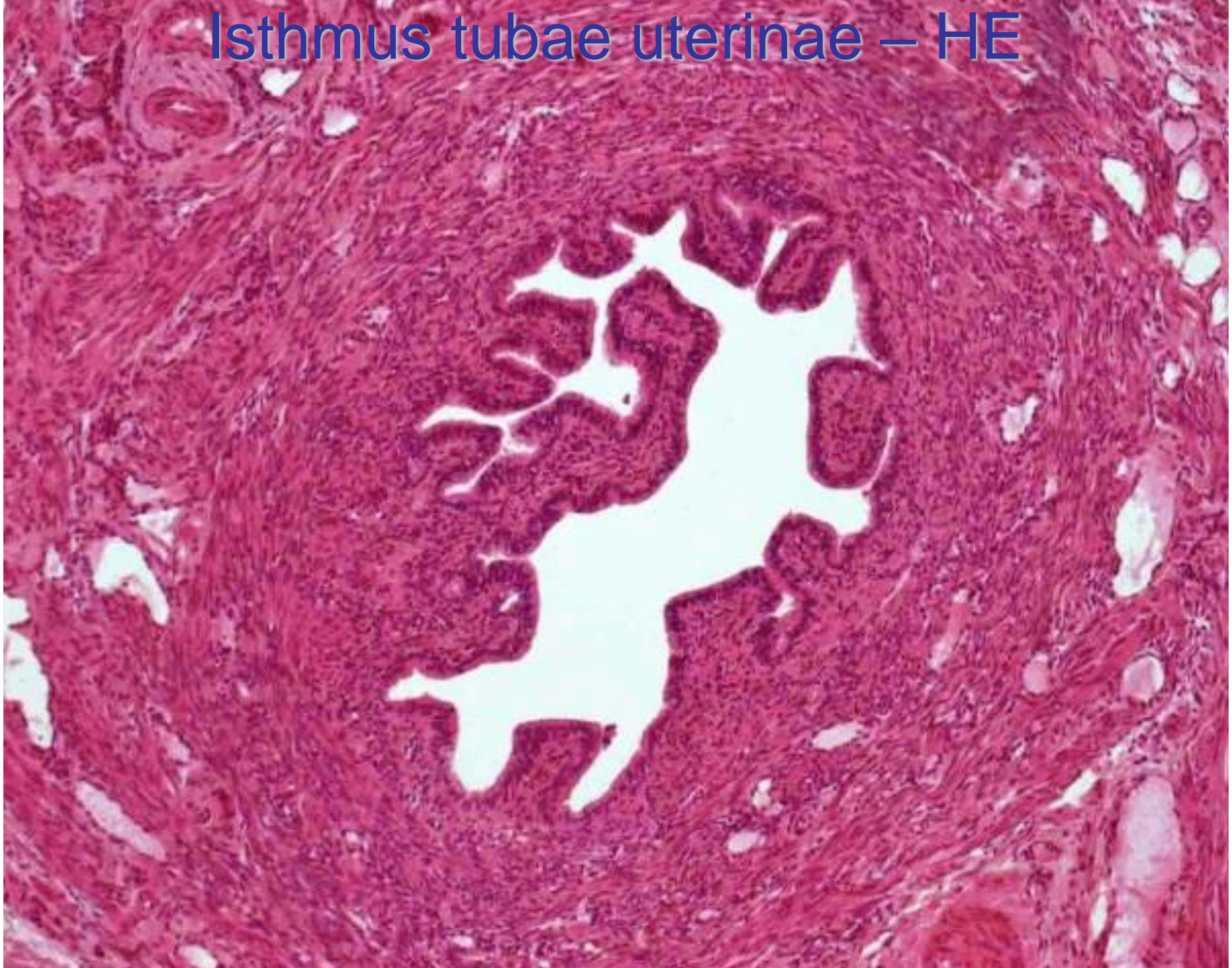	Folds	Ciliated cells	Secretory cells	Muscular layers
Infundibulum	+++	+++	+	+
Ampulla	+++	+++	++	++
Isthmus	++	++	+++	+++
Pars uterina	+	+	+++	+++

Ampulla tubae uterinae – HE



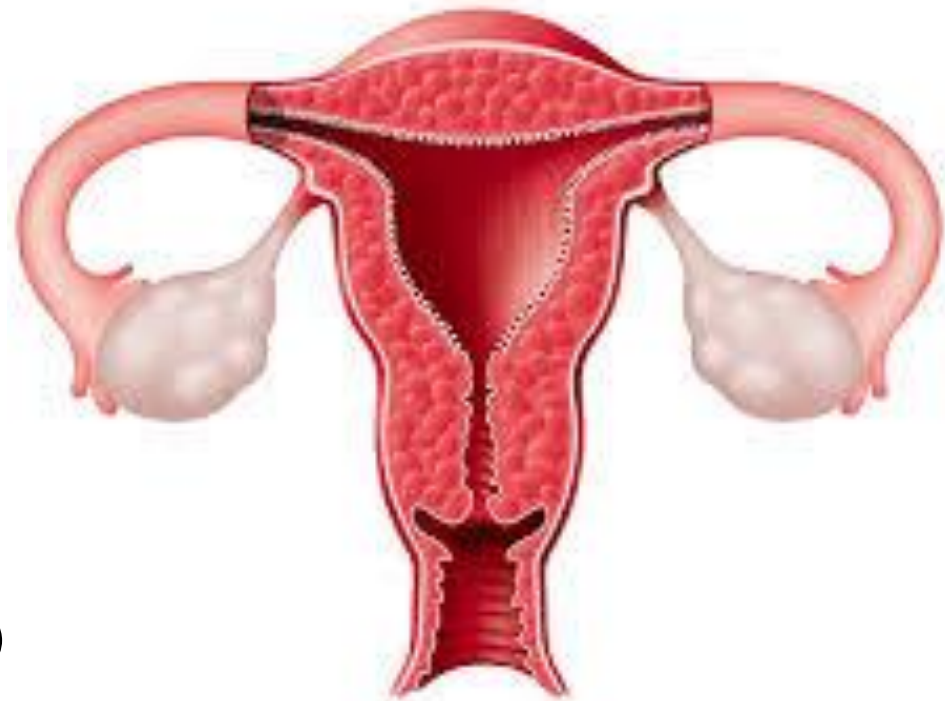

Isthmus tubae uterinae – HE

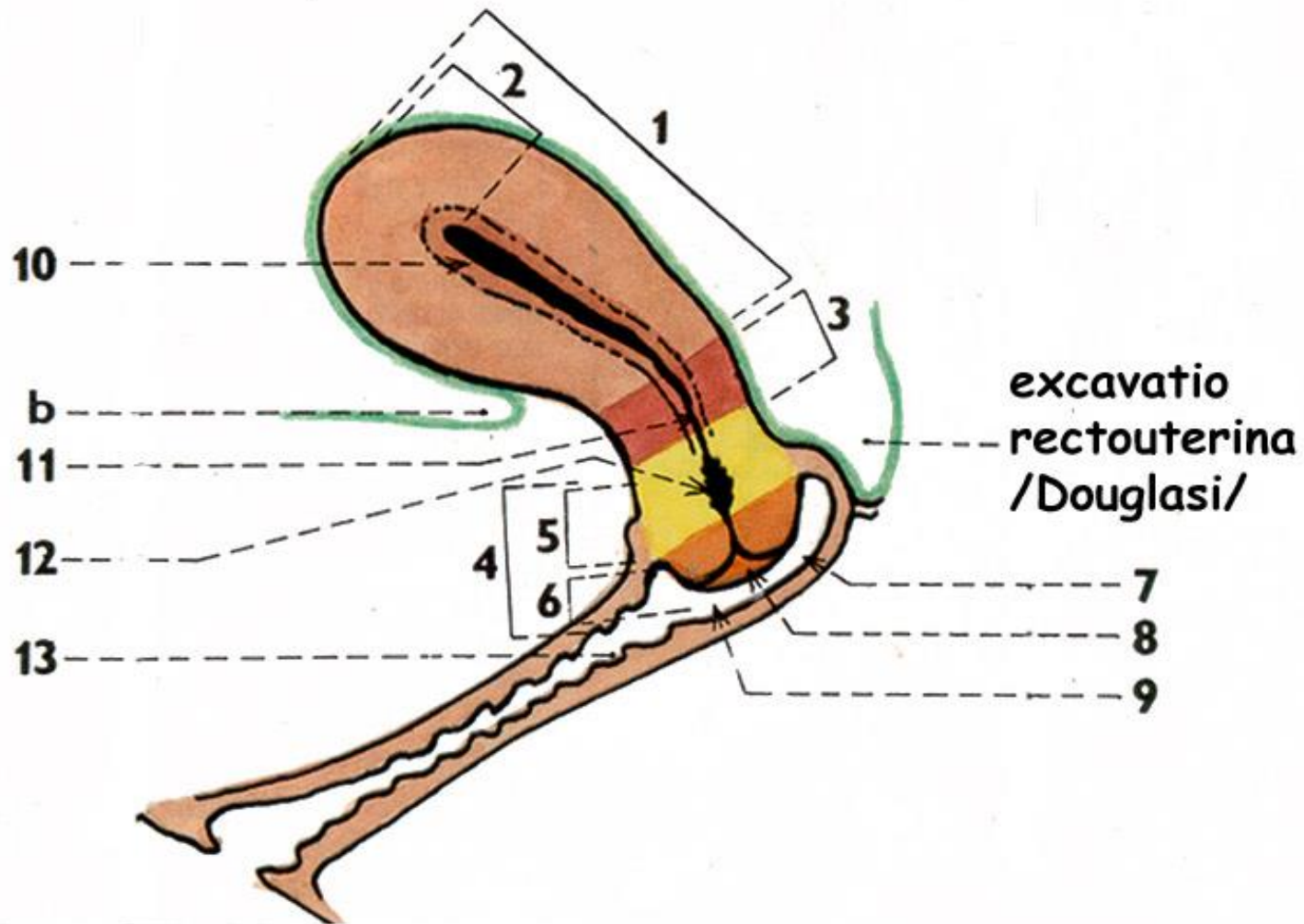


Uterus (*Metra, Hystera*)

- 8 cm, hollow organ with thick muscular wall
- embryonal and fetal development
- menstrual cycle
- portions:
 - fundus
 - corpus
 - cornu dx. + sin.
 - isthmus
 - cervix
 - portio supravaginalis
 - portio vaginalis (ectocervix)
 - margo dx. + sin.
 - facies vesicalis / anterior
 - facies intestinalis / posterior



SAGITTAL SECTION OF UTERUS AND VAGINA



- 1 / corpus uteri
- 2 / fundus uteri
- 3 / isthmus uteri
- 4 / cervix uteri
- 5 / portio supravaginalis cervicis uteri
- 6 / portio vaginalis cervicis uteri
- 7 / labium posterius
- 8 / ostium uteri

- 9 / labium anterius
- 10 / cavitas uteri
- 11 / canalis isthmi
- 12 / canalis cervicis
- 13 / vagina
- a / excavatio rectouterina
- b / excavatio vesicouterina

Uterus – *structure*

- clinical classification: body and cervix
- **body – cavitas uteri**
 - glandulae uterinae
- **cervix – canalis cervicis**
 - ostium histologicum uteri internum
 - plicae palmatae
 - glandulae cervicales → closure: ovula *Nabothi* (*glandulae cervicis dilatatae*)
 - ostium uteri (= ostium histologicum uteri externum) – shape according to number of labors
 - labium anterius + posterius
- **canalis isthmi = lower uterine segment**
 - dilates during delivery

Uterus – *fixation*

- suspensory ligaments:

- lig. latum uteri

- lig. transversum cervicis / cardinale *Mackenrodti*

- lig. teres uteri

- lig. pubocervicale et rectouterinum

- ventrodorsal ligaments – proper clinical terminology:

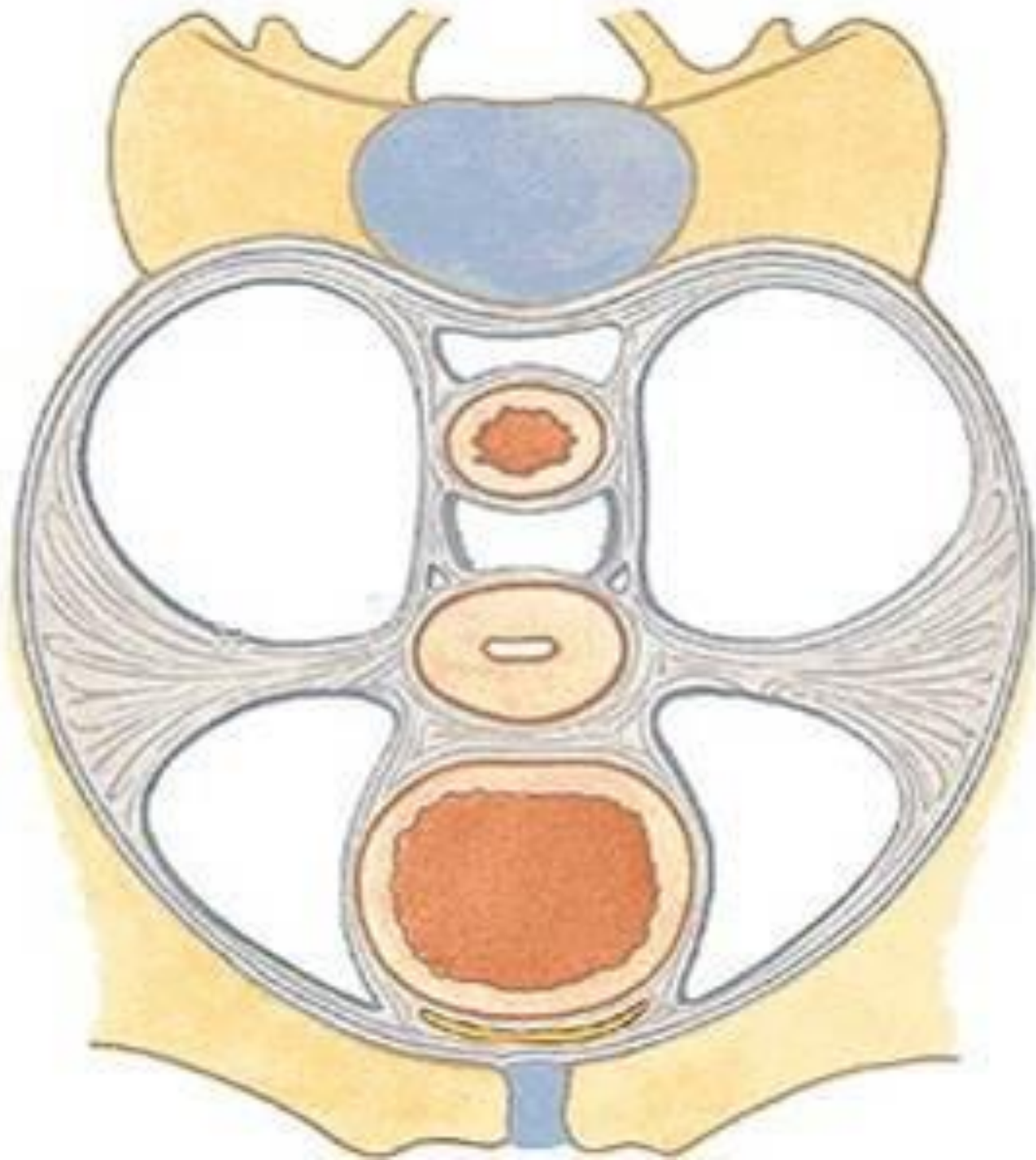
- lig. pubovesicalia* → *vesicouterina* → *rectouterina* + *sacrouterina*

- supporting apparatus:

- m. levator ani

- m. pubococcygeus → **m. pubovaginalis**

- mm. perinei (less important)

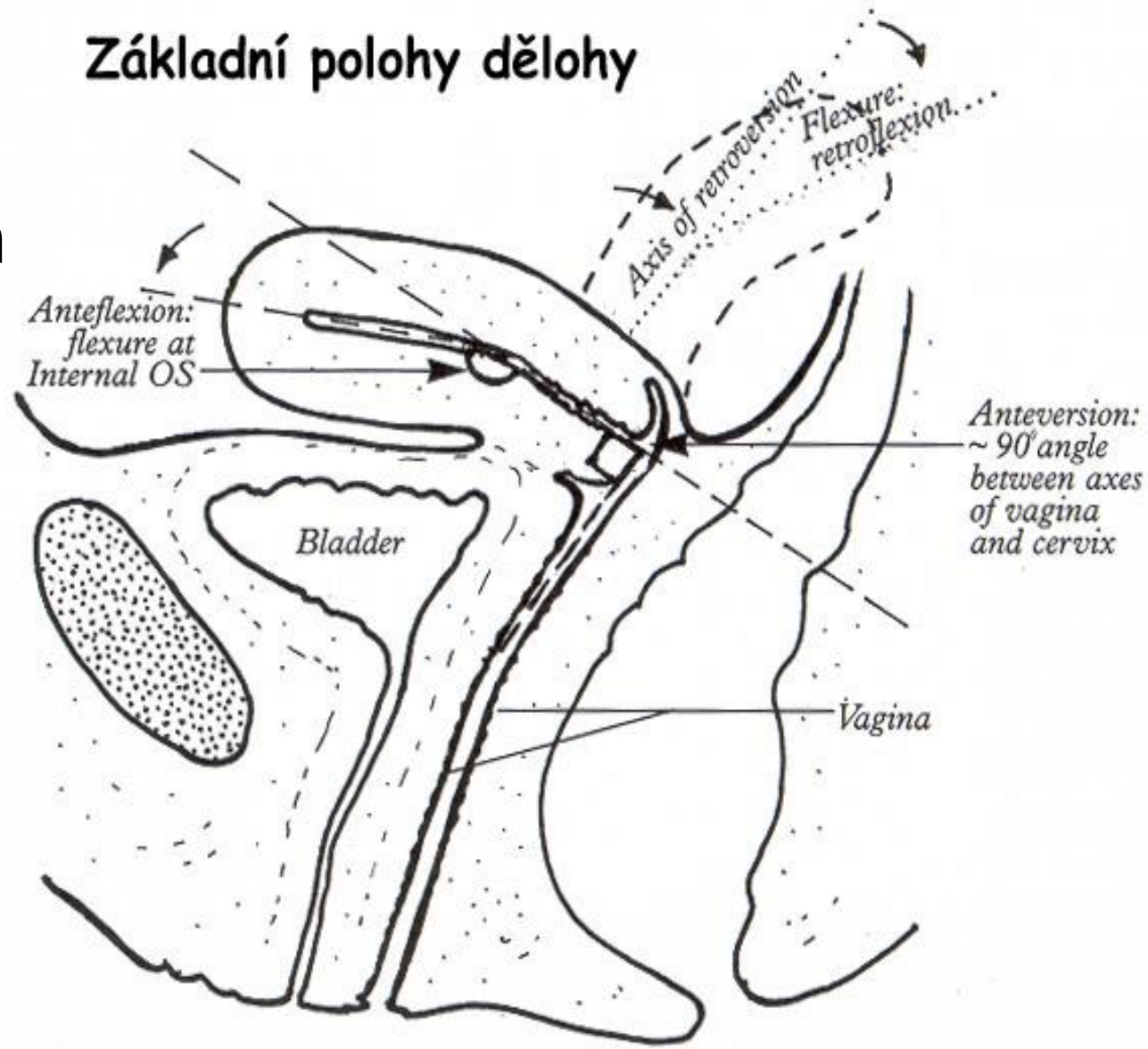


Uterus – *position* („AVF“)

- **anteflexion**
- **anteversion**
- lateroposition
- dextrotorsion = most common

retroversion
retroflexion

- during pregnancy, risk of rupture by promontorium

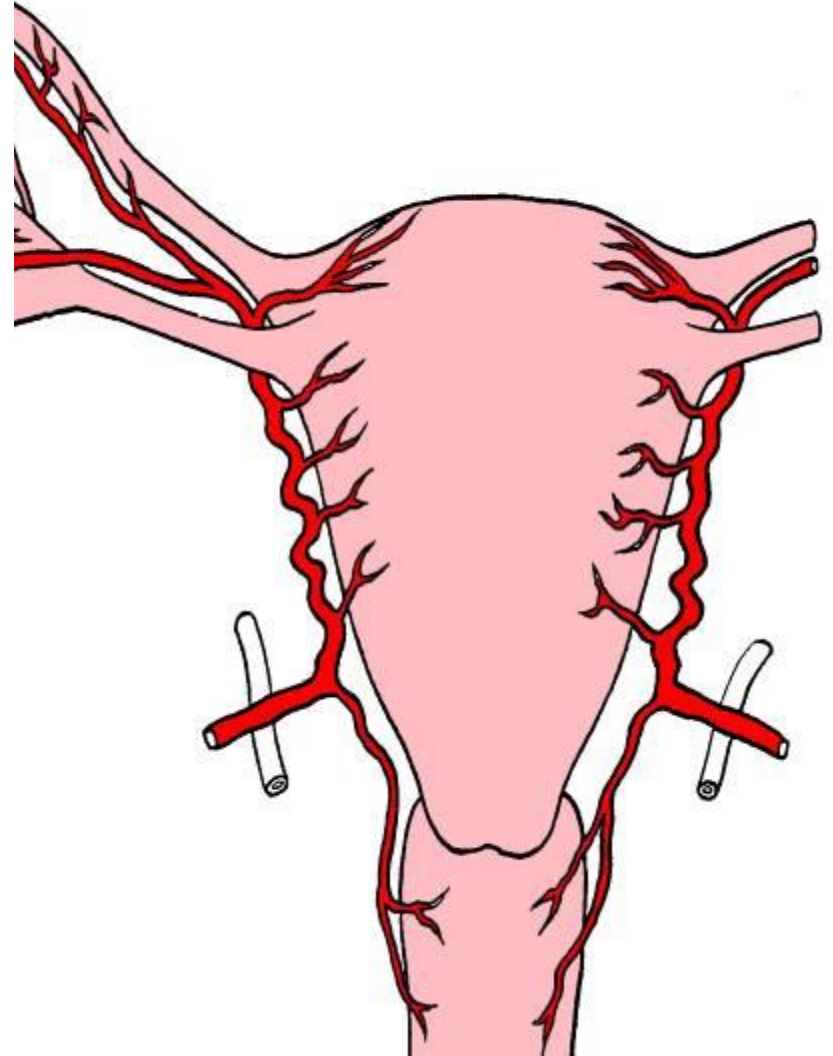


Uterus – arterial supply

arteries:

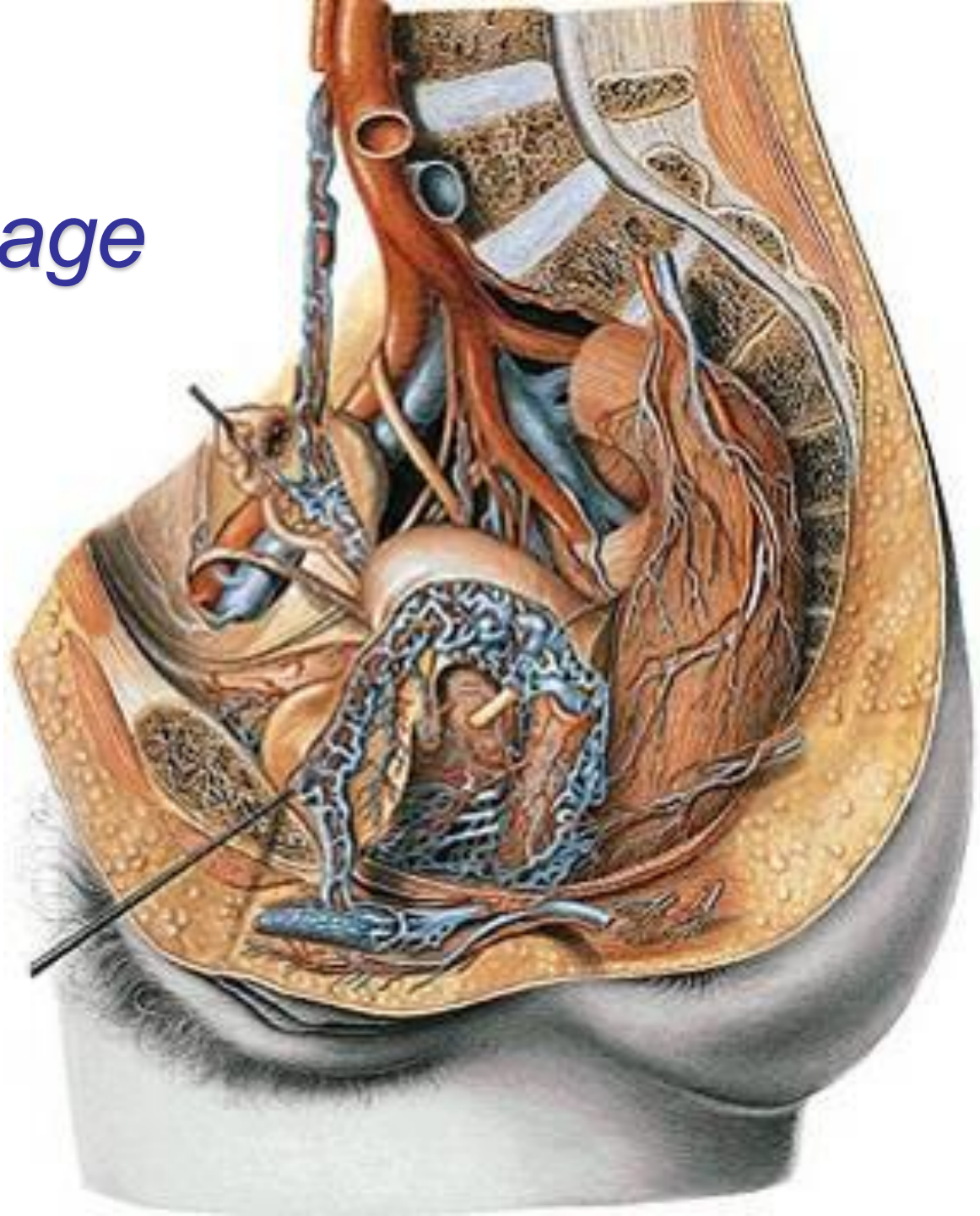
a. iliaca int.
→ a. uterina

ventrally to ureter
(„water flows under
the bridge“)



Uterus *venous drainage*

plexus
venosus
uterovaginalis
→ vv. uterinae
→ v. iliaca int.



Uterus – *lymphatic drainage*

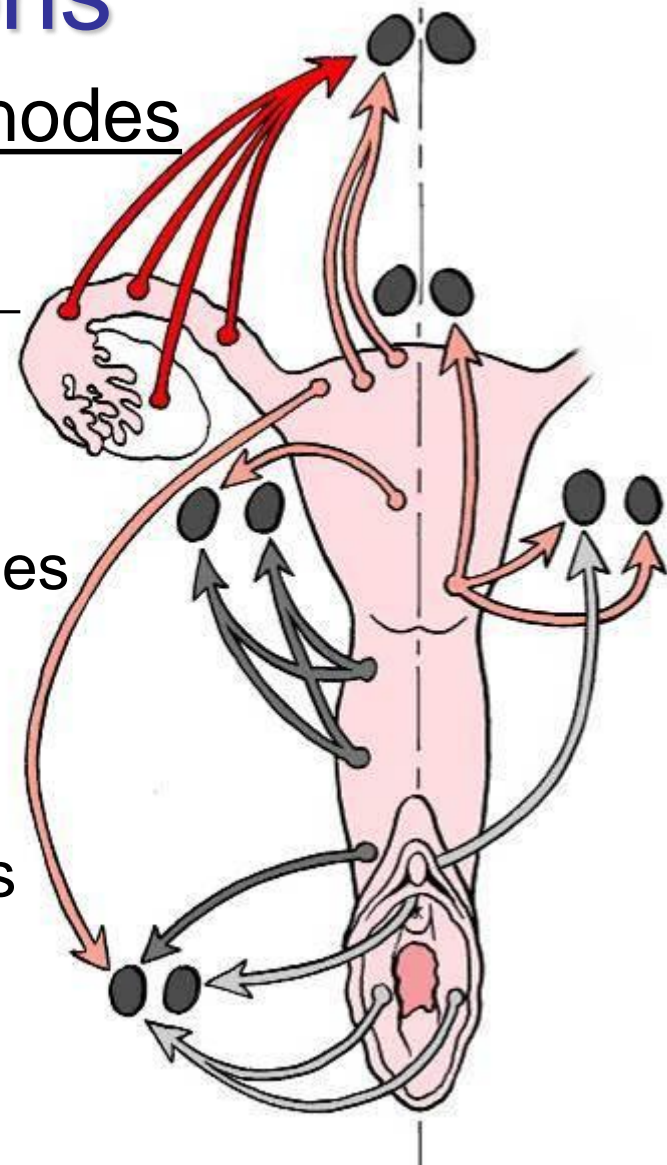
2 classifications

- according to topography of lymph nodes

- n.l.lumbales ← fundus et corpus
- n.l.iliaci interni (externi, communes) ← corpus, isthmus et cervix
- n.l.sacrales ← isthmus, cervix
- (n.l.inguinales superficiales ← margines + cornua)

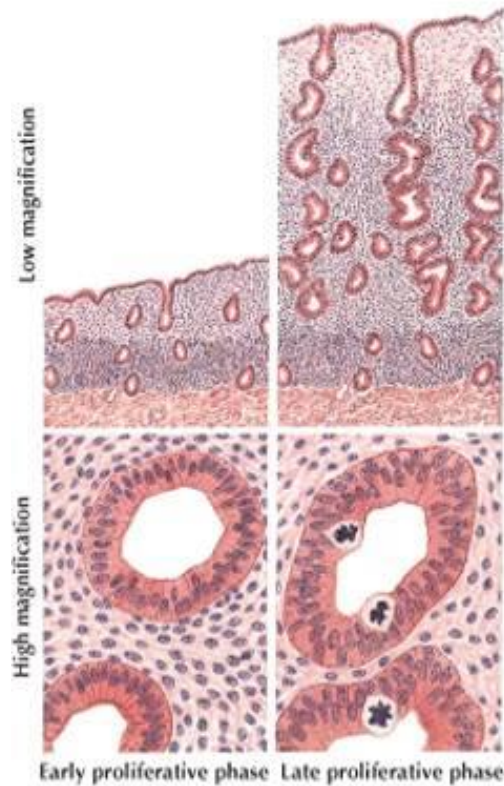
- according to uterine portion

- body → n.l. lumbales, iliaci, inguinales superficiales
- cervix → n.l. iliaci, sacrales



Corpus uteri – *inner structure* 1.

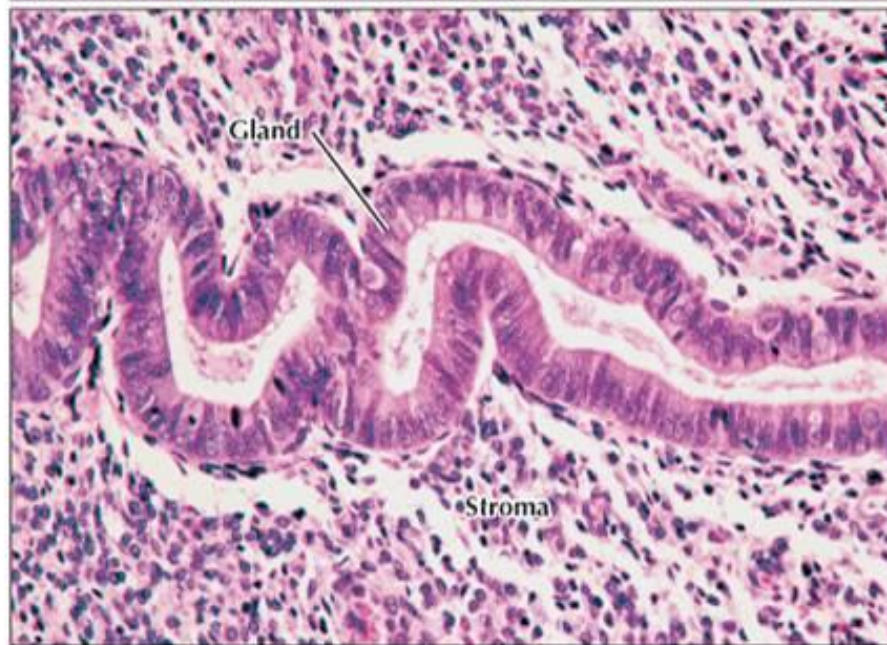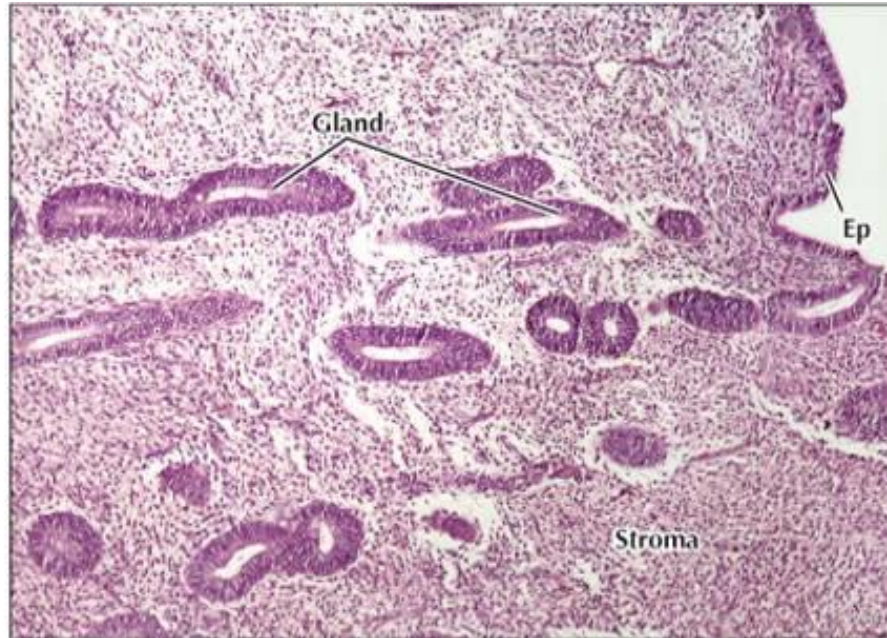
- tunica mucosa – **endometrium**
 - simple columnar epithelium
 - epitheliocytus ciliatus + exocrinocytus uterinus
 - stratum basale
 - DOES NOT undergo changes and is NOT sloughed off during menstruation, ensures regeneration of mucosa
 - more rich in cells and reticular fibers, vessels
 - stratum functionale / spongiosum
 - cyclic changes, periodically sloughed off
 - stratum superficiale / compactum
 - glandulae uterinae – simple tubular glands
 - lamina propria mucosae = stroma endometriale
 - cellula stromalis
 - cellula granularis



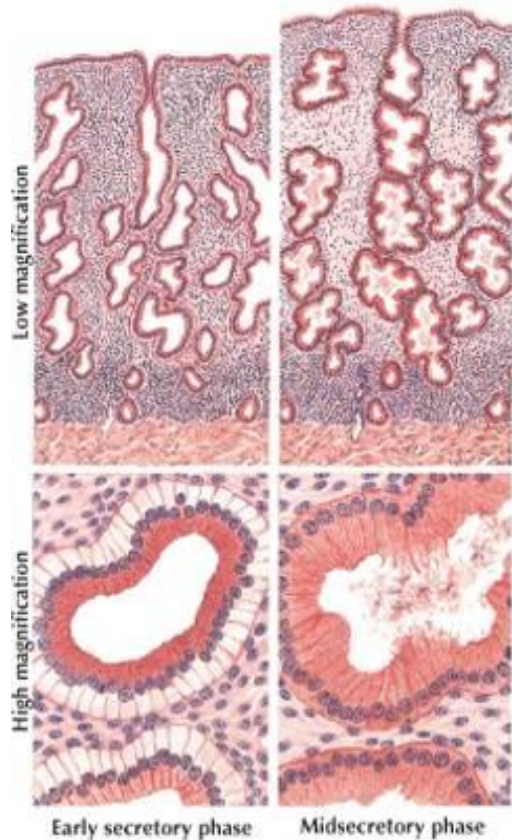
Early proliferative phase Late proliferative phase

▲ Schematics of the endometrium during early (left) and late (right) follicular phases of the menstrual cycle. In the former, the endometrium is relatively thin, and glands are simple and straight. In the late phase, the thicker endometrium shows marked growth in glands and stroma. Uterine glands appear more convoluted, and mitoses are often seen at higher magnification. This phase is one of maximum regeneration in both epithelium and surrounding stroma.

F. Nasser



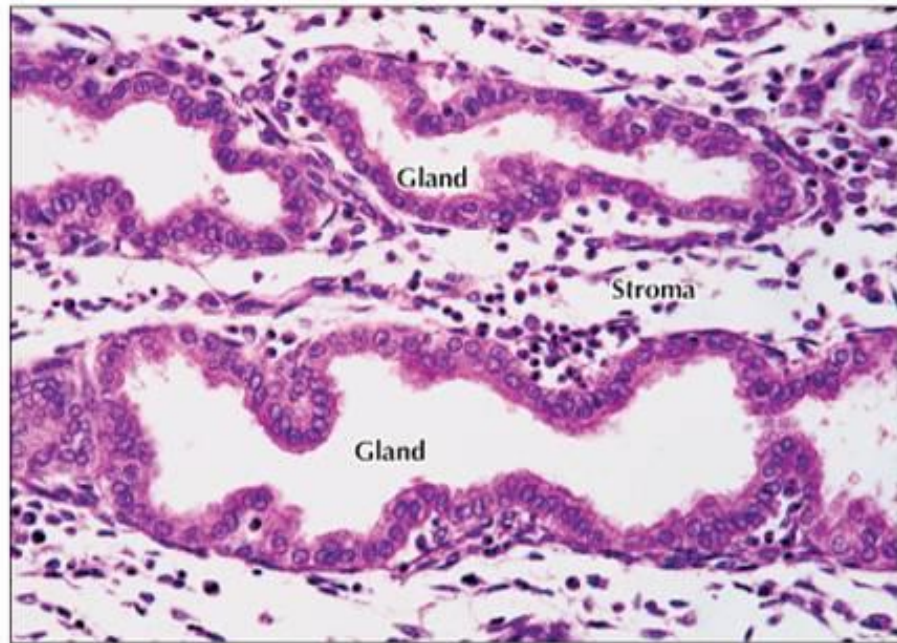
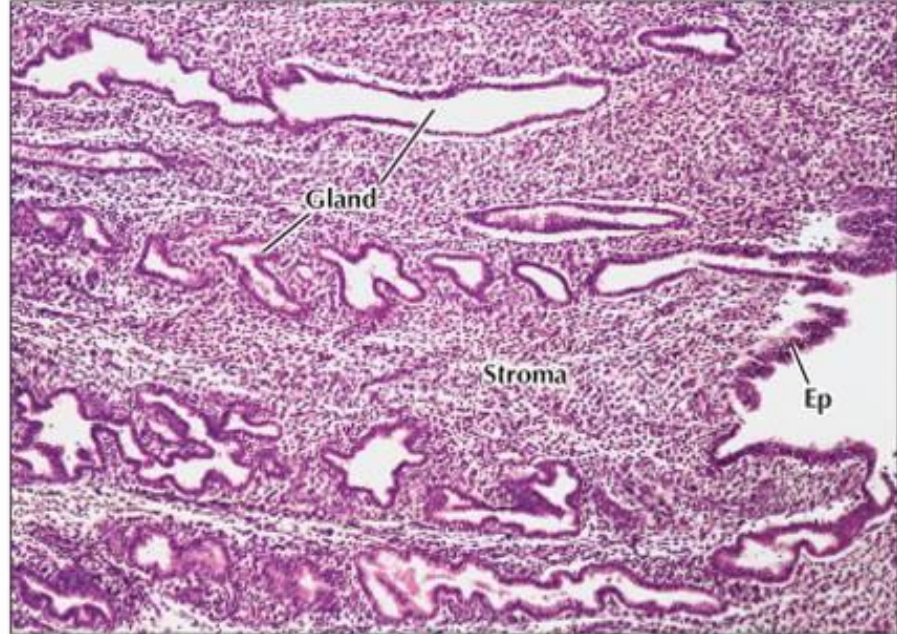
▲ LMs of the endometrium during the early follicular phase at low magnification (Above) and late follicular phase at higher magnification (Below). Uterine glands first appear straight and gradually become more tortuous as they reach the epithelial surface (Ep). Surrounding stroma is highly cellular. Above: 75x; Below: 280x. H&E.



▲ Schematic of the endometrium during early secretory (left) and midsecretory (right) phases of the menstrual cycle.

In the early phase and under the influence of progesterone, endometrial stroma shows less edema. Epithelial cells of the glands have round nuclei, with pale-staining basal cytoplasm due to glycogen deposits. In the later phase, glands have a distinctive saw-toothed appearance, and glandular epithelial cells are tall columnar with apically located glycogen. Secretions form bubbles at luminal margins and are discharged into the glandular lumen.

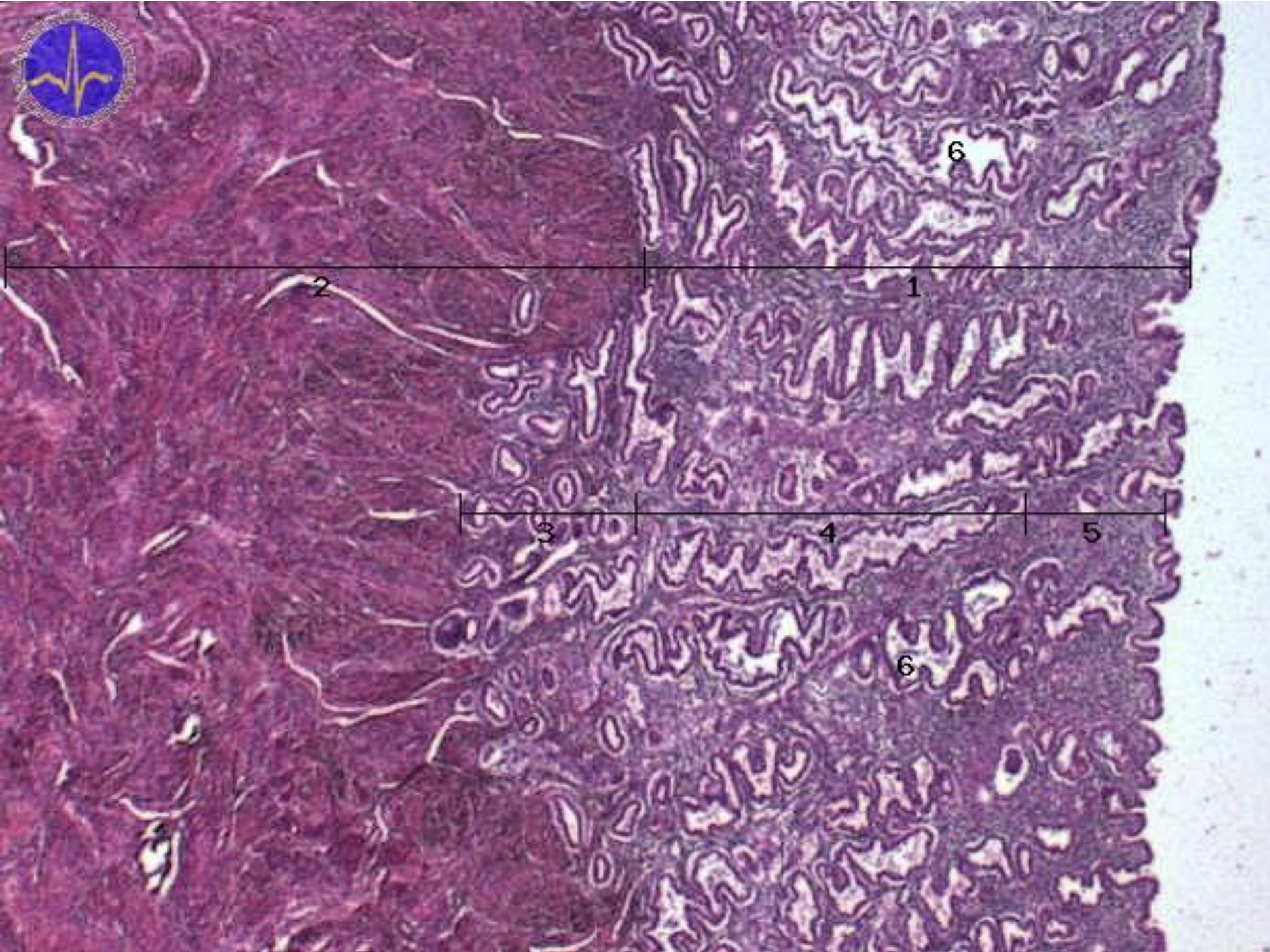
F. Nasser

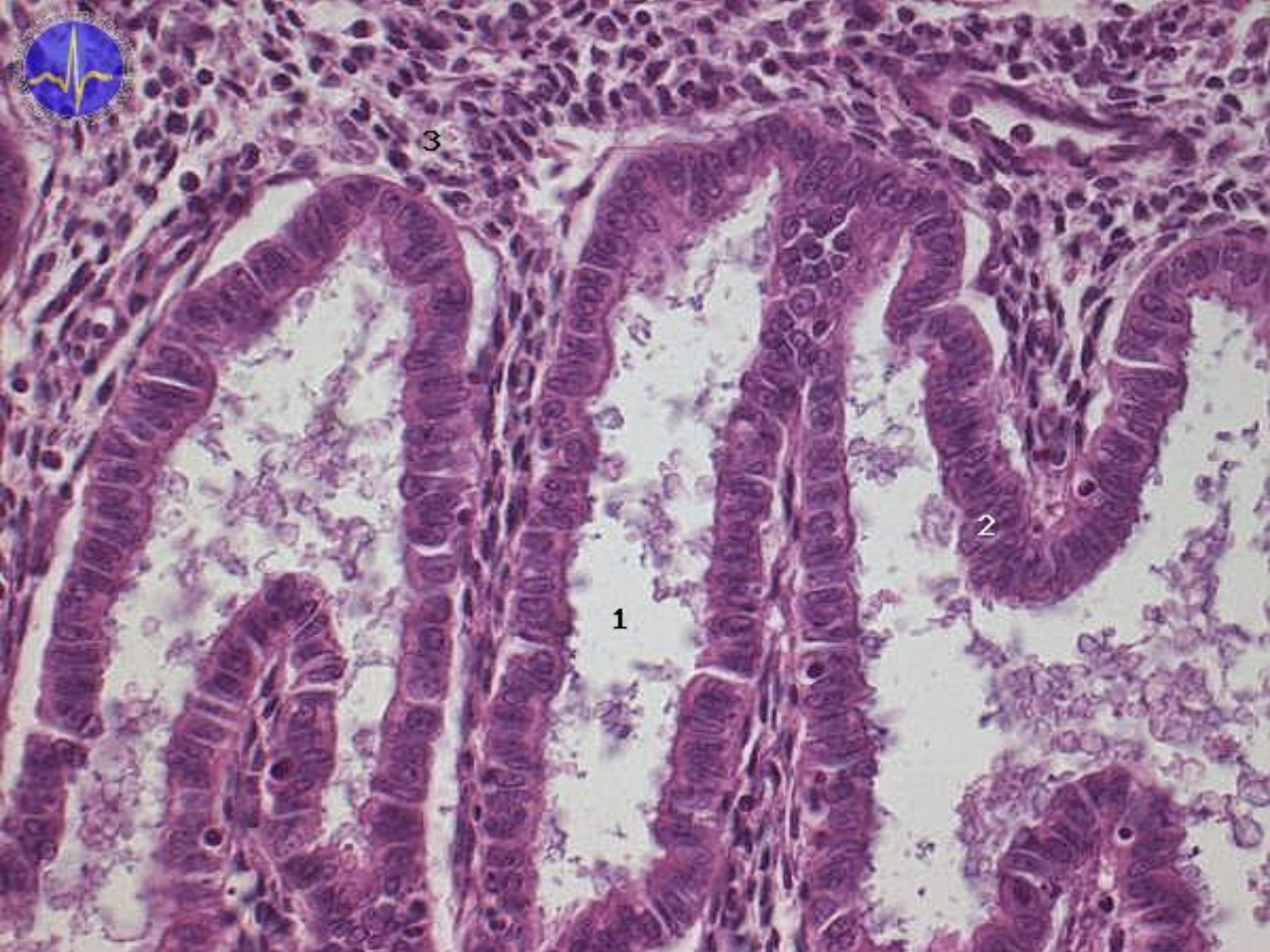


▲ LMs of the endometrium during the secretory phase of the cycle at low (Above) and higher (Below) magnification. Uterine glands are highly tortuous and have a serrated outline in section. They open onto the epithelial surface (Ep). Surrounding stroma is highly cellular. Above: 75×; Below: 280×. H&E.

Corpus uteri – *inner structure 2.*

- tunica muscularis – **myometrium**
 - 15 mm, spirally interwoven densely arranged bundles of connective tissue
 - muscle cells are spindle-shaped about 40-90 μm large (the longest cells in human body)
 - during pregnancy increase in number (hyperplasia) and also in size (hypertrophy)
 - before delivery number of oxytocin receptors is increased (200 times)
 - 3 layers (stratum submucosum, vasculosum, supravasculosum)
- tunica serosa = peritoneum – **perimetrium**
 - tela subserosa (contains stratum musculorum subserosum = 4th muscular layer)
- tunica adventitia – **parametrium**
 - loose collagen connective tissue, vessels + suspensory ligaments

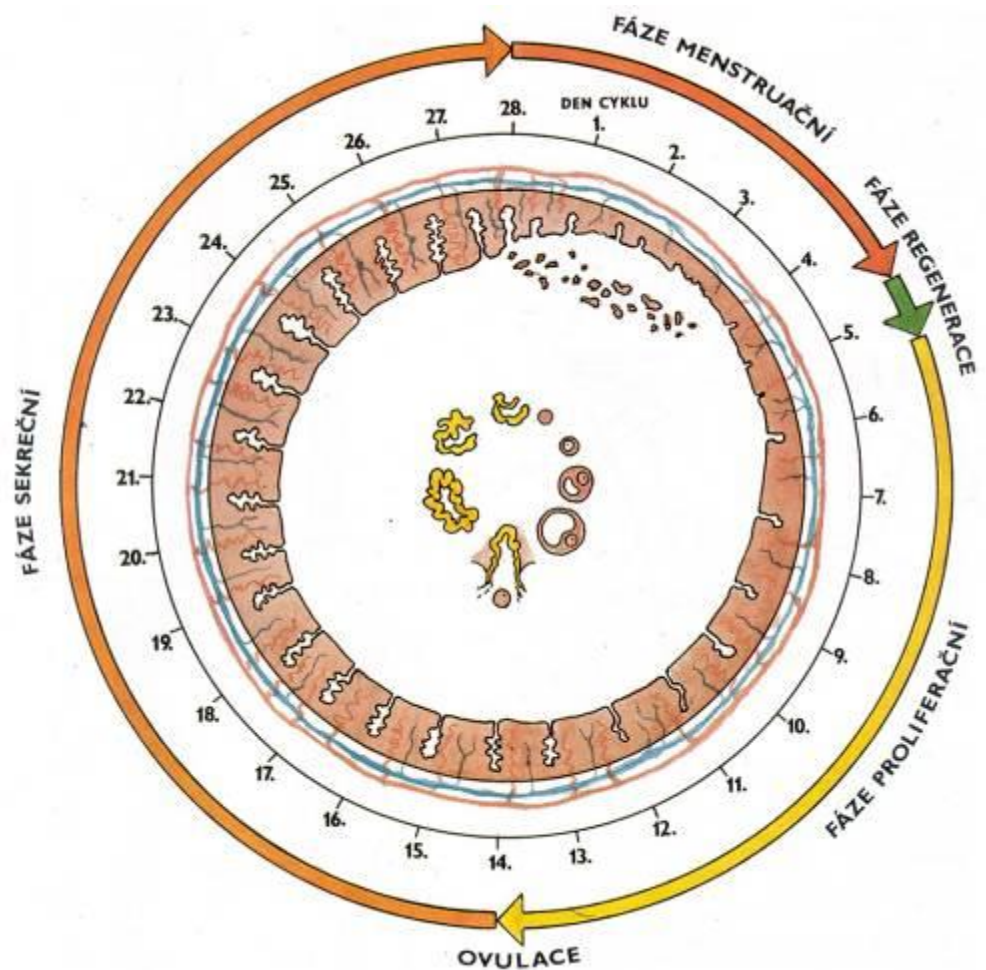




Menstruation = *Menstruatio*

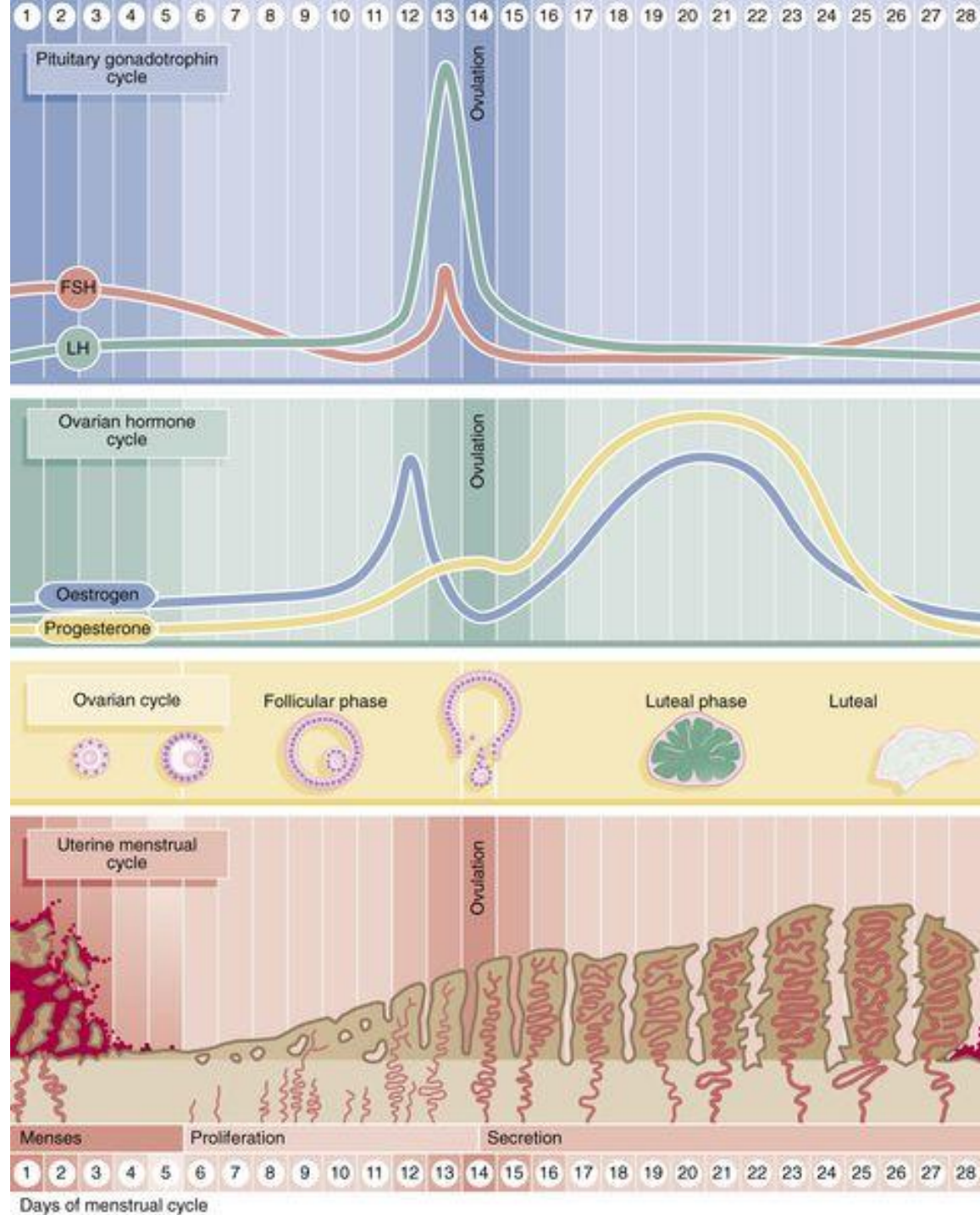
menstrual cycle

- menstrual phase – 1st-4th day
- proliferative phase – 5th-14th day
- secretory phase – 15th-28th day
- ischemic phase – 28th day



- menarché (10th-13th year of age)

- menopause (about 50th year of age)



Menstral phase

Phasis menstrualis / desquamativa

- stratum functionale et superficiale tunicae mucosae are sloughed off
- stratum basale remains
- re-epithelialization of nuded surface
 - finished 5th day = phase of regeneration
- mucosa 0.5-1 mm thick

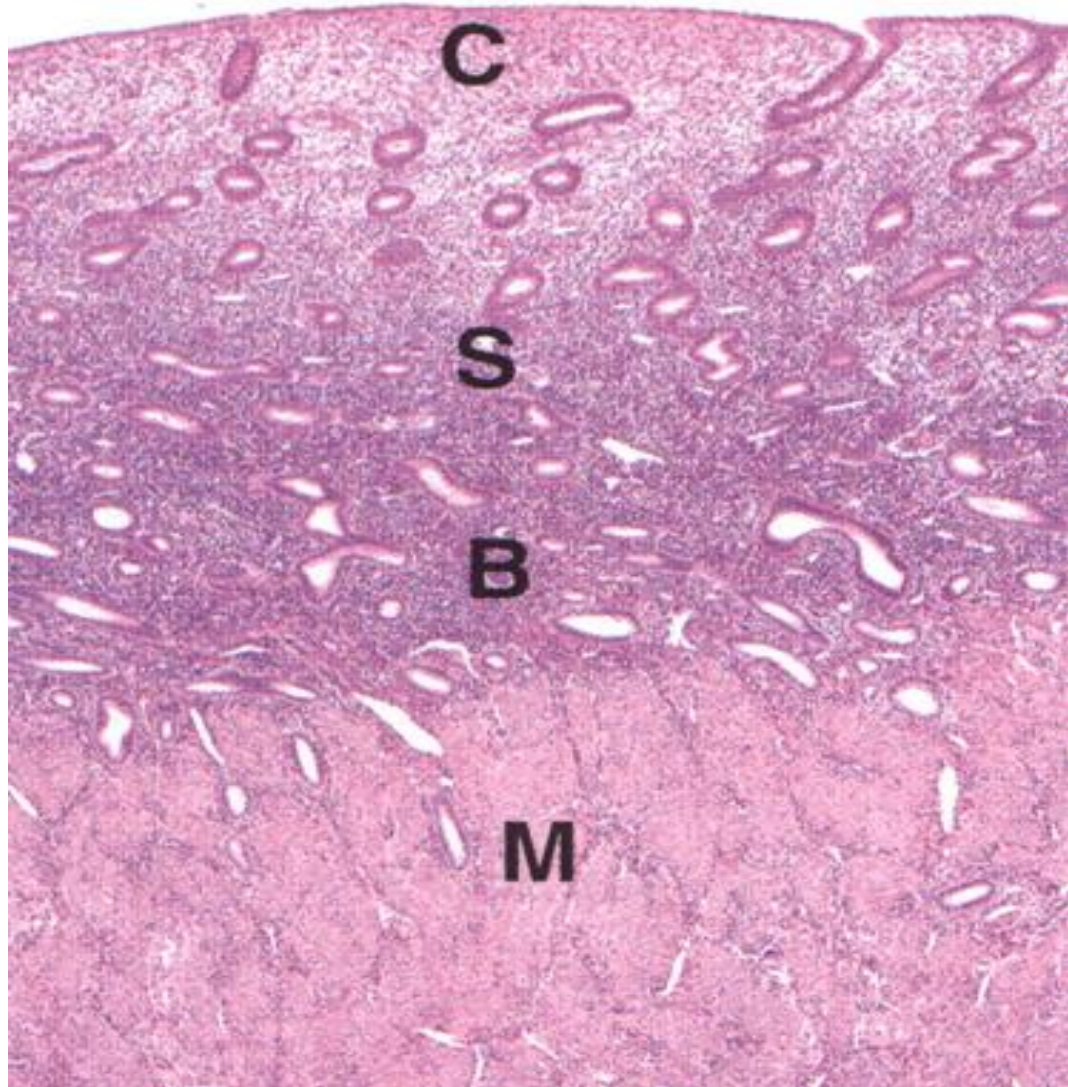
Proliferative phase

Phasis proliferativa / follicularis

- under influence of estrogens
- mitotic activity → hyperplasia (↑ count) of stratum functionale
- elongation of glands, they are narrow, without secretion, by the end of phase they begin to coil
- cytoplasm of epithelial cell is rich in gER
- mucosa 3 mm thick
- increased level of LH → **ovulation** (14th day)

Proliferative phase

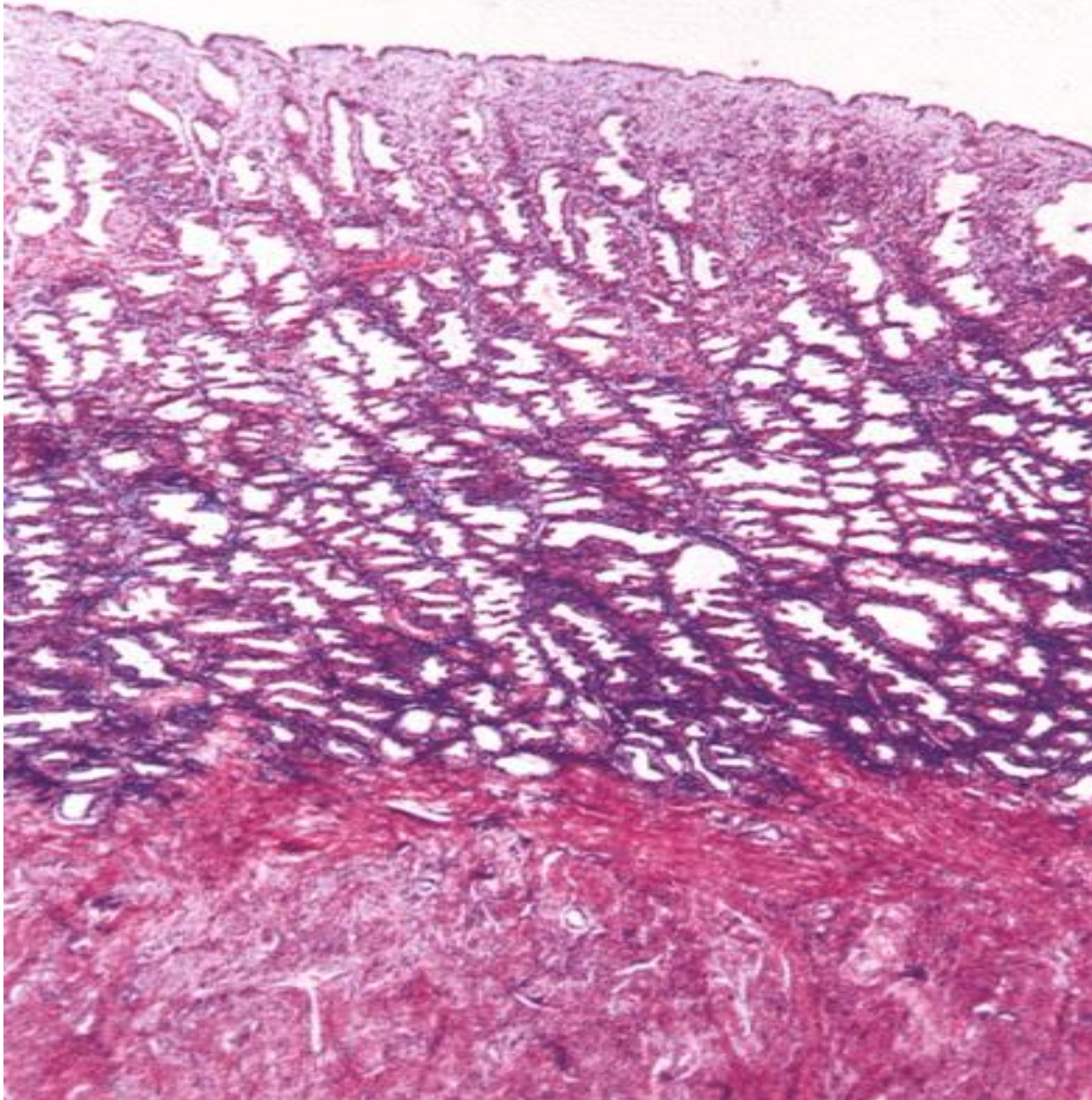
Phasis proliferativa / follicularis



Secretory phase (*Phasis secretoria*)

- influence of hormones from corpus luteum (progesteron)
- stratum functionale – hypertrophy (↑ size)
 - glands are coiling (except basal and apical ends)
 - stratum spongiosum – coiled
 - stratum compactum – straight
 - secretion contains mucine, glycogen and lipids
 - epithelial cell contain mucine and glycogen (first in basal portion, then in apical)
- arterioles elongate and coil
- mucosa 6-7 mm thick
- decidual reaction
 - stromal cells enlarge and fill with glycogen and lipids (*cellulae predeciduales*)
 - later during pregnancy they exhibit mitotic activity (*cellulae deciduales*)

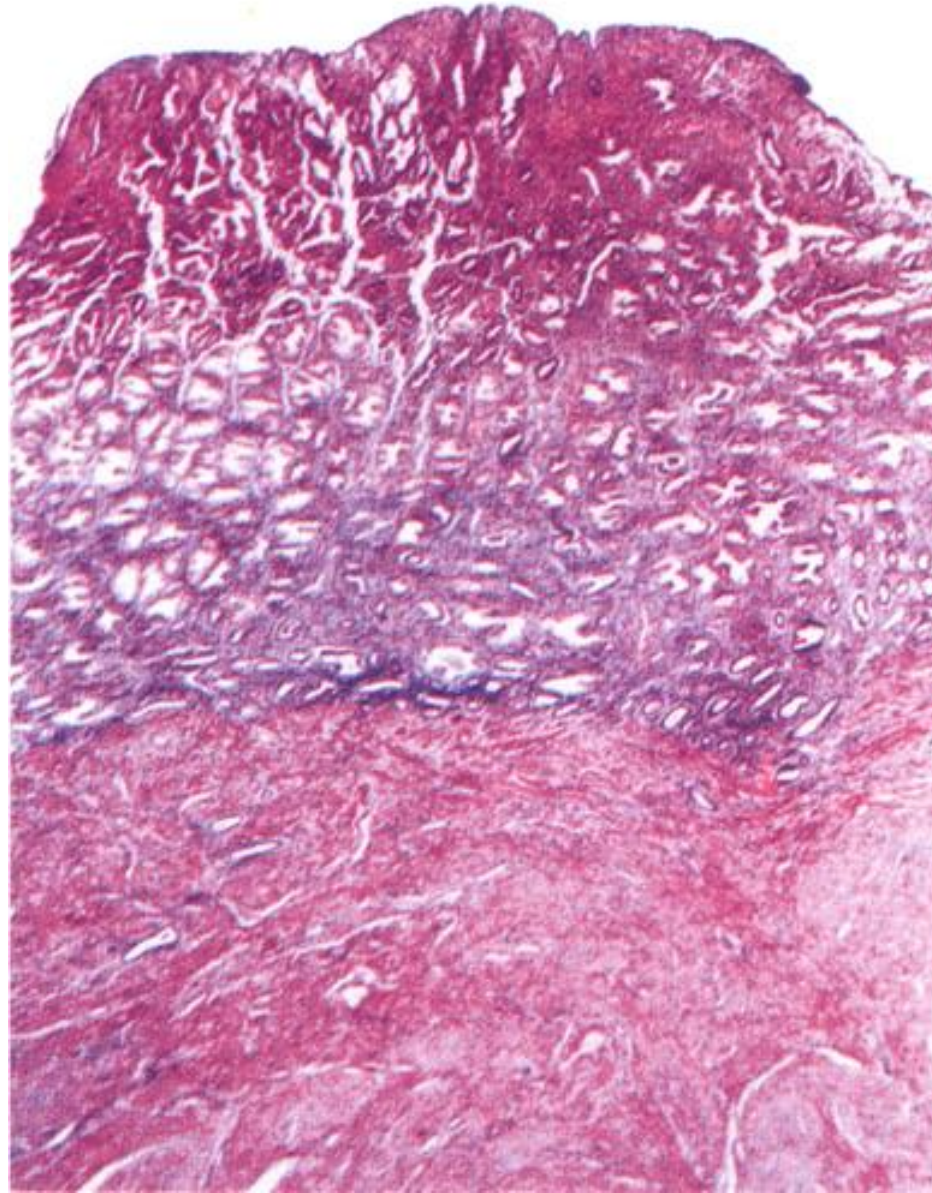
Secretory phase (*Phasis secretoria*)



Ischemic phase (*Phasis ischemica*)

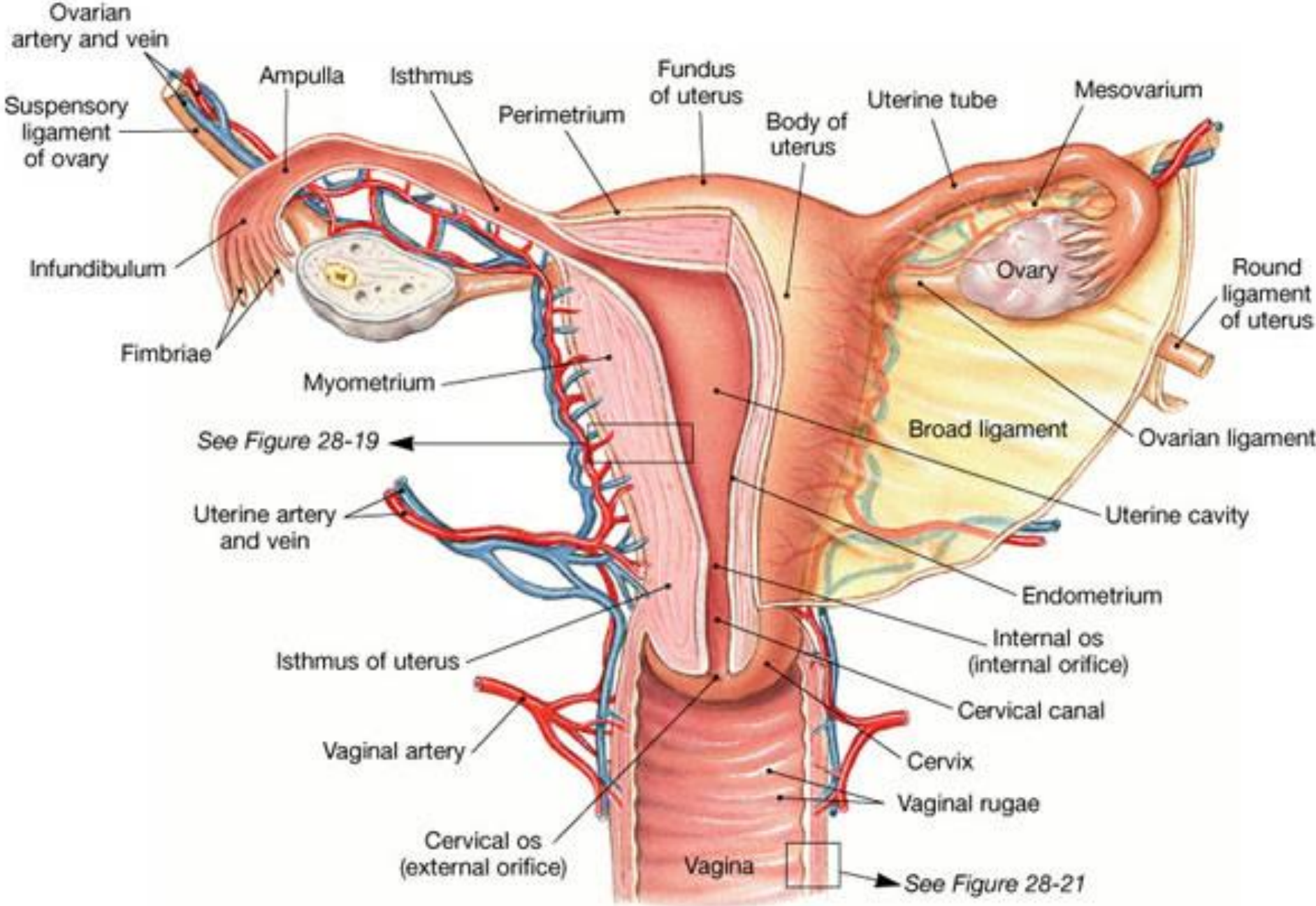
- 1 day
- due to decreased level of progesteron
- constriction of spiral arterioles → ischemia of stratum functionale et superficiale → necrosis
- migration of leukocytes → degenerative processes
- menstrual blood
 - mix of arterial and venous blood
 - enzymes from mucosa → incoagulable
- contraction of myometrium and vessels → stop the bleeding

Ischemic phase (*Phasis ischemica*)



Uterine isthmus = *Isthmus uteri*

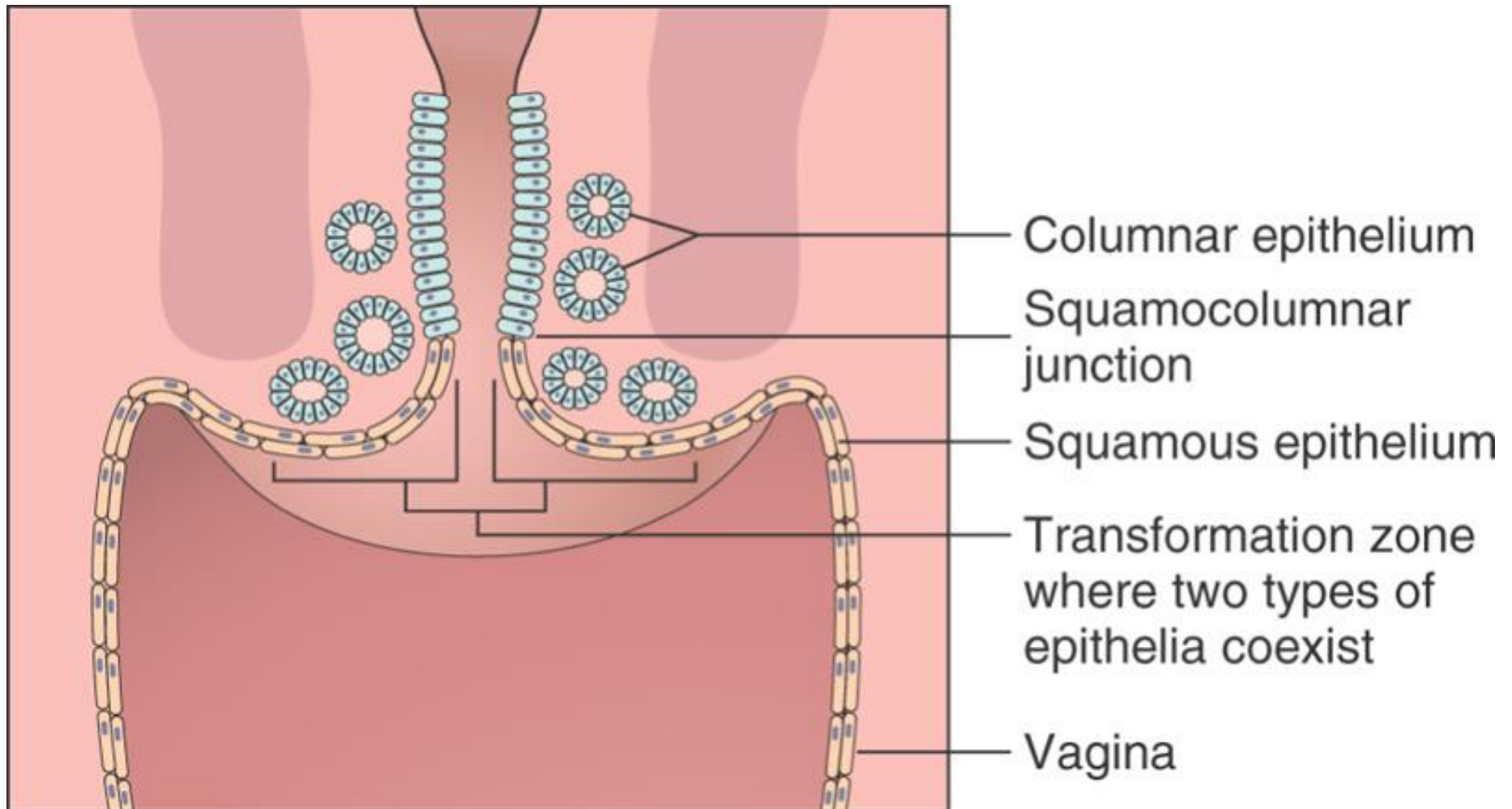
- 5-9 mm
- structure similar to uterine body
 - myometrium contains less vessels → surgical approach to Caesarean section
 - lower endometrium, does not undergo cyclic changes
 - boundary of mucosa between body and cervix (*ostium histologicum uteri internum*)



(c) Posterior view

Uterine cervix = *Cervix uteri* 1.

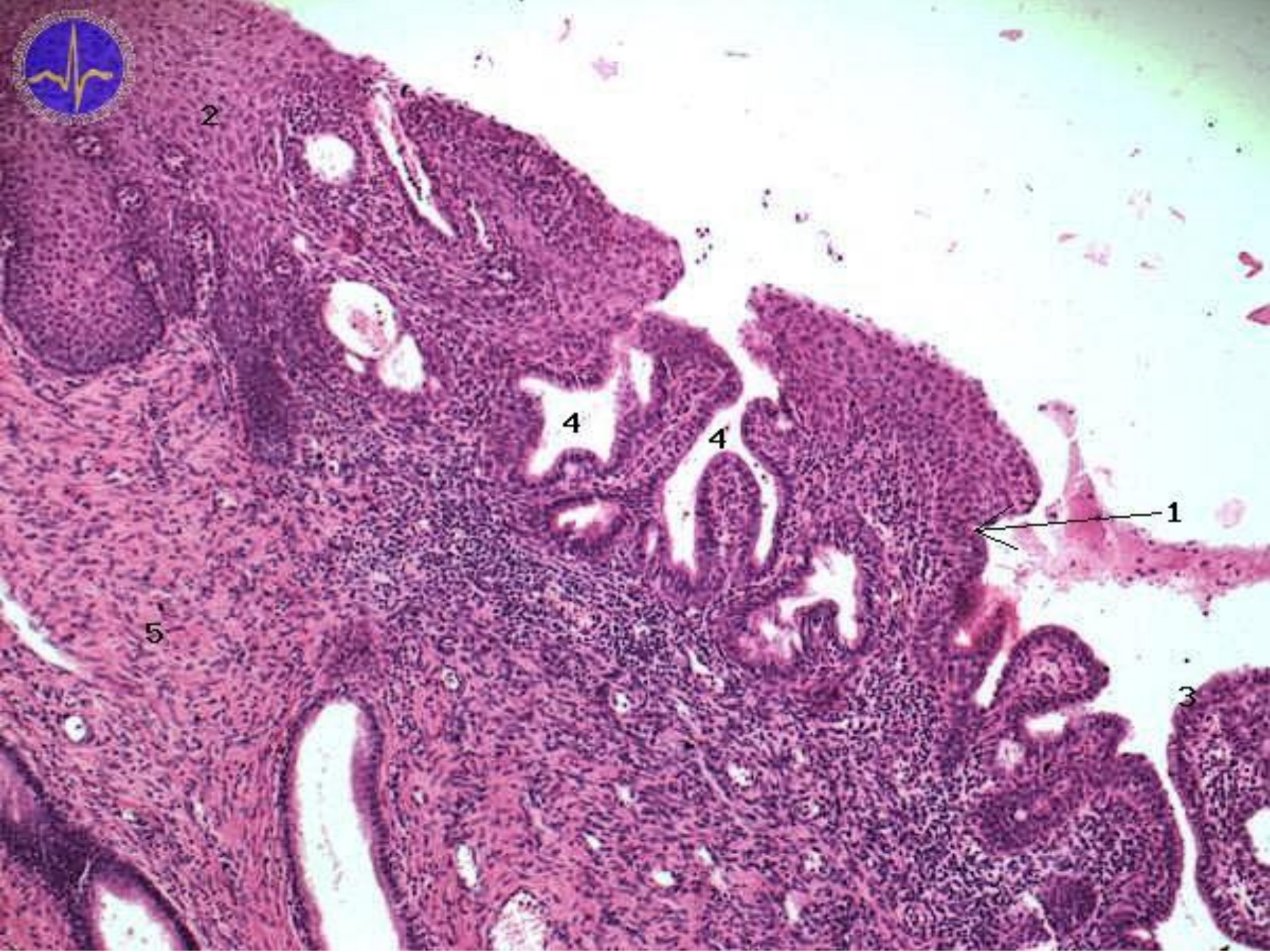
- portio supravaginalis cervicis
 - upper part surrounded by fibrous tissue of parametrium
- portio vaginalis cervicis = **ectocervix**
 - lower part protrudes into vagina
- canalis cervicis
 - plicae palmatae
 - crypts – with opening of tubular glandulae cervicales
 - alkaline secretion, various density depending on phase of cycle
 - tunica mucosa endocervicalis
 - simple columnar epithelium
 - mucous cells (*mucocytī*), less of ciliated cells (*epithelocytī ciliatī*)
- mucous plug (*obturamentum cervicale*)



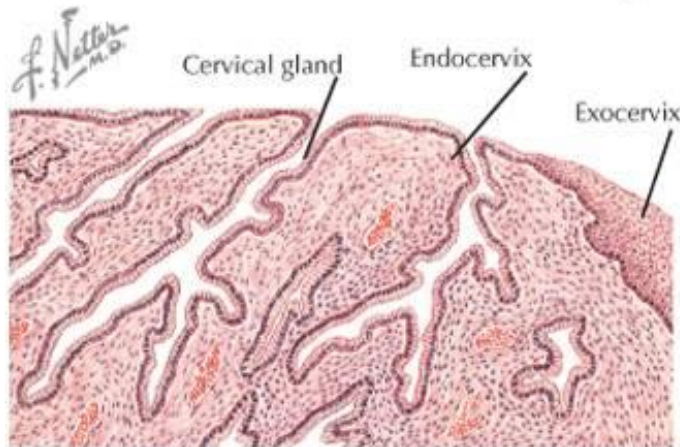
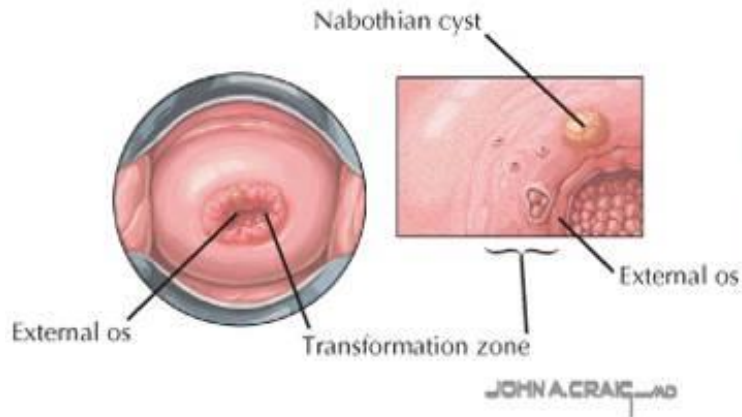
Kumar et al: Robbins & Cotran Pathologic Basis of Disease, 8th Edition.
Copyright © 2009 by Saunders, an imprint of Elsevier, Inc. All rights reserved.

Uterine cervix = *Cervix uteri* 2.

- tunica mucosa exocervicalis (vaginal surface of cervix)
 - non-keratinized stratified squamous epithelium (similar to vaginal epithelium)
 - transition in area of ostium uteri (external orifice of uterus)
 - borderline with columnar epithelium lies in endocervix – is not visible
- ectropium = endocervical epithelium extends to the vagina (after labour)
- ectopia = epithelial metaplasia = precancerosis (columnar epithelium is replaced by stratified squamous – transformation zone) → conization
- HPV

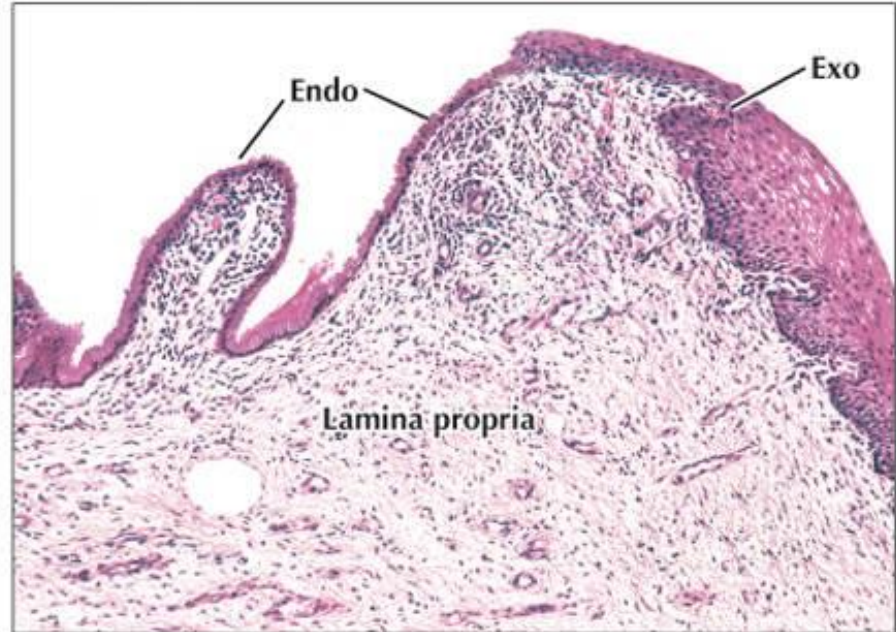

▼ Low- and high-power colposcopic views of the normal transformation zone.

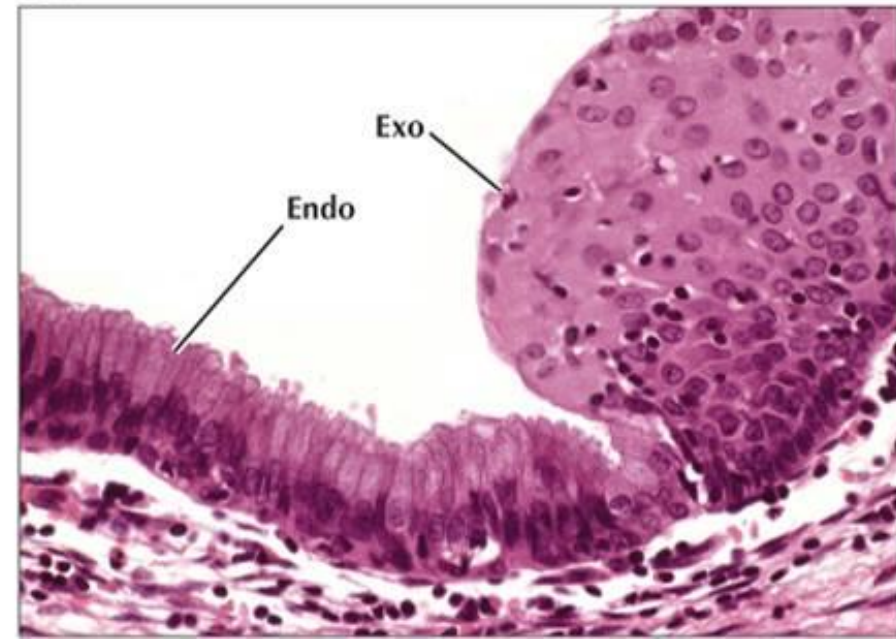


▲ Schematic of the cervical squamocolumnar junction.

► Higher magnification LM of the cervical squamocolumnar junction. The endocervix (**Endo**) is lined by simple columnar epithelium with tall mucus-secreting cells. The epithelium abruptly changes to a nonkeratinized stratified squamous type in the exocervix (**Exo**). 290 \times . H&E.



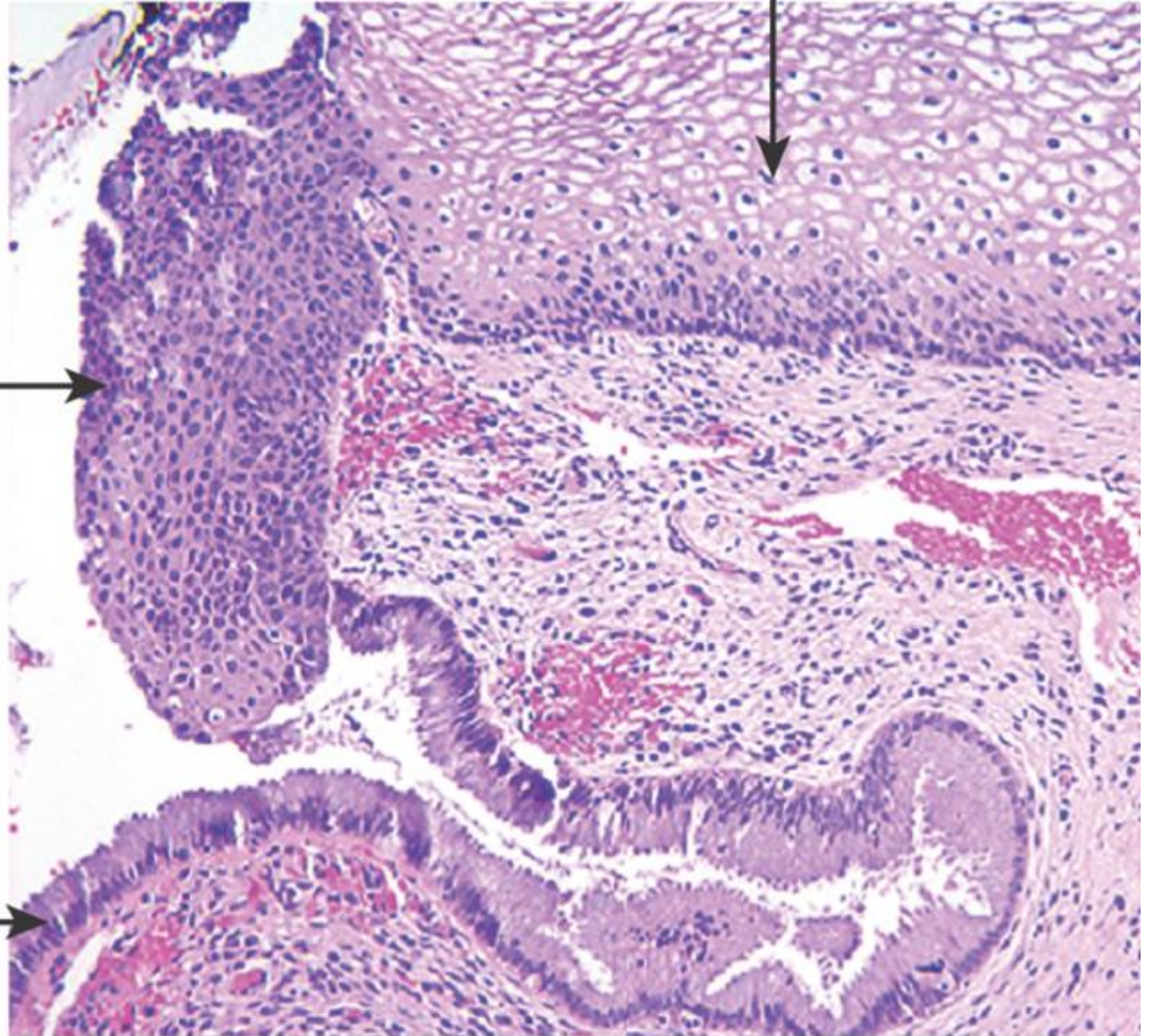
▲ Low-magnification LM of the mucosa of the uterine cervix. The simple epithelium of the endocervix (**Endo**) is highly folded and continuous with stratified epithelium of the exocervix (**Exo**). Underlying lamina propria is richly cellular. 96 \times . H&E.



Mature squamous cells

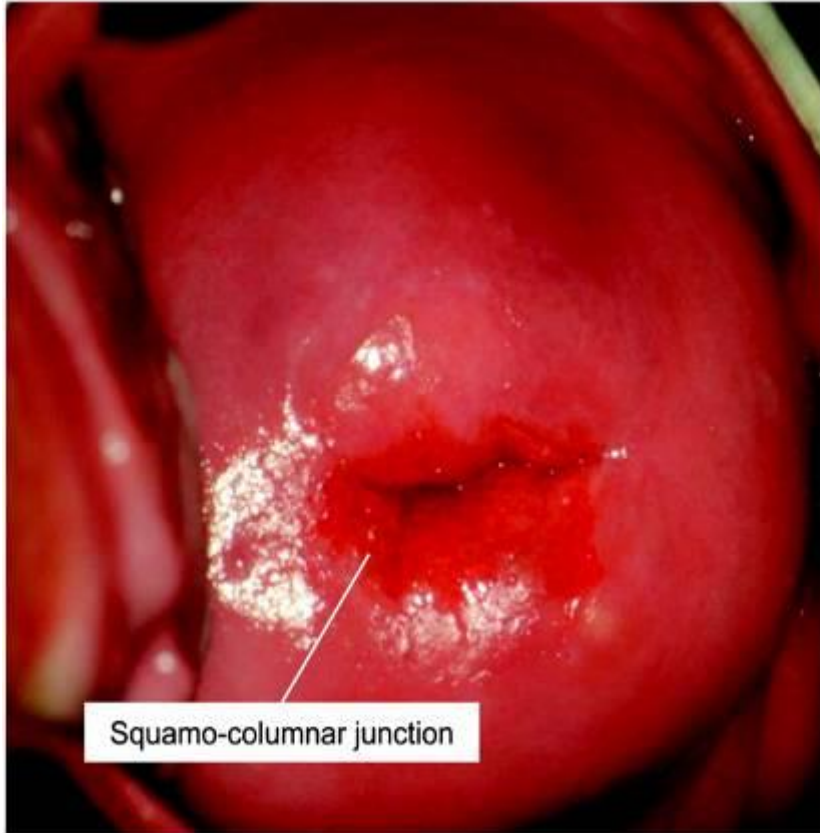
Immature
squamous
cells

Columnar
glandular
cells

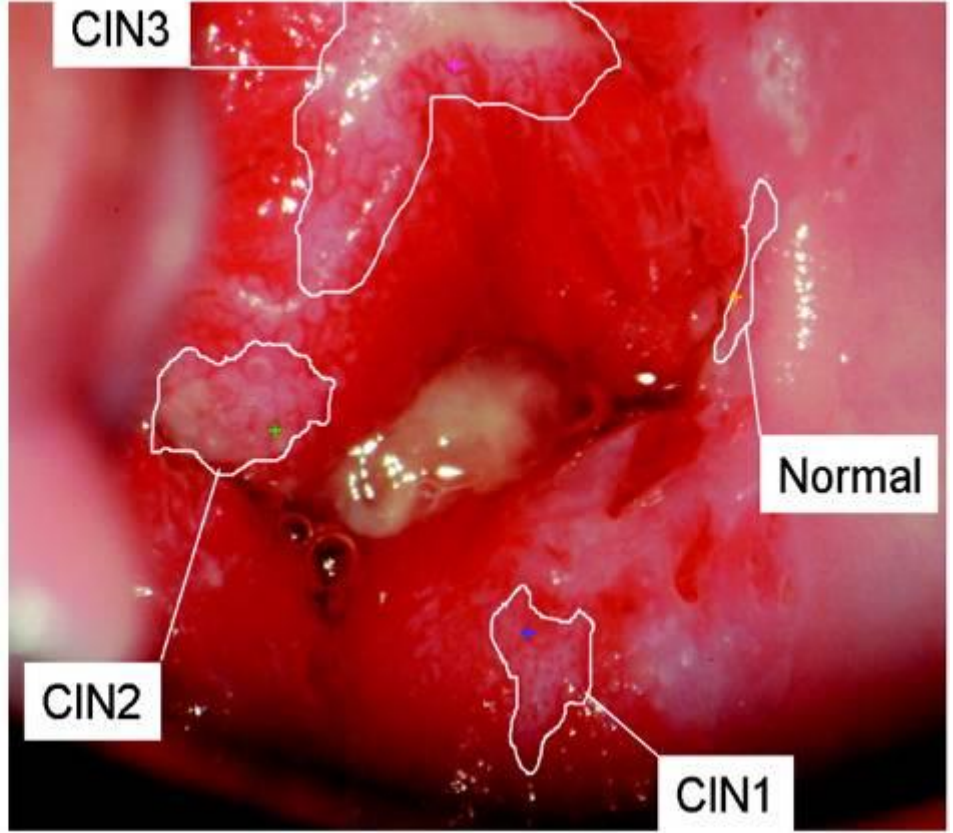


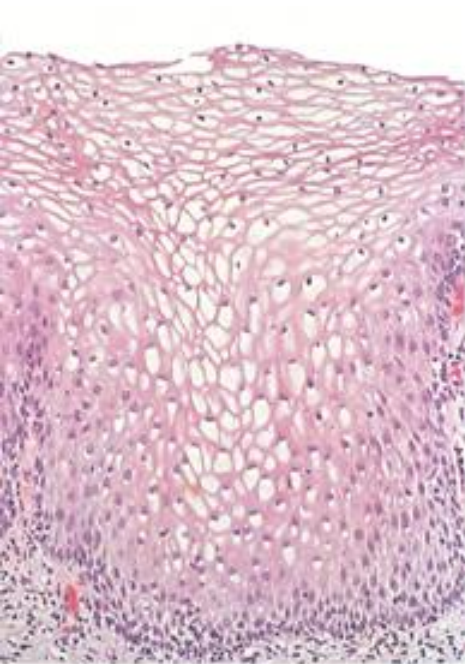
Cervical metaplasia

A

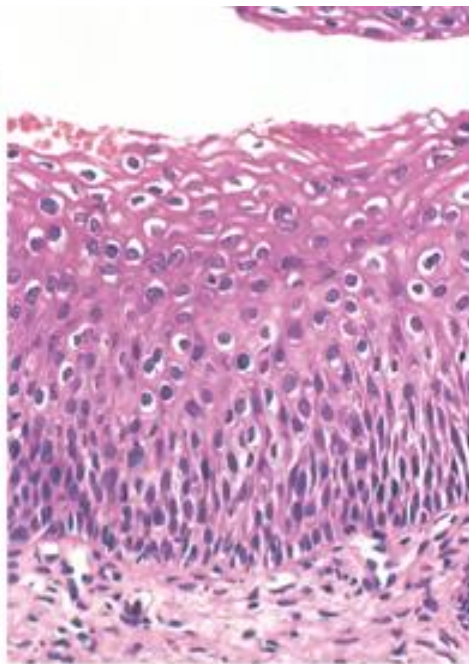


B

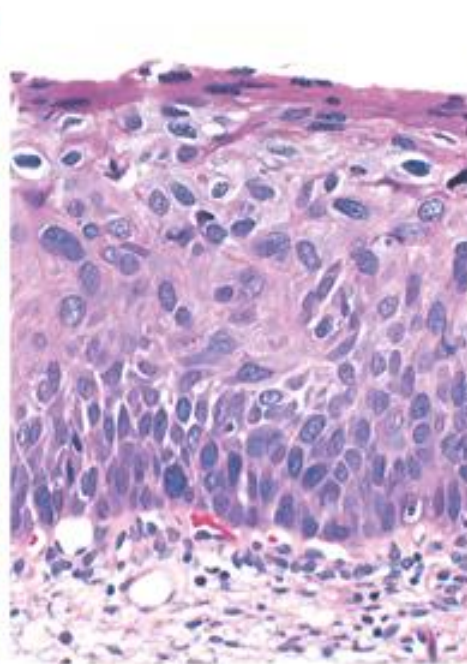




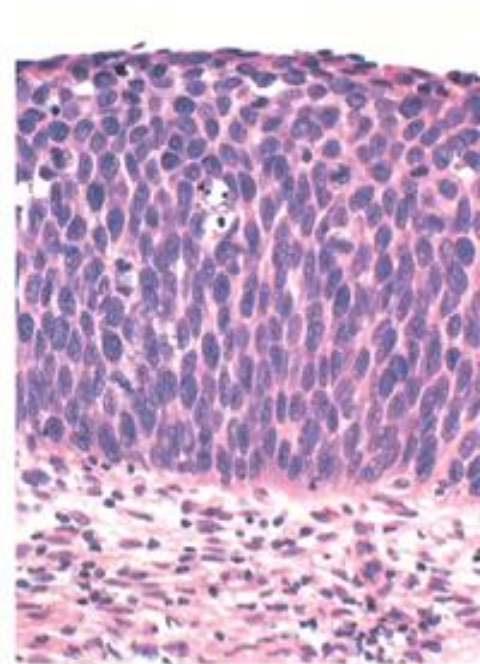
Normal



CIN I

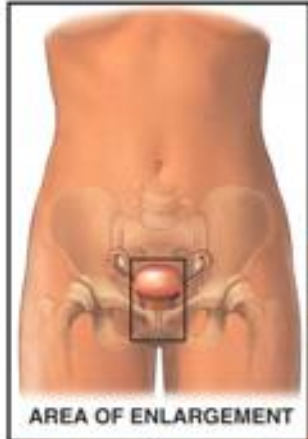


CIN II

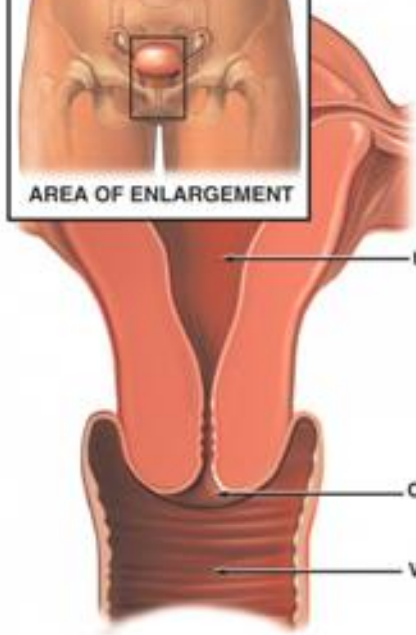


CIN III

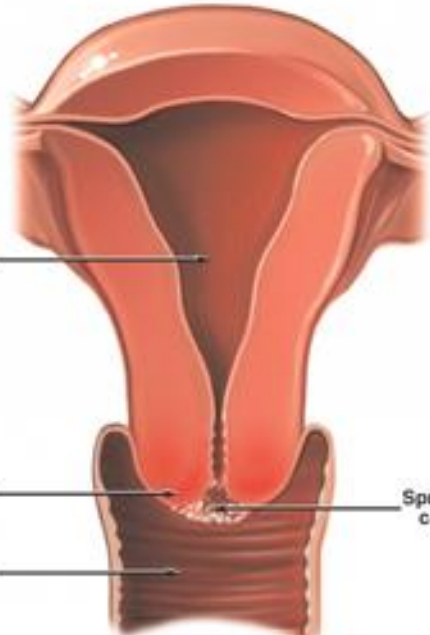
Kumar et al: Robbins & Cotran Pathologic Basis of Disease, 8th Edition.
Copyright © 2009 by Saunders, an imprint of Elsevier, Inc. All rights reserved.



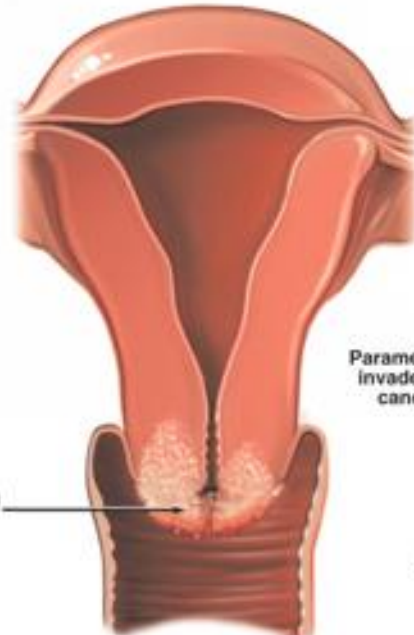
AREA OF ENLARGEMENT



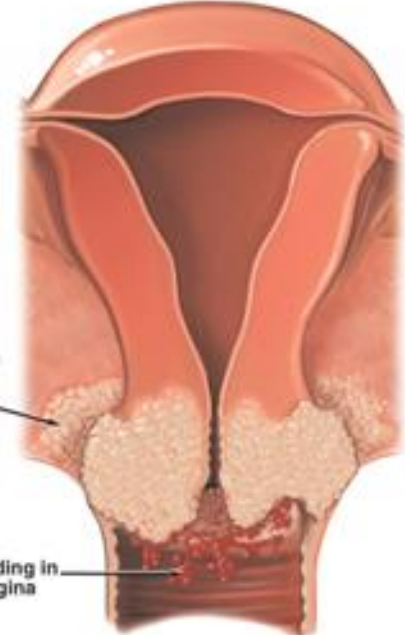
Normal cervix and vagina (cut-away view)



Early stage IB cancer of cervix



Late stage IB cervical cancer



Stage IIB: The cancer spreads outside cervix to pelvic tissue

Uterus

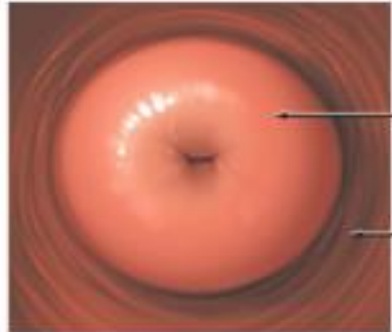
Cervix

Vagina

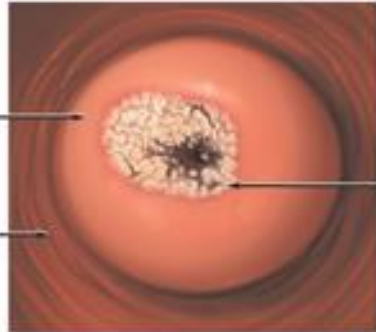
Spreading cancer

Parametrium invaded by cancer

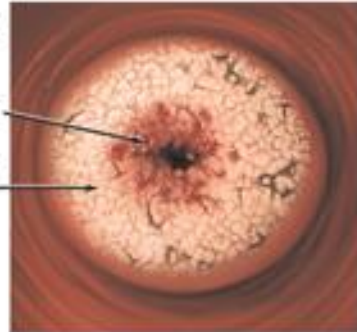
Bleeding in vagina



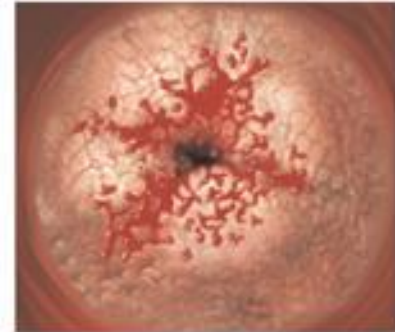Normal cervix (speculum view)



Early stage IB cervical cancer



Late stage IB: cervical cancer is still limited to cervix



Stage IIB cervical cancer

Cervix

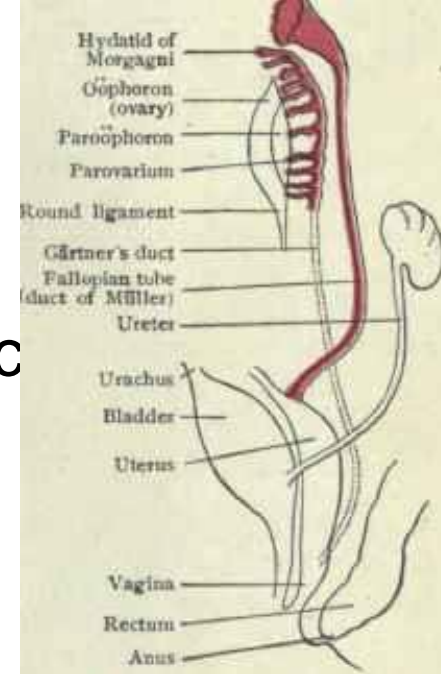
Vagina

Spreading cancer

Surface bleeds easily when touched

Developmental remnants in female

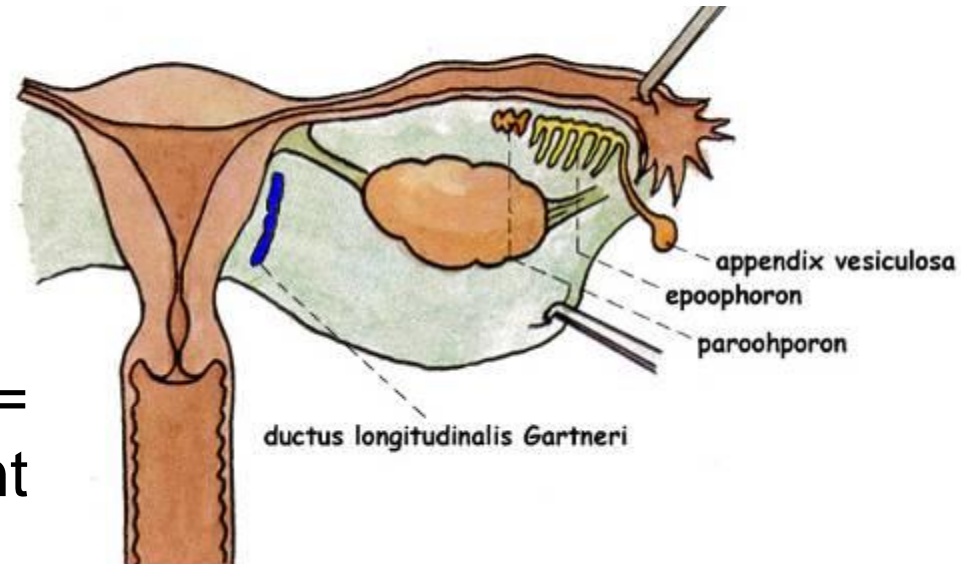
- **epoophoron** *Rosenmülleri* – in mesosalpinx
 - ductuli transversi (remnants of mesonephric tubules)
 - ductus longitudinalis Gartneri (remnant of Wolffian duct near the uterine margin in lig. latum uteri)



- **paroöphoron** *Kobelti* (remnant of mesonephric tubules)
 - in mesosalpinx closer to uterus

Rudiments of female genital organs

- **appendices vesiculosae** (= *hydatis Morgagni*) – remnant of Wolffian duct



Clinical points

- tumors
 - benign – leiomyom
 - malignant – adenocarcinoma
- endometriosis
- amenorrhea
- dysmenorrhoea
- menorhagia, menometrorrhagia

Vagina = *Kolpos*

- 10 cm long muscular tube
- fornix (posterior, anterior, lateralis)
- paries (anterior, posterior)
- ostium vaginae
 - hymen → defloration → carunculae hymenales
- canalis vaginae
 - rugae vaginales
 - columnae rugarum (anterior, posterior)
 - carina urethralis
 - area trigonalis *Pawliki*

Vagina – *relations and syntopy*

- septum urethrovaginale et rectovaginale *Denonvilliersi*
- excavatio rectouterina *Douglasi*
 - peritoneum attaches the dorsal vaginal vault
 - palpation, puncture, colposcopy
- m. pubovaginalis → promontorium of Thomas

Vagina – *supply*

- arteries: **a. iliaca interna**
 - a. vaginalis (sometimes missing)
 - a. uterina → r. vaginalis
 - a. rectalis media → r. vaginalis
 - a. pudenda int. → r. vaginalis
- veins: **plexus venosus uterovaginalis** → v. pudenda int., v. uterina → v. iliaca int.
- lymph: **n.l. iliaci int.+ ext.**
 - n.l. inguinales superficiales (caudally to hymen)

Vagina – *structure*

- tunica mucosa: fold and columns
 - epithelium: non-keratinized stratified squamous
 - glycogen → Lactobacillus acidophilus → lactate → acid pH (4-5)
 - **no** glands (surface lubricated from cervical glands and by transudation)
- tunica muscularis: smooth muscle tissue
 - inner – circular
 - outer – longitudinal
- tunica adventitia
 - paracolpium

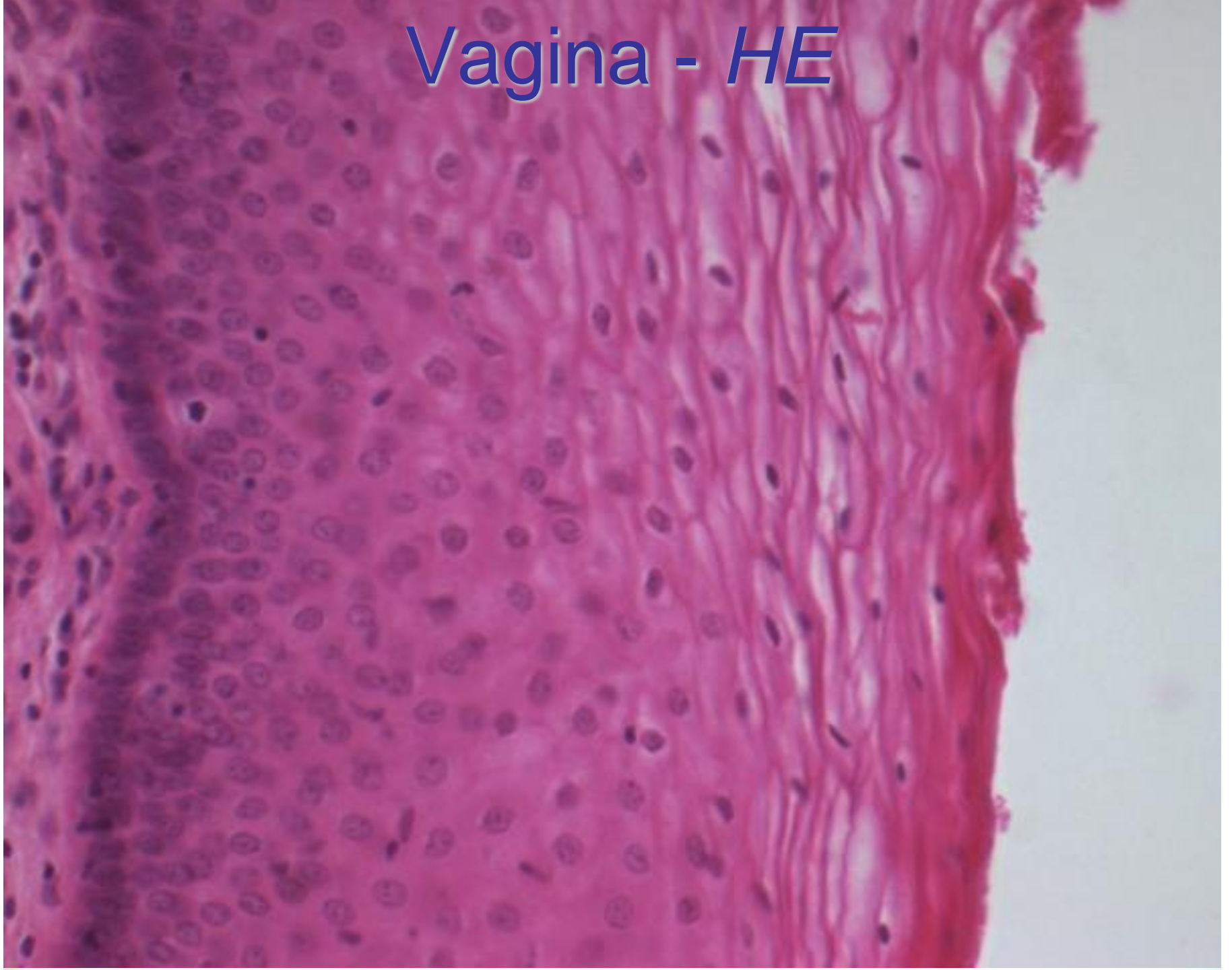Vagina – *epithelium*

4 layers:

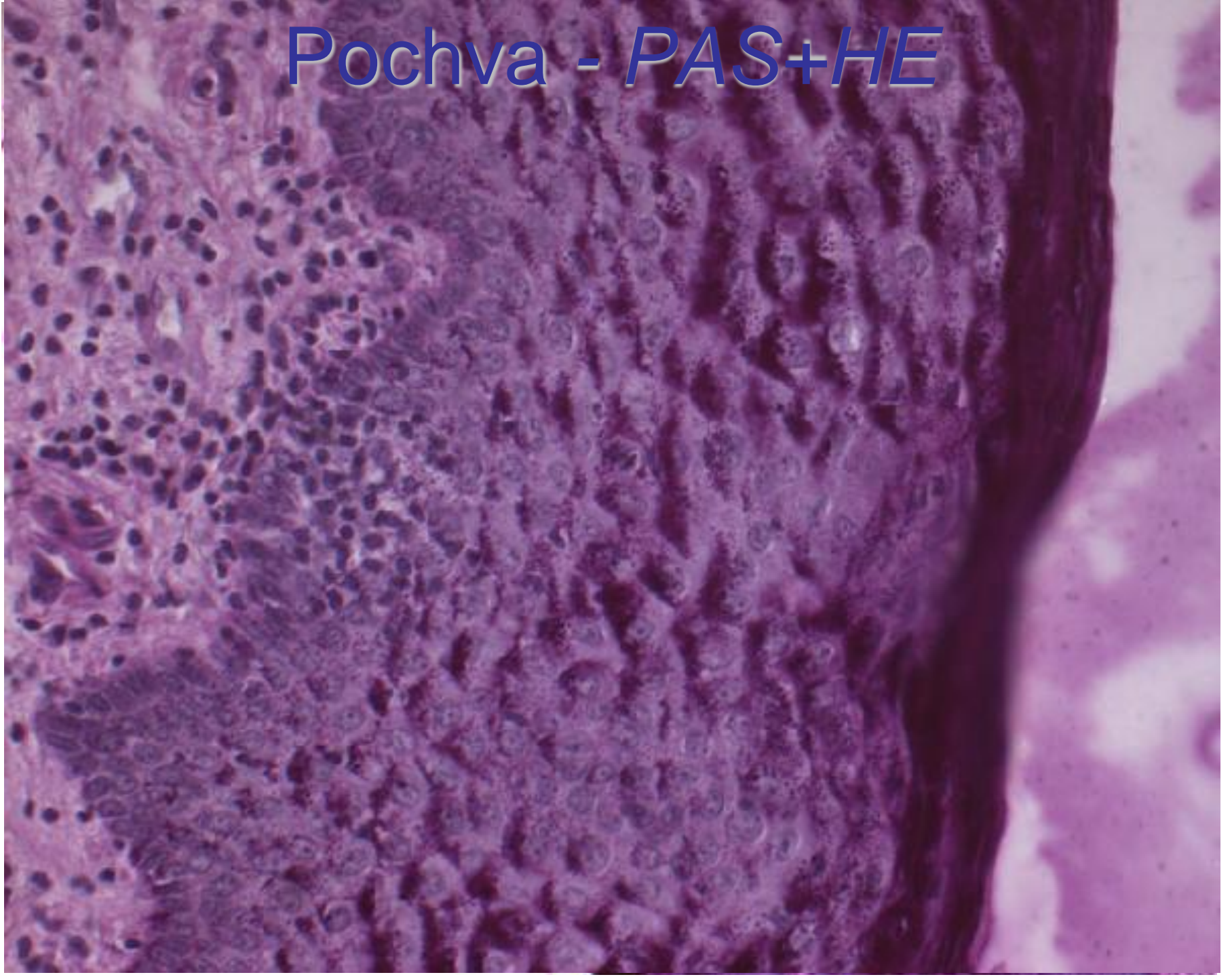
- stratum **basale** – proliferation
- stratum **parabasale** – begin of differentiation, larger cells
- stratum **intermedium** – glycogen, differentiation, flattened cells
- stratum **superficiale** – ↑ glycogen, ↑ differentiation, flattened cells

- dendritic cells
- cyclic changes
 - proliferative phase – cells containing acidic cytoplasm
 - secretory phase – cells containing basophilic cytoplasm
- *vaginal (exfoliative) cytology*

Vagina - HE



Pochva - *PAS+HE*



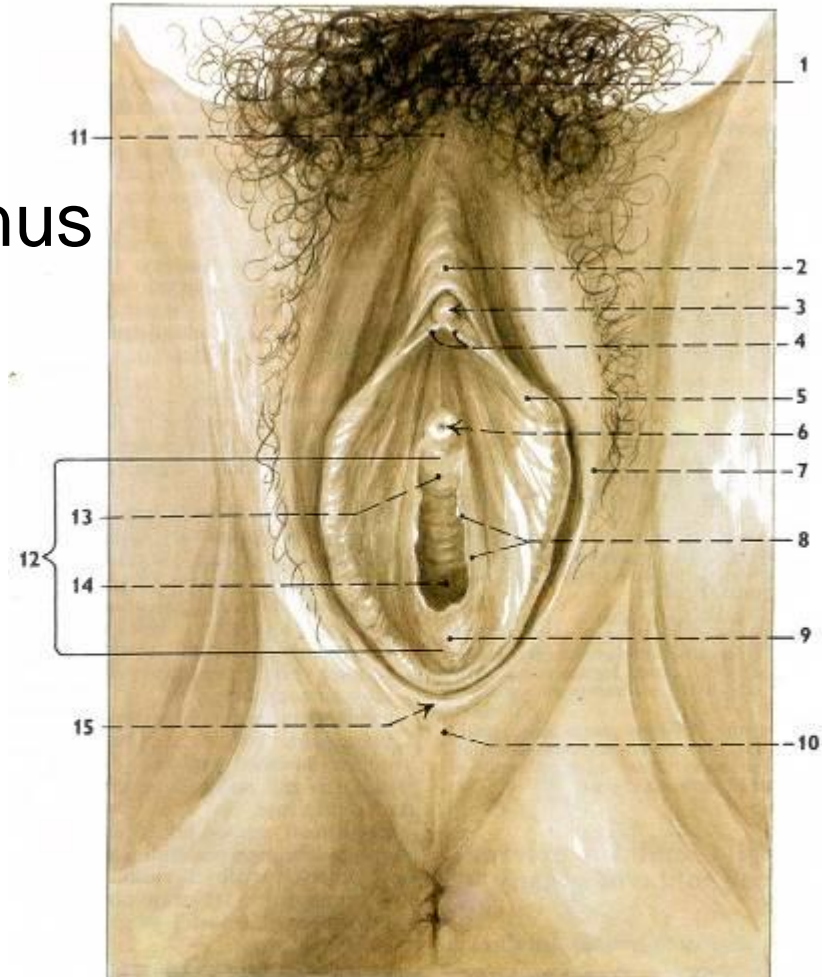
Vagina – *interesting things*

- colposcopy
- culdoscopy
- exfoliative vaginal cytology
- MOP I (pathological conditions MOPII-VII)
- episiotomy
- G-point (Grafenberg) does not exist

Organa genitalia feminina externa (pudendum femininum, vulva)

vulva

- mons pubis = tubercle of Venus
- labia pudendi
- vestibulum vaginae
 - bulbus vestibuli
 - glandulae vestibulares
- clitoris
- urethra feminina



253. ORGANA GENITALIA FEMININA EXTERNA (puloschematically)

- | | |
|------------------------------|------------------------------------|
| 1 / mons pubis | 9 / fossa vestibuli vaginae |
| 2 / praeputium clitoridis | 10 / commissura labiorum posterior |
| 3 / glans clitoridis | 11 / commissura labiorum anterior |
| 4 / frenulum clitoridis | 12 / vestibulum vaginae |
| 5 / labium minus pudendi | 13 / carina urethralis vaginae |
| 6 / ostium urethrae externum | 14 / ostium vaginae |
| 7 / labium majus pudendi | 15 / frenulum labiorum pudendi |
| 8 / hymen | |

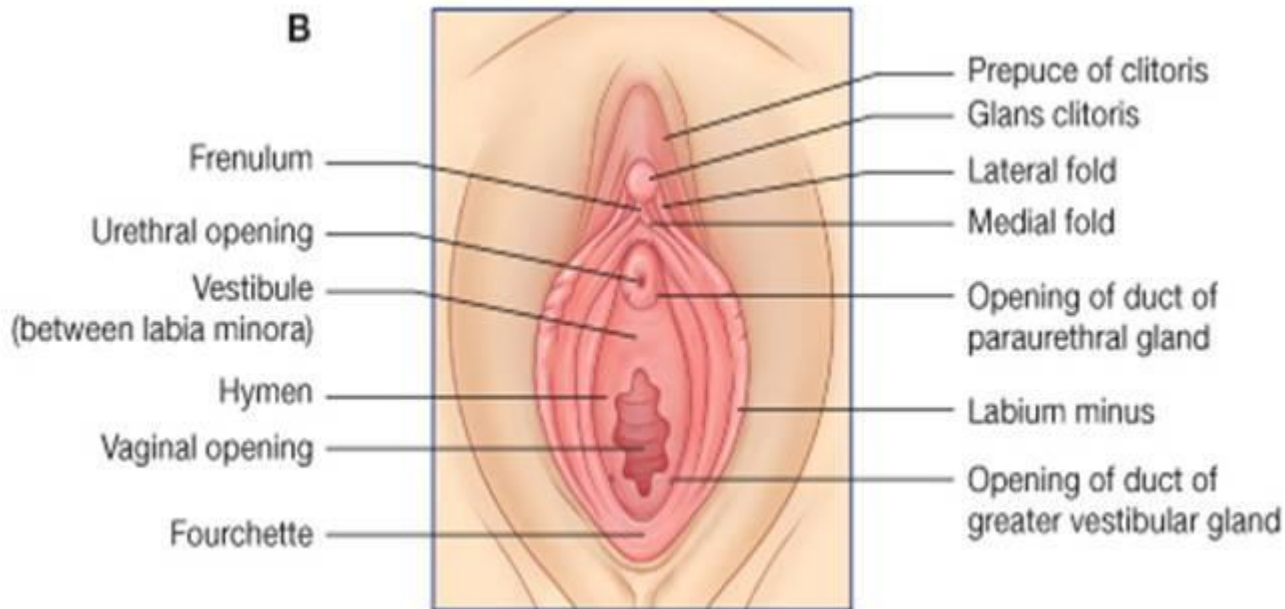
Labia = Labia pudendi

- labia majora
 - collagen connective tissue, adipose cells
 - outward: skin with hair, sebaceous, sweat and aromatic glands
 - inward: hair are missing, present glands
- labia minora
 - no adipose cells
 - stratified squamous epithelium – slightly keratinized
 - sebaceous glands → smegma preputii
- rima pudendi
- commissura labiorum anterior + posterior

Vaginal vestibule

Vestibulum vaginae

- ostium urethrae externum
- ostium vaginae
- ostia glandularium vestibularium

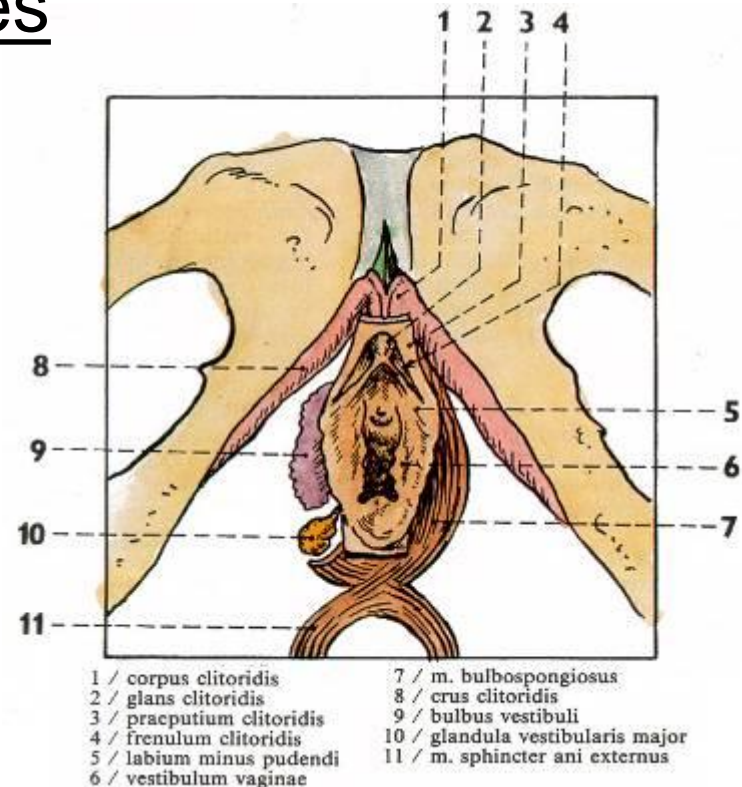


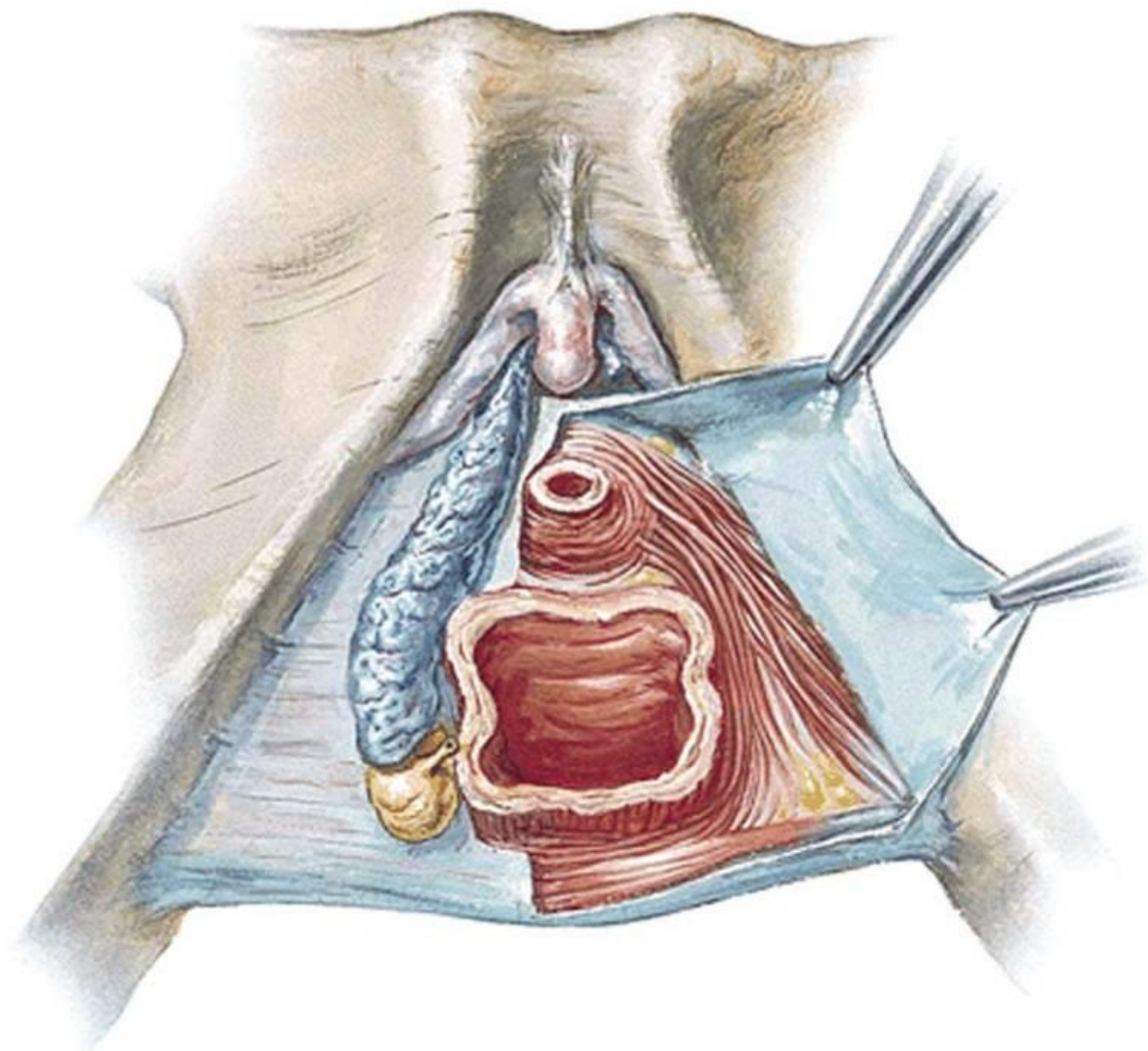
Glands and cavernous bodies

- glandulae vestibulares majores *Bartholini*
 - paired, pea-shaped large
 - from below in membrana perinei
 - tubulo-alveolar and mucous glands
- glandulae vestibulares minores

cavernous bodies:

- clitoris (f.)
- paired cavernous bodies
 - surrounded by tunica albuginea
- bulbus vestibuli
 - paired spongy body
 - commissura bulborum





External genitalia – *blood supply*

Arteries:

- a. femoralis → aa. pudendae ext. → rr. labiales ant.
- a. iliaca int. → a. pudenda int. → rr. labiales post., a. profunda clitoridis, a. dorsalis clitoridis, a. bulbi vestibuli

Veins:

- v. dorsalis superficialis clitoridis + vv. labiales ant. → vv. pudendae ext. → v. saphena magna → v. femoralis communis
- v. dorsalis profunda clitoridis + vv. labiales post. + v. bulbi vestibuli → v. pudenda int. → v. iliaca int.

External genitalia

lymph + nerves

Lymphatic drainage:

- nn.ll. inguinales superficiales
(even cross the midline)

Nerves:

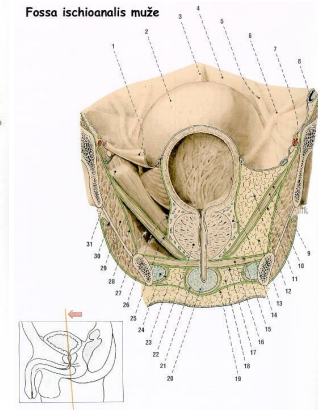
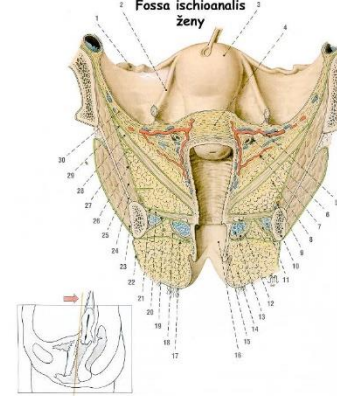
- n. ilioinguinalis
- r. genitalis n. genitofemoralis
- n. pudendus → nn. perineales, nn. labiales post., n. dorsalis clitoridis

Perineum

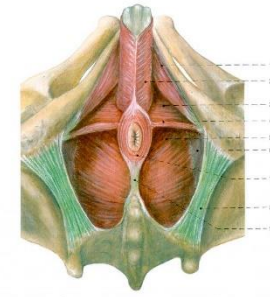
- **corpus perineale** (*centrum tendineum perinei*)
- **mm. perinei** = perinael muscles
- corpus / lig. anococcygeum
- membrana perinei
- trigonum urogenitale et anale
- fossa ischioanalis
 - recessus pubicus
 - canalis pudendalis *Alcocki*
 - corpus adiposum fossae ischioanalis

Urogenital floor

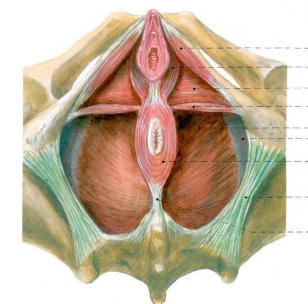
- = diaphragma urogenitale
- **NOT PROPER TERM** of Terminologia Anatomica 1998
- fits for illustration
- **perineal muscles = *musculi perinei*** according to TA 1998
- 4 muscles in line = „floor“
- + 3 ♀ / 1 ♂ another muscles around urethra
- its centre is corpus perineale



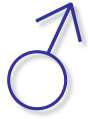Svaly dna pánevního a močopohlavního muže žabí perspektiva



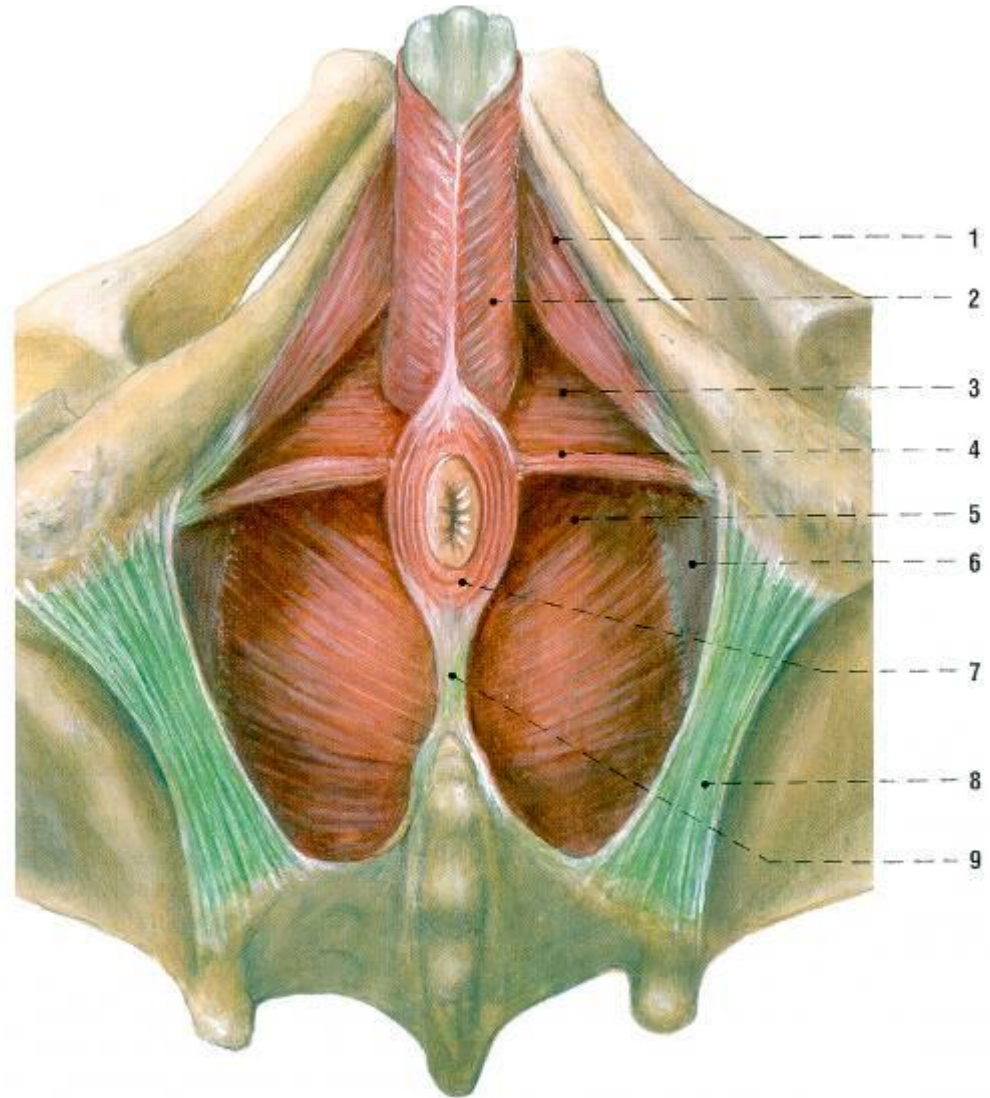
Svaly dna pánevního a močopohlavního ženy žabí perspektiva



Svaly dna pánevního a močopohlavního muže žabí perspektiva

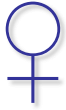

- m. transversus perinei profundus
- m. transversus perinei superficialis
- m. bulbospongiosus
- m. ischiocavernosus
- m. sphincter urethrae externus

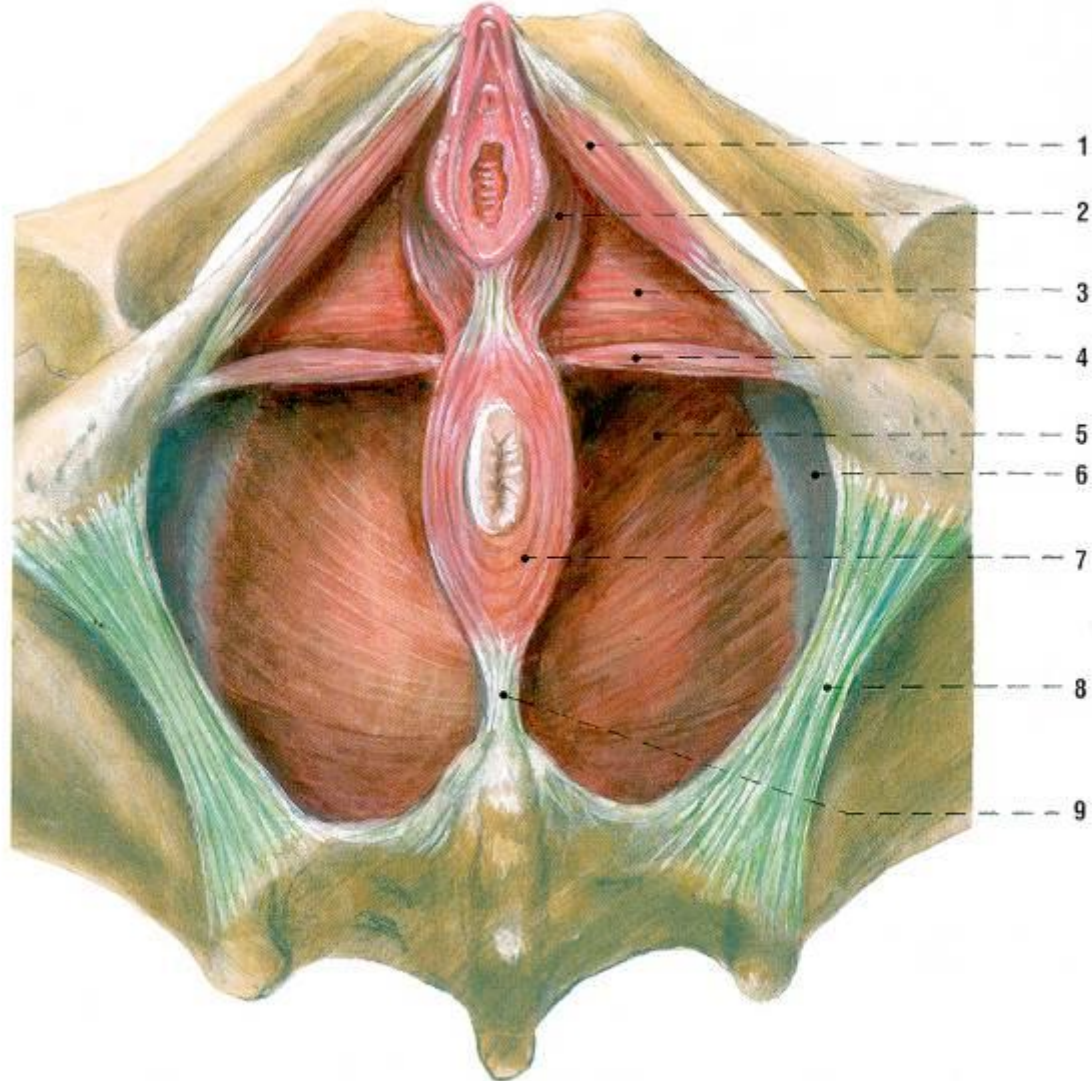


1 m. ischiocavernosus
2 m. bulbospongiosus
3 diaphragma urogenitale
4 m. transversus perinei superficialis

5 m. levator ani
6 m. obturatorius internus a jcho fascie
7 m. sphincter ani externus
8 lig. sacrotuberale
9 lig. anocecygeum



- m. bulbospongiosus
- m. ischiocavernosus
- m. transversus perinei superficialis



1 m. ischiocavernosus
2 m. bulbospongiosus
3 diaphragma urogenitale
4 m. transversus perinei superficialis

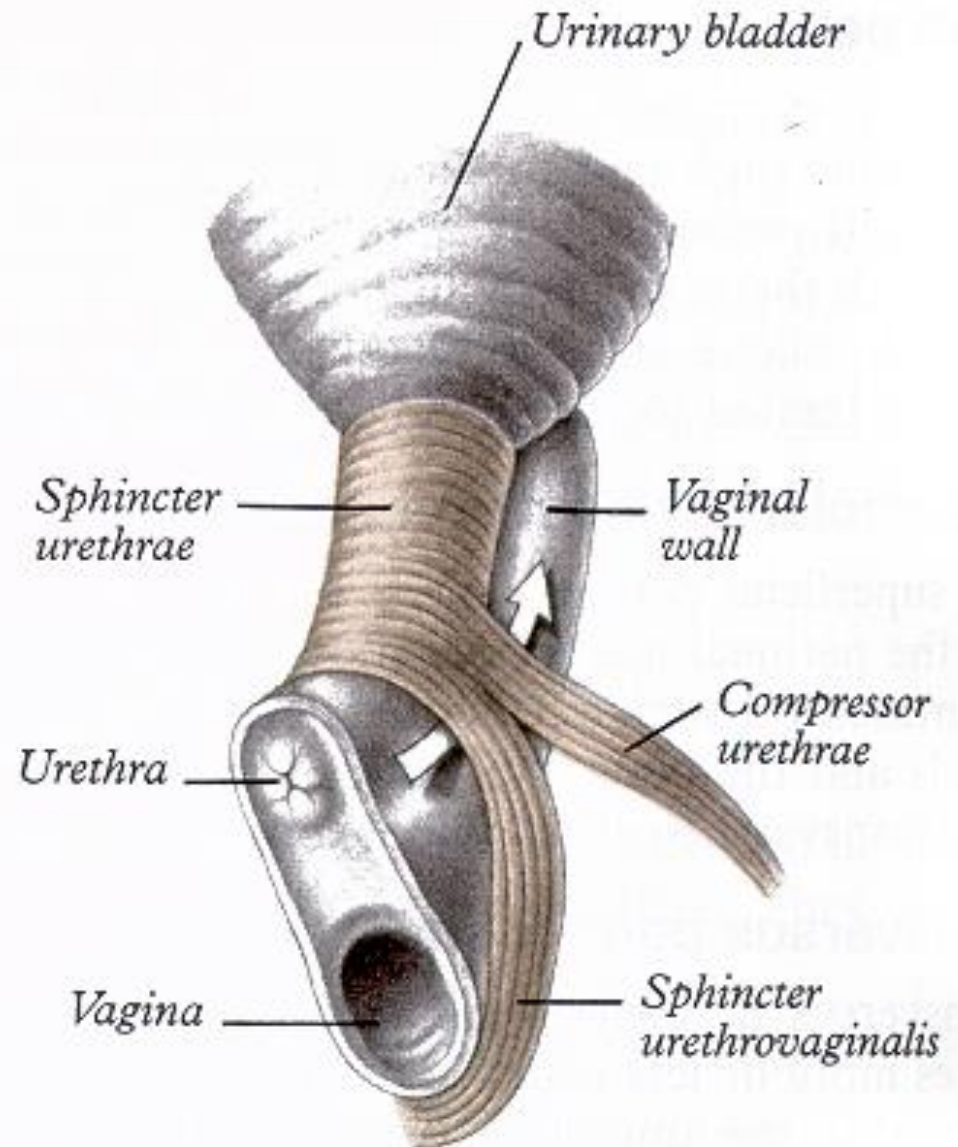
5 m. levator ani
6 m. obturatorius internus a jeho fascie
7 m. sphincter ani externus
8 lig. sacrotuberale
9 lig. anococcygeum



- m. sphincter urethrae



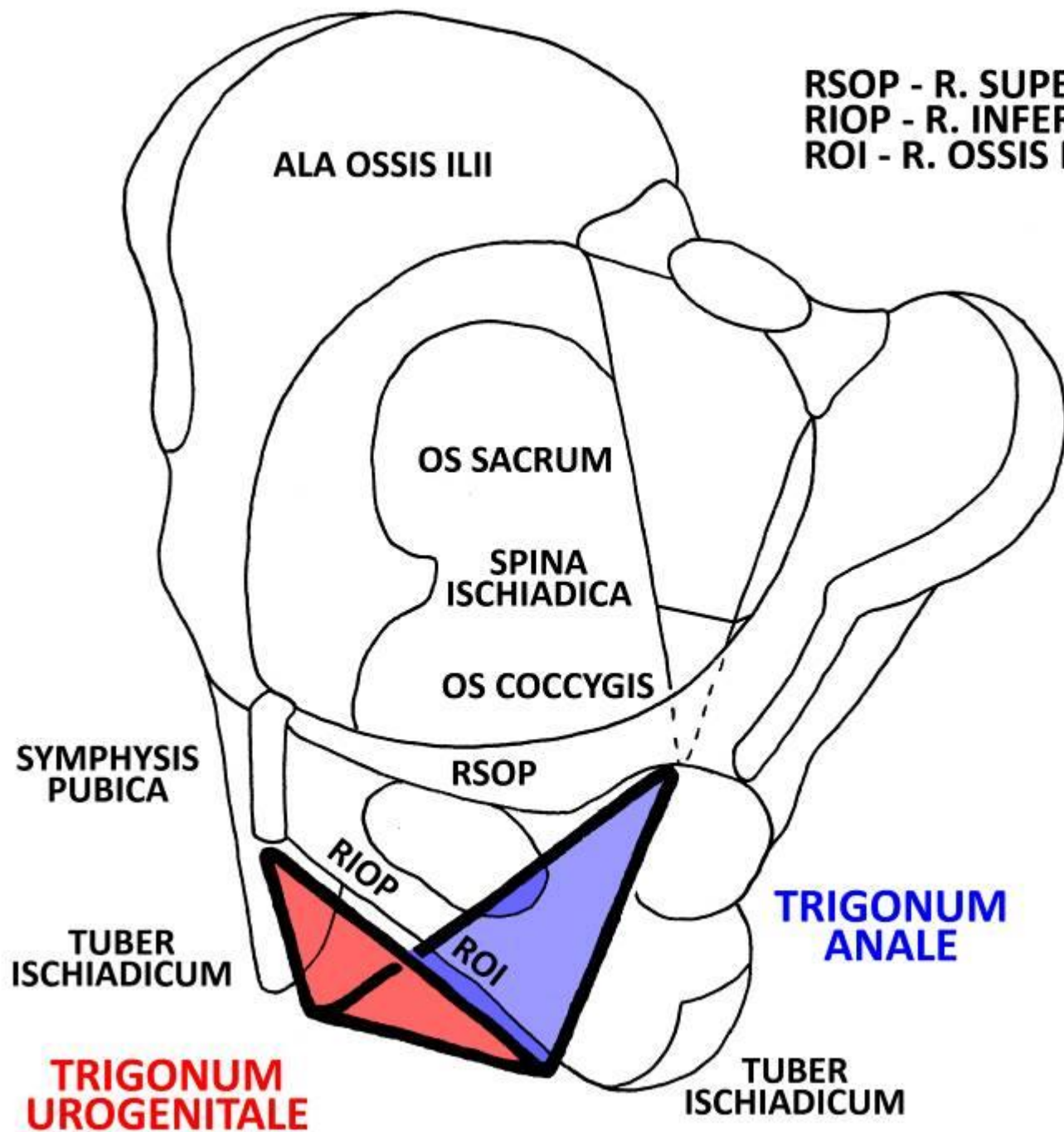
- m. sphincter urethrae
- m. compressor urethrae
- m. sphincter urethrovaginalis



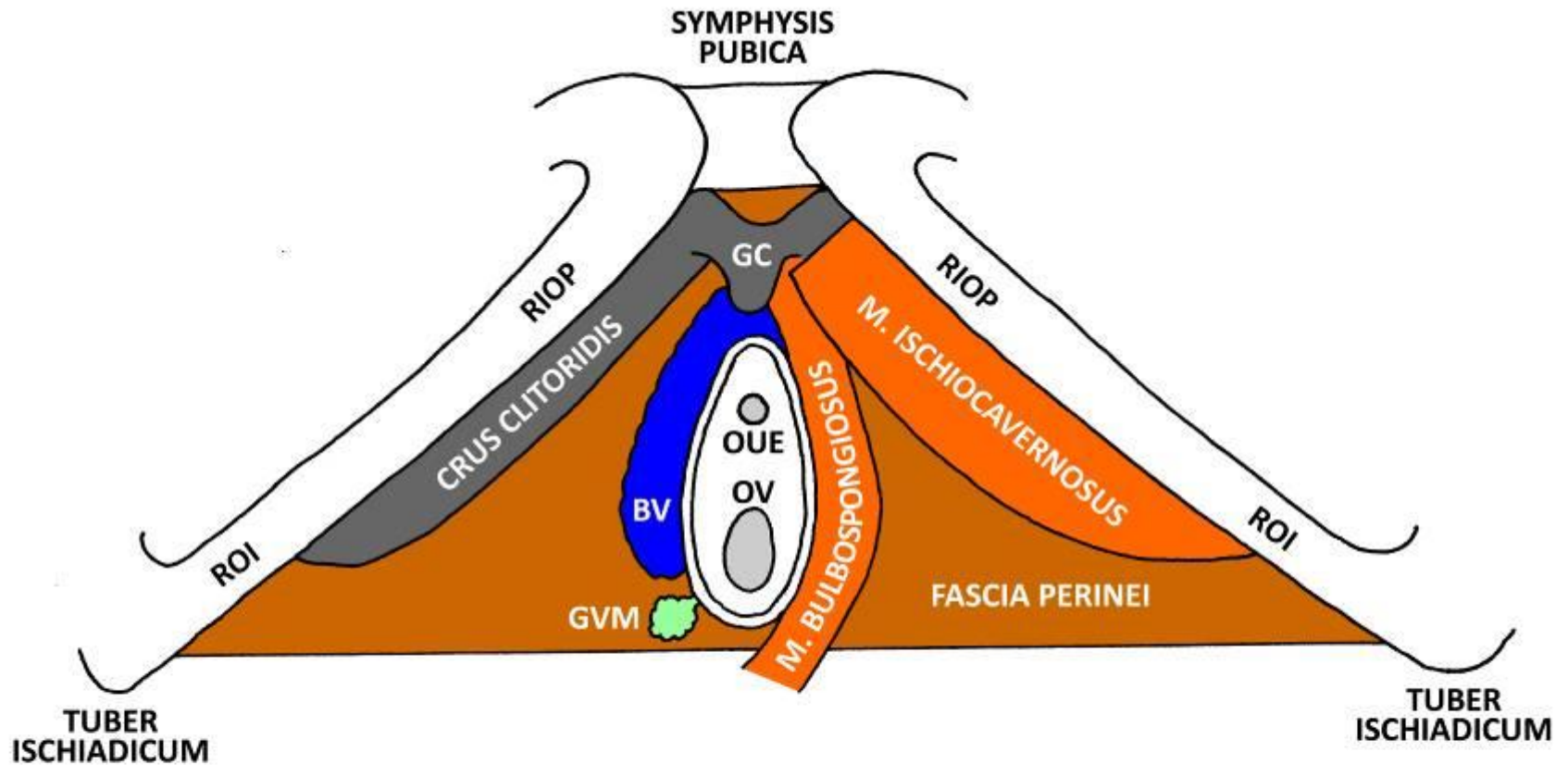
Perineal muscles - *innervation*

root S4

- nn. perineales n. pudendi
- rr. anteriores nn. sacralium
- nn. splanchnici sacrales

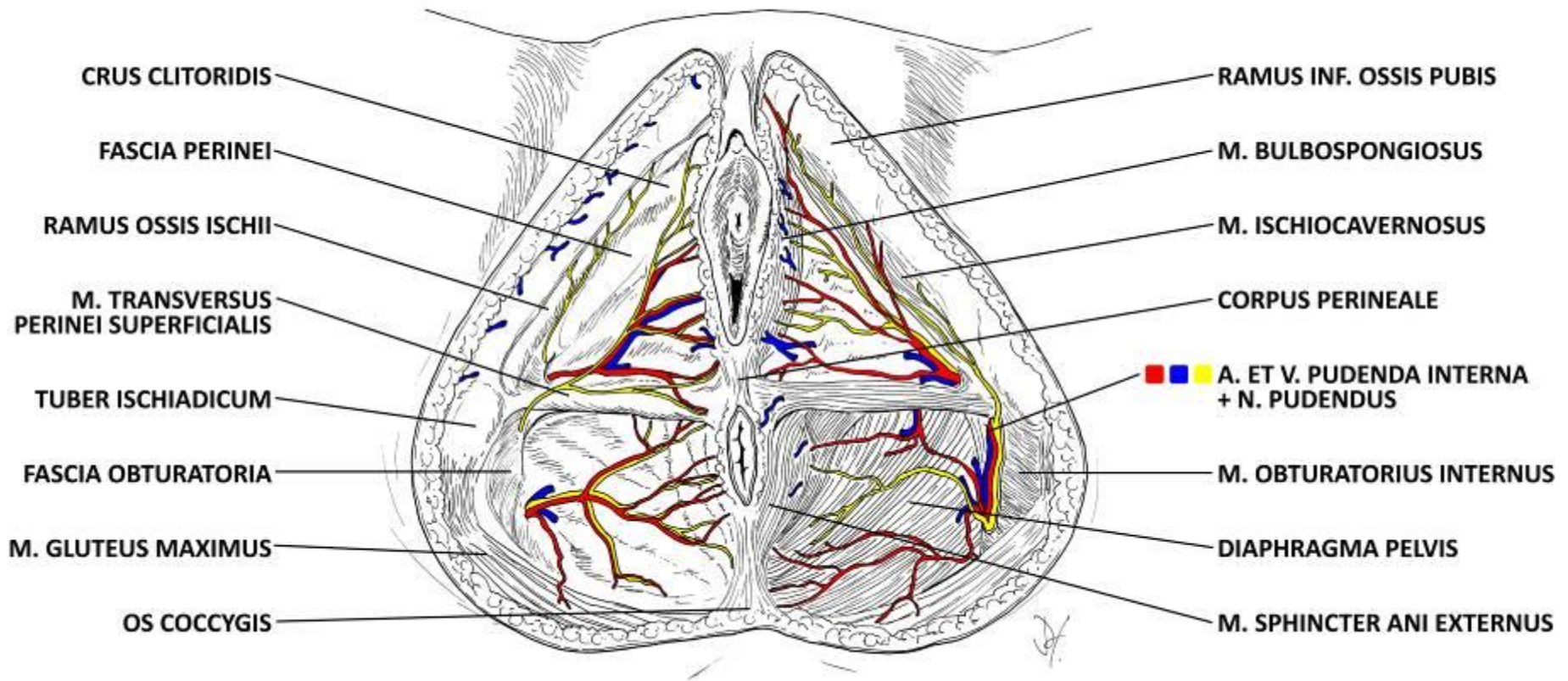


Trigonum urogenitale ♀



RIOP - R. INF. OSSIS PUBIS
ROI - R. OSSIS ISCHII
GC - GLANS CLITORIDIS
BV - BULBUS VESTIBULI
OUE - OSTIUM URETHRAE EXTERNUM
OV - ORIFICIUM VAGINAE
GVM - GLANDULA VESTIBULARIS MAJOR

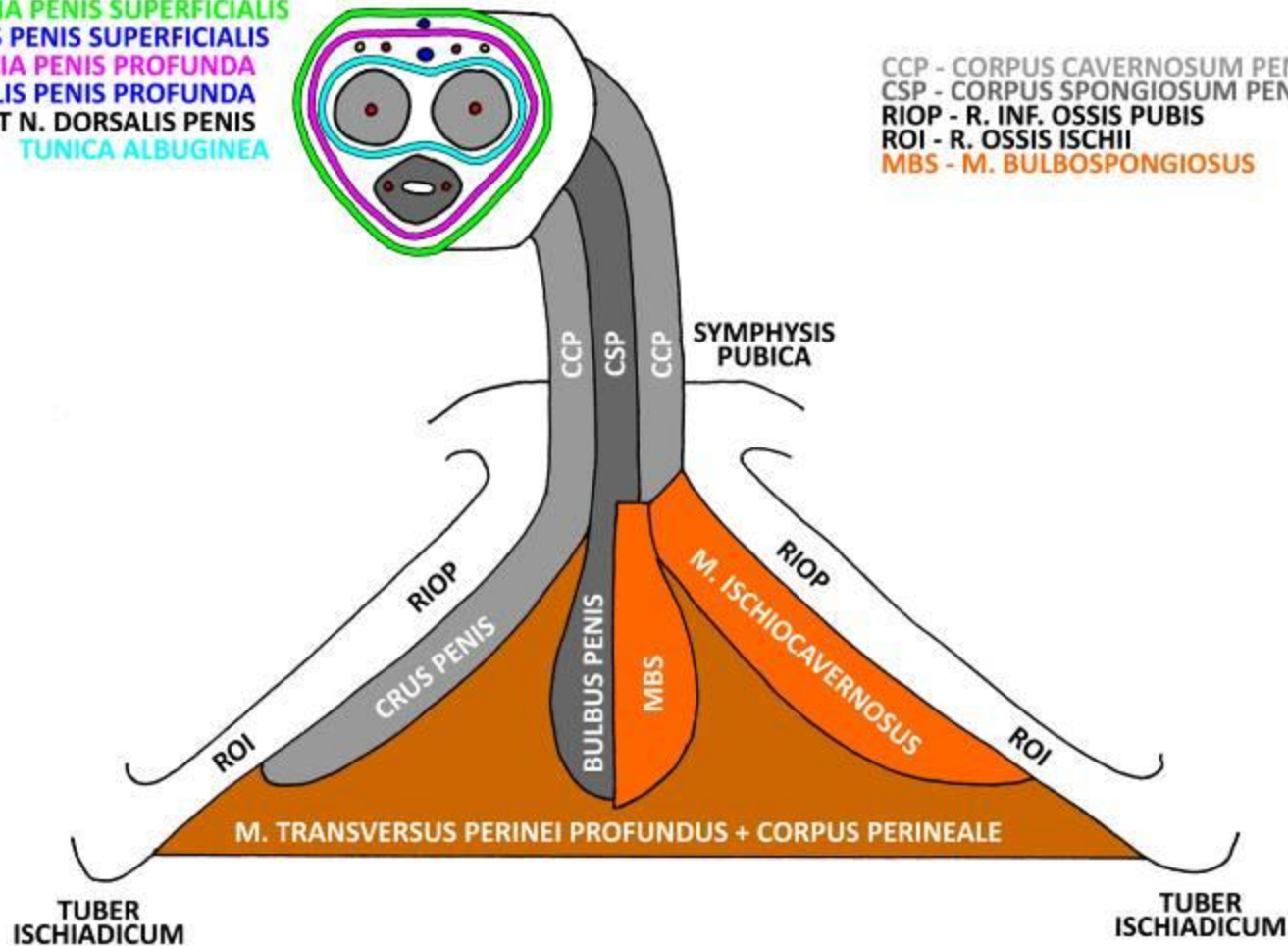
Regio perinealis ♀



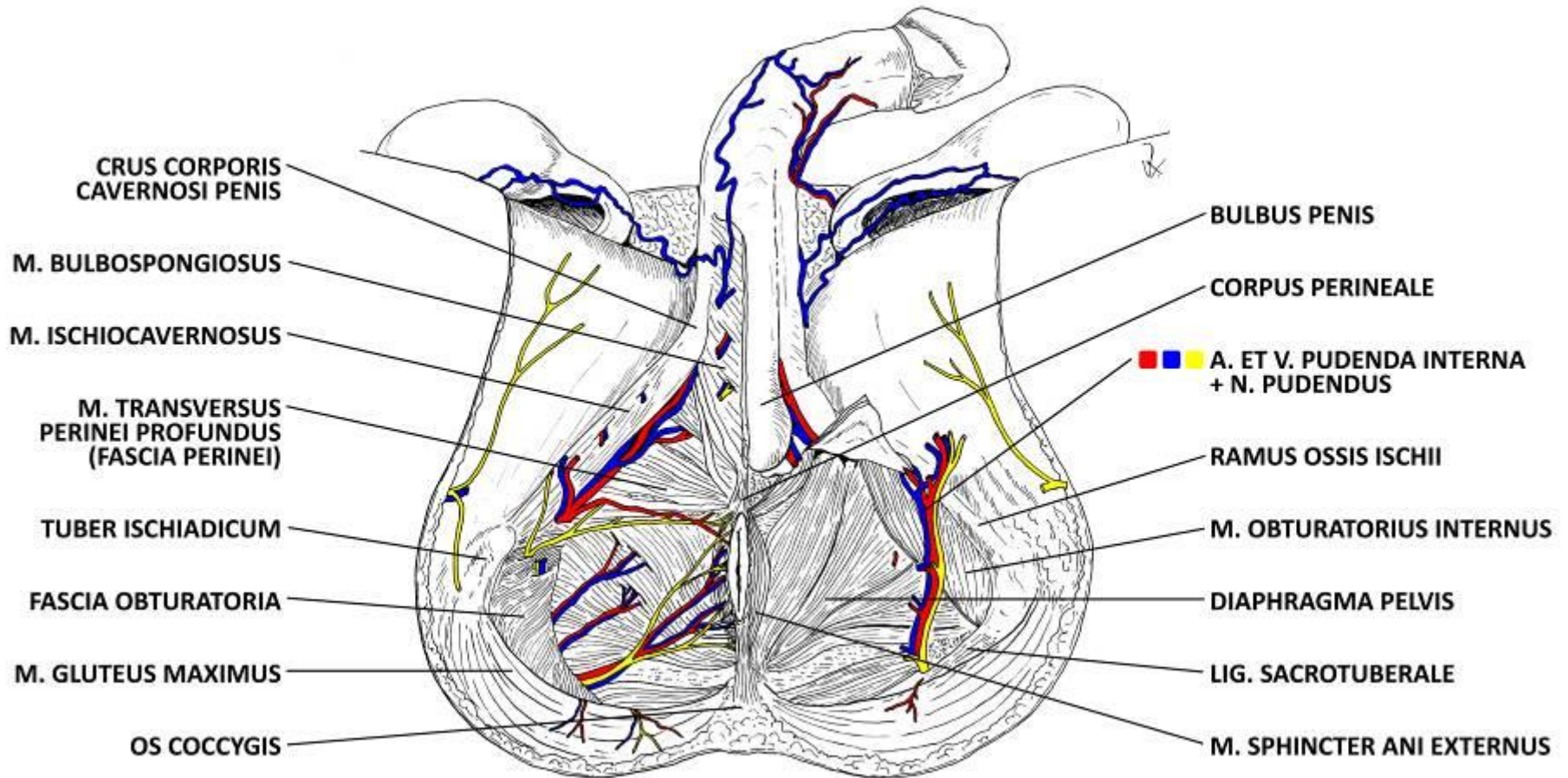
Trigonum urogenitale ♂

FASCIA PENIS SUPERFICIALIS
V. DORSALIS PENIS SUPERFICIALIS
FASCIA PENIS PROFUNDA
V. DORSALIS PENIS PROFUNDA
+ A. ET N. DORSALIS PENIS
TUNICA ALBUGINEA

CCP - CORPUS CAVERNOSUM PENIS + A. PROFUNDA PENIS
CSP - CORPUS SPONGIOSUM PENIS + AA. URETHRALES
RIOP - R. INF. OSSIS PUBIS
ROI - R. OSSIS ISCHII
MBS - M. BULBOSPONGIOSUS



Regio perinealis ♂



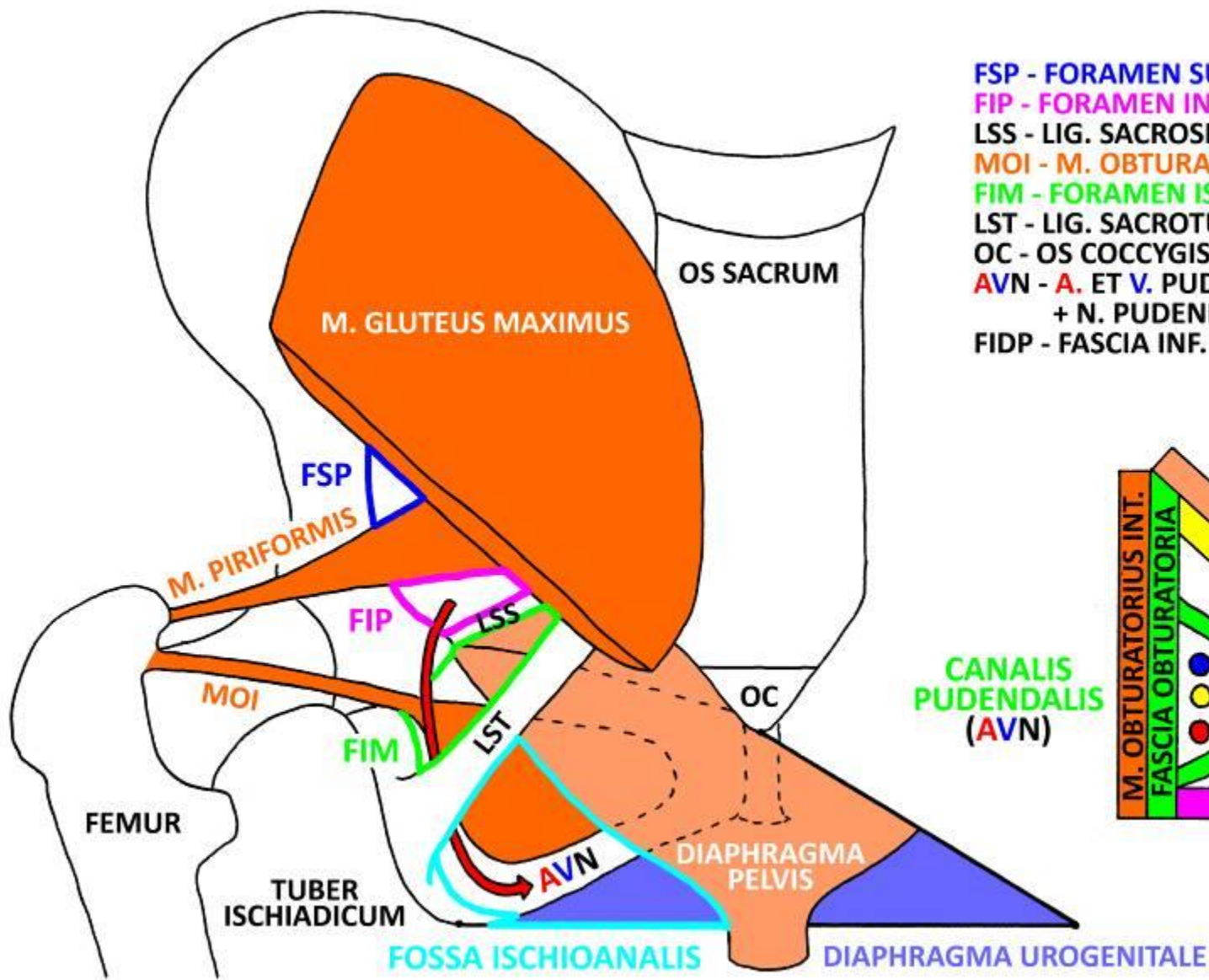
Fossa ischioanal

Boundaries:

- **MEDIOCRANIALY + CRANIALY:** m. sphincter ani externus, fascia inferior diaphragmatis pelvis
- **LATERALLY:** tuber ischiadicum, fascia obturatoria
- **DORSALLY:** lower margin of m. gluteus maximus, lig. sacrotuberale
- **CAUDALLY:** fascia perinei superficialis

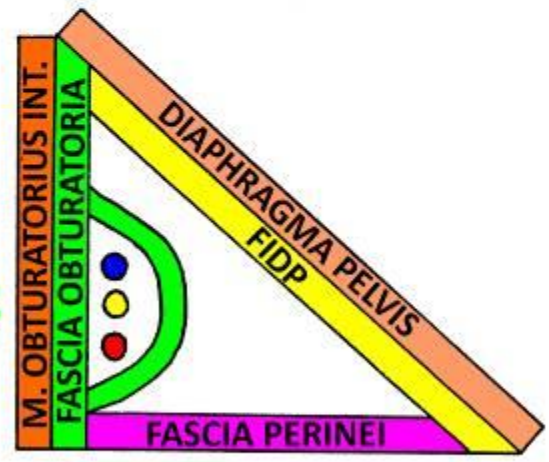
CONTENT:

- canalis pudendalis (*Alcocki*)
- corpus adiposum fossae ischioanal
- paired recessus pubicus extends ventrally above trigonum urogenitale up to symphysis pubica

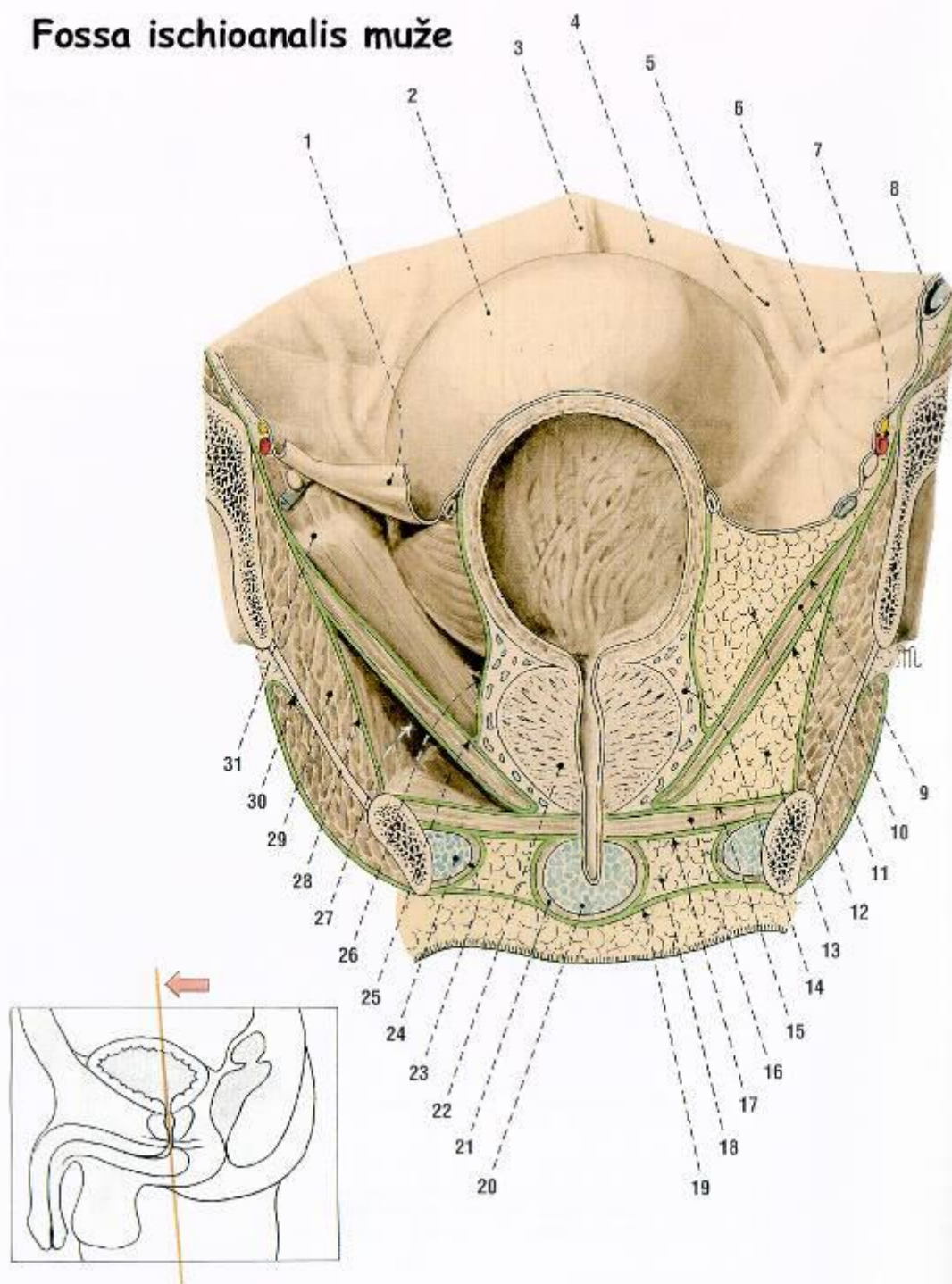
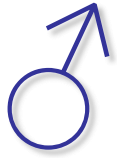

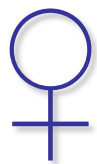- FSP - FORAMEN SUPRAPIRIFORME
- FIP - FORAMEN INFRAPIRIFORME
- LSS - LIG. SACROSPINALE
- MOI - M. OBTURATORIUS INTERNUS
- FIM - FORAMEN ISCHIADICUM MINUS
- LST - LIG. SACROTUBERALE
- OC - OS COCCYGIS
- AVN - A. ET V. PUDENDA INTERNA
+ N. PUDENDUS
- FIDP - FASCIA INF. DIAPHRAGMATIS PELVIS

CANALIS PUDENDALIS (AVN)



Fossa ischioanalis muže





Fossa ischioanalis ženy

