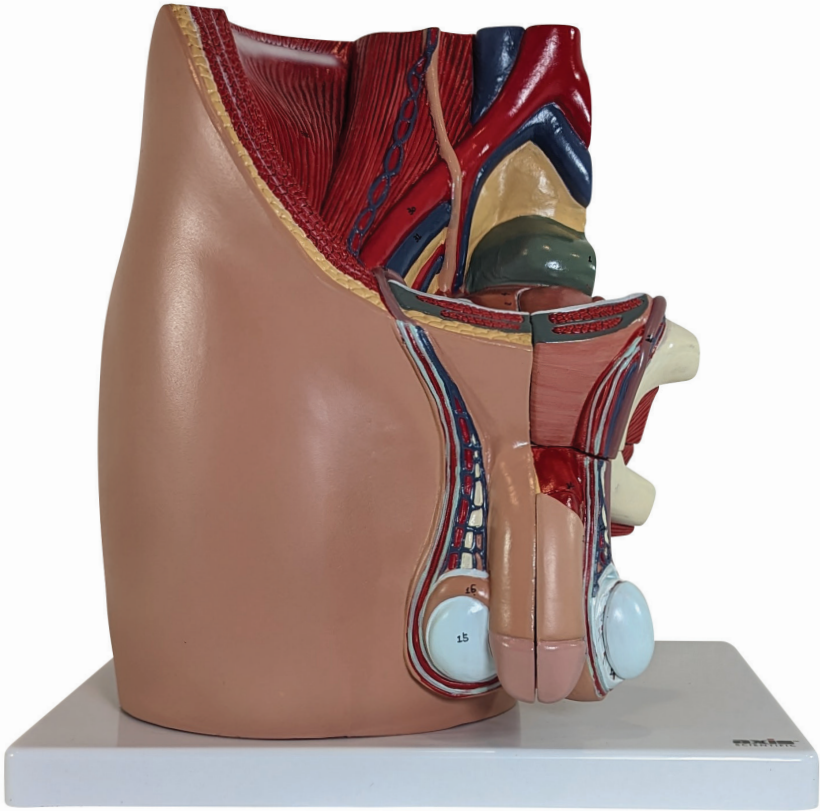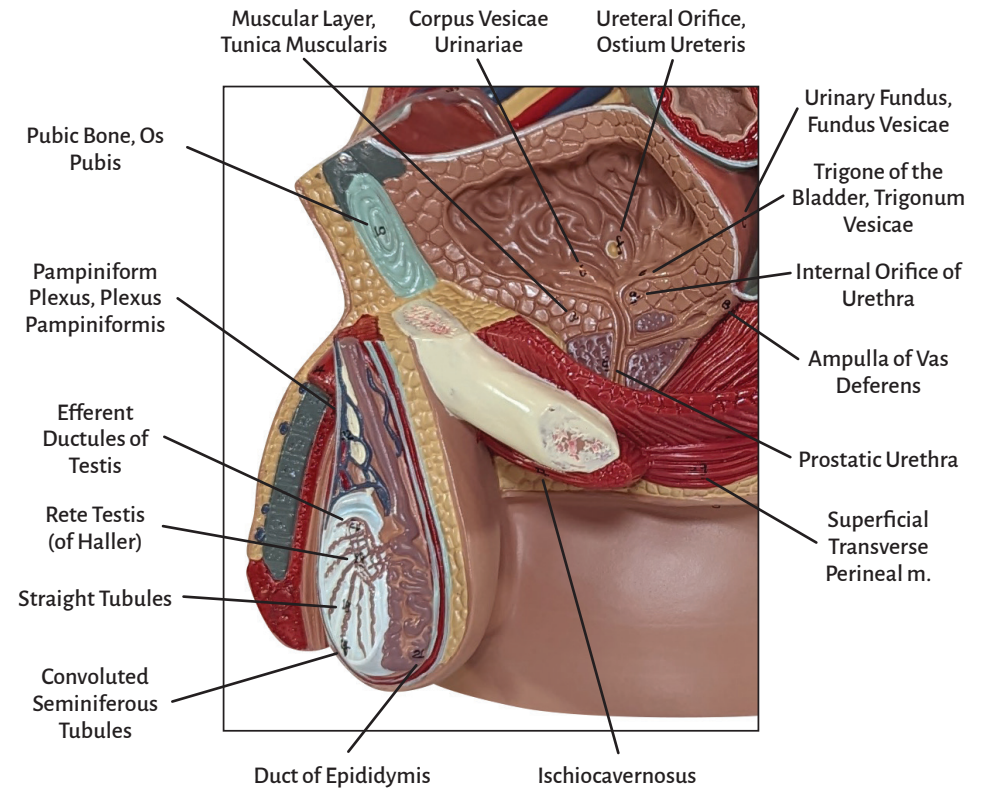
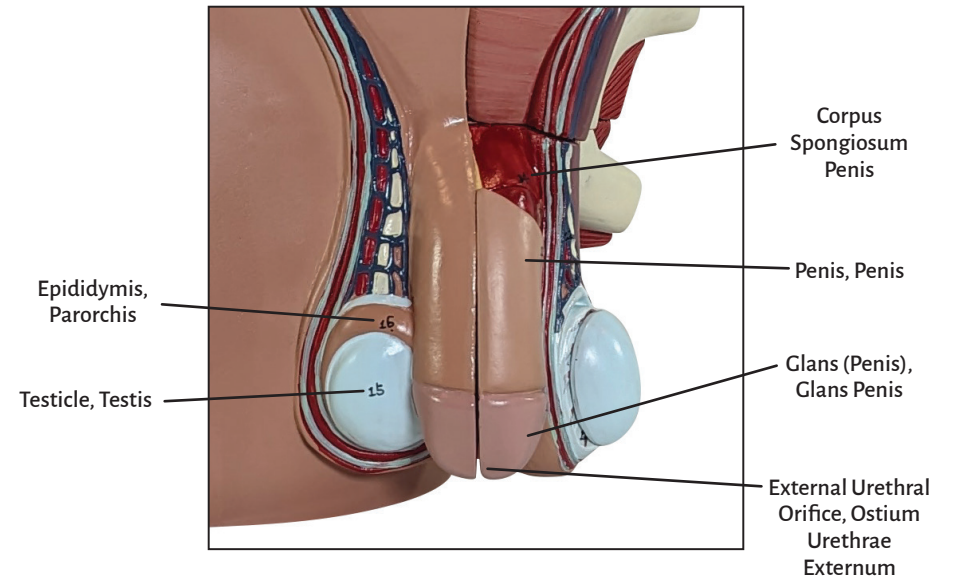
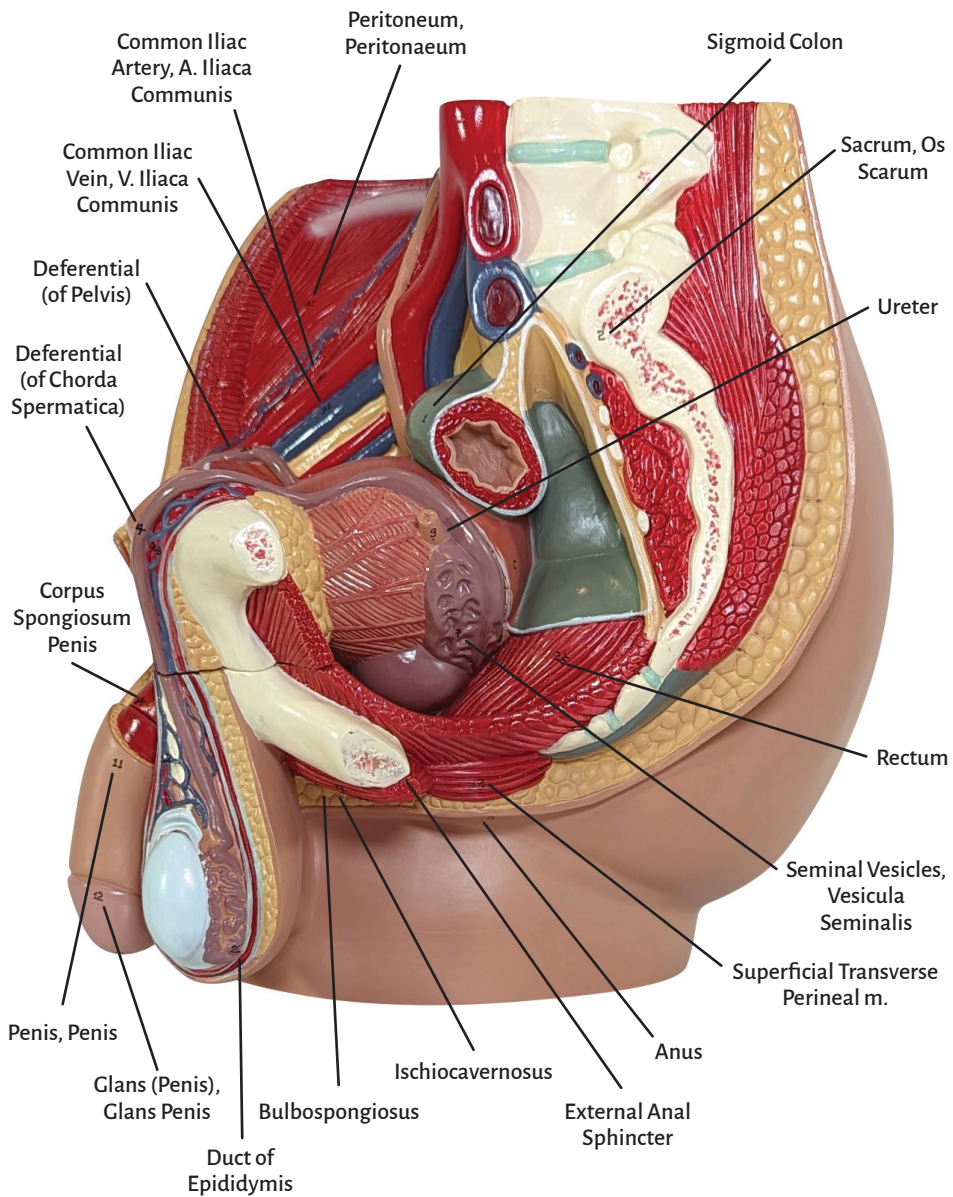
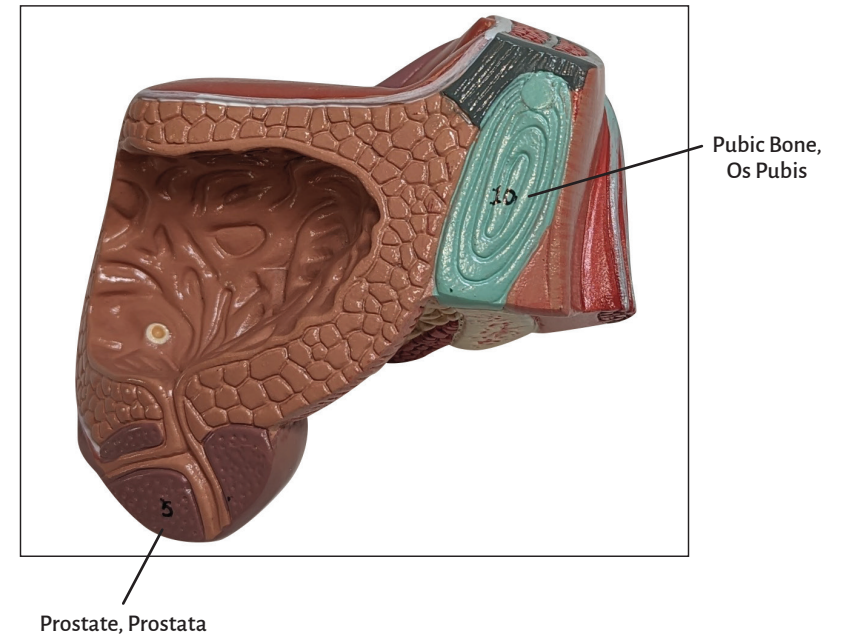
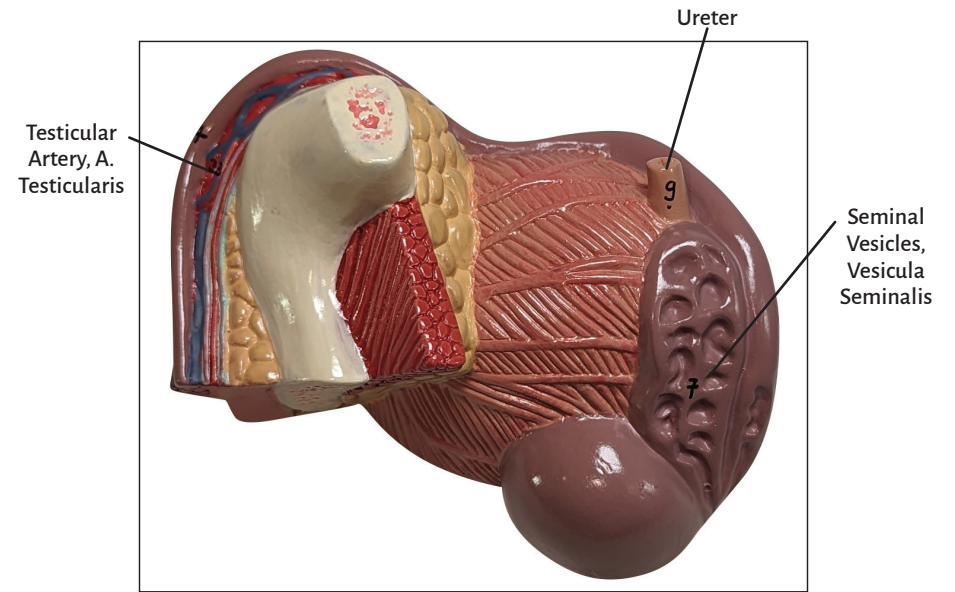
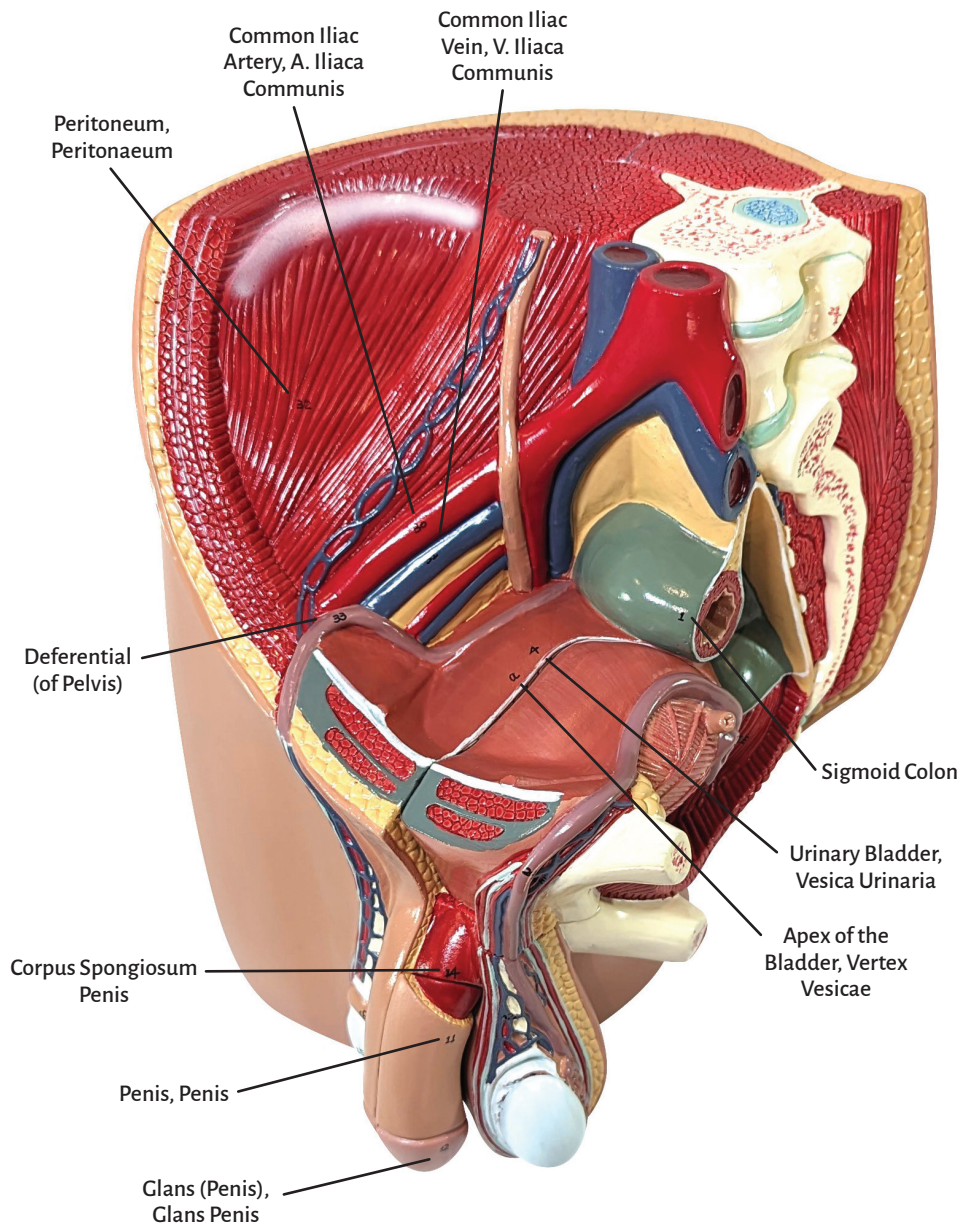




Axis Scientific 4-Part Male Pelvis

A-105187







4-Part Male Pelvis

Sigmoid Colon	Straight Tubules
Sacrum, Os Sacrum	Rete Testis (of Haller)
Anus	Efferent Ductules of Testis
Urinary Bladder, Vesica Urinaria	Duct of Epididymis
Prostate, Prostata	Pampiniform Plexus, Plexus Pampiniformis
Prostatic Urethra	Testicular Artery, A. Testicularis
Seminal Vesicles, Vesicula Seminalis	Deferential (of Chorda Spermatica)
Ampulla of Vas Deferens	Rectum
Ureter	Bulbospongiosus
Pubic Bone, Os Pubis	Ischiocavernosus
Penis, Penis	Superficial Transverse Perineal m.
Glans (Penis), Glans Penis	External Anal Sphincter
External Urethral Orifice, Ostium Urethrae Externum	Common Iliac Artery, A. Iliaca Communis
Corpus Spongiosum Penis	Common Iliac Vein, V. Iliaca Communis
Testicle, Testis	Peritoneum, Peritoneum
Epididymis, Parorchis	Deferential (of Pelvis)
Convolutated Seminiferous Tubules	

