

Cryptosporidiosis, Isosporiasis, Cyclosporiasis & Sarcocystosis

Mary K. Klassen-Fischer, Ronald C. Neafie,
Douglas J. Wear and Wayne M. Meyers

Introduction

Cryptosporidiosis, isosporiasis, cyclosporiasis, and sarcocystosis are diseases caused by protozoa of the phylum Sporozoa, class Coccidea, order Eimeriida.¹ All are obligate intracellular parasites of intestinal epithelial cells. *Cryptosporidium* sp, *Isospora belli* and *Cyclospora cayotensis* complete their life cycles within a single host. They cause self-limited or prolonged diarrhea, depending on the host's immune status. In contrast *Sarcocystis* requires two host species. Compared to other coccidia, *Cryptosporidium* sp are less host or organ specific, resist antimicrobial agents and produce auto infection, features more closely related to gregarines.²

CRYPTOSPORIDIOSIS

Definition and General Considerations

At least 9 species and 4 genotypes of *Cryptosporidium* cause human infection: *C. hominis*, *C. parvum*, *C. meleagridis*, *C. felis*, *C. canis*, and occasionally *C. muris*, *C. suis*, *C. andersoni*, and *Cryptosporidium cervine* sp and, *Cryptosporidium* genotypes in horse, rabbit, skunk, and chipmunk.³ *Cryptosporidium hominis* and *C. parvum* are morphologically identical and their completely sequenced

genomes are 97% identical.^{4,5,6} Although both have 8 chromosomes, the genome of *C. hominis* appears slightly larger, 9.16 Mb to 9.11 Mb and 3,994 to 3,952 genes compared to the genome of *C. parvum*.⁵ *Cryptosporidium* was first described in 1895,⁷ identified in 1910,⁸ and in the 1970s recognized as a cattle pathogen. Some early reported patients had contact with livestock. In the 1980s, *C. parvum* was discovered to be the cause of prolonged diarrhea in patients with acquired immunodeficiency syndrome (AIDS), and is now known also to cause diarrhea in immunocompetent patients.¹

Epidemiology

Cryptosporidium causes approximately 250 to 500 million cases of diarrhea per year in developing nations of Asia, Africa, and Latin America. *Cryptosporidium* is the most common parasitic cause of diarrhea in the United Kingdom,⁹ and infected 28,636 persons in the United States between 2006 and 2008.¹⁰ The asymptomatic carriage rate may be as high as 13% among immunocompetent individuals.¹¹ Cryptosporidiosis develops in an estimated 10-15% of patients with AIDS in the United States and in 30%-50% of patients with AIDS in the developing world.¹² The serological prevalence of *Cryptosporidium*

Report Documentation Page

Form Approved
OMB No. 0704-0188

Public reporting burden for the collection of information is estimated to average 1 hour per response, including the time for reviewing instructions, searching existing data sources, gathering and maintaining the data needed, and completing and reviewing the collection of information. Send comments regarding this burden estimate or any other aspect of this collection of information, including suggestions for reducing this burden, to Washington Headquarters Services, Directorate for Information Operations and Reports, 1215 Jefferson Davis Highway, Suite 1204, Arlington VA 22202-4302. Respondents should be aware that notwithstanding any other provision of law, no person shall be subject to a penalty for failing to comply with a collection of information if it does not display a currently valid OMB control number.

1. REPORT DATE JUN 2011	2. REPORT TYPE	3. DATES COVERED 00-00-2011 to 00-00-2011			
4. TITLE AND SUBTITLE Cryptosporidiosis, Isosporidiosis, Cyclosporiasis, Sarcocystosis		5a. CONTRACT NUMBER			
		5b. GRANT NUMBER			
		5c. PROGRAM ELEMENT NUMBER			
6. AUTHOR(S)		5d. PROJECT NUMBER			
		5e. TASK NUMBER			
		5f. WORK UNIT NUMBER			
7. PERFORMING ORGANIZATION NAME(S) AND ADDRESS(ES) Inova Central Laboratory, 2832 Juniper Street, Fairfax, VA, 22031		8. PERFORMING ORGANIZATION REPORT NUMBER			
9. SPONSORING/MONITORING AGENCY NAME(S) AND ADDRESS(ES)		10. SPONSOR/MONITOR'S ACRONYM(S)			
		11. SPONSOR/MONITOR'S REPORT NUMBER(S)			
12. DISTRIBUTION/AVAILABILITY STATEMENT Approved for public release; distribution unlimited					
13. SUPPLEMENTARY NOTES See also ADA545141. Chapter 13 from e-book, Topics on the Pathology of Protozoan and Invasive Arthropod Diseases.					
14. ABSTRACT					
15. SUBJECT TERMS					
16. SECURITY CLASSIFICATION OF:			17. LIMITATION OF ABSTRACT	18. NUMBER OF PAGES	19a. NAME OF RESPONSIBLE PERSON
a. REPORT unclassified	b. ABSTRACT unclassified	c. THIS PAGE unclassified	Same as Report (SAR)	19	

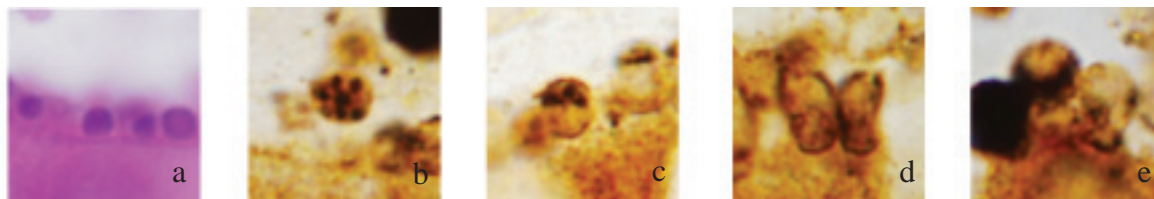


Figure 13.1

Spherical or cone-shaped cell stages of *Cryptosporidium* within human cells lining gastrointestinal tracts. x1000. a. Spherical: 4 trophozoites deep in microvilli, H&E; b. Spherical: type I meront with 7 of 8 merozoites, WS; c. Spherical: type II meront with 4 merozoites, WS; d. Cone-shaped: 2 side-by-side macrogamonts, WS; e. Cone-shaped: microgamont with microgametes on right, Spherical: 2 attached oocysts; single-walled oocyst with 4 sporozoites (center); Double-walled, densely stained oocyst on left, WS.

ranges between 30%-60% in industrialized countries and reaches 95% in tropical and developing countries.¹²

Infectious Agent

Morphologic Description

All four stages of *Cryptosporidium* (trophozoite/type I meront, type II meront, microgamont, and macrogamont/oocyst) form spherical or cone-shaped cells (Fig 13.1) within epithelial cells lining the host's gastrointestinal tract.

Except for unfertilized macrogamonts, each mature stage produces a smaller banana or bullet-shaped penetrating form that is asexual (sporozoite, type I merozoite, type II merozoite) or sexual (microgamete).

Trophozoites are 1 μm to 2.5 μm in diameter¹³ (Fig 13.2). Each contains a single nucleus (Fig 13.3),¹⁴ endoplasmic reticulum, and ribosomes, and is surrounded by 5 unit membranes,¹⁵ the outer 2 originating with the host. The parasitophorous vacuole membrane has an electron-dense microfilament network where the host cell membrane apposes the parasite (Fig 13.4). The membrane and the microfilaments form a series of compact folds, called, the feeder organelle, believed to be responsible for nutrient transfer. The parasitophorous vacuole lies in the microvillous border of the cell, just below the plasma membrane. This intracellular but extracytoplasmic location differs from that of related coccidia that reside in intracytoplasmic vacuoles.^{1,15}

Type I meronts are 1.5 μm to 2.5 μm in diameter¹³ and contain 8 type I merozoites (Figs 13.1b & 13.5). Type II meronts are 3.5 μm in diameter¹³ and contain 4 type II merozoites (Fig 13.6). The nuclei of first- or second-generation meronts become smaller during division and migrate toward the periphery. Microgamonts are 2 μm in diameter¹³ and contain 14 to 16 peripherally arranged microgametes¹ (Fig 13.7). Macrogamonts are spherical and are 4 μm x 5 μm in diameter¹³ (Figs 13.4 & 13.8). They contain a large, eccentrically placed nucleus with a prominent nucleolus.¹⁴ Mature oocysts of *Cryptosporidium* are spherical, refractile (Fig 13.9), 5 μm x 7 μm in diameter,¹³ and contain 4 sporozoites (Fig 13.1e). Each of the 4 sporozoites is 2.4

μm x 0.69 μm to 4.5 μm x 0.95 μm and has no sporocyst (Fig 13.10). Merozoites are 0.4 μm x 1 μm in diameter¹³ (Figs 13.1 b & 13.1c) and contain a Golgi apparatus, endoplasmic reticulum, and nucleus. Merozoites and sporozoites also contain the organelles comprising the apical complex: rhoptries, micronemes, subpellicular microtubules, polar ring, and conoid. These structures apparently serve as the entry apparatus and disappear in the trophozoite stage.¹⁶ Microgametes are bullet- or rod-shaped not more than 1 μm to 2 μm long (Fig 13.7). Unlike some other members of this phylum, *Cryptosporidium* microgametes have no flagellum.

Life Cycle and Transmission

The life cycle (Fig 13.11) of *C. parvum* is completed in 3 days in human cell culture¹⁷ and 8 days in cell free culture.¹⁸ Ingested oocysts excyst within a host's stomach, releasing 4 motile sporozoites. The sporozoites are carried along the intestinal tract where they infect epithelial cells, usually in the small intestine. Apposition and invagination of host and parasite membranes mediated by a host receptor result in the formation of a parasitophorous vacuole.^{19,20} The sporozoites differentiate into spherical bodies called trophozoites and divide by schizogony (asexual reproduction) to form schizonts (meronts). The outer membranes invaginate deeply around nuclei, forming daughter merozoites. If 2 divisions occur (second-generation schizogony), the result is 4 merozoites or type II meronts. If 3 divisions occur (first-generation schizogony), the result is 8 merozoites or type I meronts. Type I meronts reinfect epithelial cells.²⁰

Type II meronts undergo gametogony (sexual reproduction) to produce microgamonts (containing microgametes) and macrogamonts (which become macrogametes). Macrogametes contain polysaccharide and phospholipid amylopectin granule precursors of the oocyst wall. Fertilization occurs when luminal currents or motility of the microgametes carry them near macrogametes. Microgametes attach to and penetrate the cytoplasm of macrogametes, then enter the nucleus where nuclear fusion takes place.¹³

The resulting zygote undergoes schizogony to form an oocyst. Wall-forming bodies coalesce to form oocyst walls.

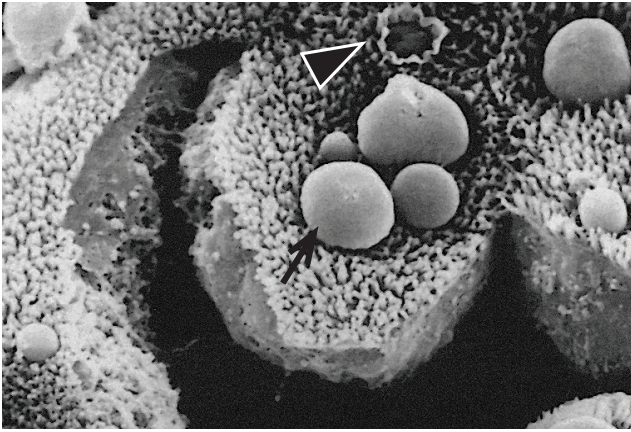


Figure 13.2
Scanning electron micrograph showing numerous cryptosporidia on surface of epithelial cells: trophozoites (arrow), crater-like area (arrowhead) is a ruptured parasitophorous envelope. x3500

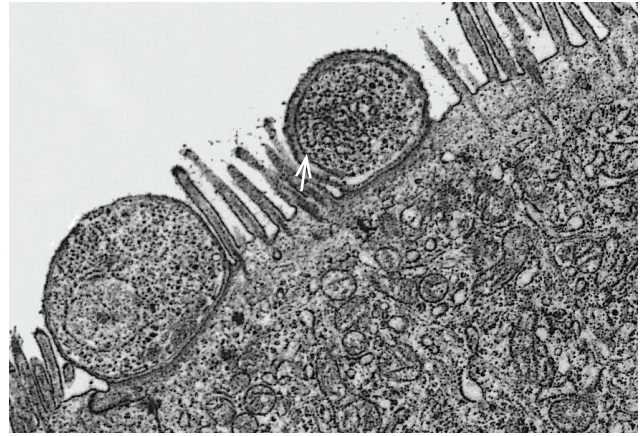


Figure 13.3
Transmission electron micrograph of *Cryptosporidium* sp of sheep showing trophozoite with a single nucleus, endoplasmic reticulum and ribosomes deep in microvilli of epithelial cell. Note parasitophorous vacuole (arrow). x5120

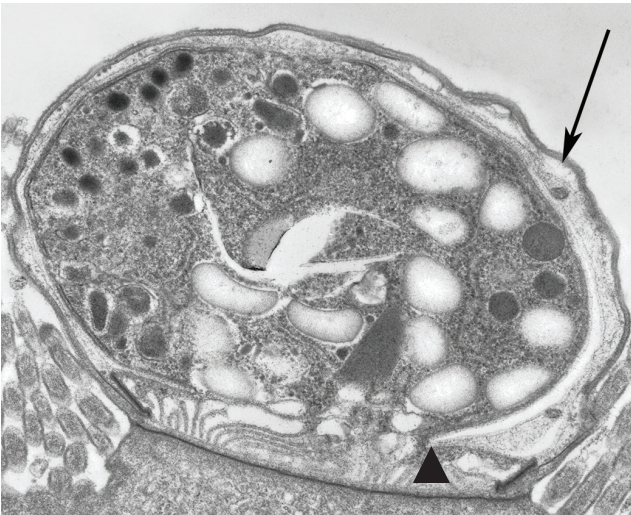

Figure 13.4
Transmission electron micrograph of a fertilized macrogamete 4.1 μm x 2.5 μm connected to the host cell and surrounded by the parasitophorous vacuole (arrow) and the feeder organelle (arrow head). x25250

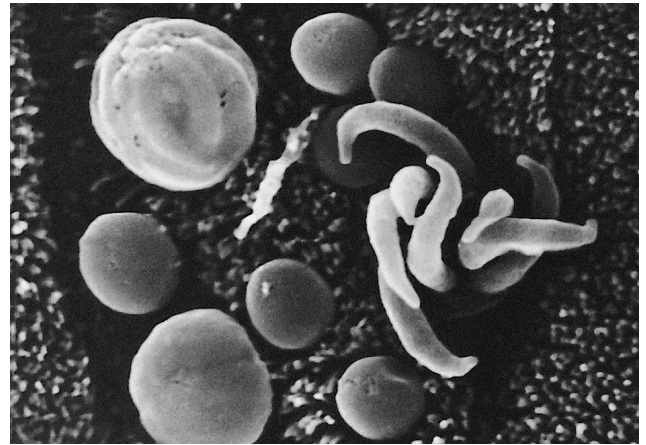


Figure 13.5
Scanning electron micrograph showing type I meront releasing 8 merozoites. x18000

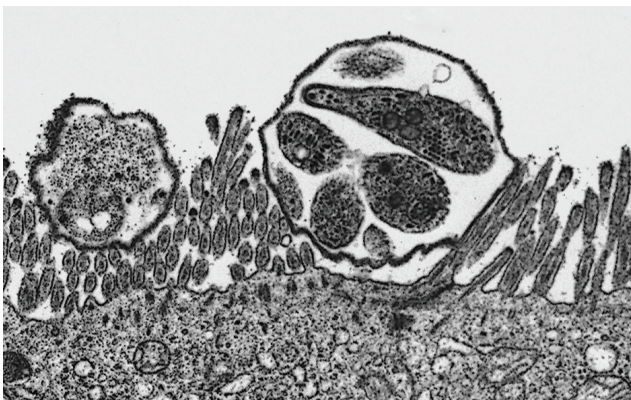


Figure 13.6
Transmission electron micrograph showing type II meront containing 4 merozoites. x5720

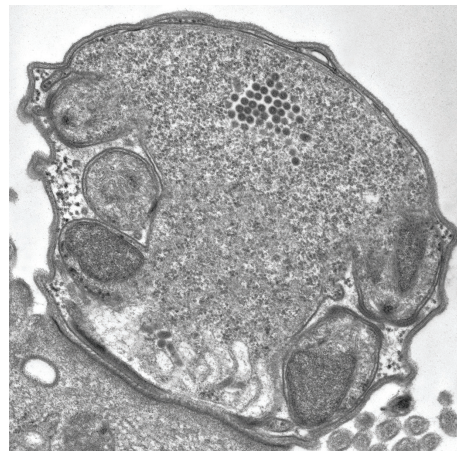


Figure 13.7
Transmission electron micrograph showing 5 microgametes in a microgamont. x 24000

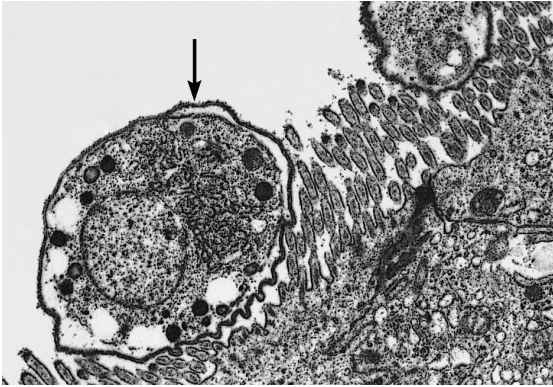


Figure 13.8
Transmission electron micrograph showing macrogamont with nucleus and dark bodies. x5720

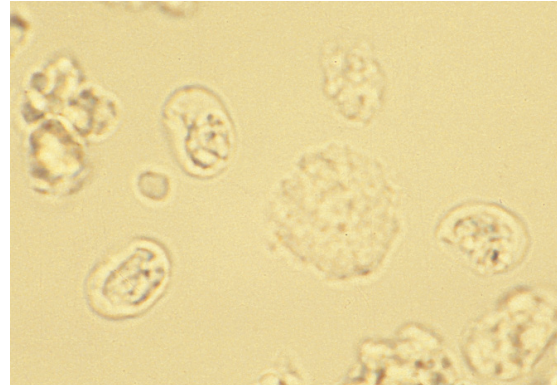


Figure 13.9
Cryptosporidium parvum of calves. Fecal float with refractile unstained oocysts suspended in water. x500

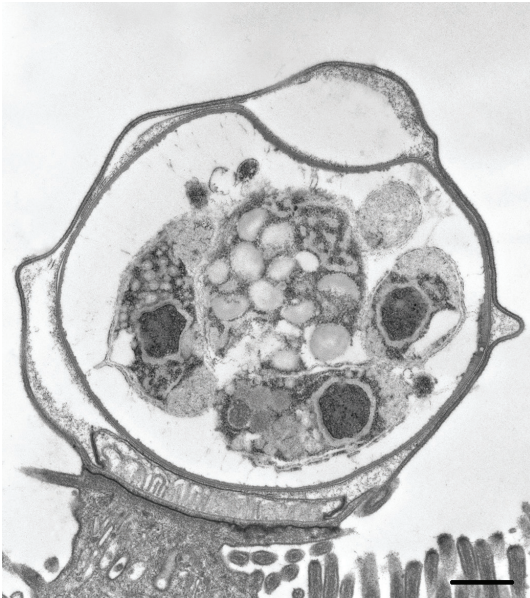


Figure 13.10
Transmission electron micrograph showing 3 of 4 naked sporozoites. The oocyst is still within the hosts cell-derived parasitophorous vacuole. Bar, 500 nm

Approximately 20% of oocysts have a thin, single-unit membrane wall and can release their sporozoites in the host before passage, resulting in autoinfection. The remaining 80% have thick-walled, bilayer membranes and are fully sporulated and infectious upon passage from the host.

Cryptosporidiosis spreads from person to person, from animals to people, and from the environment to people by contact with fomites or ingestion of contaminated food or water.²¹⁻²⁴ Factors that contribute to the spread of cryptosporidiosis include travel, overcrowding, malnutrition, early weaning, other infections, use of antibiotics, poor sanitation, and working at or attending health or day-care centers.²⁵ Waterborne infections have been associated with

contamination of reservoirs by pasture runoff and inadequate filtration of swimming pools and water slides. The infective dose is as few as 10 organisms.²⁶

Clinical Features and Pathogenesis

The incubation period for cryptosporidiosis in healthy volunteers is 4 to 22 days after ingestion of oocysts.²⁷ Most immunocompetent patients have self-limited diarrhea lasting 5 to 14 days. The diarrhea is cholera-like, profuse, watery, and foul smelling, with no leukocytes or blood. Other symptoms include nausea and vomiting, abdominal cramps, low-grade fever, anorexia, dehydration, weight loss, weakness, myalgia, and headache.^{27,28} There may be malabsorption of carbohydrates, fats, and vitamins. Rarely, severe disease results in malnutrition and death. Peripheral blood leukocytosis and eosinophilia are infrequent. Characteristic radiographic findings are nonspecific mucosal thickening and disordered small intestinal motility. Endoscopic findings include focal atrophy and small erosions.

Patients with profound immunosuppression, such as in AIDS, may have more severe and prolonged symptoms that may fluctuate with changes in CD4 count and antiretroviral therapy. The 4 patterns of clinical syndromes are chronic diarrhea, cholera-like disease, transient diarrhea, and relapsing illness.¹²

Immunocompromised individuals have a greater incidence of infection in extraintestinal sites, such as the stomach, and the biliary, pancreatic, and respiratory tracts.²⁹ Although most AIDS patients have no gastric symptoms, stomach involvement is frequent.³⁰ *Cryptosporidium* has been found in the gallbladder and biliary tree of both immunocompetent and immunocompromised individuals; symptomatic infections of the biliary tract have been seen only in AIDS patients. Up to 15% of AIDS patients with intestinal cryptosporidiosis have hepatobiliary tract infection

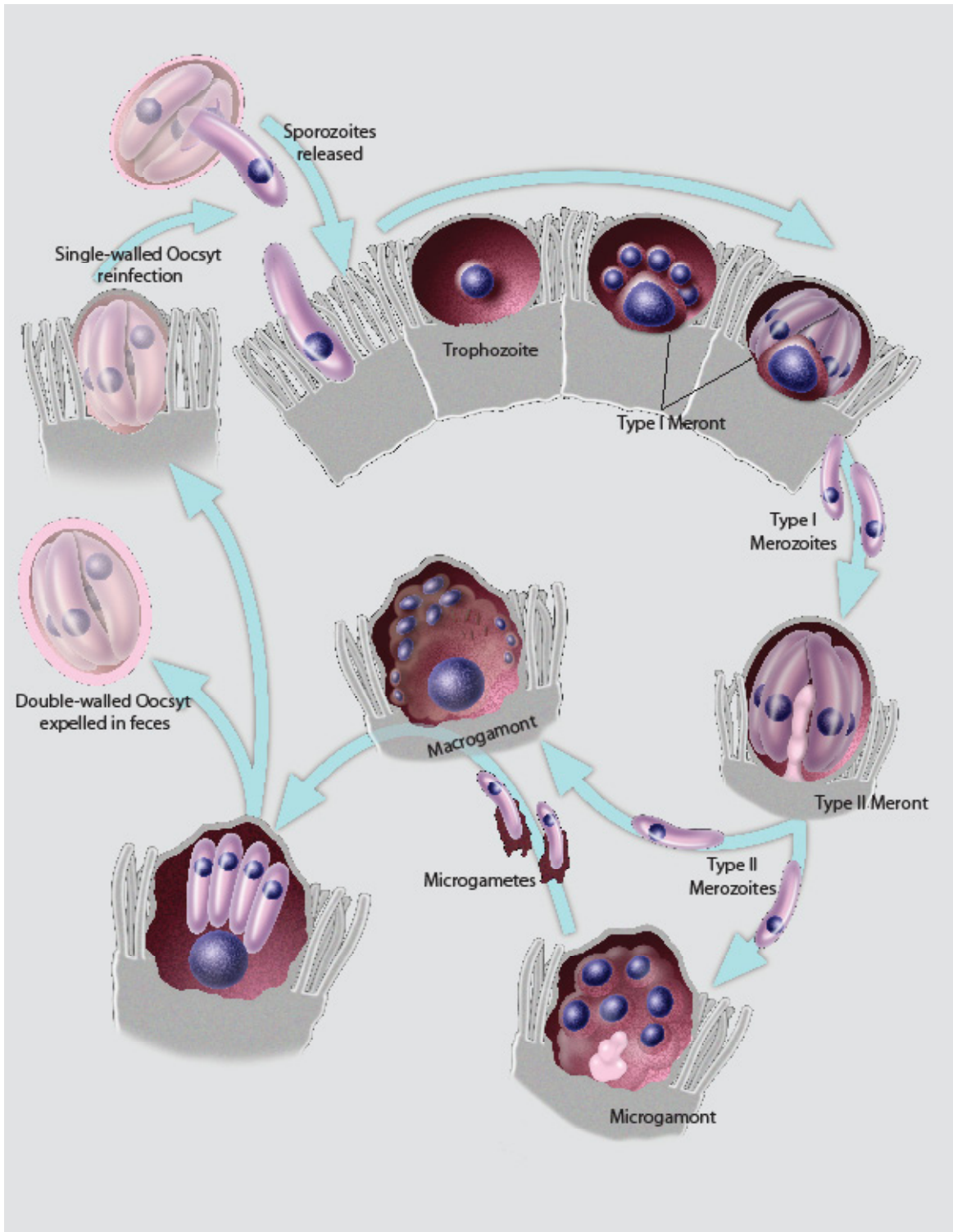


Figure 13.11
Life cycle of *Cryptosporidium parvum*. (See text for description).

resulting in fever, right upper quadrant nonradiating pain, nausea, vomiting, and diarrhea. Acalculous cholecystitis and sclerosing cholangitis with obstruction or stenosis of the ampulla of Vater have been reported. These conditions may be found by ultrasound or endoscopic retrograde cholangiography.²⁰ Respiratory cryptosporidiosis occurs rarely in immunocompetent individuals.³¹ Upper respiratory, tracheobronchial, and nasal cryptosporidiosis are common in AIDS patients with severe small intestinal disease. Lower respiratory infection causes interstitial pneumonia.³²

The pathologic mechanisms of cryptosporidial diarrhea and malabsorption are not well understood. Nutrient transfer through the parasite's feeder organelle may deplete the host cell. A heavy parasite burden may reduce the microvillous absorptive surface area and affect membrane-bound enzymes.¹ Malabsorption and impaired digestion may lead to overgrowth of intestinal flora and influx of fluid, causing diarrhea.

The normal immune response to cryptosporidiosis is both humoral and cell-mediated. When both components are functioning normally, infection is self-limited.^{20,33} Cell-mediated immunity in the intestine is important for protection against infection in human volunteers, especially CD4+ T cells and interferon- γ .³⁴

Apoptosis may be relevant to the pathogenesis of sclerosing cholangitis. Sporozoites attach to and invade the apical membrane of cholangiocytes, resulting in programmed cell death of bystander uninfected biliary epithelial cells but protect infected cells.³⁵ In vivo the host cell is killed upon parasite egress; this cell death is necrotic, not apoptotic.³⁶ The biliary tract may serve as a reservoir of infection. In cultured cells bile acids and bile salts enhance the invasiveness of *Cryptosporidium* sp.³⁷

Pathologic Features

Distribution of cryptosporidiosis in the duodenum, small intestine, and colon is highly variable.¹² In immunocompetent hosts, infection is primarily confined to the jejunum and ileum. The rectum is often involved, while the esophagus and stomach are only occasionally infected. On H&E-stained tissue sections, *Cryptosporidium* parasites appear to bulge from the surface of the epithelial cell (Fig 13.1). Because of their small size and indistinct structure, they may be confused with cellular debris or mucus. Infection is confined to the apical surfaces of enterocytes, from the base of the crypts to the tips of the villi. The numbers of parasites and the degree of inflammation vary, even within a small biopsy. There is no correlation among parasite burden, histopathologic changes, and clinical severity.¹²

In immunocompetent hosts, pathologic changes are relatively mild and nonspecific. Changes in the small intestine include villous architectural abnormalities, crypt elongation, increased inflammatory cells, and occasional crypt

abscesses³⁸ (Fig 13.2). Neutrophils and rare eosinophils infiltrate between epithelial cells and in the lamina propria. Intraepithelial lymphocytes are rare. Enterocyte abnormalities include increased mitotic figures, cellular atypia, necrosis, vesiculation, inconspicuous brush borders, and sloughing. Infected colonic crypts are often dilated, with decreased goblet cells and increased mitotic figures. Immunocompromised hosts may have more severe villous atrophy, heavy colonization throughout the alimentary tract, and dense inflammatory infiltrates (Fig 13.12).

In gastric cryptosporidiosis, organisms are present in the lining epithelium and may extend into the glands. There may be active gastritis, with lymphocytes and plasma cells in the lamina propria.

Organisms probably spread through the pancreatic and biliary ducts to infect epithelial cells of the gallbladder, biliary tract, and pancreatic ducts. Pathologic changes range from acute cholecystitis to necrosis. The gallbladder, bile ducts, and periductal glands become edematous and dilated, and are infiltrated by neutrophils, eosinophils, and chronic inflammatory cells. Organisms may be found in the bile duct epithelium of the liver. Damaged epithelial cells may become flattened, and there may be surface erosions. Organisms in the pancreatic duct epithelium are associated with pancreatitis and periductal inflammation. Unlike the intestinal epithelium, the pancreatic ducts undergo squamous metaplasia.

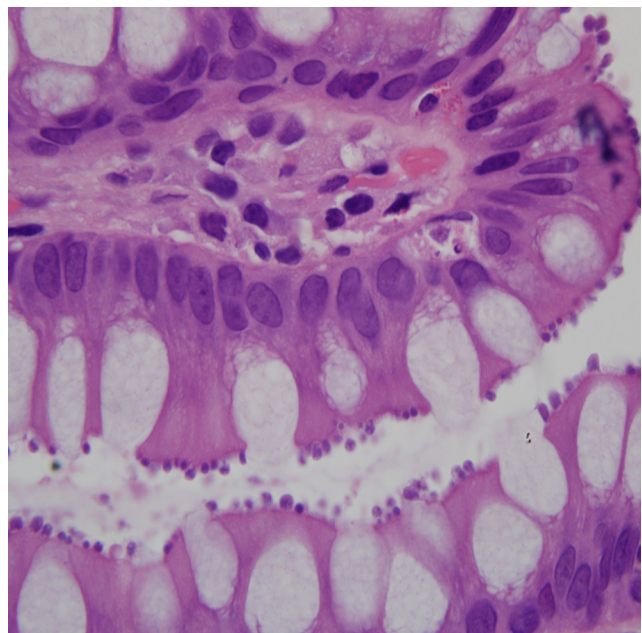


Figure 13.12 Large intestine from an immunosuppressed (HIV positive) patient showing flattened epithelial cells supporting heavy protozoan colonization, and an inflammatory infiltrate in the lamina propria with rare eosinophils. H&E. Original magnification x400

In immunocompromised individuals, organisms have been found in tracheal epithelium, macrophages, bronchioles, and alveolar exudates. Infection of columnar epithelial cells may result in squamous metaplasia.

Diagnosis

Cryptosporidiosis can be diagnosed by stool examination, biopsy, cytology, and serology. The ability to sample oocysts from the entire digestive tract without invasive procedures makes stool examination the preferred method. The number of oocysts passed in feces varies, necessitating multiple sample collections and use of concentration techniques. Stool specimens should be fixed in formalin or sodium acetate-acetic acid-formalin. Oocysts can be concentrated by flotation (Fig 13.9), centrifugation, or sedimentation. Oocysts in stool are stained by a variety of techniques, including modified cold Kinyoun acid-fast (Fig 13.13), Ziehl-Neelsen acid-fast, Safranin-methylene blue, Giemsa, fluorescent acridine orange, and auramine-rhodamine stains. Oocysts are autofluorescent.³⁹ On phase-contrast microscopy, oocysts are bright, refractile (Fig 13.14), have up to 6 black granules, and often adhere to mucus. They are pink on bright field microscopy (Fig 13.9). Other techniques include ELISA, indirect fluorescent antibody (IFA) tests (Fig 13.15), direct immunofluorescence tests for screening, and fluorescence in situ hybridization (FISH) for verification.⁴⁰ The sensitivity of PCR in fecal samples is reduced because of substances that inhibit DNA sequencing.⁴¹ DNA extraction methods for stool samples appears to increase sensitivity.⁴²

Some patients require endoscopic intestinal biopsies for diagnosis. *Cryptosporidium* stains basophilic to amphiphilic by H&E, dark blue by Giemsa, and red to purple by Gram stain (Figs 13.16 & 13.17). Acid-fast stains are less effective on tissue sections than on stool or cytology specimens. Electron microscopy has been used to diagnose cryptosporidiosis, but it is impractical and unnecessary in most cases. Cytological diagnosis of cryptosporidiosis has been made by identifying acid-fast organisms in small-intestinal brushing specimens, sputum, bronchoalveolar lavage, bronchial brushings, and tracheal aspirates. Other techniques include indirect immunofluorescence, immunoperoxidase techniques, and molecular diagnostic procedures.²⁰

Differential staining, using light microscopy, will identify various stages in the growth cycle of cryptosporidiosis (Figs 13.16 & 13.17). The Grocott's methenamine silver (GMS) stain does not silver any early stage (asexual cycle), i.e. trophozoite or meronts (Figs 13.16m, 13.16r, & 13.16w). In the sexual stages only the microgamonts (Figs 13.17e, 13.17 i, & 13.17 j), not the macrogamonts (Fig 13.17c) stain. Within microgamonts, microgametocytes and the microgamonts' attachment site are silvered. In maturing and mature oocytes, only the sporozoites are silvered (Fig

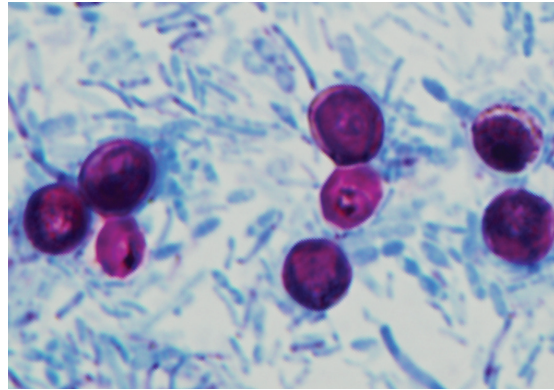


Figure 13.13
Cryptosporidium parvium in centrifuged human feces stained with modified cold Kinyoun acid-fast. x1000

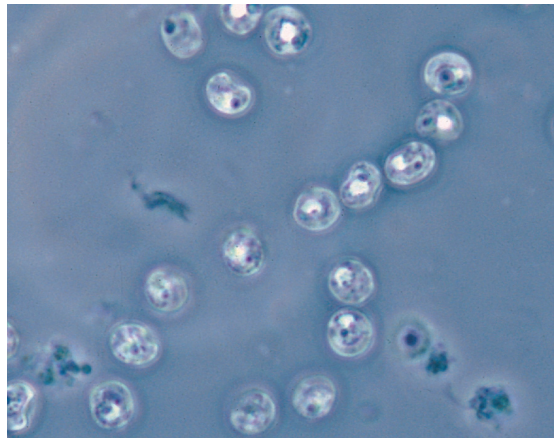


Figure 13.14
Fecal float with unstained oocysts suspended in sugar solution and viewed with phase-contrast microscopy. x1500

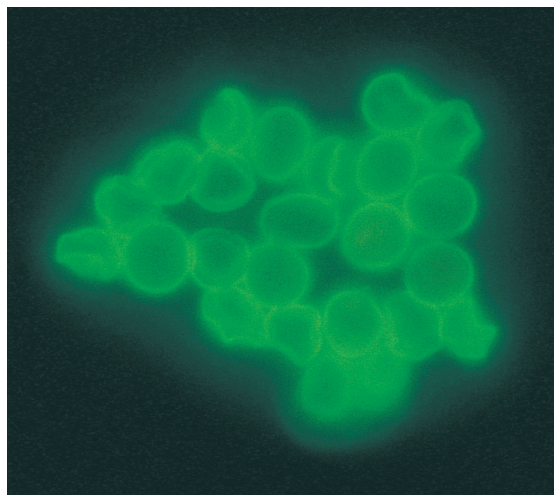


Figure 13.15
Fecal float with oocysts stained with monoclonal antibody conjugated with fluorescent isothiocyanate. X750

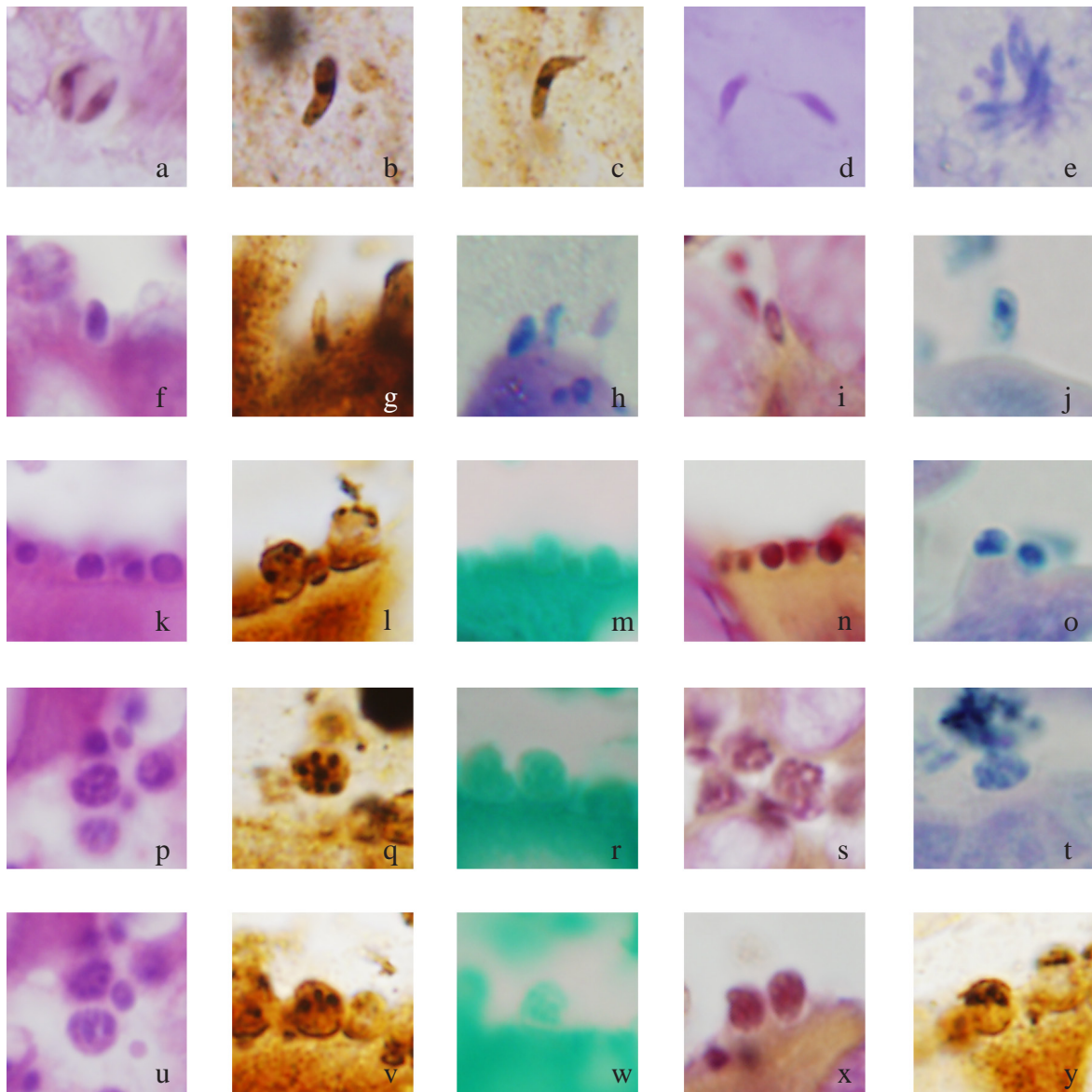


Figure 13.16
 Differential staining of asexual stages in growth cycle of *Cyptosporidium* sp. x1000
 Excysted sporozoites in feces: a. H&E; b. WS; c. WS; d. B&H; e. Type I merozoites (for comparison) ZN.
 Early sporozoite attachment: f. H&E; g. WS; h. ZN; i. B&H; j. Giemsa.
 Trophozoite: k. H&E; l. WS (in middle); m. GMS; n. B&H; o. Giemsa.
 Type I meronts contain 8 type I merozoites: p. H&E; q. WS; r. GMS; s. B&H; t. Giemsa.
 Type II meronts contain 4 type II merozoites: u. H&E; v. WS; w. GMS; x. B&H; y. WS.

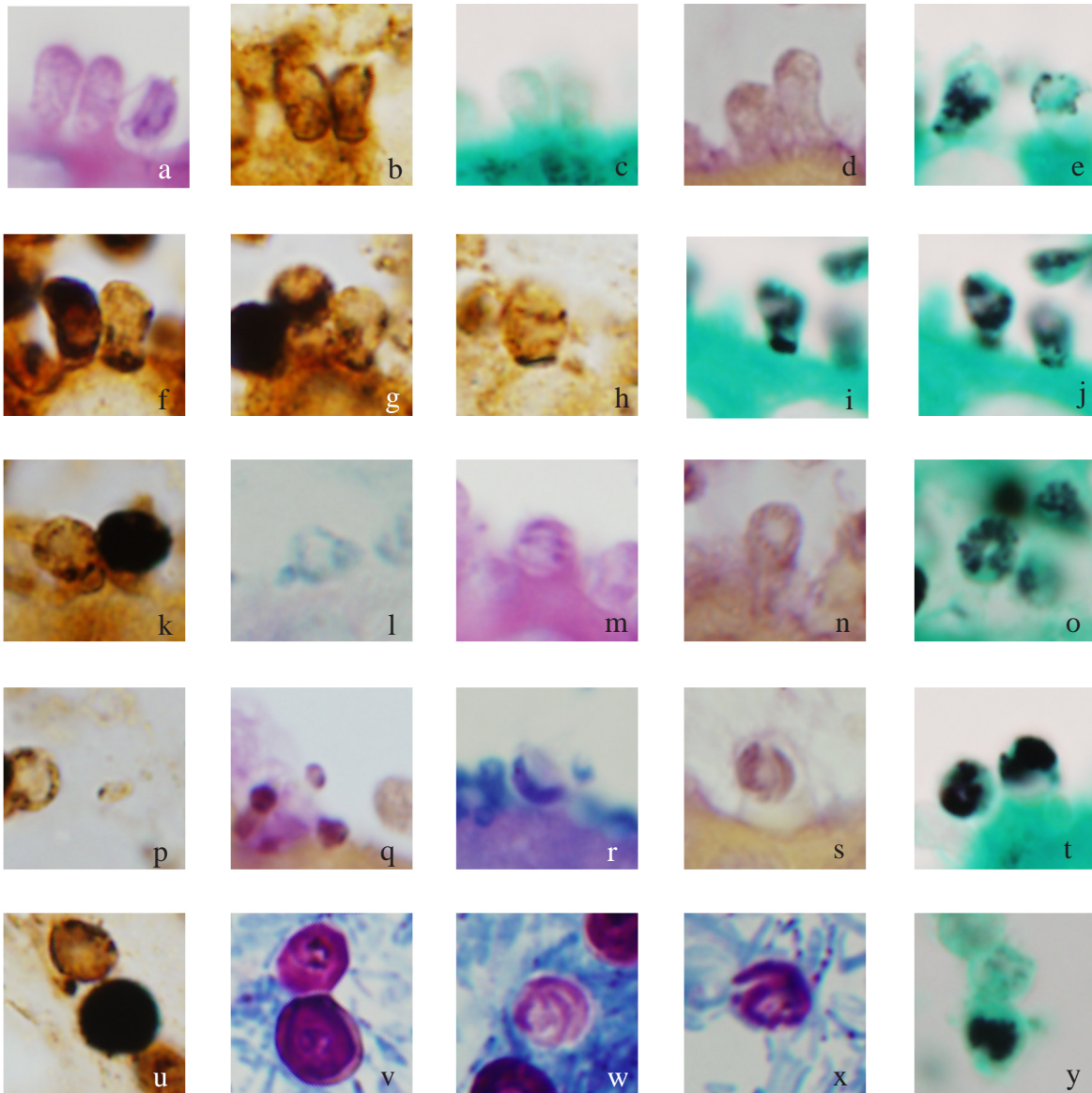


Figure 13.17

Differential staining of sexual stages in growth cycle of *Cryptosporidium* sp. x1000

Macrogamonts: a. H&E; b. WS; c. GMS; d. B&H; e. Macrogamete right, microgamete left GMS.

Microgametes: f. Arrow WS; g. Microgamont with microgametes on right WS; h. WS; i. GMS (focus level 1); j. GMS (focus level 2).

Maturing attached oocysts: k. Single walled (left), double walled (right) WS; l. ZN; m. H&E; n. B&H; o. GMS.

Miscellaneous: p. Microgamont with released microgamete (center) WS; q. released microgamete B&H; r. Mature oocyte with sporozoites (center) ZN; s. Mature oocyte with sporozoites B&H; t. Mature oocytes GMS.

Oocysts in feces: u. Single walled (top), double walled (center) WS; v. Kinyoun acid-fast; w. Kinyoun acid-fast; x. Kinyoun acid-fast; y. GMS.

Oocysts in feces: u. Single walled (top), double walled (center) WS; v. Kinyoun acid-fast; w. Kinyoun acid-fast; x. Kinyoun acid-fast; y. GMS.

13.17t). The Warthin-Starry silver impregnation stain (WS) silvers the trophozoite's and microgamont's thickened attachment site (Fig 13.16l), but only slightly to moderately stains the attachment sites of meronts (Figs 13.16l, 13.16q, 13.16v, & 13.16y). Merozoites, however, stain well within meronts (Fig 13.17g). In a variety of stains the 8 merozoites in type I meronts tend to appear as a circle around the wall (Figs 13.16 p, 13.16q, 13.16s, & 13.16t) whereas the 4 merozoites of type II meronts tend to present in a row, side-by-side (Figs 13.16u, 13.16v, & 13.16y). The Brown-Hopps (B&H) tissue gram stain demonstrates early trophozoites best (Fig 13.16n). As trophozoites mature, the darker red fades from the attachment site (Fig 13.16x). Merozoites may also stain deep red. In later stages only the microgametocytes stain well.

Treatment and Prevention

In persons with normal immunity, cryptosporidiosis is usually self-limited and requires only fluid replacement. Nitazoxanide is the only drug approved by US FDA in immunocompetent persons.³³ Immunosuppressed patients require treatment with an anti-HIV regime.³³ Paromomycin has shown success in AIDS patients and may be more effective when combined with azithromycin.^{43,44} Efforts are ongoing to develop an effective vaccine for cryptosporidiosis.⁴⁵

The Centers for Disease Control and Prevention have established the Waterborne Cryptosporidiosis Working Group to develop guidelines for prevention and early identification of outbreaks of waterborne cryptosporidiosis, now a notifiable disease in the United States. Methods for detecting oocysts in water are improving with new molecular techniques.⁴⁶ Oocysts have been found in 17% to 87% of surface drinking-water supplies in the United States. Ozone, chlorine, formaldehyde, and conventional filtration do not eradicate oocysts, making prevention difficult.

ISOSPORIASIS

Definition and Synonym

Isosporiasis is acute or chronic enteritis caused by infection with *Isospora belli*. Isosporiasis is also known as isosporidiosis.

General Considerations

Isospora causes intestinal disease in several mammalian species.⁴⁷ Virchow observed *I. belli*, the species that infects humans, in 1860. During World War I *Isospora belli* was detected in the stools of European soldiers stationed in the Middle East; during World War II it was a pathogen among troops in the Pacific. Isosporiasis in the Americas was first reported in the 1960s. *Isospora belli* causes traveler's diarrhea in immunocompetent hosts and is an opportunistic pathogen in patients with AIDS.

Epidemiology

Isospora belli is cosmopolitan, but more common in the tropics and subtropics. It is endemic to South Africa⁴⁸, South America⁴⁹, and the Southwest Pacific islands. In South America, reported infection rates range from 0.1% to 1.8%. Immunodeficiency,⁵⁰ malnutrition,⁵¹ and poor hygiene are risk factors. A cross-sectional study conducted in Ethiopia found 12 percent of 214 HIV positive patients infected, while none of 164 HIV negative patients was infected.⁵² Isosporiasis is more prevalent in children, but the exact prevalence of the disease is not known.

Infectious Agent

Morphologic Description

Isospora oocysts are ellipsoid and approximately 20 μm to 33 μm by 10 μm to 19 μm (Figs 13.18a to 13.18c). The smooth, thin cyst wall is composed of 2 layers. The outer layer is tough, impermeable to fluids, and environmentally resistant; the inner layer is membranous.⁴⁷ Sporocysts are 12 μm by 7 μm to 9 μm (Fig 13.19). Sporozoites are slender and crescent-shaped (Figs 13.20a & 13.20b). The internal structures of sporozoites and merozoites are similar to those of other coccidians and include polar rings, rhoptries, micronemes, conoids, microtubules, and amylopectin granules. Trophozoites are spherical (Fig 13.21). Macrogamonts contain a single large, centrally located nucleus and wall-forming bodies (Fig 13.22). Microgamonts contain multiple nuclei that migrate to the periphery, elongate and protrude from the surface, and bud into mature flagellated microgametes 5 μm to 6 μm long (Figs 13.23a to 13.23c).

Life Cycle and Transmission

The life cycle of *Isospora* is similar to that of *Cryptosporidium*, except that oocysts are not sporulated when passed

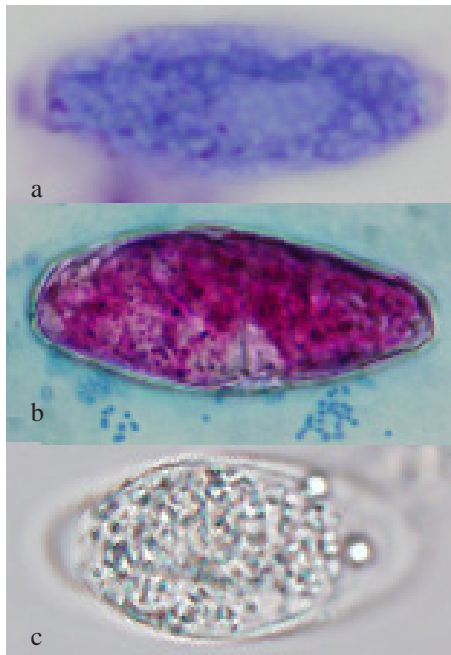


Figure 13.18 a-c
Unsporulated oocyst (25 μ m x 8 μ m) of *Isospora belli*: a. In duodenal aspirate (Giemsa); b. Unsporulated oocyst of *I. belli* in feces (Kinyoun); c. Unsporulated oocyst of *I. belli* in feces. Unstained. Original magnification x400

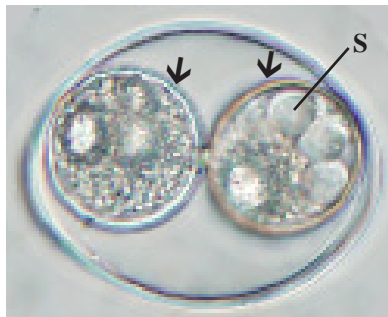


Figure 13.19
Sporulated oocyst of *Isospora felis* in feces. Oocyst contains two sporocysts (arrows). Each sporocyst contains four sporozoites (S). Unstained. Original magnification x1000

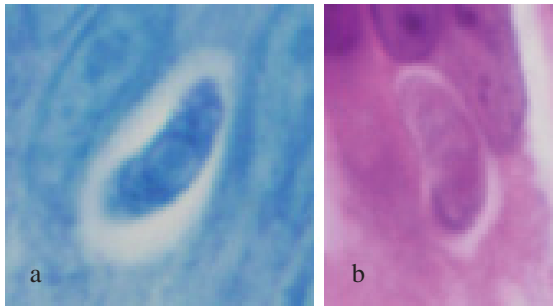


Figure 13.20 a-b
Released *Isospora belli* sporozoites (8 μ m x 3 μ m) have penetrated enterocyte in duodenum: a. Ziehl-Neelsen; b. H&E x300

in feces (Figs 13.18a to 13.18c). Under appropriate conditions, the 1 or 2 sporoblasts of *Isospora* secrete a wall and become sporocysts (Fig 13.19). Divisions result in 4 sporozoites per sporocyst. Ingested oocysts excyst in the small intestine.

Released sporozoites move about until they penetrate enterocytes in the distal duodenum, proximal jejunum, or

other sites (Figs 13.20a & 13.20b). Trophozoites develop in the host-cell cytoplasm (Fig 13.21). By the process of schizogony, (Figs 13.24a to 13.24c) daughter merozoites form within a schizont. When the schizont and its host cell rupture, merozoites move into the gut lumen and penetrate uninfected enterocytes. The organisms either begin another round of merozoite formation or shift to gametogony, the sexual phase. Mature macrogametes develop from macrogamonts and can be differentiated by the multimembranous vacuoles which budded off the nucleus⁵³ (Figs 13.25a, & 13.25b). Mature microgametes bud from a microgamont. Fertilization takes place when microgametes attach to and penetrate macrogametes. Nuclear fusion ensues and wall-forming bodies coalesce to form oocysts.

Infection is acquired by ingesting infective oocysts through contaminated food or water,⁵⁴ or from poor personal hygiene.

Clinical Features and Pathogenesis

Immunocompetent hosts are susceptible to infection, though they may remain asymptomatic, with parasites evident in feces or biopsy specimens for several months or years. Symptoms include diarrhea, steatorrhea, headache, fever, malaise, colicky abdominal pain, vomiting, dehydration, and weight loss. Stools are watery, steatorrheic, and foul smelling, with no blood or pus. Malabsorption can occur in chronic infections. Some patients have peripheral eosinophilia.^{47,49,55,56}

Immunocompromised hosts experience more severe infection. Significant damage to the jejunal and ileal mucosa, along with severe alteration of the enterohepatic circulation of bile acids and vitamin B12 absorption may occur. AIDS patients may have a more watery diarrhea. Extraintestinal isosporiasis has been observed in AIDS patients, but not in immunocompetent patients.⁴⁷

On double-contrast radiography, patients with diarrhea lasting a year or less show minimally thickened mucosal folds in the duodenum and proximal jejunum. In patients with long-standing disease (17 to 30 years duration), the duodenum and proximal jejunum have a granular mucosal appearance with effacement of the folds. Radiographic changes seem to reflect the degree of villous atrophy.⁵⁷

The pathologic mechanisms of isosporiasis are not known. Unlike *C. parvum*, *I. belli* does not reside in the microvillous border of the host cell. Destruction of the absorptive surface and digestive enzymes by the parasite is probably not involved in acute infections, nor is an enterotoxin suspected.

Pathologic Features

Biopsies of the small intestine from individuals with isosporiasis may be normal or show changes of mild to

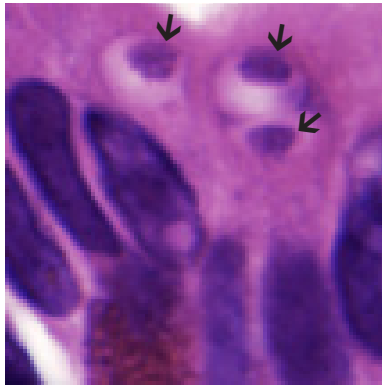


Figure 13.21
Spherical *Isospora belli* trophozoites (arrows) (largest 3 μm x 2 μm) in duodenal enterocyte. Note eosinophilic granules of Paneth cell. H&E x2300

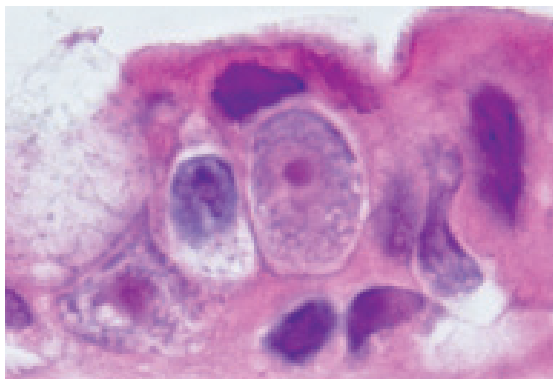


Figure 13.22
Macrogamont (12 μm x 8 μm) with single large, centrally located nucleus in duodenum. H&E x1750

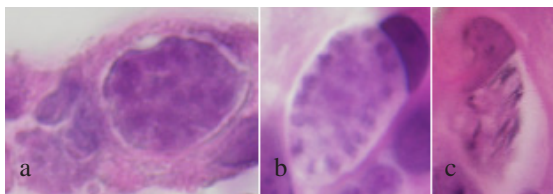


Figure 13.23 a-c.
Development of microgametes from microgamont in duodenum: a. Microgamont (12 μm x 8 μm) with multiple nuclei; b. Nuclei have migrated to periphery (12 μm x 7 μm); c. Mature flagellated microgametes 5 μm to 6 μm long, (total size 10 μm x 5 μm). Helmes x1500

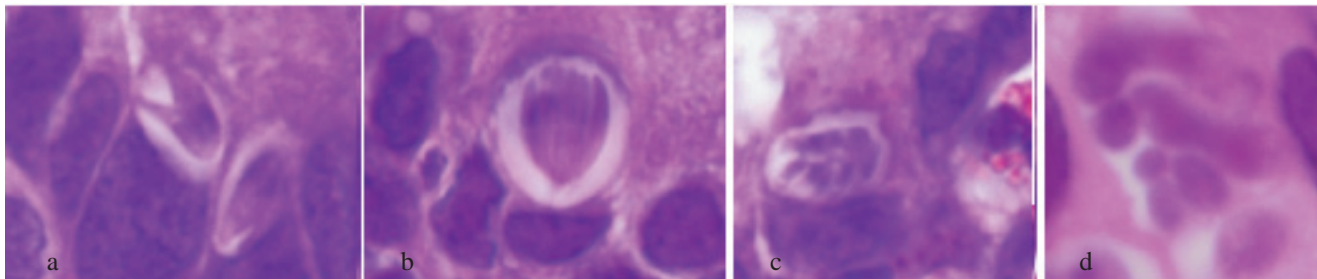


Figure 13.24 a-d
Merozoites (7 μm x 1 μm) of *Isospora belli* in duodenum forming within a schizont: a. First division, two merozoites; b. Second division, four merozoites; c. Third division, eight merozoites (total size 6 μm x 5 μm); d. Maturing eight merozoites (total size 10 μm x 6 μm). H&E x2000

moderate villous atrophy and crypt hyperplasia with increased inflammatory cells (Fig 13.26). The organisms tend to sit beneath the nucleus, which take on a transverse position in the superficial cytoplasm leading to the so-called ‘T sign’ (Fig 13.27).⁵⁸ Heavily parasitized specimens may have villous blunting or atrophy, crypt hypertrophy, and inflammation of the lamina propria, as seen in cryptosporidiosis. Several stages demonstrate PAS stained granules (Figs 13.28a to 13.28d). Brown-Hopps tissue gram stain also demonstrates the stages (Figs 13.29a to 13.29d). Organisms have rarely been found in mesenteric⁵⁹ and tracheobronchial lymph nodes,⁶⁰ the bile duct,⁶¹ or in the liver and spleen.⁶²

Diagnosis

Identifying *I. belli* oocysts in stool is the accepted method of diagnosis. Concentration of stool by Sheather’s sugar flotation is recommended. *Isospora* oocysts stain well by the Kinyoun acid-fast technique (Fig 13.18b), and auramine-rhodamine⁶³ staining produces good results. Oocysts stained with carbol-fuchsin fluoresce bright red under green light (546 nm). The oocysts’ autofluorescence does not survive staining.³⁹

If isosporiasis is suspected but stool examination is repeatedly negative, intestinal biopsy should be performed. Both sexual and asexual stages are readily distinguished in H&E-stained sections (Figs 13.21 to 13.27). Diagnosis by electron microscopy is also possible. DNA analysis of formalin-fixed paraffin-embedded tissue has been successful⁶¹ as well as DNA analysis of stool samples.⁶⁴

Treatment and Prevention

Trimethoprim-sulfamethoxazole can effect clinical and parasitological cure in approximately 7 days. Low-dose trimethoprim-sulfamethoxazole or weekly pyrimethamine-sulfadoxine is recommended to prevent or treat recurrent infections in AIDS patients.^{47,48} Metronidazole and quina-

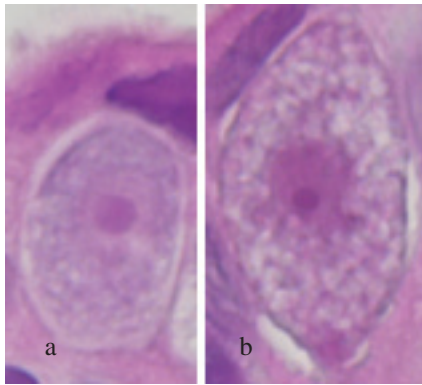


Figure 13.25 a-b
Macrogamont differentiate into macrogamete by multimembranous vacuoles which budded off the nucleus: a. Macrogamont (12 μm x 8 μm) H&E x2400; b. Macrogamete (12 μm x 10 μm) H&E x2500

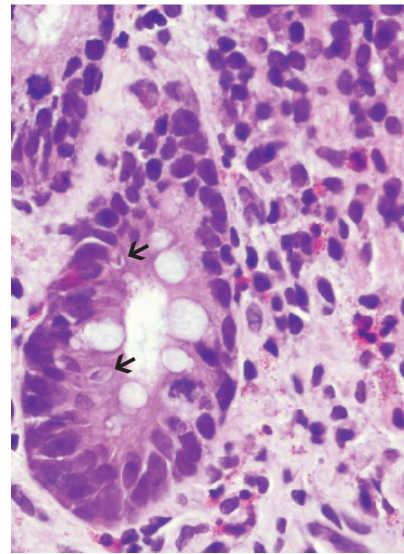


Figure 13.26
Heavily parasitized biopsy of duodenum with lymphocytes, plasma cells and eosinophils in lamina propria. Note merozoites (arrows) in enterocytes of gland. H&E x500

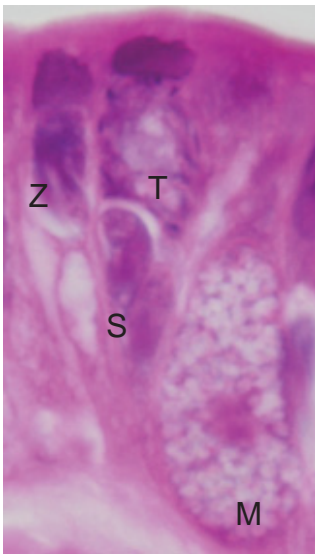


Figure 13.27
Heavily parasitized biopsy with sporozoite (S), two merozoites (Z), macrogamete (M) (15 μm x 8 μm), and microgamont (T) with host cell nucleus forming "T" sign and developing microgametes within. H&E x2000

crine are also effective. In cases of prolonged, severe diarrhea, hydration therapy may be indicated.

Isosporiasis can be prevented with adequate sanitation, measures to protect food and water supplies, and increased public awareness of the means of transmission.

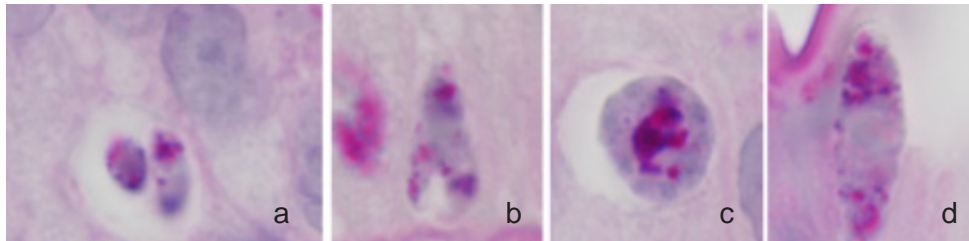


Figure 13.28
Developing stages of *Isospora belli* demonstrate PAS stained granules x2000: a. Trophozoite (smaller 2 μm x 2 μm); b. Merozoite (larger 8 μm x 2 μm); c. Microgamont (8 μm x 8 μm); d. Macrogamete (13 μm x 4 μm).

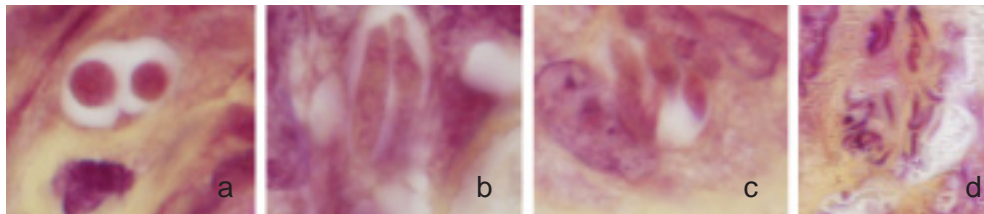


Figure 13.29
Developing stages of *Isospora belli* stained by the Brown-Hopps tissue gram stain x2000: a. Trophozoite (largest 4 μm x 4 μm); b. Merozoite (two cell stage larger cell 10 μm x 2 μm); c. Merozoite (four cell stage, individual 7 μm x 2 μm , total 10 μm x 6 μm); d. Microgametes (individuals 3 μm x 0.5 μm).

CYCLOSPORIASIS

Definition and Epidemiology

Cyclosporiasis is infection with the protozoan *Cyclospora cayatanensis*. It was first reported in humans in New Guinea in 1977. Several outbreaks occurred in the United States in 1996 and 1997.⁶⁵ In 2005, 11.9% of the indigenous people in Bolivar State, Venezuela, were infected.⁶⁶

Infectious Agent

Morphologic Description

Cyclospora oocysts are 8 μm to 10 μm in diameter (Fig 13.30). Hematoxylin-alone stained sections of duodenal biopsies show the intracellular stages.⁶⁷ A later report recommends hematoxylin & eosin.⁵⁸ All four asexual stages (sporozoite, trophozoite, schizont, and merozoite) have

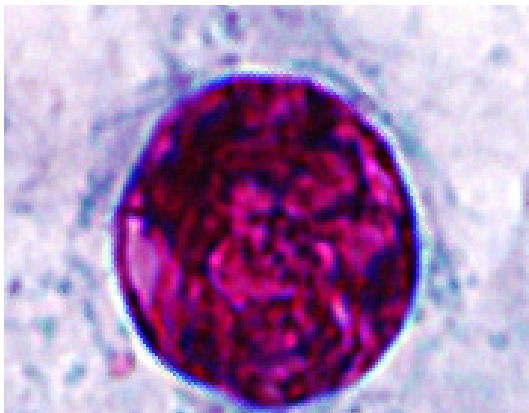


Figure 13.30
Spherical *Cyclospora* oocyst (8 μm to 10 μm in diameter). Ziehl-Neelsen acid fast stain x4000

been observed in the enterocyte.⁶⁸ Immature schizonts (uninuclear trophozoites) are 2 μm to 3 μm in diameter (Fig 13.31). Budding (ectomerogony) produces the asexual types I and II meronts that contain 8 to 12 merozoites (Fig 13.32) and 4 merozoites (Fig 13.33), respectively.⁶⁹ Merozoites are banana-shaped and 5 μm to 6 μm long, with a nucleus in the posterior third. Although macrogametocytes and microgametocytes are more easily identified by transmission electron microscopy,⁶⁷ a microgamont with developing microgametes is identified. (Fig 13.34). The organisms lack a PAS-positive sheath.⁶⁷

Life Cycle and Transmission

Ingestion of sporulated oocysts causes infection in humans. Sexual and asexual forms develop within an apical intracytoplasmic parasitophorous vacuole in enterocytes of the small intestine (Fig 13.30).⁷⁰ Unsporulated oocysts are excreted in feces (Fig 13.30).

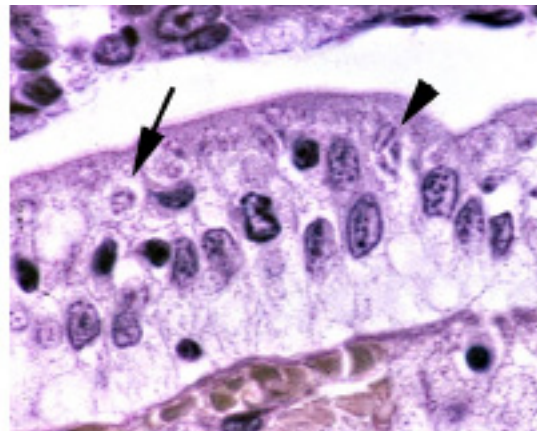


Figure 13.31
Cyclospora uninuclear trophozoites (2 μm to 3 μm in diameter—long arrow) develop into budding merozoites (arrow head) ending in banana-shaped merozoites (short arrow). Hematoxylin alone, original magnification x420

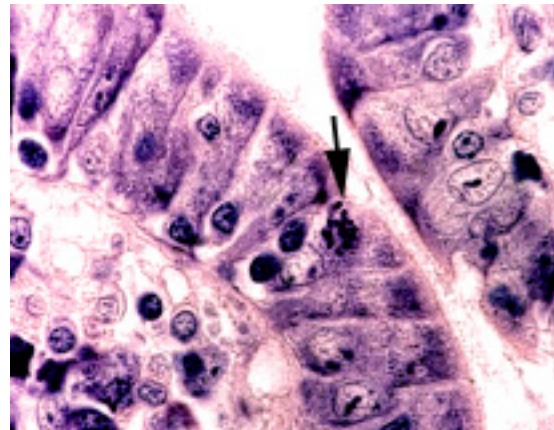


Figure 13.32
Asexual type I *Cyclospora* meronts (arrow) in apinuclear location of enterocyte. Hematoxylin alone, original magnification x420

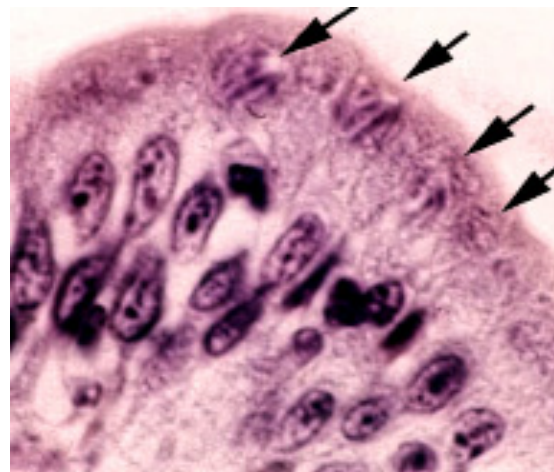


Figure 13.33
Asexual type II *Cyclospora* meronts (arrows) in apinuclear location of enterocyte. Hematoxylin alone, original magnification x420

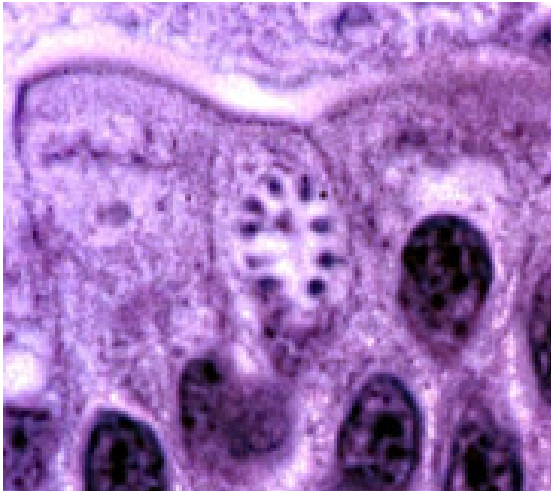


Figure 13.34
Microgamont of *Cyclospora* with developing microgametes.
Hematoxylin alone, original magnification x420.

Cyclospora may be transmitted by contaminated food or water.^{54,71} Washing does not easily remove oocysts from fruits and vegetables. The infectious dose is unknown, but is presumed to be low.⁷⁰ Animal reservoirs have not been found.

Clinical Features

The incubation period of *Cyclospora cayentensis* is 2–22 days.⁵⁸ Symptoms include watery diarrhea, nausea, anorexia, abdominal cramping, fatigue, and weight loss.⁷⁰ In HIV-positive patients *C. cayentensis* produces prolonged diarrhea, wasting and weight loss,⁵⁸ but was found in only one of 113 HIV-positive patients, 34 of whom had chronic diarrhea.⁵⁶

Pathologic Features

In infected enterocytes, which are not enlarged, the or-

ganisms cluster at the tops of villi.⁶⁷ The parasitophorous vacuole is 8 μ m to 10 μ m in maximum diameter. Jejunal mucosal biopsies show altered architecture with surface epithelial disarray, shortening and widening of villi due to edema, and mild to moderate infiltration of the lamina propria by mixed inflammatory cells, as seen in cryptosporidiosis (Figs 13.31 to 13.34). There is also reactive hyperemia with vascular dilation and congestion of villous capillaries.⁶⁹ There are no eosinophils in the inflammatory infiltrate.⁶⁷

Diagnosis

Oocysts from stool specimens are easily observed by phase-contrast microscopy; the alga-like morula appearance is evident in fresh specimens. Oocysts autofluoresce and stain positively using a modified trichrome method, and stain variably acid-fast using modified Ziehl-Neelsen (Fig 13.30).³⁴ An oocyst DNA extraction method and PCR screening assay to detect a single oocyst is available to evaluate agriculture produce washes.⁷²

Treatment and Prevention

Treatment consists of supportive care, maintenance of fluid and electrolyte balance, symptomatic relief, and antibiotic therapy. Trimethoprim-sulfamethoxazole effectively eradicates the organism.⁷³

SARCOCYSTOSIS

Definition and Synonym

Sarcocystosis, also called sarcosporidiosis and sarcocystitis, is infection by protozoa of the genus *Sarcocystis*, which are members of the family Sarcocystidae that also includes *Toxoplasma gondii*. They are heteroxenous, re-

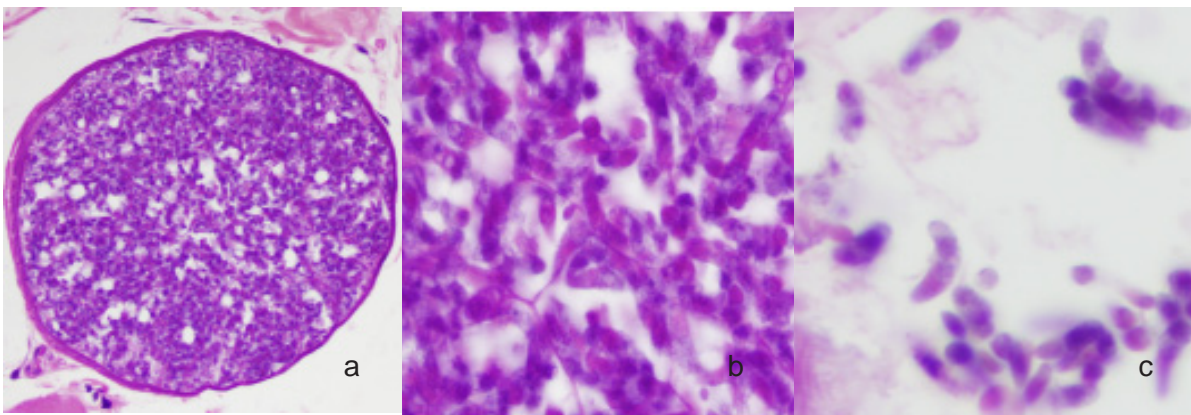
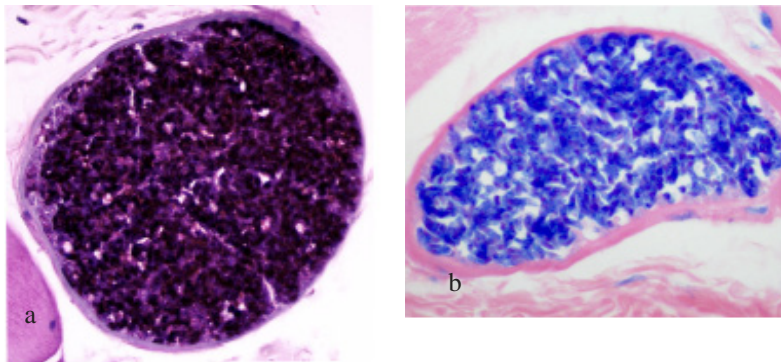


Figure 13.35a-c
Mature sarcocyst of *Sarcocystis hominis* in striated muscle from iliac fossa: a. Only a thin band of muscle envelops the sarcocyst (190 μ m diameter) x270; b. Mature bradyzoites in center of sarcocyst x1000; c. Escaped bradyzoites (9 μ m to 12 μ m x 2 μ m to 4 μ m) nearby a sarcocyst. H&E x1000

**Figure 36 a,b**

Mature sarcocysts in human muscle: a. Bradyzoites are PAS positive. Original magnification x400
b. Bradyzoites are Giemsa positive. Original magnification x400

quiring 2 host species to complete their life cycle. Asexual development takes place in the muscle of an herbivorous intermediate host; sexual development occurs in the intestine of a carnivorous definitive host. Humans are definitive hosts for *Sarcocystis hominis* and *Sarcocystis suihominis*. Zoonotic species are occasionally found in human muscle. Three types found in skeletal muscle resemble species found in monkeys; another type found in cardiac muscle resembles a species seen in cattle.^{74,75}

General Considerations

Sarcocystis was first reported by Miescher in 1843 in mice, and in 1865 in the muscle of swine.⁷⁶ In 1970, it was discovered that bradyzoites develop into coccidian gametes in cell culture,⁷⁶ and into oocysts when fed to cats.

Epidemiology

Sarcocystis is widely distributed but found more frequently in tropical areas.⁷⁷ Cases have been reported from the Africa, Central and South America, China, Europe, India, Malaysia, Southeast Asia, and United States.⁷⁶

Infectious Agent

Morphologic Description

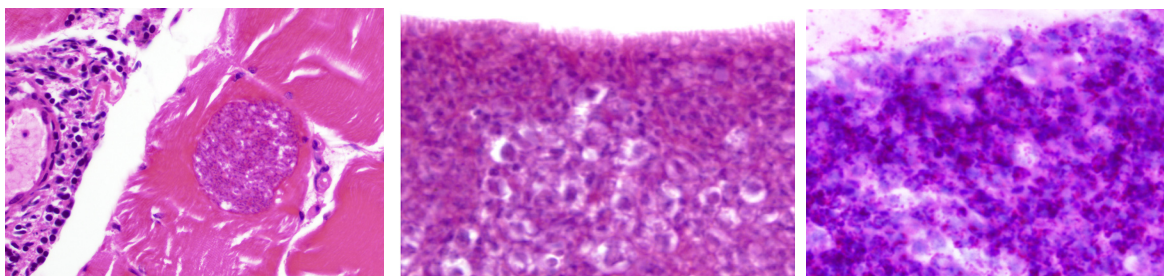
Zoitecysts in muscle are called sarcocysts or Miescher's

tubules.⁷⁶ The structure of the cyst wall varies in different stages of development. The origin of the cyst wall is unknown, but may be of host origin, parasitic origin, or both. Cysts range from 30 μm to 137.5 μm wide (Figs 13.35a to 13.35c). Cyst walls are smooth and less than 1 μm thick. Numerous merozoites, also called bradyzoites, stain both with PAS and Giemsa (Figs 13.36a & 13.36b) but not with acid-fast and have diameters averaging 1 μm , fill the cyst, and in more immature sarcocysts, form 2 distinct regions (Figs 13.37a to 13.37c).^{76,78} The peripheral region is occupied by globular metrocytes that become bradyzoites, which are similar to those of other coccidian merozoites.

Organisms in the sexual stages are within a parasitophorous vacuole bounded by 2 membranes. Gamonts of *S. suihominis* are up to 10 μm in diameter. Microgametes are slender and approximately 4 μm to 5 μm long. Macrogametes are bounded by 2 membranes and contain 2 types of inclusions thought to be wall-forming bodies (Fig 13.38). Each oocyst has a dense outer layer, 4 membranes, and 2 sporocysts, each with 4 sporozoites.⁷⁹

Life Cycle and Transmission

When an intermediate host consumes infective sporocysts, sporozoites are released from the sporocysts and penetrate the intestinal epithelium (Figs 13.39a & 13.39b). They are distributed throughout the body, invading blood vessel endothelial cells in many tissues, including skeletal

**Fig 13.37**

Immature sarcocysts of *Sarcocystis hominis* in striated muscle left leg: a. Spherical form (66 μm diameter) H&E x230; b. Two distinct regions formed by smaller merozoites (1 μm) and larger globular metrocytes (2 μm to 4 μm diameter) in a long narrow sarcocyst (50 μm wide) H&E x1000; c. Peripheral globular metrocytes do not stain with PAS, only the bradyzoites stain. PAS: original magnification x1000

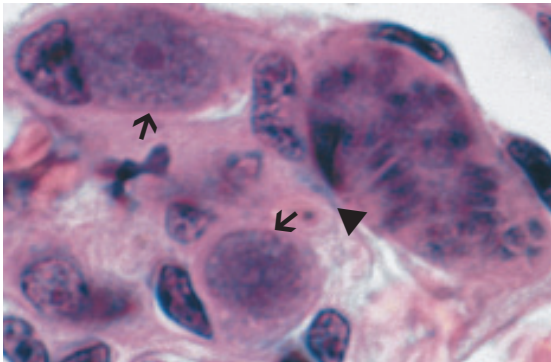


Figure 13.38
Renal glomerulus of calf containing three forms of *Sarcocystis cruzi*, two immature macrogamonts (arrows) and a mature meront with merozoites (arrow head). H&E, original magnification x1500

and cardiac muscle, where they undergo schizogony (asexual reproduction). Large accumulations of merozoites form within zoitocysts. After several divisions, merozoites in the periphery of the zoitocyst give rise to elongated bradyzoites, which are infective in definitive hosts.

Eating meat contaminated with zoitocysts causes infection in a definitive host. The wall of the zoitocyst is digested, and the released bradyzoites penetrate the lamina propria of the small intestine. Within the muscle fiber, they undergo gamogony (sexual reproduction) without an intervening schizogonic generation. The large nucleus of every microgamont gives rise simultaneously to about 20 to 30 microgametes.⁷⁹ Male gametes penetrate female gametes, and the resulting oocyst sporulates in the lamina propria. The oocyst wall is thin and is usually ruptured during intestinal passage to form a sporocyst in the stool (Fig 13.40).

Clinical Features

Sarcocystis has been found in muscles of the larynx, diaphragm, chest, abdomen, extremities, heart, and tongue.⁷⁶ Conditions associated with sarcocystosis include fever, chronic myositis, muscle soreness, weakness, subcutaneous swelling, sinus drainage, eosinophilia, periarteritis, and polyarteritis nodosa.^{74,76,80}

Pathologic Features

Inflammation is not usually seen.⁷⁸ There may be surrounding fibrosis and lymphocytic infiltration with a few eosinophils.⁷⁷

Diagnosis and Treatment

Sarcocystosis is diagnosed by histologic examination of excised tissue. It may be treated with trimethoprim-sulfamethoxazole or by excision of the involved organ in a life-threatening condition.^{77,80}

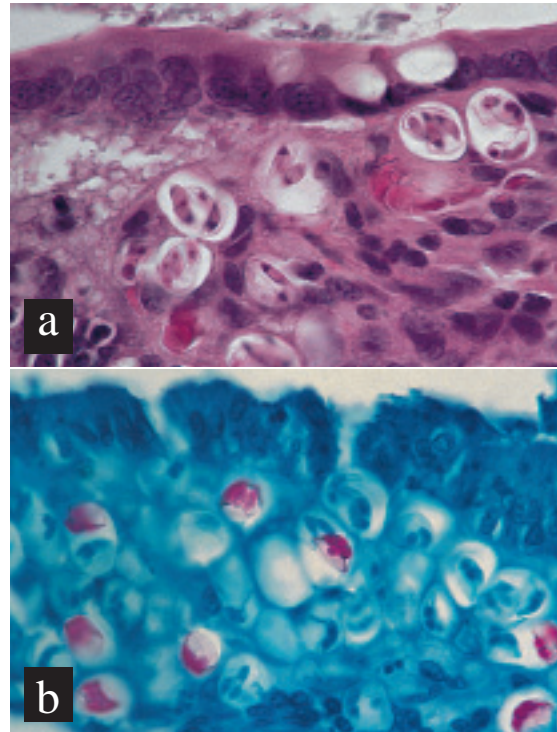


Figure 13.39 a-b
Small intestines with numerous sporulated oocysts in subepithelium: a. *Sarcocystis cruzi* in dog. H&E: original magnification x630; b. *Sarcocystis* sp in rattlesnake. Note acid-fastness of mature sporozoites. Acid-fast stain: original magnification x630

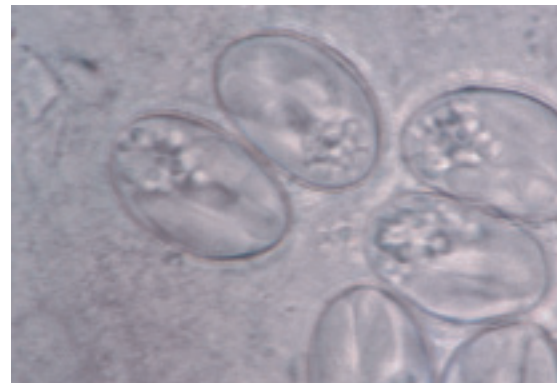


Figure 13.40
Feces of dog containing sporocysts of *Sarcocystis cruzi*, each with four sporozoites and granular residuum. Unstained: original magnification x1500

References

- Cox FEG. Taxonomy and classification of the human parasites, volume 2 Chapter 132, p 1989-1994. In: *Manual of Clinical Microbiology*. PR Murray, EJ Baron, JH Jrgensen, ML Landry, MA Pfaller, eds. 9th Edition ASM Press, Washington, DC.
- Barta JR, Thompson RC. What is *Cryptosporidium*? Reappraising its biology and phylogenetic affinities. *Trends Parasitol*. 2006;22:463-468.
- Xiao L. Molecular epidemiology of cryptosporidiosis: an update. *Exp Parasitol*. 2010;124:80-89.
- Abrahamson MS, Templeton TJ, Enomoto S, et al. Complete genome sequence of the apicomplexan, *Cryptosporidium parvum*. *Science*. 2004;304:441-445.
- Xu P, Widmer G, Wang Y, et al. The genome of *Cryptosporidium hominis*. *Nature*. 2004;431:1107-1112.
- Tanriverdi S, Widmer G. Differential evolution of repetitive sequences in *Cryptosporidium parvum* and *Cryptosporidium hominis*. *Infection, Genetics and Evolution*. 2006;6:113-122.
- Clarke JJ. A study of coccidia met with in mice. *J Micros Soc*. 1895;37:277-302.
- Tyzer EE. An extracellular coccidium, *Cryptosporidium muris* (gen et sp nov.) of the gastric glands of the common mouse. *J Med Res*. 1910;23:487-516.
- Hunter PR, Chalmers RM, Syed Q, Hughes LS, Woodhouse S, Swift L. Foot and mouth disease and cryptosporidiosis: possible interaction between two emerging infectious diseases. *Emerg Infect Dis*. 2003;9:109-112.
- Yoder JS, Harral C, Beach MJ; Centers for Disease Control and Prevention (CDC). Cryptosporidiosis surveillance - United States, 2006-2008. *MMWR Surveill Summ*. 2010;59:1-14.
- Roberts WG, Green PH, Ma J, Carr M, Ginsberg AM. Prevalence of cryptosporidiosis in patients undergoing endoscopy: evidence for an asymptomatic carrier state. *Am J Med*. 1989;87:537-539.
- Manabe YC, Clark DP, Moore RD, et al. Cryptosporidiosis in patients with AIDS: correlates of disease and survival. *Clin Infect Dis*. 1998;27:536-542.
- Borowski H, Thompson RC, Armstrong T, Clode PL. Morphological characterization of *Cryptosporidium parvum* life-cycle stages in an in vitro model system. *Parasitology*. 2010;137:13-26.
- Orenstein JM. Cryptosporidiosis. In: Connor DH, Chandler FW, Schwartz DA, Manz HJ, Lack EE. *Pathology of Infectious Diseases*, Vol II, 1997, Appleton & Lange: Stamford, pp1147-1158.
- Tzipori S, Griffiths JK. Natural history and biology of *Cryptosporidium parvum*. *Adv Parasitol*. 1998;40:5-36.
- O'Hara SP, Huang BQ, Chen XM, Nelson J, LaRusso NF. Distribution of *Cryptosporidium parvum* sporozoite apical organelles during attachment to and internalization by cultured biliary epithelial cells. *J Parasitol*. 2005;91:995-999.
- Hijjawi NS, Meloni BP, Morgan UM, Thompson RC. Complete development and long-term maintenance of *Cryptosporidium parvum* human and cattle genotypes in cell culture. *Int J Parasitol*. 2001;31:1048-1055.
- Hijjawi NS, Meloni BP, Ng'anzo M, et al. Complete development of *Cryptosporidium parvum* in host cell-free culture. *Int J Parasitol*. 2004;34:769-777.
- Huang BQ, Chen X-M, LaRusso NF. *Cryptosporidium parvum* attachment to and internalization by human biliary epithelia in vitro: a morphologic study. *J Parasitol*. 2004;90:212-221.
- Chen X-M, Keithly JS, Paya CV, LaRusso NF. Cryptosporidiosis. *N Engl J Med*. 2002;346:1723-1731.
- Centers for Disease Control and Prevention (CDC). Foodborne outbreak of cryptosporidiosis--Spokane, Washington, 1997. *MMWR Morb Mortal Wkly Rep*. 1998;47:565-567.
- Pönkä A, Kotilainen H, Rimhanen-Finne R, et al. A foodborne outbreak due to *Cryptosporidium parvum* in Helsinki, November 2008. *Euro Surveill*. 2009;14. pii:19269.
- Mac Kenzie WR, Hoxie NJ, Proctor ME, et al. A massive outbreak in Milwaukee of *Cryptosporidium* infection transmitted through the public water supply. *N Engl J Med*. 1994;331:161-167. Erratum in: *N Engl J Med*. 1994;331:1035.
- Centers for Disease Control and Prevention (CDC). Outbreak of cryptosporidiosis associated with a splash park - Idaho, 2007. *MMWR Morb Mortal Wkly Rep*. 2009;58:615-8. Erratum in: *MMWR Morb Mortal Wkly Rep*. 2009;58:781. *MMWR Morb Mortal Wkly Rep*. 2009;58:645.
- Hunter PR, Hughes S, Woodhouse S, et al. Sporadic cryptosporidiosis case-control study with genotyping. *Emerging Infect Dis*. 2004;10:1241-1249.
- Chappell CL, Okhuysen PC, Langer-Curry R, et al. *Cryptosporidium hominis*: experimental challenge of healthy adults. *Am J Trop Med Hyg*. 2006;75:851-857.
- DuPont HL, Chappell CL, Sterling CR, Okhuysen PC, Rose JB, Jakubowski W. The infectivity of *Cryptosporidium parvum* in healthy volunteers. *N Engl J Med*. 1995;332:855-859.
- Fayer R, Ungar BLP. *Cryptosporidium* spp. and cryptosporidiosis. *Microbiol Rev*. 1986;50:458-483.
- Clark DP. New insights into human cryptosporidiosis. *Clin Microbiol Rev*. 1999;12:554-563.
- Rossi P, Rivasi F, Codeluppi M, et al. Gastric involvement in AIDS associated cryptosporidiosis. *Gut*. 1998;43:476-477.
- Mor SM, Tumwine JK, Ndeez G, et al. Respiratory cryptosporidiosis in HIV-seronegative children in Uganda: potential for respiratory transmission. *Clin Infect Dis*. 2010;50:13661-13672.
- Travis WD, Schmidt K, MacLowry JD, Masur H, Condron KS, Fojo AT. Respiratory cryptosporidiosis in a patient with malignant lymphoma. *Arch Pathol Lab Med*. 1990;114:519-522.
- Borad A, Ward H. Human immune responses in cryptosporidiosis. *Future Microbiol*. 2010;5:507-519.
- Xiao L. Overview of *Cryptosporidium* presentations at the 10th International Workshops on Opportunistic Protists. *Eukaryot Cell*. 2009;8:429-436.
- Chen XM, Levine SA, Splinter PL, et al. *Cryptosporidium parvum* activates nuclear factor kappaB in biliary epithelia preventing epithelial cell apoptosis. *Gastroenterology*. 2001;120:1774-1783.
- Elliott DA, Clark DP. Host cell fate on *Cryptosporidium parvum* egress for MDCK cells. *Infect Immun*. 2003;71:5422-5426.
- Feng H, Nie W, Sheoran A, Zhang Q, Tzipori S. Bile acids enhance invasiveness of *Cryptosporidium* spp. into cultured cells. *Infect Immun*. 2006;74:3342-3346.
- Lumadue JA, Manabe YC, Moore RD, Belitsos PC, Sears C, Clark DP. A clinicopathologic analysis of AIDS-related cryptosporidiosis. *AIDS*. 1998;12:2459-2466.
- Varea M, Clavel A, Doiz O, Castillo FJ, Rubio MC, Gómez-Lus R. Fuchsin fluorescence and autofluorescence in *Cryptosporidium*, *Isospora* and *Cyclospora* oocysts. *Int J Parasitol*. 1998;28:1881-1883.
- Deere D, Vesey G, Milner M, Williams K, Ashbolt N, Veal D. Rapid method for fluorescent in situ ribosomal RNA labelling of *Cryptosporidium parvum*. *J Appl Microbiol*. 1998;85:807-818.
- Widmer G. Genetic heterogeneity and PCR detection of *Cryptosporidium parvum*. *Adv Parasitol*. 1998;40:223-239.
- Stroup SE, Roy S, Mchele J, et al. Real-time PCR detection and speciation of *Cryptosporidium* infection using Scorpion probes. *J Med Microbiol*. 2006;55:1217-1222.
- Smith NH, Cron S, Valdez LM, Chappell CL, White AC Jr. Combination drug therapy for cryptosporidiosis in AIDS. *J Infect Dis*. 1998;178:900-903.
- Meamar AR, Rezaian M, Rezaie S, et al. *Cryptosporidium parvum* bovine genotype oocysts in the respiratory samples of an AIDS patient: efficacy of treatment with a combination of azithromycin and paromomycin. *Parasitol Res*. 2006;98:593-595.
- Liu K, Zai D, Zhang D, et al. Divalent Cp15-23 vaccine enhances immune responses and protection against *Cryptosporidium parvum* infection. *Parasite Immunol*. 2010;32:335-344.
- Connelly JT, Nugen SR, Borejsza-Wysocki W, Durst RA, Montagna RA, Baeumner AJ. Human pathogenic *Cryptosporidium* species bioanalytical detection method with single oocyst detection capability. *Anal Bioanal Chem*. 2008;391:487-495.
- Lindsay DS, Dubey JP, Blagburn BL. Biology of *Isospora* spp. from humans, nonhuman primates, and domestic animals. *Clin Microbiol Rev*. 1997;10:19-34.
- Guiguet M, Furco A, Tattevin P, Costagliola D, Molina JM; French Hospital Database on HIV Clinical Epidemiology Group. HIV-associated *Isospora belli* infection: incidence and risk factors in the French Hospital Database on HIV. *HIV Med*. 2007;8:124-130.
- Curry A, Smith HV. Emerging pathogens: *Isospora*, *Cyclospora* and *microsporidia*. *Parasitology*. 1998;117 Suppl:S143-159.
- Koru O, Araz RE, Yilmaz YA, et al. Case report: *Isospora belli* infection in a renal transplant recipient. *Turkiye Parazit Derg*. 2007;31:98-100.
- Kochhar A, Saxena S, Malhotra VL, Deb M. *Isospora belli* infection in a malnourished child. *J Commun Dis*. 2007;39:141-143.
- Assefa S, Erko B, Medhin G, Assefa Z, Shimelis T. Intestinal parasitic infections in relation to HIV/AIDS status, diarrhea and CD4 T-cell count. *BMC Infect Dis*. 2009;9:155.
- Ferguson DJ, Birch-Andersen A, Hutchison WM, Siim JC. Ultrastructural observations on macrogametogenesis and the structure of the macrogamete of *Isospora felis*. *Acta Pathol Microbiol Scand B*. 1980;88:161-168.

54. Elshazly AM, Elsheitka HM, Soltan DM, Mohammad KA, Morsy TA. Protozoal pollution of surface water sources in Dakahlia Governorate, Egypt. *J Egypt Soc Parasitol.* 2007;37:51-64.
55. Meamar AR, Rezaian M, Mirzaei AZ, et al. Severe diarrhea due to *Isoospora belli* in a patient with thymoma. *J Microbiol Immunol Infect.* 2009;42:526-529.
56. Gupta S, Narang S, Nunavath V, Singh S. Chronic diarrhoea in HIV patients: prevalence of coccidian parasites. *Indian J Med Microbiol.* 2008;26:172-175.
57. Hizawa K, Iida M, Eguchi K, et al. Comparative features of double-contrast barium studies in patients with isosporiasis and strongyloidiasis. *Clin Radiol.* 1998;53:764-767.
58. Field AS. Light microscopic and electron microscopic diagnosis of gastrointestinal opportunistic infections in HIV-positive patients. *Pathology.* 2002;34:21-35. Erratum in: *Pathology.* 2002;34:301.
59. Frenkel JK, Silva MB, Saldanha J, et al. *Isoospora belli* infection: observation of unicellular cysts in mesenteric lymphoid tissues of a Brazilian patient with AIDS and animal inoculation. *J Eukaryot Microbiol.* 2003;50 Suppl:682-684.
60. Restrepo C, Macher AM, Radany EH. Disseminated extraintestinal isosporiasis in a patient with acquired immune deficiency syndrome. *Am J Clin Pathol.* 1987;87:536-542.
61. Walther Z, Topazian MD. *Isoospora* cholangiopathy: case study with histologic characterization and molecular confirmation. *Hum Pathol.* 2009;40:1342-1346.
62. Michiels JF, Hofman P, Bernard E, et al. Intestinal and extraintestinal *Isoospora belli* infection in an AIDS patient. A second case report. *Pathol Res Pract.* 1994;190:1089-1093.
63. Hanscheid T, Cristino JM, Salgado MJ. Screening of auramine-stained smears of all fecal samples is a rapid and inexpensive way to increase the detection of coccidian infections. *Int J Infect Dis.* 2008;12:47-50.
64. ten Hove RJ, van Lieshout L, Brienen EA, Perez MA, Verweij JJ. Real-time polymerase chain reaction for detection of *Isoospora belli* in stool samples. *Diagn Microbiol Infect Dis.* 2008;61:280-283.
65. Centers for Disease Control and Prevention. Update: outbreaks of cyclosporiasis—United States, 1997. *JAMA.* 1997;277:1838.
66. Devera R, Blanco Y, Cabello E. [High prevalence of *Cyclospora cayetanensis* among indigenous people in Bolivar State, Venezuela]. *Cad Saude Publica.* 2005;21:1778-1784.
67. Nhieu JT, Nin F, Fleury-Feith J, Chaumette MT, Schaeffer A, Bretagne S. Identification of intracellular stages of *Cyclospora* species by light microscopy of thick sections using hematoxylin. *Hum Pathol.* 1996;27:1107-1109.
68. Sun T, Ilardi CF, Asnis D, et al. Light and electron microscopic identification of *Cyclospora* species in the small intestine. Evidence of the presence of asexual life cycle in human host. *Am J Clin Pathol.* 1996;105:216-220.
69. Ortega YR, Nagle R, Gilman RH, et al. Pathologic and clinical findings in patients with cyclosporiasis and a description of intracellular parasite life-cycle stages. *J Infect Dis.* 1997;176:1584-1589.
70. Sterling CR, Ortega YR. *Cyclospora*: an enigma worth unraveling. *Emerg Infect Dis.* 1999;5:48-53.
71. Dorny P, Praet N, Deckers N, Gabriel S. Emerging food-borne parasites. *Vet Parasitol.* 2009;163:196-206.
72. Lalonde LF, Gajadhar AA. Highly sensitive and specific PCR assay for reliable detection of *Cyclospora cayetanensis* oocysts. *Appl Environ Microbiol.* 2008;74:4354-4358.
73. Brown GH, Rotschafer JC. *Cyclospora*: review of an emerging parasite. *Pharmacotherapy.* 1999;19:70-75.
74. Beaver PC, Gadgil K, Morera P. *Sarcocystis* in man: a review and report of five cases. *Am J Trop Med Hyg.* 1979;28:819-844.
75. Dubey JP, Lindsay DS. Neosporosis, toxoplasmosis, and sarcocystosis in ruminants. *Vet Clin North Am Food Anim Pract.* 2006;22:645-671.
76. Fayer R. *Sarcocystis* spp. in human infections. *Clin Microbiol Rev.* 2004;17:894-902, table of contents.
77. Liu CT, Roberts LM. Sarcosporidiosis in a Bantu woman. *Am J Clin Pathol.* 1965;44:639-641.
78. Wong KT, Clarke G, Pathmanathan R, Hamilton PW. Light microscopic and three-dimensional morphology of the human muscular sarcocyst. *Parasitol Res.* 1994;80:138-140.
79. Mehlhorn H, Heydorn AO. Electron microscopical study on gamogony of *Sarcocystis suihominis* in human tissue cultures. *Z Parasitenkd.* 1979;58:97-113.
80. Van den Enden E, Praet M, Joos R, Van Gompel A, Gigasse P. Eosinophilic myositis resulting from *sarcocystosis*. *J Trop Med Hyg.* 1995;98:273-276.

Acknowledgements

Figures 13.2, 13.3, 13.5, 13.6, 13.8, 13.9, 13.14, 13.15, 13.38, 13.39, 13.40

Gardiner CH, Fayer R, Dubey JP. An Atlas of Protozoan Parasites in Animal Tissues (Second Edition). Armed Forces Institute of Pathology, American Registry of Pathology: Washington, DC.

Figures 13.4, 13.7, 13.10

Saul Tzipori, Division of Infectious Diseases, Tufts University, School of Veterinary Medicine, North Grafton, MA as published in Tzipori S, Ward H. Cryptosporidiosis: biology, pathogenesis and disease. *Microbes and Infection* 2002;4:1047-1058. Licensed to the AFIP :Copyright © Elsevier, France.

Figures 13.11

Saul Tzipori, Division of Infectious Diseases, Tufts University, School of Veterinary Medicine, North Grafton, MA as modified from Tzipori S and Widmer G. The biology of *Cryptosporidium*. *Contributions for Microbiology* 2000;6:1-32. Artist: Douglas Landry.

Figures 13.31, 13.32, 13.33, 13.34

Pr Stéphane Bretagne, Laboratoire de Parasitologie-Mycologie, Faculté de Médecine, Créteil Cedex, France as published in Nhieu JT, Nin F, Fleury-Feith J, Chaumette MT, Schaeffer A, Bretagne S. Identification of intracellular stages of *Cyclospora* species by light microscopy of thick sections using hematoxylin. *Hum Pathol* 1996;27:1107-1109.