

EFSUMB



EFSUMB Course Book

Student Edition

Editors: Jan Tuma, Radu Badea, Christoph F. Dietrich

Ultrasound of the spleen

**Simona Ioanitorescu¹, Laura Iliescu¹, Mihai Harza², Gener Ismail¹,
Ionel Copaci¹**

¹ Center of Internal Medicine, Fundeni Clinical Institute, Bucharest, Romania

² Center for Urology and Renal Transplantation, Fundeni Clinical Institute,
Bucharest, Romania

Corresponding author:

Dr. Simona Ioanitorescu

Center of Internal Medicine, Fundeni Clinical Institute

258 Fundeni Street, District 2, Bucharest, Romania

zip code 022328

Tel.: (+) 40- 722 – 494 – 586

Email: simona.ioanitorescu@gmail.com

Acknowledgment:

The authors thank Radu Badea for peer review of the manuscript.

Content

Content	2
Introduction	3
Topography	3
Anatomy	4
Anatomical orientation	4
Architecture	4
Examination technique	8
Patient preparation and positioning	8
Spleen examination technique.....	8
Transducer selection	10
Ultrasound assessment criteria of normal findings and its variants	11
Size	11
Measurements	12
Position of the spleen	13
Shape and contour	14
Texture and echogenicity (echopattern)	14
Variations of the number of the spleen	14
Accessory spleen	14
Asplenia and polysplenia.....	16
Hyposplenia.....	16
VIP: Very Important (and most frequent) Pathologies of the spleen	17
Splenomegaly	17
Diffuse splenomegaly	19
Splenic abscess.....	23
Splenic hydatid cyst.....	25
Focal splenic lesions	26
Benign splenic lesions	26
Splenic cystic lesions.....	26
Solid splenic lesions	29
Malignant splenic lesions.....	31
Lymphomas.....	31
Leukemias	32
Metastases of the spleen.....	33
Vascular disease	34
Traumatic spleen	37
References	39

Introduction

The rarity of spleen's own pathology is well known, this being the reason why Goerg has also named the spleen as "the forgotten organ". Otherwise, the spleen is frequently involved in other organ's pathology or in systemic disorders; consequently, monitoring the spleen has its significance in the follow-up of these, mainly chronic, disorders. Furthermore, ultrasonography plays an important role because of its recognized advantages and it is also of critical importance in early diagnosing of spleen trauma and in monitoring the blunt trauma. These are the reasons why ultrasonography should be the modality of choice in spleen's imaging examination.

Topography

The spleen is a bean-like shape organ that lies on the left hypochondrium and partly in the epigastrium with its superior extremity. Thus, the spleen is located between the fundus of the stomach and the diaphragm which separates it from the 9th, 10th and 11th ribs of the left side and from the lower margin of the left lung and pleura (Figure 1, Figure 2). The spleen is a highly vascular organ with soft and friable consistency and dark purple in colour; its size and weight may vary between individuals and in the same individual. Usually, a healthy spleen is not palpable.

Figure 1 Normal positioned spleen, left hypocondrium. Axial section through the splenic hilum. Anatomical relation with the diaphragm.

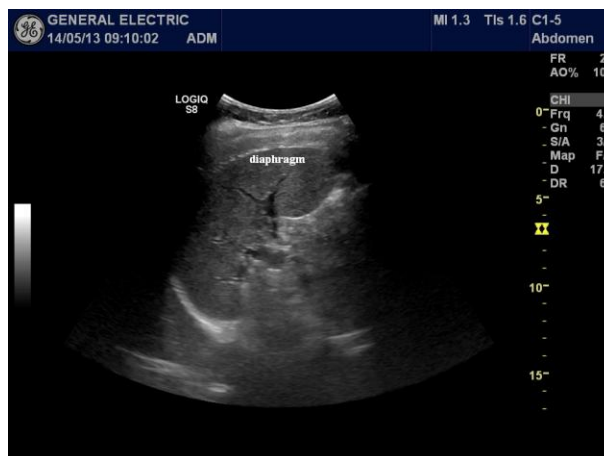
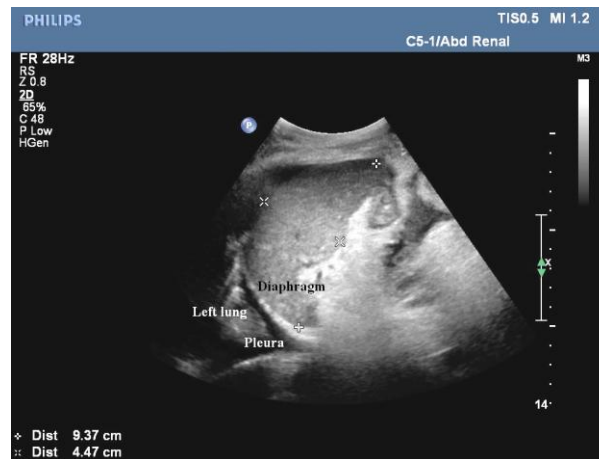

Figure 2 Normal positioned spleen in a patient with pleurisy. Anatomical relations with pleura and left lung, better visualization due to the presence of pleural effusion.



Anatomy

Anatomical orientation

The spleen has one anterior and one posterior extremity. The anterior end is thin, looking more like an edge and is directed forward and downward, reaching the midaxillary line while the posterior end is rounded and looks upward and backward, resting on the upper pole of the left kidney.

The spleen has 3 borders: superior, inferior and intermediate respectively. The anterior extremity notches the superior border but the inferior one is rounded and smooth. The intermediate border faces the right side of the body.

The spleen has also 2 surfaces: a diaphragmatic surface and a visceral surface. While the diaphragmatic surface is smooth and rounded, the visceral one is concave and has irregularities corresponding to the gastric, renal, colic and pancreatic impressions. The gastric impression which matches the fundus of the stomach is the largest one and the most concave impression of the spleen; the renal impression is made by the left kidney and is located between the inferior and the intermediate borders; the colic impression corresponds to the splenic flexure of the colon and its inferior part is connected to the phrenicocolic ligament. Between the hilum and the colic impression lies the pancreatic impression of the pancreatic tail (Figure 3, Figure 4).

Architecture

The hilum of the spleen is located on the inferomedial part of the gastric impression and contains the splenic vessels and nerves; it also plays the role of attachment to the gastrosplenic and splenorenal ligaments.

Figure 3 Anatomic orientation of the spleen

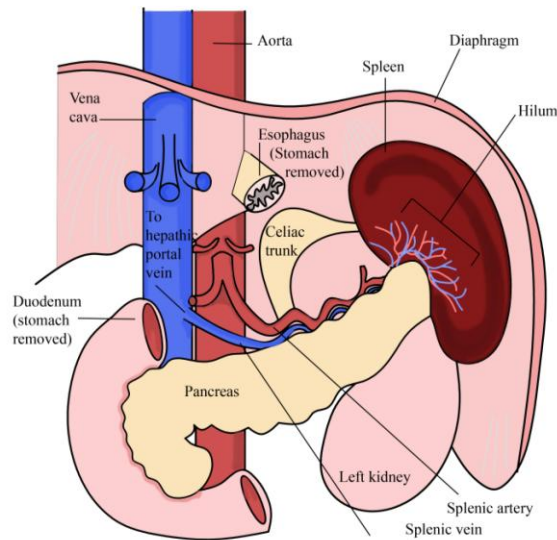
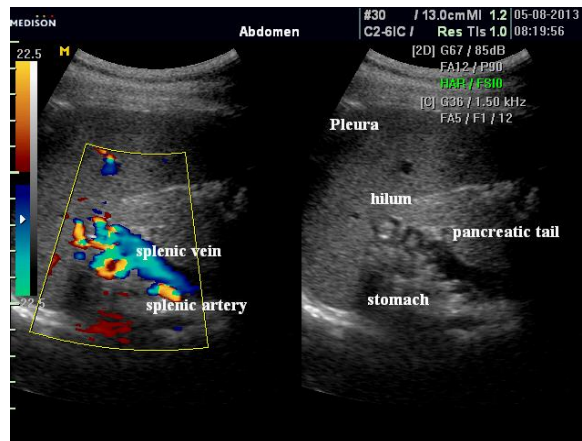


Figure 4 Normal spleen. Longitudinal section through the splenic hilum. The retropancreatic trajectory of the splenic vein is revealed. Anatomical relations with pancreatic tail, stomach and pleura.



Peritoneal relations

The peritoneum surrounds almost entirely the spleen, firmly adhering to its capsule; the spleen is held in position by multiple ligaments which are as follows:

- the gastrosplenic ligament which runs from the hilum of the spleen to the greater curvature of the stomach and contains some short gastric vessels along with lymphatic vessels and sympathetic fibers;
- the splenorenal ligament between the hilum of the spleen and the left kidney, containing splenic vessels and the pancreatic tail;
- the phrenicocolic ligament is derived from the peritoneum and has the role to support the inferior pole of the spleen; it runs between the splenic flexure of

the colon and the diaphragm and forms the upper extremity of the left paracolic gutter.

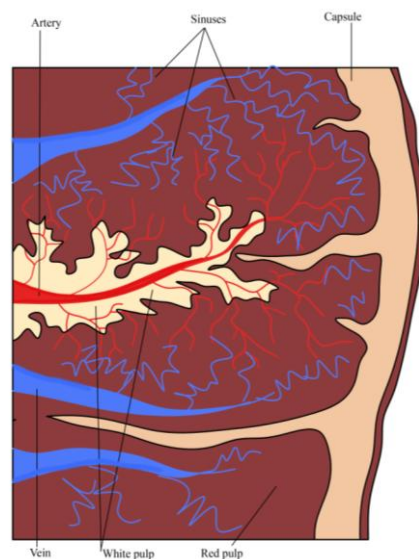
Surface marking

The projection of the spleen to the surface of the body corresponds with the long axis of the 10th rib on the left side of the back; the superior border is marked alongside the upper border of the 9th rib while the inferior border is marked along the 11th rib. The medial extremity lies 5 cm from the midline and the lateral extremity is located at the midaxillary line.

Microscopic anatomy

The spleen has 4 major components: the supporting tissue, the white pulp, the red pulp and the vascular system (Figure 5).

Figure 5 Microscopic anatomy of the spleen



The supporting tissue is represented by the fibroelastic coat from which small fibrous bands called trabeculae disperse in all directions; between these trabeculae, small spaces called areolae are formed, containing the splenic pulp. The presence of elastic tissue confers the spleen the great amount of elasticity which explains the great variance in size seen under certain conditions.

The white pulp is made of lymphatic nodules organized around an eccentric arteriole called the Malpighian corpuscle.

The red pulp is a soft mass, dark-red in colour made of a fine reticulum of fibres which continue the trabeculae. The meshes of the reticulum contain blood; the cell population consists of all types of lymphocytes, red blood cells, attached and free macrophages.

Vascular supply

The main arterial blood supply of the spleen is represented by the splenic artery which is the largest branch of the celiac artery; it reaches the hilum of the spleen after passing through the splenorenal ligament. It divides into six or more branches which enter the hilum (trabecular arteries) and then subdivides in central arteries.

The blood vessels of the spleen are adapted to sustain the main function of the spleen, separation and storage of red blood cells.

The splenic arteries enter the pulp within the trabeculae. From the central arteries many small minute arterioles emerge and divide to the red and the white pulp. The arterioles lose their tubular character and open freely into the splenic pulp bringing blood into intimate relation with the pulp where it undergoes important changes. The arteries branching into the white pulp are surrounded by a sheath of lymphocytes mainly T-cells (PALS: periarterial lymphatic sheath). From the central arteries small branches enter the red pulp or are connected directly to the sinusoids at the end of the arterioles. These sinusoids are part of the marginal zone and are the site of the vascular exchange between the spleen and the circulatory system. Blood from the sinusoids are collected into the pulp and trabecular veins. These trabecular veins merge to form the splenic vein leaving the spleen through the hilum and unite to constitute the splenic vein which runs behind the pancreas and joins the superior mesenteric vein to form the portal vein.

Remarkably, the veins have numerous anastomoses, while the arteries hardly have anastomose at all.

Thus, two circulation patterns can be differentiated inside the spleen: an open, slow circulation, (mainly open-ended arterioles in the red pulp) that functions as a filter for erythrocytes and a closed, rapid circulation, in which arterioles are directly connected to the sinusoids.

This particular aspect of the spleen circulation can be imaged on contrast enhanced imaging explorations (CEUS, CE-CT, CE-MRI) (Figure 6, Figure 7).

Figure 6 Arterial inhomogeneous enhancement on CEUS at 13 s and 29 s after contrast injection. The arterial enhancement proves the different circulation patterns present inside the spleen.

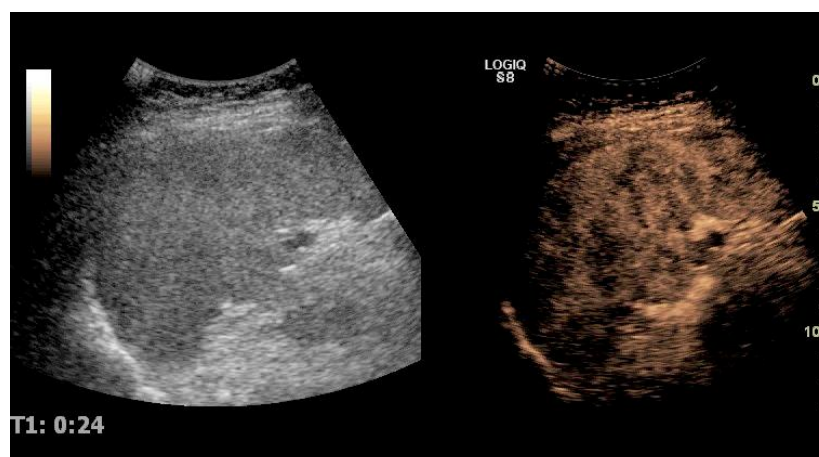
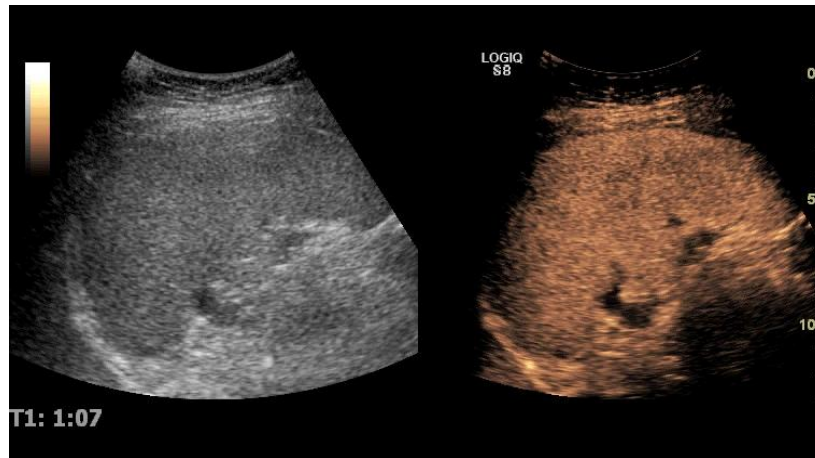


Figure 7 Homogeneous enhancement pattern on parenchymal phase

Nerve supply of the spleen is represented by sympathetic fibres originating in the celiac plexus which are distributed to the blood vessels and the smooth muscles of the splenic capsule and trabeculae.

Lymphatic drainage of the spleen is provided by the pancreaticosplenic lymph nodes and comes from the capsule and the trabeculae because the proper splenic tissue has no lymphatic vessels.

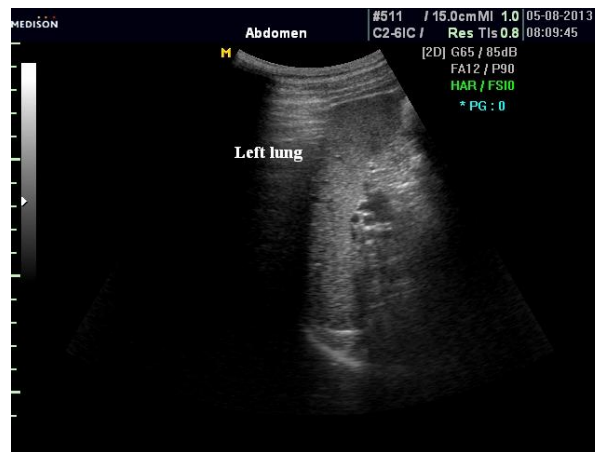
Examination technique

Patient preparation and positioning

Ultrasonographic examination of the spleen might be difficult due to the position of the spleen. The spleen is located under the diaphragmatic dome, in proximity to the left lung and to the left colic flexure. The aeration of the lung and the colon makes these two organs difficult to be penetrated by the ultrasound beam (Figure 8). Because of the reasons mentioned above, the ultrasonographic exploration is more challenging in patients with pulmonary emphysema or aerocolia.

Examination of the spleen is preferably undertaken a jeun; the patient is asked to assume a supine or right lateral decubital position, with the left hand placed above the head in order to widen the intercostal spaces. Sometimes a slight right decubital position could improve the examination.

Figure 8 Normal positioned spleen. Partial vizualization due to the aeration of the lung.



Spleen examination technique

Examination starts from a lateral plane, coronal or transverse, and oblique, positioning the transducer between the intercostal spaces IX – XI in order to let ultrasounds penetrate the intercostal spaces. It is important to take into account the breathing movements of the patient. Thus, a deep inspiration facilitates the visualization of the postero-superior pole of the spleen.

Systematically, the transducer is used to explore the entire length of the organ, coronal, transversely and oblique. There are at least two important images of the spleen to obtain, in the longitudinal and transverse plane that include the splenic hilum. The contour, the echostructure and the splenic vessels should be described.

The examination should include not only the spleen, but the entire perisplenic area to analyse the integrity of the left diaphragm, the left pleural space in order to exclude pleural effusions and the upper pole of the left kidney.

Systematic examination of the entire spleen, as well as of the perisplenic space is very important in order to identify any focal lesions in hematological pathology as well as to assess the integrity of the splenic capsule and to exclude the presence of perisplenic fluids, especially in patients with cirrhosis and splenomegaly or in those who have suffered a traumatic event.

Doppler examination completes the 2D examination, colour Doppler demonstrating the permeability of the splenic vessels and differentiating the collateral circulation (Figure 9). Pulse Doppler allows the analysis of the resistivity and pulsatility indexes, important parameters in monitoring portal hypertension (Figure 10, Figure 11).

Provided splenomegaly is discovered, the examination is extended, including the space immediately under the rib cage.

Figure 9 Longitudinal section. Doppler colour examination demonstrate normal opposite direction of blood flow inside the splenic artery and vein

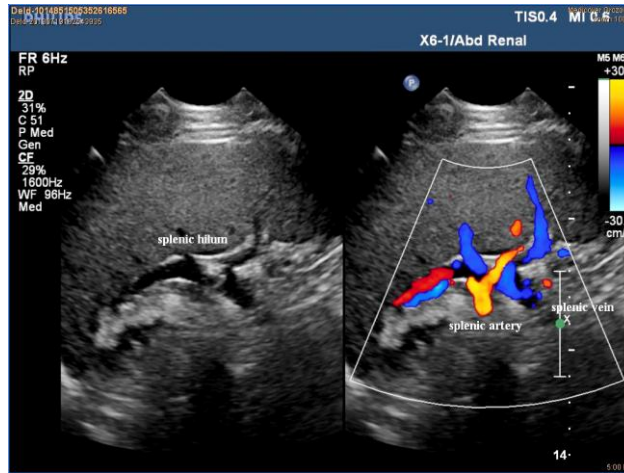


Figure 10 Splenic artery. Normal low resistivity flow. Typical for splanchnic arteries, higher pulsatility index “a jeun” and low pulsatility index after meal.

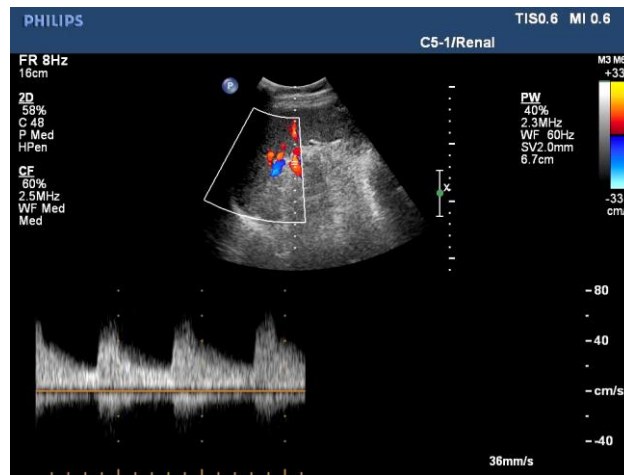
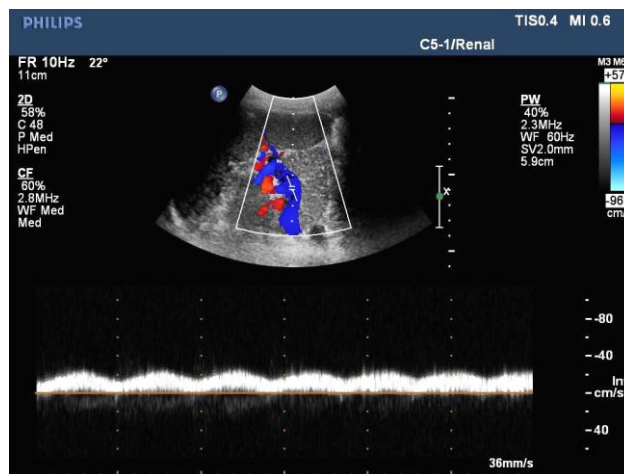


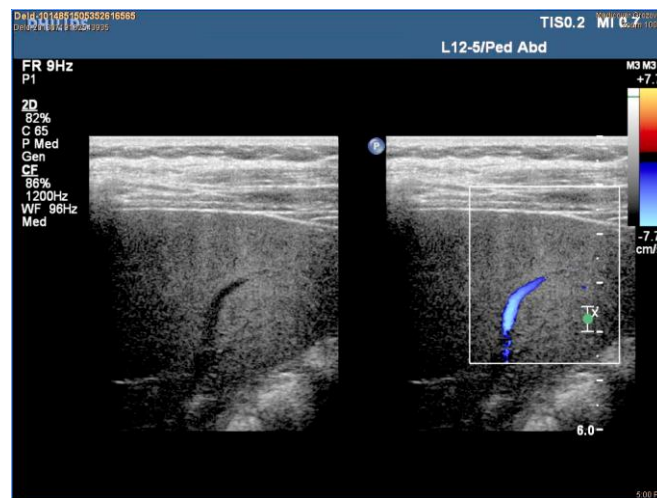
Figure 11 Splenic vein. Normal monophasic flow, typical for splanchnic veins.



Transducer selection

The most frequently used transducer is the wideband, 2-5 mHz convex probe. In children or in cases in which the surface of the spleen needs to be evaluated in great detail, linear transducers with high resolution, but low penetrability may be used to complete the standard examination (Figure 12). Such situations arise in splenomegalies pertaining to hematological disorders (for the identification of the intrasplenic masses), and in the congestive disorders of the spleen.

Figure 12 Linear probe demonstrating the irregular contour of the spleen in cirrhotic patient with moderate splenomegaly



Ultrasound assessment criteria of normal findings and its variants

Size

Several studies have proved that the normal dimensions of the spleen vary according to age, weight, body surface area, height and sex. The size of the spleen undergoes changes in accordance with the nutritional status of the patient, as it exhibits a slight growth after meals.

As splenomegaly is common to many conditions, it is important to know in clinical practice when to consider that a spleen is enlarged.

In a study published in 2012 in which 111 human cadaveric spleens have been analyzed, the average length of the spleens examined was 9.66 cm (ranging from 5 cm to 13 cm), the average width of 6.22 cm (values ranged between 3.5 cm and 9.5 cm) and the thickness varied between 1.5 cm and 5.5 cm, with an average of 3.06 cm. The weight also showed great variations, ranging between 80 and 300g, 145.76g being the average weight.

Another study indicates that normal average dimensions of the spleen in a healthy male athlete with a height above 2 m range between 13.2 cm and 16.2 cm. In female

athletes taller than 2 m the average dimensions of the spleen were found to be approximately 11.2 cm, with the maximum value recorded of 14 cm.

The current clinical practice guidelines accept 11-12 cm (less than 13 cm) as the normal length of the spleen in a healthy adult, 3-4 cm in breadth and a weight of about 150g.

The spleen shrinks proportional to the aging process.

Measurements

In current clinical practice, the maximum axial and transverse diameters of the spleen are recorded (Figure 13).

Frequently, the diameter measured is solely the axial diameter, as this has been proven to be a conclusive indicator of splenomegaly, according to clinical studies.

Among other measurements used, albeit not routinely, measurement of the surface area of the spleen in maximum section and the estimation of the volume of the spleen are of note (Figure 14).

It is important to measure the vascular pedicle of the spleen; the diameter of the splenic artery should be around 4-5 mm and the splenic vein should measure a maximum of 9 mm in diameter (Figure 15).

The caliber of the splenic vein is a valuable indicator for the assessment of portal hypertension in patients with chronic liver disease.

Figure 13 Measuring the splenic size

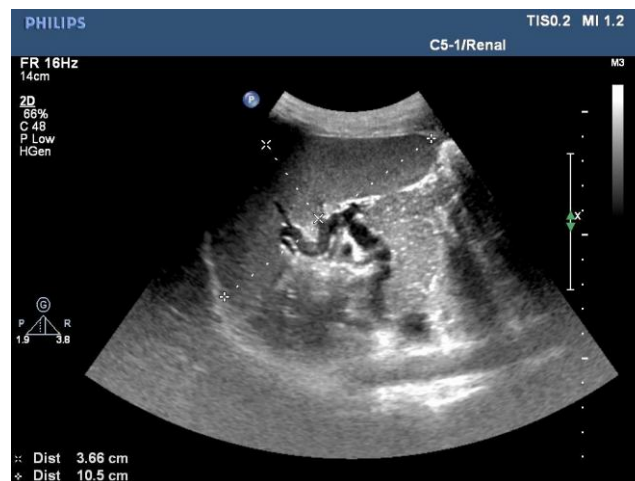


Figure 14 Splenic area calculation

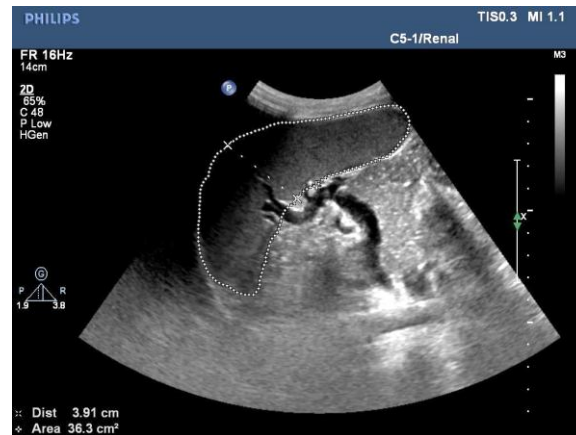
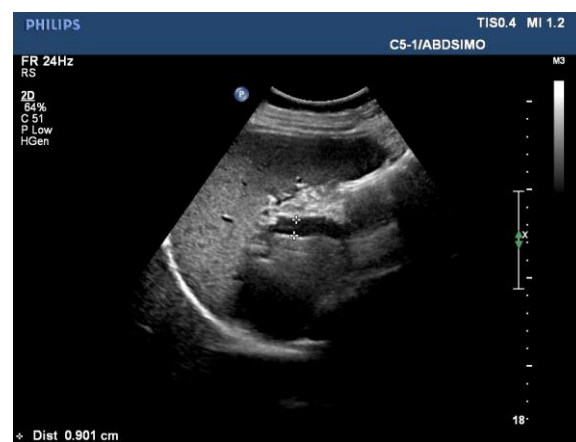
Figure 15 Splenic vein calculation



Position of the spleen

Under normal circumstances, the anatomical position of the spleen is under the diaphragmatic dome, within the left hypochondrium.

In rare situations, be they congenital or acquired, the spleen may be found in unusual positions within the abdominal cavity. The “wandering spleen” is a very rare congenital condition, in which the spleen can freely move in the abdominal cavity, reaching positions as far as the lower abdomen or the pelvis. This condition is brought about by the total or partial absence of the suspensory ligaments of the spleen. Thus, the spleen is held into place solely by the vascular pedicle. A major risk of this particular condition is torsion of the spleen, which can lead to splenic infarction that becomes clinically manifest through acute or chronic abdominal pain.

Another situation in which the spleen is mobile within the abdominal cavity is encountered in connective tissue disorders or in multiparous women, due to visceroptosis or rupture of the suspensory ligaments of the spleen.

In these rare situations the spleen may be mistaken for a tumor. The diagnosis of a malposition of the spleen is difficult and requires additional investigations (CT, angiography, scintigraphy). The most sensitive imaging technique is using technetium-labeled, heat-damaged autologous erythrocytes scintigraphy.

Shape and contour

Anatomically, the spleen is most frequently wedge shaped. This shape has been cited in several studies, according to which the frequency of the wedge shape ranges between 44 and 61.26%, followed by the tetrahedral shape (42% – 21.62%) and triangular shape (12.61% – 14%). Shapes encountered with a relatively low frequency are ovoid (3.60%) and irregular shapes (0.90%).

The shape of the spleen visualized using ultrasonography is that of a bean or of an orange slice, as only the longitudinal and transverse axes are seen.

The spleen is an encapsulated structure and has a smooth contour. The splenic capsule appears as a fine, hyperechoic line that envelops the parenchyma of the spleen. The diaphragmatic side of the spleen is concave, while the visceral side is convex or linear, sometimes with an irregular border. The visceral side contains the splenic hilum, which contains the splenic vessels with hyperechoic walls. The ramifications of the splenic vessels, proceeding from the hilum can be visualized in the splenic parenchyma.

Texture and echogenicity (echopattern)

The echostructure of the spleen is homogenous, finer than that of the hepatic parenchyma and slightly hyperechoic, with mild-to-low echogenicity.

The consistency of the spleen correlated with different pathologies as vascular congestion or tumoral infiltration was less studied compared to the liver, and the results were inconclusive. Also the results in quantitative CEUS studies for diffuse splenomegalies had no clinical relevance.

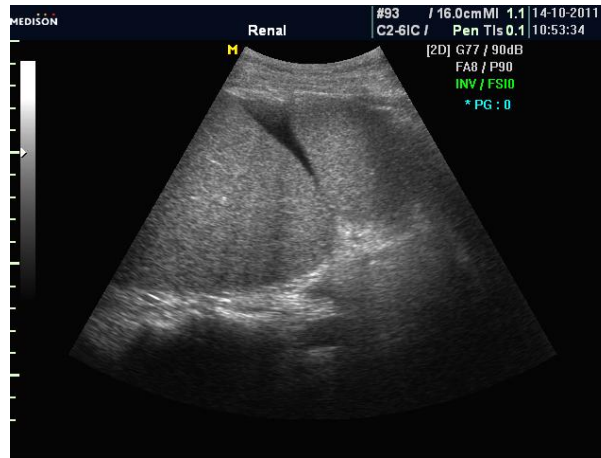
Variations in the numbers of the spleen

Accessory spleen

A supernumerary spleen (also known as splenule or splenunculus) is frequent in the general population – discovered in 10-15% of the routine ultrasonographic examinations and more than 30% discovered at the time of the autopsy. A supernumerary spleen represents normal splenic tissue, separated from the spleen. It has no pathological significance.

The spleen forms from the mesoderm during the embryonic period of development. At first it takes the shape of multiple nodules that fuse with time. A sign of the fetal lobulation that may persist during adulthood is the persistence of notches on the surface of the spleen. In the majority of cases, these notches are found on the superior border of the spleen. In some cases, the lobulated shape of the spleen may persist after birth (Figure 16).

Figure 16 Lobulation of the spleen, better seen in a cirrhotic patient with an enlarged spleen



During the fetal period of development, small masses of splenic tissue may form and detach from the programmed developmental trajectory of the spleen, thus becoming accessory spleens.

In the majority of cases, the accessory spleens are located in close contact with the splenic hilum or medially to the inferior pole of the spleen, in proximity to the tail of the pancreas (Figure 17). However, accessory spleens may be found anywhere on the programmed developmental trajectory of the spleen during the fetal period of development: adjacent to the splenic vessels, in the gastrosplenic ligament, in the splenorenal ligament, within the greater omentum, in the mesentery, in the walls of the stomach or those of the intestines. In rare cases, accessory spleens have been found intrapancreatically, in the tail of the pancreas or close to the genital organs.

The accessory spleens are rarely multiple, frequently there is just one supernumerary spleen, characterized by reduced dimensions, of about 1 cm, possibly reaching 2-3 cm.

Ultrasonographic, the accessory spleens have a rounded shape, a smooth border; the echostructure is homogenous, similar to that of the spleen. They might be mistaken for a tumour or an enlarged lymph node, especially when not situated in the proximity of the spleen. Nevertheless, on contrast enhanced imaging (CT, MRI, CEUS) the same hemodynamic profile found in the spleen is also noted in the case of accessory spleens. The preferred imaging method in the more difficult cases remains the scintigraphy using technetium-labeled, heat-damaged autologous erythrocytes.

Accessory spleens become hypertrophic after splenectomy (Figure 18).

Figure 17 Accessory spleen

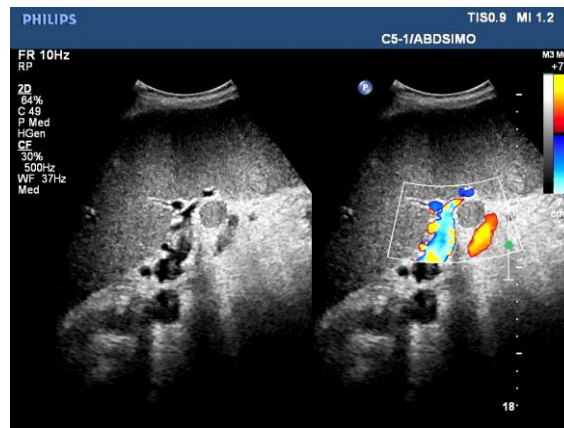
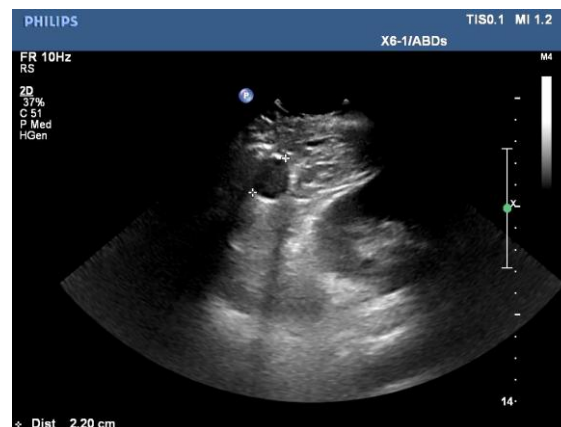

Figure 18 Moderately enlarged accessory spleen after posttraumatic splenectomy.



Asplenia and polysplenia

Asplenia and polysplenia are parts of the syndrome called visceral heterotaxia.

Asplenia is defined as the congenital absence of the spleen and is associated with inborn immunological deficits.

Polysplenia is a very rare entity, characterized by the existence of several spleens of smaller dimensions than a regular spleen. The absence of a “parent spleen” with normal dimensions is noted in this case. These small spleens are usually located on the patient's left side, but their presence has also been observed bilaterally, in some cases. Polysplenia is frequently associated with malformations of the heart, biliary atresia and the transposition of the inferior vena cava.

Polysplenia needs to be differentiated from posttraumatic splenosis (secondary to splenic rupture/ avulsion), in which parts of splenic tissue are detached from the spleen and spread through the peritoneal cavity. These small pieces of tissue grow to form small ectopic spleens. Splenosis is secondary to trauma or surgical splenectomy. A characteristic finding is that the vascular supply of the ectopic

spleens stems from local vessels, whereas in the case of accessory spleens and polysplenia, the vascular supply proceeds from the splenic artery.

The differential diagnosis with abdominal lymphadenopathies or tumours is difficult. The appearance of ectopic spleens is that of small rounded nodules with smooth borders and homogenous echostructure, similar to that of the spleen. Using contrast enhanced CT and CEUS, contrast is taken up by the ectopic spleens similarly to the original spleen, but the preferred imaging method remains a scan using technetium-labeled heat-damaged autologous erythrocytes.

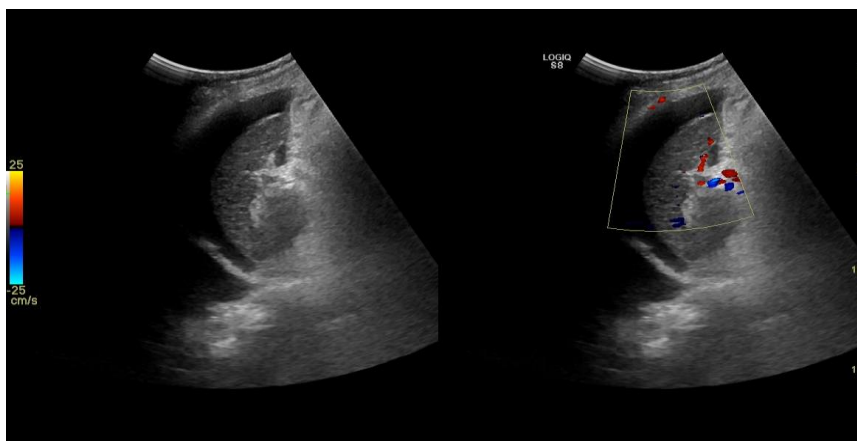
Hiposplenias

Functional asplenia is defined as the absence of normal spleen function and is currently associated with serious infection risks. Hyposplenias define the reduced ('hypo-') splenic functioning, but not as severely affected as in asplenia. Hypo and asplenia are usually consequences of splenic atrophy.

Splenic atrophy can be found in normal individuals, especially in the elderly, but also associated with different diseases, as chronic hemolytic anemia, particularly homozygous sickle-cell anemia, autoimmune diseases, inflammatory bowel diseases, after septicemia, or after bone marrow transplantation (Figure 19). On US examination the spleen become hardly recognizable, due to multiple changes in structure: infarctions, increasing fibrosis, loss of pulp, iron and calcium deposits. The contour becomes irregular, the echostructure intensely inhomogenous, hardly to be differentiated from the neighboring organs or tissues. Color Doppler demonstrates a diminished splenic vascularization while CEUS shows only a short enhancement in functional hypo- asplenia.

Hypo- or functional asplenia can be described also in a small or enlarged spleen as in sickle cell anemia.

Figure 19 Small spleen in chronic kidney disease patient. We note the inhomogeneous pattern, the thickness of the vessels walls suggesting fibrosis. Diminished colour Doppler signal in parenchyma.



VIP: Very Important (and most frequent) Pathologies, Splenic diseases

Splenomegaly

Splenomegaly is defined by increased splenic dimensions and volume. Spleen longitudinal and transverse diameters averaged over 13 cm, respectively over 5 cm are considered splenomegaly.

Besides measuring the spleen diameters, there have been studies that used the calculus of the maximum area of the spleen in order to classify the splenomegaly using ultrasound.

In a study describing portal hypertension in cirrhotic patients Gaiani defined a normal sized spleen by an area of <math><45\text{ cm}^2</math>, a moderately enlarged spleen by $45\text{-}65\text{ cm}^2$, and a marked splenomegaly by an area of $>65\text{ cm}^2$.

Splenomegaly usually occurs associated with other organs pathology and sometimes it can be the debut sign of a disease onset.

Mild-to-moderate splenomegaly (weight <math>< 1000\text{g}</math>) are usually corelated with portal hypertension or with infections, while severe splenomegaly (weight $>1000\text{ g}$) are common in hematological diseases, especially chronic leukemia and myelofibrosis.

There are many diseases associated with moderate splenomegaly, in contrast with the severe splenomegalies, that are found only in few conditions (Table 1).

Table 1. Splenomegaly associated pathologies

Increased number of RBC destruction	<ul style="list-style-type: none"> • Thalassemia, sickle cell anemia, hereditary spherocytosis, hemoglobinopathies, • nutritional anemia
Immune response of the spleen in infections (viral, bacterial, fungal, parasitic)	<ul style="list-style-type: none"> • mononucleosis, viral hepatitis, AIDS • bacterial endocarditis, bacterial septicemia • splenic abscess, typhoid fever • brucellosis, leptospirosis, tuberculosis • histoplasmosis • malaria, leishmaniasis, trypanosomiasis
Autoimmune and inflammatory diseases	<ul style="list-style-type: none"> • rheumatoid arthritis • Systemic lupus erythematosus • autoimmune hemolytic anemia • serum sickness • sarcoidosis • inflammatory pseudotumour of the spleen • drug reactions

<p>Acute or chronic congestion of spleen</p>	<ul style="list-style-type: none"> • liver cirrhosis • obstruction of hepatic veins (Budd-Chiari syndrome), • Heart failure • Portal hypertension • Cystic fibrosis • Portal or splenic vein thrombosis • Acute splenic sequestration crisis of sickle cell disease
<p>Metabolic diseases</p>	<ul style="list-style-type: none"> • Gauchers disease • Niemann–Pick disease • Hurler syndrome and other mucopolysaccharidoses • amyloidosis • Tangier disease
<p>Malignant diseases</p>	<ul style="list-style-type: none"> • Systemic neoplastic diseases: leukemias, lymphomas (Hodgkin and Non-Hodgkin disease), • myeloproliferative disorders: primary myelofibrosis, chronic myelogenous leukemia, chronic myelomonocytic leukemia; • polycitemia vera • metastatic tumors (commonly melanoma), • spindle-cell sarcomas, • histiocytosis X
<p>Benign tumours</p>	<ul style="list-style-type: none"> • Littoral cell angioma, hemangioma, lymphangioma,

The causes of massive splenomegaly (spleen weight >1000 g) are:

- mainly: myelofibrosis and chronic myelogenous leukemia
- visceral leishmaniasis (kala-azar)
- malaria
- very rare: primary lymphoma of spleen

Splenomegaly can be due to the presence of one or more intrasplenic nodular masses, or diffuse, usually homogenous.

Diffuse splenomegaly

Diffuse splenomegalies generally do not have a characteristic ultrasonographic appearance for a particular condition, except for portal hypertension.

In diffuse splenomegalies, the splenic ultrasound-defined structure is homogenous, rarely appears unspecifically inhomogenous and the splenic contour can be regular or slightly irregular. Splenic surface must be examined systematically in order to notice any areas of infarction or trauma, or the presence of splenic infiltrations in haematological diseases (Figure 20, Figure 21, Figure 22, Figure 23). In these cases it is recommended to use of the high frequency linear probe, with high resolution, allowing detailed examination of the superficial area of the spleen.

Figure 20 Mild splenomegaly in Child A Cirrhosis

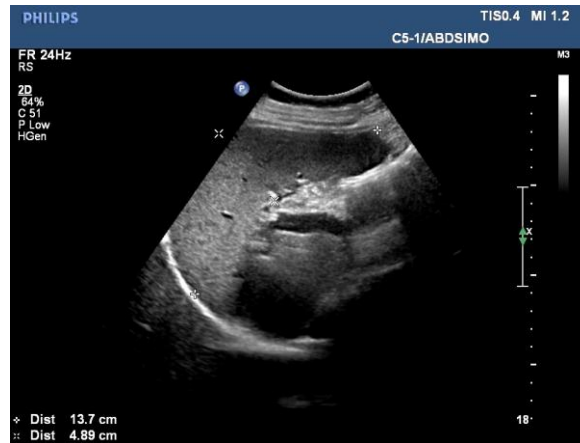

Figure 21 Massive splenomegaly in VHC cirrhotic patient with long history of disease. We note the mild irregular contour and inhomogeneous echostructure with diffuse hyperechoic foci suggesting small infarctions

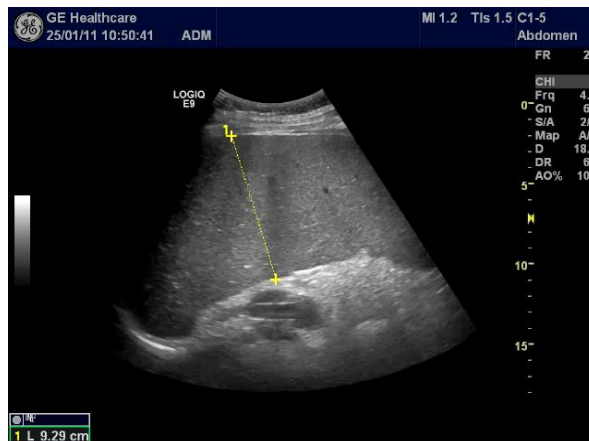

Figure 22 Same case, important dilation of splenic vein

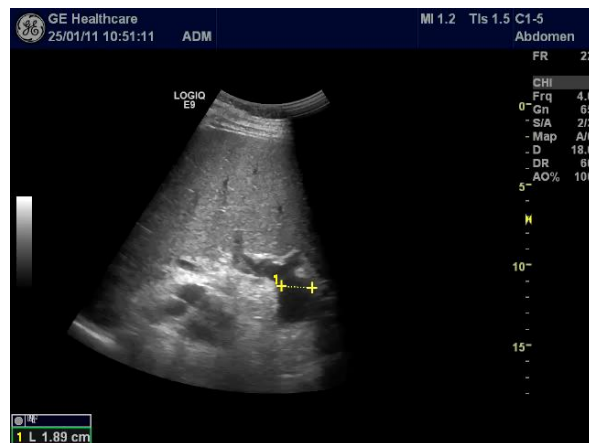
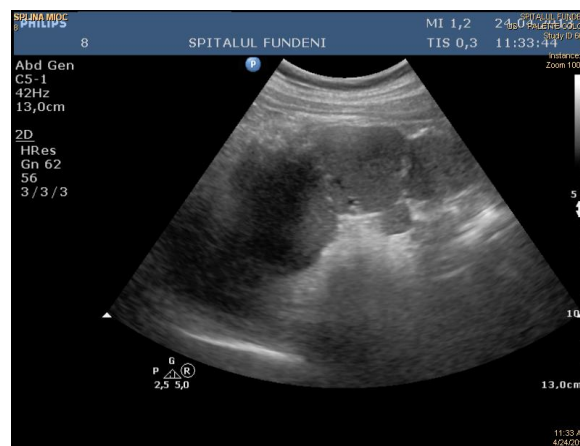


Figure 23 Moderate splenomegaly with multiple infarctions and accessory spleen in VHB cirrhotic patient



Although the main pathological mechanism of splenomegaly in cirrhosis is considered the splenic congestion due to portal hypertension, recent studies show that an important component is represented by the tissue hyperplasia. The same study shows a weak correlation between spleen size and portal vascular resistance underlining the fact that in cirrhosis portal hypertension is not the main etiological factor of splenomegaly. Also, no relationship has been reported between spleen size and portal pressure or the degree of oesophageal varices. There were no differences in the level of portal pressure between cirrhotic patients with or without splenomegaly or a relationship between portal pressure and spleen size reported in the same study. These data are confirmed by the observation that in cirrhosis the diameter of the portal vein begins to increase later than the length of spleen and the diameter of the splenic vein.

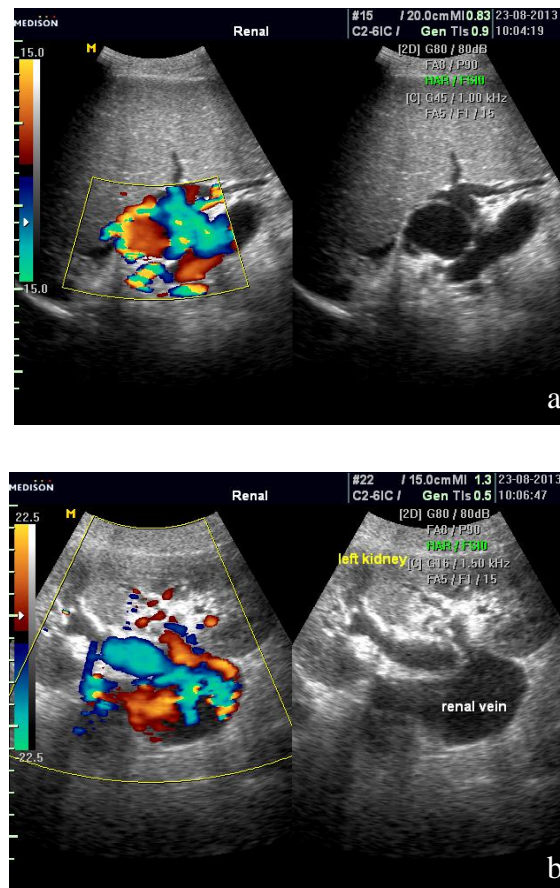
Therefore, in cirrhosis, the splenic vascular structure does not seem substantially modified from the hemodynamic point of view.

Spleen ultrasound examination is mandatory in hepatic cirrhosis evaluation and to appreciate the presence of portal hypertension. It is a systematic evaluation that is performed both at the moment of diagnosis and periodically, to assess the evolution of liver cirrhosis and the presence of complications.

The complete ultrasound examination of the spleen in hepatic cirrhosis includes 2D standard examination and colour and pulsed Doppler examination.

2D ultrasound of the spleen should bring the following information: spleen size (enlargement), splenic vein diameter – to appreciate the dilation of the splenic vein (> 9 mm), the presence of the venous dilations in the splenic hilum and porto-systemic venous collaterals by adding colour Doppler examination (Figure 24 a, b).

Figure 24 Spleno-renal shunt. Dilated splenic vein in the hilum (a) and important dilation of renal vein (b)



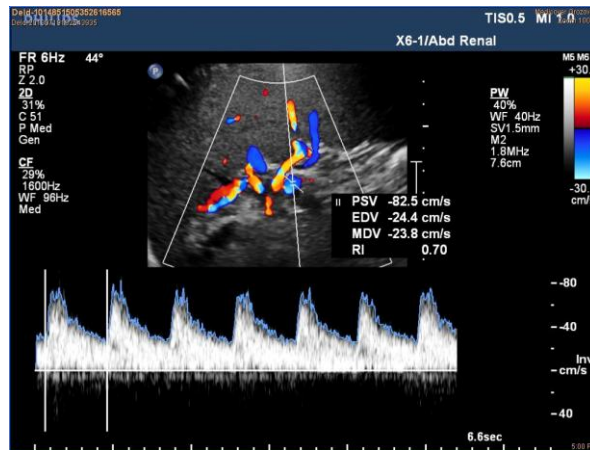
Pulsed Doppler brings information to assess the evaluation of the degree of portal hypertension. Doppler changes occur in the context of clinically significant portal hypertension, which supports the study data presented above. These are: the reduction of splenic vein respiratory variations, alongside with portal vein and superior mesenteric vein, reduction of flow velocity and flow direction reversal in splenic vein. So, stiffness (absence of respiratory variations) of splenic or superior mesenteric veins is highly suggestive of portal hypertension.

Increase in splenic artery impedance indexes is highly suggestive for clinically significant portal hypertension in patients with cirrhosis (Figure 25).

Intraparenchymal Doppler impedance (RI and PI) of the splenic artery is measured in a main splenic branch, close (approximately 1 cm) to the place where it enters the parenchyma.

There have been studies that have assessed the values of RI and PI on normal subjects and on patients with different degrees of portal hypertension and the results are: normal subjects, 0.51 ± 0.05 and 0.72 ± 0.11 ; cirrhotic patients with hepatopetal portal blood flow ($n = 167$), 0.64 ± 0.08 and 1.03 ± 0.24 ; cirrhotic patients with hepatofugal portal flow ($n = 3$), 0.74 ± 0.08 and 1.27 ± 0.08 ; cirrhotic patients with portal vein thrombosis ($n = 9$), 0.74 ± 0.08 and 1.36 ± 0.34 .

Figure 25 Moderately increased RI in mild portal hypertension



In addition to the data provided by the standard and Doppler ultrasound examination, different studies have attempted to measure the degree of splenic fibrosis or tumour infiltration by analyzing different ultrasound signal parameters as speed or attenuation, but the results were inconclusive.

Quantitative studies are also performed on CEUS enhancement, and the results were also inconclusive.

On CEUS examination changes in enhancement of the splenic parenchyma are neither constant nor specific. In some cases with marked splenomegaly a slightly delayed global enhancement can be observed, with a less intense opacification of splenic parenchyma and a more prolonged early-phase inhomogeneity.

There are some clinical situations when splenomegalies have particular aspects.

In hematological diseases we note sickle cell disease where splenomegaly present different sonographic appearances depending upon its disease stage: in acute sickle cell crisis, commonly in children we can see splenomegaly and subacute hemorrhage that appears as a hypoechoic area in the periphery of the spleen.

In time, the spleen shrinks due to multiple progressive infarctions and fibrosis, called auto-splenectomy.

In polycitemia vera the spleen appears variably enlarged with infarction areas and thrombosis.

Thalassemia, depending on its degree, is associated to homogeneous splenomegaly which can be huge in major thalassemia, and seems to fill the entire abdomen cavity.

From storage diseases we mention amyloidosis. The spleen is the most frequently involved organ and may be of normal size, but generally enlarged, depending on the amount and distribution of amyloid. There are two types of involvement: nodular and diffuse.

In the nodular involvement type the amyloid is found in the walls of sheathed arteries and within the follicles. The red pulp is not involved.

In the diffuse involvement type the follicles are not involved and amyloid is stored into the red pulp. Severe and moderate splenomegalies are found in this type.

In Gaucher's disease diffuse inhomogeneous splenomegaly and multiple splenic nodules are described. The nodules usually are hypoechoic, well defined lesions, but can be also irregular, hyperechoic or mixed. They represent areas of Gaucher's cells associated with fibrosis and infarction.

Splenic abscesses

It is important to know that in the course of infectious pathology of the spleen, we can meet both types of spleen injury, focal and diffuse. Usually a homogenous, mild to moderate splenomegaly is found. In case of severe infections of other organs that disseminate in the spleen (endocarditis, acute supra-infected pancreatitis, postoperative infection complications) occurring mainly in immunosuppressed patients, splenic abscesses can be found. The frequency of splenic abscesses is low, cited in literature as 0.14-0.17% cases discovered at autopsy.

A splenic abscess has a variable ultrasound appearance, hypo or hyperechoic nodule. Large abscesses, usually unique, rarely multiple, are characteristic for microbial infection, and a wedge-shaped abscess may typically be seen in patients with infective endocarditis and associated septic embolism.

Usually they appear with well-defined contour but with an irregular wall, multilocular, with inhomogeneous, complex echostructure, most often hypoechoic. It may present debris, septa or gas (characteristic for anaerobic infections) and posterior enhancement, and usually are avascular on colour Doppler ultrasound.

Splenic phlegmons differentiate by abscesses with a poorly defined border compared with the rest of the splenic parenchyma (Figure 26).

Fungal abscesses, that are present in HIV and other immunosuppressive disorders are caused by *Mycobacterium tuberculosis*, atypical mycobacteria, *Pneumocystis carinii* and candidiasis and shows a characteristic appearance of multiple small lesions with hyperechoic center and hypoechoic rim, the typical "bull's eye" appearance. The use of a high-frequency linear probe will enhance the detection of micro-abscesses.

Sometimes the ultrasound cannot distinguish between splenic abscesses and tumours only using standard and Doppler examination (Figure 27). In these cases the contribution of CEUS examination is very important to set the final diagnosis. The CEUS aspect of splenic abscess does not differ from that of hepatic abscesses. Intraparenchymal abscess are described as slightly or clearly hypoechoic, especially on late-phase images and may show peripheral enhancing rim and enhancing septa.

Typically, no sign of contrast microcirculation is seen within the internal fluid, debris, and necrotic components (Figure 28).

Subcapsular and perisplenic abscesses are described as anechoic collections with enhancing borders.

Figure 26 Giant splenic phlegmon in young female patient with suspected pancreatitis as onset point. We note extended inhomogeneous area inside the spleen, ill-defined diaphragmatic splenic contour with hypoechoic area under splenic capsule. The inhomogeneous area also appears ill-defined. We note the presence of perisplenic fluid. Highly suspicion capsular infarction. CEUS examination revealed a large nonenhancing area inside the spleen.

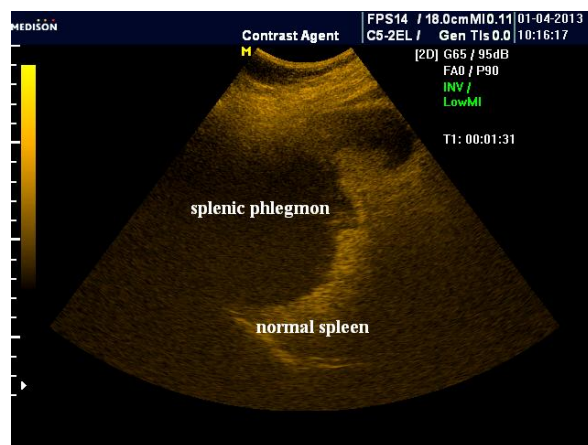
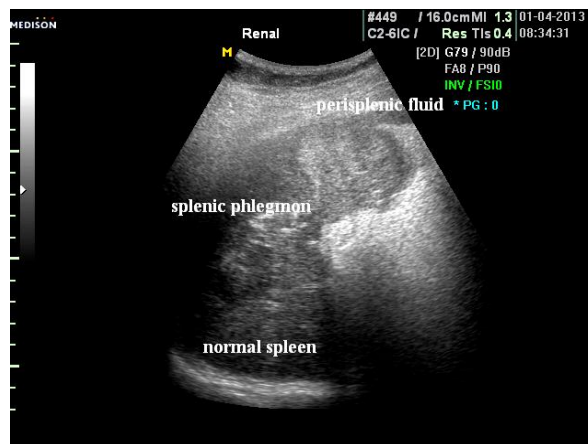
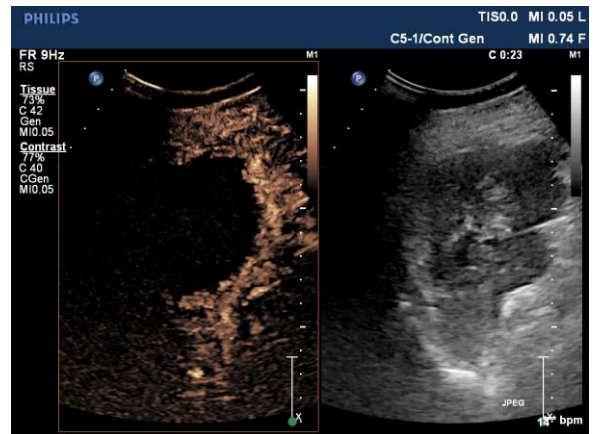


Figure 27 Same case after drainage of free fluid and conservatory treatment of splenic abscess. One can see deformed spleen, with irregular shape and inhomogeneous, apparently encapsulated mass inside. No colour Doppler signal inside the mass. B-mode and colour Doppler examinations cannot reliably differentiate between remaining abscess and a tumour.

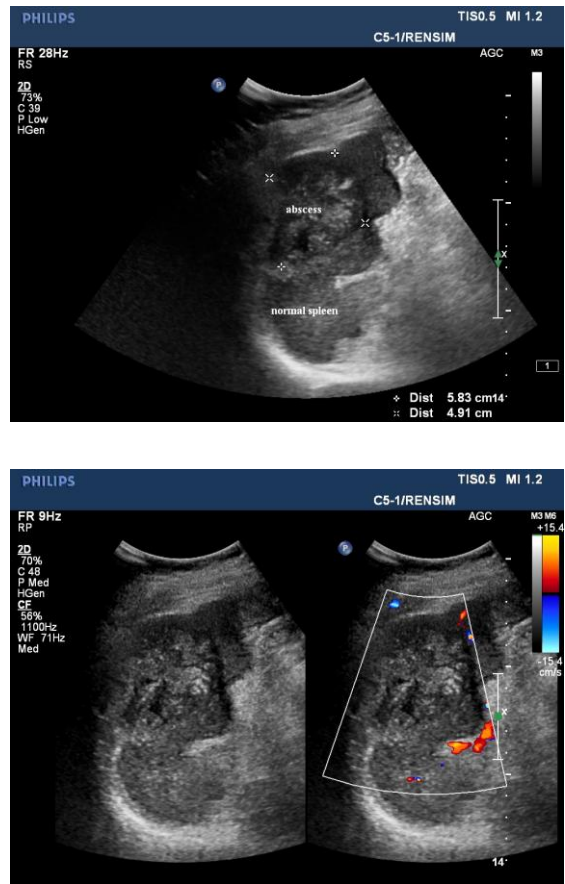

Figure 28 CEUS examination reveals the non-enhancement of the splenic mass, proving the encapsulated remaining abscess.



Splenic hydatid cyst

The frequency of splenic hydatid cyst is very rare (less than 2% of all hidatydosis localizations) and generally appears by haematogenous dissemination of a hepatic hydatid cyst and not as a primary localization of the disease. Therefore, when a splenic hydatid cyst is suspected, also another possible localization should be sought (peritoneal, hepatic). The evolution of the ultrasonographic aspect does not differ

from that of the hepatic hydatid cyst, and on CEUS examination it appears non-enhanced (Figure 29, Figure 30).

Figure 29 Old hidatid cyst, known history of hydatidosis. B-mode and Colour Doppler examination cannot reliably differentiate between cyst and tumour mass. However, one can see a fine capsule and the absence of Doppler signal inside the lesion.

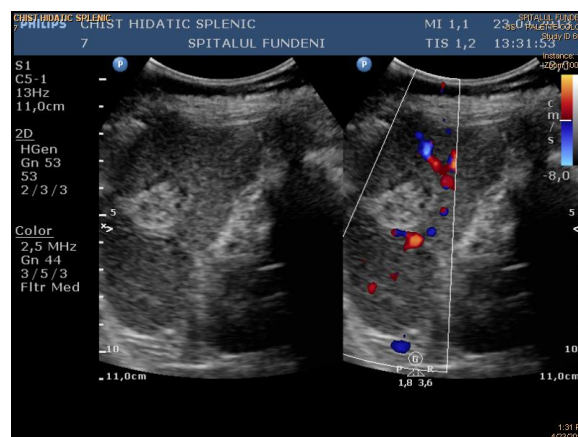
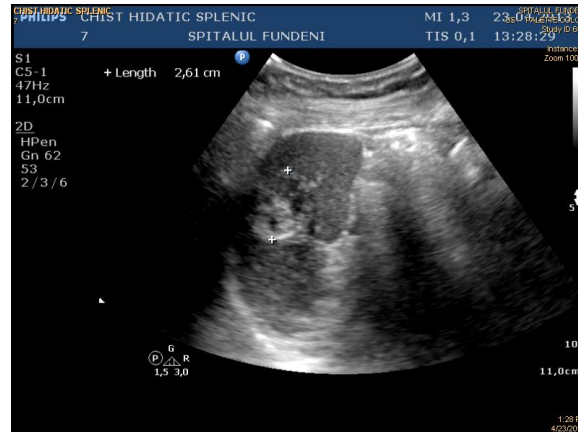
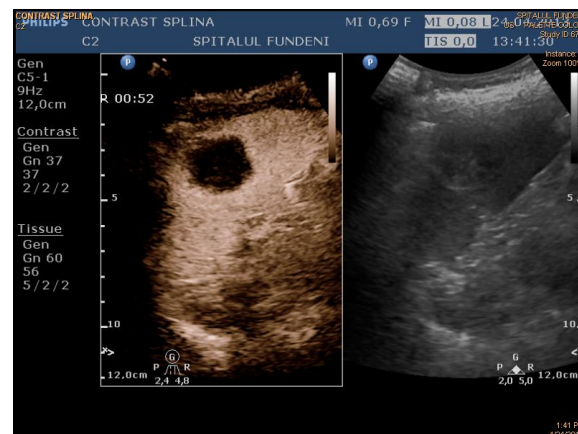


Figure 30 Same case, CEUS examination shows non-enhancement, proving the cystic nature of the lesion



Focal splenic lesions

It is a known fact that the focal splenic pathology is rare. The most recently published study, June 2010 by Neesse et al., extended over 6 years (between 2004 and 2009), with a total of 50,000 abdominal ultrasounds, only 279 (less than 0.6%) focal splenic lesions were reported.

The 279 patients ($\approx 0.6\%$) with focal splenic lesions were diagnosed on B-mode ultrasound as follows: 72 cases (25.8%) splenic infarction, 57 cases (20%) Non-Hodgkin's Lymphoma, 51 cases (18.4%) splenic incidentaloma (incidentaloma defined as incidentally detected focal splenic lesion, without patient's history of tumour, infection or trauma, lesion stable on follow-up examination), 35 cases (12.6%) splenic rupture, 7 cases (2.5%) splenic abscess, 25 cases (9.1%) miscellaneous splenic lesions (i.e., hemangioma, hamartoma), and 32 cases (11.5%) splenic metastases of solid tumours.

Focal splenic lesions can be single or multiple, benign or malignant, and can occur on normal or enlarged spleen.

Ultrasound is a proven procedure for detecting focal splenic lesions, but their characterization is difficult, the ultrasound pattern often being uncharacteristic for different pathologies. The low lesions number and the difficulty to obtaining a histological document, makes their analysis harder. Their diagnosis is often based only on CE-CT and/or CE-MRI and clinical follow-up, the spleen biopsy not being an option due to the increased bleeding risk.

Benign splenic lesions

Splenic cystic lesions

Splenic cystic lesions can be congenital (true epidermoid or false posttraumatic cysts) – characterized by the presence of an inner endothelial lining or posttraumatic cysts (pseudocysts) which do not have cellular lining.

Congenital cysts include lymphangiomas and, very rarely, cystic hemangiomas.

Ultrasound cannot make reliable differentiation between true cysts and pseudocysts. The cysts usually appear as transonic areas, well delineated, with sharp contour and posterior enhancement. They can have calcified walls and may contain cholesterol crystals or debris that appears as low-level echoes inside. When they bleed, the cysts appear partially or totally filled with fine, mobile echoes when the patient's position is changed, or their content appears highly inhomogeneous, difficult to be differentiated from a tumour lesion. Usually the ultrasound pattern on B-mode ultrasound and the lack of Doppler signal are sufficient for cysts diagnosis, further investigations not being necessary (Figure 31, Figure 32). But there are complex cysts, where the CEUS examination proves the non-enhancement of the cyst and further investigations are not necessary (Figure 33, Figure 34).

Figure 31 Simple splenic cysts, incidental findings

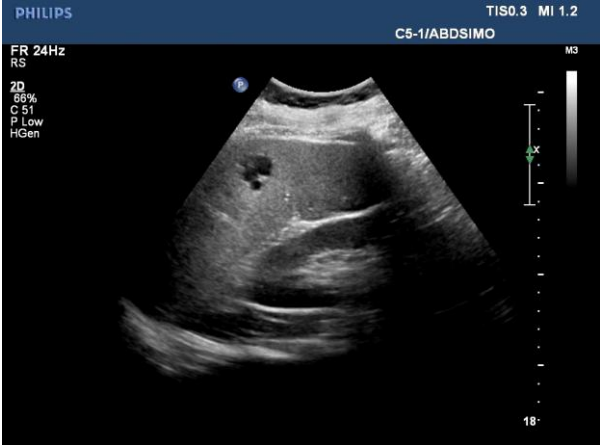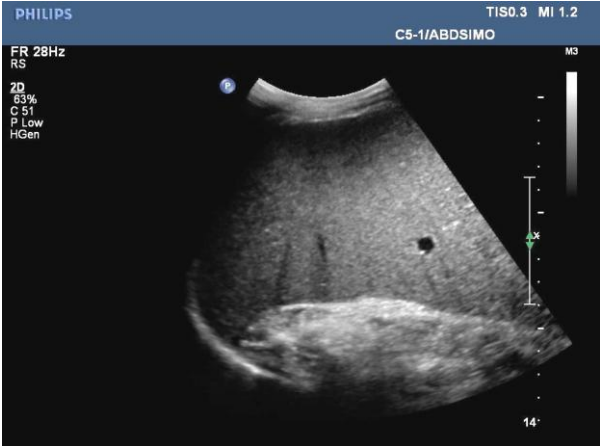
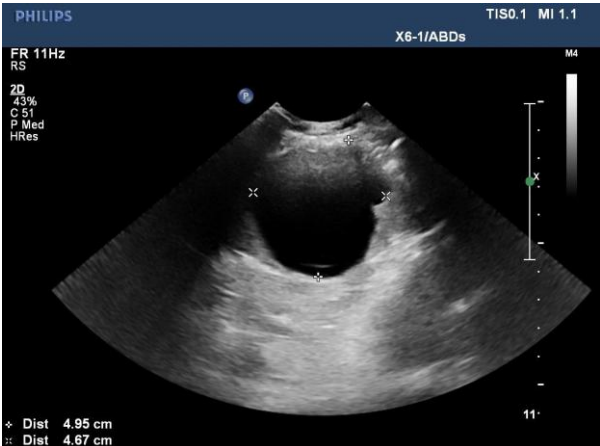
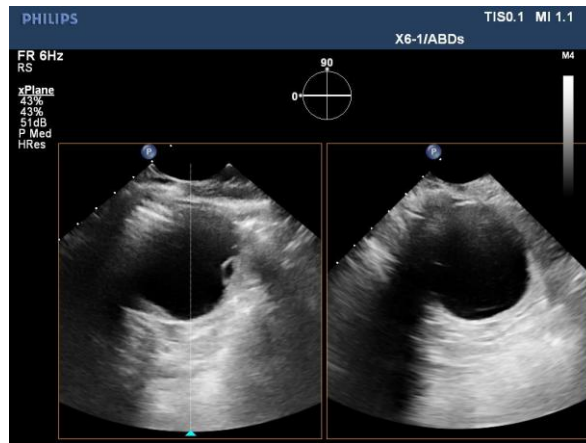


Figure 32 Splenic cyst, incidental finding. X-plane examination shows irregular internal contour of the wall. Suspicion of hydatid cyst, not confirmed





In addition to splenic cysts there is a spectrum of lesions that have a predominantly cystic appearance at imaging. Cystic splenic masses may be inflammatory (abscesses, hydatid cyst), vascular (infarction, peliosis), posttraumatic (hematoma, false cyst), or tumoral (benign: hemangioma, lymphangioma, or malignant: lymphoma, metastasis).

Figure 33 Multiple, multiloculated cysts, incidental findings

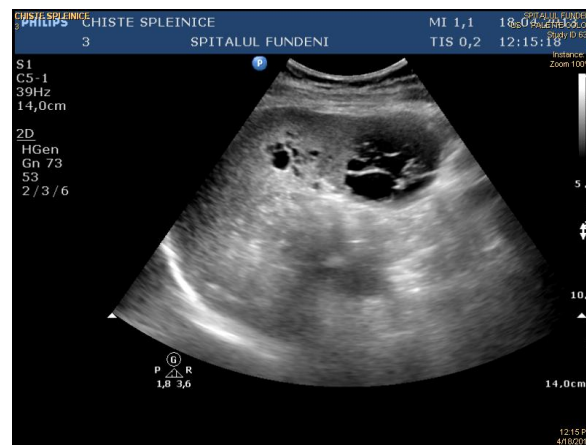
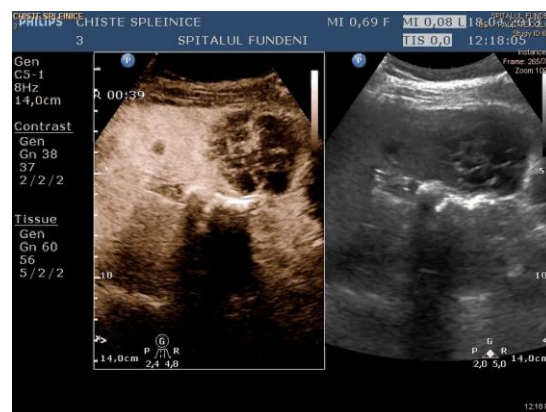
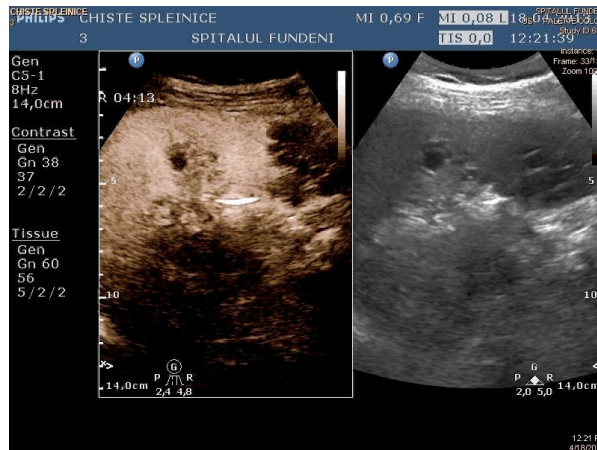


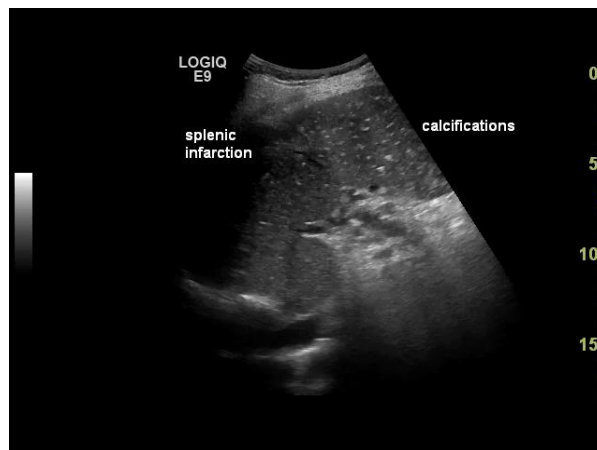
Figure 34 Same case, CEUS exploration shows hyperenhancement of septa and hypoenhancement of the pericystic area. Hydatid disease not confirmed. CT scan was performed, concluding splenic infarctions.





Parenchymal calcifications are quite common, non-specific, incidental findings, of different sizes. They could be secondary to splenic infarction, granulomas, tuberculosis or metastases (Figure 35).

Figure 35 Multiple tiny splenic calcifications and splenic infarction in systemic lupus eritematosus patient with long history of disease.



Solid splenic lesions

The solid splenic lesions have a different pattern in B-mode ultrasound, hyper-, iso- or hypo-echoic than the surrounding normal tissue.

Benign primary tumours of spleen are rare and include hamartoma, hemangioma and cystic lymphangioma.

Splenic hemangiomas have been reported in up to 14% of autopsy studies. They can be found isolated or may occur in the Klippel-Trenaunay-Weber syndrome. There is no ultrasound specific pattern for hemangiomas. The majority are hyperechoic homogeneous lesions, with precise contour, measuring less than 2 cm. On CEUS examination, hemangiomas are filled with homogenous contrast with respect to the rest of the parenchyma. A splenic hyperechoic lesion on baseline images that becomes undetectable on CEUS is considered hemangioma (Figure 36, Figure 37).

Figure 36 Splenic hemangioma. Small, unspecified lesion on B-mode examination, no colour Doppler signal inside.

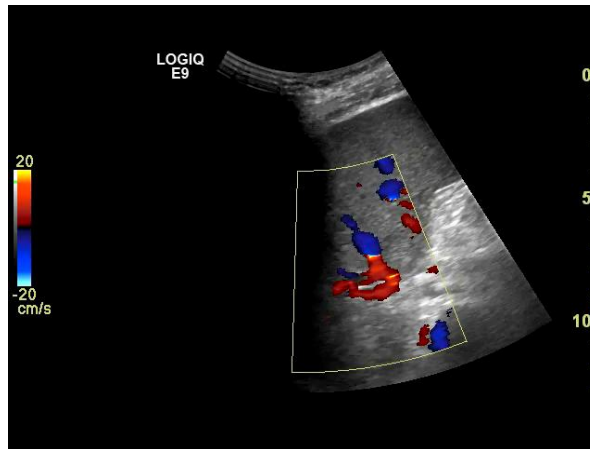
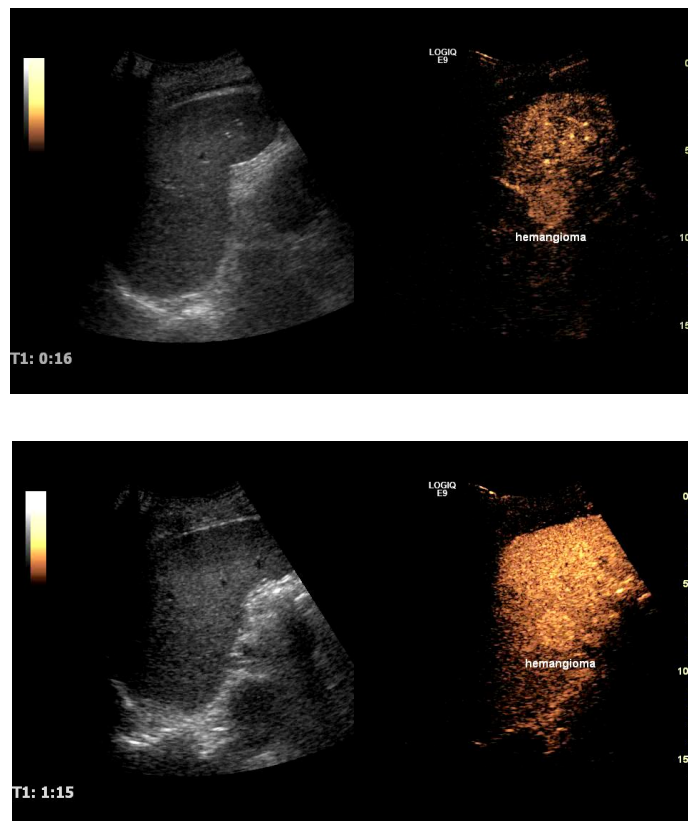


Figure 37 Same case. CEUS proves a rapid hyperechoic lesion on arterial phase, isoechoic and homogeneous on parenchymal phase. CE-CT scan confirm hemangioma.



Larger, cavernous hemangiomas (> 3 cm) may appear iso- to hypoechoic with cystic changes or calcifications. They show a greater enhancement degree, with rapid or slow opacification. Filling-in can be centripetal or diffuse. Contrast enhancement is very pronounced and prolonged, with a possible shadowing in larger hemangiomas.

In a minority of cases hemangiomas are quickly enhanced with a centripetal direction of enhancement

On ultrasound examination, hamartoma has both solid and cystic components, and generally appears hyperechoic.

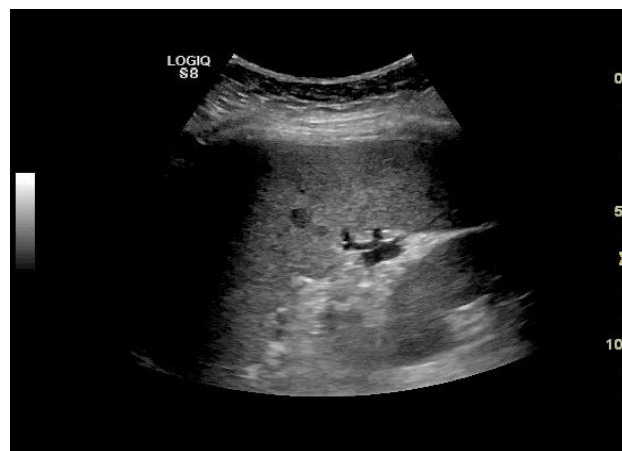Ultrasonographic appearance of lymphangioma is as a multicystic mass replacing splenic parenchyma.

Usually, benign splenic lesions are mostly hyperechoic. Lesions that do not wash out or only a little can be regarded as benign. The most common causes are previous granulomatous infections, as histoplasmosis, tuberculosis or sarcoidosis and we encountered similar aspects in LES cases, much less studied or quoted in the literature. Usually multiple hyperechoic small lesions can be seen diffusely throughout the spleen and can be associated with calcifications in the splenic artery.

But in active, millitary tuberculosis multiple small hypoechoic splenic lesions or small cystic lesions can be seen, representing tuberculous abscesses. On CEUS examination, the lesions appear hypoechoic, with progressive hypoenhancement in parenchymal phase.

In sarcoidosis B-mode ultrasound allows the evidence of splenomegaly in more than 50% of cases, whereas clinical examination reveals only a small percentage of cases. The ultrasound exploration in sarcoidosis may reveal multiple echo-poor round shaped infiltrations that on CEUS progressively wash out like malignant tumours. The same aspect has been found in LES debut with multiple systemic determinations including splenic (Figure 38). In granulomas of the spleen no specific finding on B-mode or CEUS can be seen (Figure 39).

Figure 38 Small rounded hypoechoic lesions in LES patient at onset of disease. CEUS examination improves the detection of the lesions. On CEUS examination the lesions appears hypoechoic, with intense wash-out on parenchymal phase.



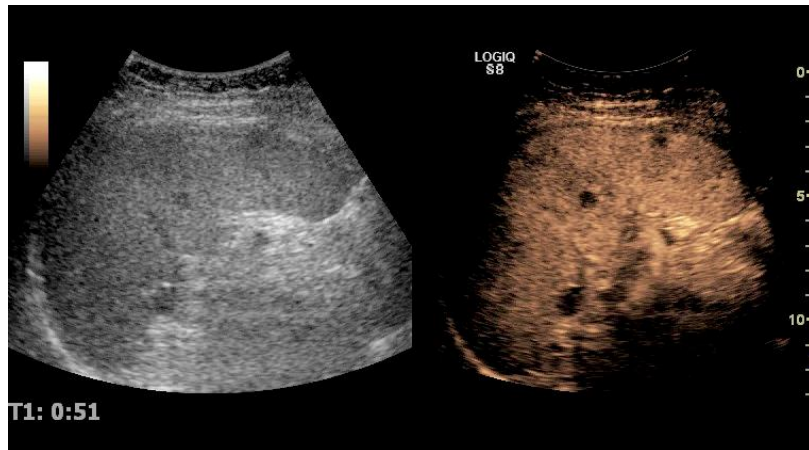
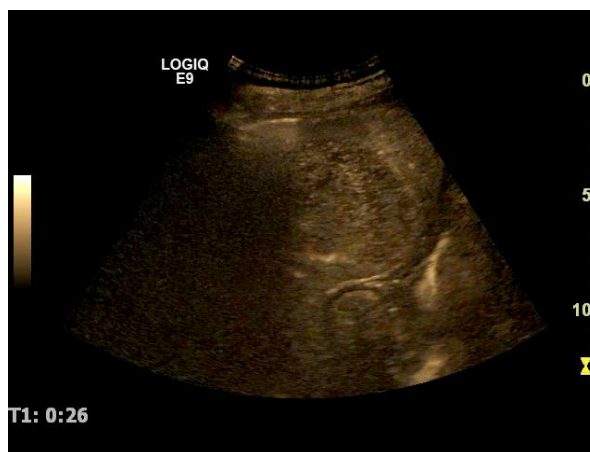
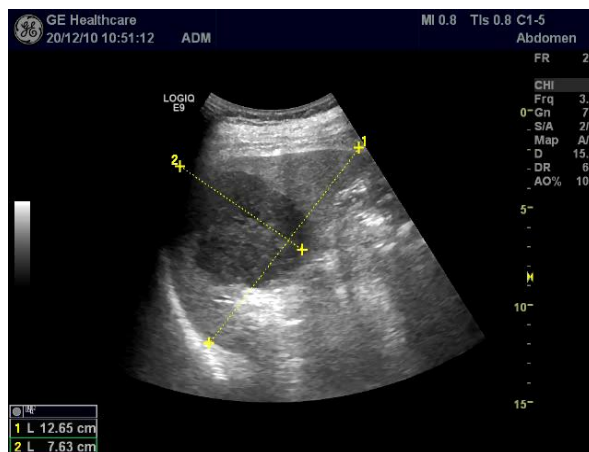
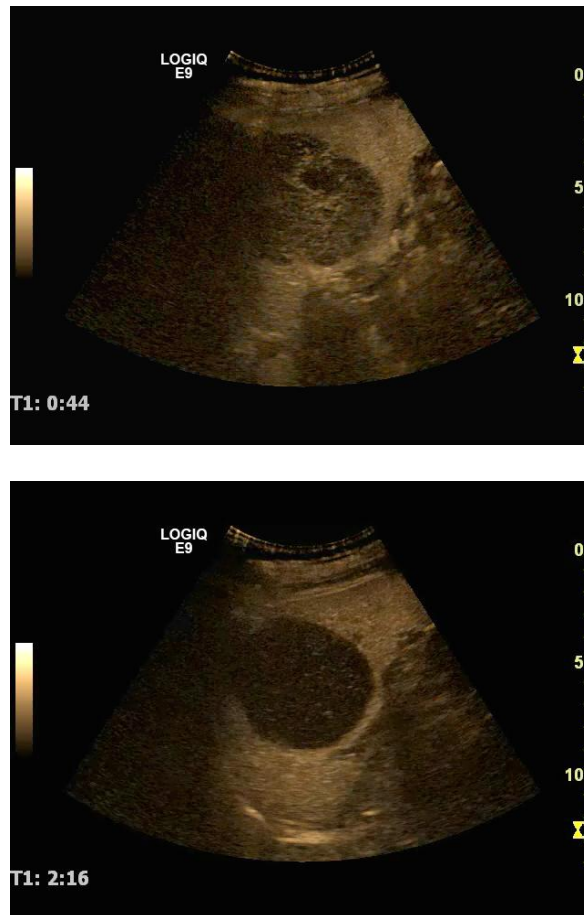


Figure 39 Unique hypoechoic inhomogenous 6,5 cm splenic lesion, incidental finding (a). Diffuse arterial enhancement, isoenhancing, with anechoic areas inside (b). Early wash-out and marked venous progressive wash-out, suggesting malignant lesion (c,d). Histological examination after splenectomy diagnosed rare non-specific inflammatory granuloma.





Malignant splenic lesions

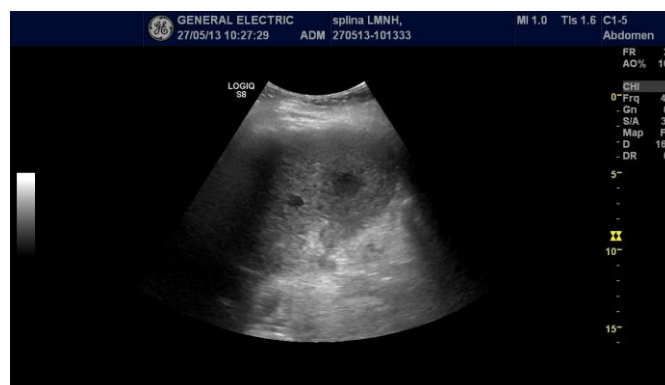
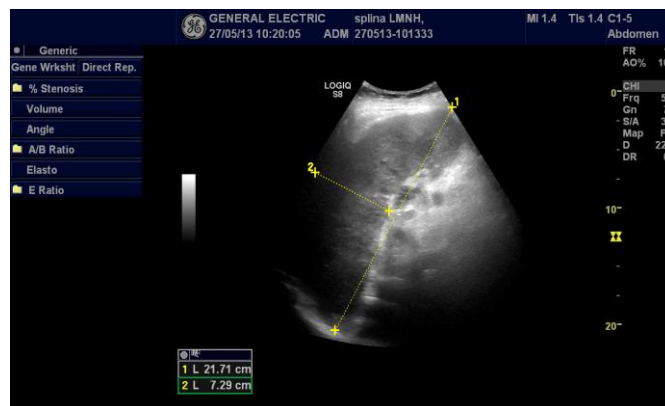
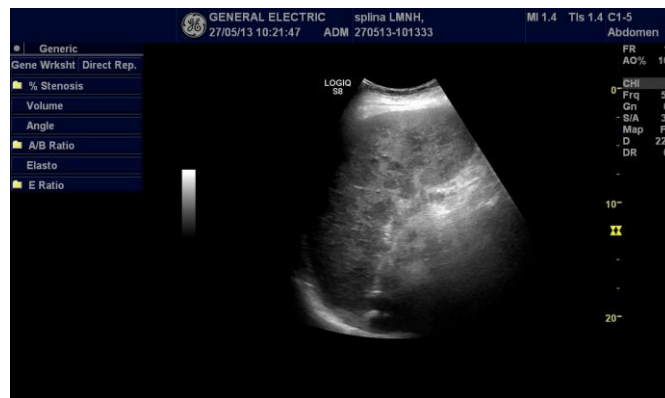
Lymphomas

Splenic involvement in Hodgkin or Non-Hodgkin disease is the most common cause of focal splenic lesions. The detection of splenic involvement is very important for clinicians, as it might change the therapeutic approach. Different studies show that the spleen is involved in less than 25% of the cases. Therefore, Görg published a retrospective study in 2009 and found that in 41 out of 250 cases with a variety of lymphatic diseases had involvement of the spleen, and another study shows the spleen involvement in 101 cases out of 680. The data on CEUS contribution improving the splenic lesions detection in lymphomas is contradictory, Görg showing in a 250 patients study that CEUS examination is not superior to B-mode imaging in splenic focal lesions detection, while Picardi found in a study with 100 patients with Hodgkin disease that CEUS was the most sensitive imaging modality to detect splenic involvement and was superior to CT and FDG PET.

On ultrasound, there are 4 types of splenic involvement in lymphomas: diffuse, with small focal lesions below 1cm in size, with large focal lesions and bulky disease. The diffuse involvement and the small focal lesions are frequently in LH and in low-differentiated lymphomas. This is why the tiny lesions can be best detected by using high frequency linear probes.

The focal splenic lesions are described as hypoechoic and mostly hypo-enhancing on CEUS, a small number being iso-enhancing during the arterial phase, but washing out in parenchymal phase. The small lesions in NHL might be overlooked even on CEUS as its microvasculature does not differ from the non-infiltrated tissue. In other cases the lesions are hypo-vascularized even during the wash in phase and may completely wash out over time (Figure 40, Figure 41, Figure 42).

Figure 40 Infiltrated spleen in Non-Hodgkin’s Lymphoma. Marked, inhomogeneous splenomegaly, one can see multiple confluent hypoechoic lesions.



Leukemias

The splenic involvement in leukemias can be homogeneous diffuse or focal.

Figure 41 Diffuse homogeneous splenomegaly in patient with acute leukemia. Convex and linear probe examination

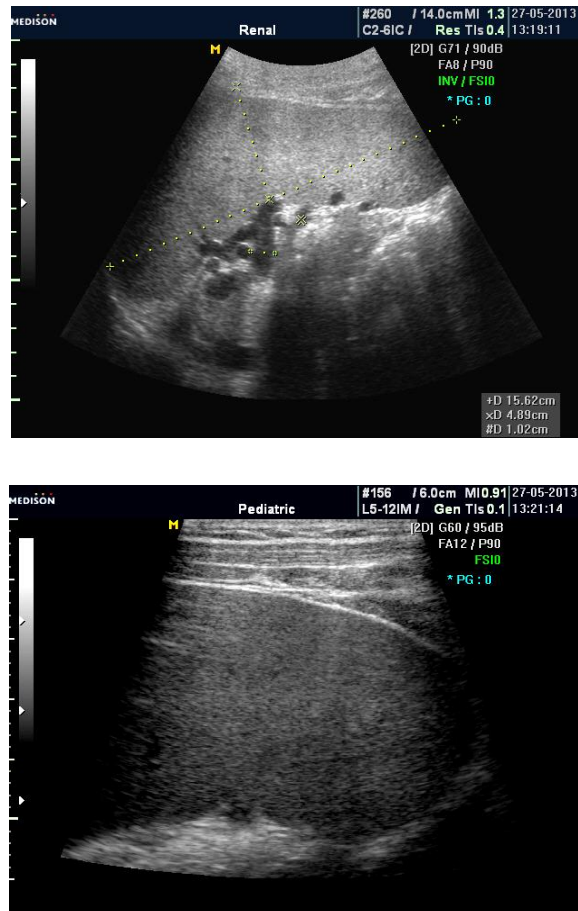
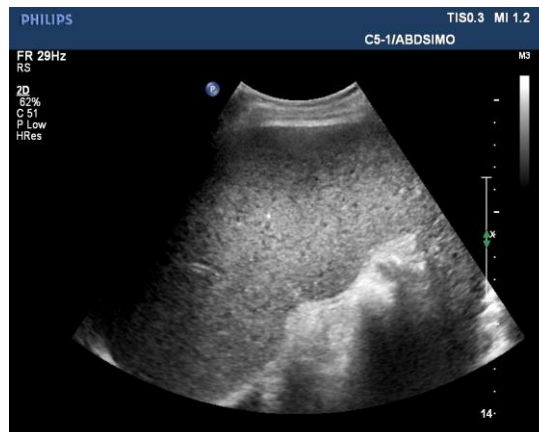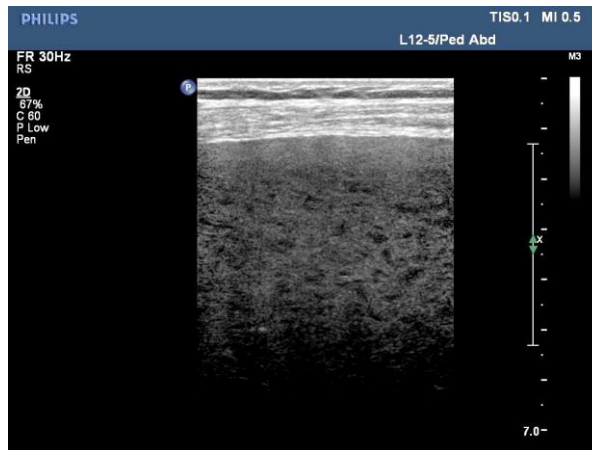


Figure 42 Chronic granulocytic leukemia. Inhomogeneous splenomegaly. The linear probe exploration reveals multiple small, rounded, hypoechoic lesions distributed in the entire spleen.





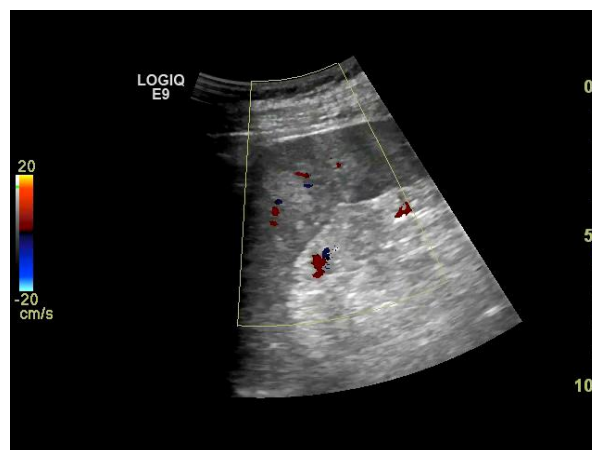Primary neoplasm of the spleen like hemangiosarcomas is very rare.

Metastases

Splenic metastases are mostly seen in far advanced malignant diseases, except in patients with testicular germ cell tumors, and small cell lung cancer in which the spleen might be the only abdominal organ showing a metastatic spread. Mostly splenic metastases have a hypoechoic appearance. But echogenicity alone is not a reliable sign for the lesion's character. Patients with testicular germ cell tumours (4 from 9 patients had splenic metastasis), malignant melanoma (9 from 27 had spleen metastasis), and small cell lung cancer (8 out of 106 had spleen metastasis) have the highest frequency of splenic involvement.

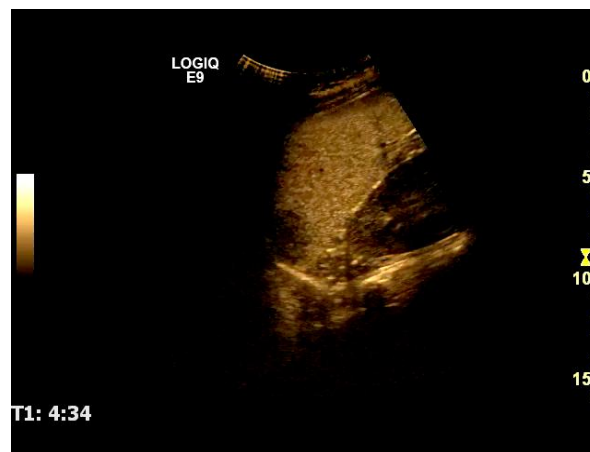
In the majority of cases a biopsy is not needed, clinical context being clear, its proof or non-proof will not change the clinical management of these patients. Metastases are mostly hypoechoic with no or only little tumour vasculature on colour Doppler imaging. On CEUS the lesions are hypo-enhancing and quickly washed out (Figure 43, Figure 44).

Figure 43 Splenic metastases in known hepatocellular carcinoma



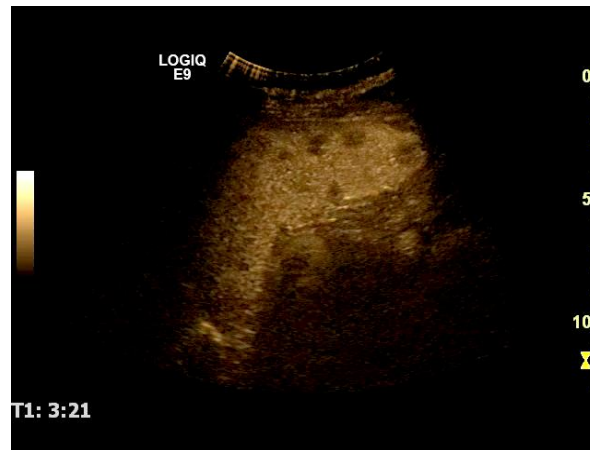

Figure 44 Splenic metastases in very aggressive, low-differentiation carcinoma, unknown primary affected organ.



Vascular disease

Infarction of the spleen is considered the most common cause of focal splenic lesions. The study published by Neesse et al. reported a frequency of 25.8% splenic infarctions detected from all focal splenic lesions. They are caused by the embolic occlusion of the branches of the splenic artery or even of the splenic arterial trunk (thromboembolic diseases, septic distance embolism) or local thrombosis in cases of acute pancreatitis, hematological disorders (sickle cell anemia, leukemia, lymphomatous disorders) or other diseases (sarcoidosis, systemic lupus erythematosus, polyarteritis nodosa).

The ultrasound aspect differs according to the time elapsed from the initial moment (the occurrence of the infarction) and the sizes of the infarction area. Often, in the first 24 hours the splenic infarction, especially the small sized one, can escape the ultrasound examination, appearing only as an unhomogenous area, ill-defined in the splenic parenchima. After 24 hours the splenic infarction appears hypoechoic, with borders not always well delineated, and dimensions generally underestimated. In

time, due to fibrosis, splenic infarction appears hyperechoic, triangular shaped (wedge-shape) with the base always orientated to the splenic capsule and with capsular retraction. Sometimes the appearance can be nodular. Due to fibrosis, their dimensions decrease over time. They can keep the triangular aspect or they can produce linear scars, form calcifications or they can turn into pseudocysts. Sometimes they can mimic a tumoral mass.

On colour Doppler examination infarction areas do not present vascular signals. CEUS examination brings an important diagnostic contribution; the splenic infarct does not capture the contrast substance, thus allowing the differential diagnosis with a splenic tumour. It also enables the correct assessment of its extension.

Sometimes the CEUS examination on arterial phase may reveal an abruptly interrupted enhanced artery in relation to the infarct apex, these representing the obstructed arterial branch (Figure 45, Figure 46, Figure 47).

Figure 45 Two cases of old splenic infarctions. Periferic hyperechoic “wedge-shaped” areas

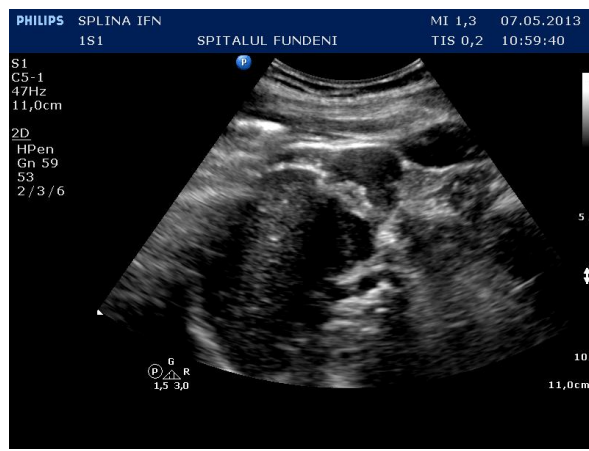
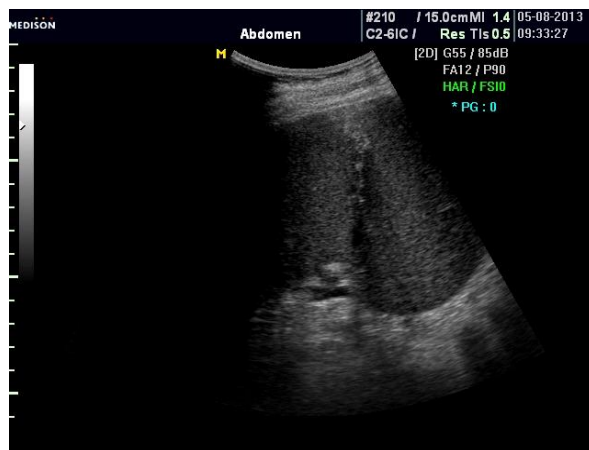
Figure 46 Splenic infarction, CEUS examination. B-mode shows only an inhomogeneous area, while CEUS demonstrates splenic infarction showing non-enhancing peripheral area.

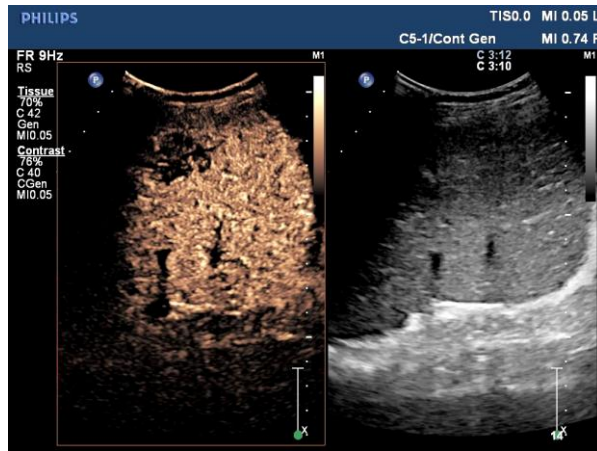
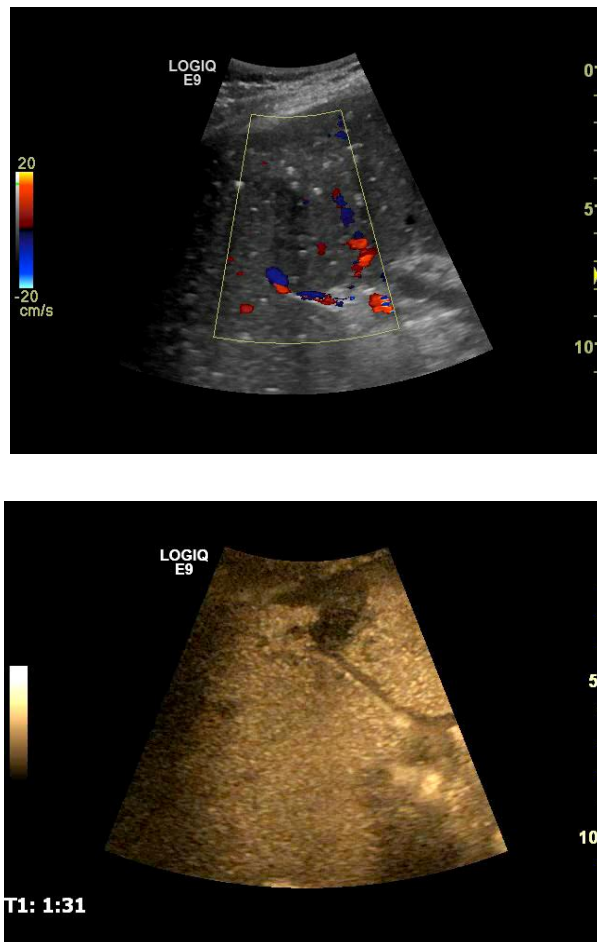
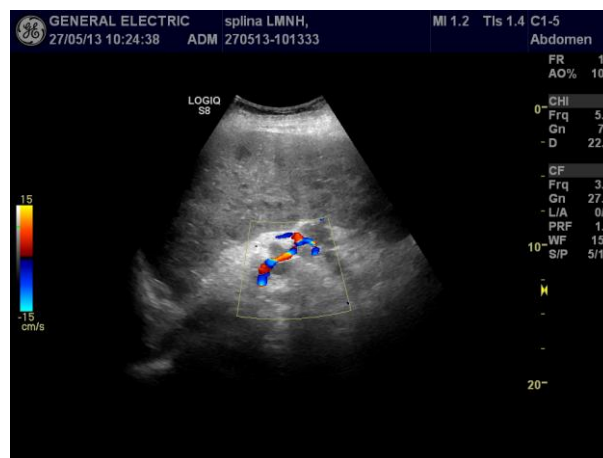
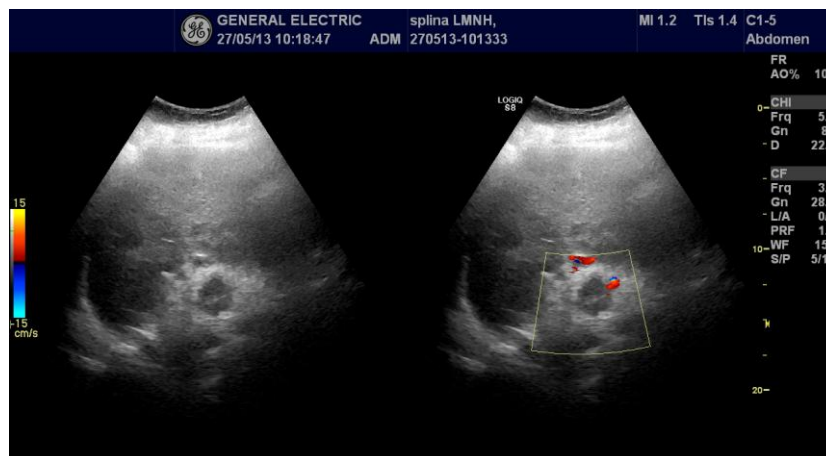


Figure 47 Splenic infarction in LES patient with a long history of disease. CEUS examination demonstrates splenic infarction and proves the vascular supply of the infarcted area.



Splenic vein thrombosis is a common complication seen in patients with acute pancreatitis or sepsis. We also found splenic vein thrombosis in patients with hematologic malignancies. Recent partial or total thrombosis, in the first days appears hypoechoic and is quite difficult to diagnose it on 2D or colour Doppler ultrasound examination. CEUS examination shows a much higher accuracy for setting the diagnosis (Figure 48).

Figure 48 Splenic vein thrombosis in a patient with LMNH. One can see enlarged lumen of the splenic vein, and the inhomogeneous aspect inside. Doppler examination proves lack of vascularization inside the splenic vein.



Traumatic spleen

The spleen is often affected in abdominal trauma, due to its fragility. In major trauma ultrasound has a major role in detecting life threatening complications due to the FAST protocol (Focused Assessment of Sonography in Trauma) commonly used today to detect or exclude the presence of free fluid in the pericardium or in the abdomen in cases of trauma.

Ultrasound is a fast technique, portable and proved that it can easily be integrated into the resuscitation of the patients with trauma without delay of the therapeutic

measures. Routine abdominal ultrasound can be also performed at the bedside in trauma centers. Studies show that the use of screening ultrasound in the follow-up of traumatic patients can improve clinical decision making for the use of the emergency laparotomy.

On the other side, in major trauma with clinically stable patients, contrast enhanced CT remains the method of choice, with the advantage of the entire examination of the abdominal cavity and the possibility of standardization. But its efficiency decreases in minor trauma, contusions, lacerations or oedemas, which can be ignored or overestimated on CT scan.

But B-mode ultrasound has a poor detection rate in blunt splenic injury, especially in imaging minor tissue damage, therefore is not recommended in the assessment of stable trauma patients.

In these situations CEUS examination allows a better evaluation of the blunt abdominal trauma, especially in children and has the advantage that it is not irradiant or toxic, and it may be used for cases treated conservatively to avoid unnecessary CE-CT examinations.

The ultrasound exam can diagnose a series of traumatic lesions as hematomas, contusions, lacerations or capsular effraction. Frequently these lesions are combined, often associating traumatic lesions of other organs. We must note the traumatic context of these lesions, but the rare possibility of the spontaneous spleen rupture should not be neglected, usually arising on a pathological spleen.

The sonographic appearance of hematoma depends on the amount of splenic tissue damaged and the delay time between the trauma and the first US examination. Immediately post-traumatic, the hematoma has a hypoechoic appearance and can be easily differentiated from splenic parenchyma. But, within the first few hours, hematoma develops a nearly isoechoic appearance with inhomogenous areas inside and an intra-splenic hemorrhage might not be visible at all. Depending on the volume of hemorrhage the spleen may be enlarged causing local pain. Over the following days, hematoma becomes slightly hypo-echoic, due to re-liquefaction. Finally, a hematoma can be differentiated as clearly hypoechoic areas. Because the splenic capsule is very thin, we can receive important information about the integrity of the capsule analyzing the shape of the fluid collection. If the collection is crescent and conforms to the contour of the spleen, we can presume that hematoma is subcapsular. If the collection is irregularly shaped, perisplenic hematoma is suggested.

During the recovery process, hematoma sizes gradually decrease and its echostructure may become hyperechoic due to the fibrosis process. When the spleen recovers, it may contain small irregular foci or the parenchyma may have a homogeneous B-mode appearance again. Sometimes at a later scan, pseudocysts can be seen at the site of the hematoma. CEUS is the most sensitive US technique

to prove minor defects during the follow up after splenic trauma (Figure 49, Figure 50).

Blunt parenchymal trauma may cause other various injuries, such as lacerations, contusions, capsule rupture and vessel tears of different severities. B-mode ultrasound shows minimal or absent modifications of the splenic parenchyma. Most often an inhomogeneous area in the parenchyma is seen or a hypoechoic area with ill-defined irregular borders; this, in time, can evolve to resolution or it can form a collection (hematoma).

Figure 49 Posttraumatic follow-up. Inhomogeneous “wedge-shaped”, ill-defined subcapsular area with small cysts inside.

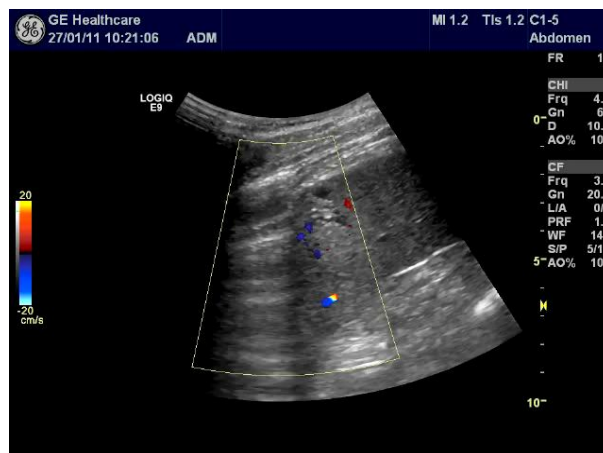
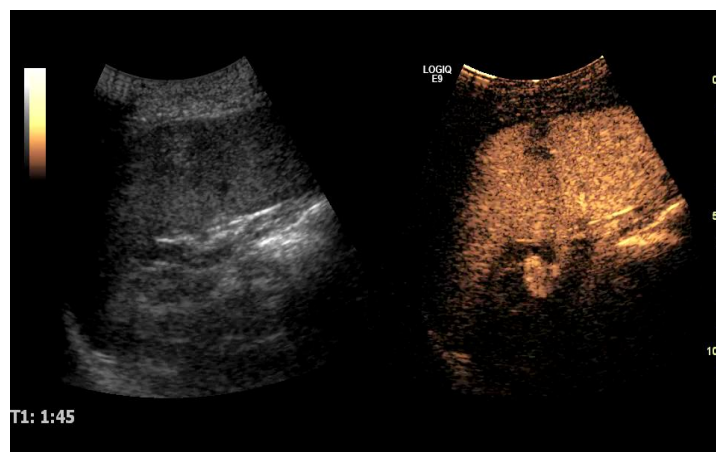


Figure 50 Same case, CEUS examination allows better delineation of the old hematoma



CEUS is the examination that determines the presence and the extension of these lesions. They appear on CEUS as opacification defects visible in all circulatory phases of the organs. Necrotic parenchymal areas appear non-enhanced, sharp edge delineated. Lacerations appear as clearly hypoechoic bands linear or branched, which are usually perpendicular to the spleen surface. Contusion appears as ill-defined, slightly hypoechoic areas, with various degrees of decreased perfusion

because of crushing rather than tearing of parenchyma. Presumably, the less intact the perfusion, the worse and more vulnerable is the contusion injury. Laceration-contusive areas and parenchymal hematomas appear without mass effect or vessel displacement. Hematomas appear after the stop of bleeding as nonenhanced sharp edge delineated areas. In case of active bleeding contrast extravasations can be seen as an early-phase hyperechoic pool or jet within the splenic parenchyma or perisplenic hematomas. Partial hypoperfused areas (post-traumatic infarctions) appear as wedge-shaped or polar hypoechoic areas. In cases of pedicle avulsion or severe hypovolemia ("shock spleen") total or subtotal lack of enhancement is detectable. In cases of shock spleen overall parenchymal enhancement is poor, clearly less than expected, and less than the adjacent left kidney.

In detection of perisplenic fluids the sensitivity of CEUS is lower than CE-CT (contrast enhanced computed tomography) and only slightly superior to US, especially when we talk about small amounts of fluid. In a preliminary study Catalano et al. reported a detection rate of 73% with CEUS, lower than for other organ injuries and not different from the US detection rate. Also the most recently published study (2011, in press) report a good detection rate of perisplenic fluids, but inferior to CE-CT (11 from 13 patients detected on CE-CT). The quoted factors of this failure were the minimal amount of fluid and the deep localization that cause it to be mistaken for intra-abdominal fat due to the limited penetrability of low-mechanical index ultrasound that make the deep lesions difficult to detect. Those two factors were also reported by other CEUS trauma studies of retroperitoneal lesions in which the detection rate of perisplenic fluids was reduced to 69%. On the other hand, due to its relatively low perfusion, fat appears almost anechoic on CEUS like free fluid or hematomas, the reference image or baseline B-mode helps to differentiate fluid from fat.

Recommended reading

- Gray H. Chapter 88: The spleen. In: Standring S, ed. *Gray's Anatomy: The Anatomical Basis of Clinical Practice*. 39th ed. Edinburgh, UK: Churchill Livingstone Elsevier; 1239-44.
- Lee McGregor A, Decker GAG, du Plessis DJ. Chapter 8: The spleen. Lee McGregor's Synopsis of Surgical Anatomy. 12th ed. Oxford, UK: Butterworth-Heinemann; 1986:106-13.
- Vos PM, Mathieson JR, Cooperberg PL. The spleen. In *Diagnostic Ultrasound*, third edition, Elsevier Mosby Ed 2005;147-170
- A. Berzigotti, F. Piscaglia, and the EFSUMB Education and Professional Standards Committee. Ultrasound in Portal Hypertension – Part 2 – and EFSUMB Recommendations for the Performance and Reporting of Ultrasound Examinations in Portal Hypertension. *Ultraschall in Med* 2012; 33: 8–32
- Hagen-Ansert SL. The spleen. In *Textbook of diagnostic ultrasonography*. Mosby Ed 2001; 308-326

- Ioanimescu ES, Weskott HP. The spleen. In EFSUMB Course Book of Ultrasound;169-194. Published by EFSUMB, 2012.
- Claudon M, Cosgrove D, Albrecht T, et al. Guidelines and good clinical practice recommendations for contrast-enhanced ultrasound (CEUS): update 2008. *Ultraschall Med* 2008; 29:28–44
- Piscaglia F, Nolse C, Dietrich CF, et al. The EFSUMB Guidelines and Recommendations on the clinical practice of Contrast-Enhanced Ultrasound (CEUS): update 2011 on non-hepatic applications. *Ultraschall Med* 2012; 33:33–59
- Thorelius L – Contrast-Enhanced Ultrasound in Low-Energy Blunt Abdominal Trauma. In *Enhancing the Role of Ultrasound with Contrast Agents*; Springer Ed 2006:193-203
- Neesse, A.; Huth, J.; Kunsch, S.; Michl, P.; Bert, T.; Tebbe, J. J.; Gress, T. M.; Görg, C.: Contrast-Enhanced Ultrasound Pattern of Splenic Metastases – a Retrospective Study in 32 Patients. *Ultraschall in Med* 2010; 31: 264–269.