

Update in Salivary Gland Pathology

Benjamin L. Witt

University of Utah/ARUP Laboratories

February 9, 2016

Objectives

- Review the different appearances of a selection of salivary gland tumor types
- Establish an immunohistochemical staining pattern to aid in distinguishing between certain tumors
- Discuss some newer concepts in salivary gland pathology

Acinic Cell Carcinoma

- Originally this was considered a benign neoplasm until its malignant potential was described in the 1950s
- Later regarded as in between adenoma and carcinoma (acinic cell tumor; WHO 1972)
- Finally classified as acinic cell carcinoma in 1991 WHO classification
- Diagnosis can be rendered in absence of invasive growth

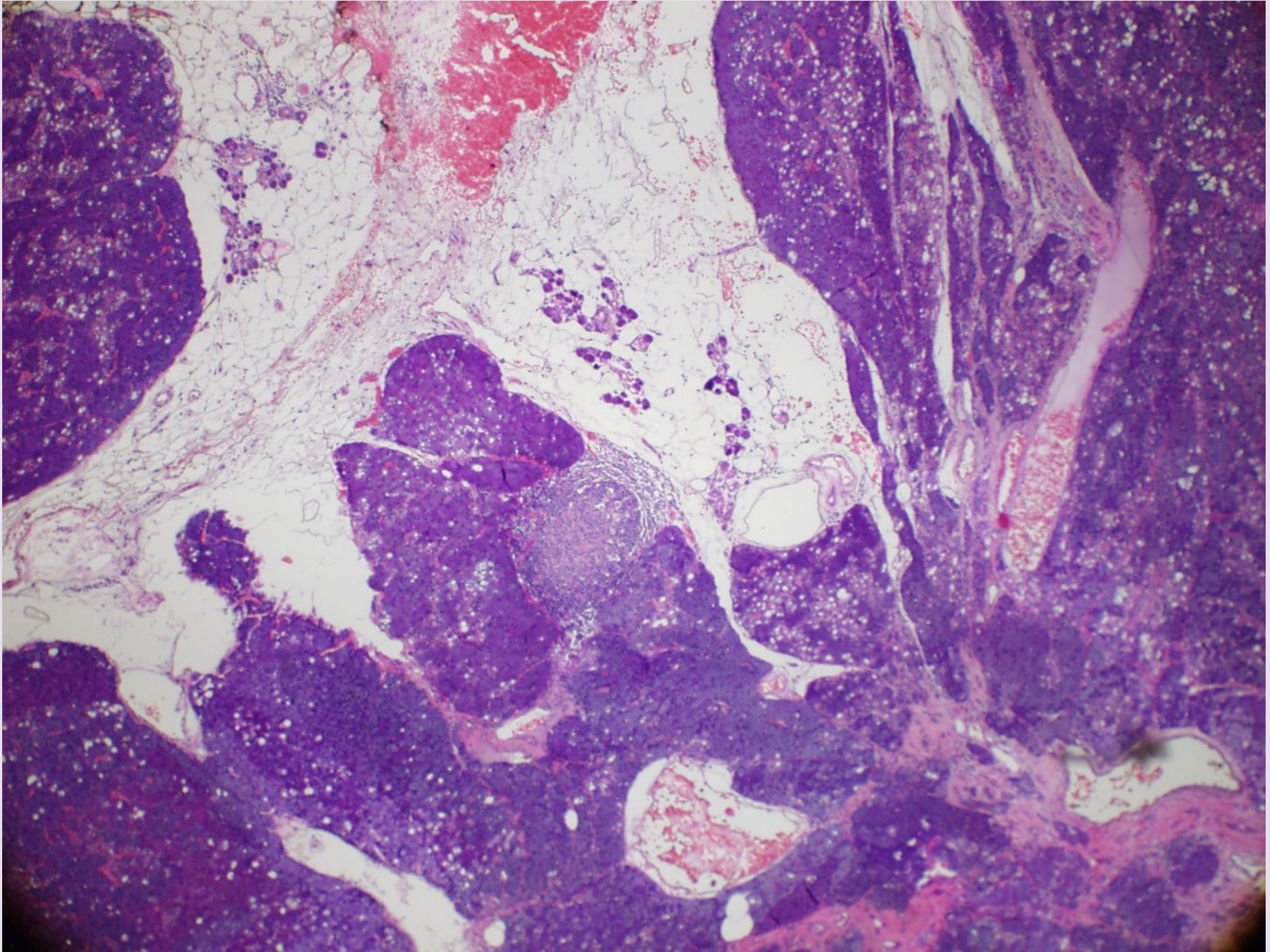
Acinic Cell Carcinoma

- Third most common malignancy of major salivary gland (15%)
- Most non-parotid ACC (11/14; 80%) actually represent misclassified mammary analogue secretory carcinoma (MASC)
 - Based upon positivity for S100, mammaglobin
 - Confirmatory *ETV6* t(12;15) translocation by FISH

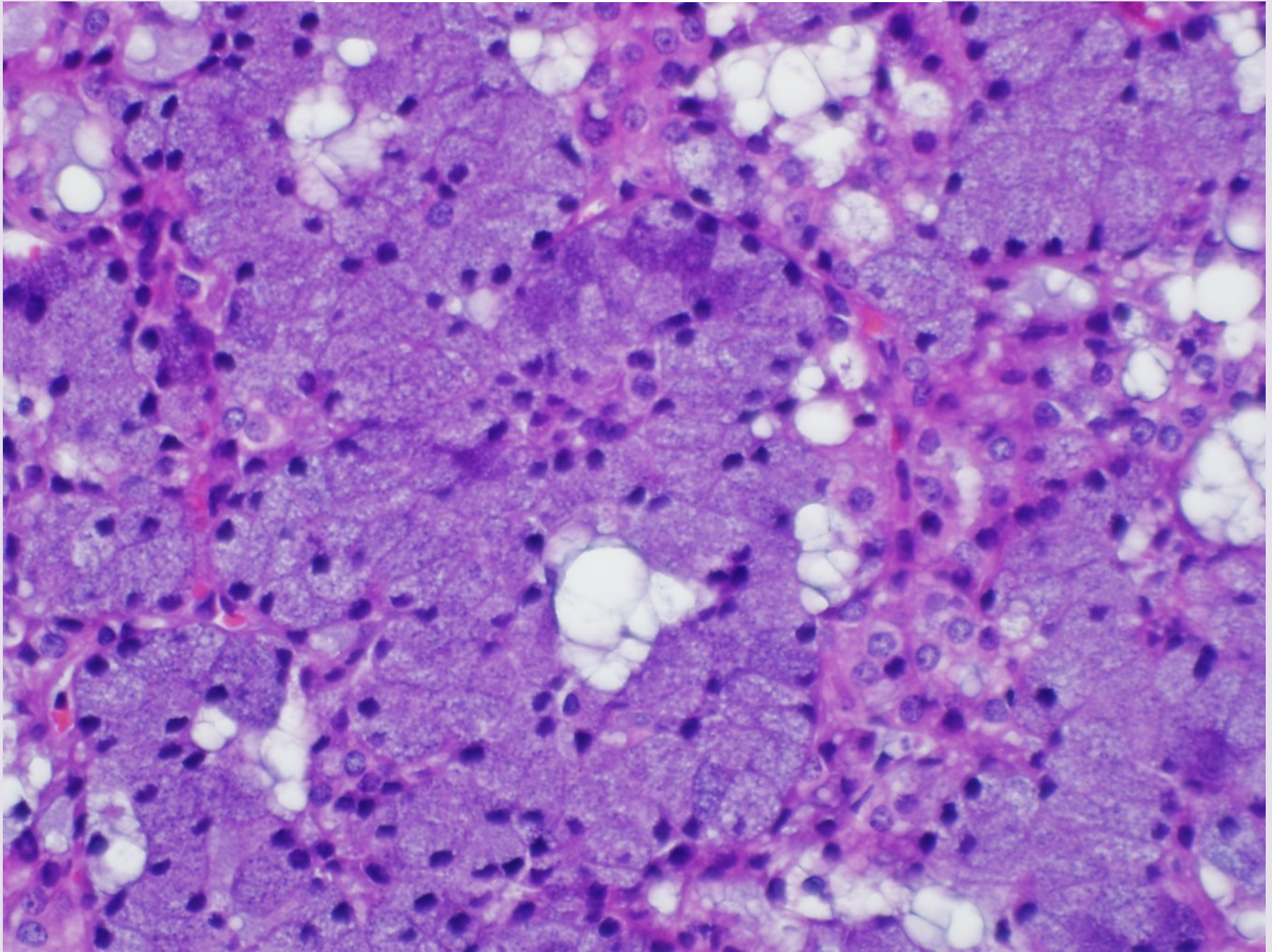
Acinic Cell Carcinoma

- Neoplasm of cells differentiated towards serous acinar cells
- Aside from the zymogen granule rich cells (pathognomonic acinar cells) other cell types frequent these tumors:
 - Vacuolated cells
 - Clear cells (non-mucinous, PAS negative)
 - Nonspecific glandular cells
- No grading system exists although high grade transformation is reported

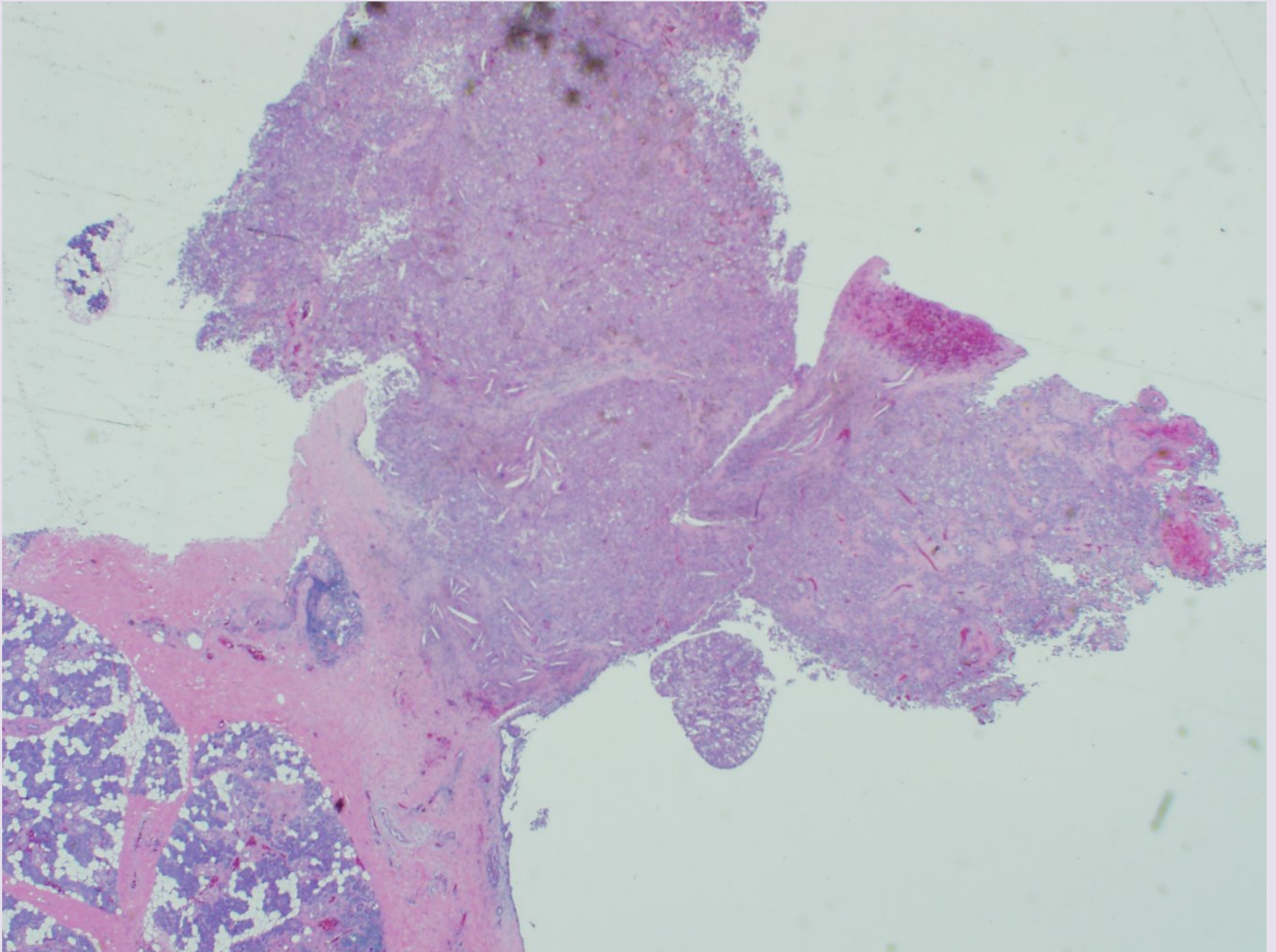
Lesion 1: Parotid Mass in 68 year old female



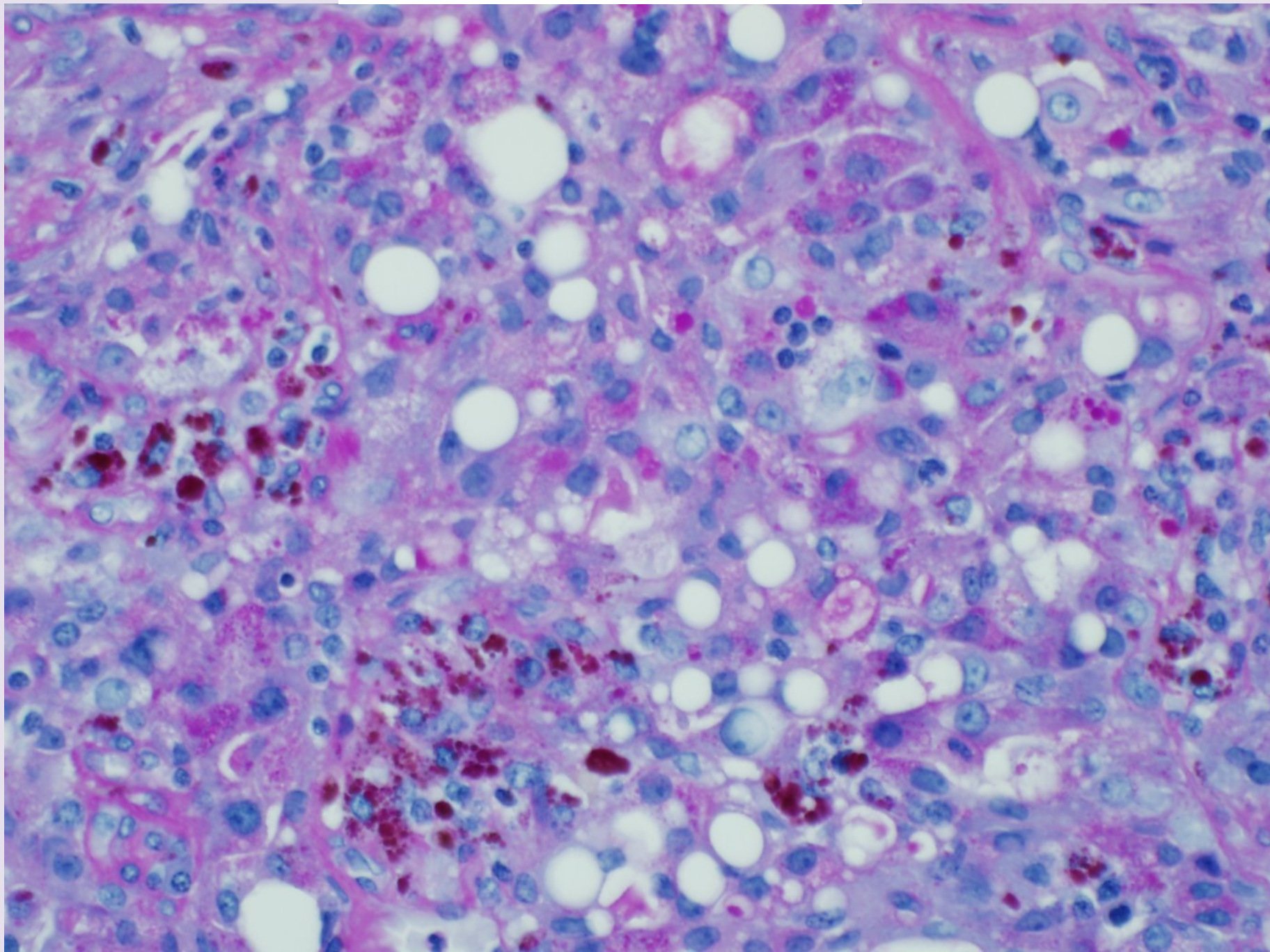
Lesion 1: Note clear and vacuolated cells



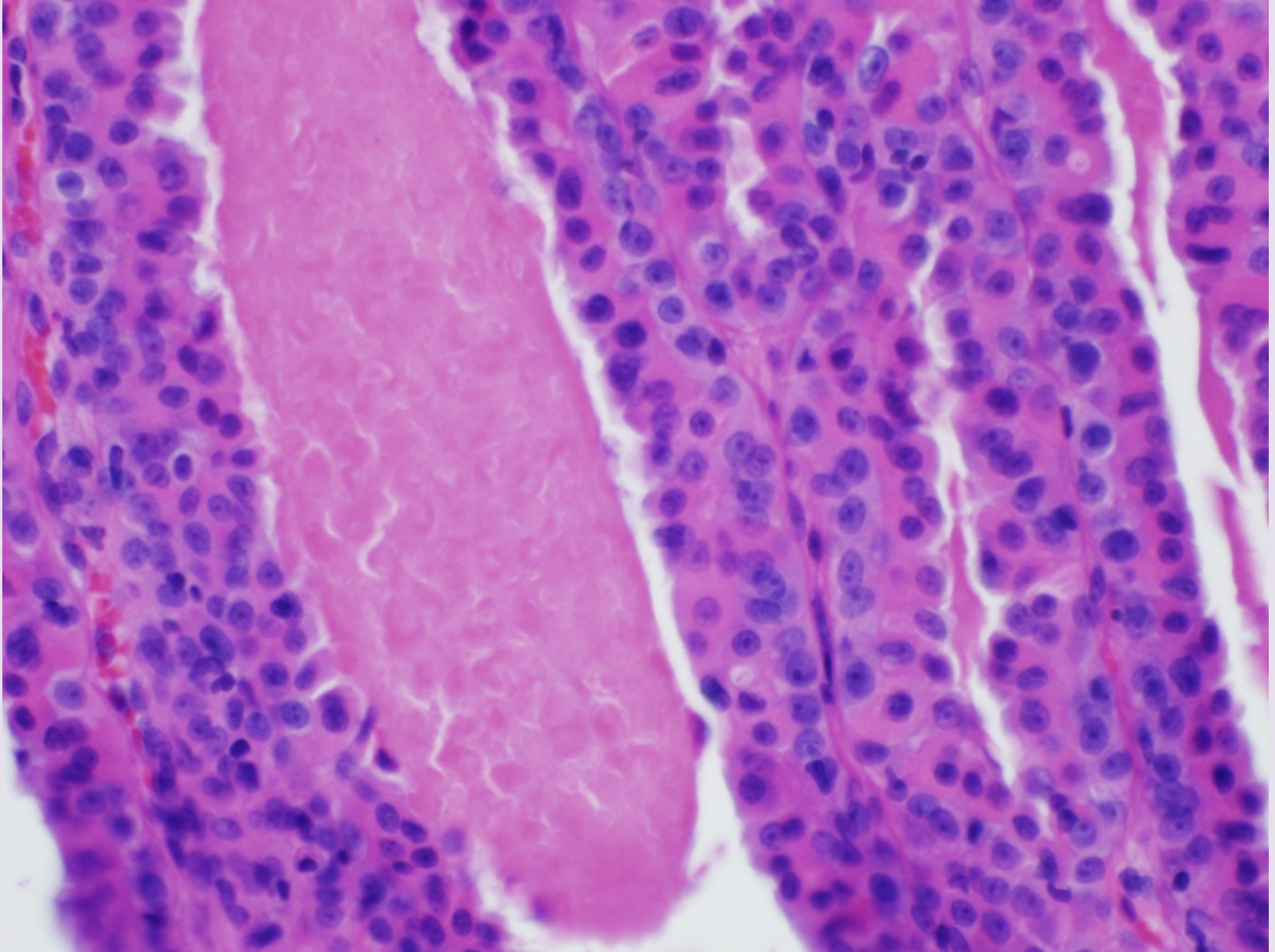
Lesion 2: Parotid mass (3 cm) in 15 year old female



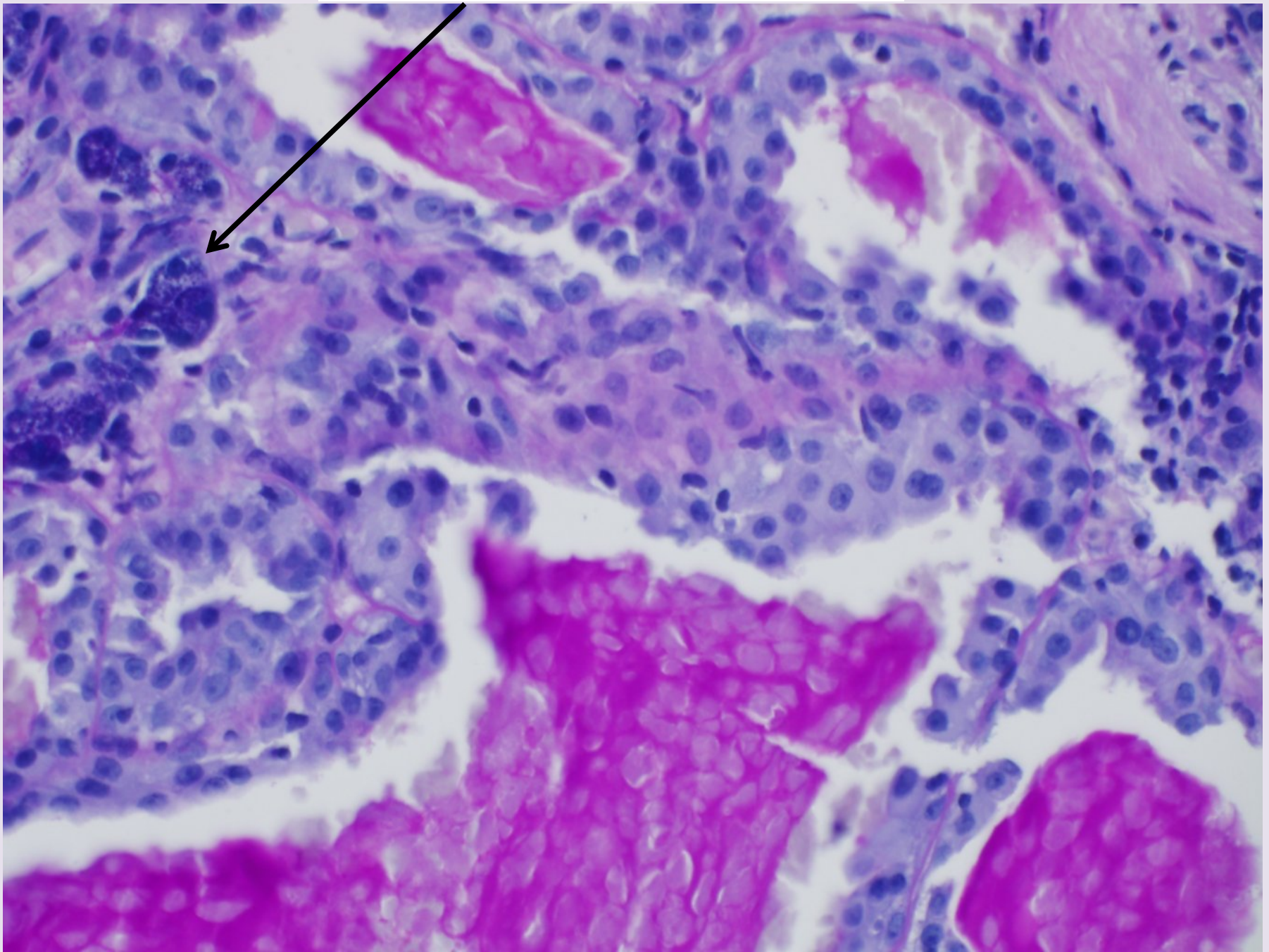
PAS-D on Lesion 2



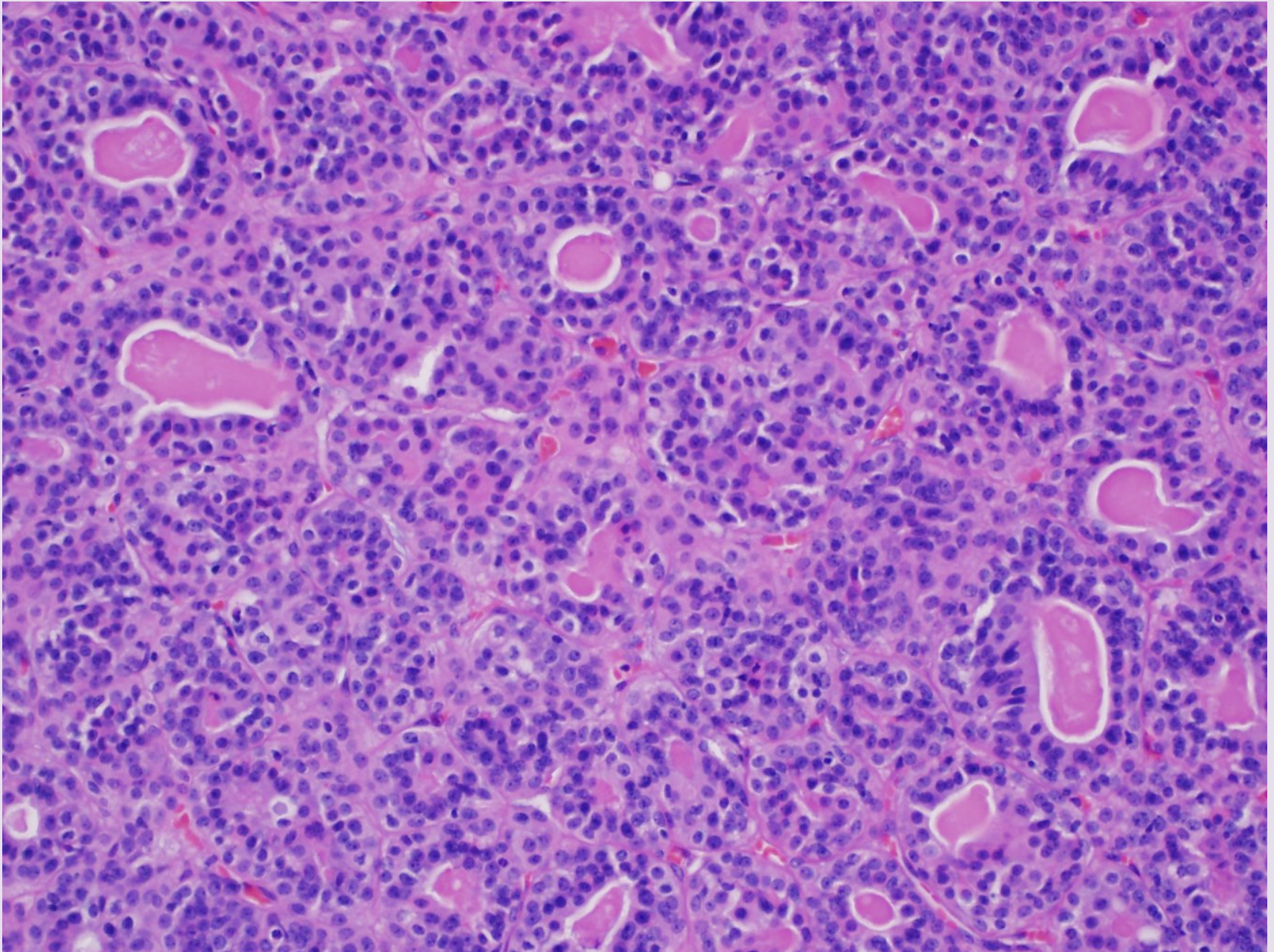
Lesion 3: From parotid mass of 55 year old male



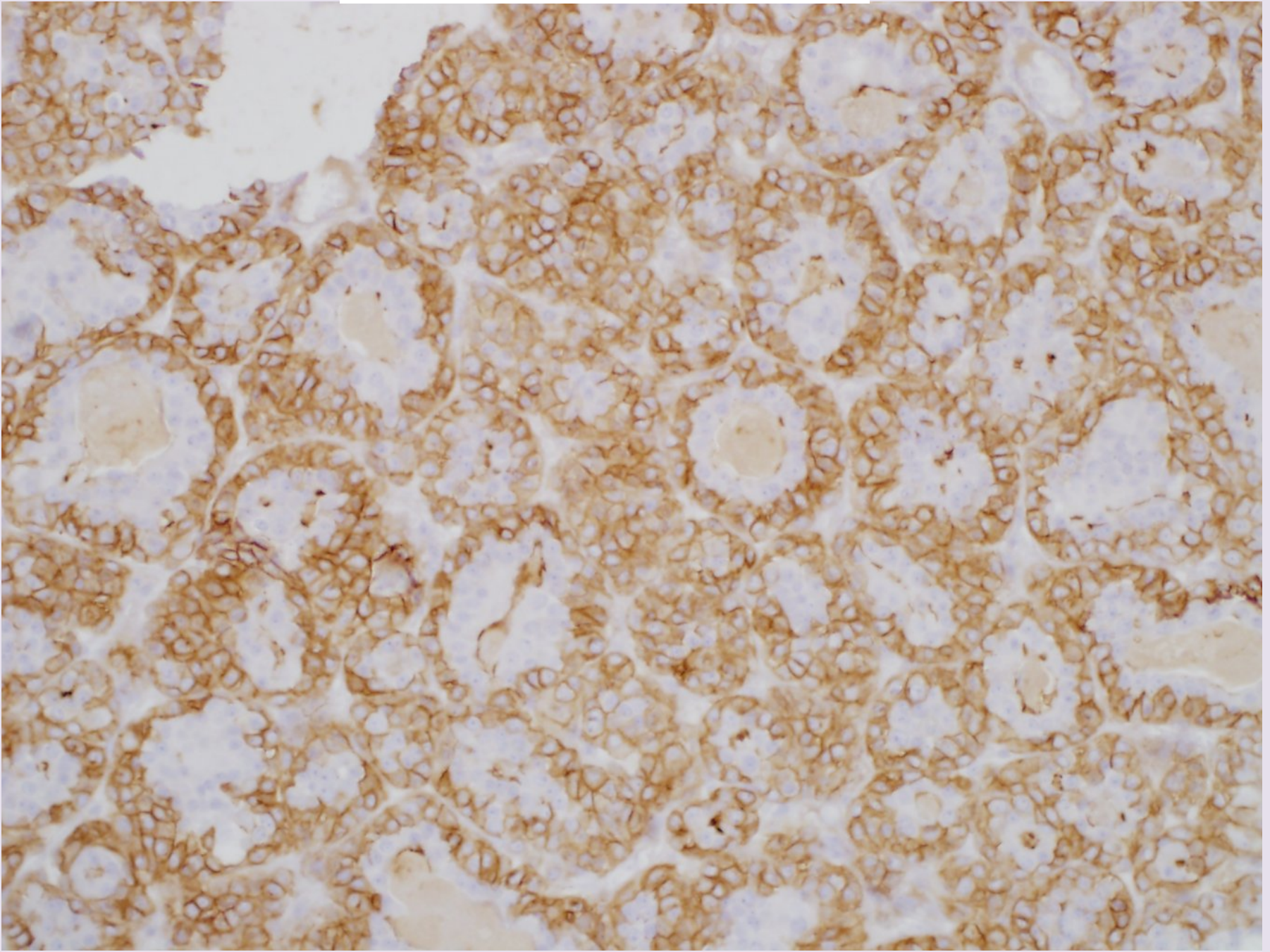
PAS-D from Lesion 3



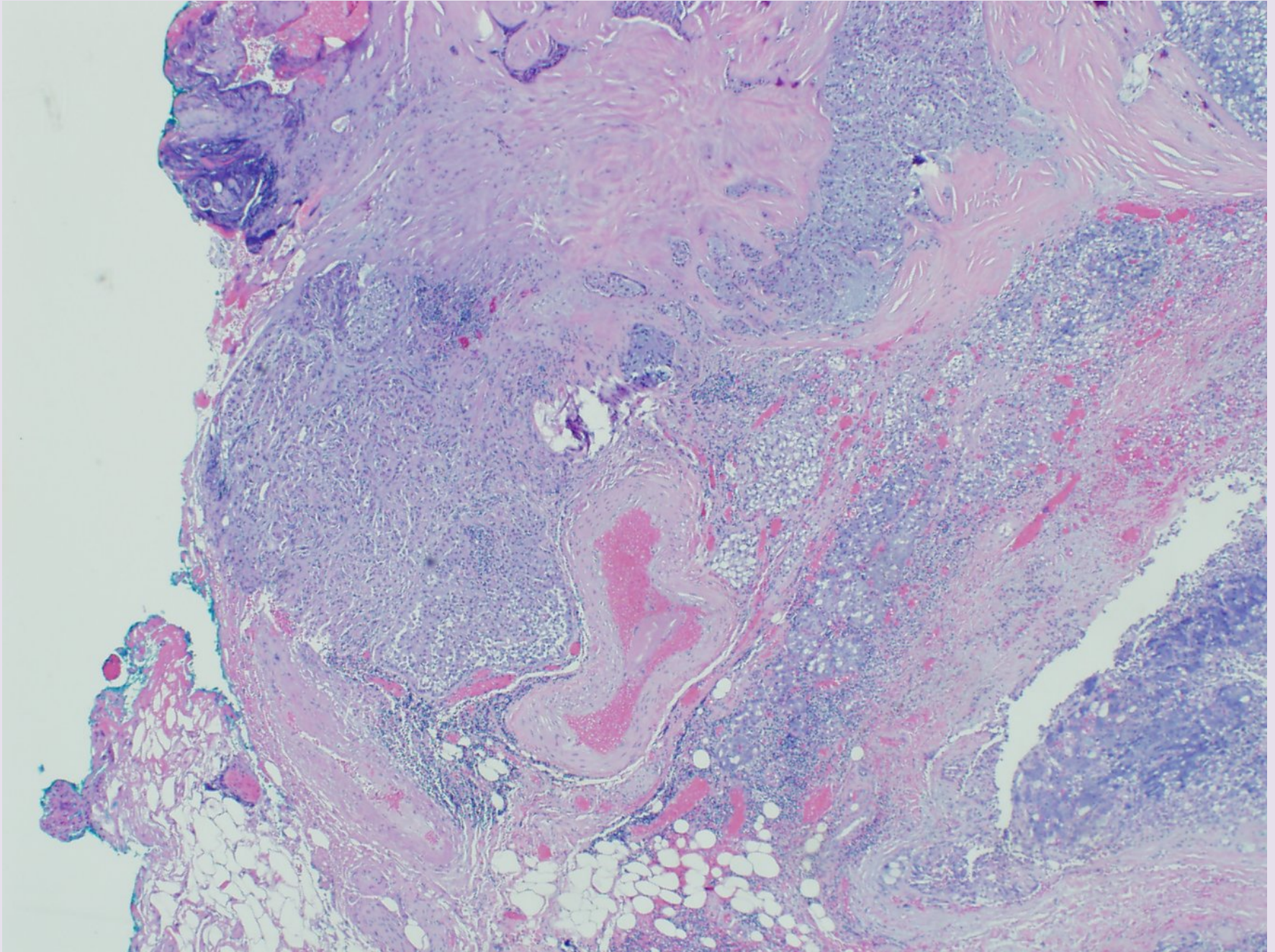
Lesion 4: 67 year old female (least common follicular pattern)



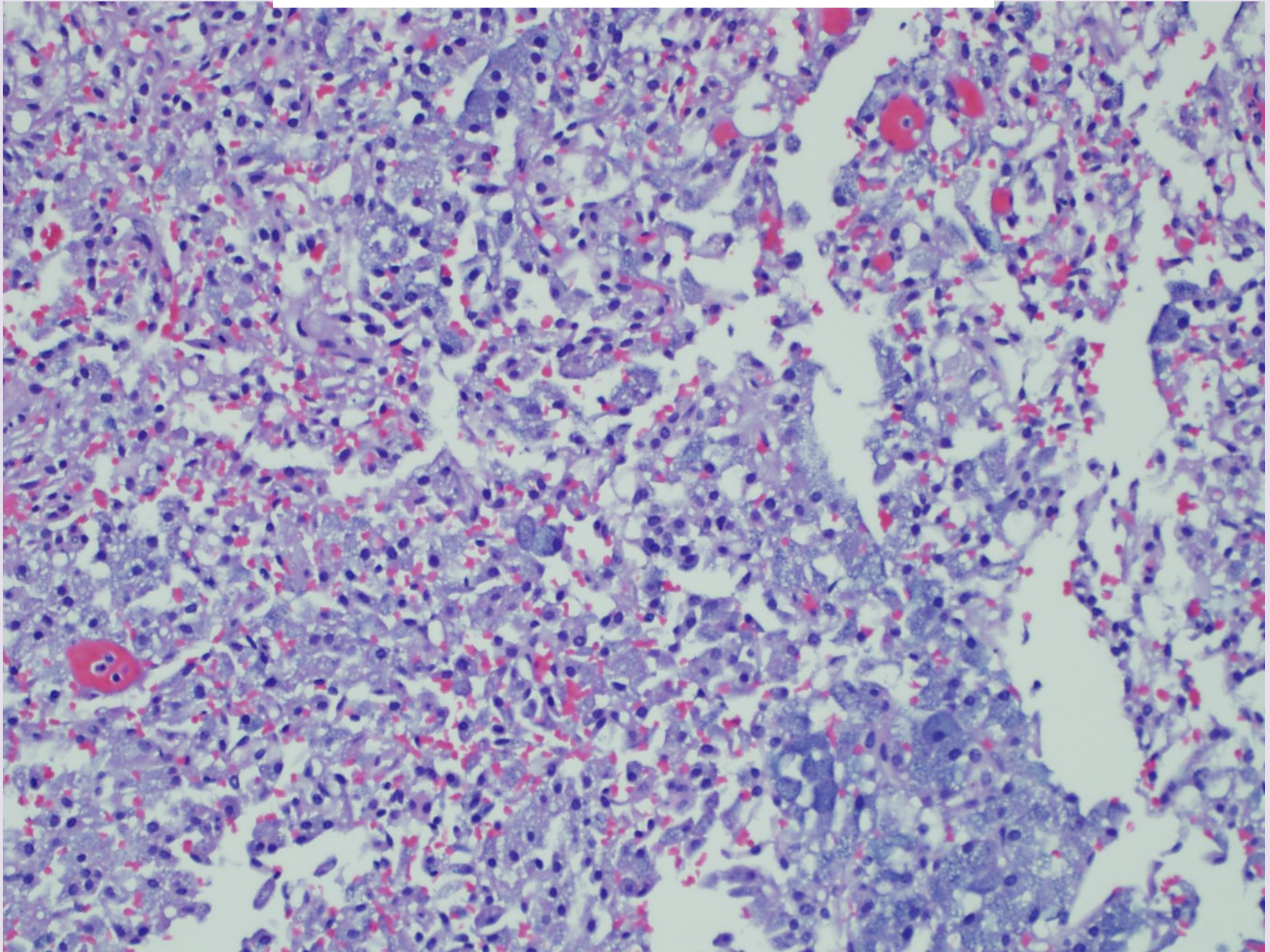
Lesion 4: DOG 1



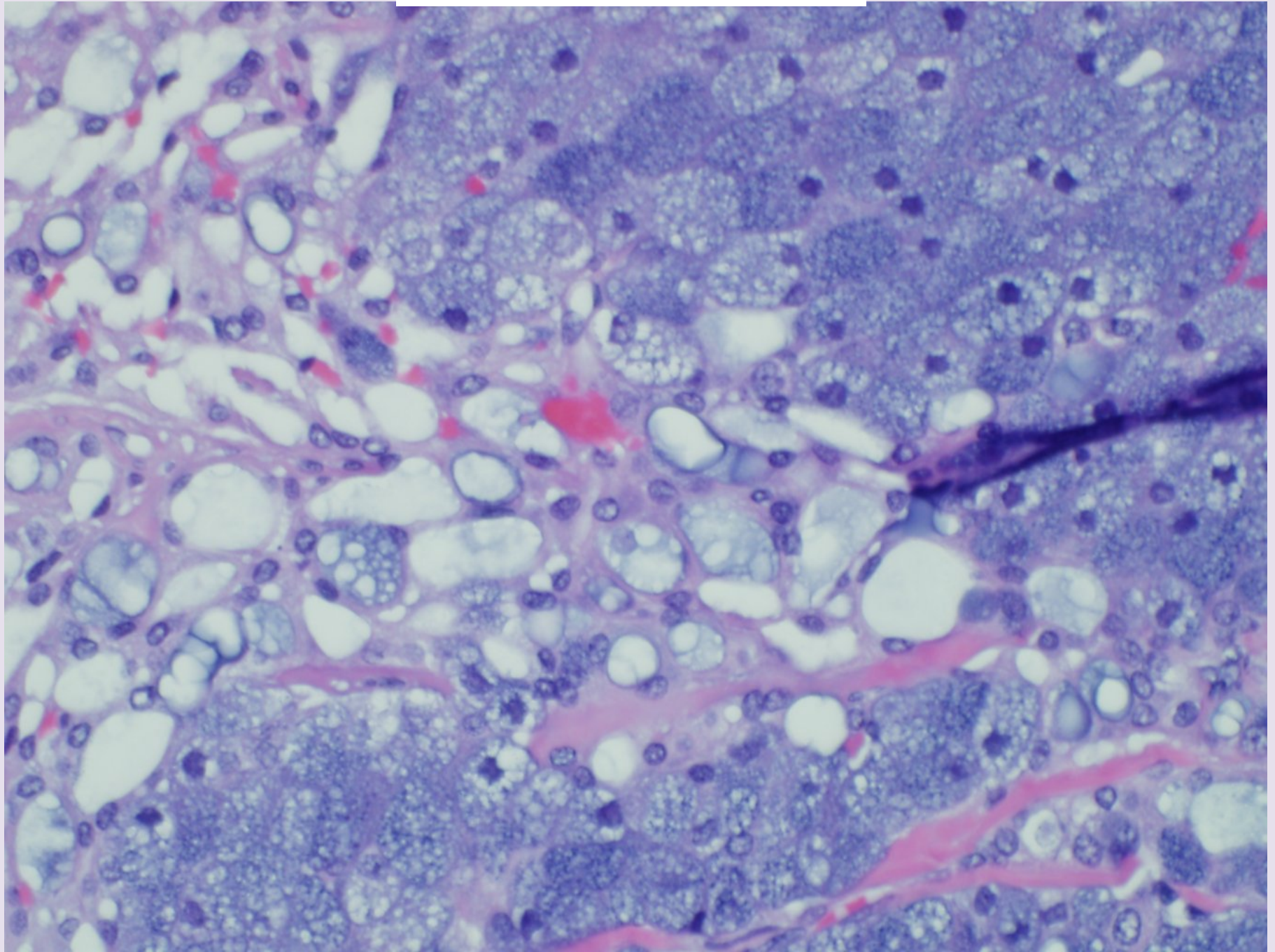
Lesion 5: 76 year old female with parotid mass



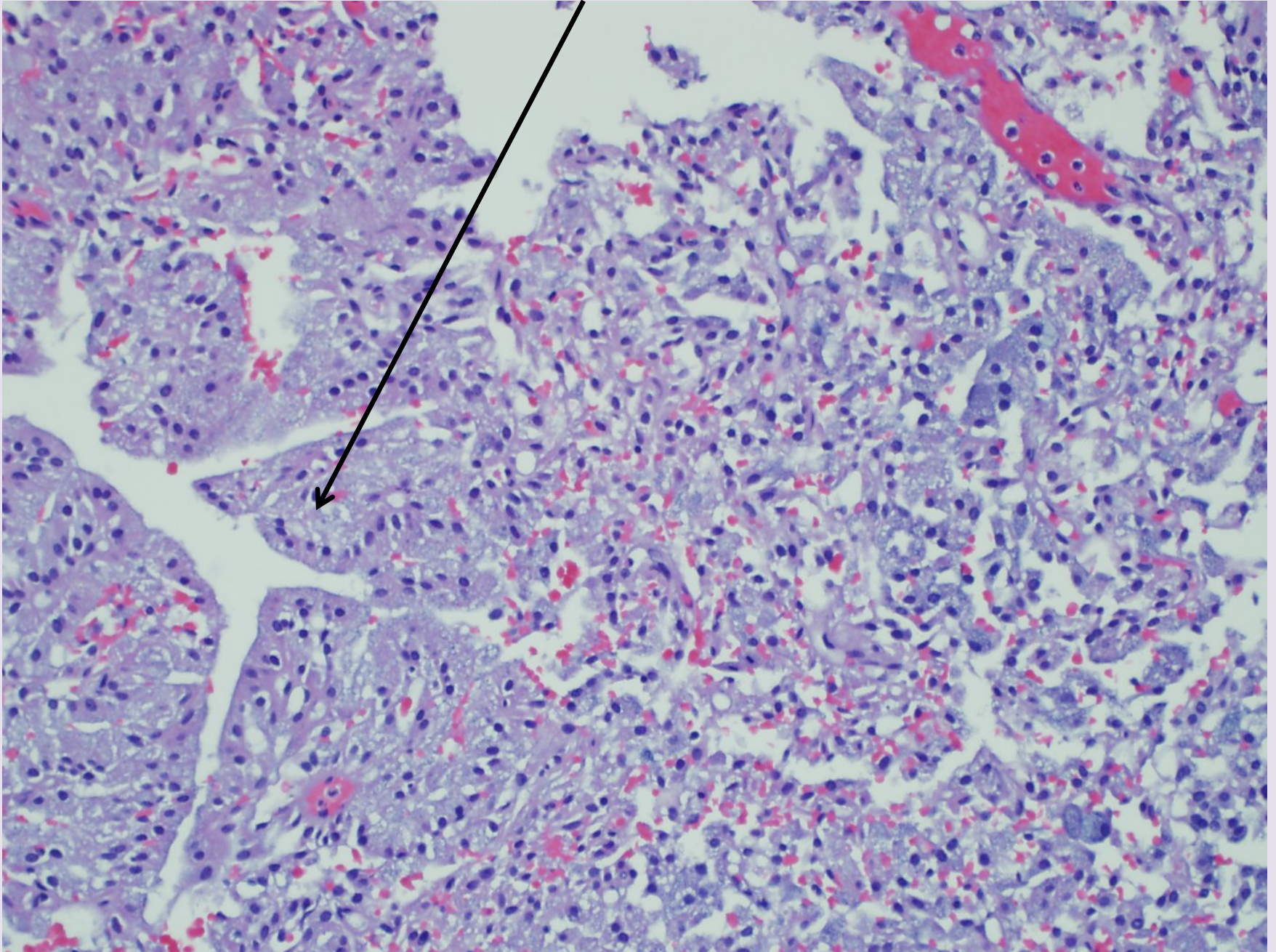
Lesion 5: Microcystic with clear/vacuolated cells



Lesion 5



Lesion 5: Nonspecific glandular cells



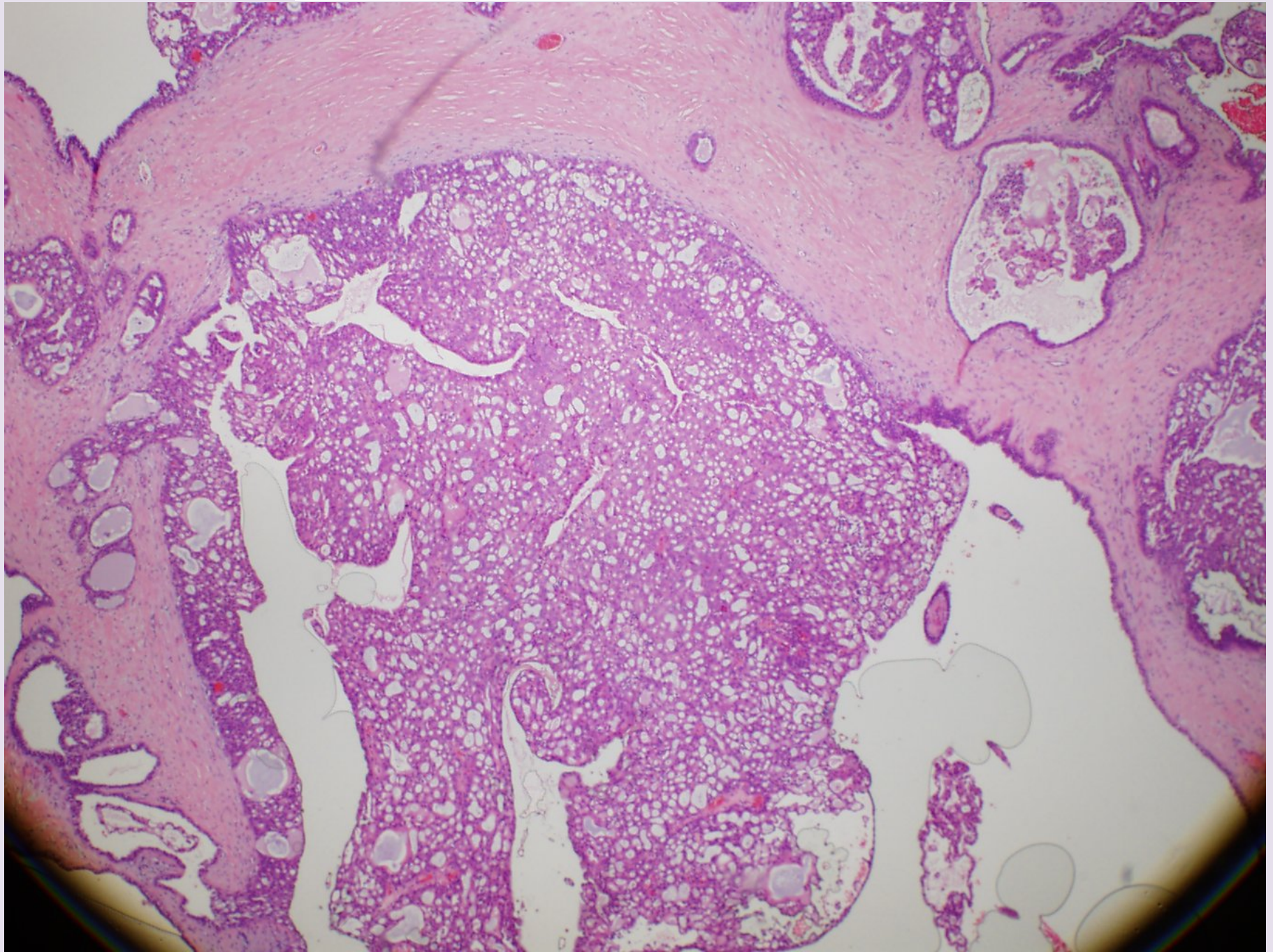
Mammary Analogue Secretory Carcinoma (MASC)

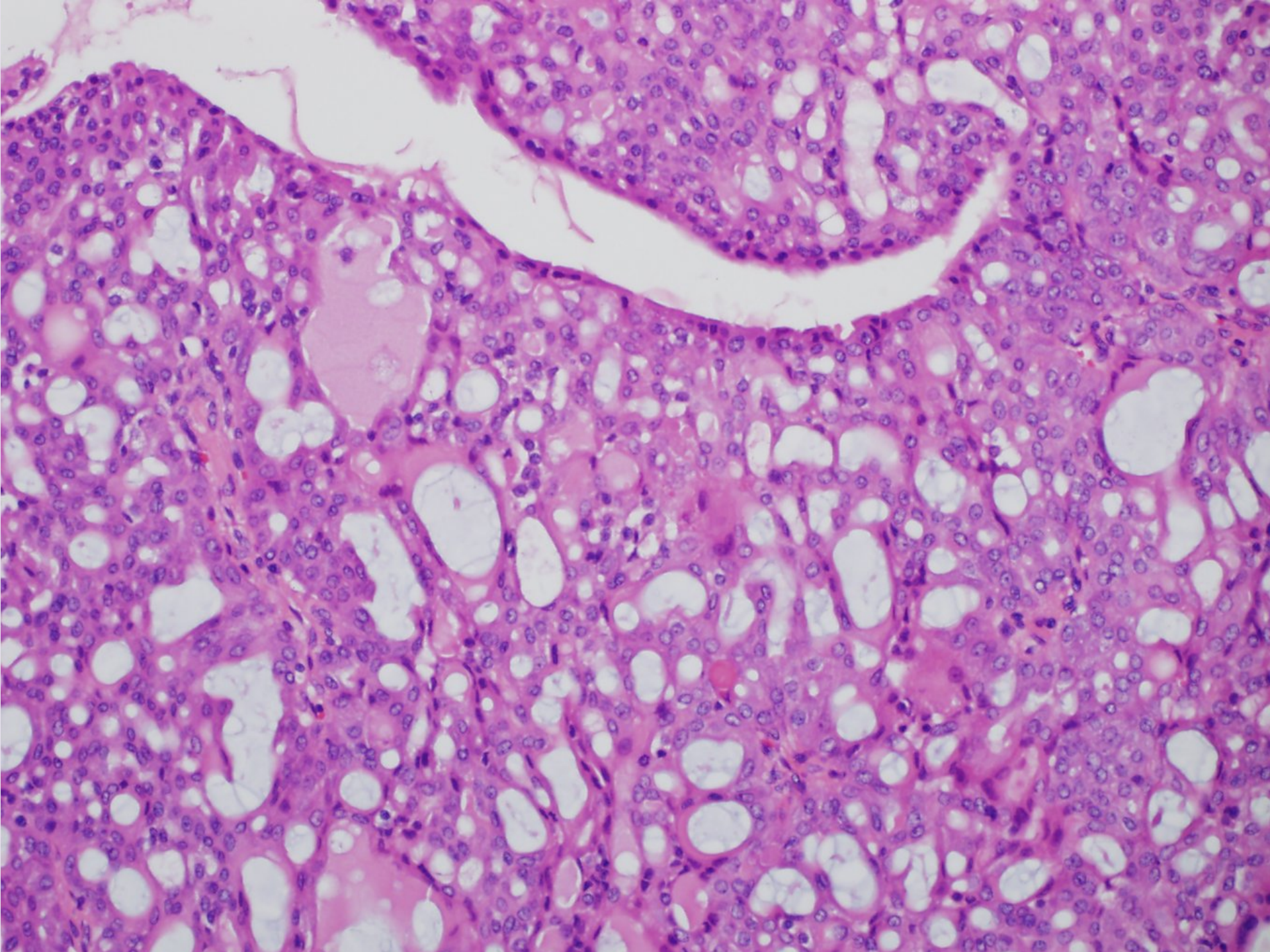
- Recently described (2010) salivary gland tumor with morphologic resemblance to secretory carcinoma of the breast
- Known *ETV6-NTRK3* t(12;15) gene rearrangement
- Uniform/bland cell proliferation
- Eosinophilic vacuolated cytoplasm
- Mostly solid, microcystic pattern with abundant PAS/D + secretions

MASC

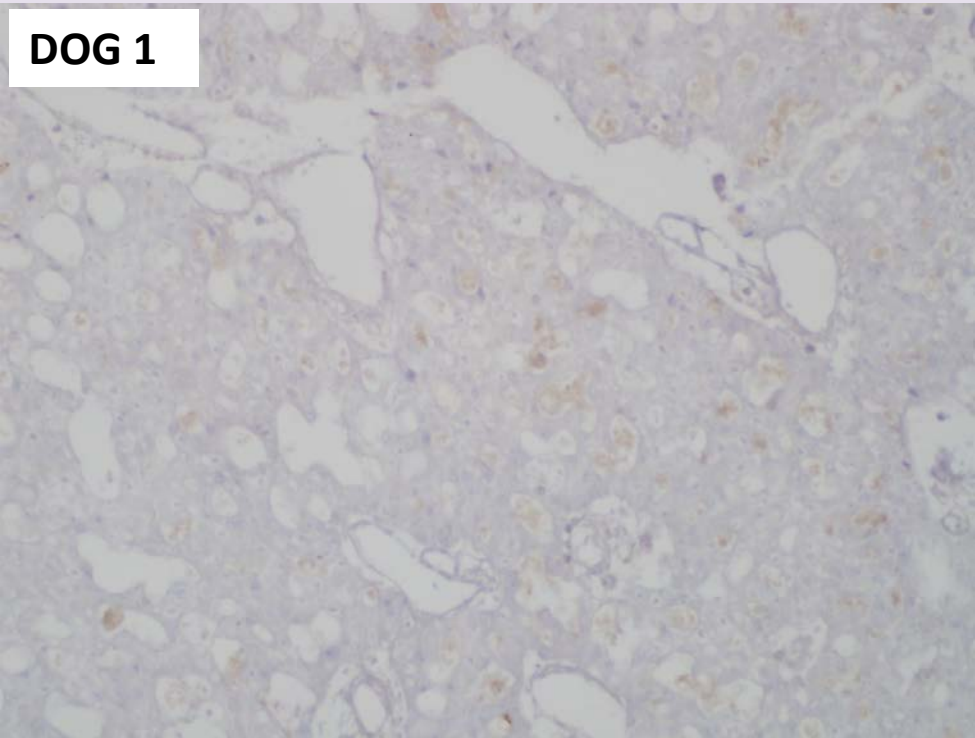
- In prior years the majority would have been classified as secretory poor (or intercalated duct predominant) acinic cell carcinomas or low grade adenocarcinomas NOS
- No significant prognostic difference between MASC and Acinic cell carcinoma
- MASC does have slight male predilection
- MASC more common to extraparotid sites
- MASC have greater potential to develop nodal metastases

36 year old male with 3 cm parotid mass

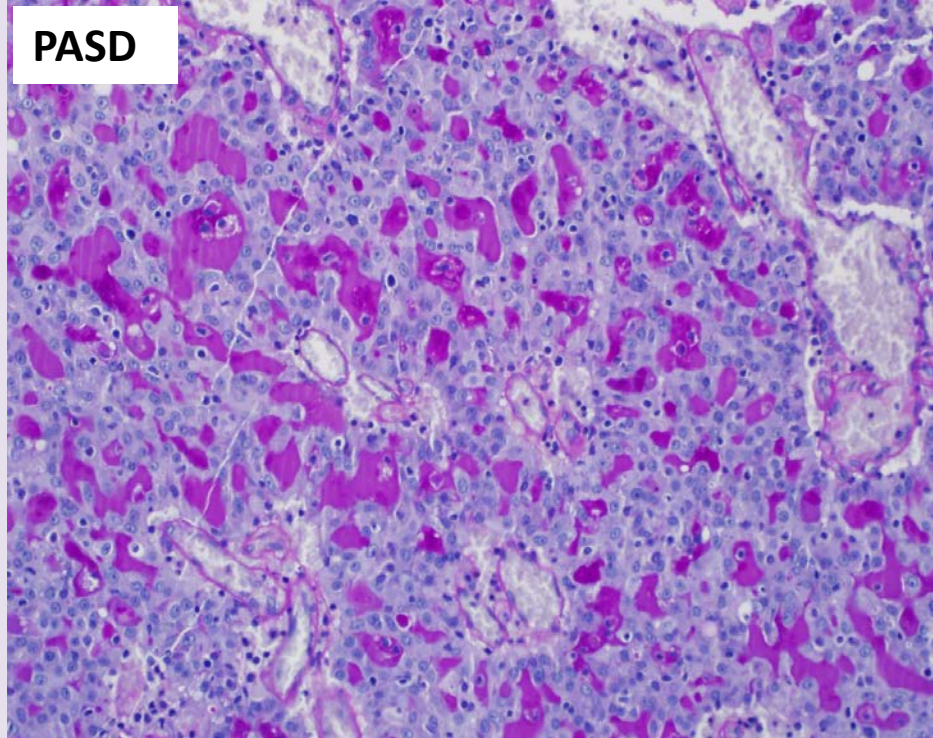




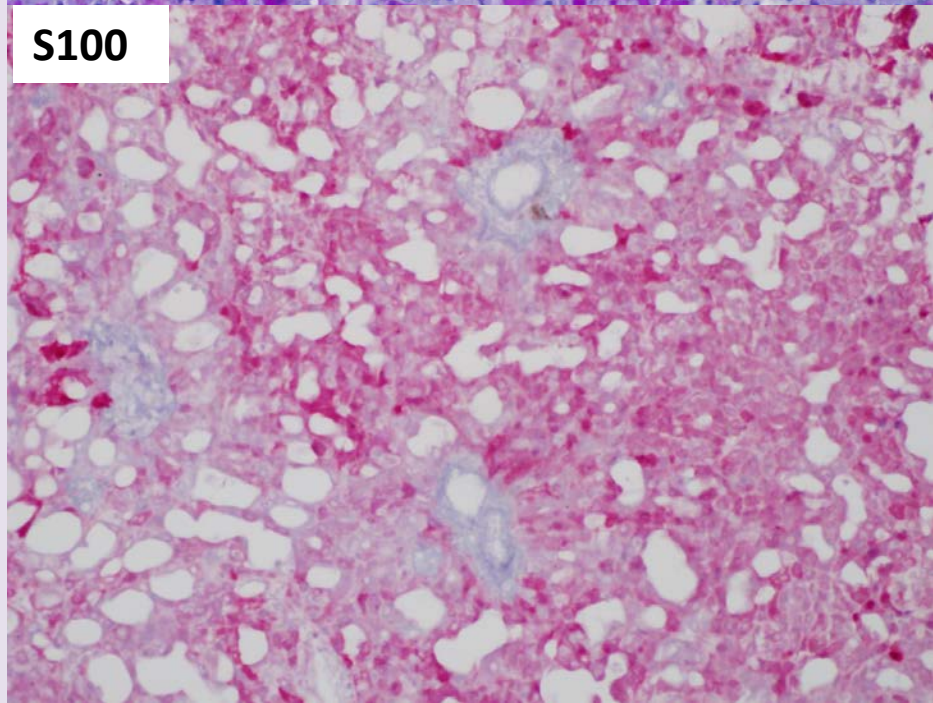
DOG 1



PASD



S100



MASC

Suggested IHC Panel for Acinic Cell Carcinoma versus MASC

	Acinic Cell Carcinoma	Mammary Analogue Secretory Carcinoma
S-100	Mostly -	Strongly +
Mammaglobin	-	+
DOG-1	+ (diffuse apical/membranous staining)	Usually -
GATA3	-	Diffuse +
PAS-D	+ (zymogen granules)	- (NO zymogen granules)

Both Acinic Cell Carcinoma and MASC lack significant p63 positivity to help distinguish from low grade mucoepidermoid carcinoma

Schwartz et al. *Head and Neck Pathol* (2013) 7:311-315

Chenevert et al. *Modern Pathology* (2012) 25:919-29

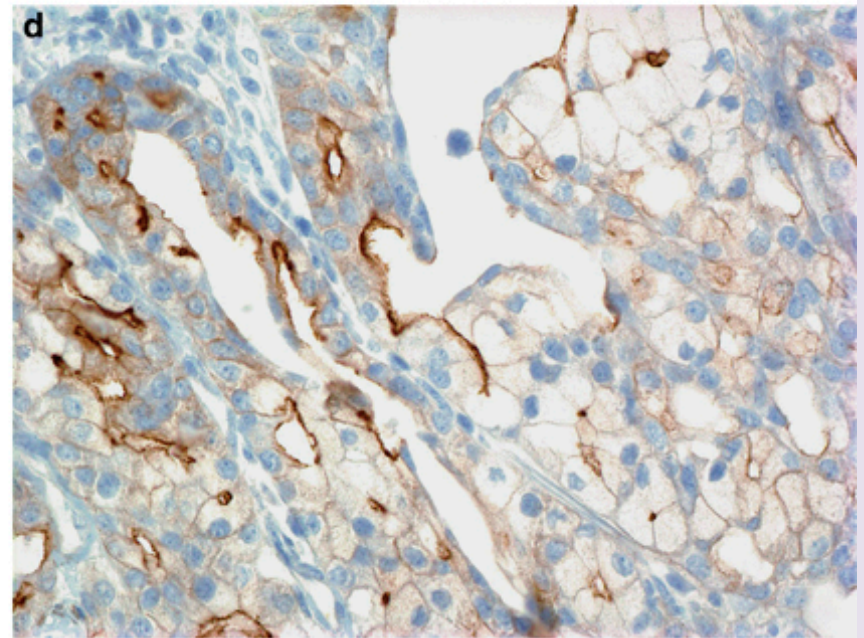
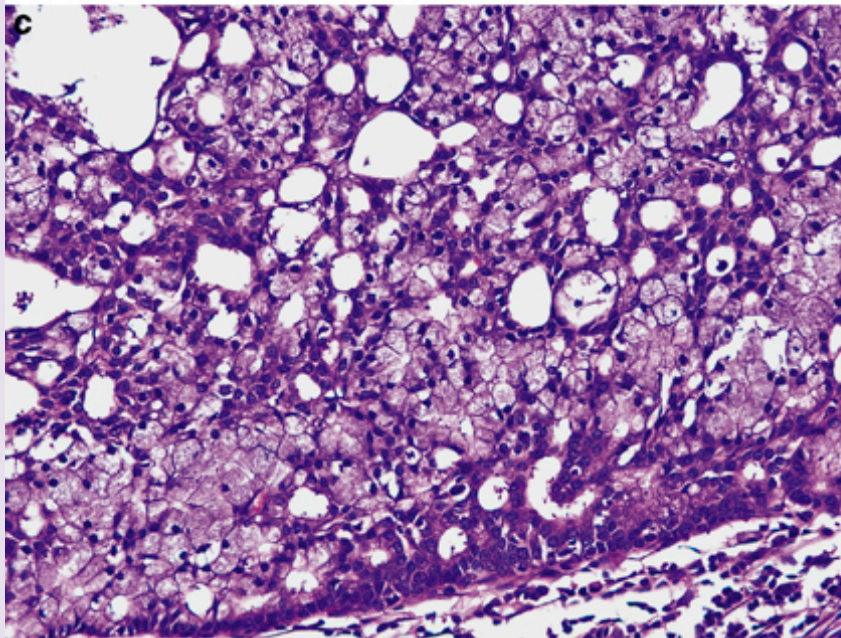
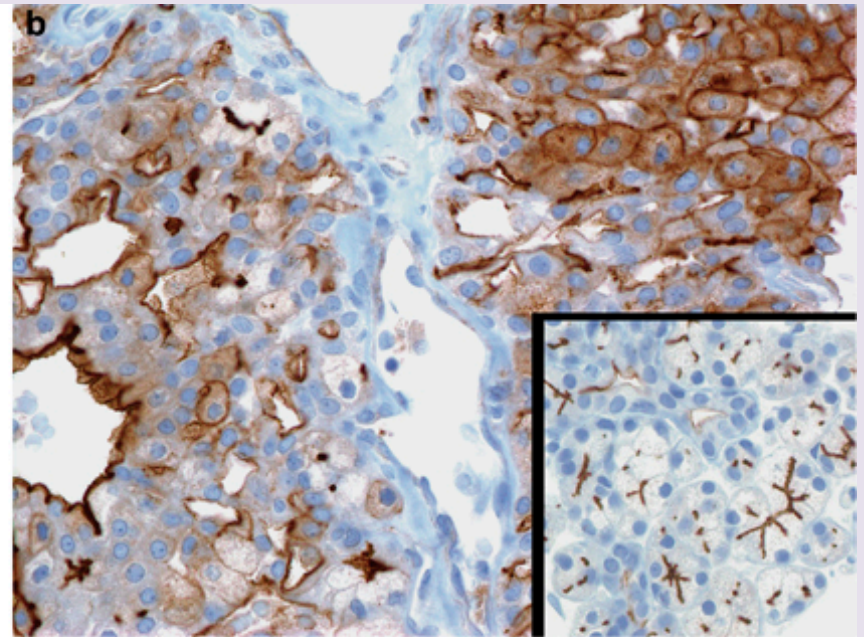
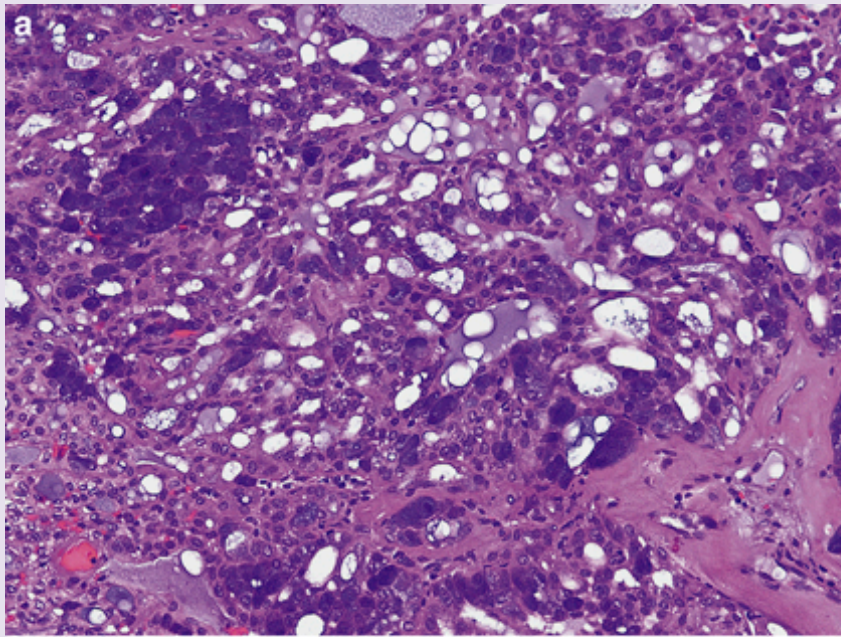
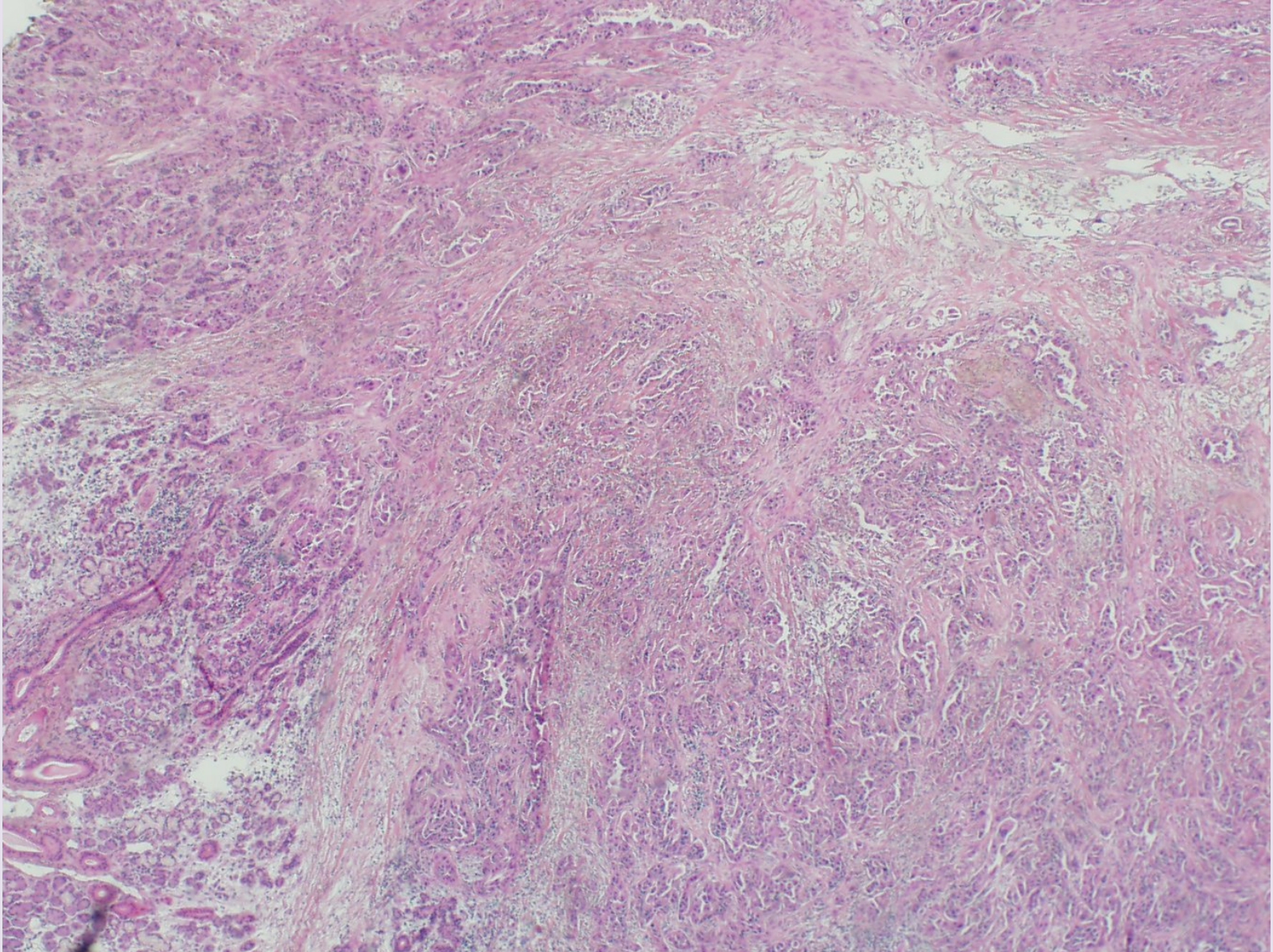
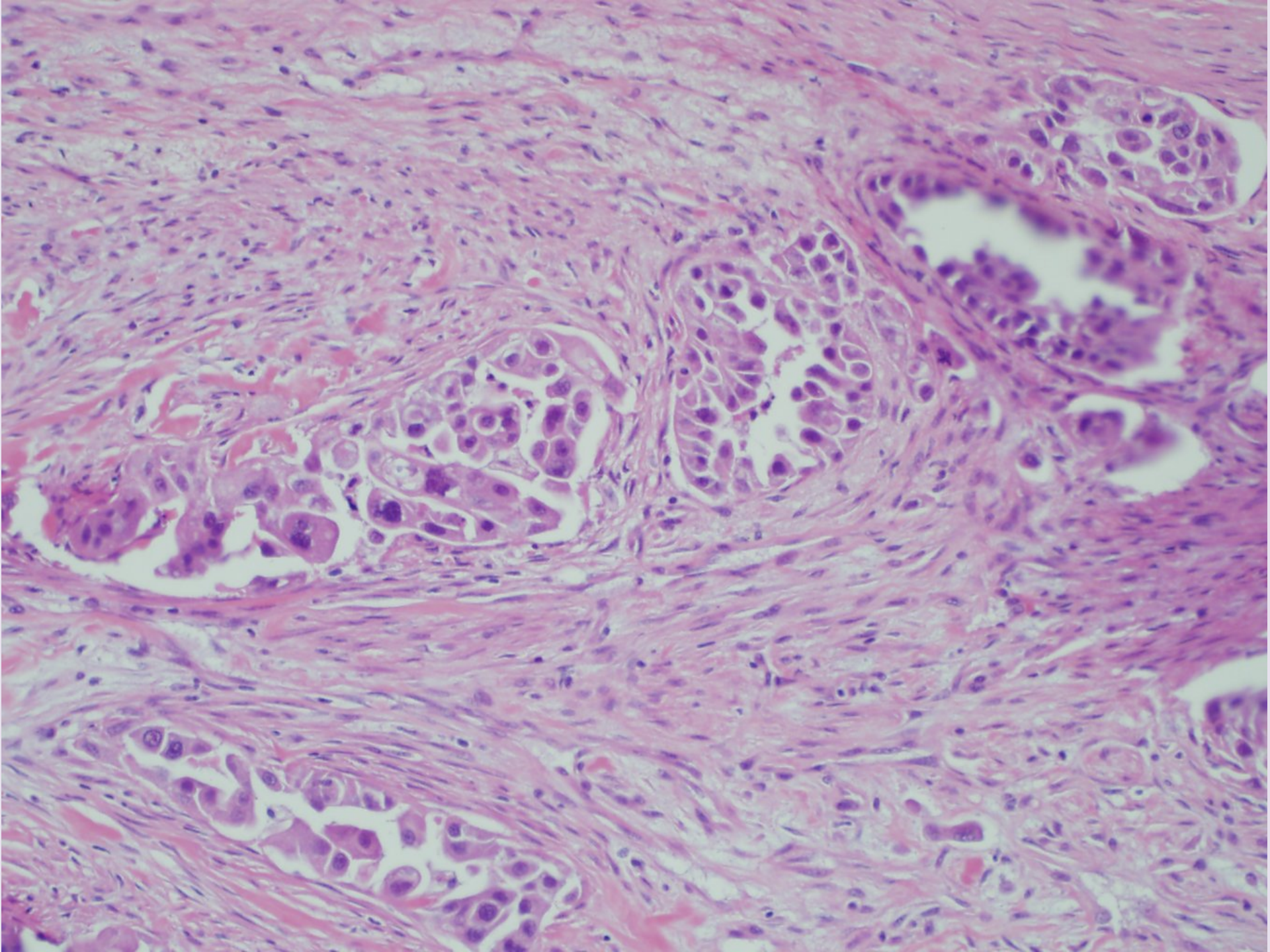


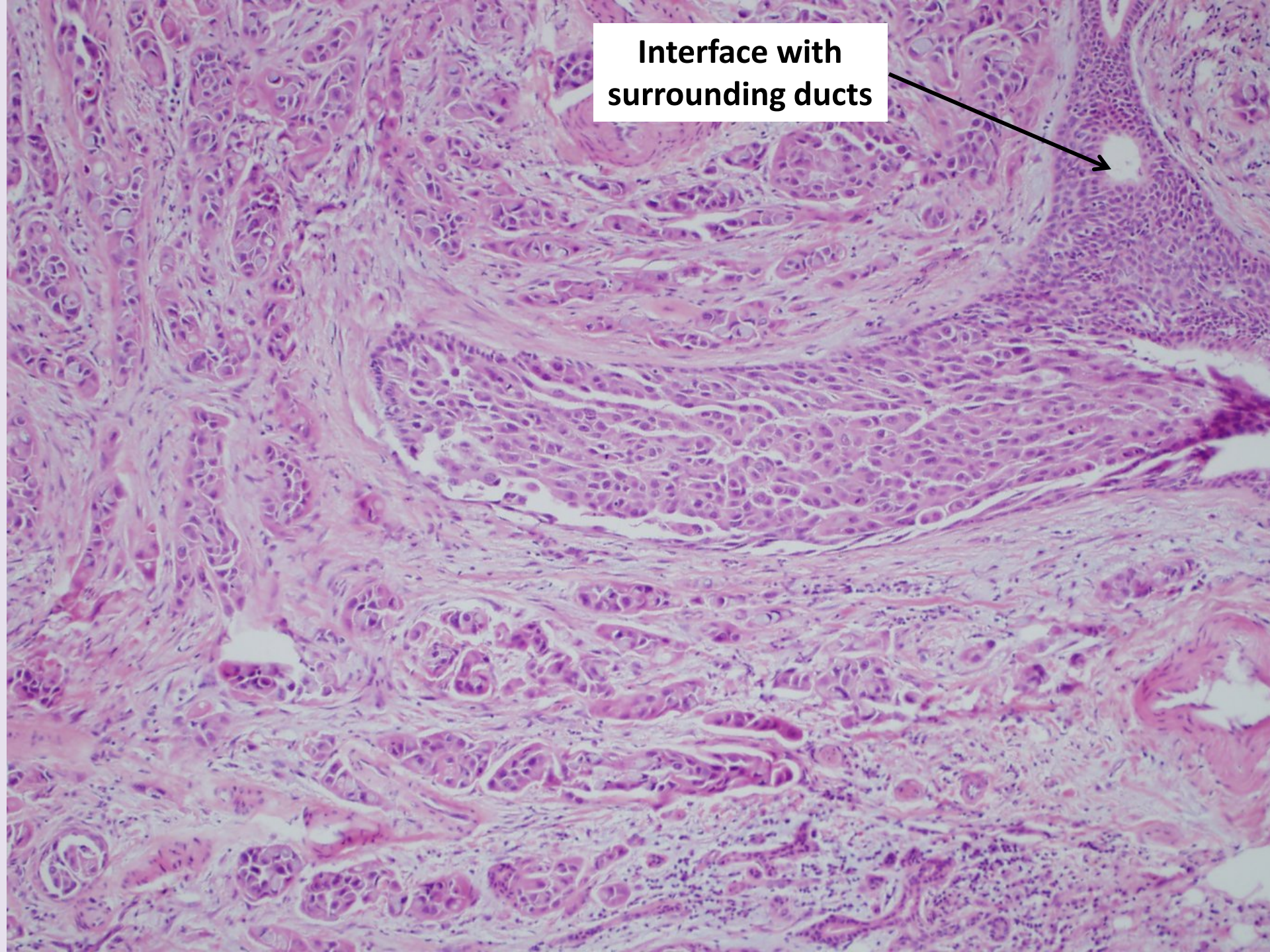
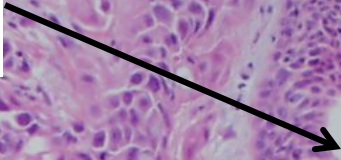
Image adapted from Chenevert et al. *Modern Pathology* (2012) 25,919-29

55 year old female with parotid mass and mediastinal/abdominal adenopathy

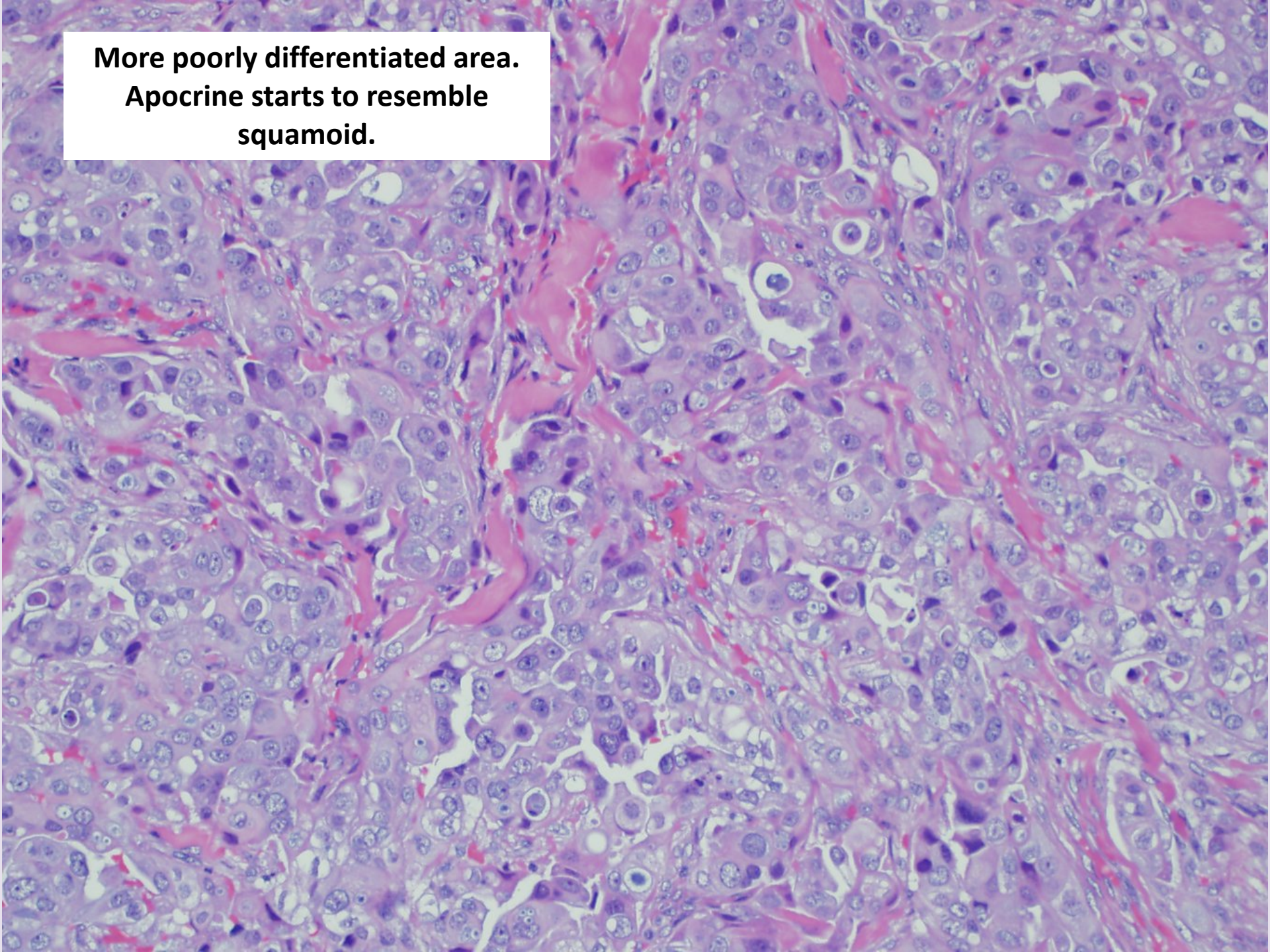




**Interface with
surrounding ducts**



**More poorly differentiated area.
Apocrine starts to resemble
squamous.**



An Immunohistochemical Panel for Reliable Differentiation of Salivary Duct Carcinoma and Mucoepidermoid Carcinoma

- SDC is often mistakenly diagnosed as high grade MEC
 - Apocrine features of SDC can mimic squamoid of MEC
 - Vacuolated cells of SDC can mimic mucocytes of MEC
- Given emerging evidence that biologic therapies may have a role in the management of SDC it is an important distinction

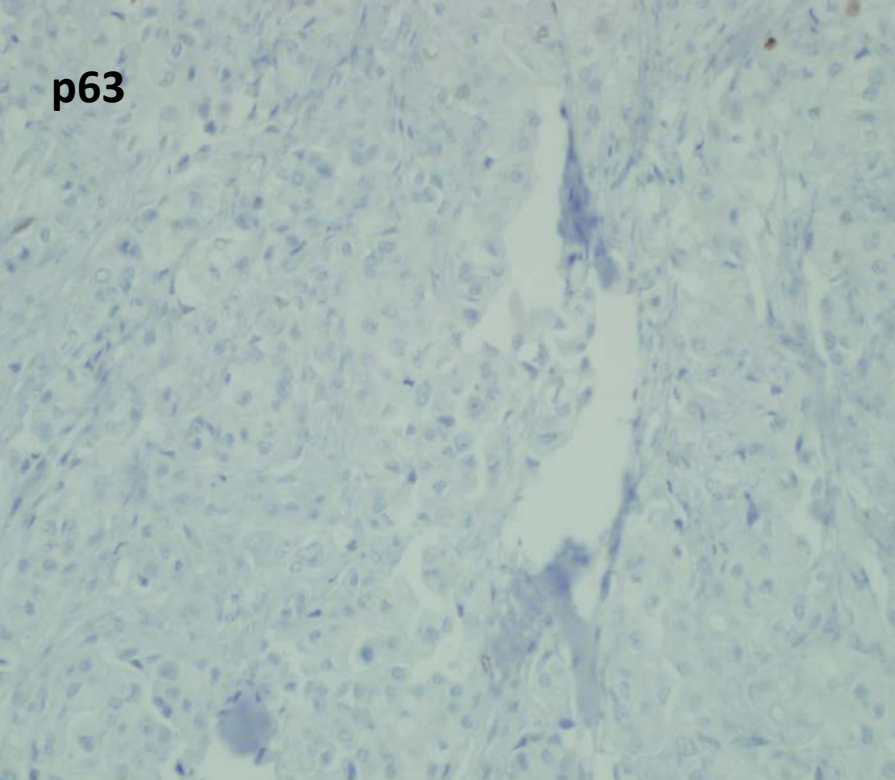
An Immunohistochemical Panel for Reliable Differentiation of Salivary Duct Carcinoma and Mucoepidermoid Carcinoma

	SDC	MEC
p63	- (87% had no staining)	+
CK 5/6	- (63% had no staining)	+
AR	+ (67-100%)	- (100%)
Her2/Neu	+/-	- (100% 0 to 1+)
GATA 3	+ (100%, 25/25 typically strong)	-/+ (41%, 11/27 variable)

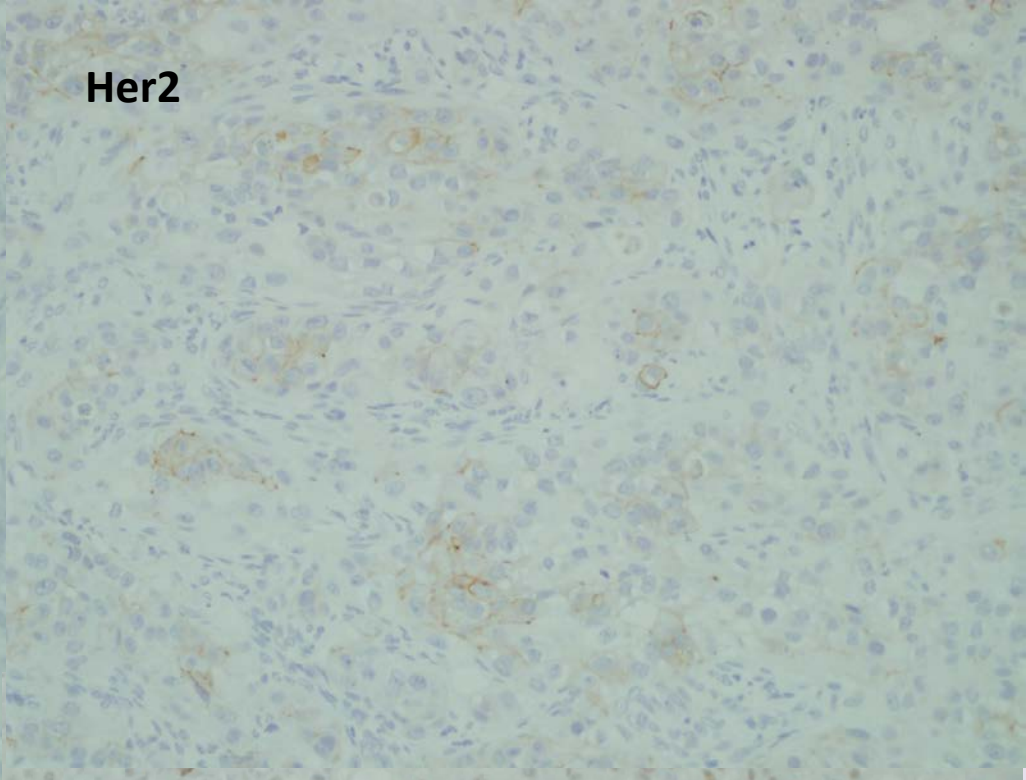
Schwartz et al. *Head and Neck Pathol.* 2013;7:311-315

Butler RT et al. *Head and Neck Pathol.* 2014; 8:133-140

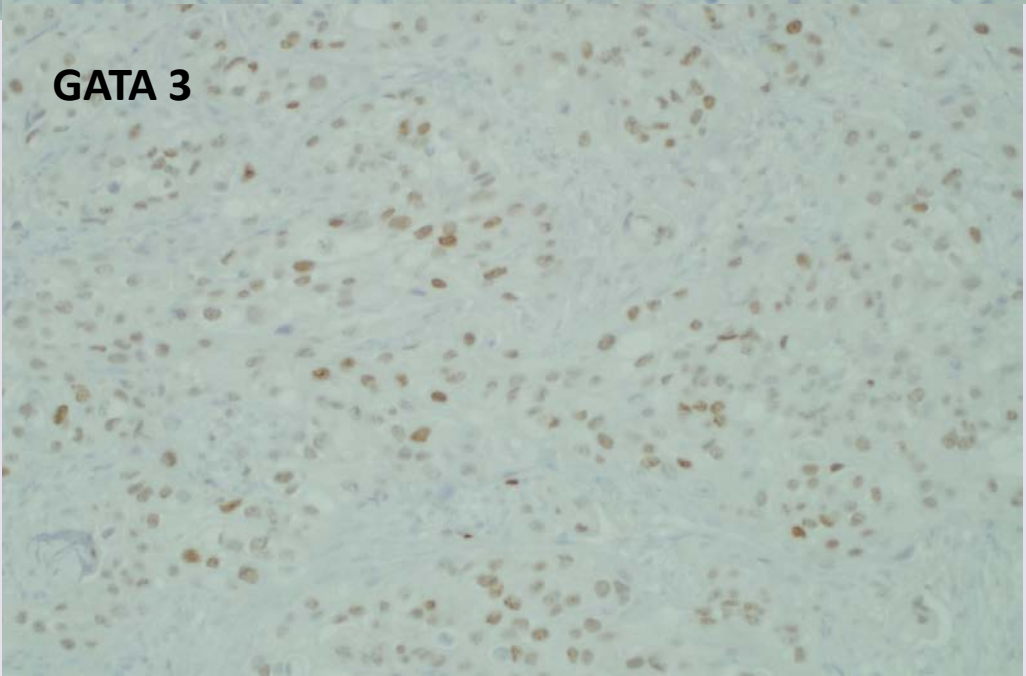
p63



Her2



GATA 3

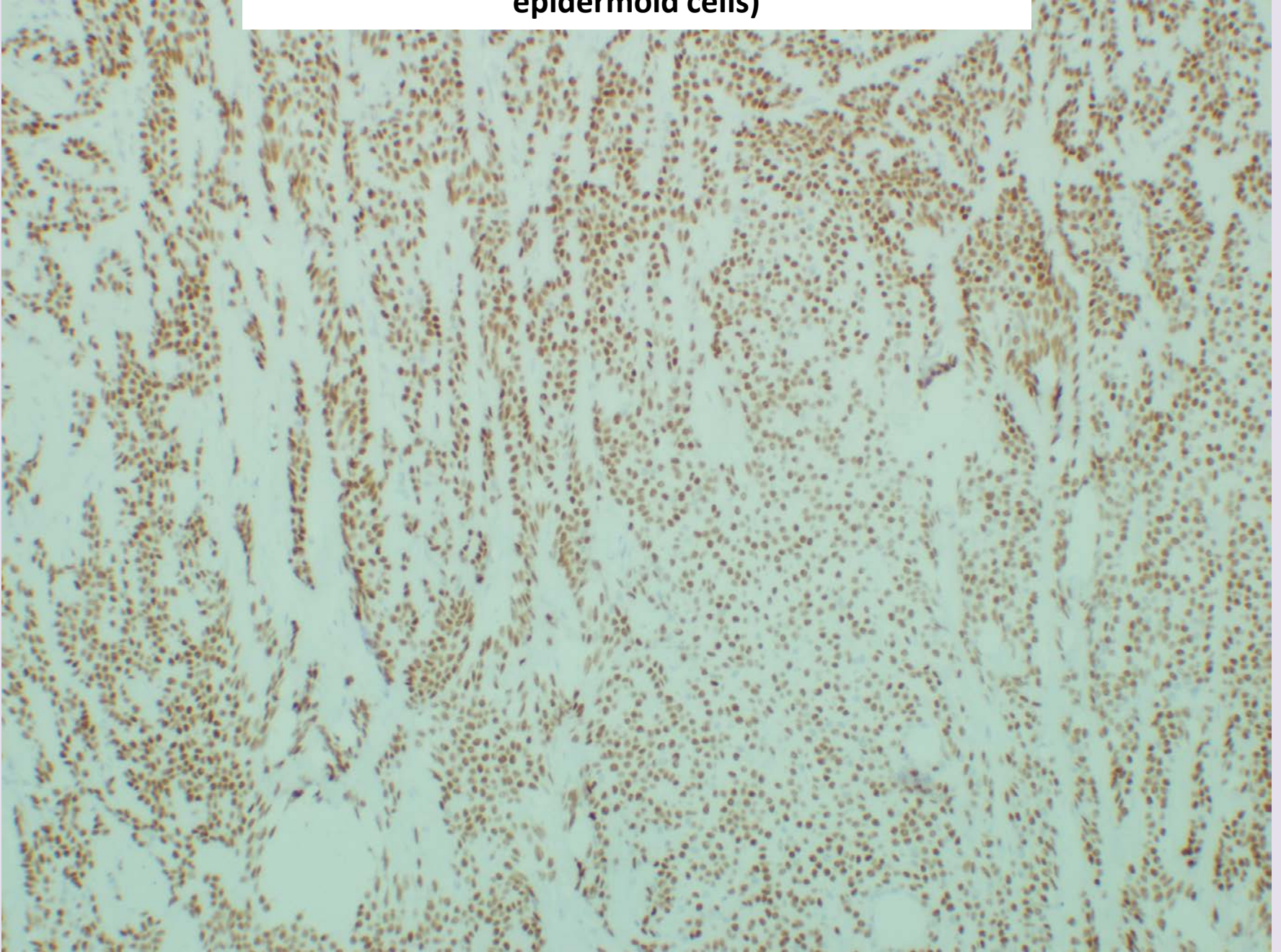


Our case from above

Our Case

- Overall morphology most consistent with SDC
 - ductal interface
 - apocrine features predominate
- IHC pattern supports SDC
 - convincing GATA 3 nuclear staining
 - equivocal HER2 result
 - negative p63

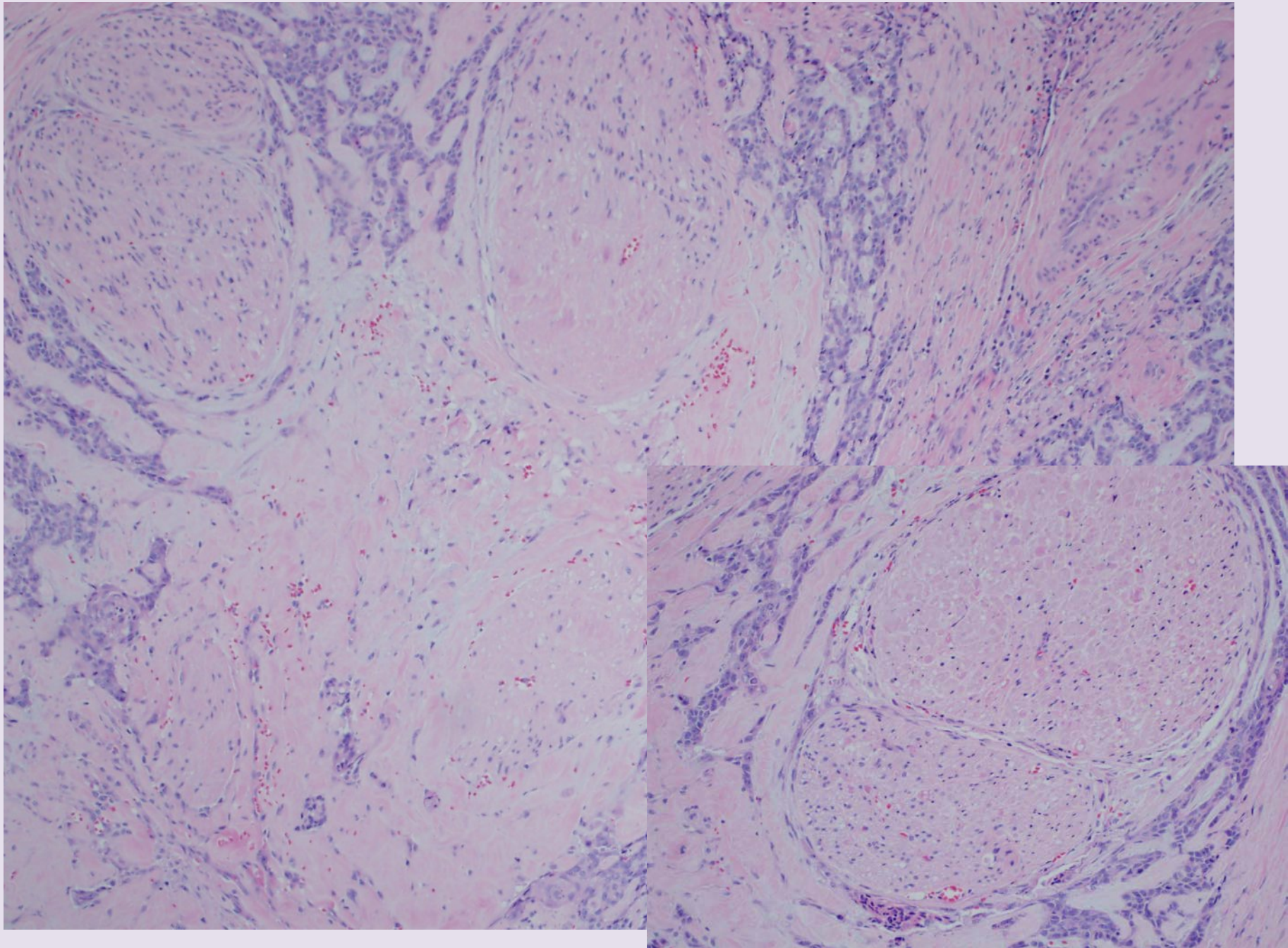
Expected result for p63 in a MEC (Intermediate to epidermoid cells)

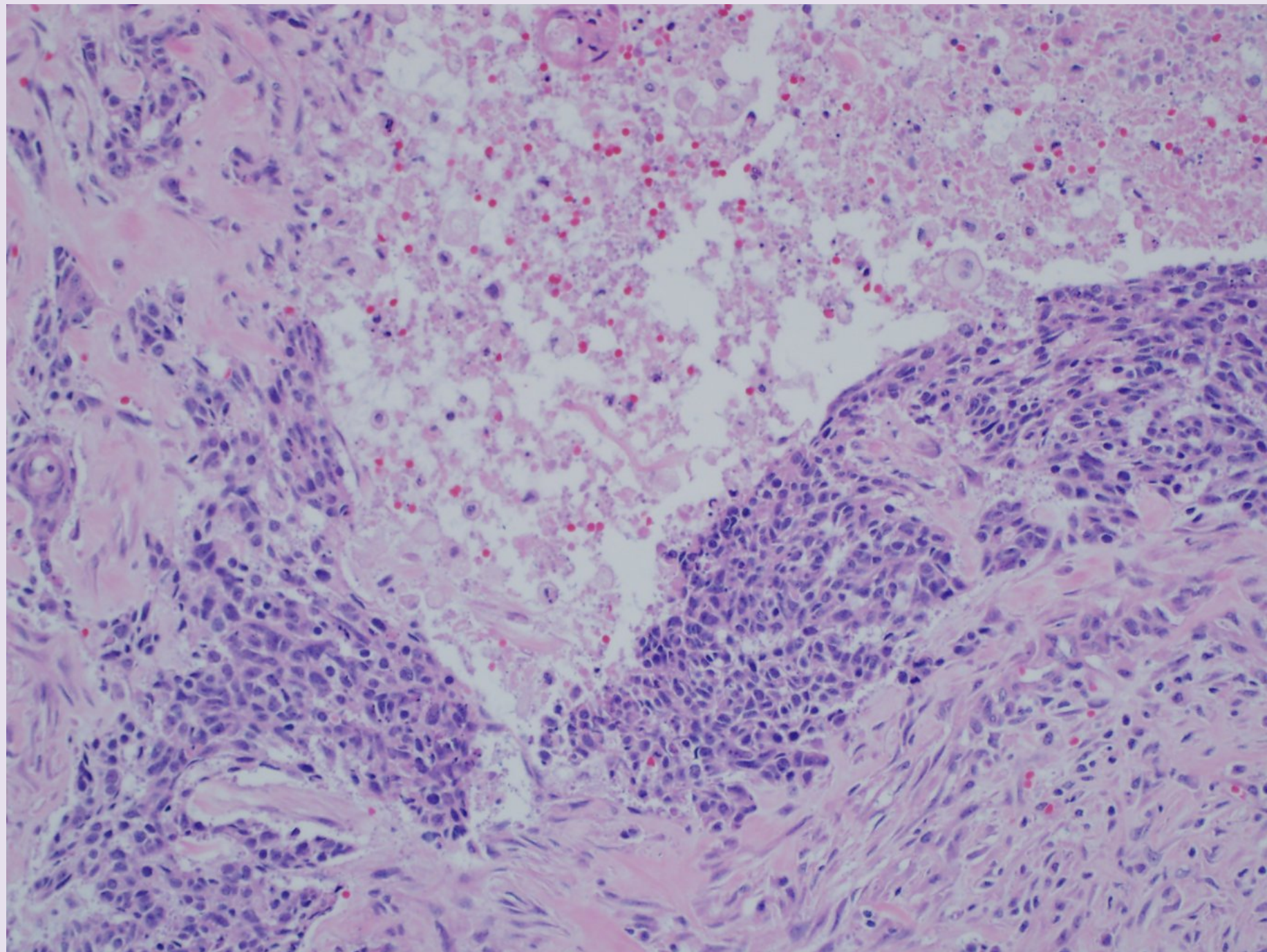


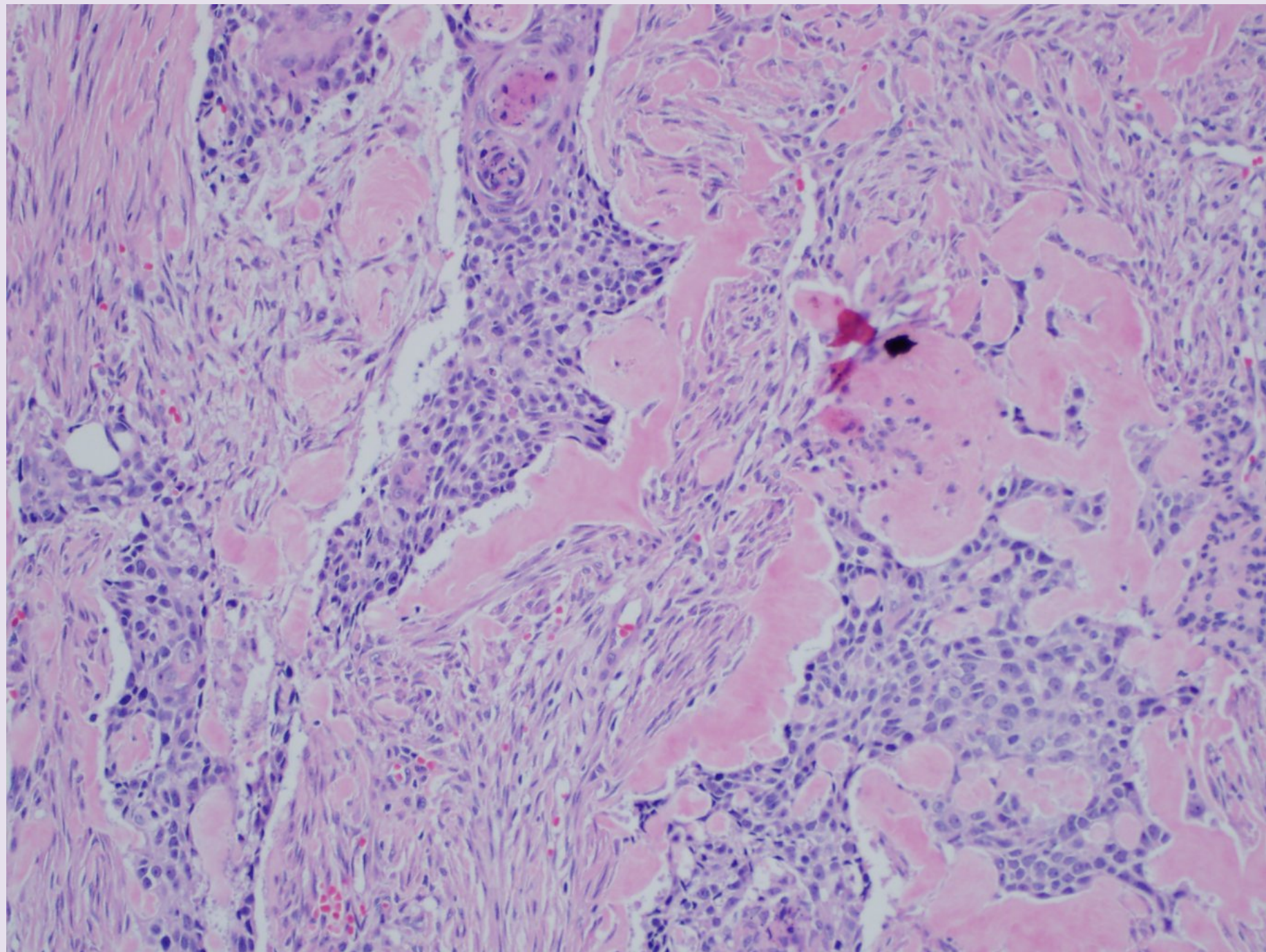
High Grade Transformation (Dedifferentiation) in Salivary Gland Carcinomas

- Has been described in several of the common salivary gland carcinomas
- This is distinct from hybrid carcinomas (2 distinct tumor entities)
- Abrupt transition of a well-differentiated tumor into a high-grade appearance
- In general the transformed component shows different growth pattern, as well as increased pleomorphism, mitoses and necrosis
- Poor prognosis regardless of original tumor type

Parotid mass in 74 year old male with recent increase in size







Adenoid Cystic Carcinoma with High Grade Transformation

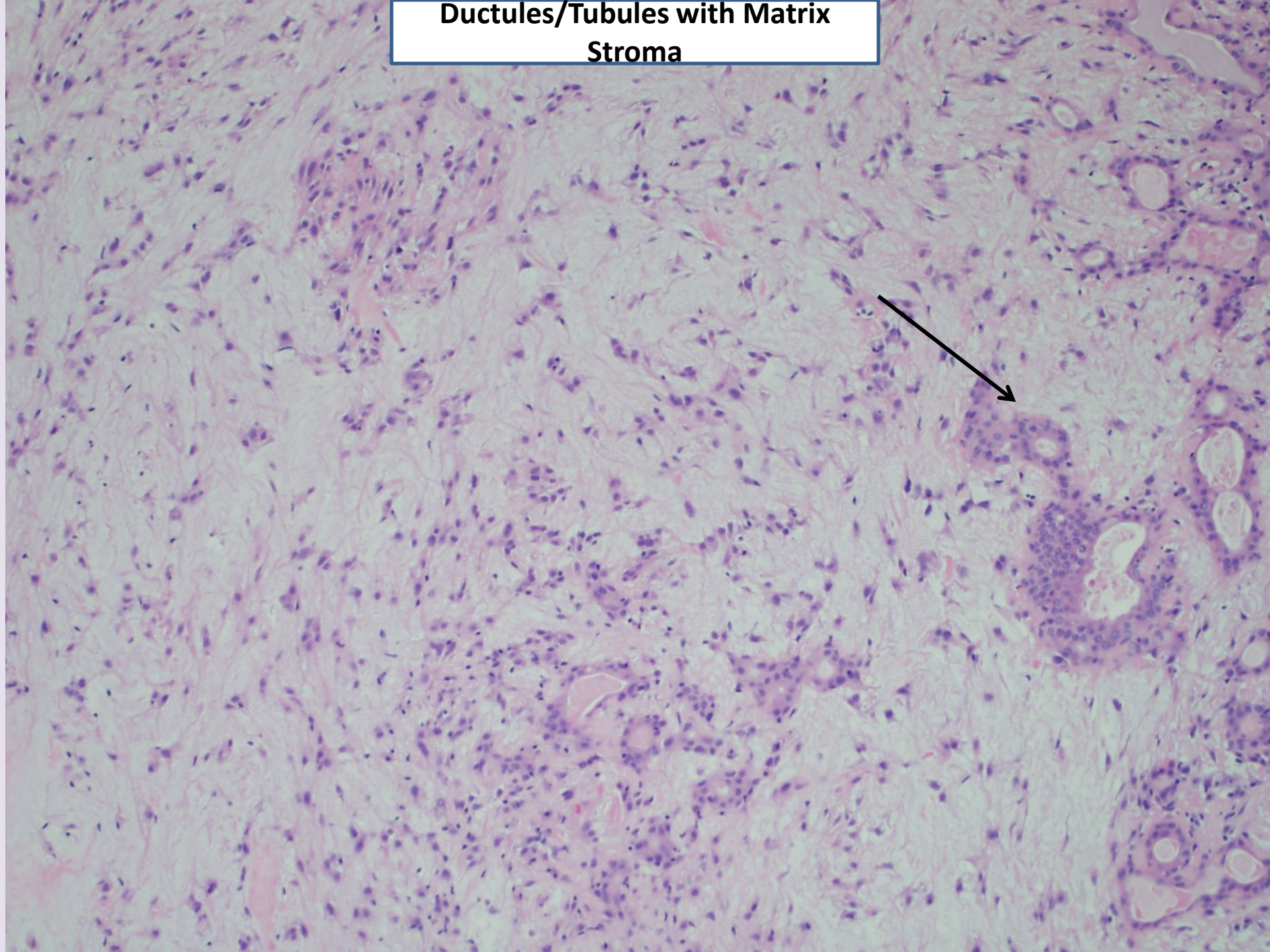
- Distinct from the solid pattern that is used to grade conventional adenoid cystic carcinoma
- The HGT component exhibits:
 - large pleomorphic nuclei
 - more cytoplasm than ACC
 - spans between poorly differentiated adenocarcinoma to solid nests with squamous eddies
- Worse prognosis than solid ACC; with mean survival of 3 years (in 24 patients)

Toshitaka Nagao. *Head and Neck Pathol.* 2013;7:S37-S47.

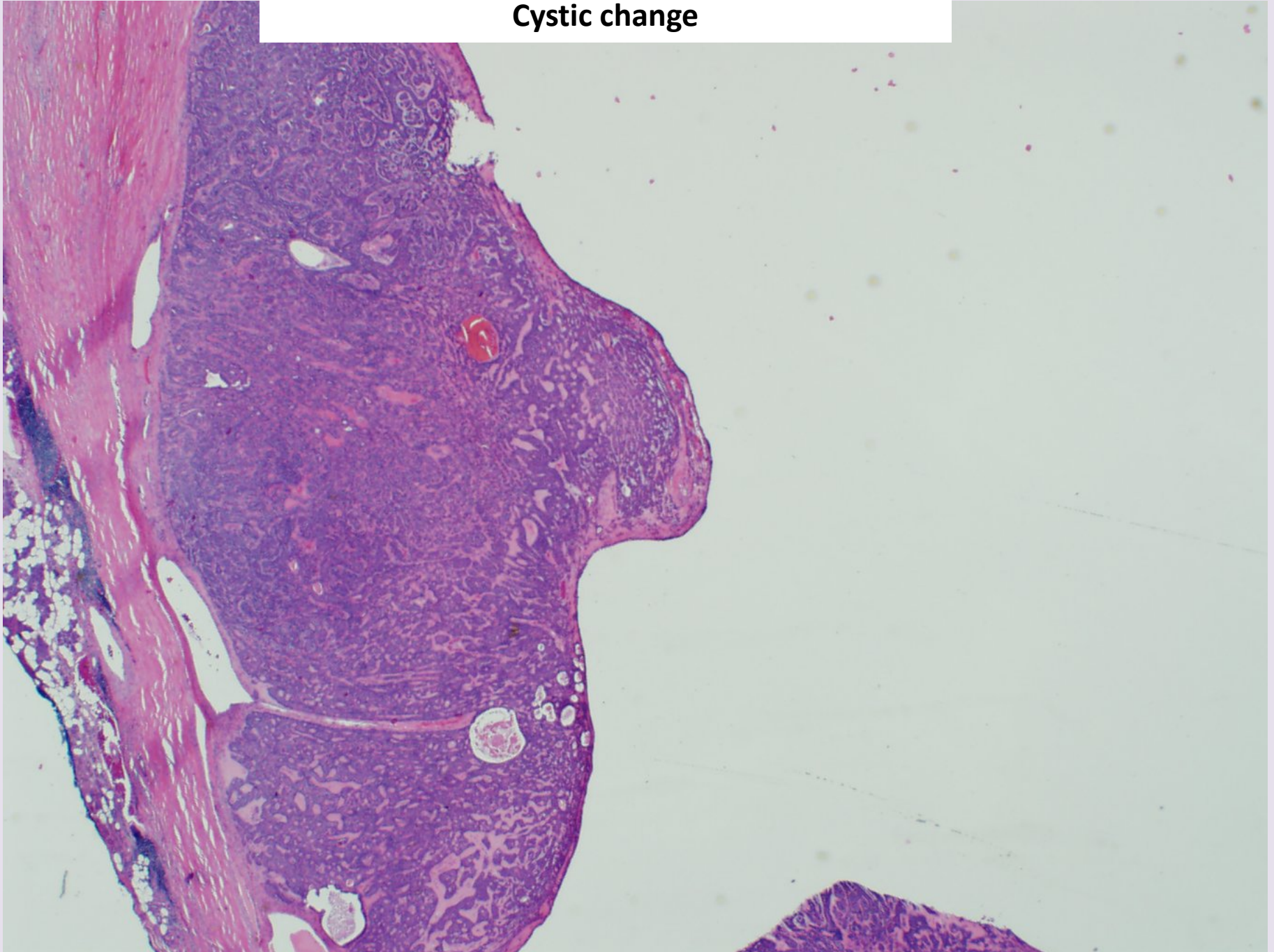
Pleomorphic Adenoma

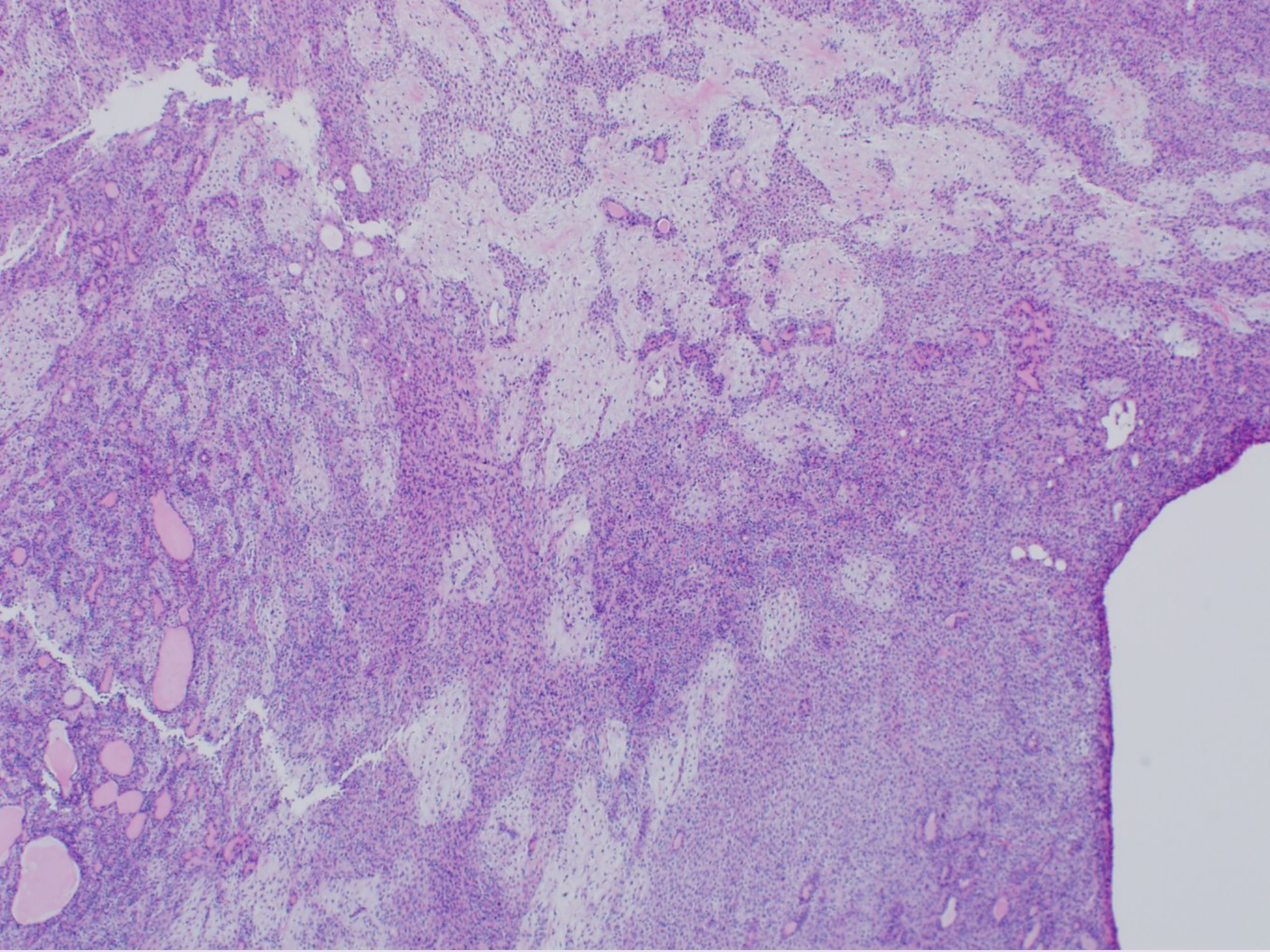
- One of the devil's cruelest tricks is the mimicry of PAs
 - More cellular/generally not encapsulated in minor salivary gland sites
 - Multilobular growth with irregular interface at periphery
 - Metaplasia (squamous, lipomatous, mucinous)
 - Varied growth patterns (can resemble adenoid cystic carcinoma)
- 70% of PAs have either *PLAG1* or *HMGA2* gene rearrangement

Ductules/Tubules with Matrix
Stroma

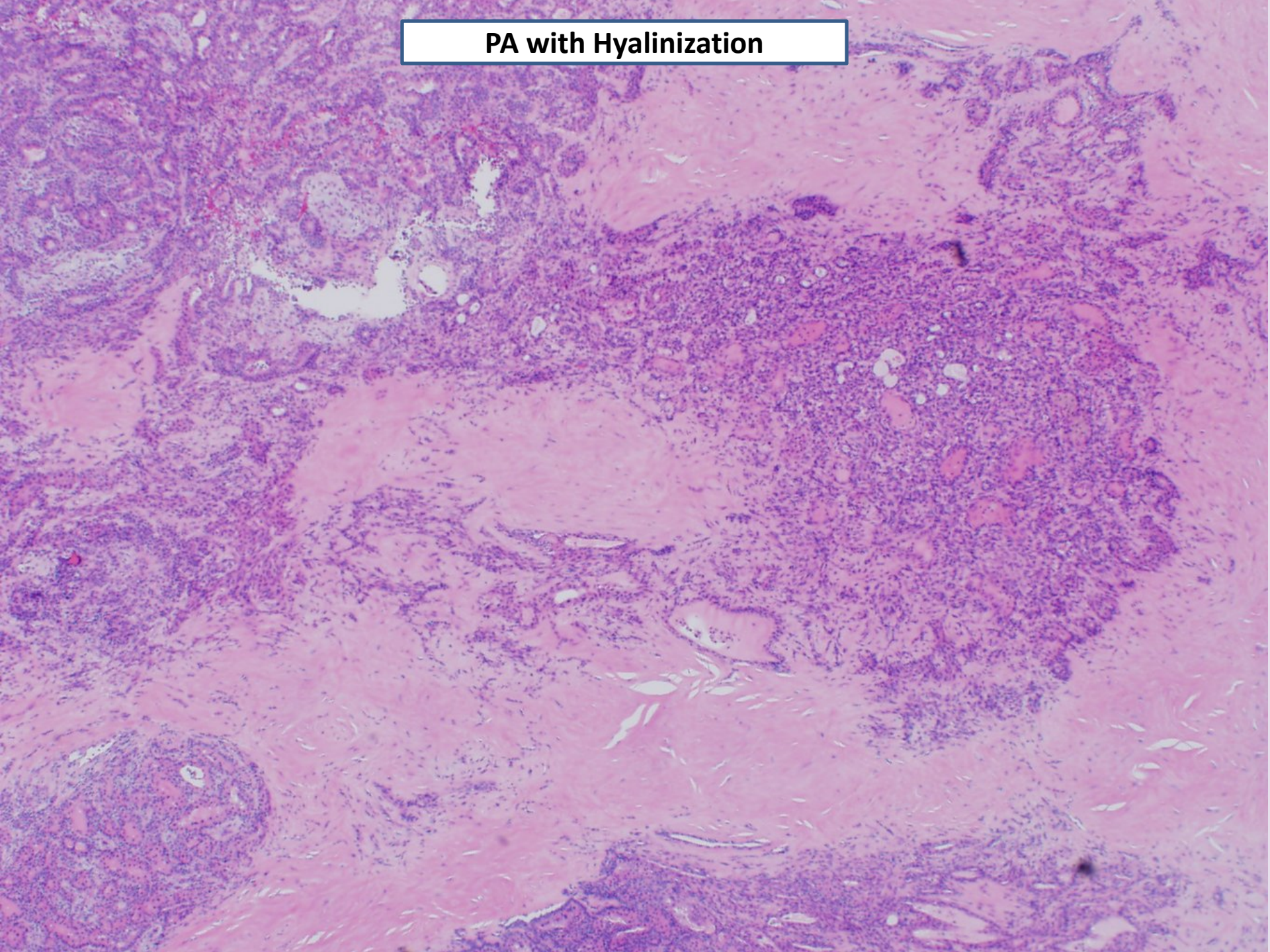


**48 year old male with 3.5 cm parotid mass,
Cystic change**

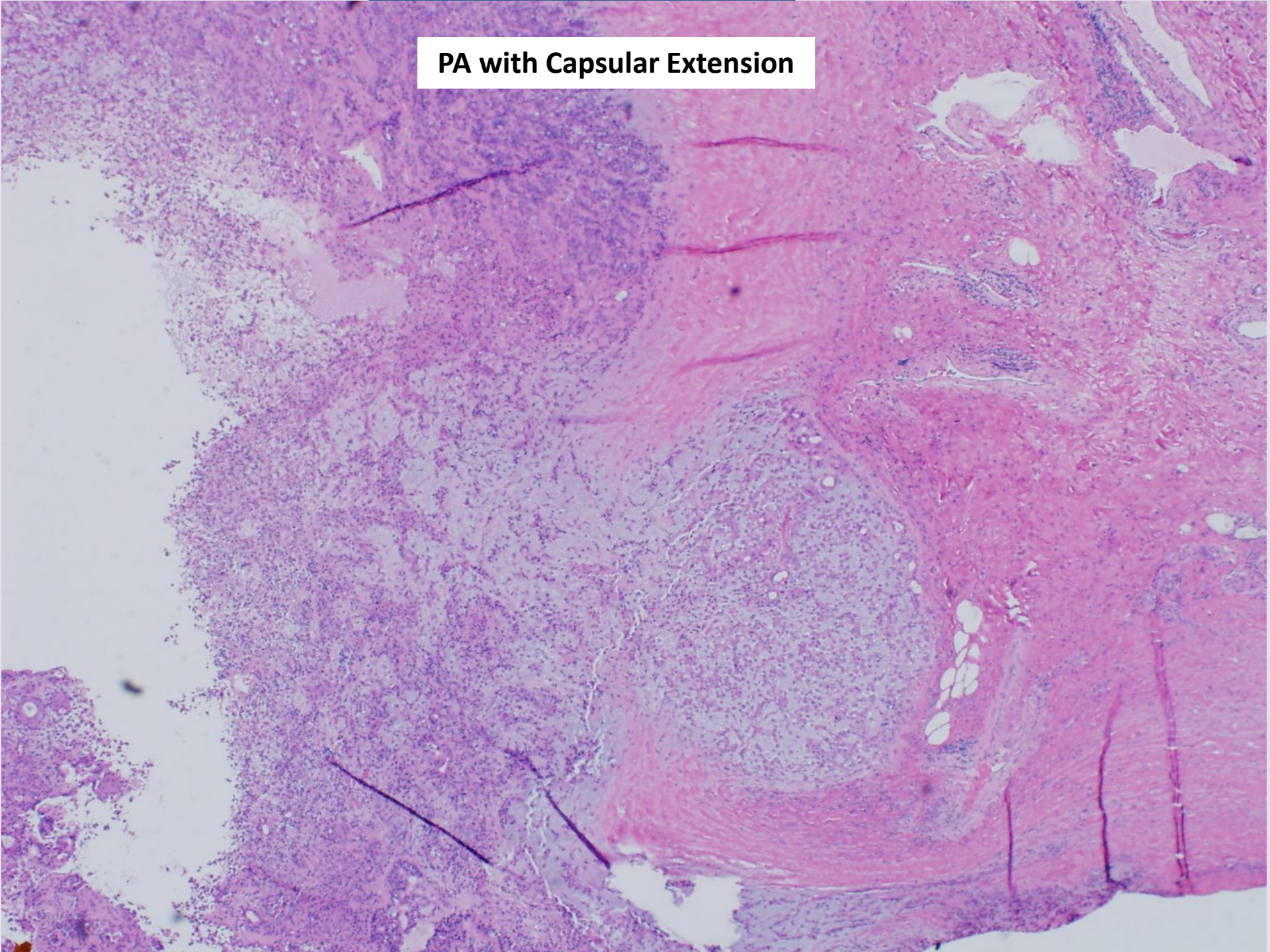




PA with Hyalinization



PA with Capsular Extension

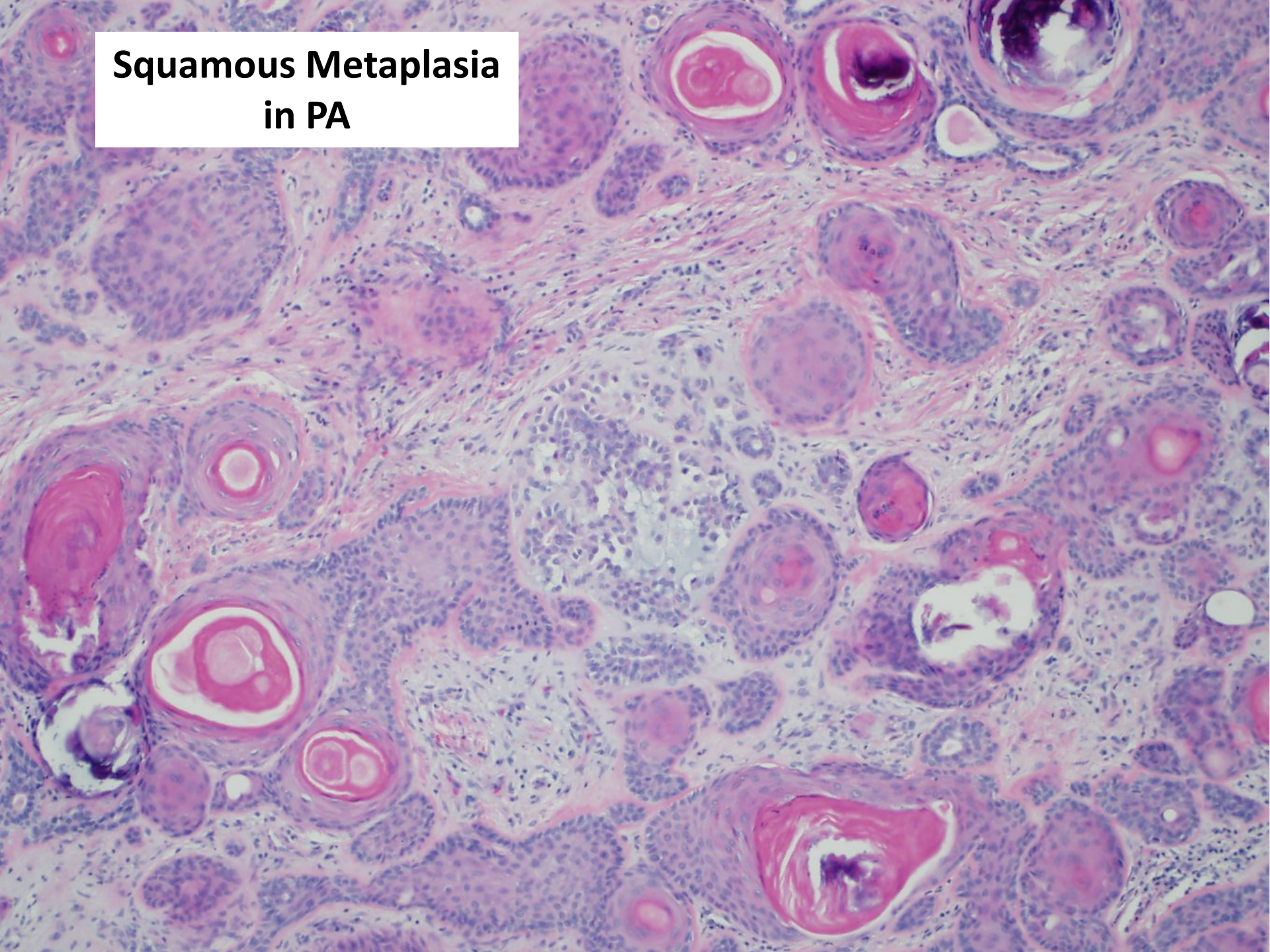


PA with Benign Vascular Invasion

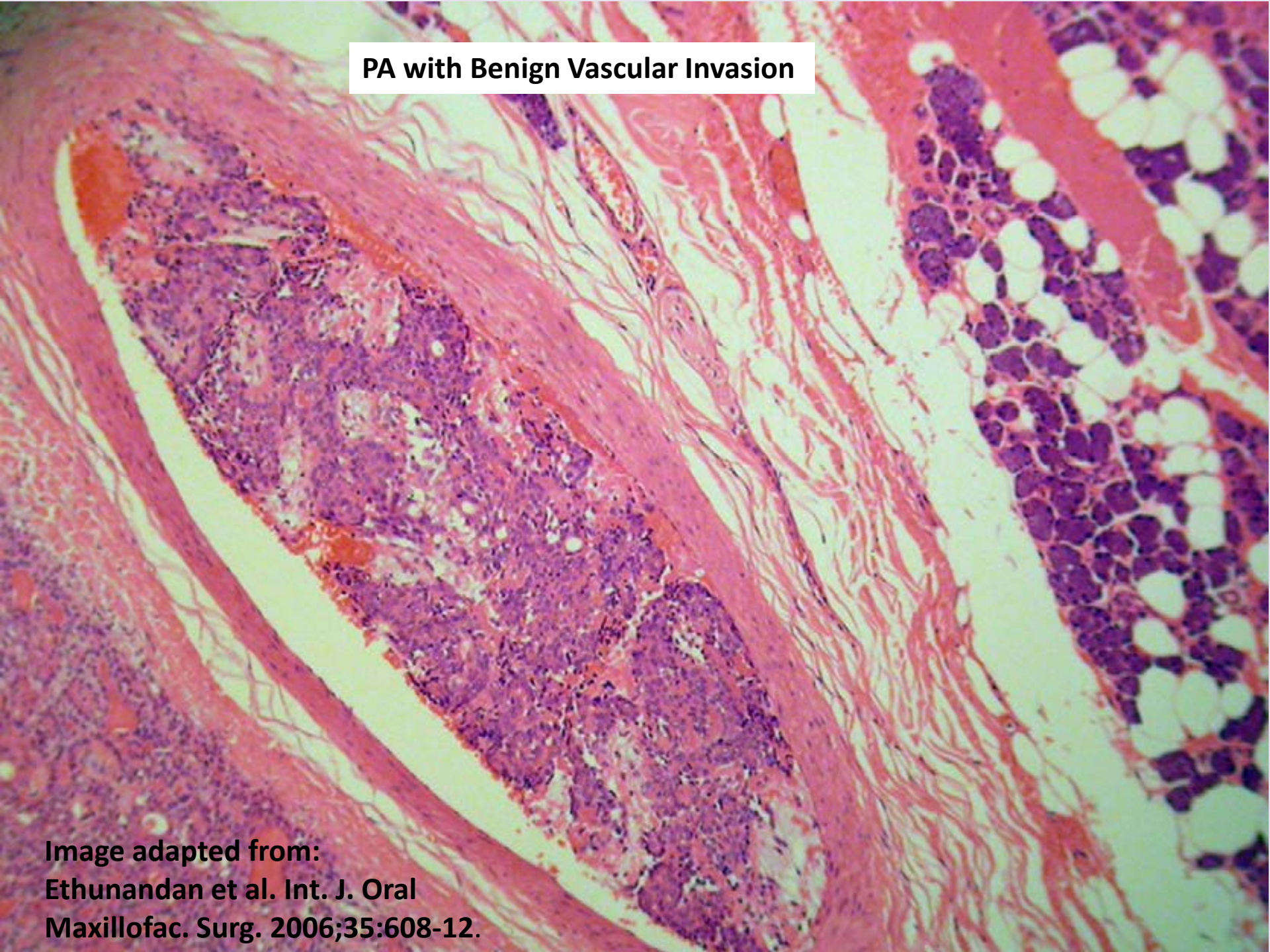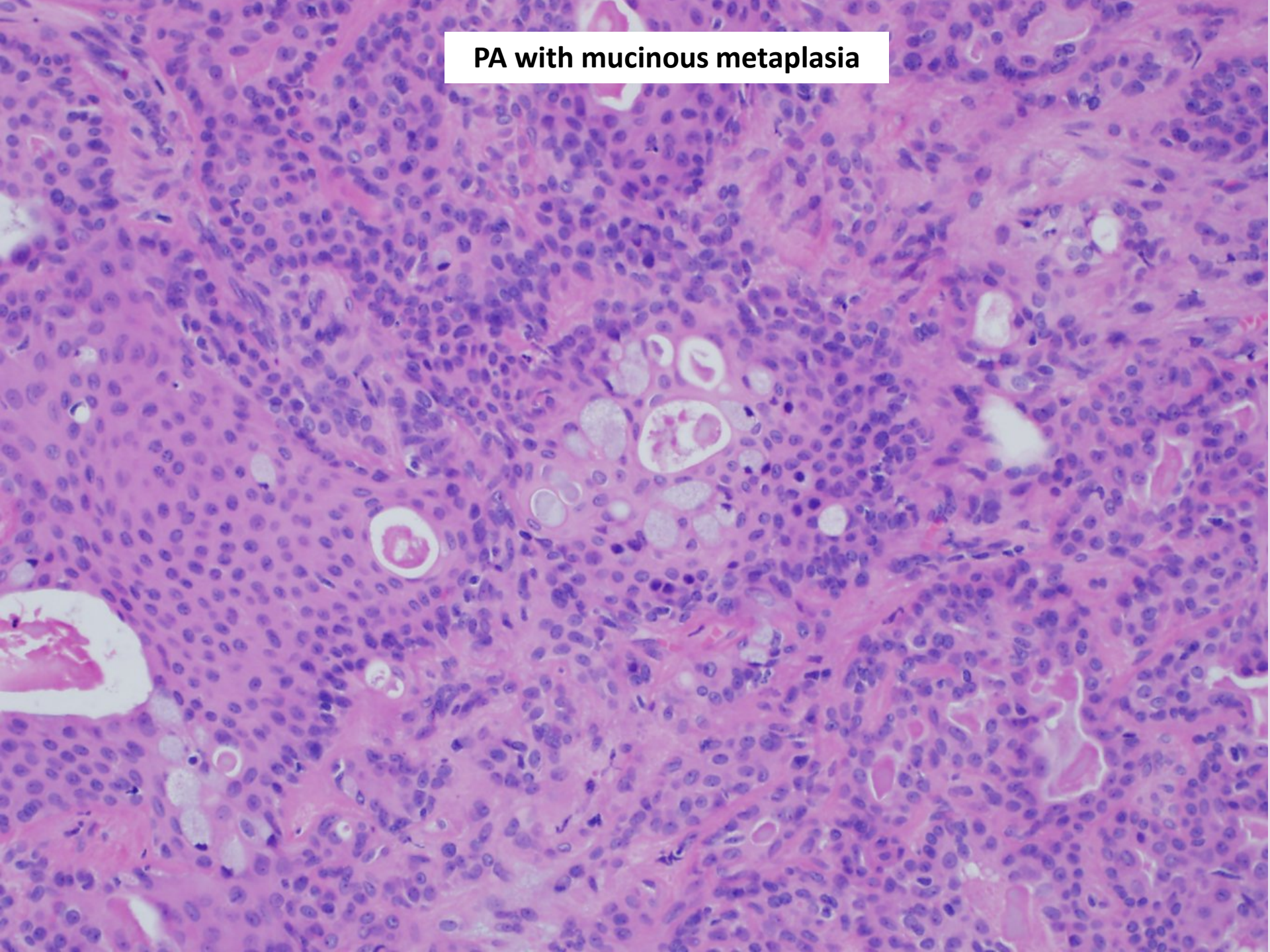


Image adapted from:
Ethunandan et al. *Int. J. Oral
Maxillofac. Surg.* 2006;35:608-12.

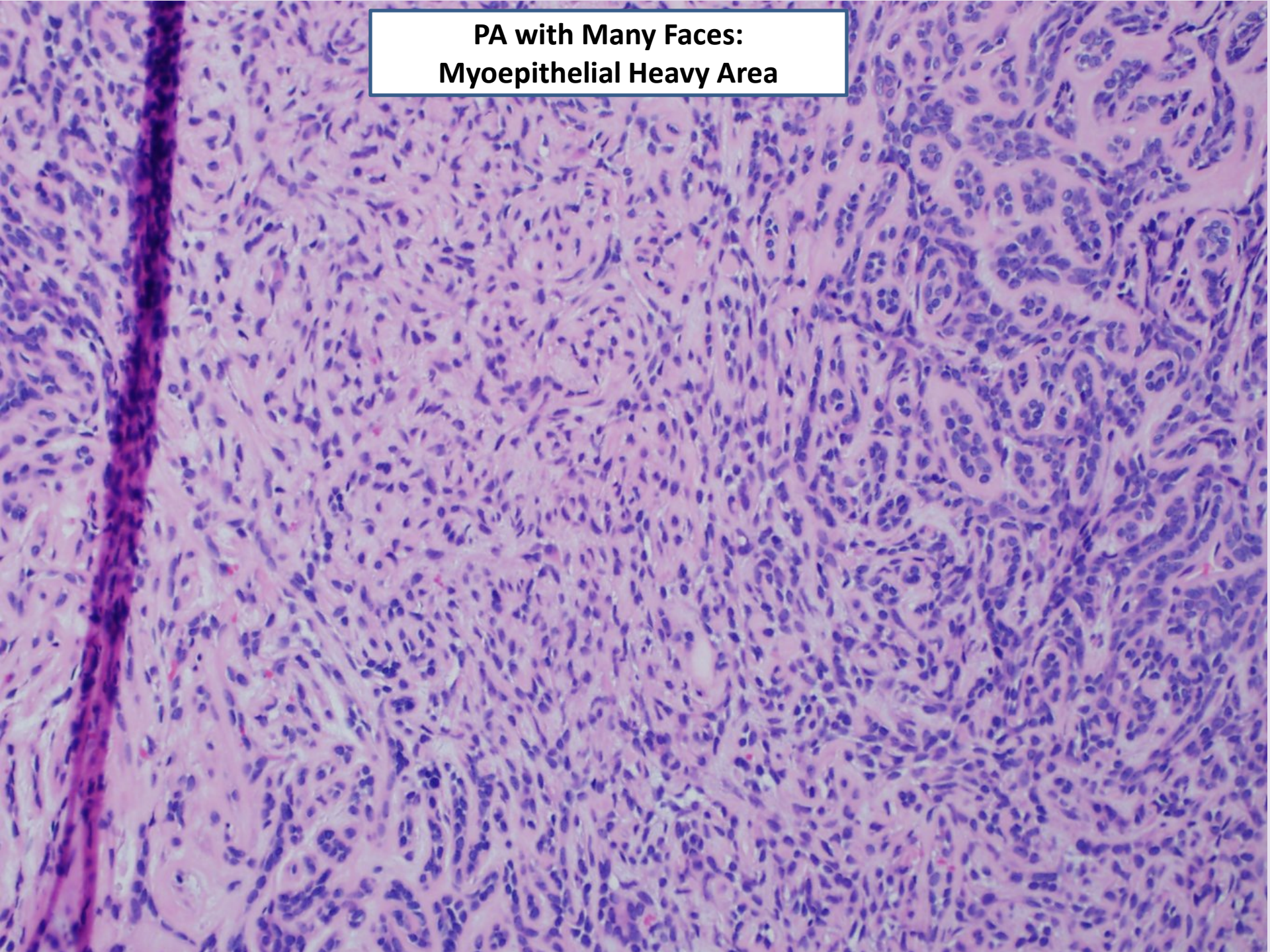
**Squamous Metaplasia
in PA**



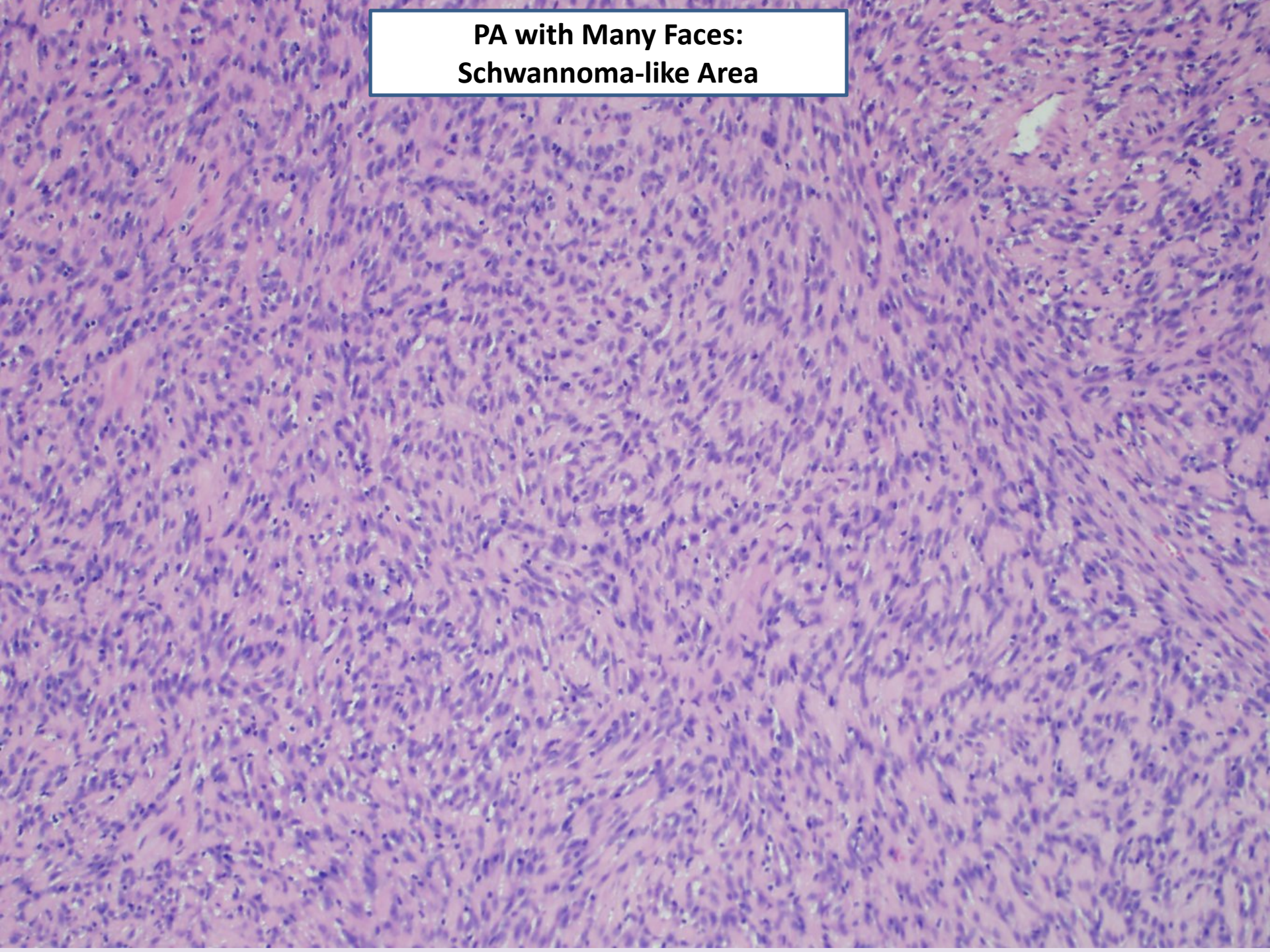
PA with mucinous metaplasia



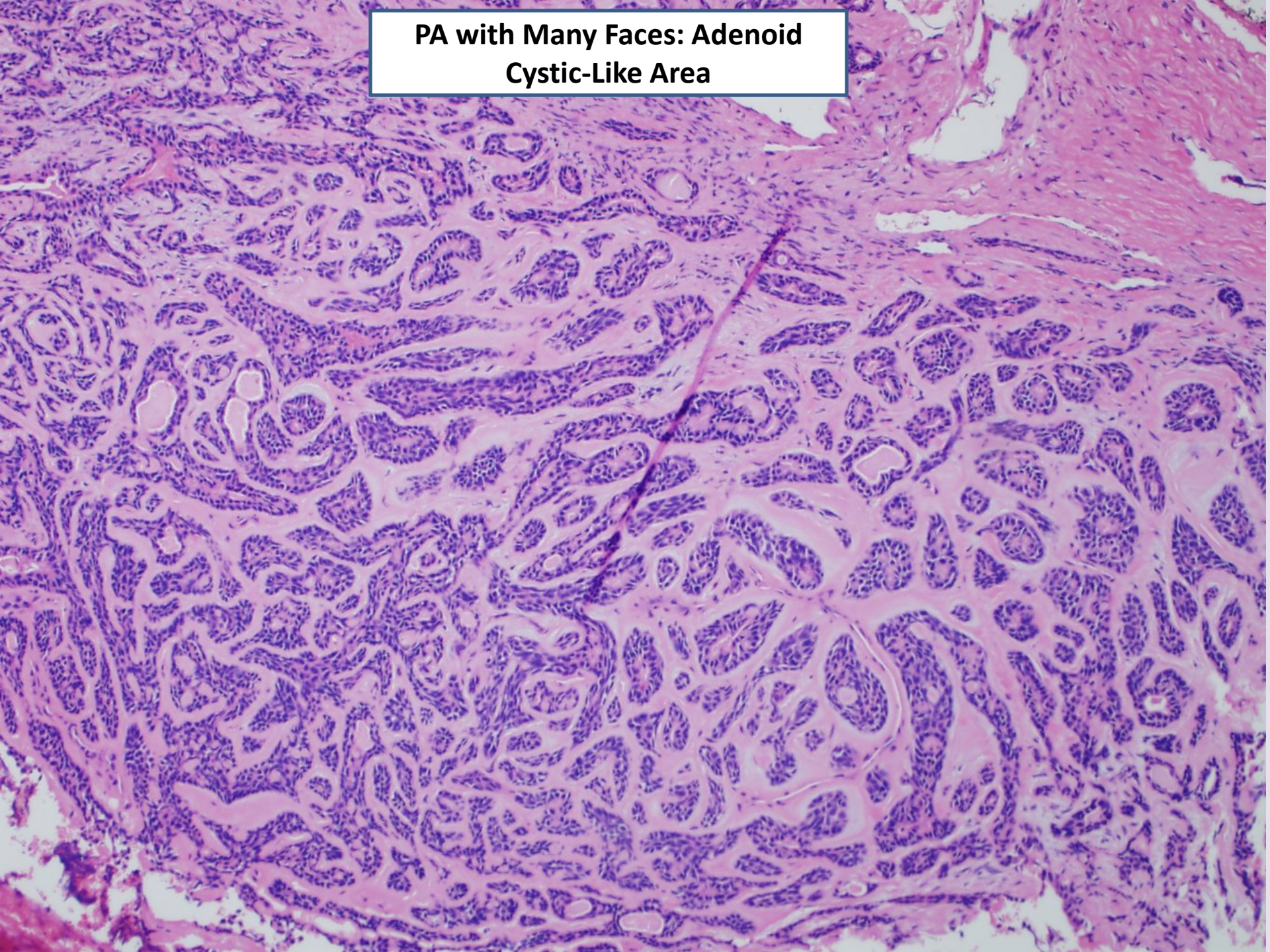
**PA with Many Faces:
Myoepithelial Heavy Area**



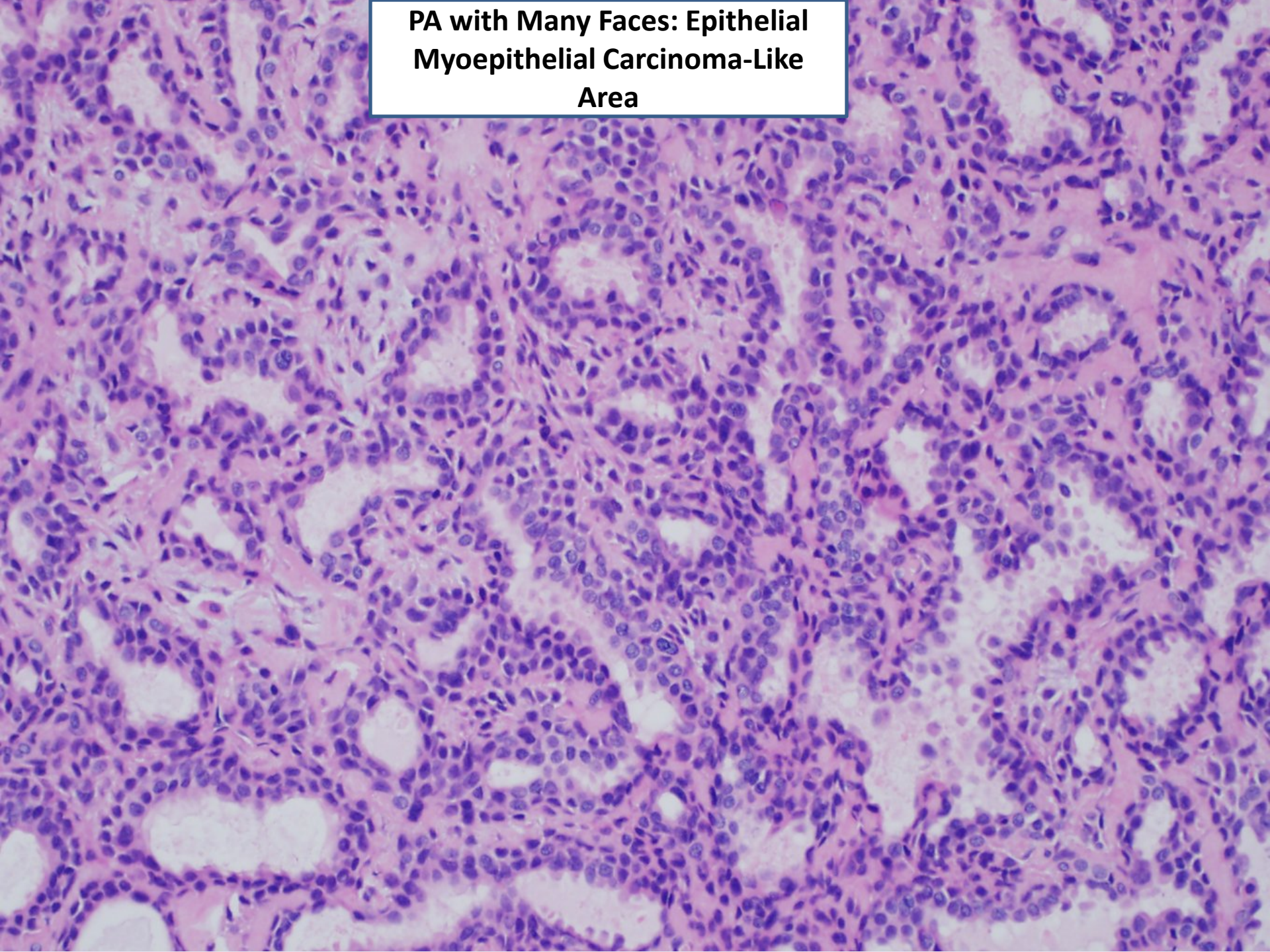
**PA with Many Faces:
Schwannoma-like Area**



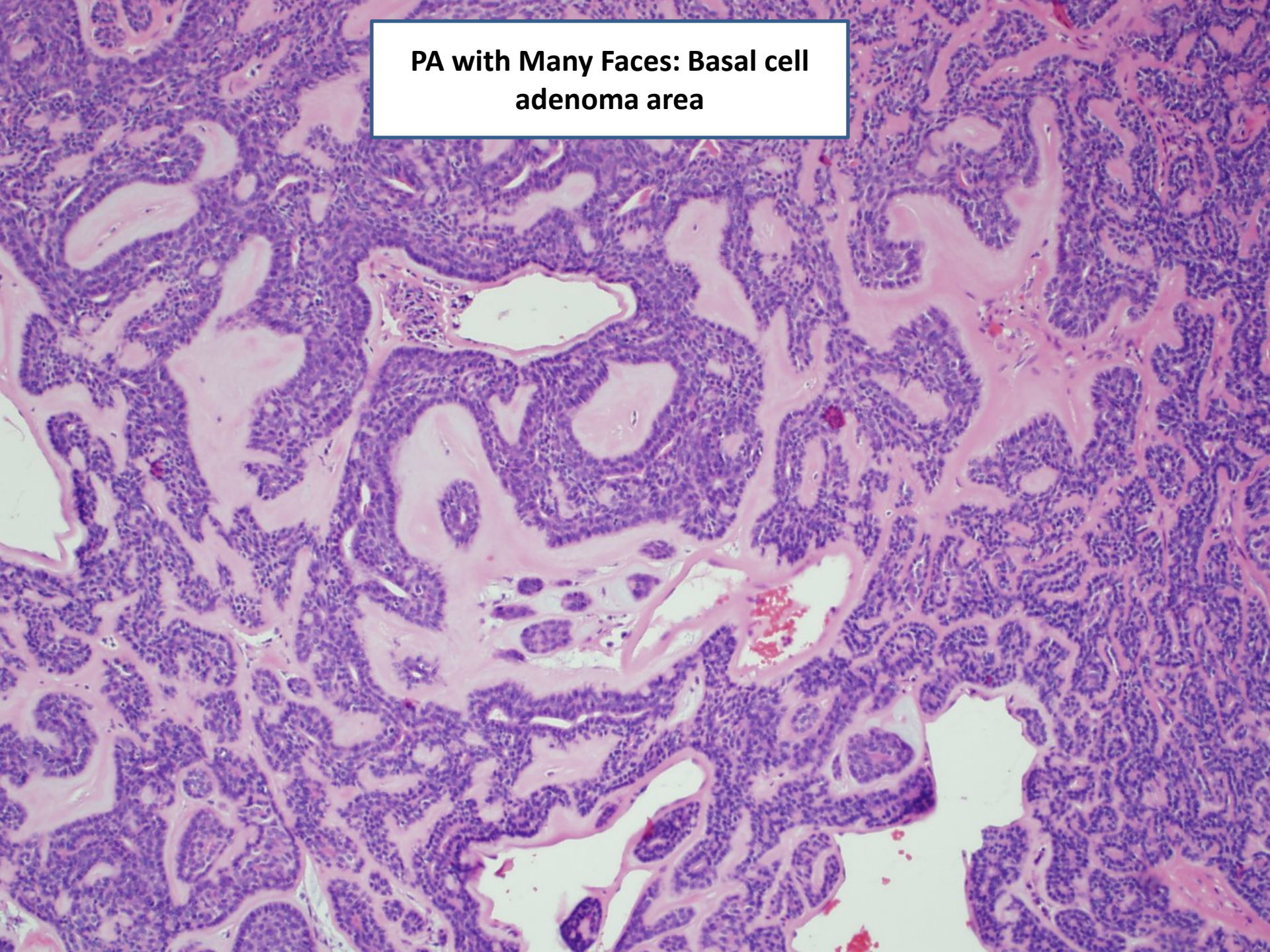
**PA with Many Faces: Adenoid
Cystic-Like Area**



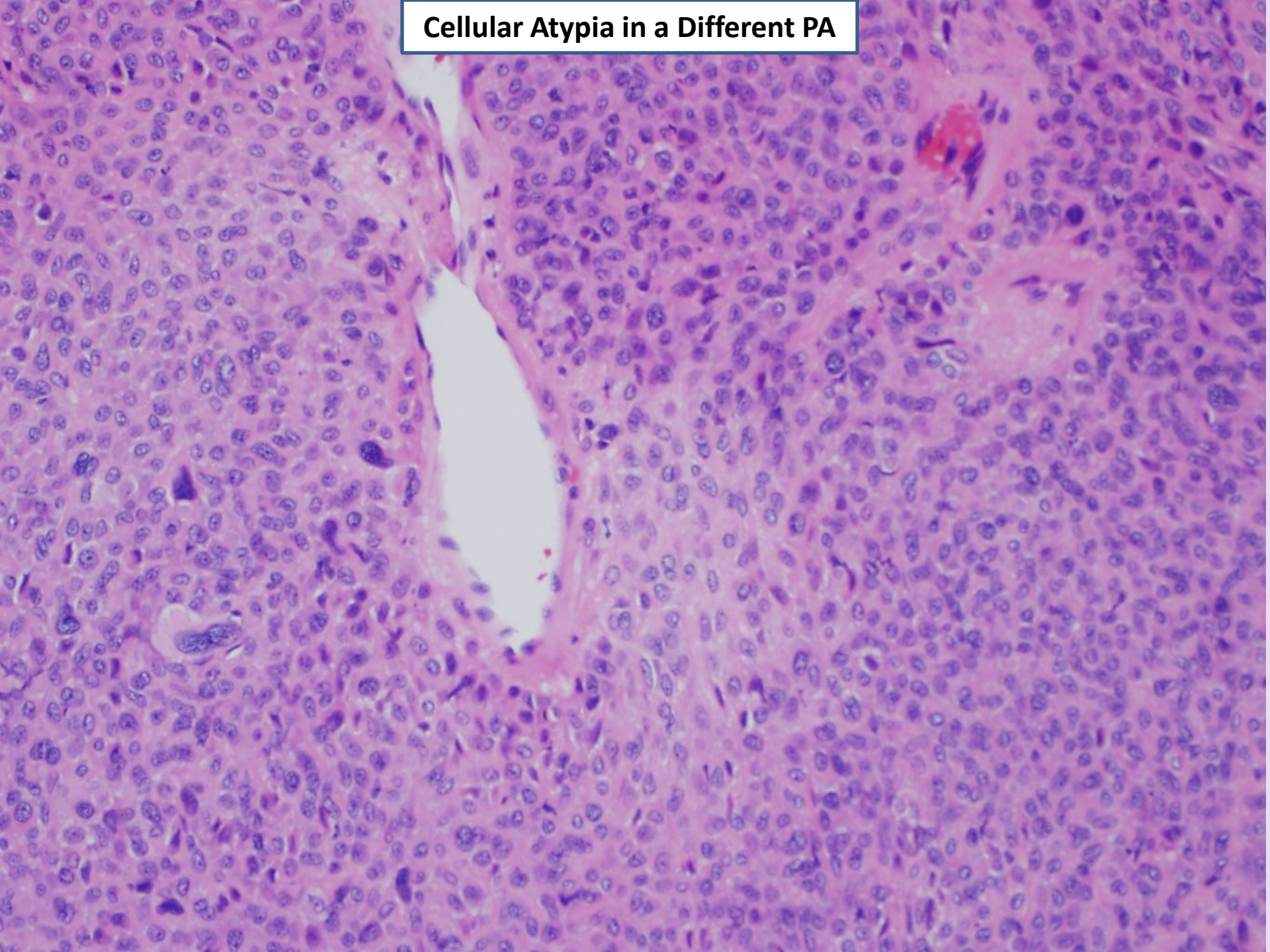
**PA with Many Faces: Epithelial
Myoepithelial Carcinoma-Like
Area**



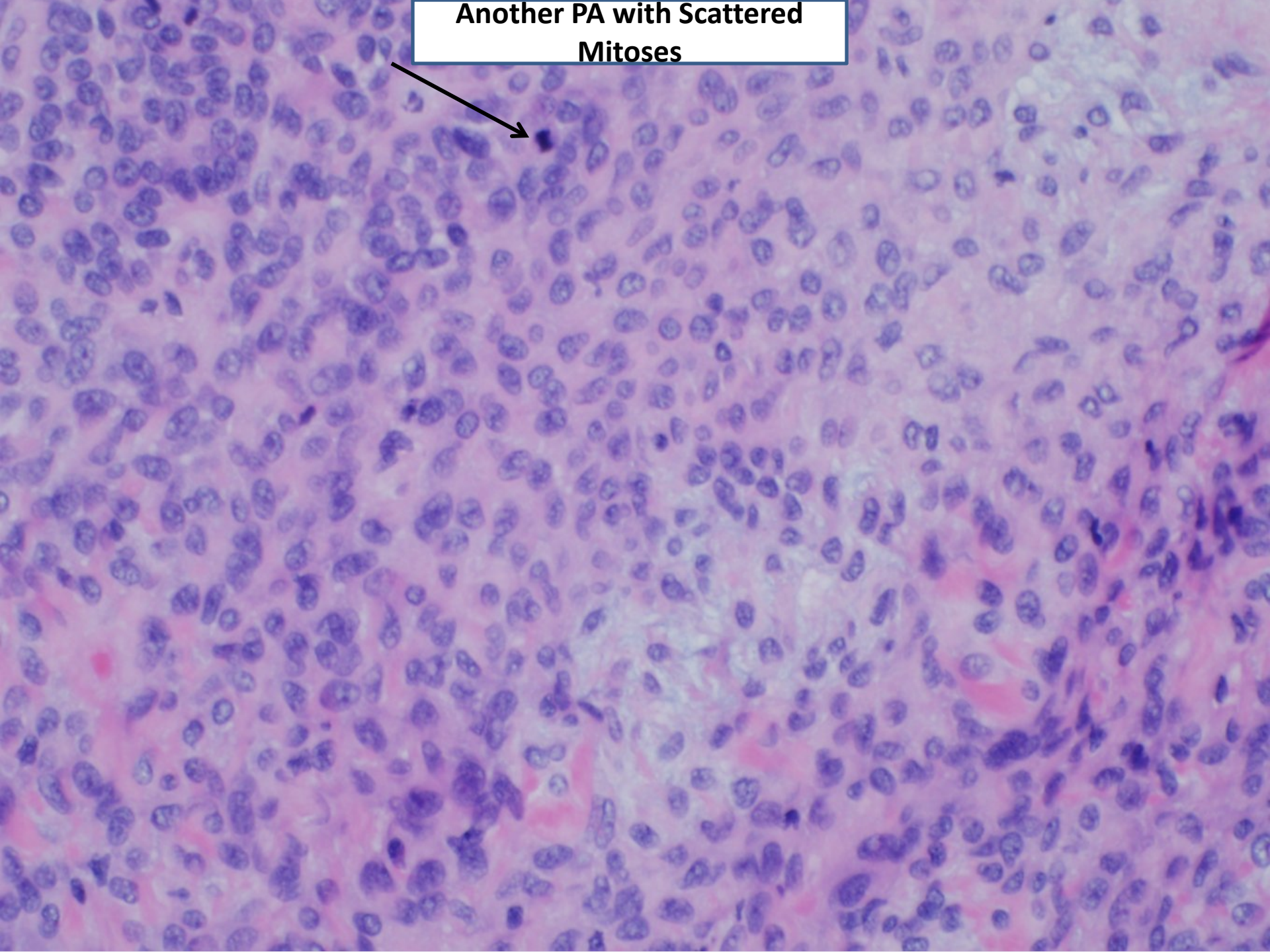
**PA with Many Faces: Basal cell
adenoma area**



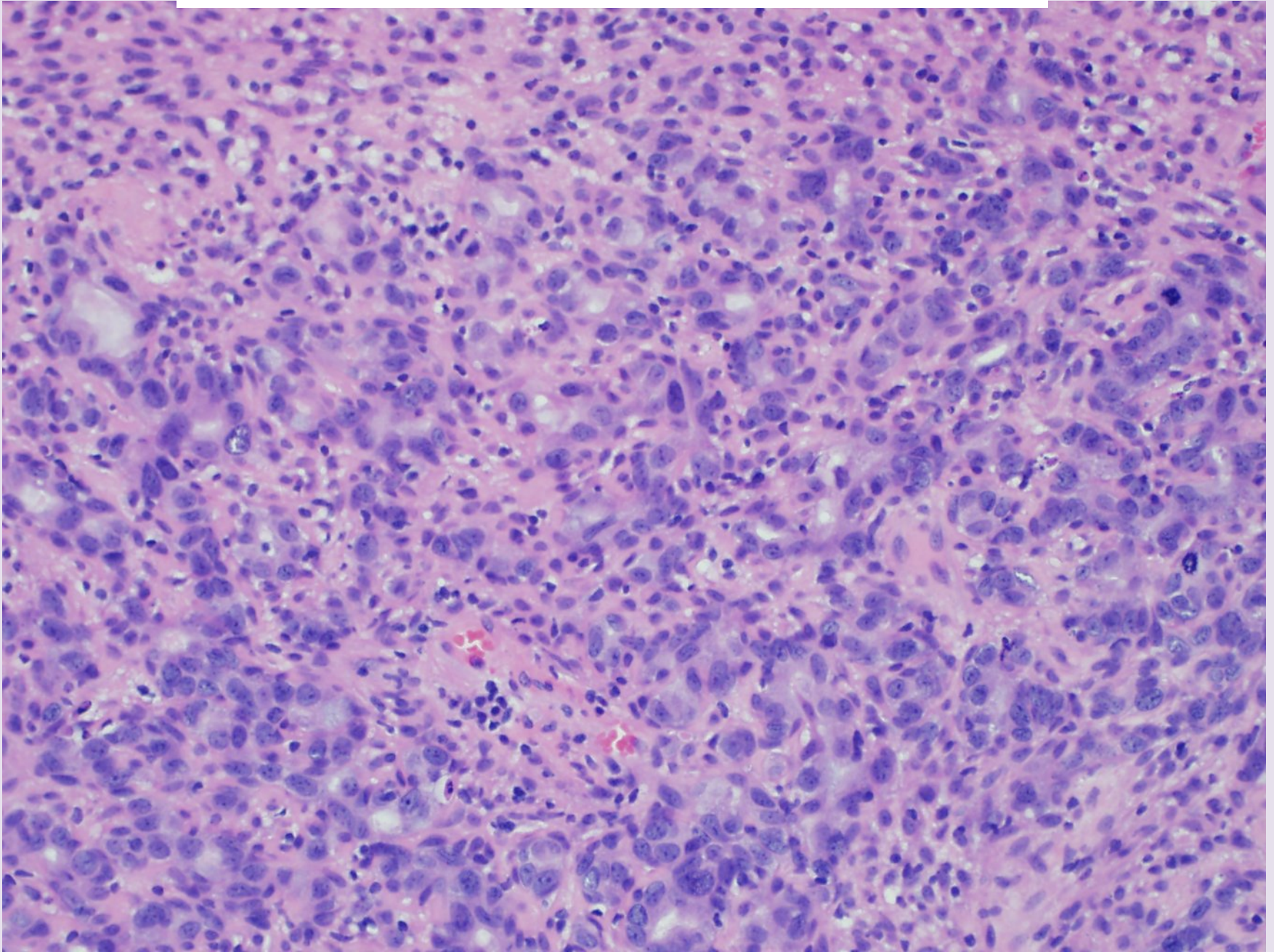
Cellular Atypia in a Different PA



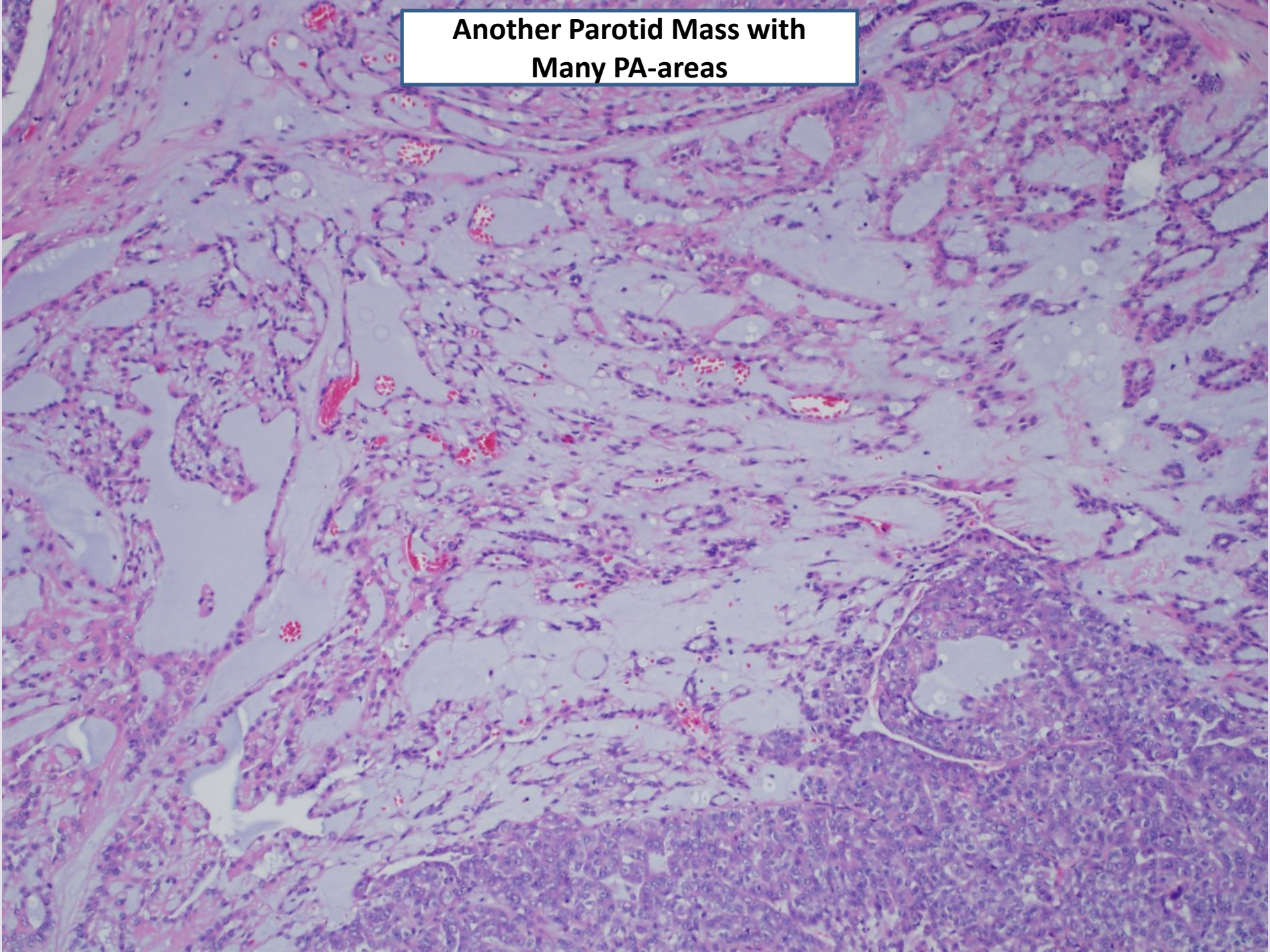
Another PA with Scattered Mitoses



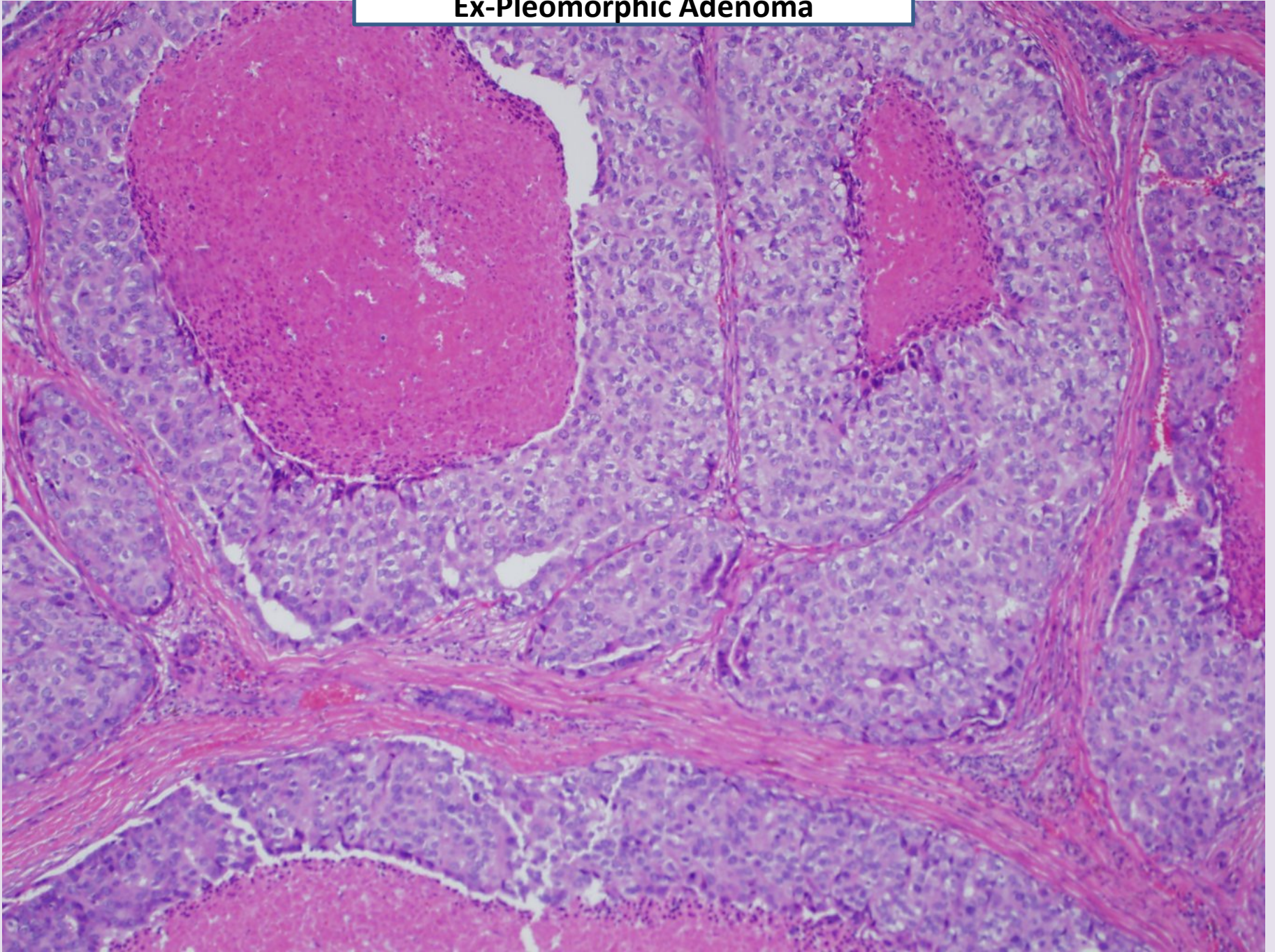
**By contrast here's a different parotid lesion that fit for
Focal Carcinoma in Situ ex-PA (or within a PA)**



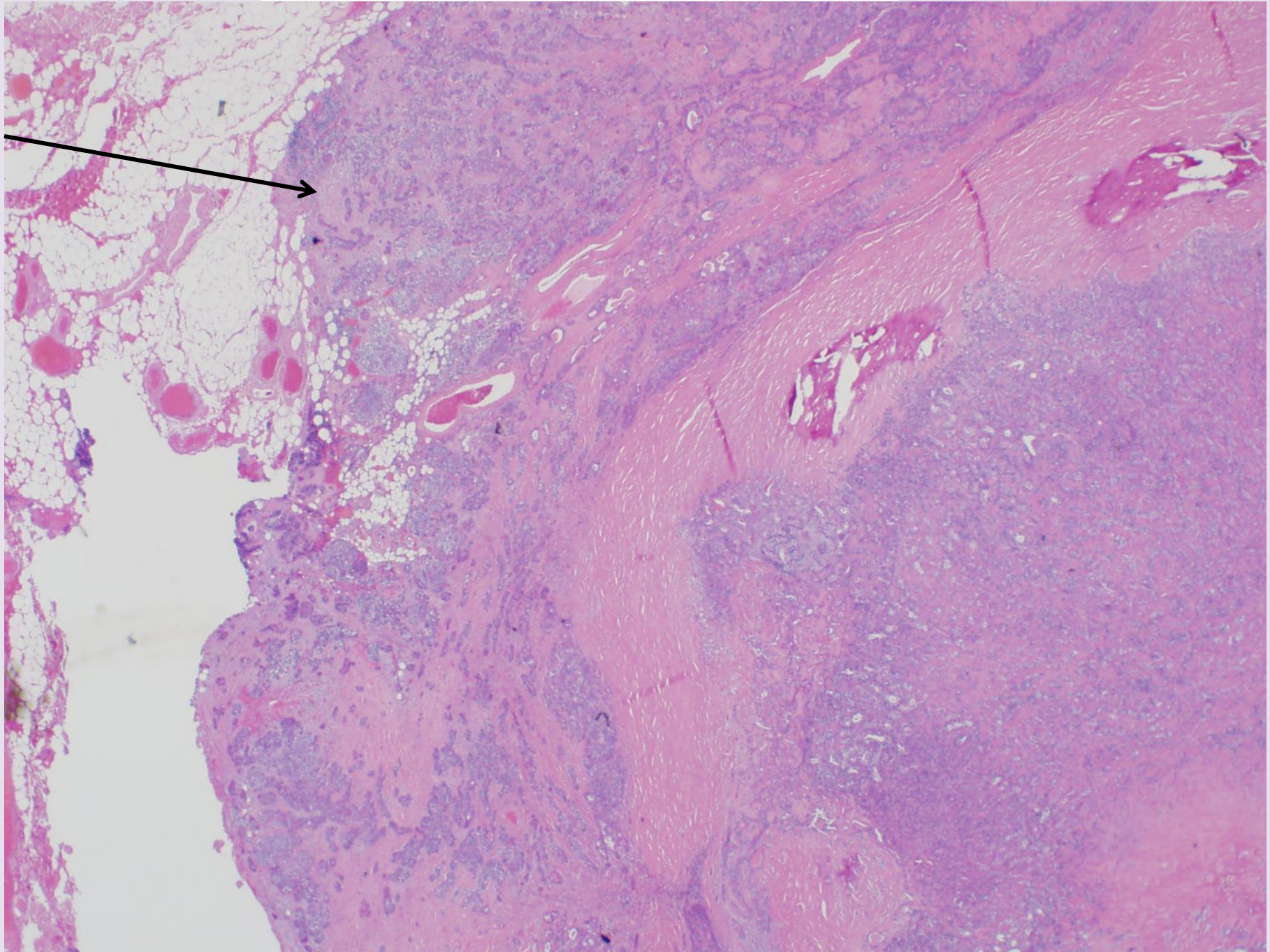
**Another Parotid Mass with
Many PA-areas**

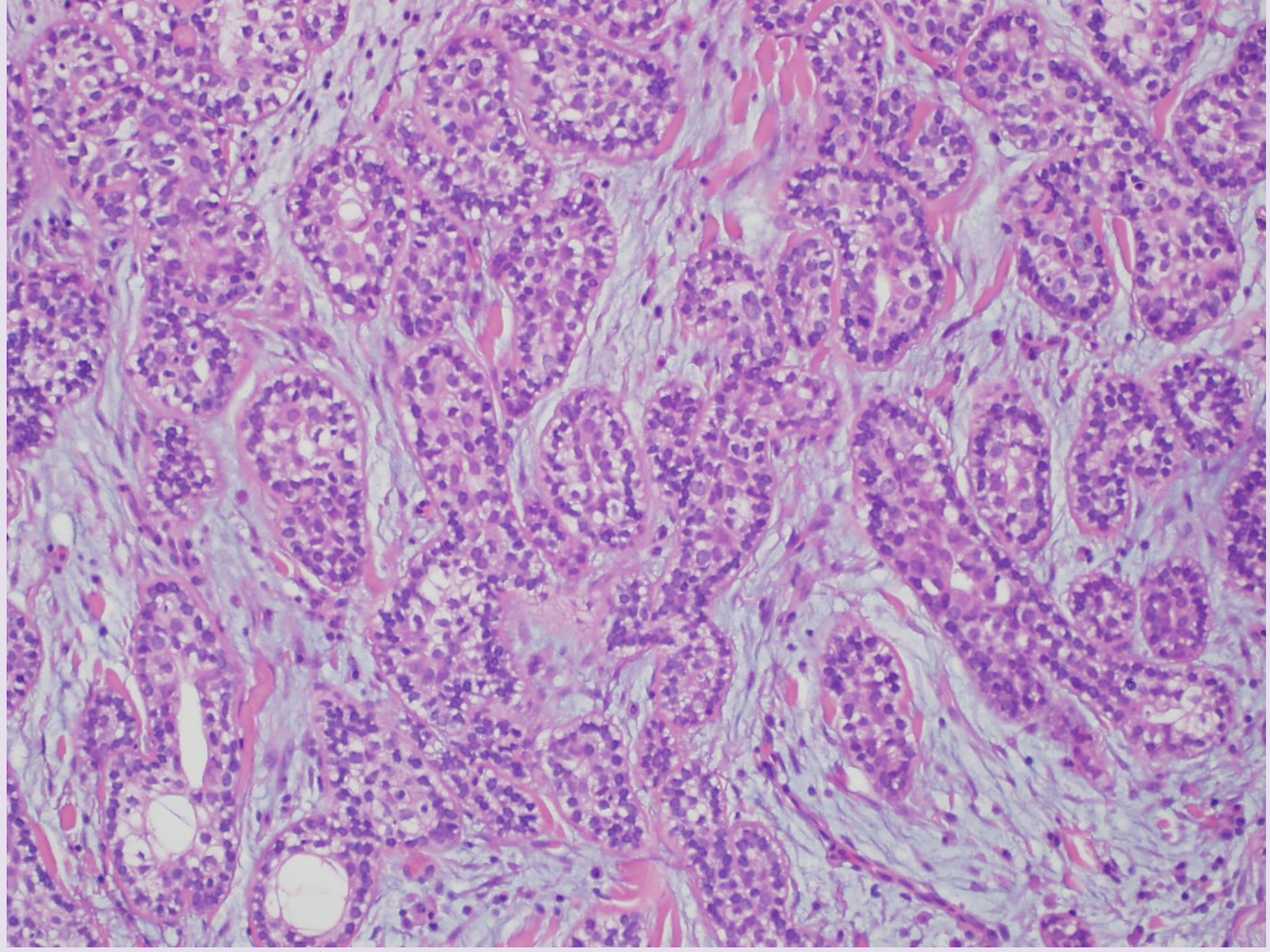


**Same Lesion: Salivary Duct Carcinoma
Ex-Pleomorphic Adenoma**

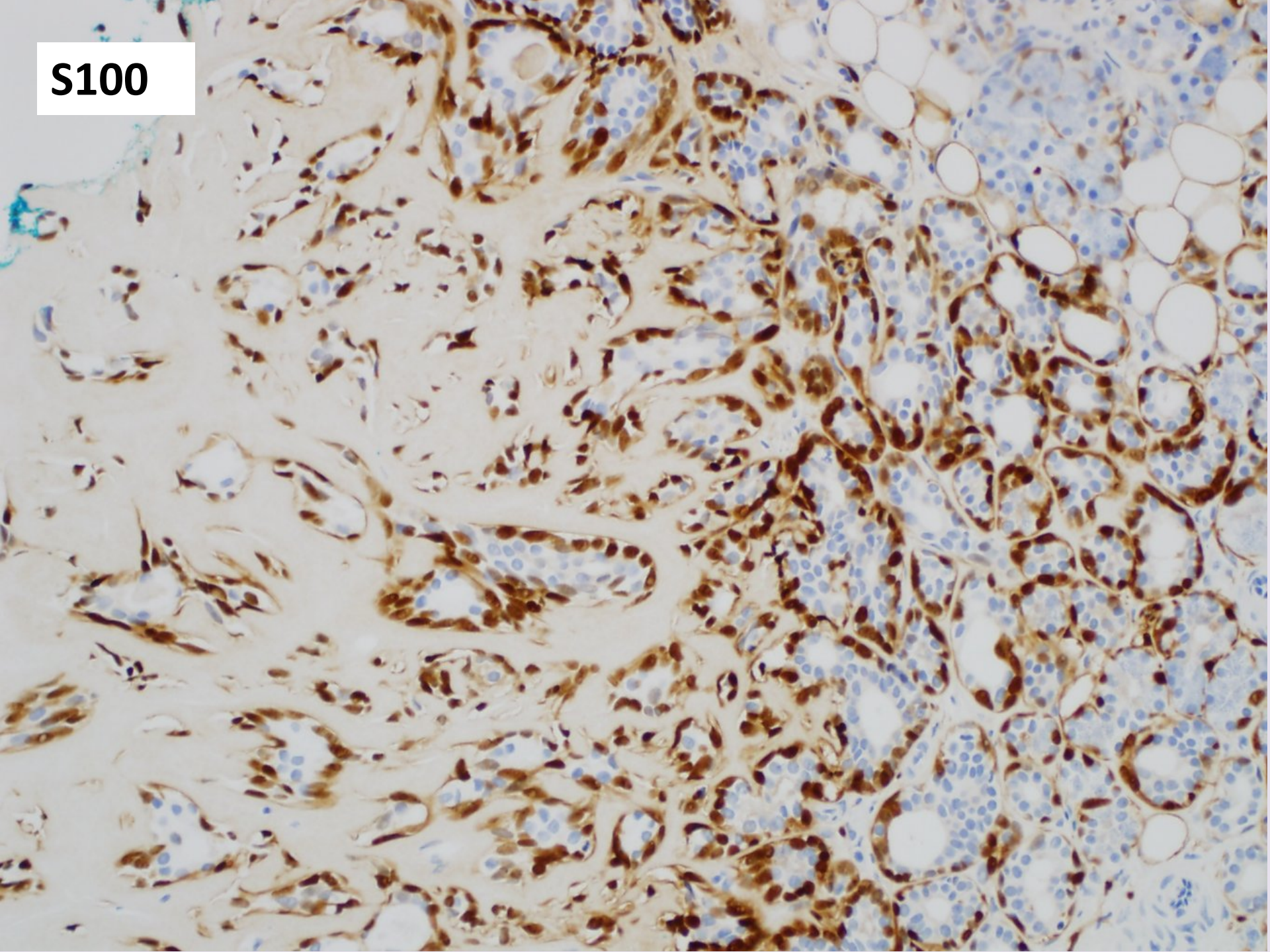


Epithelial-Myoepithelial Carcinoma Ex-PA

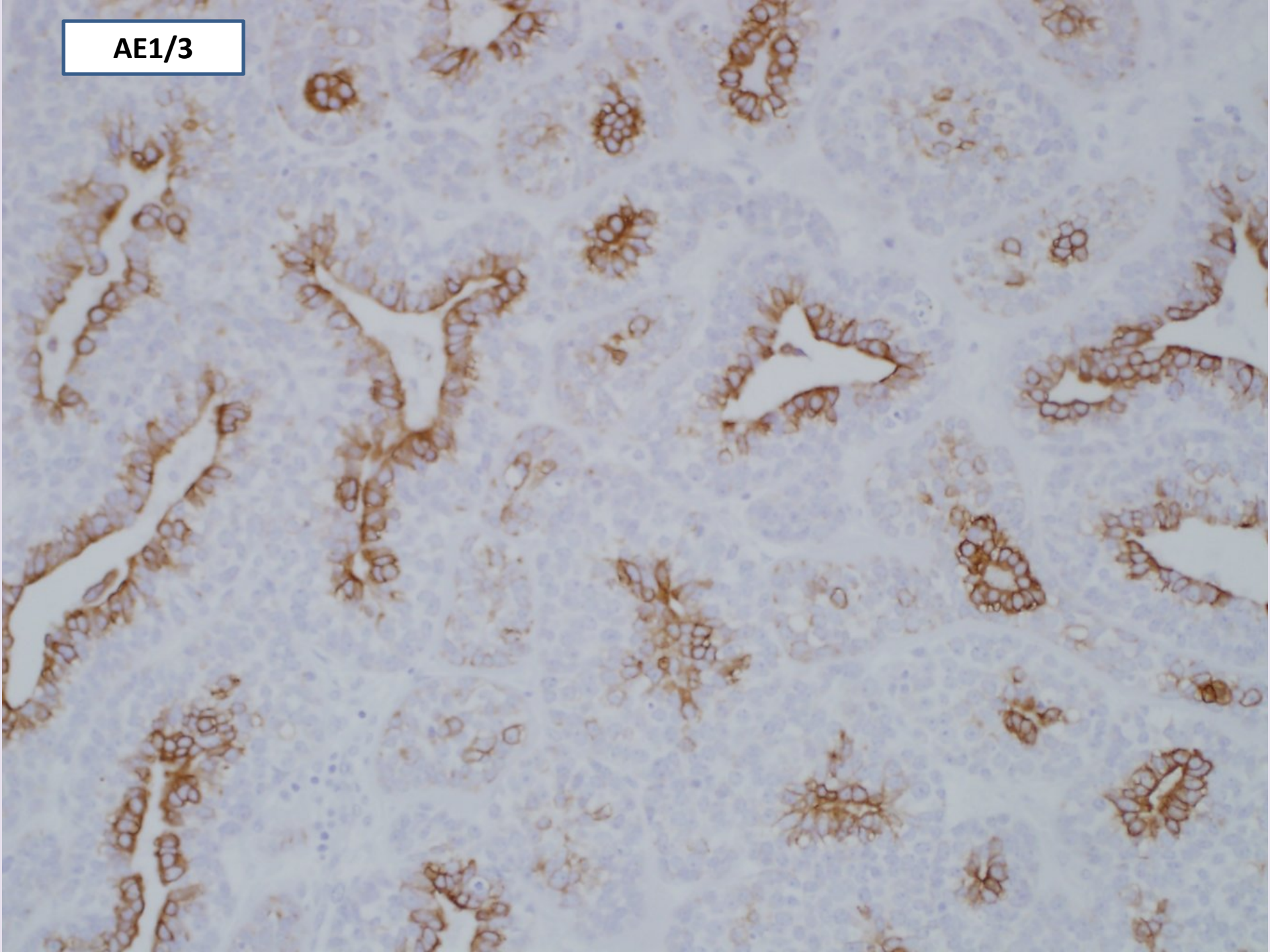




S100



AE1/3



Carcinoma Ex-Pleomorphic Adenoma

- 12% of all malignant salivary gland neoplasms
- Requires identifiable areas of associated PA
- Risk increases with duration of tumor (9.5% for tumor present >15 years)
- Submandibular gland location
- Salivary ductal carcinoma is most common type of malignant transformation
- Prognosis is excellent if non-invasive (encapsulated)

Poor Prognostic Factors in Carcinoma ex-PA

- Extent of Invasion beyond capsule (most important but also most debated)
 - Greater than 1.5 mm beyond tumor capsule; WHO system
 - Greater than 8 mm (Tortoledo et al. 1984)
 - Several recent studies suggest prognostic cutoff of 5mm
- Vascular invasion
- High grade subtypes
- Myoepithelial carcinoma subtype (especially within the minimally invasive group)
- High mitotic rate (>5 per 10 hpfs)/Atypical mitoses
- Positive surgical margin

Concept of Atypical PA

Histologic Parameter	Transformed to Carcinoma (N=9)	No malignant transformation (N=56)
Hypercellularity	6 / 9 (67)	34/56 (61)
Capsule violation	6/9 (67)	34/56 (71)
Cellular anaplasia	2/9 (22)	24/56 (43)
Hyalinization	6/9 (67)	18/56 (32)
Necrosis	3/9 (33)	10/56 (18)
Mean mitoses per 10 hps	1.5	0.66

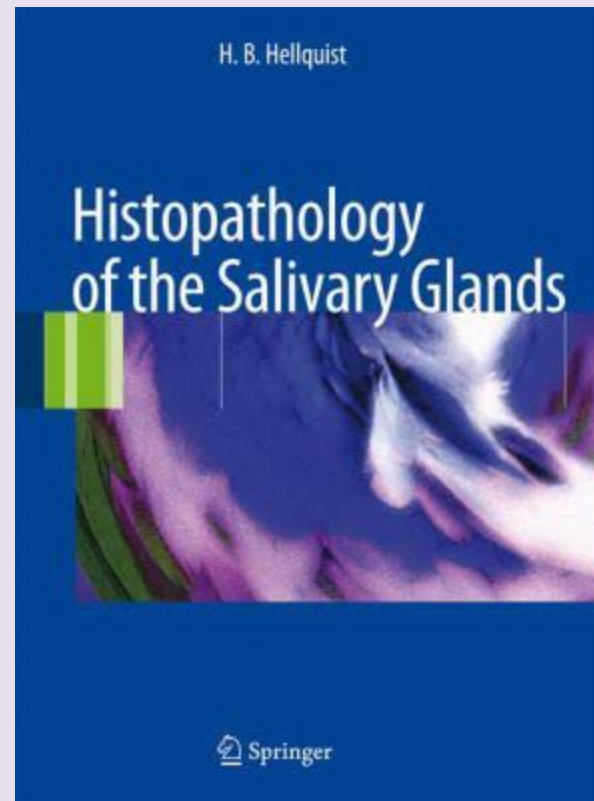
No feature showed statistical significance (hyalinization came the closest).
 “Morphologic differences between mixed tumors that undergo malignant transformation and those that do not are minimal. All mixed tumors of the salivary glands, particularly those in the submandibular gland, have the potential to undergo malignant transformation, and should be treated accordingly.”

Pleomorphic Adenomas (My Advice)

- Most things want to be PAs (60-70% of all salivary gland neoplasms; all sites)
- Allow for cellularity especially in minor salivary gland sites
- Let the differing patterns (even those resembling other tumors) be reassuring
- Atypical features should prompt thorough sampling but do not connote malignancy (no different management)
- Maybe they are actually a gift

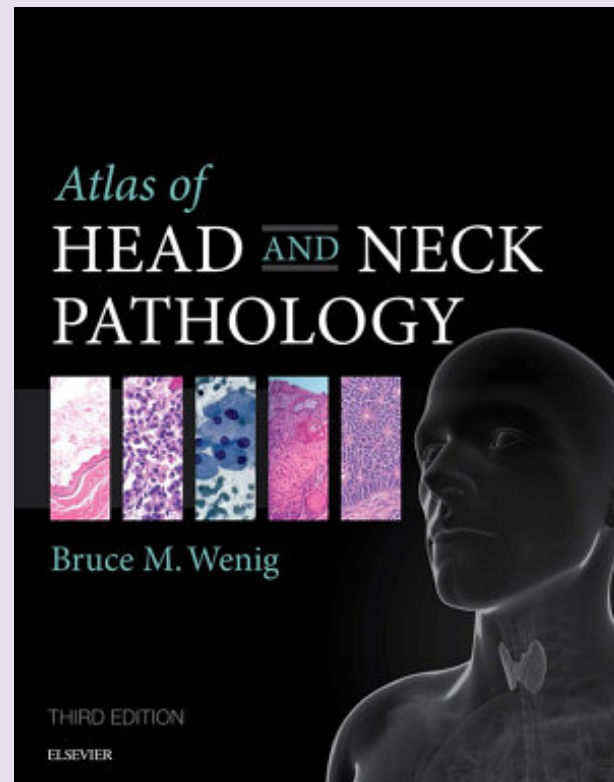
Useful Reference

- Henrik Hellquist and Alena Skalova.
Histopathology of the Salivary Glands.
Springer 2014.



Useful Reference

- Bruce M. Wenig. Atlas of Head and Neck Pathology. Third Edition. Elsevier 2016.



Questions?

