

The Awol Cholesterol-abetalipoproteinemia

Anubha Bajaj

Consultant Histopathologist, A.B.Diagnostics,A-1, Ring Road,Rajouri Garden, New Delhi 110027, India

ABSTRACT

Abetalipoproteinemia is an autosomal recessive disorder characterized by declining values of plasma cholesterol, low-density lipoproteins (LDL), and very LDLs (VLDLs). The condition arises due to mutations within microsomal transfer protein gene encoding microsomal triglycerides transfer protein with a consequent absence of mammoth, 97 kilo-Dalton subunit of microsomal triglyceride protein. Paucity of beta-lipoproteins engenders severe malabsorption of dietary fats and lipid-soluble vitamins from gastrointestinal tract into the circulation resulting in nutritional deficiencies demonstrating diverse clinical manifestations. Typically, abetalipoproteinemia manifests fat malabsorption, spinocerebellar degeneration, acanthocytic red blood cells, and retinitis pigmentosa. Intestinal epithelium delineates lipid-laden intestinal epithelial cells with prominent adipose tissue vacuoles situated within apical, villous cytoplasm.

Key words: Autosomal recessive, fat malabsorption, nutritional deficiencies

PREFACE

A betalipoproteinemia (ABL) is an exceptional, autosomal recessive disorder characterized by minimal or absent values of plasma cholesterol, low-density lipoproteins (LDL), and very LDLs (VLDLs). The hereditary disorder demonstrates impairment of intestinal absorption of fats and lipid-soluble vitamins.^[1] ABL arises due to chromosomal mutations within microsomal transfer protein (MTP) gene encoding microsomal triglycerides transfer protein (MTTP). Aforesaid mutations engender a defect in synthesis and export of APO-protein B from intestinal mucosal cells with consequent restriction of free fatty acids and monoglycerides into assembly of chylomicrons (CMs) and triglyceride conversion.^[1,2] Clinical signs and symptoms of ABL arise due to severe deficiency of lipid-soluble vitamins such as Vitamin A, E, and K. Predominant manifestations are hematological or appear within the gastrointestinal tract, ocular, and nervous system.^[1] ABL is also designated as ABL neuropathy, ABL, acanthocytosis, apolipoprotein B (APOB) deficiency, Bassen-Kornzweig disease, Bassen-Kornzweig syndrome, beta-lipoprotein deficiency disease, congenital beta-lipoprotein deficiency syndrome, MTTP deficiency disease, or MTP deficiency.^[1,2]

DISEASE CHARACTERISTICS

ABL is a homozygous condition engendered by an estimated 33 chromosomal mutations within the MTTP gene. The gene encodes for MTTP which mediates configuration and movement of VLDL or intracellular CMs within intestinal mucosa and hepatocytes.^[2,3] As an infrequent disorder, ABL occurs within < one per one million subjects. Consanguinity in marriages is a significant factor in disease emergence. Equivalent gender distribution is observed. Pertinent mutation is frequent in Ashkenazi Jewish people wherein a protein building block or stops signal, amino acid glycine at position 865 (Gly865X or G865X), is replaced. Consequently, an aberrant, miniature, non-functional protein is configured.^[2,3] The autosomal recessive condition mandates dual genomic copies of cellular MTTP gene to be defective or mutated. Although phenotypically normal, each parent incorporates a copy of mutated gene autosomal recessive ABL is accompanied by 25% possibility of incrimination of siblings, 50% proportionate emergence of an asymptomatic carrier, and 25% probability of being unaffected or an absence of carrier stage. With established, familial MTTP genomic variants, evaluation of candidates at risk, prenatal discernment of at-risk pregnancies, and preimplantation

Address for correspondence:

Anubha Bajaj, *Consultant Histopathologist, A.B.Diagnostics,A-1, Ring Road,Rajouri Garden, New Delhi 110027, India.*

© 2020 The Author(s). This open access article is distributed under a Creative Commons Attribution (CC-BY) 4.0 license.

genetic diagnosis can be obtained. Comprehensive (100%) homozygotes or compound heterozygotes with MTTP genomic variants demonstrating ABL exemplify incomplete or variably severe clinical manifestations pertaining to age of incriminated individuals.^[2,3] ABL is suspected in individuals with an absent or minimal LDL-cholesterol or triglyceride. Simultaneously, APOB values with bi-allelic genetic variants of MTTP gene can be discerned by single gene or multigene molecular assay [Figures 1 and 2].^[3]

DISEASE PATHOGENESIS

ABL arises due to chromosomal mutation within the MTTP gene. The gene ensures satisfactory production of MTTP which is essential for engendering intestinal and hepatic beta-lipoproteins. Beta-lipoproteins absorb and transport fats, cholesterol, and lipid-soluble vitamins from intestine into the circulatory system with appropriate systemic dissemination of nutrients. Satisfactory levels of fats, cholesterol, and vitamins are necessitated for cellular growth, development, and maintenance of diverse tissues or organs.^[4] Beta-APOs are mammoth APOs critical for configuration and secretion of CMs and VLDLs. Anomalies and obstruction of the process engender ABL or hypobetalipoproteinemia. MTP is localized within the lumen of hepatic and intestinal mucosal microsomes and catalyzes transport of triglycerides, cholesterol esters, and phosphatidylcholine molecules between membranes, apart from facilitating transfer of lipids onto (APOB). Lipid transport occurs in order of triglyceride, cholesteryl ester, diglyceride, cholesterol, and phosphatidylcholine. MTP is a heterodimer composed of subunits of 58 kilo-Dalton to 97 kilo-Dalton, in contrast to associated lipid transfer proteins. Mammoth 97 kilo-Dalton subunit is imbued with or confers lipid transfer activity to configured molecules.^[3,4] Individuals with ABL appear to be devoid of mammoth, 97 kilo-Dalton subunit of microsomal triglyceride protein. Initial assembly of lipids occurs within the endoplasmic reticulum wherein APOs, cholesterol, phospholipids, and triacylglycerides are synthesized and incorporated into lipoprotein particles which are subsequently transported onto Golgi apparatus and secreted. Lipoproteins are pertinent for lipid composition and configuration of accompanying APOs.^[3,4] Cogent β-APOs are B-100 and B-48. Apo B-100 is synthesized by hepatic parenchyma, is a larger molecule than ApoB-48, is articulated upon VLDL, and comprises binding sites essential for LDL adherence to hepatocyte LDL receptors. ApoB-48 is configured of 4536 amino acids, is confluent with CMs, and is derived from a gene identical to ApoB-100 gene.^[4] Majority of MTTP genetic mutations generate MTTP with depleted or absent function and inadequate configuration of beta-lipoproteins. Paucity of beta-lipoproteins ensures severe malabsorption of dietary fats and lipid-soluble vitamins from gastrointestinal tract into circulation. Consequent nutritional deficiencies engender diverse clinical manifestations in incriminated individual.^[2,4]

CLINICAL ELUCIDATION

Typically, ABL manifests fat malabsorption, spinocerebellar degeneration, acanthocytic red blood cells, and retinitis pigmentosa. Clinical signs and symptoms appear on account of severe deficiency of fats and lipid-soluble vitamins, especially Vitamin E. The disorder is initially discerned in infancy and manifests as a failure to thrive, diarrhea, and steatorrhea with fat laden, malodourous stools, abdominal distension, spinocerebellar degeneration, and retinitis pigmentosa.^[5] Symptoms pertaining to gastrointestinal tract are severe diarrhea, vomiting, malabsorption of fat, and deficiency of lipid-soluble vitamins. Disease severity is contingent to intake of dietary fat and diarrhea or steatorrhea subside as dietary fat intake is restricted. However, depletion of lipid-soluble vitamins persists as their assimilation and

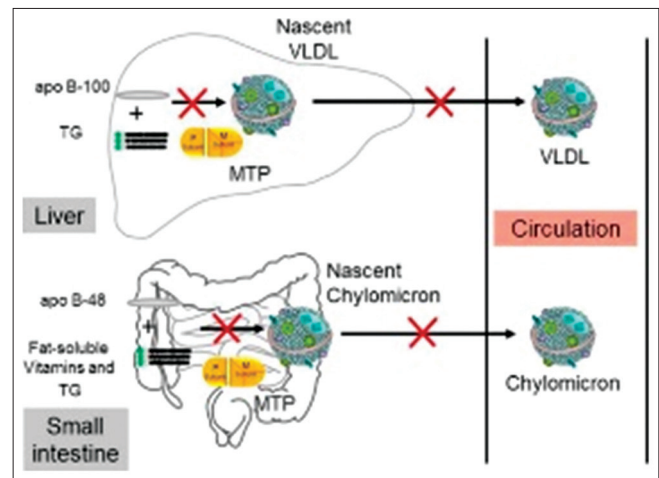


Figure 1: ABL depicting mutation within microsomal transfer protein gene with consequent decimation of circulating chylomicrons and very-low-density lipoprotein.^[9]

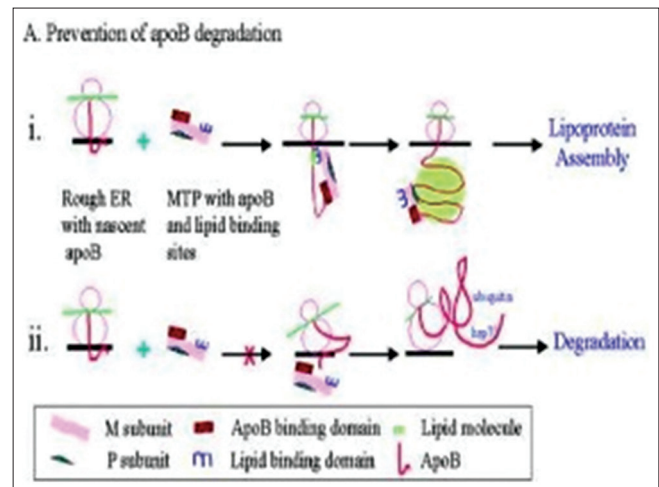


Figure 2: ABL delineating microsomal transfer protein in association with Apo B configuring diverse lipid-binding sites along with lipid assembly and lack of lipid degradation.^[10]

transport pertains to integrity of APOB pathway and is associated with the absence of APOB.^[5] Hepatic steatosis manifests as hepatomegaly with subsequent hepatic damage. Elevated levels of serum alanine transaminase (ALT) and aspartate transaminase (AST) may ensue. Hepatic disease is frequently stable and may not progress or appear clinically significant. Steatohepatitis, fibrosis, and cirrhosis are exceptionally documented.^[4,5] Anemia with acanthocytosis or burr cells and coagulation disorders with anomalous hemorrhage can arise. The characteristic hematologic parameter is the occurrence of acanthocyte or burr cell with aberrant spikes upon red cells emerging due to damaged phospholipid cell membrane, also discerned in hepatic dysfunction. Erythrocyte sedimentation rate is reduced as red cells are unable to display rouleaux formation. In addition, reticulocytosis, hyperbilirubinemia, hemolysis, and prolonged international normalized ratio (INR) due to deficient Vitamin K are observed.^[5,6] Malabsorption of fat engenders deficiency of iron or folic acid with consequent anemia. Vitamin E shields cells from free radical injury and deficiency of Vitamin E can activate cellular lipid peroxidation with consequent hemolysis and anemia. Vitamin K affects gamma decarboxylation of coagulation factors, fundamental for coagulation, and deficiency can result in coagulation disorders.^[5,6] With progressing age, additional signs and symptoms appear such as peripheral neuropathy, inadequate muscular coordination, myopathy, and spinocerebellar ataxia. Impaired speech or dysarthria, tremors, and involuntary movements or motor tics are observed. Myriad, variably intense symptoms of delayed intellectual development and loss of deep tendon reflexes, proprioception, or vibratory sense occur due to demyelination arising from deficiency of lipid-soluble vitamins. Central and peripheral nervous systems are implicated.^[4,6] Muscle weakness and enhanced muscular degeneration is encountered. Muscular disorders disrupt skeletal development with the emergence of lordosis, kyphoscoliosis, pes cavus, or club foot. Ultimately, Friedrich-like ataxia with a broad base and high stepping gait emerges in young, untreated adults. Untreated neuromuscular manifestations arising due to deficiency of Vitamin E commonly appear within the first or second decade.^[5,6] Ocular conditions such as retinitis pigmentosa due to lack of Vitamin A, reduced night and color vision with consequent complete loss of vision can occur. In addition, nystagmus, strabismus, acquired atypical pigmentation of retina, or progressively expanding scotomas can be discerned. Individuals may be asymptomatic till adulthood. With a lack of appropriate therapy, disease may progress to complete blindness. Exceptionally, corneal ulcers arise due to lack of Vitamin A. Ptosis and ophthalmoplegia may infrequently ensue due to deficiency of Vitamin E with consequent demyelination of cranial nerves.^[5,6] Exceptionally, cardiomegaly appears within decades accompanied by morbidity due to cardiomyopathy; subclinical and overt hypothyroidism is delineated in cruminate infants depict diverse gastroenterological,

neurological, and ophthalmological symptoms such as delayed mental growth, absent deep tendon reflexes, ataxia, slurred speech, peripheral neuropathy, intention tremors, reduced night and color vision, blindness, or retinitis pigmentosa which appears by adolescence.^[5,6]

HISTOLOGICAL ELUCIDATION

On endoscopic evaluation, intestinal mucosa subjected to an absence of dietary fat restriction demonstrates a “geleebanche” or “white hoar frosting” appearance. Microscopic examination of intestinal epithelium delineates lipid-laden intestinal epithelial cells with prominent adipose tissue vacuoles situated within apical, villous cytoplasm. Thus, intracellular free fatty acid and monoglyceride accumulation and lipid vacuolization of intestinal epithelial cells is discerned. Villous architecture is unremarkable. Pertinent adipose tissue stains such as Oil Red O or Sudan Black B emphasize intracellular lipid vacuoles.^[6,7] Detection of acanthocytes upon peripheral blood smear examination is contemplated to be pathognomonic for ABL. Acanthocytes are designated as irregularly spiculated erythrocytes [Figures 3-8].^[7]

DIFFERENTIAL DIAGNOSIS

ABL mandates segregation from coeliac sprue, a condition which demonstrates distinctive features such as intraepithelial lymphocytes, crypt hyperplasia, and villous atrophy megaloblastic anemia exemplifies the occurrence of erythroid precursors with megaloblastic features or nuclear immaturity and giant neutrophils tropical sprue which delineates variable villous hypertrophy, crypt hyperplasia, injury to distal small intestine, and mucosal inflammation;^[3,4] ABL also requires demarcation from chronic cholestatic liver disease, combined neuropathy and ataxia, familial Vitamin E deficiency, hereditary sensorimotor neuropathies, retinal

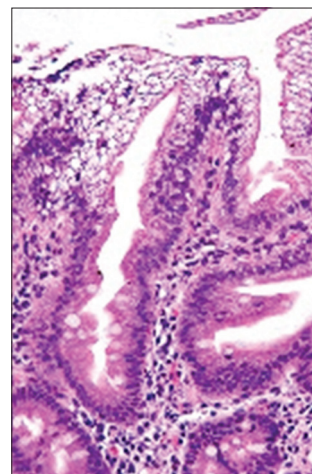


Figure 3: ABL enunciating fat incorporated within epithelial cells and minimal epithelial inflammation.^[11]

degeneration, secondary malignancies, or spinocerebellar disorders [Table 1].^[1,3]

INVESTIGATIVE ASSAY

ABL is devoid of pertinent, clinical, or diagnostic criterion and mandates appropriate evaluation of cogent disease indications. Comprehensive assessment of ABL can be achieved with appraising growth parameters, fecal fat estimation, and serum lipid profile with levels of total cholesterol, LDL-cholesterol, high-density lipoproteins (HDL)-cholesterol, triglycerides, Apo B, and Apo A-1. Serum concentrations of lipid-soluble Vitamins A, D, E, and K require evaluation. Liver function tests, hepatic transaminases, serum bilirubin, complete blood count, reticulocyte count, and INR require estimation. Furthermore, thyroid-stimulating hormone (TSH), serum calcium, serum phosphate, and serum uric acid assays are beneficial.^[7,8] Complete blood count assessment in ABL depicts anemia, thrombocytopenia, or pancytopenia peripheral smear displays acanthocytes or burr cells fasting

lipid profile demonstrates declining or minimal triglycerides, VLDL, LDL, HDL, and total cholesterol. Plasma APO-B may be absent. Total cholesterol levels of around 40 mg per deciliter or one millimole/liter may be exhibited;^[7,8] stool examination demonstrates excessive fecal fat due to malabsorption of fat and an absence of concurrent causes elevation of hepatic transaminases, AST, and ALT up to 1.5 times the upper reference value prolonged INR reduced serum concentration of lipid-soluble Vitamins A, D, E, and K (8) ≈ Imaging assay with hepatic scan or ultrasonography can exemplify hepatic steatosis magnetic resonance imaging (MRI) displays degeneration of spinocerebellar region displays ocular and retinal examination and imaging is required to assess retinal damage (7) ≈ Single-gene assay aids in evaluation of sequence analysis of MTTP gene wherein detection of miniature, iatrogenic, genomic deletions/insertions, and missense, nonsense and splice site variants are denominated. Typically, exons or whole gene deletions/duplications are indecipherable. Alternatively, assessment

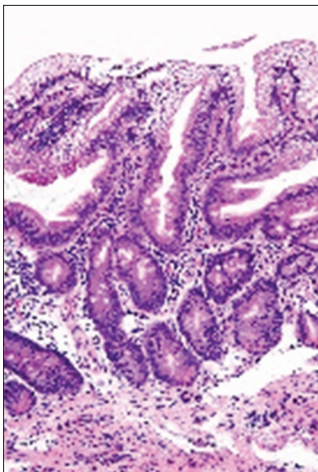


Figure 4: ABL exemplifying fat impacted within epithelial cells with a lack of inflammatory exudate.^[12]

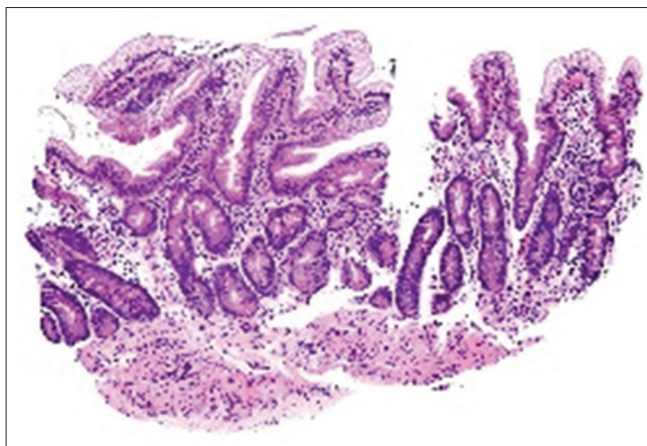


Figure 5: ABL exhibiting fat imbued within epithelial cells and an absence of atypia or mitosis.^[13]

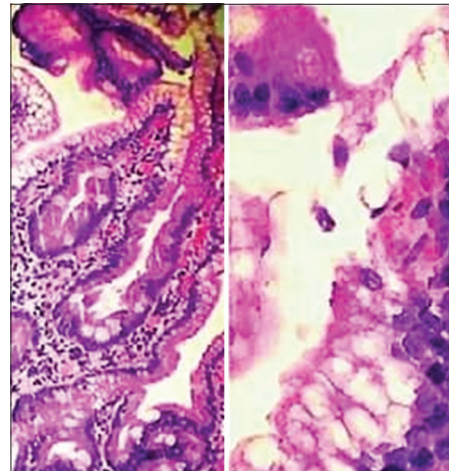


Figure 7: ABL delineating fat aggregation within intestinal epithelial cells with an absence of inflammation.^[15]

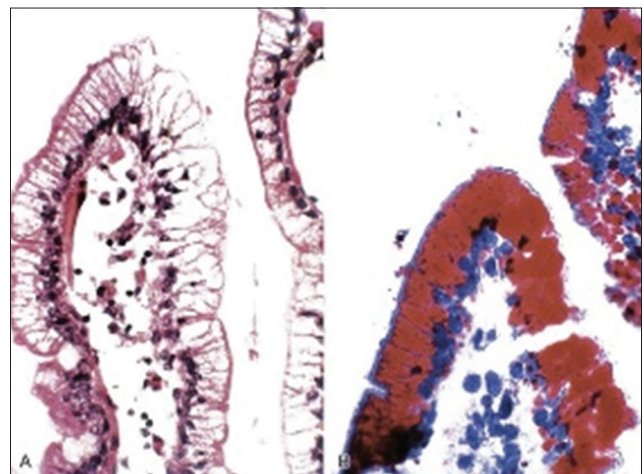


Figure 6: ABL displaying fat in epithelial cells with minimal intraepithelial inflammation.^[14]

Table 1: Differential diagnosis of ABL.^[2]

Disorder	Gene	Clinical features	Distinguishing features
Homozygous hypobetalipoproteinemia (AR)	APOB	Identical to ABL	LDL cholesterol <50% normal
McLeod syndrome (XL)	XK	Acanthocytosis, peripheral neuropathy	Normal lipid profile, no manifestation of fat-soluble vitamin deficiency
Friedreich ataxia (AR)	FXN	Broad-based, high stepping gait, loss of proprioception, loss of deep tendon reflexes	Normal lipid profile, no manifestation of fat-soluble vitamin deficiency

AR: Autosomal recessive, XL: X-linked, LDL: Low-density lipoproteins, ABL: Abetalipoproteinemia, APOB: Apolipoprotein B

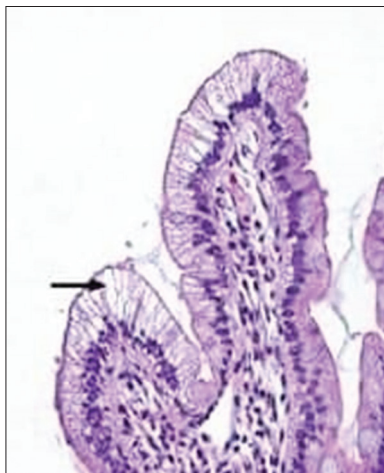


Figure 8: ABL depicting fat accumulation within intestinal epithelial cells.^[16]

with a multigene panel is constituted by deletion/duplication, sequence, or non-sequence-based investigations.^[7,8]

THERAPEUTIC OPTIONS

Pertinent strategies for treating ABL are directed toward arresting neuropathy and impeding efficiency-induced complications. Clinical manifestations can be treated with an adequate caloric intake, restriction of dietary fat to around 10–20% of total ingested calories, oral supplementation of essential fatty acids, and thyroid replacement hormones. Oral supplementation of lipid-soluble Vitamins A, D, E, and K along with supplements of Vitamin B-12, folate, and iron is recommended.^[7,8] Dietary modifications mandate a strict restriction of long-chain fatty acids. Vitamin supplementation is required, especially with oral Vitamin E or Vitamin A, and in instances where an elevated prothrombin time ensues due to Vitamin K depletion.^[7,8] Supplementation with significant quantities of Vitamin E only minimally enhances serum Vitamin E levels, whereas supplementation with Vitamin A achieves normal serum values. Thus, despite deranged intestinal absorption, transfer of Vitamin A by serum retinol-binding protein is unimpaired in ABL.^[7,8] Adjuvant therapeutic measures such as physiotherapy or occupational therapy can be beneficial. A multidisciplinary approach is

an optimal strategy for treating ABL.^[8] Weight control is beneficial as obesity exacerbates clinical complications. Liver transplantation is recommended for treating hepatic fibrosis or cirrhosis. Prognostic factors which influence disease outcome are age at disease discernment and onset of therapy with fat-restricted diet and vitamin replacement therapy. Category of genomic mutation of MTP and APOE genotype impacts extended prognosis of ABL.^[7,8] Therapeutic absence of high-dose, lipid-soluble vitamin supplementation is accompanied by morbidity due to severe neuropathy and respiratory failure within the third decade. However, life-long, oral supplementation of high-dose and lipid-soluble vitamins is associated with mild clinical symptoms and longevity into the seventh or eighth decade. Relatives associated with the possible occurrence of ABL can be discerned with the determination of serum lipid profile and APO-B levels. Molecular assessment of genomic variants of MTP gene can be achieved.^[7,8]

CONCLUSION

ABL mandates segregation from conditions such as coeliac sprue, tropical sprue, megaloblastic anemia, chronic cholestatic liver disease, combined neuropathy and ataxia, familial Vitamin E deficiency, hereditary sensorimotor neuropathies, retinal degeneration, secondary malignancies, or spinocerebellar disorders. ABL can be evaluated with assessing growth parameters, fecal fat estimation, serum lipid profile, total cholesterol, LDL-cholesterol, HDL-cholesterol, triglycerides, APO B, Apo A-1, lipid-soluble Vitamins A, D, E, and K, liver function tests, hepatic transaminases, serum bilirubin, complete blood count, reticulocyte count, INR, TSH, serum calcium, serum phosphate, and serum uric acid. Furthermore, hepatic scan, ultrasonography, MRI, ocular or retinal examination, and single gene assay are beneficial. Optimal therapy is directed toward arresting neuropathy, dietary modifications, oral supplementation of micronutrients, lipid-soluble and associated vitamins, and control of obesity.

REFERENCES

1. Junaid Z, Patel K. Abetalipoproteinemia. Treasure Island, Florida: Stat Pearls; 2020.

2. Burnett JR, Hooper AJ. Abetalipoproteinemia: Gene Reviews. Seattle: University of Washington; 2020.
3. Lee J, Hegele RA. Abetalipoproteinemia and homozygous hypobetalipoproteinemia a framework for diagnosis and management. *J Inher Metab Dis* 2014;37:333-9.
4. Magnolo L, Najah M, Fancello T, Di Leo E, Pinotti E, Brini I, *et al.* Novel mutations in SAR1B and MTTP genes in Tunisian children with chylomicron retention disease and abetalipoproteinemia. *Gene* 2013;512:28-34.
5. Welty FK. Hypobetalipoproteinemia and abetalipoproteinemia. *Curr Opin Lipidol* 2014;25:161-8.
6. Cuerq C, Henin E, Restier L, Blond E, Draï J, Marçais C, *et al.* Efficacy of two Vitamin E formulations in patients with abetalipoproteinemia and chylomicron retention disease. *J Lipid Res* 2018;59:1640-8.
7. Walsh MT, Iqbal J, Josekutty J, Soh J, Di Leo E, Özaydin E, Gündüz M, *et al.* Novel abetalipoproteinemia missense mutation highlights the importance of the N-terminal β -barrel in microsomal triglyceride transfer protein function. *Circ Cardiovasc Genet* 2015;8:677-87.
8. Yilmaz BS, Mungan MO. Homozygous familial hypobetalipoproteinemia a Turkish case carrying missense mutation in apolipoprotein B. *Clin Chim Acta* 2016;452:185-90.
9. Image 1 Courtesy: Science Direct.
10. Image 2 Courtesy: Slide Share.
11. Image 3 Courtesy: Wikipedia.
12. Image 4 Courtesy: Wikimedia Commons.
13. Image 5 Courtesy: Dovemed.com.
14. Image 6 Courtesy: Clinical Gate.
15. Image 7 Courtesy: Research Gate.
16. Image 8 Courtesy: LWW Journals.

How to cite this article: Bajaj A. The Awol Cholesterol-abetalipoproteinemia. *J Community Prev Med* 2020;3(1):1-6.