

Biochemical and Histochemical Assessment of the Protective Effects of Aqueous and Ethanol Fruit Extracts of Phoenix Dactylifera on Mercury-induced Liver Toxicity

Musa Garba Abubakar (✉ wellorganised@yahoo.com)

Ahmadu Bello University

Abel Nosereme Agbon

Ahmadu Bello University

Research Article

Keywords:

Posted Date: January 5th, 2024

DOI: <https://doi.org/10.21203/rs.3.rs-3826526/v1>

License: © ⓘ This work is licensed under a Creative Commons Attribution 4.0 International License.

[Read Full License](#)

Additional Declarations: No competing interests reported.

Abstract

Background: Mercury is a highly toxic metal that causes severe damage to the body system of humans and animals that establish contact with it. Date palm (*Phoenix dactylifera*) fruits have been documented to possess several pharmacological abilities and have been used in traditional medicine worldwide. The present study was aimed at assessing the protective effects of aqueous and ethanolic fruit extracts of *Phoenix dactylifera L.* on mercury-induced liver damage toxicity in Wistar rats.

Design; A total of forty-five (45) Wistar rats of male sex (80 – 125g) were randomly divided into nine groups (I-IX) of five (5) rats each. Group 1 served as the control and was administered distilled water (2 ml), group II was administered mercury chloride (HgCl₂) only at 5 mg/kg body weight; group III was pretreated with silymarin at 100 mg/kg then followed by HgCl₂ at 5 mg/kg; groups IV and V were pretreated with aqueous fruit extract of *Phoenix dactylifera* (AFPD) at 500 mg/kg and 1000 mg/kg respectively, followed by HgCl₂ at 5 mg/kg; groups VI and VII were pretreated with ethanol fruit extract of *Phoenix dactylifera* (EFPD) at 500 mg/kg and 1000 mg/kg respectively, followed by HgCl₂ at 5 mg/kg, while groups VIII and IX were treated with AFPD and EFPD only at 1000 mg/kg respectively. After two weeks of oral administration, the animals were humanely sacrificed using cervical dislocation method, and blood samples were collected through the jugular vein for biochemical studies (liver serum enzymes: Aspartate transaminase (AST), Alanine transaminase (ALT) and Alkaline phosphatase (ALP); and oxidative stress markers, (MDA, SOD, CAT, and GPx). Tissue samples of the liver were collected and processed for histochemical (Gordon and Sweet) stain analysis.

Results: The results of the present study showed that toxicity and oxidative stress were induced by the significantly ($p < 0.05$) increased levels of ALP and MDA when compared to the control. Histochemical analysis revealed severe degenerative changes in the liver. Extracts (AFPD and EFPD) of *P. dactylifera* preserved liver serum enzymes and antioxidant enzyme activities to levels similar to that of the control. The effects of HgCl₂ toxicity were ameliorated as observed by the remarkably decreased levels of MDA and significantly increased activity of SOD, as well as preserved histoarchitecture of the liver parenchyma when compared to the HgCl₂-treated group. The protective activities of the extracts of *Phoenix dactylifera* could be attributed to the antioxidant properties of the constituent phytochemicals, such as flavonoids.

Conclusion: Thus, these extracts could be potential candidates for use in the management and treatment of mercury-induced liver diseases in our localities.

Introduction

Mercury is a widespread environmental and industrial pollutant that exerts toxic effects on a variety of vital organs; it induces severe alterations in the tissues [1, 2]. Mercury will cause severe disruption to any tissue it comes into contact with in sufficient concentration. The liver and kidney are organs that suffer significant damage caused by inorganic mercury such as mercuric chloride. Inorganic mercury compounds rapidly accumulate in the kidney [3], the main target organ for these compounds. Mercury

poisoning can result from inhalation, ingestion, or absorption through the skin and may be highly toxic and corrosive once absorbed into the bloodstream [1].

Despite massive efforts in search of new drugs that could counteract mercurial toxicity, there is no effective treatment available that can completely abolish its toxic effects. The use of chelating agents assists the body's ability to eliminate mercury from the tissues [4]. However, these chelants are of limited use, because of their adverse side effects [5]. As a result, the need to evaluate plants for their medicinal activities is of paramount importance.

Date palm (*Phoenix dactylifera*) fruits are good source of energy, vitamins such as vitamin A, vitamin B6 (pyridoxine), vitamin K, and a group of elements like phosphorus, iron, potassium, and a significant amount of calcium [6, 7]. Dates are widely used in traditional medicine for the treatment of various disorders e.g., memory disturbances, fever, inflammation, paralysis, loss of consciousness, nervous disorders [8]. It is also used in the treatment of sore throat, to relieve fever, cystitis, gonorrhoea, edema, liver and abdominal troubles and to counteract alcohol intoxication [9, 10]. The World Health Organization (WHO) estimates that up to 80% of the world's population relies on traditional medicinal systems for some aspect of primary health care [11].

Many pharmacological studies have been conducted on *Phoenix dactylifera* and it has been demonstrated to have antiulcer activity; anticancer activity; anti-diarrhoeal activity; hepatoprotective activity; antimutagenic activity; anti-inflammatory activity; *in vitro* antiviral activity; effect on reproductive system; antihyperlipidemic activity; nephroprotective activity and antioxidant activity [12]. Several researchers have also documented the antioxidant properties of *Phoenix dactylifera* [13, 14].

Materials and Methods

Plant Material Collection and Identification

Dried *Phoenix dactylifera* L. (date palm) fruits were obtained and authenticated in the Herbarium Unit of Department of Biological Sciences, Faculty of Sciences, Ahmadu Bello University Zaria, Kaduna State, Nigeria where the Voucher Specimen Number, 7130, was obtained.

Experimental Animals

A total of forty-five (45) male Wistar rats (80 to 125 g) were obtained from the Department of Pharmacology animal house, Faculty of Pharmaceutical sciences, Ahmadu Bello University Zaria, Kaduna, Nigeria. Animals were housed in the animal house of the Department of Human Anatomy, Faculty of Medicine, Ahmadu Bello University, Zaria, where they were acclimatized for two weeks prior to the commencement of the experiments. The rats fed on rat chow and water allowed *ad libitum*.

In addition, the rats were administered aqueous or ethanol fruit extract of *P. dactylifera*/mercury/silymarin. Rats were weighed at the beginning, during and at the end of the study.

Drugs

- **Mercury**

Seventy grams of mercuric chloride was obtained and used to induce nephrotoxicity for the experiment. The product was manufactured by British Drug Houses (*BDH chemicals*, Poole, England. Batch number- 291634U.

- **Silymarin**

Silymarin was used as the standard antioxidant drug for the experiment. Each tablet is film coated and contains 140 mg of silymarin. The product was manufactured by Micro Labs Limited 92, Sipcot, Hosur- 635 126, India. Batch number- SYFH0011.

Animal Feed

Pelletized Vital Feed was obtained and used to feed the animals for the experiment. The product was manufactured by Grand Cereals and Oil Mills Limited (GCOML), Km 17, Zawan Roundabout, Plateau State, Nigeria; RC 54291.

Plant Extraction

Preparation of aqueous and ethanol fruit extracts of *P. dactylifera* were conducted in the Department of Pharmacognosy, Faculty of Pharmaceutical Sciences, Ahmadu Bello University, Zaria, Kaduna, Nigeria. The maceration methods of Abdul-Wahab *et al.* [15] and Agbon *et al.* [16] were used for the preparation of the aqueous and ethanol fruit extract of *P. dactylifera* respectively.

Phoenix dactylifera Phytochemical Screening

Phytochemical screening of aqueous and ethanol fruit extracts of *P. dactylifera* were done in the Department of Pharmacognosy, Faculty of Pharmaceutical Sciences, Ahmadu Bello University, Zaria, Kaduna, Nigeria. The method of Trease and Evans¹⁷ for Phytochemical screening was adopted.

Experimental design

Forty-five (45) Wistar rats of male sex were divided into common groups (consisting of Groups; I-III) and treatment groups (consisting of Groups IV-IX) having five rats each. Group I served as control and was administered distilled water at 2ml/kg. Nephrotoxicity was induced by HgCl₂ administration. Group II was administered 5 mg/kg of HgCl₂; 12.5% LD₅₀; 40 mg/kg - Sheikh *et al.* [18]) only. Group III was administered 100 mg/kg of Silymarin as reported by Ahmed *et al.* [19], followed by 5 mg/kg of HgCl₂. Groups IV was administered 500mg/kg of aqueous fruit extract of *P. dactylifera* followed by 5 mg/kg of HgCl₂. Group V was administered 1000 mg/kg of aqueous fruit extract of *P. dactylifera* followed by HgCl₂ at 5 mg/kg. Groups VI was administered 500 mg/kg of ethanol fruit extract of *P. dactylifera* followed

by HgCl₂ at 5 mg/kg. Group VII was administered 1000 mg/kg of ethanol fruit extract of *P. dactylifera* followed by 5 mg/kg of HgCl₂. Groups VIII was administered 1000 mg/kg of aqueous fruit extract of *P. dactylifera* only while Group IX was administered 1000 mg/kg of ethanol fruit extract of *P. dactylifera* only. The administrations were orally done and lasted for a period of 2 weeks as shown in Table 1.

Table 1: Treatment of Experimental Animals

Group	Treatment/ daily	Duration
I	Distilled water (2 ml/kg)	2 weeks
II	HgCl ₂ (5 mg/kg)	2 weeks
III	Silymarin (100 mg/kg) + HgCl ₂ (5 mg/kg)	2 weeks
IV	AFPD (500 mg/kg) + HgCl ₂ (5 mg/kg)	2 weeks
V	AFPD (1,000 mg/kg) + HgCl ₂ (5 mg/kg)	2 weeks
VI	EFPD (500 mg/kg) + HgCl ₂ (5 mg/kg)	2 weeks
VII	EFPD (1000 mg/kg) + HgCl ₂ (5mg/kg)	2 weeks
VIII	AFPD (1000 mg/kg) only	2 weeks
IX	EFPD (1000 mg/kg) only	2 weeks

Note: *Treatments were administrations orally. Mercuric chloride (HgCl₂); aqueous fruit extract of P. dactylifera (AFPD), ethanol fruit extract of P. dactylifera (EFPD).*

Animal Sacrifice

At the end of the experiment, the rats were humanely sacrificed under chloroform anesthesia. The rats were dissected, blood samples were collected with the use of sample bottles and the kidney was excised, weighed and fixed in 10% formal saline.

Biochemical Studies

Biochemical studies were carried out using the collected blood samples in the Department of Chemical Pathology, Faculty of Medicine, Ahmadu Bello University Teaching Hospital, Shika. Biochemical analysis for liver serum markers namely Alanine transaminase-ALT, Alkaline phosphatase- ALP and Aspartate aminotransferase- AST; and antioxidant enzyme activity namely malondialdehyde - MDA, superoxide dismutase - SOD, catalase - CAT and glutathione peroxidase - GSHPx were performed.

Histochemical Studies

At the end of the experiment, harvested liver organ was fixed in 10% formal saline and tissues were processed for histochemical (Godon and Sweet for demonstrating reticular fibers) analysis. Micrographs were examined under the light microscope.

Results

Phytochemical Analysis

Phytochemical analysis of aqueous and ethanol fruit extracts of *Phoenix dactylifera* indicating the presence of secondary metabolites is as shown in **Table 1**.

Table 1: Phytochemical Constituents of the Fruit Extracts of *Phoenix dactylifera*

	Aqueous extract	Ethanol extract
Constituents	Inference	Inference
Alkaloids	+	+
Anthraquinones	–	–
Carbohydrates	+	+
Cardiac glycosides	–	–
Flavonoids	+	+
Tannins	+	+
Saponins	+	+

+ = **Positive (present)**

– = **Negative (absent)**

Biochemical Studies

Biochemical studies involved the analyses of serum liver enzymes, lipid peroxidation and antioxidant enzyme activities of the experimental animals.

Serum Liver Enzymes

The results showed increased levels of AST and ALT enzymes in the HgCl₂ treated group when compared to the control while other treatment groups revealed a decrease in these enzymes when compared to the HgCl₂ treated group. However, these changes were not significant as seen in figures 1 and 2. ALP levels increased significant ($p < 0.05$) in groups II, IV, VI and IX when compared to the control group as shown in Figure 3.

Lipid Peroxide Levels and Antioxidant Enzyme Activity

The malondialdehyde (MDA) or thiobarbituric acid-reactive-substances (TBARS) assay was used to estimate lipid peroxidation levels which is a marker of lipid peroxidation, while antioxidant enzymatic activity was estimated by assaying for superoxide dismutase (SOD), catalase (CAT) and glutathione peroxidase (GPx) activities using the serum of the rats.

Serum MDA levels increased ($p < 0.05$) in the HgCl₂-treated group when compared to the control group. All other treated groups revealed non-significant changes in MDA as compared to the control. When compared to the HgCl₂-treated group, MDA levels decreased significantly in all the treated Groups as shown in figure 4.

The Serum SOD results showed non-remarkable changes in SOD activity in all the treated groups except in group IV which showed a remarkable increase in SOD activity as compared to the control group. In comparison to the HgCl₂-treated group, SOD activity increased remarkably in group IV as shown in figure 5.

There were no significant changes in serum CAT and GPx activity in all the treated groups when compared to control as well as the HgCl₂-treated group as shown in figures 6 & 7.

Histopathological Studies of the Liver

Histological sections of Wistar rats' liver stained with Gordon and Sweet, (GS) were examined under the light microscope and revealed the following:

The results of the histological observation of the liver sections of rats in the control group revealed normal reticulin framework as shown in figure 8, Plate a. In the group treated with HgCl₂ histological observation revealed areas of severe disintegrating reticulin framework when compared to the control as shown in figure 8, Plate b. The silymarin and AFPD-treated groups followed by HgCl₂ showed mild distortion of reticular fibers while the EFPD treated group followed by HgCl₂ was comparable to the control as seen in figure 8, Plate c – g. Histochemical examinations of the liver sections of Wistar rats treated with AFPD and EFPD only was also comparable to the control as shown in figure 8, Plate h & i.

Discussion

In the present study, preliminary phytochemical screening was carried out, and the protective effect of aqueous and ethanolic fruit extracts of *Phoenix dactylifera* on mercury-induced liver damage in Wistar rats were investigated using biochemical and histochemical techniques. Phytochemical screening of the plant (*Phoenix dactylifera*) fruit extracts (aqueous and ethanol), in the present study, revealed the presence of flavonoids, saponins, tannins and alkaloids which have been reported to possess nephroprotective activities [14, 20] in animals and cell culture models.

When there is damage to the liver, cellular enzymes namely AST, ALT and ALP leaks into the blood resulting in the elevation of their serum concentration. HgCl₂ is known to cause liver damage leading to elevated levels of AST, ALT, ALP [21, 22]. The results of the present study revealed that the rats treated with HgCl₂ showed increased blood levels of aspartate aminotransferase (AST), alanine aminotransferase (ALT) and significant increase in alkaline phosphatase (ALP) as compared to the control group. Rats that were pretreated with silymarin, AFPD and EFPD followed by HgCl₂ showed a decrease in AST, ALT, and ALP when compared to HgCl₂ treated group. Groups treated with AFPD revealed decreased levels of ALT and ALP but significant increase in AST level compared to HgCl₂ group. EFPD treated groups revealed decreased level of ALT and increased levels of AST and ALP when compared to HgCl₂ group. The present result indicated that aqueous and ethanol fruit extracts of *P. dactylifera* offer protection against HgCl₂ hepatotoxicity as supported by previous studies of Al-Qarawi *et al* [14] and Ali *et al.* [23].

Oral administration of HgCl₂ induced nephrotoxicity as observed by the increase in the levels of oxidative stress biomarkers. Malondialdehyde (MDA) levels significantly increased while the activities of superoxide dismutase (SOD), catalase (CAT) and glutathione peroxidase (GPx) decreased as a result of HgCl₂ exposure. This is as a result of the accumulation of toxic metabolites in the system brought about by HgCl₂ induced oxidative stress. Pretreatment with AFPD and EFPD followed by HgCl₂ significantly decreased the level of MDA and restored (increased) the activities of SOD, CAT and GPx towards normal. These findings corroborate the nephroprotective effect extracts of *P. dactylifera* against HgCl₂ induced toxicity. This result agrees with previous reports on the nephroprotective effects of *P. dactylifera* by Saafi *et al.* [20], Ali *et al.* [23].

In the present study, light microscopic examination of Gordon and Sweet stained histological sections of Wistar rats' liver tissues were carried out. The liver is the major site of metabolism, hence, resulting in severe damage when exposure to mercury occurs [24]. According to Wargovich *et al.* [25], mercury chloride is one of the most toxic forms of mercury because it easily forms organomercury complexes with proteins. Histochemical results obtained revealed normal reticular framework in the liver sections obtained from the control, however, sections from the HgCl₂ treated group showed areas of collapsed or disintegrated reticular frame work as a result of mercury toxicity. Reticulin fibers are thin fibers composed of collagen III which form a delicate stromal network in many organs. The reticulin network is particularly rich in the liver and can be seen along hepatic sinusoids. Since reticulin provides the stromal support for the liver parenchyma, the reticulin stain provides important information about the architectural integrity of

the liver. When hepatocytes are damaged and undergo necrosis, the reticulin fibers surrounding them collapse in the empty space left behind [26].

As a hepatoprotective agent, silymarin has been used for centuries to treat liver, spleen and gall bladder disorders [27]. The groups administered silymarin, AFPD and EFPD followed by HgCl₂ demonstrated areas of mild disintegration of the reticular fibers when compared to the HgCl₂ treated group. This indicates that the administration of silymarin, AFPD and EFPD ameliorated the severe effect of HgCl₂ toxicity. Treatment of Wistar rats with only AFPD and EFPD revealed normal reticulin fiber framework, an indication of the protective abilities possessed by the extracts of *Phoenix dactylifera*.

Conclusion

The result of the present study suggested that, the aqueous and ethanol fruit extracts of *Phoenix dactylifera* possesses the ability to protect against mercury-induced alterations in the liver of Wistar rats. As regards the outcome of this study, the hepatoprotective property of the extracts is comparable to that of the standard drug (silymarin), this maybe attributed to the antioxidant properties of the constituent phytochemicals, such as flavonoids. Also, the EFPD seems to have more protective effects when compared to the AFPD. This may be due to the quantity and quality of phytochemicals found in the EFPD owing to the preparation process. Thus, these extracts are potential candidates for use in the management and treatment of ROS-induced liver and kidney diseases.

Declarations

Ethical approval

This experiment complied with the international regulations guiding the use of Animals in biomedical research and experimental design as ethical Approval was obtained from Ahmadu Bello University Ethics Committee on the use of Animals for Research.

Funding

This research did not receive any specific grant from funding agencies in the public, commercial, or not-for-profit sectors.

Availability of data and materials

Not applicable.

Competing of interest

There was no competing of interest on financial and non-financial grounds.

Conflict of interest

There was no conflict of interest between the authors.

Authors contributions

All the authors contributed extensive and accordingly to the research work.

Acknowledgments

The authors wish to acknowledge the Department of Human Anatomy, Faculty of Basic Medical Sciences, Ahmadu Bello University, Zaria, for providing the facilities to conduct this study.

References

1. Wadaan MA. Effects of mercury exposure on blood chemistry and liver histopathology of male rats. *Journal of Pharmacology and Toxicology*. 2009;4(3):126-31.
2. Xu F, Farkas S, Kortbeek S, Zhang FX, Chen L, Zamponi GW, Syed NI. Mercury-induced toxicity of rat cortical neurons is mediated through N-methyl-D-Aspartate receptors. *Molecular brain*. 2012 Dec;5:1-4.
3. Hounkpatin AS, Roch C, Senou M, Dovonon L, Chibuisi G, Alimba SG, Gnonlonfoun JM, Glitho I. Protective effects of vitamin C on kidney, liver and brain: a study in wistar rats intoxicated with mercury. *Ann. UP Série Sci. Nat. Agron*. 2017;7:168-77.
4. Carvalho MC, Franco JL, Ghizoni H, Kobus K, Nazari EM, Rocha JB, Nogueira CW, Dafre AL, Müller YM, Farina M. Effects of 2, 3-dimercapto-1-propanesulfonic acid (DMPS) on methylmercury-induced locomotor deficits and cerebellar toxicity in mice. *Toxicology*. 2007 Oct 8;239(3):195-203.
5. Tchounwou PB, Ayensu WK, Ninashvili N, Sutton D. Environmental exposure to mercury and its toxicopathologic implications for public health. *Environmental Toxicology: An International Journal*. 2003;18(3):149-75.
6. Hafiz MA, Shalabi AF, Akhal IA. Chemical composition of 15 varieties of dates grown in Saudi Arabia. In *Proceedings of the Fourth Conference on the Biological Aspects of Saudi Arabia*. 1980. University of Riyadh.
7. El-Gazzar UB, El-Far AH. The ameliorative effect of *Phoenix dactylifera* extract on CCl₄ hepatotoxicity in New Zealand rabbits. *Journal of Applied Sciences Research*. 2009(September):1082-7.
8. Nadkarmi KM, *Indian Materia Medica Vol 1*. 1976 Mumbai, Bombay Popular Prakashan Pvt. Ltd.
9. Barh D, Mazumdar BC. Comparative nutritive values of palm saps before and after their partial fermentation and effective use of wild date (*Phoenix sylvestris* Roxb.) sap in treatment of anemia. *Research Journal of Medicine and Medical Sciences*. 2008;3(2):173-6.
10. Al-Daihan S, Bhat RS. Antibacterial activities of extracts of leaf, fruit, seed and bark of *Phoenix dactylifera*. *African Journal of Biotechnology*. 2012;11(42):10021-5.
11. Farnsworth NR, Akerele O, Bingel AS, Soejarto DD, Guo Z. Medicinal plants in therapy. *Bulletin of the world health organization*. 1985;63(6):965.

12. Vyawahare N, Pujari R, Khsirsagar A. Phoenix dactylifera: An update of its indigenous uses, phytochemistry and pharmacology.
13. Mohamed DA, Al-Okbi SY. In vitro evaluation of antioxidant activity of different extracts of Phoenix dactylifera L. fruits as functional foods. *Deutsche Lebensmittel-Rundschau*. 2005;101(7):305-8.
14. Al-Qarawi AA, Abdel-Rahman H, Mousa HM, Ali BH, El-Mougy SA. Nephroprotective action of Phoenix dactylifera. in gentamicin-induced nephrotoxicity. *Pharmaceutical Biology*. 2008;46(4):227-30.
15. Wahab AA, Mabrouk MA, Joro JM, Oluwatobi SE, Bauchu ZM, John AA. Ethanolic extract of Phoenix dactylifera L. prevents lead induced hematotoxicity in rats. *Cont. J. Biomed. Sci*. 2010;4:10-5.
16. Agbon AN, Kwaneshie HO, Hamman WO. Antidiarrheal activity of aqueous fruit extract of Phoenix dactylifera (DATE PALM) in Wistar rats. *British Journal of Pharmacology and Toxicology*. 2013 Jun 25;4(3):121-7.
17. Trease GE, Evans WC. Phytochemicals. In: *Pharmacognosy*. 2002;15: 42-393.
18. Sheikh TJ, Patel BJ, Joshi DV, Patel RB, Jegoda MD. Repeated dose oral toxicity of inorganic mercury in wistar rats: biochemical and morphological alterations. *Veterinary World*. 2013 Aug 1;6(8).
19. Ahmed AF, Mahmoud MF, Ouf MA, Abd El-Fathaah E. Aminoguanidine potentiates the hepatoprotective effect of silymarin in CCL4 treated rats. *Annals of hepatology*. 2016 Apr 15;10(2):207-15.
20. Saafi-Ben Salah EB, El Arem A, Louedi M, Saoudi M, Elfeki A, Zakhama A, Najjar MF, Hammami M, Achour L. Antioxidant-rich date palm fruit extract inhibits oxidative stress and nephrotoxicity induced by dimethoate in rat. *Journal of physiology and biochemistry*. 2012 Mar;68:47-58.
21. Uzunhisarcikli M, Aslanturk A, Kalender S, Apaydin FG, Bas H. Mercuric chloride induced hepatotoxic and hematologic changes in rats: The protective effects of sodium selenite and vitamin E. *Toxicology and industrial health*. 2016 Sep;32(9):1651-62.
22. Shi M, Lam TT, Hon CC, Hui RK, Faaberg KS, Wennblom T, Murtaugh MP, Stadejek T, Leung FC. Molecular epidemiology of PRRSV: a phylogenetic perspective. *Virus research*. 2010 Dec 1;154(1-2):7-17.
23. Abedi A, Karimian SM, Parviz M, Mohammadi P, Roudsari HR. Effect of aqueous extract of Phoenix dactylifera pollen on dopamine system of nucleus accumbens in male rats. *Neuroscience and medicine*. 2014 Mar 24;5(01):49-59.
24. Badr MI, AA AE, SS AE. Effects of some medicinal plants on bone formation and bone resorption in normal and diabetic rats. *Archives of Agriculture Sciences Journal*. 2019 Apr 1;2(1):13-27.
25. Wargovich MJ, Woods C, Hollis DM, Zander ME. Herbs, cancer prevention and health. *The Journal of nutrition*. 2001 Nov 1;131(11):3034S-6S.
26. Saxena R. Nonneoplastic Hepatobiliary Disease. *Essentials of Anatomic Pathology*. 2011:1771-827.
27. Shaker E, Mahmoud H, Mnaa S. Silymarin, the antioxidant component and Silybum marianum extracts prevent liver damage. *Food and Chemical Toxicology*. 2010 Mar 1;48(3):803-6.

Figures

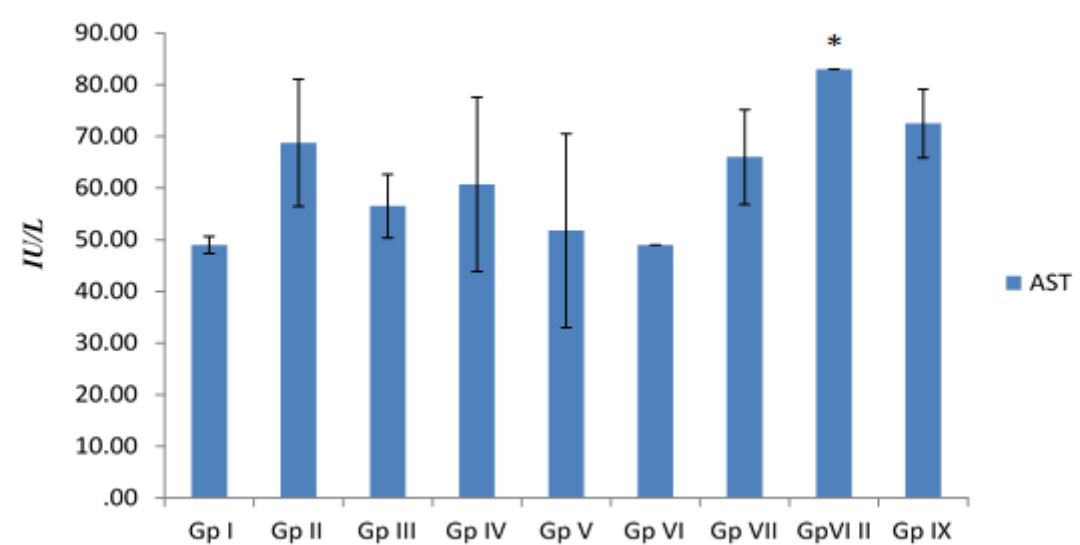


Figure 1

Effect of fruit extracts of *P.dactylifera* on Aspartate Transaminase (AST) against mercury-induced liver toxicity in Wistar rats

n=5, values are mean \pm SEM. * = $p < 0.05$; significant difference when compared with the control. **Gp I**=Control (distilled H₂O 0.5 ml/kg); **II**= HgCl₂ (5 mg/kg); **III**= Silymarin(100mg/kg); **IV and V**= Aqueous fruit extract of *P.dactylifera*(500 and 1,000 mg/kg respectively); **VI and VII**= Ethanol fruit extract of *P.dactylifera*(500 and 1,000 mg/kg respectively); **aqueous fruit extract of *P.dactylifera***(1,000 mg/kg); **Ethanol fruit extract of *P.dactylifera***(1,000 mg/kg)

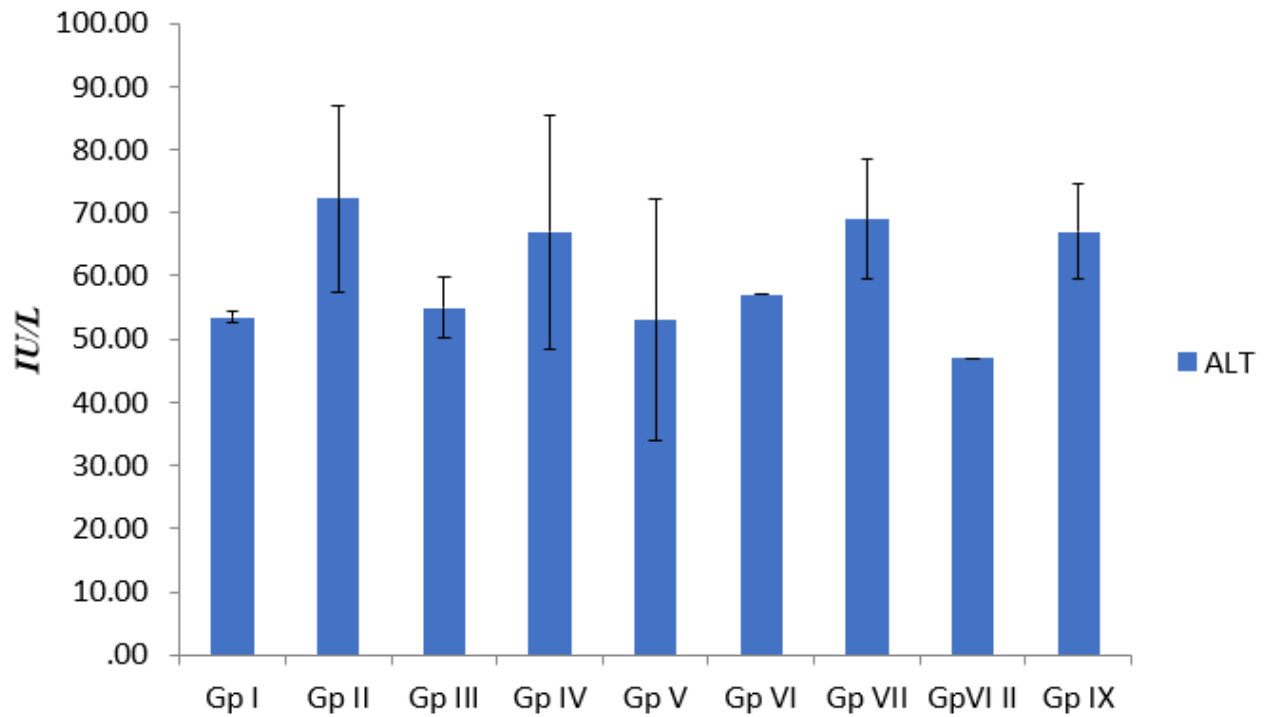


Figure 2

Effect of fruit extracts of *P.dactylifera* on Alanine Transaminase (ALT) against mercury-induced liver toxicity in Wistar rats

n=5, values are mean \pm SEM. $p > 0.05$; when compared with the control. **Gp I**=Control (distilled H₂O 0.5 ml/kg); **II**= HgCl₂ (5 mg/kg); **III**= Silymarin(100mg/kg); **IV and V**= Aqueous fruit extract of *P.dactylifera*(500 and 1,000 mg/kg respectively); **VI and VII**= Ethanol fruit extract of *P.dactylifera*(500 and 1,000 mg/kg respectively); **aqueous fruit extract of *P.dactylifera*(1,000 mg/kg)**; **Ethanol fruit extract of *P.dactylifera*(1,000 mg/kg)**

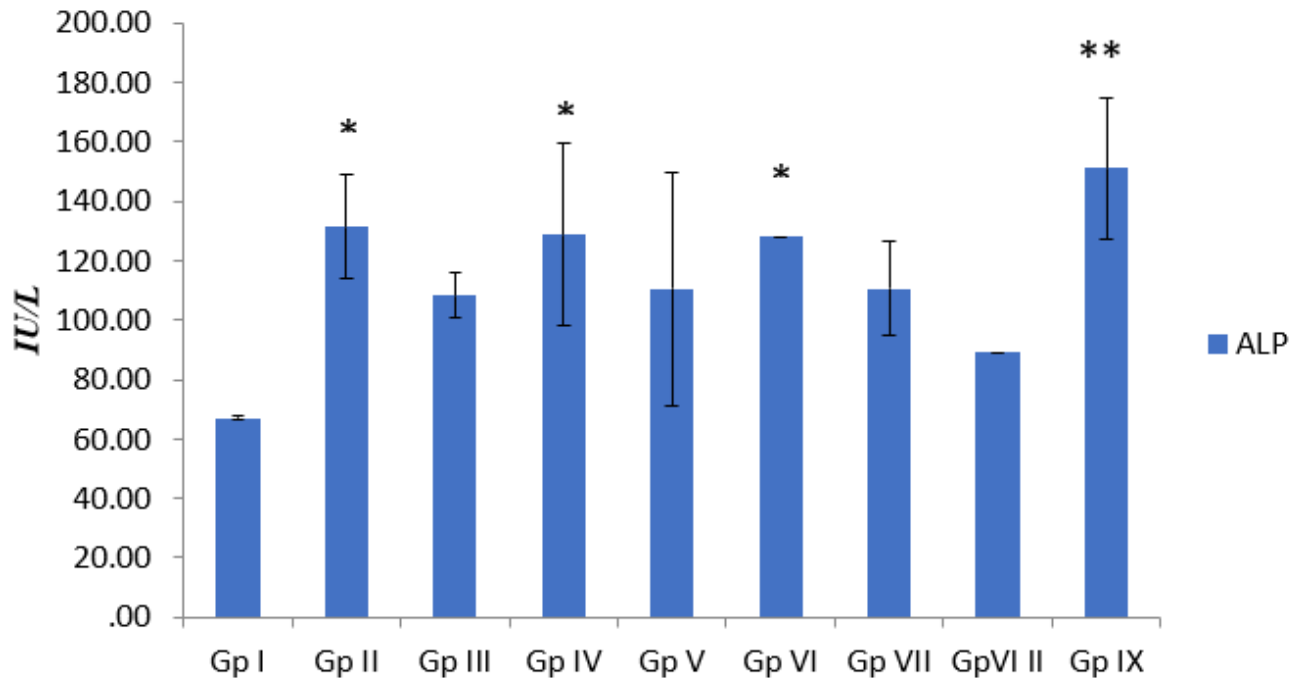


Figure 3

Effect of fruit extracts of *P.dactylifera* on Alkaline Phosphatase (ALP) against mercury-induced liver toxicity in Wistar rats

n=5, values are mean \pm SEM. * = $p < 0.05$; ** = $p < 0.01$; significant difference when compared with the control. **Gp I**=Control (distilled H₂O 0.5 ml/kg); **II**= HgCl₂ (5 mg/kg); **III**= Silymarin(100mg/kg); **IV and V**= Aqueous fruit extract of *P.dactylifera*(500 and 1,000 mg/kg respectively); **VI and VII**= Ethanol fruit extract of *P.dactylifera*(500 and 1,000 mg/kg respectively); **aqueous fruit extract of *P.dactylifera***(1,000 mg/kg); **Ethanol fruit extract of *P.dactylifera***(1,000 mg/kg)

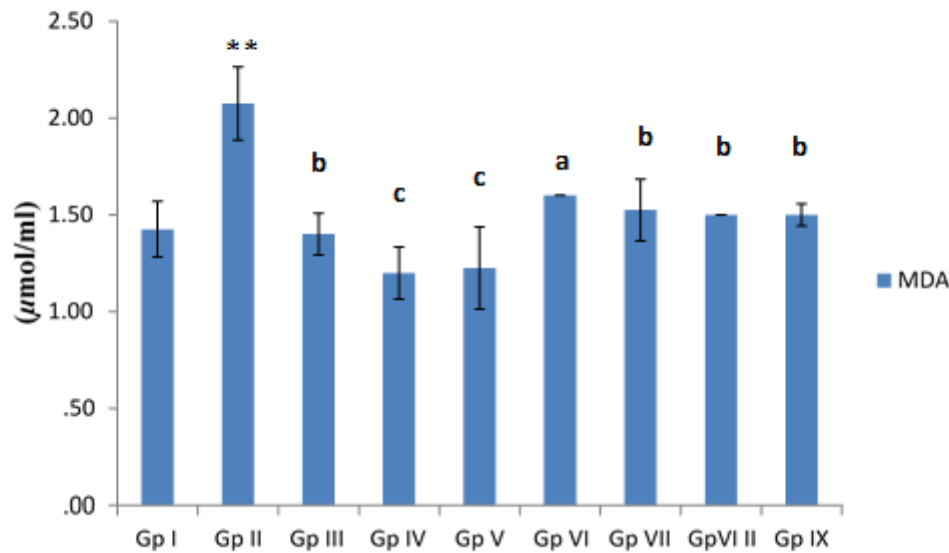


Figure 4

Effect of fruit extracts of *P. dactylifera* on blood serum Malondialdehyde (MDA) concentration of Wistar rats

n=5, values are mean \pm SEM. ** = $p < 0.01$; significant difference when compared with the control, a = $p < 0.05$, b = $p < 0.01$, c = $p < 0.001$; significant difference when compared with the MCL group. **Gp I**=Control (distilled H₂O 0.5 ml/kg); **II**= HgCl₂ (5 mg/kg); **III**= Silymarin (100mg/kg); **IV and V**= Aqueous fruit extract of *P.dactylifera* (500 and 1,000 mg/kg respectively); **VI and VII**= Ethanol fruit extract of *P.dactylifera* (500 and 1,000 mg/kg respectively); **aqueous fruit extract of *P.dactylifera* (1,000 mg/kg); Ethanol fruit extract of *P.dactylifera* (1,000 mg/kg)**

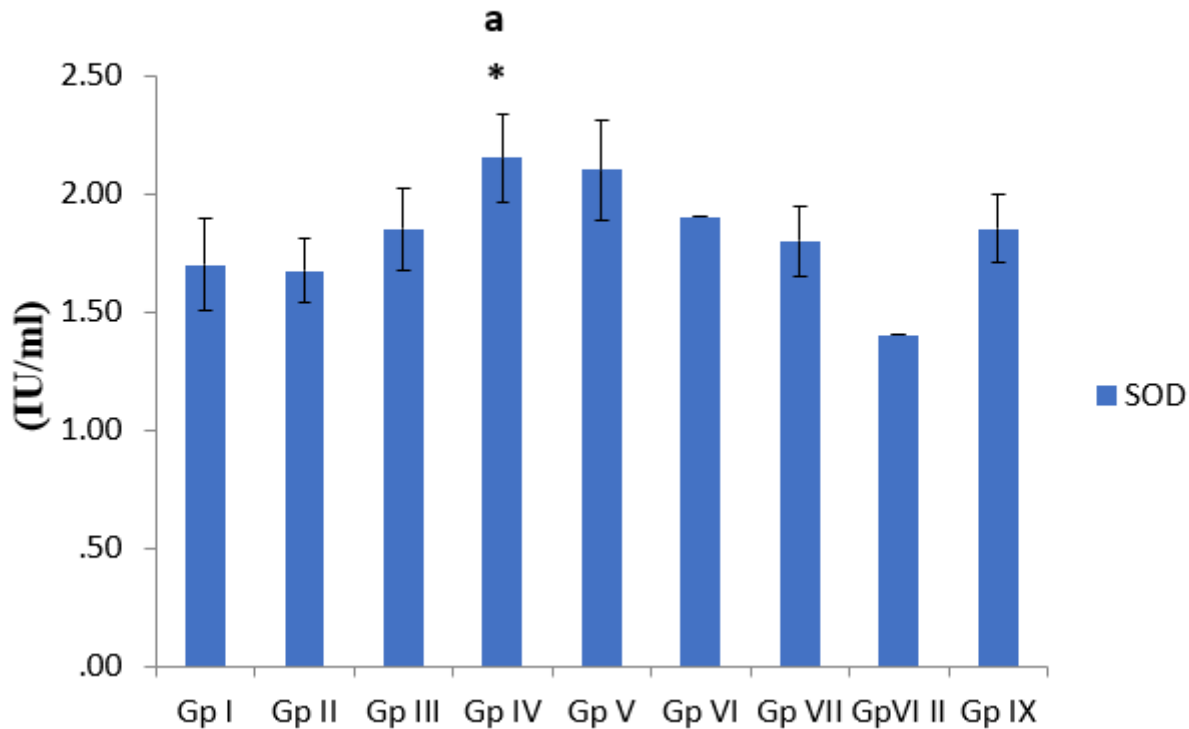


Figure 5

Effect of fruit extracts of *P. dactylifera* on blood serum Superoxide dismutase (SOD) activity of Wistar rats

n=5, values are mean \pm SEM. * = $p < 0.05$; significant difference when compared with the control; **a** = $p < 0.05$; significant difference when compared with the MCL group. **Gp I**=Control (distilled H₂O 0.5 ml/kg); **II**= HgCl₂ (5 mg/kg); **III**= Silymarin (100mg/kg); **IV and V**= Aqueous fruit extract of *P.dactylifera* (500 and 1,000 mg/kg respectively); **VI and VII**= Ethanol fruit extract of *P.dactylifera* (500 and 1,000 mg/kg respectively); **aqueous fruit extract of *P.dactylifera* (1,000 mg/kg); Ethanol fruit extract of *P.dactylifera* (1,000 mg/kg)**

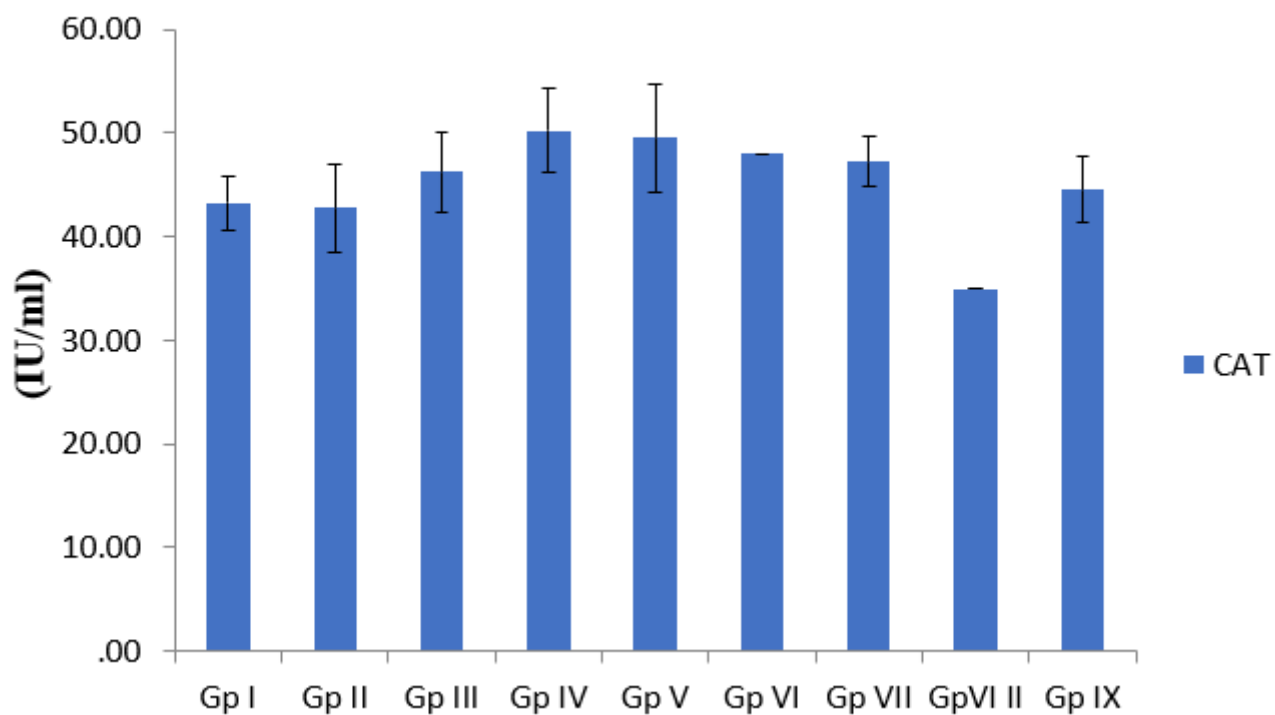


Figure 6

Effect of fruit extracts of *P. dactylifera* on blood serum Catalase (CAT) activity of Wistar rats

n=5, values are mean \pm SEM. $p > 0.05$; when compared with the *control*. **Gp I**=Control (distilled H₂O 0.5 ml/kg); **II**= HgCl₂ (5 mg/kg); **III**= Silymarin (100mg/kg); **IV and V**= *Aqueous fruit extract of P.dactylifera* (500 and 1,000 mg/kg respectively); **VI and VII**= *Ethanol fruit extract of P.dactylifera* (500 and 1,000 mg/kg respectively); **aqueous fruit extract of P.dactylifera** (1,000 mg/kg); **Ethanol fruit extract of P.dactylifera** (1,000 mg/kg)

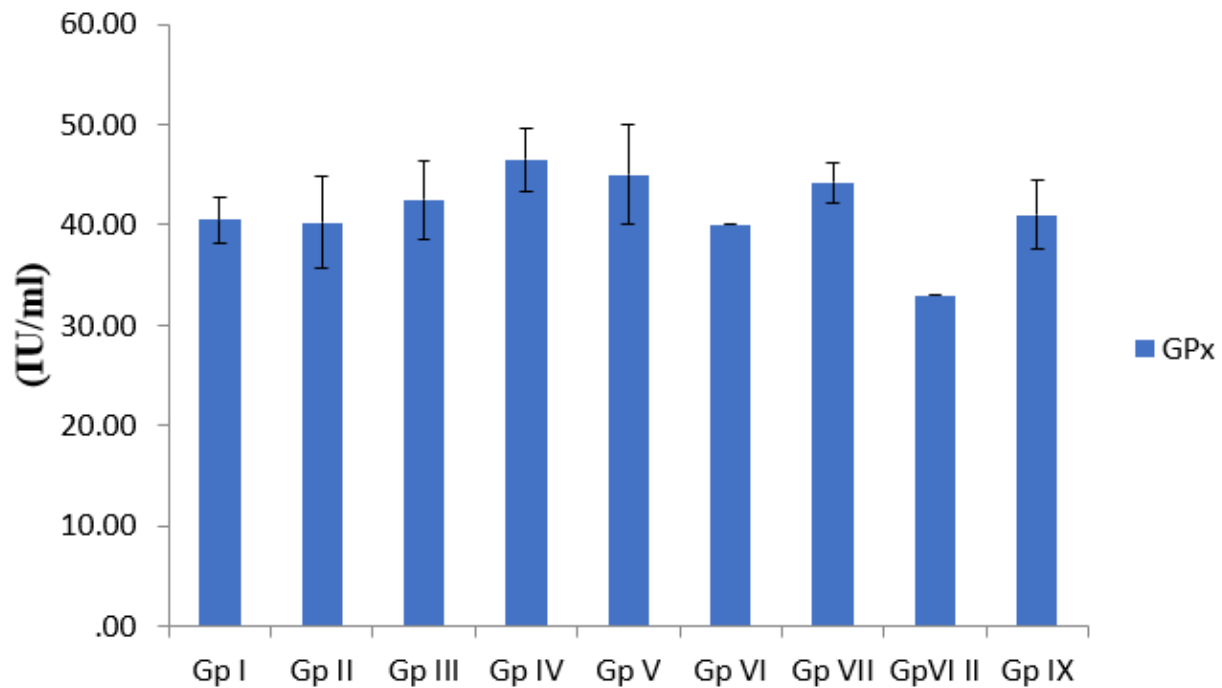


Figure 7

Effect of fruit extracts of *P. dactylifera* on blood serum Glutathione peroxidase (GPx) activity of Wistar rats

n=5, values are mean ± SEM. $p > 0.05$; when compared with the *control*. **Gp I**=Control (distilled H₂O 0.5 ml/kg); **II**= HgCl₂ (5 mg/kg); **III**= Silymarin (100mg/kg); **IV and V**= *Aqueous fruit extract of P.dactylifera* (500 and 1,000 mg/kg respectively); **VI and VII**= *Ethanol fruit extract of P.dactylifera* (500 and 1,000 mg/kg respectively); *aqueous fruit extract of P.dactylifera* (1,000 mg/kg); *Ethanol fruit extract of P.dactylifera* (1,000 mg/kg)

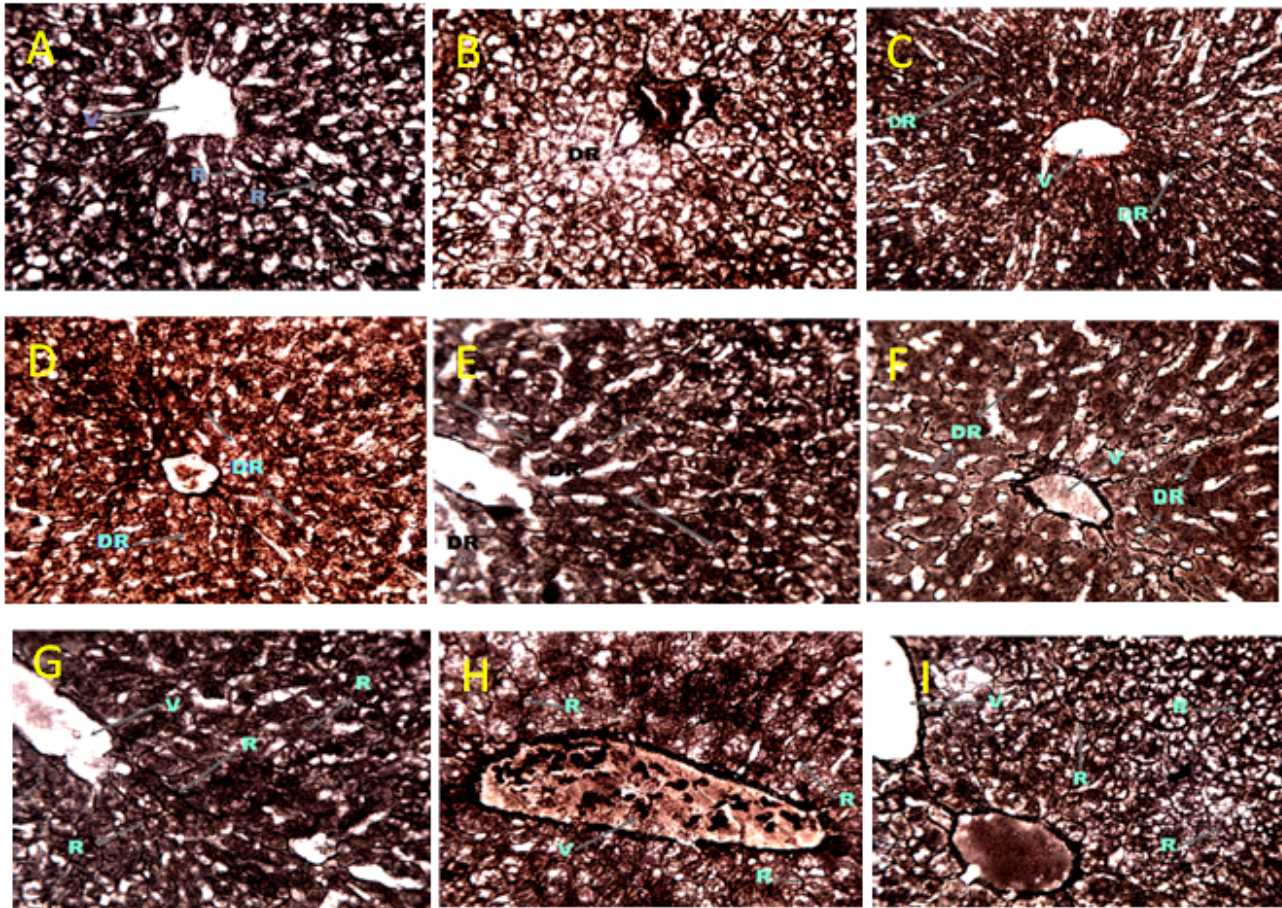


Figure 8

The liver section of Wistar rat (G & S x 250)

Plate a: Photomicrograph of the transverse section of Liver section of Wistar rat of Control Group showing; normal reticular framework (R); Central vein (V). Gordon and Sweet; (Mag x 250).

Plate b: Photomicrograph of the transverse section of Liver section of Wistar rat of Group II demonstrating area of disintegrated reticulin framework (DR). Gordon and Sweet; (Mag x 250).

Plate c: Photomicrograph of the transverse section of Liver section of Wistar rat of Group III demonstrating areas of disoriented reticulin framework (DR). Central vein (V). Gordon and Sweet; (Mag x250).

Plate d: Photomicrograph of the transverse section of Liver section of Wistar rat of Group IV demonstrating areas of disintegrated reticulin fiber (DR). Gordon and Sweet; (Mag x 250).

Plate e: Photomicrograph of the transverse section of Liver section of Wistar rat of Group V demonstrating areas of disintegrated reticulin fibers (DR); Central vein (V). Gordon and Sweet; (Mag x 250).

Plate f: Photomicrograph of the transverse section of Liver section of Wistar rat of Group VI demonstrating disoriented reticulin framework (DR); Central vein (V). Gordon and Sweet; (Mag x 250)

Plate g: Photomicrograph of the transverse section of Liver section of Wistar rat of Group VII demonstrating normal reticulin framework (R). Central vein (V). Gordon and Sweet; (Mag x250).

Plate h: Photomicrograph of the transverse section of Liver section of Wistar rat of Group VIII demonstrating normal reticulin fibers (DR). Central vein (V). Gordon and Sweet; (Mag x250).

Plate i: Photomicrograph of the transverse section of Liver section of Wistar rat of Group IX demonstrating normal reticulin framework (R); Central vein (V). Gordon and Sweet; (Mag x250).