

CHAPTER

32

VIRUSES

■
Helga Gerlach

Worldwide movement of birds for the pet market can cause a blending of different populations with the possibility of carrying widely varying microorganisms or antibodies against them. If one group of birds is exposed to another with a latent infection, then a severe disease outbreak can occur. Such latently infected birds create a diagnostic and flock management dilemma. While the carrier birds may be clinically inconspicuous, the virus may propagate at a low level and shed through the feces, urine, respiratory secretions or exfoliated epithelial cells from the feathers or skin. In some cases, latently infected birds may succumb to disease, with the virus replicating very rapidly, and both groups of birds may become sick. Artificial incubation and shipping of eggs has been suggested as a method to protect a given population from introduction of an exogenous virus. However, this concept is flawed because a hen can pass antibodies and some viruses to her offspring while the egg is developing. Infected neonates can cause severe epornitics with high mortality in a nursery situation.

In general, viral infections remain untreatable. Non-specific supportive care, antimicrobials to prevent secondary bacterial and fungal infections and good nutritional support, including the supplementation of vitamin C, remain the only available therapeutic regimens for most viral infections. Newly emerging concepts in the use of antisense RNA will undoubtedly result in more specific therapies for many infectious diseases (see Chapter 6). Interferon has been suggested for treatment of viral infections. Paramunity inducers have proven effective with some viral diseases.^{334,365} Acyclovir has proven to be effective with some strains of avian herpesvirus and may have positive effects in treating poxvirus infections (see Table 32.18). Substantial viral disease outbreaks may be prevented by having a working knowledge of the transmission routes and pathogenesis of a particular virus, by using specific diagnostic tests to detect clinical or subclinical infections, by practicing sound hygiene and by maintaining closed aviaries. Virus adaptation on specific host cells may be difficult to overcome with the routine avian culture systems, and great patience might be necessary when trying adaptation passages (at least ten or more). Continued international cooperation will be mandatory for the expansion of knowledge in the field of avian virology. The application of molecular biology

techniques seems to improve the researcher's ability to diagnose infections and to establish the role that viruses play in the disease process.

Diagnostic Principles

An unequivocal diagnosis of a particular viral infection can be made only through specific laboratory diagnostic methods. Clinical, pathologic and histologic changes are perhaps suggestive of a diagnosis but pathognomonic lesions are rare, and in-depth diagnostic tools are necessary to confirm a virus as a cause of morbidity or mortality in an avian host (Table 32.1). There are several procedures that can be used to confirm the presence of a viral infection: 1) Isolation of the pathogen from the test material; 2) Demonstration of viral particles or inclusion bodies by histopathology; 3) Demonstration of viral antigen (Ag) in infected tissues using viral-specific antibodies (Ab); 4) Demonstration of viral nucleic acid in infected tissues using viral-specific nucleic acid probes; 5) Indirect demonstration of a viral infection by detection of humoral antibodies. A viral disease can sometimes be demonstrated by a rise in antibody titers in paired serum samples.

Viral-specific nucleic acid probes are more sensitive than other techniques and allow the detection of small concentrations of virus as well as the ability to detect the presence of viral nucleic acid before substantial histologic changes may have occurred.

Virus Cultures

Choosing an optimum culture system for avian viruses is difficult. There are over 8,700 avian species, which probably have an equally large number of specifically host-adapted viruses. Primary cell cultures from fibroblasts, kidney or liver cells collected from embryos of the test species normally provide the best chance of isolating a host-adapted virus. Unfortunately, such embryos (which should ideally be free of specific pathogens) are rarely available for the bird species seen in private practice. Cell cultures derived from chickens, ducks and geese are most often used as an alternative choice because of their wide availability; however, these sources of cells have inherent problems. Not every newly prepared cell culture is identical to its predecessor, which may affect virus propagation. If pathogens from heterologous bird

TABLE 32.1 Virus Identification Tests

Immunodiffusion (ID)

The ID is a common, inexpensive method to demonstrate mainly group-specific soluble antigens (primarily IgM). The antigen and antibody diffuse toward each other in an agar gel. Where reactive partners meet, they form a precipitate that is visible as one or several pale lines. This technique is relatively simple and adequately fulfills several objectives. It is, however, relatively insensitive when compared to other techniques. The gel should contain 8% NaCl when testing avian serum (Figure 32.1).

Hemagglutination Inhibition Test (HI)

Proteins present on the surface of some viruses agglutinate erythrocytes from certain avian or mammalian species. By adding antibodies directed against the agglutinating portion of the virus, hemagglutinin activity is neutralized so that hemagglutination cannot take place (hemagglutination inhibition - HI). The HI test recognizes surface antigens (primarily detects presence of IgG).

Virus Neutralization Test (VN)

Test serum is mixed with an antigen. If viral-specific neutralizing antibodies are present in the test serum, and the quantitative ratio is correct, then virus in a sample will be neutralized. Determining that an Ag-Ab reaction has occurred must then be demonstrated by showing that the neutralized virus is incapable of inducing disease in a test system (usually cell culture). Although VN tests can be performed for many viruses, they are time-consuming and require a series of dilutions that consume a large quantity of raw materials and reagents. The VN test is suitable for serotyping depending on the virus species and the type of antibody used.

Complement-Fixation (CF)

Complement is necessary for binding to occur between Ag and Ab. If an Ag-Ab reaction occurs with test material then complement is fixed (used up), and a second reaction with an Ag-Ab indicator system can no longer take place. This system is just as complicated as the ELISA test, which is much more sensitive. Furthermore, commercially available guinea pig complement is inappropriate for use with many bird species. The CF test is generally used for demonstrating group-specific antigens.

ELISA

Antigen or antibody is bound firmly to a plate. A test material is added (can be serum for detecting Ab or tissue samples for detecting Ag). The occurrence of an Ag-Ab reaction is demonstrated by adding a third Ag or Ab that is conjugated with an enzyme. A substrate that is converted by the bound enzyme is added to the system and a color change occurs. This system is highly sensitive and technically simple to operate. However, preparation of the appropriate enzyme conjugate with a correspondingly high degree of specificity is demanding. Nonspecific reactions are frequently observed. Generally, the ELISA recognizes group-specific antigens; however, with the use of monoclonal antibodies, serotypes, biovars or mutants can be demonstrated.

Immunofluorescence (IF)

Antigen or Ab is conjugated with fluorescent dyes. If an Ag-Ab reaction occurs with test material then fluorescence is present after washing off the superfluous reagents. Nonspecific fluorescence that complicates interpretation of the test is common. The IF is best suited for demonstration of group-specific antigens.

Radioimmunoassay (RIA)

Either antigens or antibodies are radioactively labelled. The technique itself is essentially similar to that of IF. Although this method is very sensitive, it presents inherent dangers to personnel dealing with radioactive materials as well as creating disposal problems for radioactive waste. Identification of group-specific antigens, serovars or individual antigenic sites is possible with the correct antibodies.

species will grow in non-host cell cultures at all, they often require repeated passages for adaptation to the cells, prolonging the recovery of a virus from weeks to months. Many viral pathogens have never been successfully isolated in cell culture.




FIG 32.1 Agar-gel diffusion test using serum from an adult psittacine bird three weeks after vaccination with an experimental inactivated PBFD virus vaccine. The initial precipitating antibody titer was 0. The presence of a precipitation line at 1/80 (arrow) indicates that the bird seroconverted following vaccination and produced anti-PBFD virus precipitating antibodies.




FIG 32.2 Some viruses will cause the agglutination (no button forms) of certain types of erythrocytes. Noted examples of avian viruses that will agglutinate some erythrocytes include PBFD virus, polyomavirus and paramyxovirus. Antibodies to these viruses can be detected by determining if serum from a patient prevents agglutination (the antibodies bind to the hemagglutination site on the RBC and allow a button to form). In this photograph, decreasing dilutions of PBFD virus were used to agglutinate (HA) guinea pig and cockatoo erythrocytes. The point at which the diluted virus will no longer agglutinate the cells (button forms) is the HA titer for the virus. Anti-PBFD virus antibodies could be detected by showing that serum would block (hemagglutination inhibition-HI) the virus from causing agglutination, which allows a button to form (reprinted with permission from *Am J Vet Res* 52:1991).

In addition to tissue cultures, embryonated eggs have been used to recover avian viruses. In contrast to tissue culture, they offer a complete biologic system with cells of endo-, meso- and ectodermal origin. The flocks from which these eggs are obtained should be free of viruses and virus antibodies in order to allow a particular virus to grow.

Virus Identification

Direct identification of a virus by electron microscopy is possible only with a relatively high concentration of the virus (generally $>10^6$ particles/ml). As a rapid but insensitive survey, fresh tissue samples fixed on grids (stained with osmium or another appropriate stain) can be examined by electron microscopy for the presence of viruses. Viral-specific nucleic acid probes allow the detection of very small concentrations of a virus in infected tissues or contaminated samples (crop washing, feces, respiratory excretions). Analytic methods such as electrophoresis without blot systems (Ab-dependent with blots), chromatography and nucleic acid probes are the most sensitive methods of demonstrating virus. They function independent of Ag-Ab reactions. The recent advances in genetic engineering will certainly have profound effects on virus detection in the future. DNA probes are currently available for detecting polyomavirus and psittacine beak and feather disease virus. Other similar diagnostic tests will ultimately be developed. All other methods of virus identification are based on changes induced by the virus, such as histologically discernible inclusion bodies. Viral-specific antibody preparations can be used to confirm the presence of

a virus. Depending on the test objective, either polyclonal or monoclonal antibodies can be used. Monoclonal antibodies are normally used for identifying specific antigen structures and to differentiate between serotypes, subtypes, variants and mutants. Polyclonal antibodies are generally adequate for routine diagnostic tests. The identification of viruses using known antibodies inevitably requires an appropriate system to show that an antigen-antibody reaction has taken place. A test is chosen based on the objective of the test (group-specific antigens, serotyping) and the type of antibody (polyvalent, monovalent, monoclonal) available. Frequently used tests to demonstrate the presence of a virus or antibodies against a virus are listed in Table 32.2.

Indirect Virus Identification

Indirect virus identification techniques require the demonstration of specific antibodies in a patient's serum. To differentiate between Ab's that have been induced by prior exposure to an agent and those caused by a current infection, it is necessary to test two serum samples collected at two- to three-week intervals. A rise or fall in Ab concentrations or a switch from IgM to IgG are indicative of an active infection. Egg yolk (containing IgG) can be used in place of serum for some diagnostic tests.

Serologic cross-reactions caused by closely related antigens or epitopes with an identical structure can cause false-positive results when using indirect virus identification techniques. Precipitating Ab's (as used in the immunodiffusion test) consist primarily of IgM and are present relatively quickly after an infection and are broken down equally rapidly once the pathogen has been eliminated. The immunodiffusion test; therefore, is useful in diagnosing an actively occurring antibody response. It should be noted that not all infected individuals will produce precipitating Ab's.

Test Material

The proper test material for diagnosing viral infections depends on whether antemortem or postmortem samples are available and which viral disease is suspected. Antemortem samples may include feces, skin, organ or feather biopsy, blood or serum, or mucosal swabs from the trachea, cloaca, pharynx or conjunctiva. When flock problems occur, collecting fresh postmortem samples from a recently affected

bird is the best way to achieve an accurate diagnosis. Samples for culture should be transported quickly and well cooled in a transport medium containing antibiotics. A relevant anamnestic report is valuable to help guide the laboratory diagnostic efforts.

Avipoxvirus

Members of the Poxviridae family (*Avipoxvirus* genus) cause a variety of diseases in birds. These large DNA viruses (250 to 300 nm) induce intracytoplasmic, lipophilic inclusion bodies called Bollinger bodies (pathognomonic). These inclusion bodies may be identified in affected epithelial cells of the integument, respiratory tract and oral cavity. Many bird species are considered to be susceptible to some strain of poxvirus, and isolates from different bird species have been classified into taxons. Biologic and serologic-immunologic properties for many avian poxviruses have not been determined, and the currently described taxons are probably incomplete.

The genus *Avipox* seems to be restricted to birds. Most of the members of the genus seem to be species-specific, but some taxons appear to be able to pass the species, genus or even family barrier. Although certain poxvirus strains will experimentally infect a variety of host species, cross-immunity may not al-

TABLE 32.2 Characteristic Histologic Lesions and Diagnostic Techniques of Selected Avian Viruses

Virus	Characteristic Lesions	Diagnostic Methods
Adenovirus	Basophilic intranuclear inclusions	Histopathology, serology (AGID)
EEE	Non-suppurative encephalitis, "descending" encephalitis	Histopathology, serology (HI)
Herpesvirus	Basophilic to eosinophilic intranuclear inclusion bodies (Cowdry type A)	Histopathology, virus isolation (Ab titers inconsistent)
Papillomavirus	Hyperkeratotic epidermis, intranuclear inclusions	Histopathology
Polyomavirus	Enlarged cells containing clear basophilic or amphophilic inclusions	Histopathology suggestive, virus isolation, viral-specific DNA probes (detecting shedders and confirming infections), <i>in situ</i> hybridization of tissues
PBFD virus	Basophilic intranuclear inclusions in epithelial cells, basophilic intracytoplasmic inclusions in macrophages	Histopathology, viral-specific DNA probes (detecting symptomatic or asymptomatic infections in blood), <i>in situ</i> hybridization of tissues
Paramyxovirus		Electron microscopy (EM), serology (HI), viral isolation
Poxvirus	Epithelial ballooning degeneration, intracytoplasmic inclusions (Bollinger bodies) pathognomonic, intranuclear inclusion bodies	Histopathology, viral culture, virus detection in feces by culture or EM
Reovirus	Necrotizing hepatitis, rarely intracytoplasmic inclusions	Virus isolation

Viruses

Color 32.1

A young pionus parrot was confirmed to have PBFD virus by demonstrating viral antigen in infected tissues with viral-specific antibodies and by demonstrating viral nucleic acid in circulating white blood cells using a DNA probe test. This bird was infected as a neonate when the breeder unknowingly added some infected African Grey Parrot chicks to the nursery.

Color 32.2

An Umbrella Cockatoo chick shows the first clinical feather changes associated with PBFD virus a minimum of 34 days after being exposed to the virus. The bird was depressed for two days before necrotic feathers became apparent. All of this bird's primary and secondary feathers were affected within a week after this photograph was taken.

Color 32.3

PBFD virus in older birds is characterized by progressive feather dystrophy and loss that typically starts with the powder down feathers as seen in this Umbrella Cockatoo. The disease then progresses during the ensuing molts to a point where the flight and tail feathers are also involved.

Color 32.4

Scarlet Macaw with the progressive form of PBFD virus causing dystrophic changes in the primary and secondary feathers.

Color 32.5

An experimental PBFD virus vaccine has been shown to be effective in preventing infections in neonates. In this photograph, an infected (right) and a vaccinated, protected African Grey Parrot chick of the same age dramatically illustrate the effects of the PBFD virus on a developing chick.

Color 32.6

PBFD virus antigen and nucleic acid can be demonstrated in infected white blood cells

using viral-specific antibodies (shown here) or viral-specific DNA probes. The circulating white blood cells that are brown contain PBFD virus antigen. The other white blood cells in this preparation do not contain viral protein, suggesting that both infected and uninfected white blood cells are present in the circulation (courtesy of Kenneth Latimer).

Color 32.7

Immunoperoxidase staining of a feather from a bird with PBFD virus. Viral antigen is demonstrated in intranuclear (arrow) and intracytoplasmic (open arrow) inclusion bodies (courtesy of Kenneth Latimer).

Color 32.8

a) Large, basophilic intranuclear inclusion bodies are suggestive of avian polyomavirus. Infections can be confirmed only by documenting viral antigen or nucleic acid in suspect lesions using viral-specific antibodies (shown here) or **b)** DNA probes, respectively.

Color 32.9

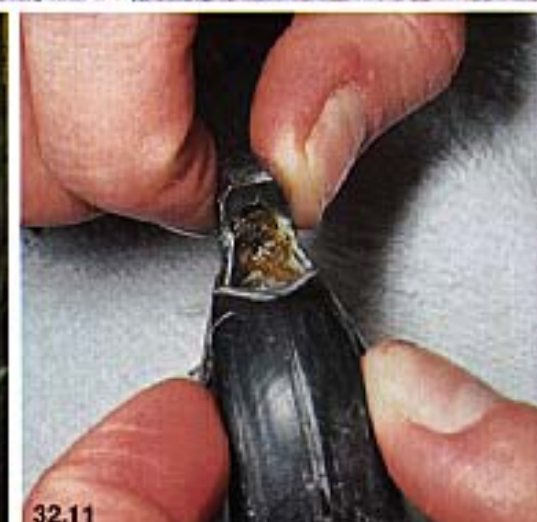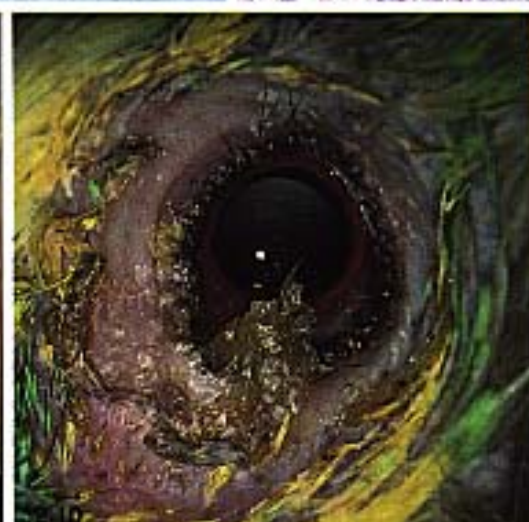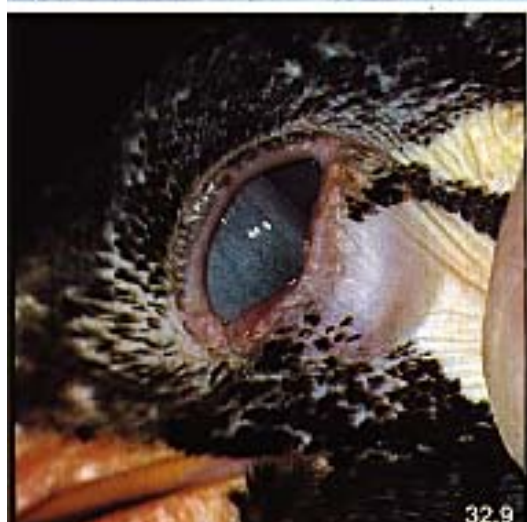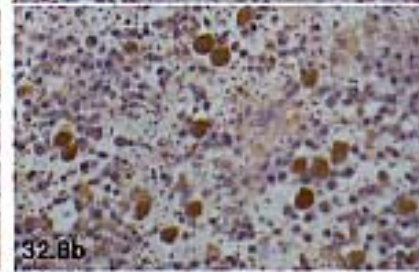
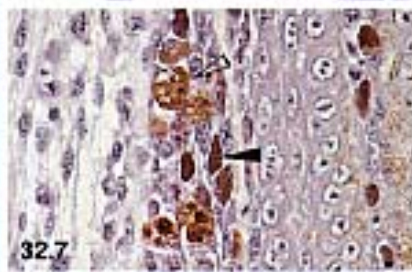
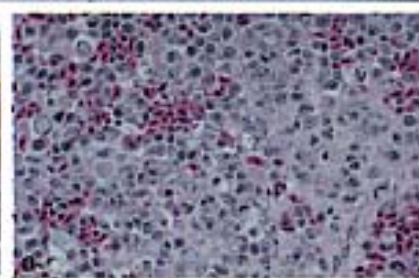
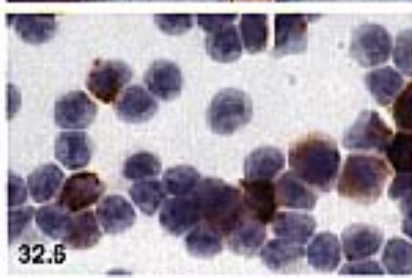
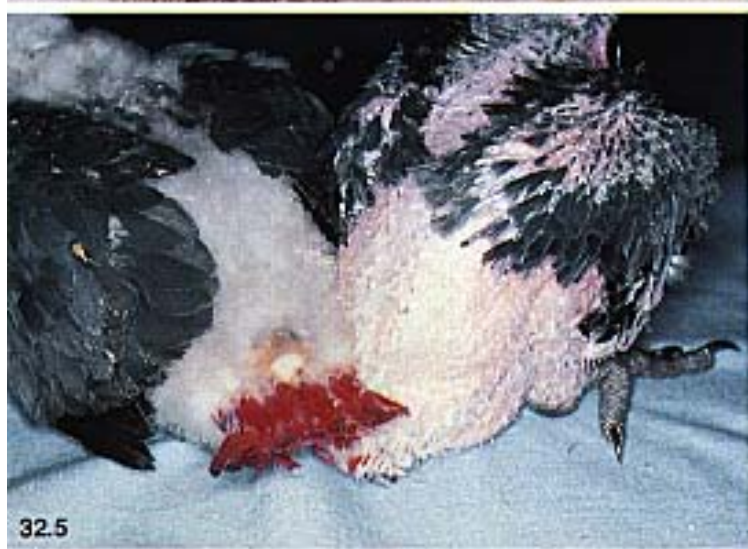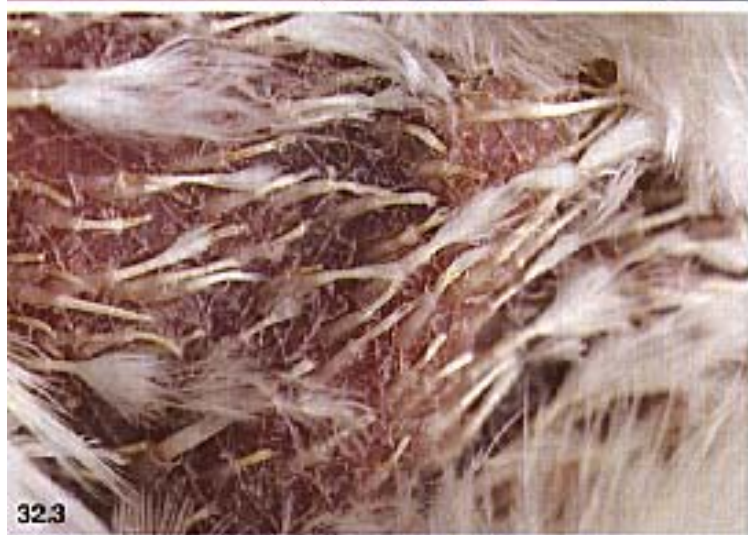Early poxvirus lesions on the lid margin of a mynah bird.

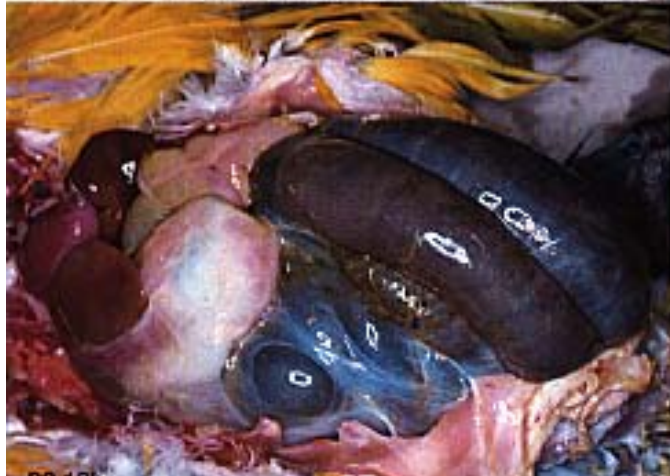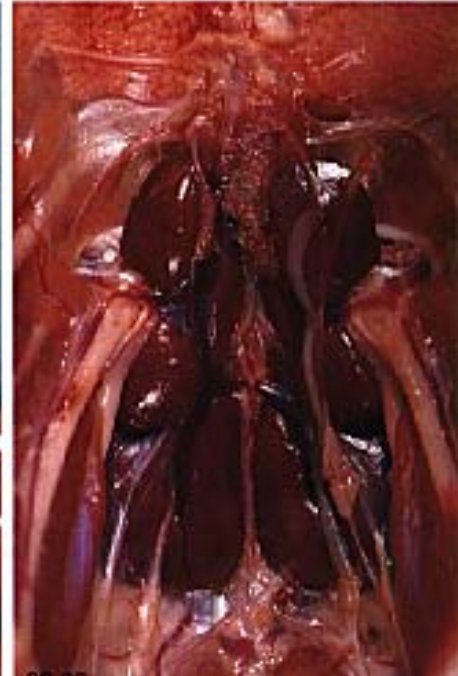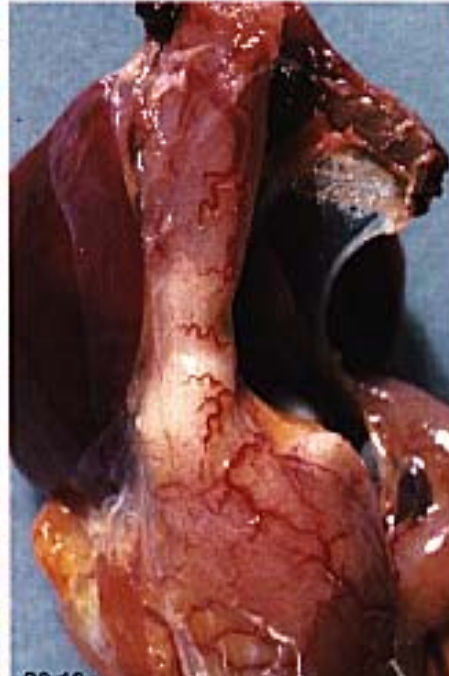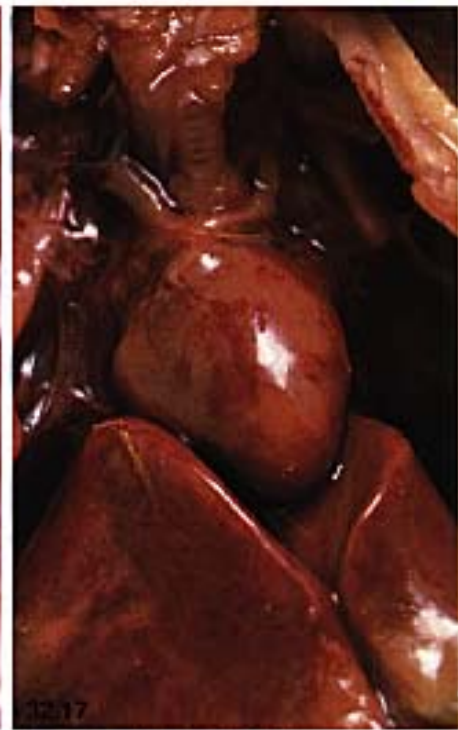
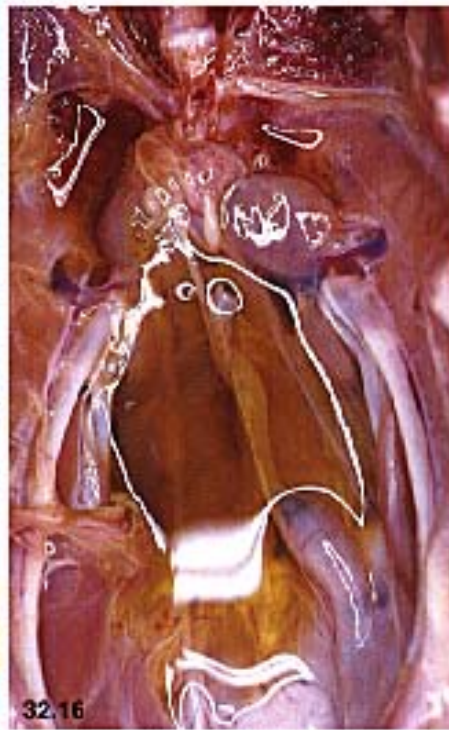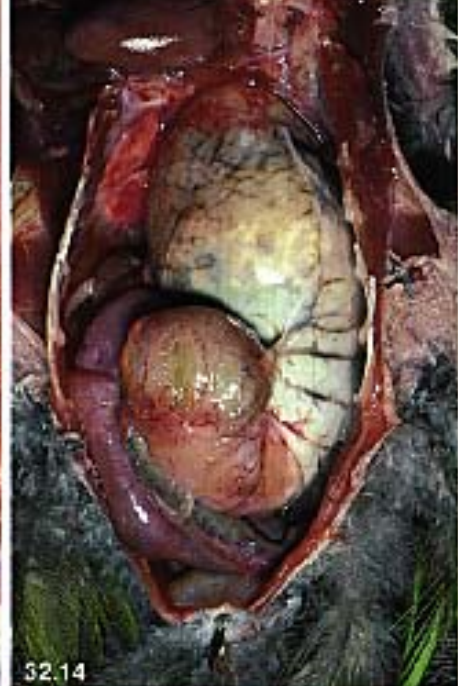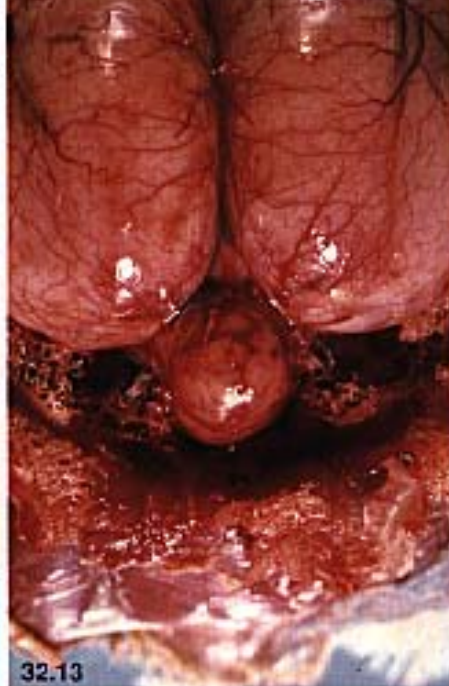Color 32.10

A recently imported Blue-fronted Amazon Parrot was presented with oculonasal discharge. Ulcerative lesions of the lid margins with accumulation of necrotic debris were characteristic for poxvirus. The bird responded to supportive care that included flushing the ocular lesions with sterile saline QID and administration of broad spectrum antibiotics to prevent secondary bacterial infections.

Color 32.11

Beak changes may or may not occur in birds with PBFD virus infections. If they occur, they generally start as palatine necrosis.





Viruses

Color 32.12

Subcutaneous hemorrhage in a Blue and Gold Macaw chick suggestive of a polyomavirus infection.

Color 32.13

A Moluccan Cockatoo was presented with a progressive neurologic disease that started with ataxia and tremors several months before presentation. The bird had an upper respiratory disease about two weeks before the CNS signs were first noted. The bird's feather condition was marginal. DNA probe testing for PBFV virus and polyomavirus were negative. Radiographs were normal. Abnormal clinicopathologic findings included WBC=25,000 (lymphocytosis) and CPK=1500. EEG indicated an inflammatory disease. The bird died despite extensive supportive care. Several milliliters of yellow fluid were collected from the brain cavity at necropsy. The brain was hyperemic. Histopathology indicated basophilic intranuclear inclusion bodies similar to those caused by adenovirus.

Color 32.14

Finding a dilated, thin-walled proventriculus is suggestive of neuropathic gastric dilatation. The diagnosis can be confirmed only by demonstrating characteristic histopathologic lesions including lymphoplasmacytic ganglioneuritis.

Color 32.15

A 25-day-old budgerigar with PBFV virus. The feather lesions caused by PBFV virus are grossly similar to those caused by polyomavirus. French moult may be caused by either the PBFV virus or polyomavirus. Differentiation of these viral diseases requires detection of viral-specific antibodies or viral-specific DNA probe testing.

Color 32.16

Typical fluid accumulation in the abdomen of a Blue and Gold Macaw with avian viral serositis.

Color 32.17

A Blue and Gold Macaw chick was presented for evaluation. The bird was in a comatose state and was the sixth baby from a psittacine nursery to die acutely. The bird had subcutaneous hemorrhages, hepatomegaly and swollen hemorrhagic kidneys, all suggestive of polyomavirus. The bird was confirmed to have avian polyomavirus by identifying suggestive intranuclear inclusion bodies in the liver, spleen, kidneys and heart and by DNA probe detection of viral nucleic acid on a swab taken from the cut surface of the liver and spleen.

Color 32.18

An 18-week-old Blue and Gold Macaw was presented with a one-week history of lethargy and regurgitation. **a)** The abdomen was severely enlarged and filled with fluid. Abnormal clinicopathologic findings included TP=0.7, PCV=19, WBC=3,000. Radiographs indicated ileus with severe bowel loop distension. **b)** Gross necropsy findings included distension of the black, congested intestines. Histopathology indicated multifocal nonsuppurative serosities and lymphocytic proventriculus suggestive of avian viral serositis. The bird's clutch mate died several weeks later with the same lesions.

Color 32.19

A cockatoo that had been exposed to birds with neuropathic gastric dilatation (NGD) was suspected to have the disease based on clinical signs of diarrhea, hypermotility of gastrointestinal tract (as detected by contrast radiography) and weight loss. The bird died acutely. The only gross necropsy lesion was congestion of the gastric vasculature. The bird had histologic lesions consistent with NGD.

Color 32.20

Congestion and hemorrhage of the kidneys in a female Blue and Gold Macaw chick with avian polyomavirus.

ways be inducible. Further, the *Avipox* genus has a high capacity for recombination, which has been shown to occur between field and vaccine strains of virus when actively infected flocks are vaccinated. Many experimental infections have been performed without determining the strain of virus, which probably adds to confusion about poxvirus epizootiology.

Various *Avipox* spp. demonstrate serologic cross-reactions (VN and ID). Hemagglutinins are not produced. Species differentiation is based on host spectrum, plaque morphology of primary isolates, thermostability, optimal propagation temperature, serology, cross-immunity and ultrastructural characteristics (Tables 32.3, 32.4).

Waterfowlpox probably does not form a uniform group. Therefore, it can be expected that the full protection provided by fowlpoxvirus is not effective in all waterfowl species.

Peacock poxvirus can experimentally infect chickens but not domesticated pigeons and probably not turkeys. However, peafowl vaccinated with fowlpoxvirus were not protected against peacockpox.¹⁶

Poxvirus lesions have been documented on the feet, beak and periorbitally in numerous Passeriformes.^{216,403}

Transmission

Transmission occurs through latently infected birds and biting arthropods in the habitat. In many areas, mosquitoes serve as the primary vectors, and infections are most common during late summer and autumn when mosquitoes are prevalent. Birds of any age are considered susceptible, although young birds are most frequently affected. A mosquito that feeds on an infected bird can retain infectious virus in the salivary glands two to eight weeks. Direct transmission of the virus between birds is linked to traumatic injuries induced by territorial behavior, which allows the virus access to the host through damaged epithelium.

Pathogenesis

Most members of the Poxviridae stimulate the synthesis of DNA in the host's epithelial cells resulting in hyperplasia of the affected epithelium. Avipoxvirus cannot penetrate intact epithelium. Traumatic lesions that may be induced by biting insects (mosquitoes, mites and ticks) can cause sufficient damage to the epithelial barrier to allow viral entrance to the host. Infections may be restricted to the portal of entry, or viremia and subsequent distribution to tar-

get organs may occur. The factors that control the type of infection have not been determined; however, it is known that a severe generalized disease occurs only if the infection takes the two-cyclic course (Figure 32.3).

This replication cycle occurs only with pathogenic strains, and the secondary viremia does not occur with nonpathogenic, slightly pathogenic or modified live virus vaccine strains. These strains generally induce an infection restricted to the inoculation site.

Avian poxvirus infections, particularly in a flock situation, can remain latent for years.^{155,216} Non-specific stress factors are associated with viral reactivation. It has been suggested that latent poxvirus infections (including vaccine strains) can be egg transmitted (at least in the chicken).¹⁵⁵ Fowlpoxvirus (including vaccine strains) is known to induce a mild immunodepression that potentiates secondary infections.²⁵

Clinical Disease and Pathology

Infections induced by poxvirus vary in clinical expression based on the virulence of the virus strain, the mode of transmission and the susceptibility of the host. The course of the disease is generally subacute, and it takes three to four weeks for an individual to recover. Flock outbreaks require two to three months to run their course. Clinically recognized symptoms include:

- **Cutaneous Form ("Dry Pox"):** The cutaneous form is the most common form of disease in many raptors and Passeriformes but not in Psittaciformes. Changes are characterized by papular lesions mainly on unfeathered skin around the eyes, beak, nares and distal to the tarsometatarsus. The interdigital webs are most frequently affected in waterfowl and the Shearwater. As lesions progress, papules change

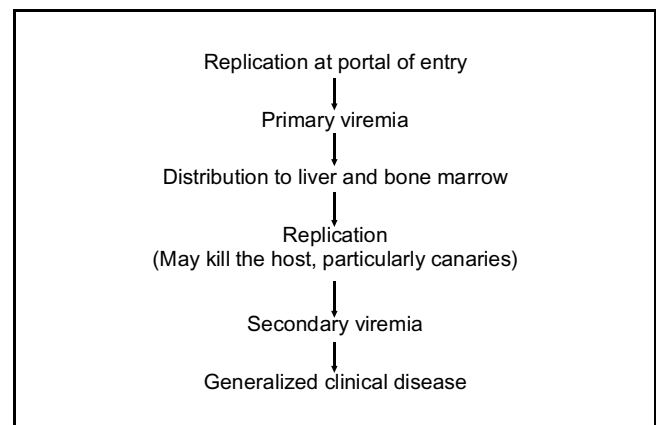


FIG 32.3 Two-cycle stage of infectivity of avian poxvirus infection.

TABLE 32.3 Survey of Avian Poxvirus

Virus	Host Spectrum	Virus	Host Spectrum
Fowlpox	Chicken, Blue Grouse, Sage-Grouse, Black Grouse, Ruffed Grouse, Prairie-Chicken	Bustardpox	Houbara Bustard, Great Bustard
Pigeonpox	Pigeon, Wood Pigeon, Chilean Pigeon, Collared Dove, Mourning Dove, Common Pheasant, Golden Pheasant	Murrepox	Murre = Guillemot
Turkeypox	Turkey, Ostrich, Humboldt Penguin	Shearwaterpox	Manx Shearwater
Canarypox	Canary and all the species that can be crossed with them	Shorebirdpox	Shore birds
Quailpox	Japanese Quail	Gullpox	Royal Tern
Juncopox	Dark-eyed Junco	Pelicanpox	No particular species given
Sparrowpox	House Sparrow	Penguinpox	Humbolt Penguin and related species
Starlingpox	Common Starling	Peacockpox	Indian Peafowl
Waterfowlpox	Mute Swan, Common Teal, Canada Goose, rarely other Anatiformes	Partridgepox	Common Partridge
Falconpox	Peregrine Falcon, Saker Falcon, Gyrfalcon, Golden Eagle, Red-tailed Hawk, Goshawk, Broad-winged Hawk	Colinusquailpox ³³¹	Bobwhite Quail, California Quail, Gambel's Quail
Agapornispox	Genus Agapornis	Guineafowlpox	No particular species given
Ostrichpox	Ostrich (probably related to turkeypox)	Swiftpox	Chimney Swift
Psittacinepox	South American parrots and parakeets	Woodpeckerpox	Common Flicker
Budgerigarpox	Budgerigar	Mynahpox ³³¹	Greater Hill Mynah
Rheapox	Greater Rhea	White-eyepox	Oriental White-eye, Silver-eye, Society Finch
Cranepox	Sandhill Crane	Creeperpox	Common Tree Creeper
		Song Sparrow Pox	Song Sparrow
		Field Sparrow Pox	Field Sparrow, Chipping Sparrow
		Thrushpox	Swainson's Thrush, Grey-cheeked Thrush, Wood Thrush
		Robin poxvirus	American Robin

TABLE 32.4 Cross-reactions of Poxviruses from Various Avian Species

	x axis									VACCINE
	Pigeonpox	Fowlpox	Turkeypox	Canarypox	Quailpox	Waterfowlpox	Falconpox	Agapornispox	Psittacinepox	
Pigeonpox	X	X								Homologous
Fowlpox		X	X		X	X	X			Homologous, heterologous (pigeonpox)
Turkeypox			X							Homologous, heterologous (fowlpox)
Canarypox				X						Homologous
Quailpox					X					Heterologous (fowlpox)
Waterfowlpox		X				X				Heterologous (fowlpox)
Falconpox	X	X	X				X			Heterologous (turkeypox)
Agapornispox								X		None
Psittacinepox									X	Homologous

Read as Pigeonpox (y axis) reacts with individual strain (x axis). Vaccines available are listed as homologous or heterologous.

color from yellowish to dark brown and develop into vesicles that open spontaneously, dry and form crusts (Figure 32.4). Spontaneous desquamation may require weeks and occurs without scarring in uncomplicated cases. Pigmented skin will frequently be discolored following an infection. Secondary bacterial or fungal colonization of lesions can substantially alter the appearance and progression of the disease.

In some cases, vesicles may not form and papules become hyperplastic, remaining in the periorbital region, nares, sinus infraorbitalis or on the tongue. These nodules may cause dyspnea (or asphyxia) or dysphagia depending on their location in the oral cavity. This progression is particularly common in the Bobwhite Quail, Canada Goose and Humboldt Penguin.²²⁸ Periorbital lesions may cause blepharitis, symblepharon, keratitis, uveitis and ultimately ophthalmophthisis. Blue-fronted Amazons and Indian Hill Mynahs frequently develop ocular lesions (Color 32.9).²⁰⁸ In domesticated male turkeys, papular infections may occur in the vent and pericloacal area without involving the cloacal mucosa or phallus. Infectivity levels may approach 75% of the flock. Virus transmission is suspected to occur during collection of semen for artificial insemination.¹⁷

- **Diphtheroid Form (“Wet Pox”):** Poxviral lesions that occur on the mucosa of the tongue, pharynx and larynx (rarely in the bronchi, esophagus and crop) cause fibrinous lesions that are grey to brown and caseous. Disturbing the exudates covering these lesions will induce severe bleeding. Multiple foci that coalesce may prevent a bird from swallowing food or result in dyspnea (or asphyxiation) if the larynx is involved. Oral lesions are frequently seen in Psittaciformes, Phasianiformes, Bobwhite Quail, some Columbiformes and Starlings.⁷¹

Cutaneous and diphtheroid lesions may occur in the same bird or either or both types of lesions may be noted in a flock outbreak. The septicemic form can also occur in conjunction with either cutaneous or diphtheritic forms of this disease.

- **Septicemic Form:** An acute onset of ruffled plumage, somnolence, cyanosis and anorexia characterize septicemic poxvirus infections. Most birds (mortality rates of 70-99%) die within three days of developing clinical signs. Cutaneous lesions are rare and antemortem documentation of infections is difficult. Septicemic infections are most common in canaries and canary and finch crosses. Canarypox frequently causes a desquamative pneumonia with occlusion of the air capillaries resulting in dyspnea. Clinical signs



FIG 32.4 The cutaneous form of poxvirus can cause mild to severe nodular lesions on the unfeathered areas of the face, feet and legs of companion and free-ranging birds of most orders.

can last for months, and death may occur by exhaustion. It has been suggested but not proven that the massive cellular proliferation of interstitial mesenchyme induced by the virus can cause neoplastic changes.¹⁶⁰ Postmortem lesions in affected canaries include small pneumonic foci and hemorrhages, as well as fatty liver degeneration and jejunitis.

- **Tumors:** Some Avipoxvirus strains have oncogenic properties. Passeriformes and Columbiformes that survive infections are prone to tumor formation. These rapidly growing, wart-like efflorescent tumors of the skin are generally void of normal epithelium and hemorrhage readily when disturbed. Bollinger bodies are usually present in the neoplastic tissue but viable virus may not be demonstrated. Surgical removal of the skin tumors is an effective therapy.

Specific Poxviral Symptoms

Psittacinepoxvirus infections have been documented in numerous South American parrots and parakeets. *Amazona* spp. and *Ara* spp. are most severely affected. Coryza and ocular lesions are frequently the dominating clinical signs in the genus *Amazona*; however, postmortem findings usually include diphtheroid enteritis or myocardial necrosis. Ocular lesions begin as dry areas on the eyelid that become crusty with exudate, sealing the lids closed. Secondary infections frequently cause keratitis, followed by ulceration, perforation of the globe, panophthalmia and finally ophthalmophthisis. When compared to other Psittaciformes, the unique clinical signs that occur in Amazon parrots are thought to be caused by virulence factors and not differences in virus strains.

Cutaneous lesions coupled with central nervous system signs (CNS) have been described in the Mourning Dove and falcons from the Persian Gulf. Cutaneous lesions in raptorial birds from most regions are relatively mild and self-limiting. In contrast, cutaneous lesions in Persian Gulf falcons were characterized by inflammatory necrotic processes that inhibited feeding. In some of these birds, CNS signs including somnolence, anorexia, opisthotonus, tonic-clonic cramps of the tail muscles and paresis and paralysis of the feet occurred. Histopathology revealed a distinct cribriform state, fresh hemorrhages in the white matter, mild inflammation of the meninges and no distinct inclusion bodies.²¹² Mild CNS signs caused by poxvirus have also been described in turkeys.

Poxvirus infections in lovebirds usually cause cutaneous lesions although diphtheroid lesions (“wet pox”) have also been described. Skin lesions rarely erupt, and the affected skin appears dehydrated and brownish in color. Ocular lesions characterized by serous conjunctivitis with heavy vascularization are common. The skin of the lower lid and of the facial angular palpebra may be yellow-brown with palpable induration. Serous exudate may become mucopurulent or fibrinous if secondary bacterial or fungal infections occur. Blepharosynechia caused by dried, crusty exudates can occur.²²³ Morbidity and mortality in lovebirds may reach 75% of the at-risk population.

A budgerigar poxvirus was isolated from “feather dusters;” however, experimental infections with the isolated virus caused only a mild dyspnea of three to four days duration with no skin or feather lesions.

Poxvirus infections in 10- to 60-day-old ostrich chicks are characterized by small vesicles containing yellowish fluid on the eyelids and face. Lesions become dry and form a scale within six to ten days of forming. Diphtheroid lesions may also occur on the larynx, oral mucosa and the base of the tongue.

Diagnosis

A definitive diagnosis of poxvirus can be made through the histologic demonstration of Bollinger bodies in biopsy samples of suspect lesions.

Culture is usually necessary to document the septicemic or coryzal forms of the disease. Cutaneous tumors are histologically characterized by a palisade-like arrangement of epithelial cords containing Bollinger bodies. Virus may be intermittently shed in the feces of asymptomatic carriers that may be identified by repeated culturing of feces. Serology is of little value in diagnosing poxvirus infections. Host recovery is primarily a function of cell-mediated immunity, and humoral antibodies are rarely and irregularly produced. If antibodies are present, they can be demonstrated by ID or VN.

Control

Birds that recover from pox should be protected from further disease for at least eight months, but many reports indicate shorter durations of immunity.²¹⁶ Cellular immunity is primarily responsible for recovery, and only small amounts of humoral antibodies are produced. Vaccination is the best method for controlling poxviral infections. Taxon-specific vaccines are available for only a few of the avian poxviruses (see Table 32.4 for the known cross immunities, which might be helpful for vaccination). Vaccines are commercially available for psittacine poxvirus, and should be considered to prevent infections in high-risk populations (imported birds, pet shop birds exposed to imported birds, areas with high densities of mosquitoes).⁴³¹ The manufacturer’s guidelines for vaccination should be carefully followed. Canaries (and crosses) should be immunized with an appropriate vaccine. Only healthy flocks of these birds should be vaccinated. The use of a vaccine in an actively infected flock of canaries and other birds may result in recombination between the field and vaccine virus strains, inducing a severe disease in the entire flock. A new or freshly sterilized needle must be used for each bird to prevent the vaccination procedure from spreading the virus. Canaries should be immune for three to six months following vaccination.

Cutaneous vaccination (wingweb, feather follicle) is normally used in gallinaceous birds. This method of vaccination causes the formation of a typical pox lesion at the site of inoculation. These lesions correlate with immunity, and vaccinated birds should be inspected nine or ten days following vaccination to be certain that lesions have formed. The statistical portion of a group of birds that must properly serocon-

CLINICAL APPLICATION

Differential Diagnosis for Pox

Cutaneous Form	Diphtheroid Form
▪ Trauma	▪ Trichomoniasis
▪ <i>Trichophyton</i> spp.	▪ Candidiasis
▪ <i>Knemidokoptes</i> spp.	▪ Aspergillosis
	▪ Pigeon herpesvirus
	▪ Hypovitaminosis A
	▪ Amazon tracheitis virus

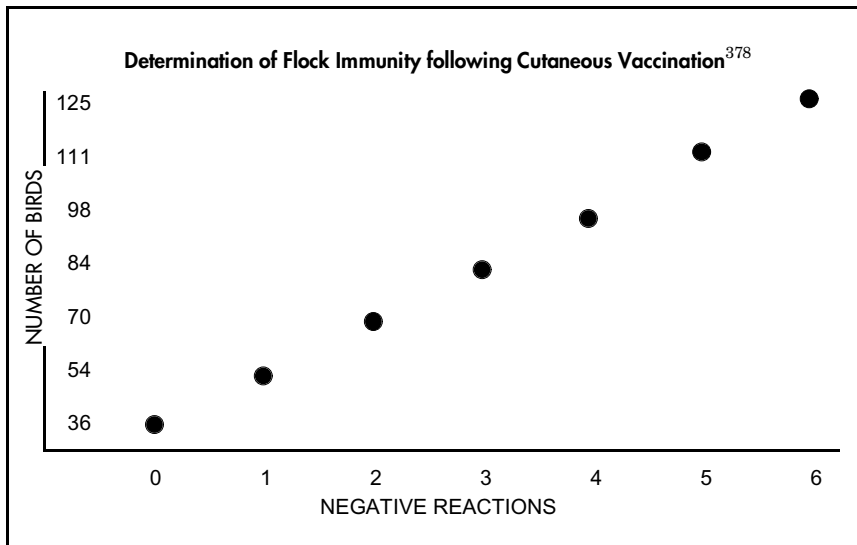


FIG 32.5 Chart for determining the number of successful poxvirus vaccination reactions necessary to ensure flock immunity.

vert in order to impart flock immunity is illustrated in Figure 32.5. For example, the statistical limits for full flock protection for 54 birds is 1.

Fowlpox vaccine has been found to provide protection for ostriches. Vaccination at 10-14 days old is recommended in areas with high densities of mosquitoes.

Herpesviridae

Herpesviridae are 120 and 220 nm diameter, double-stranded DNA viruses. Replication occurs in the nucleus. In some cells, an envelope may be obtained as the virus passes through the cytoplasmic membrane. Herpesvirus is not always restricted to a specific host or tissue. Crossing over a host- or tissue-specific barrier can alter the pathogenicity of the virus considerably. Herpesviruses primarily infect lymphatic tissue (either B- or T-cells), epithelial cells (skin, mucosa, hepatocytes) and nerve cells. Herpesviridae are considered a phylogenetic old group of viruses and as such are typically well adapted to their hosts. It should be expected that more avian herpesviridae strains will be isolated, adding further confusion to the already tangled classification system. As a group, herpesviruses generally induce latent and persistent infections (for weeks, months, years or lifetime) in an adapted host with irregular periods of recrudescence

and shedding. Latently infected birds can remain asymptomatic for years.

Concomitant disease, environmental stressors or hormonal changes have all been associated with induction of disease and activation of shedding. Reactivation does not always lead to clinical disease. Latently infected birds may shed virions via the feces, nasal discharge or desquamated skin (thereby endangering neighboring birds) without developing clinical signs. Virus can be transferred from cell to cell within an infected host with no invasion of the intracellular space, which protects the virus from humoral antibodies and antigen-processing cells. Because humoral antibodies decrease with time, indirect diagnosis of herpesvirus infections by detection of antibodies may give false-negative results. Herpesviruses generally produce Cowdry type A intranuclear inclusion bodies in target cells.

The Herpesviridae family is divided into three subfamilies:

- α -Herpesvirinae (hemorrhagic lesions)
- β -Herpesvirinae (necrotic lesions)
- γ -Herpesvirinae (lytic/neoplastic lesions)

Of the herpesvirus strains isolated from birds, only Marek's disease virus has been officially named. Table 32.5 shows the various herpesvirus taxons (it is questionable whether or not these have the status of a species), their respective subfamilies and the currently documented host spectrum. More detailed investigations may lead to further taxons, particularly with "Pacheco's disease-like" virus strains (the original Pacheco's disease virus has been lost). Table 32.6 shows the immunologic interactions.

Transmission

Transmission routes for avian herpesviruses in companion birds have not been thoroughly investigated. Vertical transmission has been confirmed only with budgerigar herpesvirus and duck plague herpesvirus. Epizootics result in high concentrations of virus being released to the environment. Budgerigars infected experimentally with Pacheco's disease virus shed virus with the feces for 48 hours post-infection. Birds in direct contact (same enclosure) and within

TABLE 32.5 Survey of Avian Herpesviridae

DISEASE	SUSCEPTIBLE SPECIES
Subfamily - α	
Infectious laryngotracheitis	Chickens, pheasants, peafowl, canaries
Amazon tracheitis	Genus Amazona, Bourke's parrot
Duck Plague (syn. Duck virus enteritis)	Ducks, geese, swans
Subfamily - β	
Pacheco's disease virus, "Pacheco's disease-like" virus	All Psittaciformes considered susceptible to varying degrees. At least three different serotypes. Host spectrum of two recent isolates is unknown.
Budgerigar herpesvirus	Budgerigar, pigeon, Double Yellow-headed Amazon
Pigeon inclusion body hepatitis (Esophagitis)	Pigeons, falcons, owls, budgerigar
Pigeon herpes encephalomyelitis	Pigeons
Falcon herpesvirus inclusion body hepatitis	Peregrine Falcon, Prairie Falcon, Common Kestrel, American Kestrel, Merlin, Red-necked Falcon Experimentally susceptible birds (see text)
Owl herpesvirus Hepatosplenitis infectiosa strigum	Eagle Owl, Great Horned Owl, Forest Eagle Owl, Snowy Owl, Striped Owl, Long-eared Owl, Little Owl, Tengmalm's Owl. Experimentally susceptible birds (see text)
Bald Eagle Herpesvirus	Bald Eagle
Lake Victoria Cormorant virus	Little Pied Cormorant
Crane inclusion body hepatitis	Demoiselle Crane, Crowned Crane, Whooping Crane, Sandhill Crane
Stork inclusion body hepatitis	Black Stork, White Stork
Colinus herpesvirus	Bobwhite Quail
Subfamily - not classified	
Marek's disease virus	Gallinaceous birds
Turkey herpesvirus	Gallinaceous birds
Canary herpesvirus	Canary
Gouldian Finch herpesvirus	Gouldian Finch
"Local" herpesvirus causing papilloma-like lesions on feet	Cockatoo, Macaw
Herpesvirus associated with papilloma	Conures

the same air space (adjacent enclosures) shed virus in the feces 48 hours later than the experimentally infected birds, suggesting an incubation period of 48 hours.

Fecal virus concentrations in clinically affected birds reached levels of up to 10^6 to 10^7 tissue culture infectious dose (TCID)₅₀/g of feces. Experimentally in-

fectured birds that remained asymptomatic shed virus in the feces for approximately three weeks. Virus concentration in the lungs was 10^6 TCID₅₀/g and in the liver was 10^7 TCID₅₀/g.⁴⁴⁵ These findings would suggest that the gastrointestinal tract (virus excreted from the liver) and the respiratory tract could be the primary points of entrance and release of the virus. Rapid spread through the aviary is common with virulent strains. The acute onset of clinical signs in several members of the flock may occur three to five days after the initial case is recognized.

Pathogenesis

Necrotizing lesions in the parenchymatous organs are characteristic of virulent herpesvirus infections. Hemorrhagic lesions may occur with some strains in various companion and aviary birds. Details on the pathogenicity of herpesvirus infections, particularly with respect to host and tissue specificity, are scarce.

Infectious Laryngotracheitis (ILT)

The herpesvirus responsible for ILT is distributed worldwide and appears to be serologically uniform. It is normally associated with acute disease of the respiratory tract, has a relatively small host spectrum and affects predominantly adult or growing birds older than eight weeks of age. Strain virulence varies widely from apathogenic to highly virulent. Several gallinaceous species (including peafowl and pheasants) have been found to be susceptible. The canary may also be susceptible to ILT as well as to its own herpesvirus strain (Kaleta EF, unpublished).^{87,227}

Unlike other herpesviridae, natural transmission is exclusively aerogenic. The virus has an affinity for respiratory epithelium, and viremia does not develop. Occasionally, the virus is recovered from the esophagus and intestine.

Clinical Disease, Pathology and Diagnosis

Virulent strains of ILT cause severe dyspnea, gasping and coughing-like sounds. During inspiration, loud wheezing sounds may occur with the neck extended and the head raised. Expectoration of bloody mucus is common, and infected birds shake their heads to expulse the mucus. In severe cases, bloody fibrin may be discharged. Affected birds become progressively weak and cyanotic and die from asphyxiation. Conjunctival and nasal discharge (mucoïd, purulent, rarely hemorrhagic), increased lacrimation and swelling of the sinus infraorbitalis frequently occur. These may be the only clinical signs associated with less virulent strains. A similar clinical picture has

TABLE 32.6 Cross-reactions of Herpesviruses from Various Avian Species

	x axis											VACCINE	
	Marek's disease virus	ILT	Turkeyherpes	Duck plague	Pigeonherpes	Falconherpes	Owlherpes	Pacheco's disease virus	Amazon tracheitis	Budgerigarherpes	Lake Victoria Cormorant	Craneherpes	
Marek's disease virus	X												Homologous
ILT		X											Heterologous (Turkeyherpes)
Turkeyherpes	X		X										Homologous
Duck plague				X									Homologous
Pigeonherpes					X	X	X						Homologous
Falconherpes					X	X	X						
Owlherpes					X	X	X						
Pacheco's disease virus								X					Homologous
Amazon tracheitis									X				
Budgerigarherpes										X			
Lake Victoria Cormorant											X		
Craneherpes												X	

Read as Marek's disease virus (y axis) reacts with individual strain (x axis). Vaccines available are listed as homologous or

been described in canaries. Primary ILT infections may be complicated by bacteria or fungi that colonize the necrotic respiratory epithelium.

Depending on the chronicity of the infection, post-mortem findings may include hemorrhagic or fibrinous inflammation of a thickened mucosa of the larynx, trachea and in some cases, the bronchi. Caseous plugs or fibrinonecrotic pseudomembranes may also be noted.

Early histopathology lesions show ballooning degeneration of the mucosal epithelium followed by desquamation and inflammatory infiltrates as disease progression occurs. Prior to the desquamation stage, typical intranuclear eosinophilic inclusion bodies (Seifried's bodies) may be found. Air capillaries occluded with detritus and pneumonia have been occasionally reported.¹⁵⁶

Immunodiffusion, VN, IF and ELISA can be used to identify isolates. In infected birds, precipitating antibodies can be demonstrated as early as eight to ten days post-infection. The occurrence of intranuclear inclusion bodies in the respiratory epithelial cell is

indicative, but confirmation of the disease requires virus isolation.

Control

Cell-adapted vaccines that have a considerable residual pathogenicity and may induce vaccinal reaction are available for chickens. Pheasants are considered to be more susceptible to ILT than chickens. Particular caution should be exercised in vaccinating pheasants with these products (this warning is not normally stated in the product insert).⁶⁷ Vaccine strains may induce life-long latency with reactivation following immunosuppression events.

Amazon Tracheitis (AT)

Chickens and the Common Pheasant are experimentally susceptible to the Amazon tracheitis virus. The disease that occurs in gallinaceous birds is mild in comparison to the clinical changes in Amazon parrots (see Color 22). The AT virus shares a serologic relationship with ILT and is considered a mutant of this virus. A herpesvirus pathologically similar to the ILT virus has been described in Bourke's Parrots; but no

comparisons between AT, ILT and this virus have been performed.^{169,245,433}

The serologic relationship of AT and ILT allows the assumption (partly verified by clinical experience) that AT primarily infects the respiratory epithelium. The virus spreads quickly through an affected flock. Experimentally, clinical signs evolve within three to four days, and peracute death occurs within six days post-infection in the Green-cheeked Amazon.

Clinical Disease, Pathology and Diagnosis

Varying species of Amazon parrots develop similar clinical disease following natural infection. Peracute, acute, subacute and chronic (up to nine months duration) infections have been described. Fibronecrotic ocular, nasal or oral discharges accompanied by open-beaked breathing, rales, rattles and coughing are common. As a rule, the disease in Bourke's Parrots takes a less florid course.

Postmortem findings include serous, mucoid or fibrinous to pseudomembranous rhinitis, pharyngitis, laryngitis and tracheitis. A hemorrhagic inflammation is also possible. Affected birds typically die from asphyxiation caused by blockage of the trachea with fibronecrotic debris. Bronchopneumonia, conjunctivitis, blepharitis, glossitis, ingluveitis and air sacculitis may occur as a result of secondary bacterial and fungal invaders that take advantage of an immunocompromised host.

Histopathologic lesions resemble those induced by ILT. Demonstration of intranuclear inclusion bodies is possible only early in the disease process prior to exfoliation of the affected mucosal epithelium. Pharyngeal or laryngeal swabs submitted for culture are suitable for confirming a diagnosis.

■ Duck Plague (DP — syn. Duck Virus Enteritis)

Duck plague virus seems to be distributed worldwide with the exception of Australia, and has been documented in free-ranging and captive Anatidae (ducks, geese and swans). DP is caused by a serologic uniform herpesvirus that does not cross-react with other avian Herpesviridae. The disease is characterized by damage to the endothelial lining of vessels resulting in tissue hemorrhage, gastrointestinal bleeding and free blood in body cavities.

Susceptibility varies considerably according to the host species and virulence of the virus strain. Mallards and to a lesser extent, the Common Teal and the Common Pintail, are relatively resistant; however,

they do produce antibodies post-exposure and are considered to be important reservoirs of the virus (particularly Mallards). Other Anatidae are considered relatively susceptible.⁴²⁷

Intermittent virus shedding in clinically healthy birds has been noted for up to five years. Outbreaks in zoological collections have been linked to free-ranging waterfowl that have access to exhibit ponds. Once infected, the captive birds can maintain the infection in the absence of an open body of water. Vertical transmission occurs, but does not seem to play an important epizootiologic role, perhaps because egg production is severely reduced in clinically affected flocks. Virus stability in water is temperature-dependent (4°C for approximately two months, 22°C for about one month).

Pathogenesis

The DP virus has an affinity for the reticuloendothelial system, propagates preferentially in undifferentiated epithelial cells and causes the destruction of B- and T-lymphocytes. Transovarially infected ducklings die during the first two weeks of life. Survivors are clinically healthy, partially immunotolerant and excrete large quantities of virus up to the sixth month of life. Although DP may occur clinically in only a single individual within a flock, it can also cause the death of 100% of the exposed birds. Climatic factors (heat, cold) are epizootiologically important. Birds (Mallards) with host-adapted strains serve as asymptomatic reservoirs and rarely develop clinical disease, but expose highly susceptible non-indigenous waterfowl to the virus.

Clinical Disease, Pathology and Diagnosis

Peracute death may occur without clinical signs. A more acute course is characterized by polydipsia, photophobia, nasal discharge, serous to hemorrhagic lacrimation, anorexia, cyanosis and greenish, watery (occasionally hemorrhagic) diarrhea. Mature birds generally have a more prolonged course of disease. Many birds swim in circles and are unable to fly. Paralysis of the phallus, convulsions or tremor of the neck and head muscles are occasionally noted. Affected free-ranging waterfowl may sit on the water with neck and head in extreme extension.

Postmortem lesions differ according to species susceptibility, degree of virus exposure and virulence of the infecting strain. Suggestive lesions include petechia and ecchymosis on the epicardium (see Color 14), serous membranes and the large blood vessels of the body; annular hemorrhagic bands on the mucosa

of the intestinal tract; necrosis in the cloacal wall and long parallel diphtheroid eruptions or confluent necrosis in the lower third of the esophagus. Nonspecific lesions include necrotic foci in the liver and hemorrhage of developing egg follicles.²³⁴

Histopathologic examination reveals eosinophilic intranuclear inclusion bodies (Cowdry A type) in hepatocytes, bile duct epithelial cells and the epithelial cells of the cloacal and esophageal mucosa. In the Muscovy Duck, erosions may be observed in the transition zone between the proventriculus and ventriculus. A definitive diagnosis requires virus isolation. VN is recommended for virus identification and to demonstrate antibodies in the host.

■ Pacheco's Disease Virus (PDV)

Pacheco's disease virus (PDV) has been described all over the world and is associated with a systemic, in many instances acute, disease that affects the liver, spleen and kidneys.

This disease was first described in parrots from Brazil.^{301,380} The affected birds died after eight days of somnolence and ruffled plumage.

Since its initial description, there have been numerous cases of a Pacheco's-like disease induced by a herpesvirus. Susceptibility to PDV seems to be restricted to the Psittaciformes. Naturally susceptible hosts include macaws, Amazon parrots, conures, African Grey Parrots, *Poicephalus* spp., lovebirds, lorries of the genus *Eos*, parakeets of the genus *Psittacula*, cockatoos, budgerigars, King Parrots and cockatiels. Patagonian and Nanday Conures are frequently discussed as asymptomatic carriers that intermittently shed virus; however, any bird that recovers from a PDV infection should be considered a carrier.

There are indications that inclusion body hepatitis in Psittaciformes (described and diagnosed as Pacheco's disease) is caused by several herpesviruses that are serologically distinct from the "original" virus.³⁸ Two serologically distinct herpesviruses (isolated from Blue-fronted Amazon Parrots, African Grey Parrots and a Moustache Parakeet) that induced lesions characteristic of Pacheco's disease have been described.²²⁵ Further investigations are necessary to clarify the relationship between these antigenically distinct strains and to determine the efficacy of currently available monovalent PDV vaccines.

Clinical Disease

PDV generally induces an acute, nonspecific disease characterized by somnolence, lethargy, anorexia, ruffled plumage and intermittent diarrhea, polyuria and polydipsia (Figure 32.6). Biliverdin staining of liquefied feces and urates is indicative of the severe liver necrosis caused by the virus (see Color 8). Sinusitis, hemorrhagic diarrhea, conjunctivitis and convulsions or tremors in the neck, wings and legs have occasionally been described. Many outbreaks are linked to a stressful event such as a change in the environment or the onset of breeding season. Stress factors are thought to induce recrudescence in asymptomatic carriers resulting in virus excretion and an epornitic in exposed birds. In other cases, only a single bird may suddenly die while the rest of the flock remains unaffected. The intensity and course of the clinical disease varies widely according to species susceptibility. Some macaws and *Amazona* spp. are considered highly susceptible, while others in the same group appear to be relatively resistant. Old World Psittaciformes appear to be more resistant to PDV than do New World Psittaciformes.

Pathology and Diagnosis

With peracute or acute disease, birds are in generally good condition at the time of death. A massively swollen, tawny, light-red or greenish-colored liver with subserosal hemorrhages or necrotic foci is common (see Color 20). The spleen and kidneys are also distinctly swollen, and the intestinal mucosa may be hyperemic (Figure 32.7). Histologic lesions include congestion, hemorrhage and coagulative necrosis of the hepatocytes. The term "inclusion body hepatitis" is often misleading, because birds frequently die from massive liver necrosis before an inflammatory reaction occurs. Intranuclear eosinophilic inclusion bodies may be noted in hepatocytes (particularly around necrotic foci), bile duct and renal tubular epithelial cells and in splenic reticular cells. Virus identification is possible by VN, ELISA and IF. Precipitation with the ID is useful as a screening test. The use of monoclonal antibodies allows differentiation between the various PDV serotypes. Antibodies to PDV are difficult to demonstrate and provide no clinically relevant information.

Treatment

Natural immunity can be induced with paramunity inducers. Acyclovir has been shown to be effective for treating at least some strains of PDV. The recommended treatment regimen is to administer the water-soluble powder at a dose of 80 mg/kg TID by



FIG 32.6 The clinical course of Pacheco's disease virus (PDV) depends on the host species. Some birds die peracutely with no clinical signs of disease, while others die following a brief period of depression, ruffled plumage, diarrhea and polyuria. Other species may survive an infection and become asymptomatic carriers. This infected bird died shortly after presentation.

gavage tube. Severe muscle necrosis will occur if the intravenous product is injected IM. If gavage administration is not practical, the powdered acyclovir can be added to the food at a dose as high as 240 mg/kg.²⁹⁴ Treatment is most effective if started before clinical signs develop. Acyclovir may cause considerable nephrotoxicity, and this drug should be administered carefully in patients with nephropathies. The role that acyclovir may play in inducing asymptomatic carriers has not been determined.

Control

An inactivated PDV vaccine is commercially available in the USA. There have been frequent reports of granulomas and paralysis following the use of this vaccine, particularly in cockatoos (Figure 32.8), African Grey Parrots and Blue and Gold Macaws.^{24,103,159,261,323,373} The vaccine is intended for use in high risk patients (import stations, pet shops that handle imported birds). The instructions for use provided by the manufacturer should be carefully followed.

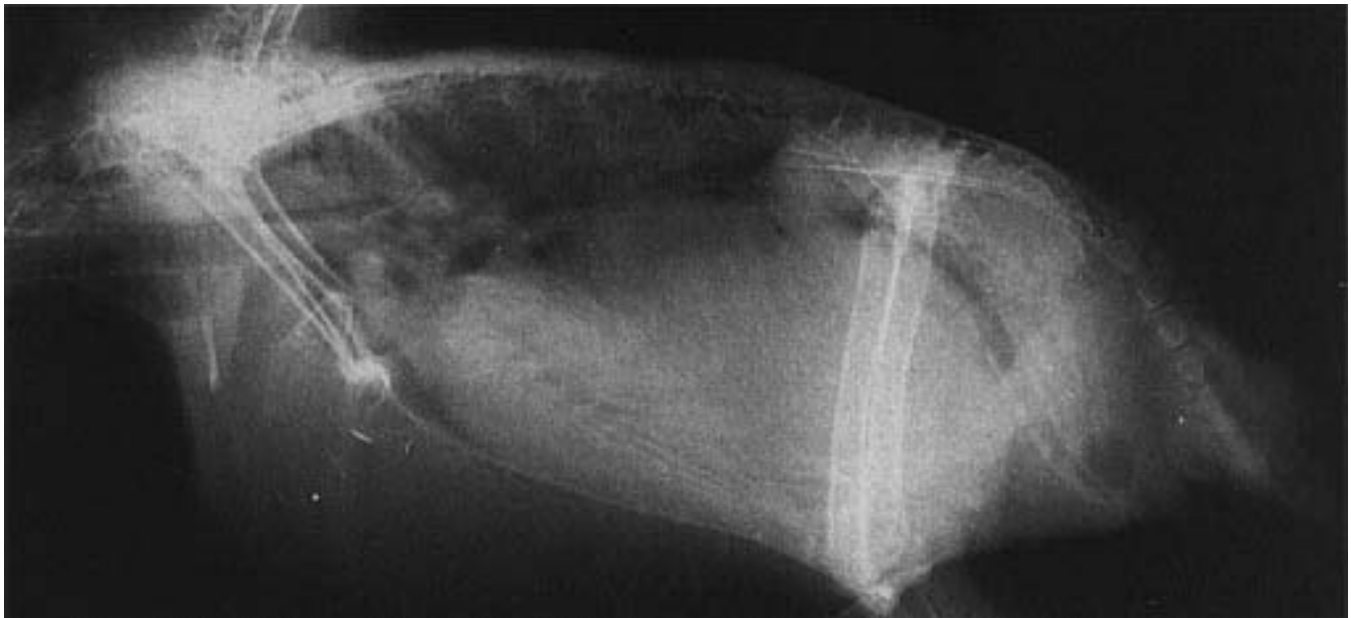


FIG 32.7 A young, recently imported female Blue and Gold Macaw was presented for anorexia, yellow discoloration of the stool and ruffled plumage. A doughy mass was palpable in the caudal abdomen. Abnormal clinical pathology findings included WBC=4000, AST=1200, LDH=980. Radiographs indicated an enlarged liver that occupied much of the abdomen and displaced the proventriculus dorsally and caused the caudal border of the heart to appear indistinct. The bird died shortly after presentation. At necropsy, the liver was enlarged (three to four times normal), mottled, red and had numerous subserosal hemorrhages. Histopathology confirmed the presence of hepatocellular necrosis and intranuclear inclusion bodies suggestive of Pacheco's disease virus.

■ Budgerigar Herpesvirus

A vertically transmitted herpesvirus has been isolated from the feathers of budgerigars. The virus is occasionally recoverable from parenchymatous organs, blood or feces. Decreased egg hatchability is the principal problem associated with this virus, which is serologically related to the pigeon herpesvirus, but not to Pacheco's disease virus or related strains.

Most isolates of this virus have been from so-called "feather dusters." It is unknown what role, if any, herpesvirus plays in this genetic problem of English Show Budgerigars.

A herpes-like virus was reported in a Yellow-crowned Amazon that died acutely following exposure to budgerigars. At necropsy, the thickened crop mucosa showed parakeratotic lesions with basophilic intranuclear inclusion bodies in the epithelial cells. Cells of the exogenic pancreas revealed degeneration accompanied by the formation of syncytial cells. The peripancreatic fat was necrotic. In addition, chronic hepatitis and proliferation of reticular cells in the spleen were noted. Intranuclear virus particles were present in the crop and pancreas, and enveloped virions with spiked outer membranes (unlike Pacheco's disease virus or ILT virus) were present in the cytoplasm.²⁴⁵

Virus isolated in cell culture can be identified using antibodies in the VN or ID tests. In infected flocks of English Standards, breeding should be interrupted to allow hens to develop immunity, which should provide some protection for the chicks.

■ Inclusion Body Hepatitis in Pigeons (Infectious Esophagitis)

This herpesvirus has a worldwide distribution, and various strains show morphologic, pathogenic and serologic differences (plaque formation in CEF). Small plaque variants are less pathogenic or apathogenic.²⁰⁷ The large and small plaque-forming viruses may be two different strains.²⁰⁶ This virus is serologically related to the falcon and owl herpesviruses. The host spectrum of this virus is uncertain, but pigeons and budgerigars are known to be susceptible.⁴¹⁷ Falcons and owls might also be susceptible and could be infected through contact with diseased pigeons. The susceptibility of falcons and owls varies with the species.

Squabs 4 to 16 weeks of age are most susceptible, but any age bird can be infected, particularly if immuno-

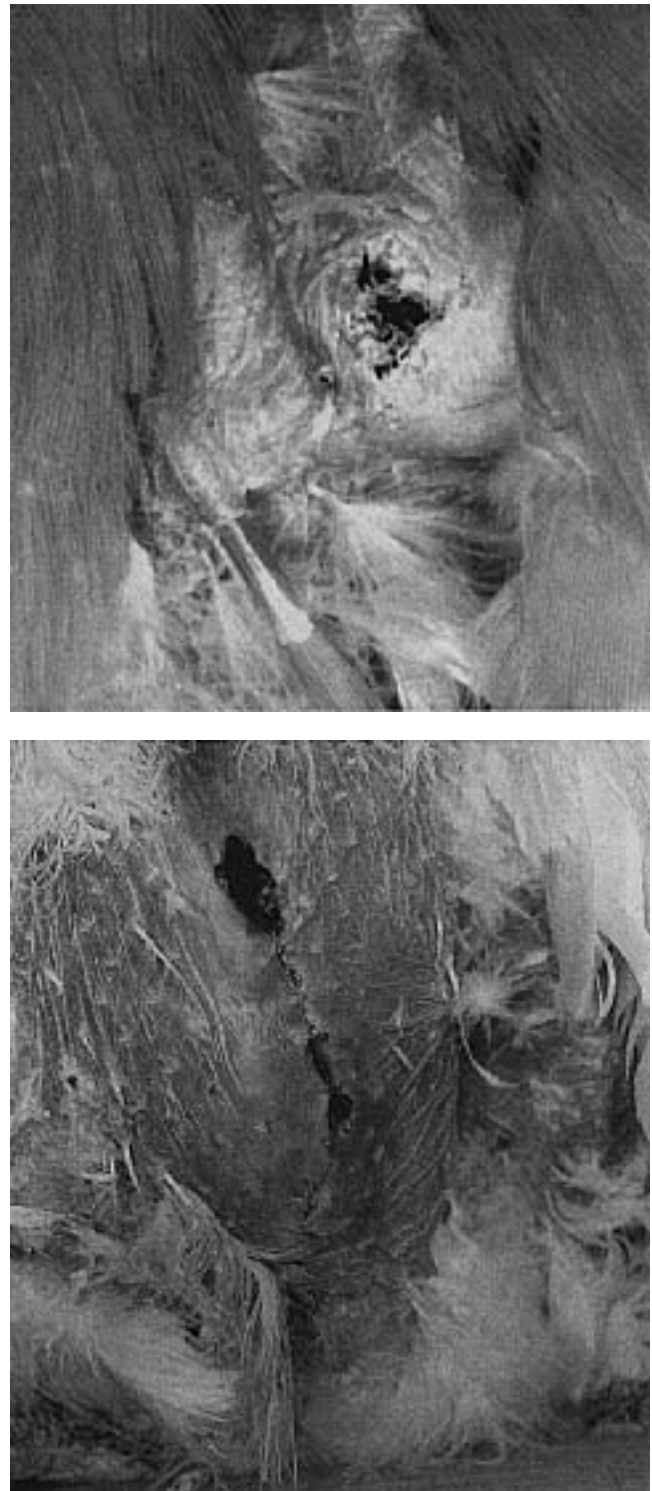


FIG 32.8 Some species of birds (particularly cockatoos) have been found to develop severe granulomas following vaccination with the killed oil-emulsion Pacheco's disease virus vaccine. Birds vaccinated subcutaneously with the oil-emulsion portion of this vaccine were found to develop granulomas suggesting that it is the vaccine adjuvant and not the viral protein that is inducing an unacceptable reaction. Occasionally, birds injected IM (bottom) with the Pacheco's disease virus vaccine can develop severe granulomas and muscle necrosis that require surgical debridement.

suppressed. Annual outbreaks have been described in some flocks. Transmission can occur through contact with contaminated feed or water, through direct contact between mates and through parenteral feeding of offspring.

Clinical Disease, Pathology and Diagnosis

In the flock, morbidity is typically 50%, with a 10 to 15% mortality rate. Serous rhinitis and conjunctivitis are usually the first clinical signs of disease. The nares become occluded, and a grayish-mucoid exudate causes dyspnea. Paresis of the third eyelid is possible. Small diphtheroid foci on the pharynx and larynx (which develop into so-called sialoliths) are indicative of an active infection.⁴⁵⁰ Mild diarrhea, anorexia, vomiting and polydipsia may also occur. Affected squabs may die within one to two weeks or slowly recover. Tremors, ataxia and an inability to fly may occur in some birds.⁴¹⁸ Recurring trichomoniasis is common in flocks with endemic herpesvirus.

Small, grayish-greenish diphtheroid foci on the mucosa of the upper airways, pharynx and occasionally the crop and intestine are characteristic necropsy findings. Air sacculitis, peritonitis, necrotic hepatitis and occasionally necrosis in the kidney, pancreas and spleen are observed. This virus may also induce only necrotic hepatitis.

Histopathology reveals necrosis (liver, kidney, pancreas, spleen) and desquamative lesions of epithelial cells (pharynx, larynx, esophagus). Cells around these lesions contain intranuclear eosinophilic and basophilic inclusion bodies.

The formation of sialoliths is suggestive of an infection, as are high morbidity rates in offspring. The virus may be identified by ID, but strain differentiation requires VN, ELISA or electrophoresis.

Contagious Paralysis of Pigeons (PHEV - Pigeon Herpes Encephalomyelitis Virus)

Pigeon herpes encephalomyelitis virus was first described in Iraq.²⁷⁷ The distribution of the virus is undetermined. Paramyxovirus-1-pigeon was also present in the initial isolate, and it is uncertain which of the central nervous system signs described were caused by herpesvirus and which were caused by paramyxovirus. Some of the reported neurologic lesions were atypical for those described with paramyxovirus-1-pigeon.^{196,333} In Germany, two strains of herpesvirus have been isolated from the brains of pigeons suffering from neurologic disease (Schnee-ganss D, unpublished).

Clinical Disease, Pathology and Diagnosis

Affected birds develop progressive, chronic central nervous signs that start with incoordination and end with an inability to fly and paralysis. Circling and torticollis, which were described in the initial report of the virus²¹⁷ have not been observed by other investigators (Schneeganss D, unpublished).

Gross necropsy findings are similar to those described with paramyxovirus-1-pigeon. The meningo-encephalitis that is common with paramyxovirus has not been described with PHEV. The Purkinje cells of the cerebellum showed degeneration, lysis and eosinophilic intranuclear inclusion bodies. Paramyxovirus-1-pigeon, salmonellosis and listeriosis are the main rule-outs. A study to describe the pathohistology of PHEV is necessary.

CLINICAL APPLICATION

Differential Diagnosis for Avian Herpesviruses

Infectious Laryngotracheitis

- Infectious coryza (*Haemophilus paragallinarium*)
- Mycoplasmosis
- Poxvirus (diphtheroid form)
- *Syngamus* spp.

Amazon Tracheitis

- Most respiratory diseases
- Avianpox (diphtheroid form)
- Newcastle disease
- Chlamydiosis
- Influenza A virus
- Candida
- Aspergillosis
- Trichomoniasis
- *Syngamus* spp.
- Hypovitaminosis A

Pacheco's Disease Virus

- Bacterial hepatitis
- Chlamydiosis
- Lead toxicosis
- Salmonellosis
- Paramyxovirus

Inclusion Body Hepatitis of Cranes

- Visceral coccidiosis

Duck Plague Virus

- Macroscopic lesions characteristic
- Influenza virus
- Duck hepatitis virus (ducklings)

Pigeon Herpesvirus

- Poxvirus (diphtheroid form)
- Trichomoniasis
- Chlamydiosis (respiratory form)
- Salmonellosis (liver form)

Pigeon Infectious Paralysis

- Paramyxovirus-1-pigeon
- CNS form of salmonellosis
- Listeriosis

Falcon Inclusion Body Hepatitis

- Many other infectious and non-infectious liver lesions

Hepatosplenitis Infectiosa Strigum

- Mycobacteriosis
- Trichomoniasis
- Candidiasis

Inclusion Body Hepatitis of the Falcon (FHV - Falcon Herpesvirus)

Falcon herpesvirus seems to be distributed in the northern hemisphere of the Old and New Worlds. The host spectrum is not fully known. There is a close antigenic relationship between FHV and the pigeon and owl herpesviruses. These three viral taxons show a certain independence, particularly with respect to host spectrum and clinical signs (see Table 32.5). Field cases of falcon herpesvirus have been described in the Peregrine Falcon, Common Kestrel, Merlin, Red-necked Falcon, Prairie Falcon and American Kestrel. Experimentally, the African Collared Dove, immature budgerigar, Striated Heron, Lone-eared Owl, Screech Owl, Great Horned Owl and Muscovy Duck have been shown to be susceptible.²⁵⁴

The falcon herpesvirus has an affinity for reticuloendothelial cells and hepatocytes. There is no confirmed information on the natural transmission of this virus. It has been suggested that the consumption of infected prey may be involved in transmission. There is no evidence that inhalation of the virus is involved in natural transmission.¹³¹

Clinical Disease, Pathology and Diagnosis

Generally, an acute disease develops with mild to severe depression, weakness and anorexia. Mortality may approach 100%.¹³¹ At necropsy, light-to-tan colored necrotic foci are seen in the liver, spleen, bone marrow and lymph follicles of the intestine.

Histopathology shows focal or disseminated degeneration and necrosis in the liver, pancreas, lung, kidney and brain. The adrenal, thyroid and parathyroid glands, as well as the ovary, testes and thymus may also be affected. Necrotic foci may be surrounded by parenchymatous cells containing intranuclear (mainly eosinophilic) inclusion bodies. Inflammatory cellular reactions are rare due to the acute nature of the disease and the rapid death of the host.

The clinical signs and gross findings of falcon herpesvirus are nonspecific. Because of the close serologic relationship between pigeon herpesvirus and owl herpesvirus, serologic identification is not possible. Separation of specific proteins using SDS-gel-electrophoresis can be used to differentiate between strains.

Hepatosplenitis Infectiosa Strigum (OHV - Owl Herpesvirus)

Owl herpesvirus has a limited host spectrum and occurs in free-ranging and captive owls.¹³⁸ The virus

is distributed across Europe, Asia and the United States. Natural infections are mainly seen in owls with yellow- or orange-colored irises including: Eagle Owl, Great Horned Owl, Striped Owl, Long-eared Owl, Snowy Owl, Little Owl, Tengmalm's Owl and Forest Eagle Owl.

Antibodies against OHV have been demonstrated in 24 species of Strigiformes.²⁰⁵ The American Kestrel, Common Kestrel, Turtle Dove and African Collared Dove can be infected experimentally. Because OHV is serologically related to the pigeon herpesvirus and the falcon herpesvirus, the currently recognized host spectrum may be incomplete.

In contrast to other avian Herpesviridae, OHV affects both epithelial and mesenchymal cells. Virus is excreted from the oral cavity and in urine.³⁷¹ Consumption of infected prey should be considered a potential method of transmission. Infection does not take place via the tracheal mucosa. Owl herpesvirus antigen has been demonstrated within the epithelium of feather follicles. Compared with other avian Herpesviridae, the incubation period for OHV is prolonged (seven to ten days) rather than the more typical three to five days.

Clinical Disease and Pathology

Clinical signs including depression, anorexia and weakness may last for two to five days. Infrequently, yellowish nodules the size of millet seeds may develop on the pharyngeal mucosa.⁴⁹ These lesions may be secondarily infected with *Trichomonas* spp. In captivity, mortality rates may approach 100%. The demonstration of antibodies in free-ranging owls indicates that birds can survive infections. Leukopenia has been described during active infections.

The necropsy reveals numerous necrotic foci in the liver, spleen and bone marrow.⁴⁹ Other suggestive lesions include diphtheroid (frequent) and hemorrhagic (rare) enteritis, diphtheroid stomatitis, esophagitis, proventriculitis and laryngitis (less frequent) as well as single necrotic foci in the lungs and kidneys. Moniliform necrotic nodules may be found along the jugular vein, probably emanating from the remains of thymic tissue.

Necrotic foci in various organs are characterized by a basophilic center with a zone of nuclear debris surrounded by eosinophilic necrotic material. Intranuclear eosinophilic inclusion bodies can be found adjacent to these necrotic areas. Inclusion bodies are rare in natural infections. Amyloidosis has been described in chronic cases.

Diagnosis

The necrotic foci in the liver, spleen, intestine and along the jugular vein should be differentiated from those caused by mycobacteriosis. Although the morphology is strikingly similar, the foci caused by herpesvirus are soft and are not demarcated from the surrounding tissue. In comparison, mycobacteria-induced tubercles are caseous, crumbly and normally well demarcated. Trichomoniasis-induced diphtheroid pharyngitis appears similar to that caused by herpesvirus. Additionally, *Trichomonas* spp. and fungi can be secondary invaders of pharyngeal lesions induced by herpesvirus.

Apparently, owl herpesvirus cannot be transmitted free of cells.³⁶¹ This finding would suggest that OHV is a separate taxon from PHV and FHV. It also implies that tissues submitted for virus isolation must contain intact cells (shipped at 4°C as quickly as possible). The bone marrow of the femur is the best tissue to submit for virus isolation.³⁷¹ Differentiation of OHV, FHV and PHV requires electrophoresis to delineate strain-specific proteins.

Eagle Herpesvirus

A herpesvirus was isolated from a clinically healthy, free-ranging Bald Eagle nestling.⁷⁶ The strain is not related to DPV, herpes simplex, FHV or crane herpesvirus. Eagle herpesvirus was also recovered from a South American eagle (probably a Grey Eagle-Buzzard) that developed lesions similar to those described in owls and falcons.²⁰⁶

Lake Victoria Cormorant Herpesvirus

A herpesvirus has been isolated from the blood of a clinically healthy Little Pied Cormorant nestling. This virus was not serologically related to other avian Herpesviridae.¹⁰² Attempts to recover this virus from other Australian birds in the same area were unsuccessful, and it has been suggested that this herpesvirus has a very narrow host range. Chickens, pigeons and budgerigars experimentally infected with the virus did not develop pathologic lesions.

Inclusion Body Disease of Cranes (Crane Herpesvirus)

Crane herpesvirus is probably distributed worldwide (except Australia). There is evidence that infections can be latent and persist for years. To date, disease has been described only in captive birds. Birds maintained by the International Crane Foundation were

found to have antibodies to the virus three years before a disease outbreak occurred.⁷⁷ Morbidity and mortality were described only in some parts of the premises, and serologic data indicated that susceptibility varied among crane species. The natural host spectrum includes Sandhill, Manchurian, Blue, Hooded, Demoiselle and Crowned Cranes. The Sandhill and Blue Cranes seem to be most susceptible, followed by the Manchurian and Hooded Cranes. The Sarus and Common Cranes seroconverted following infection without developing signs of disease. White-naped Cranes, Demoiselle Cranes and Brolga survived exposure but generally did not seroconvert.⁷⁶

The crane herpesvirus is considered to be a β -herpesvirus with a relatively narrow host spectrum and cytopathology characterized by slowly progressive, lytic lesions within enlarged infected cells and Cowdry type A intranuclear inclusion bodies.³⁴⁷ Serologically, the crane herpesvirus is closely related to or identical to the Bobwhite Quail herpesvirus.⁹⁷

Clinical Disease and Pathology

Clinical disease is usually acute, with birds seeking solitude and developing depression, anorexia and diarrhea. At necropsy, the liver, spleen and kidneys are swollen with miliary necrotic foci. Diphtheroid layers develop on the mucosa of the oral cavity, choanal slit and esophagus. Striated hemorrhages can be observed in the upper part of the esophagus. The mucosa of the duodenum, jejunum and colon may be covered with a layer of diphtheroid material. Histopathology reveals necrotic foci, which react basophilic or eosinophilic with hematoxylin and eosin (H & E) stain. Intranuclear eosinophilic inclusion bodies are rare.

Visceral coccidiosis may also cause swelling of various parenchymatous organs in cranes. Giemsa staining can be used to delineate merozoites in infected hosts.

Inclusion Body Hepatitis of Bobwhite Quail (*Colinus Herpesvirus*)

A herpesvirus was initially isolated from Bobwhite Quail.²⁰⁰ Nothing is known about the distribution of the virus, but because the Bobwhite Quail is a New World species, the virus would be expected to occur in the United States and Canada. The virus is serologically related to the crane herpesvirus.

Clinical Disease and Pathology

Clinical signs are nonspecific and include ruffled plumage, diarrhea and anorexia. The disease takes an acute course, and death occurs within two to three days of developing clinical signs. None of the birds affected by this virus have been over four weeks old. Gross lesions include hepatomegaly and splenomegaly, both of which contain numerous small yellowish foci. Catarrhal enteritis and ulcers were evident in the jejunum, and a *Clostridium* sp. was isolated from birds with intestinal lesions. Histopathology revealed multiple necrotic hepatic foci with rod-like bacteria at the center, as well as perivascular lymphocytic infiltrates. Lesions described in quail vary from those caused by other members of the avian Herpesviridae. It is thus questionable whether or not infection with a *Clostridium* sp. has caused most of the tissue changes and activation of a latent herpesvirus infection. Conversely, the herpesvirus infection could have triggered the *Clostridium* sp. infection.

Inclusion Body Hepatitis of Storks (Stork Herpesvirus)

A pathogenic herpesvirus that affects White and Black Storks has been described.^{198,201} Infections have been described only in Germany, but the virus should be expected to occur in Europe, populated regions of Asia and the African winter quarters. The host spectrum is thought to be restricted, but investigations are incomplete.

The virus is serologically unrelated to other avian Herpesviridae, is cell-associated and can be demonstrated in leukocytes in the presence of humoral antibodies. Cell-free virus can be demonstrated as well. All attempts to recover virus from the feather follicles of White and Black Storks have failed. In addition, attempts to isolate virus from the pharyngeal and cloacal mucosa of viremic storks were not successful (Kaleta EF, unpublished). Studies involving humoral antibodies have indicated that titers vary from negative to positive, year to year and among individuals.

Clinical signs are limited to sudden death. Pathologic lesions consist of small yellowish-white foci in the liver, spleen and bone marrow. There may also be diphtheroid changes in the mucosa of the esophagus, choana and larynx.

Marek's Disease Virus (MDV)

This agent, officially named the thalymphokryptovirus, is distributed worldwide and is the best known avian herpesvirus because of its importance to the poultry industry and its use in comparative oncology research. Marek's disease virus has been shown to have direct and indirect routes of transmission.^{53,176,312} Marek's disease is characterized by lymphocytic proliferation in the peripheral nerves that results in varying degrees of paresis and paralysis. The disease is common in gallinaceous species, and suggestive lesions have been reported in Great Horned Owls, ducks, a kestrel and swans. Tumors associated with MDV may occur in any organ but are commonly found in the viscera, skin, eyes, muscle and bones. Enlarged peripheral nerves are a common postmortem finding.

In a Great Horned Owl, lesions suggestive of MDV were associated with paralysis, ataxia, emaciation and formation of enlarged gray-white masses in the splenic, renal, pancreatic and mesenteric tissues. The ischiatic nerves were two to three times normal size. Lymphoblastic cells could be identified in the liver, kidney, pancreas, mesentery, spleen and sciatic nerves.^{154a}

Marek's disease virus antigen was demonstrated by an agarose gel diffusion test in the spinal cord and pudendal nerves in a toucan that exhibited a chronic slowly progressive peripheral ataxia with kidney enlargement. The histologic lesions that occurred in this bird were consistent with Marek's disease virus, but a virus could not be isolated (Latimer KS, unpublished).

Gouldian Finch Herpesvirus

An uncharacterized virus suggestive of herpesvirus has been identified by electron microscopy in clinically affected Crimson Finches, Red-faced Waxbills and Zebra Finches.⁷⁴ In a mixed species aviary, Gouldian Finches died from lesions caused by a herpesvirus, while other Passeriformes in the collection remained unaffected. Mortality in Gouldian Finch flocks may reach 70% of the birds at risk.^{353,369}

Clinical Disease and Pathology

Listless birds with ruffled plumage develop increasingly severe dyspnea with minimal discharge from the nostrils. Swollen and edematous eyelids and conjunctivae may be sealed with crusts in the lid cleft. Despite severe dyspnea, affected birds may continue

to try to eat, although sometimes unsuccessfully. Death is common five to ten days following the first clinical signs and all Gouldian Finches from one aviary died over a period of two weeks.⁷⁴

Necropsy findings included severe emaciation even though some affected birds continued to eat. Swollen eyelids and conjunctivae, serous discharge in the conjunctival sacs and fibrinoid thickening of the air sacs were the only characteristic findings. Apart from congestion, parenchymal organs appeared normal.

In one outbreak, hyperemic foci and fibrinous deposits were visible on the serosa of the jejunum, the lumen of which was filled with melena-like contents in one bird. The oviduct contained a yellowish fluid with desquamated epithelial cells.⁷⁴

Histopathology is characterized by ballooning degeneration and detachment from the basal membrane of conjunctival and respiratory epithelial cells. The epithelium may be thickened by increased numbers of the ballooning cells. Large, homogeneous, either basophilic or eosinophilic intranuclear inclusion bodies are characteristic. The submucosa may be congested and contain massive diffuse perivascular infiltration with mononuclear cells and few heterophils. The lower respiratory tract and the trachea may have similar but less severe lesions. Cilia may be damaged in affected tracheal mucosa. Hepatocytes are rarely affected.⁷⁴

Other Herpesviruses

A herpesvirus has been described in lovebirds with malformed feathers, but the involvement of this virus in causing the lesions has not been determined.¹³⁷

Papilloma-like lesions thought to be caused by a herpesvirus have been described on the feet of cockatoos (Figure 32.9). Affected birds are usually clinically normal except for the wart-like growths on their feet. Histopathology is consistent with squamous papillomas. The nuclei of affected epithelial cells are homogeneously basophilic with a smudged appearance, and the superficial cells are vacuolated. Electron microscopy has been used to demonstrate virus particles suggestive of herpesvirus. A herpes-like virus was observed by electron microscopy in association with a cloacal papilloma in an Orange-fronted Conure.¹¹⁸ Squamous papillomas are common with poxvirus and papillomavirus but rather unusual for herpesvirus infections.




FIG 32.9 An adult Moluccan Cockatoo was presented for evaluation of progressive feather dysplasia. The bird was positive for PBFV virus by feather biopsy (intranuclear and intracytoplasmic inclusion bodies) and by DNA probe (whole blood). The bird also had proliferative (wart-like) growths on several digits. Electron microscopy revealed virus particles suggestive of herpesvirus.

Papovaviridae

The Papovaviridae family of viruses consists of two genera, which vary in virion size, genome size and organization. These two genera are *Papillomavirus*, which is characterized by a 55 nm diameter nonenveloped icosahedral virion with a 7.5-8 kbp circular double strand DNA genome, and *Polyomavirus*, characterized by a 40-50 nm icosahedral nonenveloped virion with a 4.8-5.5 kbp circular double strand DNA genome.⁹³

As a group, the papovaviruses tend to cause persistent infections that become active following stressful events.⁴²⁸ Papillomaviruses are generally associated with the formation of benign skin tumors (warts).^{190,298} The first acute, generalized infection associated with a polyomavirus was described in young psittacine birds and was called budgerigar fledgling disease (BFD).^{38,39,44} A similar virus has been shown to be associated with high levels of morbidity and mortality in finches (Estrildidae) and in a number of different genera of Psittaciformes. The acute nature of avian polyomavirus infections is most unusual for Papovaviridae, the members of which are classically associated with nonpathogenic subclinical infections and chronic diseases characterized by tumor formation.⁴²⁸

Papillomavirus

Papillomavirus has been associated with the formation of benign epithelial tumors (papillomata) on the skin and epithelial mucosa of many mammalian species. The papillomaviruses that infect mammals appear to be species-specific.

Papillomavirus has been associated with proliferative growths on the unfeathered skin of some birds. In addition, clinical and pathologic lesions suggestive of those caused by papillomavirus have been described at various locations along the gastrointestinal tract, particularly in the cloaca (see Color 19). To date, no virus has been associated with these papilloma-like growths in the gastrointestinal tract of Psittaciformes.

Clinical Features

The first demonstration of a papovavirus in a non-mammalian species involved the recovery and characterization of a papillomavirus from proliferative skin masses found on the legs of finches in the family Fringillidae. Virus recovered from these birds was found to be antigenically similar to some types of papillomaviruses documented in humans. Papillomavirus was found to be common in finches, causing proliferative lesions on 330 of 25,000 Chaffinches examined. In contrast, the virus appears to be rare in other avian species.^{240,298} Lesions clinically appear as slow-growing, dry, sappy, wart-like epithelial proliferations on the skin of the feet and legs. Severe proliferations can result in the loss of digits or the foot. Histologic changes are typical for papillomas.

A papillomavirus was demonstrated in a Timneh African Grey Parrot with proliferative skin lesions on the head and palpebrae. Histologic evaluation of biopsies from this bird indicated long, thin folds of hyperplastic epidermis, which were moderately acanthotic and parakeratotic. Papillomavirus particles were demonstrated by electron microscopy and by staining with viral-specific antibodies within retained nuclei in the stratum corneum.¹⁹⁰

Papillomatous lesions have been diagnosed histologically from proliferative growths originating from skin overlying the phalanges, uropygial gland, mandible, neck, wing, eyelids and beak commissure from various Psittaciformes including Amazon parrots, African Grey Parrots, Quaker Parakeets, cockatiels and budgerigars (Figure 32.10). While a viral etiology has been assumed for these epidermal proliferations, virus has not been demonstrated in association with any of these lesions.^{318,412}

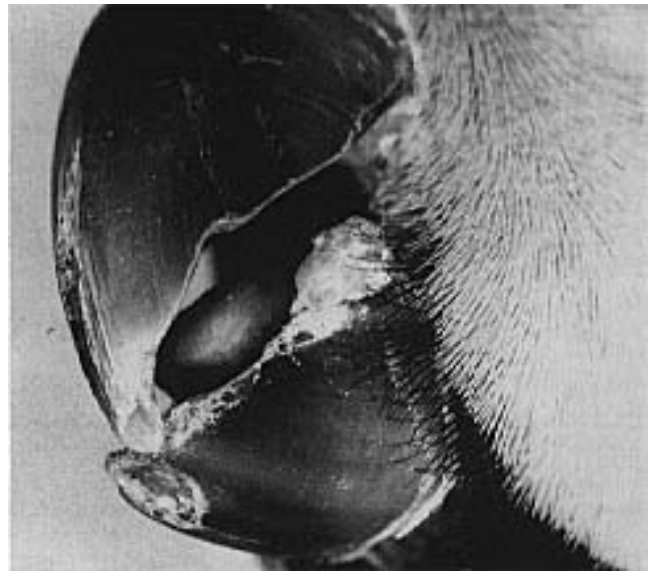

FIG 32.10 A papilloma-like growth at the commissure of the beak in an Alexandrian Parakeet hen. The bird was on a marginal diet and had numerous rhamphothecal and gnathecal defects. The growth was surgically removed. Histopathology indicated long, thin folds of hyperplastic epidermis with acanthosis. This lesion was considered suggestive of a papilloma; however, virus could not be identified histologically.

Histologic lesions suggestive of papillomas have been described at numerous locations along the avian gastrointestinal tract. These papillomatous lesions most frequently occur at the transition between mucosa and cutaneous epithelium in the cloaca. In one study involving 19 species of New World parrots, papillomatous lesions were documented in decreasing frequency in the cloaca, glottis, choanal slit, oropharynx, esophagus, proventriculus and ventriculus. Lesions are commonly reported in Hawk-headed Parrots and Green-winged Macaws, but have also been described in other macaws, African Grey Parrots, *Amazona* spp., caiques, conures, budgerigars, Barraband's Parrot, cockatiels and *Pionus* spp.^{65,135,318,399,412}

Clinically, many affected birds may appear normal with no changes in CBC or clinical chemistries. In other birds, intestinal papillomas mechanically interfere with normal physiologic activities (Table 32.7). Cloacal papillomas may cause or mimic recurrent prolapses. Droppings may be loose, causing feathers around the vent to be stained or covered with fecal material. In chronic cases, melena may be noted. Depending on the location and severity of the lesions, some birds with cloacal papillomas are able to breed normally while others may not be able to copulate.

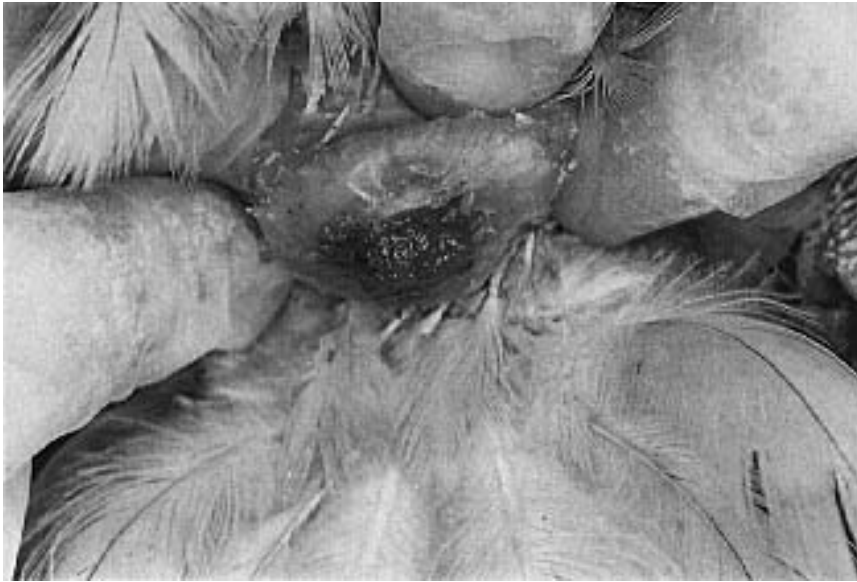

FIG 32.11 A six-year-old Blue-fronted Amazon hen was presented for tenesmus and diarrhea. The bird weighed 425 g and was in overall good condition. Excrement was accumulated on the pericloacal feathers. An irregular pink mass was present on the dorsal mucosa of the cloaca. The area was coated with five percent acetic acid, and the large mass along with several smaller raised lesions on the mucosa turned white. CBC and clinical chemistries were normal. The bird was not found to be shedding polyomavirus using a DNA probe test. These findings were suggestive of cloacal papillomatosis. The mass was removed with staged cauterization using silver nitrate.

Grossly, papillomatous lesions may appear as large, distinct masses or may occur as numerous small, raised lesions covering the mucosa (Figure 32.11). These friable growths may be pink or white and have a tendency to bleed easily when bruised (see Color 19). Acetic acid (5%) will turn papillomatous tissue white, helping to identify suspect lesions.^{260,412} Many internal papillomatous lesions are not recognized until necropsy. Suspicious lesions in the oral or cloacal cavity can be viewed directly. Endoscopy is necessary to identify and obtain diagnostic biopsies of suspect papillomatous lesions in the esophagus or proventriculus or high in the cloaca or proctodeum.

Attempts to demonstrate papillomavirus in suspect lesions by electron microscopy, low stringency southern blotting techniques or immunocytochemical procedures have all failed. Attempts to induce lesions in Amazon parrots, macaws and cockatoos using ho-

mogenized lesions have also been unsuccessful;³⁹⁹ however, the disease has features that suggest an infectious agent.^{260,412} Chronic irritation of the cloacal mucosa with epithelial cell hypertrophy or hyperplasia could result in a histologic lesion that morphologically resembles those induced by papillomavirus and has been suggested as an alternate cause of these lesions.^{135,399} Herpes-like virus particles were described in a cloacal papilloma in a conure.¹¹⁸ Malnutrition, particularly with respect to vitamin A, has been suggested to potentiate lesions.

Histologic examination is necessary to confirm a diagnosis in any suspect lesions. Proliferations of epithelial cells on a fibrovascular stalk are suggestive. The neoplasms may show numerous projections covered by a hyperplastic tessellated epithelium or a non-keratinized columnar epithelium containing some mucous glands. The stroma may show some inflammatory cells. Mitotic figures may be present in the basal cells or upper layers of hyperplastic epithelium.³⁹⁹ Amazon parrots with papillomatous lesions have been described as having a high incidence of malignant pancreatic or bile duct carcinomas.^{135,171} The differential diagnoses for papillomatosis should include the wart-like growths in cockatoos, in which herpesvirus-like particles have been identified, and the tumorous forms of avian pox (skin or oral mucosa).²⁴⁵

Therapy

Suggested therapeutic measures for cloacal papillomas have been based on the physical removal of the masses through cryotherapy, radiocautery or surgical excision. These procedures have been performed alone or in combination with the use of autogenous vaccines. None of the proposed therapies is consistently effective, and papillomatous tissue often recurs. The use of autogenous vaccines has been described but is generally not effective.^{78,260,352,412} Spontaneous regression of papillomatous tissue has been described.^{139,260,412}

With any removal technique, care should be exercised to prevent excessive tissue damage that may result in severe scarring and reduction in the size of

TABLE 32.7 Clinical Signs Associated with Internal Papillomatosis

Cloaca	Tenesmus, infertility, recurrent enteritis, hematochezia, flatulence, odoriferous stool, cloacoliths, acid pH
Oral Cavity	Dysphagia, dyspnea, wheezing
Upper GI	GI blockage, anorexia, chronic weight loss, vomiting, dilatation of the proventriculus or ventriculus, passing whole seeds

the cloacal lumen. Scarring can result in incontinence, reproductive failure or blockage of the urodeum or proctodeum.

Staged cauterization with silver nitrate sticks may prove to be the easiest, safest and best way to remove papillomatous lesions from the cloaca (see Color 19).¹⁹⁴ Lesions should be exteriorized by inserting a moistened cotton swab followed by carefully rubbing a small area of the lesion with a silver nitrate stick. The silver nitrate should be immediately inactivated with copious fluids to prevent the liquified material from burning unaffected mucosal tissues. The procedure is repeated at two-week intervals until the lesions have been removed.

Epizootiologic evidence has been used to suggest that intestinal papillomas are caused by an infectious agent even though no etiology has been confirmed. Mutual preening and sexual contact have been suggested as methods of transmission. However, other investigations suggest that the disease is not infectious (Clubb, S unpublished). Several large parrot aviaries have had epizootic outbreaks of the disease following the introduction of a clinically positive bird.^{260,412} Until further information on the etiology of this disease is available, it is prudent to isolate birds with lesions from the remainder of a collection.

Polyomavirus

Budgerigar fledgling disease (BFD) is caused by the first avian polyomavirus to be characterized (Color 32.15).^{85,376} Polyomaviruses that infect various avian hosts appear to be morphologically and antigenically similar; however, the clinical presentation, distribution of lesions and epidemiologic effects of the virus are dramatically different among susceptible species.^{38,39,130,175,188}

The capsid antigens from the BFD virus and other polyomaviruses have been shown to be antigenically related. Comparison of nucleic acid from avian and mammalian polyomaviruses indicates that there are similarities; however, the genomes are not identical. Polyomaviruses recovered from several species of Psittaciformes have been shown to be similar by comparing restriction maps of viral DNA and by using viral-specific DNA probes (Color 32.8).^{233,281,292,321}

It has been suggested that the avian strains of polyomavirus be placed into the subgenus avipolyomavirus. This is based on the finding that strains of polyomavirus recovered from budgerigars

(BFDV-1), chickens (BFDV-2) and Blue and Gold Macaws (BFDV-3) had distinct degrees of tropism.³⁹⁷ This supports the findings that polyomavirus recovered from budgerigars did not cause disease in experimentally infected Blue and Gold Macaws (Ritchie, BW unpublished). It is suspected that strains from Passeriformes are also different. DNA probes designed to detect polyomavirus from Psittaciformes do not detect some strains of polyomavirus found in passerine birds.

BFDV-2 antibodies could be detected in a flock of clinically healthy broiler chickens in Central Europe that were also infected with infectious bursal disease virus. The role that this immunosuppressive virus played in the pathogenesis of the polyomavirus infection was undetermined.³⁹⁷

Transmission

The epizootiology of polyomavirus infections is not fully understood. The factors involved in the duration and induction of viral shedding remain unresolved. Some asymptomatic adults produce persistently infected young, while others have neonates that intermittently may develop clinical signs and die. It has been suggested that persistently infected birds may be immunotolerant as a result of being infected before they are immunocompetent. Some birds are known to shed virus in the presence of high antibody titers. Asymptomatic adults that intermittently shed the virus are thought to be responsible for the persistence, transmission and spread of the virus through various avian populations.^{38,39,44,85,105,106} In polyomavirus outbreaks involving 23 different budgerigar aviaries, the onset of disease could be traced to the addition of new, clinically normal breeders.^{38,39}

Experimental data and observations with the natural disease suggest that polyomavirus transmission may occur by both horizontal and vertical routes.^{38,44,63,188,233} Parents may transmit virus to offspring through the regurgitation of exfoliated crop epithelial cells. Virus can replicate in the epidermal cells of the feather follicles resulting in the presence of virus in "feather dust," which may enter a susceptible host through the respiratory or gastrointestinal tract. Virus has been isolated from lung tissue supporting the possibility of an aerogenous transmission. The presence of virus in the renal tubular epithelial cells suggests passage of virus in the urine. Polyomavirus nucleic acid can be detected in cloacal swabs taken from birds during polyomavirus outbreaks. The recovery of viral DNA from the cloaca

suggests that the virus could be shed from gastrointestinal, renal or reproductive tissues.^{292,293}

Seronegative young adult birds will seroconvert when housed adjacent to seropositive breeding birds, implicating indirect transmission of the virus.^{63,72,188} Aviary personnel, technicians, veterinarians, pet owners and any aviary equipment should be considered important vectors for this environmentally stable virus.

Findings in support of vertical transmission include the identification of intranuclear inclusion bodies in one-day-old budgerigars and the occurrence of infections when eggs from parents that consistently produce diseased neonates are cross-fostered to parents producing normal young.^{38,39,125}

Theoretically, a persistently infected hen could pass maternally derived antibodies, virus or both to its young. The clinical status of the chick could then depend on the level of maternally derived antibodies and the stage of immunocompetency when viral exposure occurs. Chicks that have protective levels of maternal antibodies as well as infections derived from the parents may serve to infect susceptible neonates in the nursery.^{105,106} Persistent infections with intermittent shedding and vertical transmission are also suspected to occur in finches and result in early embryonic death.^{192,256}

The incubation period is not known. Affected budgerigar fledglings show peak mortality rates between the 15th and 19th day of life. In larger parrots, death may occur from 20 to 140 days of age, with most deaths occurring between 20 to 56 days of age.

Pathogenesis

As a group, polyomaviruses typically reside in a latent state, and infections become patent following periods of suffering from stressors.⁴²⁸ The age of a bird at the time of viral exposure may be a major factor in the pathogenesis of polyomavirus infections. Budgerigars that die shortly after hatch have more severe and widespread lesions than do birds in which the morbid state is more prolonged.³⁸ When 11- to 12-day-old chicken embryos are experimentally infected with polyomavirus, the hatched chicks remain normal and produce detectable antibodies by two weeks of age; in contrast, embryos infected at ten days of age are susceptible to the virus and develop pansystemic lesions.⁶³ It is theorized that persistently infected birds may be those that are infected before they are immunocompetent.^{105,106,424}

Field studies have shown that birds that die from avian polyomavirus frequently have antibodies to the virus. These findings, along with the frequent occurrence of glomerulopathy (immune complex induced) have led to the theory that death from avian polyomavirus in large psittacine birds is caused by an immune complex disease;³²¹ however, Blue and Gold Macaws that were seronegative for avian polyomavirus remained subclinical after being infected with BFD virus. These birds did seroconvert and developed high neutralizing antibody titers (>1:640) indicating that they were susceptible. DNA probe-testing of whole blood indicated intermittent viremia. The experimentally infected birds remained asymptomatic a year after infection, suggesting that other factors may precipitate the formation of immune complexes in field cases (Ritchie BW, unpublished). Further, massive hepatocellular necrosis (with intranuclear inclusion in hepatocytes) is the most frequent histologic lesion in larger psittacine birds that die from avian polyomavirus, and an immune complex theory of avian polyomavirus-induced death does not explain the principal histologic lesion.

The BFD virus can replicate in a variety of target cells of many avian species including chicken embryo cells.²⁸¹ The virus appears to require host cells that are dividing and temperatures of at least 39°C. Following the primary viremia, inclusion bodies can develop in most internal organs as well as the skin and developing feathers (Figure 32.13). The highest virus concentration is usually found in the brain. Tissue lesions can be severe and are directly related to the level of morbidity and mortality. The virus has been associated with immunosuppression through its ability to destroy or inhibit the normal development of lymphoid tissue. Infections in adult Estrildidae or Ploceidae have been suggested to be dependent on immunosuppression.⁴⁴⁰

Polyomaviruses in mammals are natural tumor inducers. There has thus far been no association between polyomavirus infections in birds and an increased incidence of tumors, although more in-depth studies are necessary.^{38,39,44,63,130,190,281} Some mammalian polyomavirus infections are known to persist by incorporating viral genome into host cell DNA.

Clinical Features

An avian polyomavirus appears to be distributed worldwide, but there are some apparent strain differences. For example in Europe, a more chronic form of the disease is common in budgerigars, while in the United States and Canada an acute form of disease

with high mortality prevails. Most members of the Papovaviridae family have a restricted host range.²⁸¹ In contrast, the avian polyomavirus appears to infect a wide variety of Psittaciformes, Estrilidae and Ploceidae including macaws, Amazon parrots, conures, White-bellied Caiques, parrotlets, African Grey Parrots, lovebirds, Ring-necked Parakeets, Eclectus Parrots,³⁹² Scarlet-chested Parrots, Bourke's Parrots,³¹¹ cockatoos^{311,363} and finches.^{381,382,440}

- **Budgerigars:** The type of clinical disease induced by polyomavirus in budgerigars appears to depend on the age and condition of the bird when exposure to the virus occurs. Neonates from infected flocks may develop normally for 10-15 days and then suddenly die with no premonitory signs. Other infected hatchlings may develop clinical signs, which include abdominal distension, subcutaneous hemorrhage, tremors of the head and neck, ataxia and reduced formation of down and contour feathers.^{38,39,72,175,257} Infections have also been associated with decreased hatchability and embryonic death.¹²⁵

Infected budgerigars may die rapidly once clinical signs develop, and reports on mortality rates vary from 30 to 100% of affected hatchlings. Mortality rates are highest in budgerigars less than 15 days of age. Survivors may exhibit symmetrical feather abnormalities characterized by dystrophic primary and tail feathers, lack of down feathers on the back and abdomen and lack of filoplumes on the head and neck (Color 32.15).^{39,44,72,175,281} Birds often die acutely with the crop and gastrointestinal tract full of food. Surviving fledglings frequently have dystrophic feathers (French moult). Developing primary and secondary feathers may break or fall out, resulting in substantial blood loss. Affected birds are unable to fly and are often called runners or hoppers. Similar feather lesions can be caused by the psittacine beak and feather disease (PBFD) virus. In general, feather lesions in budgerigars caused by polyomavirus resolve after several months, while those induced by PBFD virus will continue to progress.

It has been previously speculated that French moult represents a nonfatal form of BFD;^{38,39,175} however, budgerigars with classic French moult lesions are often seronegative for polyomavirus antibodies.²²⁶ In North America and Europe, lesions attributable to French moult are thought to be caused either by the polyomavirus or by the PBFD virus. Investigations in Australian budgerigars have demonstrated that clinical signs associated with French moult are associated with the PBFD virus and not with avian

polyomavirus.^{38,39,175} Immunohistochemical staining of infected tissues with viral-specific antibodies or DNA probes is required to differentiate between intranuclear inclusion bodies induced by polyomavirus and those caused by PBFD virus.

- **Other Psittaciformes:** In larger psittacine birds, polyomavirus infections may cause peracute death with no premonitory signs or acute death after development of clinical changes including depression, anorexia, weight loss, delayed crop emptying, regurgitation, diarrhea, dehydration, subcutaneous hemorrhages, dyspnea and polyuria (Color 32.12).^{63,130,190,363} Intramuscular injection sites or damaged feathers may bleed profusely. Neurologic signs characterized by ataxia, tremors and paralysis have been described in some Psittaciformes.⁶³ Clinical signs are common at the time of weaning, and infected fledglings typically die 12 to 48 hours after developing clinical signs. Infections may occur in both parent-raised and hand-raised neonates.^{63,130,190} In one outbreak, mortality rates in exposed neonates ranged from 31 to 41% of the at-risk population.⁶³ Infected birds that recover are thought to become asymptomatic virus carriers. Infections in adult birds are thought to result in the formation of subclinical carriers with only occasional development of clinical signs. Blue and Gold Macaw neonates experimentally infected with budgerigar fledgling disease virus (derived from cell culture) did not develop clinical signs of infection but did seroconvert, indicating that they were subclinically infected (Figure 32.12) (Ritchie BW, unpublished).

A chronic form of polyomavirus has also been described and is typified by weight loss, intermittent anorexia, polyuria, recurrent bacterial or fungal infections and poor feather formation.^{63,190} Birds that recover appear normal, although some birds have been found to die months later from renal failure.⁶³ The feather abnormalities that are relatively common with polyomavirus infections in budgerigars have been less frequently described in other psittacine birds.^{63,130,190,307}

In the Eclectus Parrot, transient gastrointestinal stasis, melena and abdominal pain have been described in older chicks. Occult hematuria has been suggested as an indication of a polyomavirus infection in this species.³⁹² Cloacal swabs from suspect patients can be screened for the presence of polyomavirus nucleic acid using viral-specific DNA probes. Affected birds may have increased activities of LDH, AST and alkaline phosphatase.⁶³



FIG 32.12 Blue and Gold Macaw chicks that did not have avian polyomavirus VN antibodies were experimentally vaccinated with a killed vaccine. The vaccinated birds seroconverted and were protected from subsequent infection. Non-vaccinated birds remained asymptomatic following experimental inoculation even though they developed high VN antibody titers, indicating that they had been infected.

In addition to clinical changes in neonates, polyomavirus infections have also been documented in an eight-month-old Splendid Parakeet and in sporadic, acute deaths in fully fledged lovebirds less than one year old.^{307,310} An adult Moluccan Cockatoo with neurologic signs was diagnosed as having polyomavirus based on the ultrastructural morphology of inclusion bodies in the brain.³⁶³ An outbreak of polyomaviral disease in an aviary with numerous Psittaciformes resulted in the deaths of an adult Eclectus Parrot, a Painted Conure and 3 of 11 adult White-bellied Caiques. The affected birds were 2 to 2.5 years old and had lesions similar to those seen with polyomavirus infections in psittacine fledglings.³⁴⁴ These cases suggest that some older Psittaciformes may be susceptible to polyomavirus infections during epornitics.

- **Finches:** Lesions suggestive of a polyomavirus infection have been described as a cause of acute mortality in two- to three-day-old fledgling, young adult and mature finches.^{98,192,256,440} Affected birds had nonspecific signs of illness 24 to 48 hrs before death.^{98,256} In one outbreak, 36 of 70 two- to three-day-old birds died. Many of the fledglings that survived had poor feather development, long tubular misshapen lower mandibles, and fledged several days later than normal young (see Figure 43.13).²⁵⁶

Pathology

The gross lesions associated with polyomavirus infections are summarized in Table 32.8 (Colors 32.17, 32.20). Neonates presented for necropsy are usually in excellent overall condition and may have full crops and gastrointestinal tracts, indicating the speed of disease progression. Karyomegaly in various tissues and hepatic necrosis are the most consistent histologic lesions in larger psittacine birds.^{38,44,63,130,132,188,190} Other suggestive histologic lesions are listed in Table 32.9. Viral antigen present within inclusion bodies from infected Psittaciformes has been confirmed to be antigenically related to the polyomavirus isolated from budgerigars through the use of fluorescent antibody staining techniques.^{130,132,175,440}

Polyomavirus-infected finches may die acutely with no detectable pathology or can have gross and histologic lesions similar to those described for other birds (Tables 32.8, 32.9).^{98,188,256,440} Inclusion bodies from some finches have been confirmed to contain polyomavirus antigen by fluorescent-antibody staining techniques.⁴⁴⁰

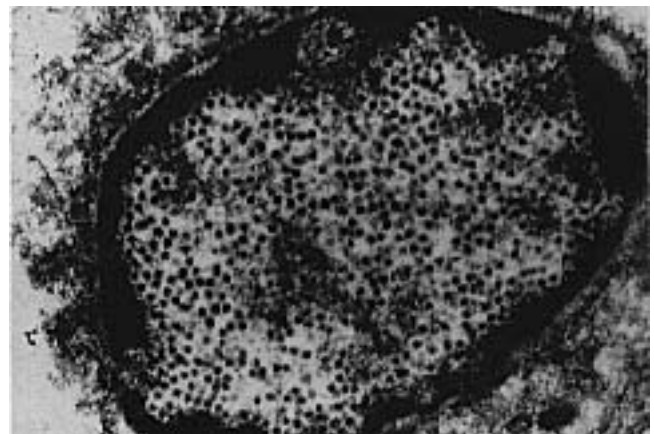


FIG 32.13 Intranuclear inclusion body in the brain of a Ducorps' Cockatoo that died after several days of depression and progressive neurologic signs (ataxia, paresis, paralysis, coma). The inclusion bodies in the brain were confirmed to contain polyomavirus antigen using viral-specific antibodies (immunoperoxidase technique) and polyomavirus nucleic acid using viral-specific DNA probes (*in situ* hybridization). This electron micrograph shows characteristic 50 nm icosahedral viral particles.

TABLE 32.8 Gross Lesions Associated with Polyomavirus Infections

	Budgerigars	Lovebirds	Other Psittaciformes	Finches
Heart	Hydropericardium, cardiomegaly, myocardial hemorrhage		Myocardial hemorrhage, epicardial hemorrhage, pale myocardium	
Liver	Hepatomegaly, yellow-white foci	Pallor, congestion, mottled hemorrhage	Hepatomegaly, red and yellow mottling, friable	Swollen, pallor, mottled hemorrhage
Spleen		Small, pallor	Splenomegaly, friable	Splenomegaly, congestion
GI tract	Intestinal hemorrhage		Intestinal hemorrhage	Serosal or subserosal intestinal hemorrhage
Kidney	Swelling, pallor or congestion, white foci, petechiation		Pallor, swollen	Perirenal hemorrhage
Skin	Subcutaneous hemorrhage, feather dystrophy		Feather dystrophy, petechial hemorrhage, ecchymotic hemorrhage	
Other	Ascites, lung congestion	Increased serosal fluids	Pale skeletal muscle, ascites, serosal and subcutaneous hemorrhage, pallor	

TABLE 32.9 Histologic Lesions Associated with Polyomavirus Infections

	Budgerigars	Lovebirds	Other Psittaciformes	Finches
Heart	Coagulative necrosis, myocardial degeneration, inclusion bodies	Enlarged endothelial cells	Myocarditis, epicardial hemorrhage, inclusion bodies (myocardium)	Myocarditis, inclusion bodies
Liver	Coagulative necrosis, vacuolar degeneration, inclusion bodies	Hepatic necrosis, hemorrhage, inclusion bodies	Hepatic necrosis, inclusion bodies	Kupffer's cell hyperplasia, hepatocellular necrosis, periportal heterophils and lymphocytes, vacuolar degeneration, inclusion bodies (hepatocytes, Kupffer's cells)
Spleen	Lymphatic atrophy, inclusion bodies, (reticulo-endothelial [RE] cells)	Lymphoid depletion, necrosis, inclusion bodies	Karyomegaly of RE cells, multifocal necrosis, inclusion bodies	Macrophage hyperplasia, necrosis, lymph depletion, inclusion bodies
GI Tract	Inclusion bodies (crop, intestines)		Serosal hemorrhage, epithelial desquamation of crop and esophagus, inclusion bodies (esophagus, proventriculus, intestines)	Necrosis and plasma cell infiltrates of lamina propria, enlarged vacuolated epithelial cells, inclusion bodies, mainly enterocytes
Kidney	Focal nephrosis, vacuolar degeneration, inclusion bodies (renal tubular epithelium)	Enlarged endothelial cells, enlarged epithelial cells, karyomegaly of renal tubules	Membranous glomerulopathy, thickened glomerular capillaries, inclusion bodies (glomerulus interstitium, collecting tubules)	Inclusion bodies (endothelium, tubular epithelium)
Skin	Ballooning degeneration (follicular epithelium, lateral and axial plate cells, epidermis) follicular and epidermal hyperplasia, inclusion bodies (epidermis, follicular epithelium, uropygial gland)		Ballooning degeneration and karyomegaly in epithelium of growing feathers, inclusion bodies (follicular epithelium)	
Other	Bone marrow necrosis, lymphatic atrophy, cerebellar lesions (particularly in the Purkinje cells), inclusion bodies (pancreas, adrenals, lung, gonads, brain)		Generalized hemorrhage, bursal medullary necrosis, bone marrow necrosis, inclusion bodies (bone marrow, pancreas, adrenals, skeletal muscle, lungs)	Bone marrow necrosis, inclusion bodies

Diagnosis

Feather lesions in surviving budgerigars cannot be macroscopically distinguished from changes caused by the PBFV virus. Malnutrition can also cause feather lesions, which might be difficult to evaluate clinically. Organ lesions can be induced by a variety of infectious agents, particularly bacteria.

Demonstration of large clear basophilic or amphophilic intranuclear inclusion bodies is considered suggestive of a polyomavirus infection. A confirmed diagnosis requires immunohistochemical staining of suspected lesions using viral-specific antibodies or the detection of viral nucleic acid using polyomavirus-specific DNA probes.^{188,292,293,440} The VN can be used to identify virus isolated in cell culture.²⁸¹

Immunodiffusion and virus neutralization techniques have been used to demonstrate polyomavirus antibodies in exposed birds. During outbreaks in mixed psittacine bird collections, infected survivors and asymptomatic birds exposed to them developed anti-BFD virus neutralizing antibodies.^{63,188} The prevalence of neutralizing antibodies against BFD virus in aviaries containing cockatoos, macaws, Amazon parrots and conures ranged from 11 to 45%. These titers were found to decrease over a two-month period. The demonstration of waning antibody titers suggests a transient serologic response in exposed birds. Adults from an infected flock that were exposed to diseased birds developed titers and subsequently raised seronegative, clinically normal young.^{63,105,106,188,424}

Subclinical carriers that intermittently shed polyomavirus have been thought to maintain high antibody titers in serial serologic assays.^{105,424} Based on these suppositions, the demonstration of sustained high antibody titers has been used to screen for polyomavirus carriers,^{63,105,106,292,424} however, polyomavirus-specific DNA probes have been used to demonstrate that there is no correlation between the shedding of polyomavirus in excrement and the titers of neutralizing antibodies.^{292,293,320}

Viral-specific DNA probes have been used to demonstrate polyomavirus nucleic acid in various tissues including liver, spleen, kidney, cloacal secretions, intestinal secretions, serum and blood. Viral nucleic acid occasionally can be detected in the blood or serum of some infected birds; however, the best antemortem sample for detecting polyomavirus shedders in larger psittacine birds is a cloacal swab. Testing birds twice per year (before and after the breeding season) is recommended to detect intermittent viral shedders.

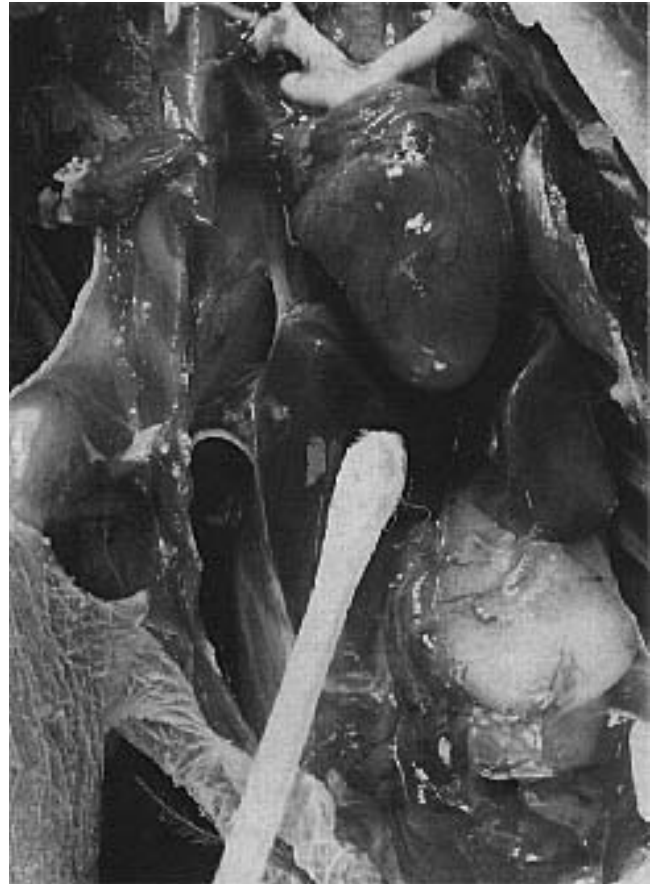

FIG 32.14 The use of a DNA probe test is the best method to confirm the presence of polyomavirus in postmortem samples. A swab is used to collect a sample from the cut surface of the liver, spleen and kidney.

DNA probes can also be used to detect viral nucleic acid in fresh tissues from birds that are suspected to have died from polyomaviral infections. In suspect cases, duplicate tissue samples can be sent for histopathology as a tentative diagnosis and for DNA probing to confirm a polyomavirus infection. The best sample to submit for postmortem confirmation of polyomavirus is a swab of the cut surface of the spleen, liver and kidney (same swab for all three tissues) (Figure 32.14).

Therapy

In chicks that are hemorrhaging, injection of 0.2-2.5 mg/kg bodyweight of vitamin K IM may be helpful and can increase survival rates favorably, although prognosis in birds with heavy hemorrhaging is poor.

Several immunostimulants have been anecdotally suggested as effective in the treatment of birds with clinical signs suggestive of avian polyomavirus; however, suggested therapies have not been confirmed to

be effective in birds that were documented (liver biopsy) to have an active avian polyomavirus infection.

Control

Polyomavirus virions are small, nonenveloped particles that are resistant to severe environmental conditions, many disinfectants and heat at 56°C for two hours.^{44,376,428} Stability of the virus causes a considerable problem in the aviary because persistently infected adult birds can shed virus in their feather dust or excrement. Manual removal of any organic debris followed by the use of appropriate disinfectants is required to prevent or contain outbreaks. Sodium hypochlorite (5%) is thought to be effective against the BFD virus at a concentration of 50 ml/liter of diluent.^{93,281} A polyomavirus DNA probe test can be used to screen walls, caging, air circulating ducts and equipment in the home or hospital to determine if this virus is contaminating a bird's environment. This is accomplished by rubbing a swab across the surfaces intended to be evaluated for the presence of polyomavirus nucleic acid.

With the highly infectious nature of avian polyomavirus, particularly to young Psittaciformes, closed breeding operations that do not allow visitors should be encouraged. A cloacal swab of any bird that is being added to a collection should be analyzed during the quarantine period to determine whether a bird is shedding polyomavirus. During an epornitic, birds that are actively shedding the virus can be identified by using DNA probes.^{292,293,344} All birds being sold from an aviary should be tested to determine if they are shedding polyomavirus before shipment. Birds also should be tested for viral shedding during the post-purchase examination.

A bird that is shedding polyomavirus could be maintained as a pet if it does not expose other birds, particularly neonates, to the virus. Breeding birds shedding polyomavirus should be separated from the remainder of the collection, and offspring from these birds should be raised separately from birds that are not shedding the virus. Offspring from shedders should also be raised separately from birds that are not shedding the virus. The applicability of killed and recombinant polyomavirus vaccines is being evaluated.

A killed avian polyomavirus vaccine was found to induce virus-neutralizing antibodies in Blue and Gold Macaw chicks that were sufficient to protect them from subsequent challenge. This suggests that a vaccine could be effective in preventing infections (Ritchie BW, unpublished).

Outbreaks of polyomavirus tend to be persistent in budgerigar aviaries that utilize a constant breeding cycle, while the disease appears to be self-limiting in aviaries raising larger Psittaciformes where breeding cycles are discontinuous.⁶³ High levels of fledgling mortality can be reduced in budgerigar aviaries by stopping the breeding cycle and resting the birds for several months. The exact mechanisms involved in stopping new cases remains undetermined.

Depopulation of budgerigar aviaries experiencing outbreaks followed by restocking with sero-negative birds has been suggested as a method of controlling enzootic infections in this species. It has been suggested that polyomavirus-free budgerigar nestlings can be produced by interrupting the breeding cycle, removing all but the older breeding birds and disinfecting the aviary.³²¹ This technique has been reported to be successful in some flocks, while in others, infections resume when breeding is initiated.¹²⁵ Depopulation is not a practical, nor recommended procedure for controlling polyomavirus in larger Psittaciformes.



Circoviridae

Psittacine Beak and Feather Disease Virus

A chronic disease characterized by symmetric feather dystrophy and loss, development of beak deformities and eventual death was first described in various species of Australian cockatoos in the early 1970's.^{315a} Free-ranging Psittaciformes with feather abnormalities suggestive of this disease were noted by Australian explorers at the turn of the century. The disease has been diagnosed in numerous Psittaciforme species in addition to cockatoos. The currently used name, coined by Perry in 1981, is "psittacine beak and feather disease" (Pbfd).³¹⁶

This disease has been experimentally reproduced in neonatal budgerigars and Rose-breasted Cockatoos using feather homogenates containing 19-22 nm viral particles, and in neonatal budgerigars, cockatiels, African Grey Parrots and Umbrella Cockatoos using purified concentrated Pbfd virions (Color 32.5).^{339,443}

The Pbfd virus is a 14 to 17 nm icosahedral nonenveloped virion associated with two major proteins that have molecular weights of 27,000 and 23,000

daltons. Virus with similar ultrastructural characteristics, protein composition and antigenic similarities can be consistently recovered from numerous different species of psittacine birds with clinical or histologic lesions of PBFDF (Figure 32.15).^{339,343,345}

The PBFDF virus infecting different hosts is antigenically similar and has sufficiently conserved nucleic acid sequences to allow detection of the virus using viral-specific DNA probes. The virus hemagglutinates erythrocytes from cockatoos and some guinea pigs (see Figure 32.2).³⁴⁰

Based on the virion dimension, polypeptide composition and nucleic acid size and experimental conformation, it has been suggested that the etiologic agent of PBFDF is a member of a new family of pathogenic animal viruses.³⁴⁵ The virion size and nucleic acid characteristics described for the PBFDF virus are similar to those found for the chicken anemia agent (CAA) and for the apparently nonpathogenic porcine circovirus (PCV).⁴⁰⁴ On the basis of these similarities, it has been suggested that these viruses be placed in the same family to be called *Circoviridae*. Because the PBFDF virus does not readily grow in cell culture, nothing is known about its replication mode. The

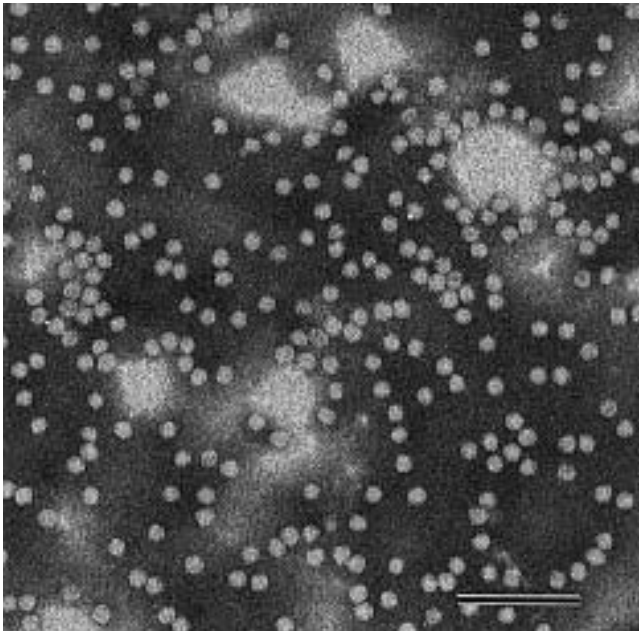


FIG 32.15 High concentrations of PBFDF virus can be recovered from dust in rooms where PBFDF-positive birds are housed. With the ease with which contaminated dust could be transferred from bird to bird through natural air circulation or through fomites (clothing, hair, skin, caging, nets), it is theorized that contaminated feather dust serves as the major method of environmental persistence and natural transmission of the virus. Areas suspected to be contaminated with PBFDF virus can be tested for the presence of virus using viral-specific DNA probes.

TABLE 32.10 Psittaciformes Currently Considered Susceptible to PBFDF virus

Sulphur-crested Cockatoo	Triton Cockatoo
Major Mitchell's Cockatoo	Citron Cockatoo
Galah	Goffin's Cockatoo
Little Corella	Vasa Parrot
Long-billed Corella	Blue-fronted Amazon Parrot
Budgerigar	Red-lore Amazon
Cockatiel	Red-vented Cockatoo
Rainbow Lorikeet	Senegal Parrot
Western Rosella	African Grey Parrot
Hooded Parrot	Meyer's Parrot
Malee Ring-necked Parakeet	Black Palm Cockatoo
Port Lincoln Parrot	Red-bellied Parrot
Red-rumped Parrot	Gang-gang Cockatoo
Bourke Parrot	Scarlet Macaw
Eclectus Parrot	Rose-ringed Parakeet
Princess Parrot	Pale-headed Rosella
Peach-faced Lovebird	Golden-shouldered Parrot
Nyassa Lovebird	Northern Rosella
Fisher's Lovebird	Jenday Conure
Masked Lovebird	Green-winged Macaw
King Parrot	Pionus Parrot
Moluccan Cockatoo	
Umbrella Cockatoo	
Indian Ring-necked Parakeet	

CAA and PCV replicate in the nucleus of the host cells.

A virus that morphologically resembles PBFDF virus has been described in pigeons.¹³⁴ When compared to PBFDF virus, the pigeon circovirus is antigenically unique and has some differences in nucleic acid sequence.⁴³⁹

Epizootiology

Histologic or clinically suggestive lesions of PBFDF have now been described in 42 species of Psittaciformes. Historically, PBFDF was thought to be restricted to Old World and South Pacific psittacine birds, with the white and pink cockatoos being particularly susceptible. However, the disease has been documented in several black cockatoos and New World psittacine birds including Amazon parrots, macaws and pionus parrots (Table 32.10) (Color 32.1). Investigations indicate that the actual host range of the PBFDF virus remains largely unknown. Psittacine beak and feather disease has been documented only in Psittaciformes.^{139,178,187,309,343}

Epizootiologic studies in one import station in the United States showed that 0.5% of imported Lesser Sulphur-crested Cockatoos, Umbrella Cockatoos, Citron Cockatoos and Moluccan Cockatoos had gross lesions consistent with PBFDF, suggesting that these birds had been infected in their country of origin.¹⁸⁷ It is postulated that PBFDF has historically been enzootic in free-ranging populations of Old World and

South Pacific psittacine birds, and that the disease has been introduced to other susceptible populations of both free-ranging and captive birds through the worldwide movement of birds for the pet market.^{271,273}

In Australia, 75% of the captive Sulphur-crested Cockatoos examined in one veterinary hospital had clinical signs consistent with PBFD. The incidence of the disease in other commonly maintained captive psittacine birds in Australia, including galahs and budgerigars, is thought to be much lower.³¹⁶ Psittacine beak and feather disease is reportedly enzootic in free-ranging populations of Sulphur-crested Cockatoos, Rose-breasted Cockatoos, Little Corellas, Major Mitchell's Cockatoos, Crimson Rosellas, budgerigars and Rainbow Lorikeets.^{271,272,308,316}

As many as 20% of free-ranging Sulphur-crested Cockatoos have clinical signs of PBFD in any one year. One flock of Sulfur-crested Cockatoos decreased from 120 individuals to 20 over a nine-month period. Many of the dead or dying members of this flock were diagnosed with PBFD. Half of the 20 birds in a free-ranging flock of Crimson Rosellas were found to have PBFD.²⁷³ There does seem to be an increased occurrence of PBFD late in the breeding season in both captive and free-ranging cockatoo populations.^{315,316}

Transmission

Susceptible birds can be experimentally infected with the PBFD virus through the combined oral, intraoccal and intranasal routes.^{339,443} Psittacine beak and feather disease virus was recovered in the feces and crop washings from various species of psittacine birds diagnosed with PBFD. During the test period, 26% (8 of 31) of the birds screened were found to be excreting PBFD virus in their feces, and 21% (3 of 14) of crop washings were positive for the PBFD virus. While the concentration of PBFD virus demonstrated in the crops of positive birds was low, the possibility of an adult transmitting the virus to neonates during feeding activities that involve the regurgitation of food and exfoliated crop epithelium deserves consideration. Virus that was recovered from the crop may have originated from infected cells located in the crop or esophageal epithelium, or may have been deposited in the crop after swallowing of exfoliated epithelium from beak or oral mucosal lesions. High concentrations of the virus also can be demonstrated in feather dust collected from a room where birds with active cases of PBFD are housed (see Figure 32.13).³⁴² It has been postulated that the

frequent demonstration of PBFD inclusions in tissues of the palate, esophagus, crop, intestines, bursa and liver probably accounts for viral shedding in the feces.²³²

The demonstration of high concentrations of virus recovered from a room where PBFD birds were being maintained implicates contaminated dust from any source as a major vehicle for the environmental persistence and natural transmission of the virus.³⁴²

Artificially incubated chicks from a PBFD-infected hen consistently develop PBFD suggesting that vertical transmission of the virus occurs. Because viremia has been shown to occur in infected birds, vertical transmission would be suspected.

Several reports suggest the possibility of asymptomatic adults producing progeny with clinical signs of PBFD in successive breeding seasons. These findings suggest a carrier state may exist with vertical or horizontal transmission of PBFD virus from parent to offspring or a genetic predisposition to the disease;^{187,316,317,386} however, in most suspected cases of parent-to-offspring transmission, epizootiologic investigations indicate probable exposure to the PBFD virus occurring through sources other than the parents. The widespread use of viral-specific DNA probes to detect subclinically infected birds may provide more information on what role, if any, these birds play in transmitting the virus.

Pathogenesis and Immunity

PBFD is a progressive disease with temporary remission in the occurrence of new lesions in the periods of nonmolting. Irregular photoperiods to which many companion birds are subjected may influence regular molting periods or the lack of them. The lesions of the beak may progress during the intermolt period.¹³⁴ It has been suggested that the virus depends on the multiplication of the host cells for its replication.²³⁶ Except for reported recoveries in budgerigars, lorikeets, lovebirds, a pionus parrot and some macaw neonates, the clinically apparent form of PBFD virus is considered fatal (Ritchie BW, unpublished).^{306,309,316} Most infected birds survive less than six months to one year after the onset of clinical signs, though some birds have been known to live over ten years in a featherless state. Death usually occurs either from changes induced by secondary bacterial, chlamydial, fungal or other viral agents, or from terminal changes that necessitate euthanasia.^{187,316,317,443} Cockatoos with PBFD have been diagnosed with severe cryptosporidiosis infections, which are generally




FIG 32.16 Cryptosporidiosis was diagnosed in a group of cockatoos with PBFV virus. In one bird, the infection was severe and extended from the small intestine to the cloaca. In general, cryptosporidiosis occurs only in animals that are immunosuppressed (courtesy of Kenneth Latimer).

considered to occur only in patients with immunodeficiencies (Figure 32.16).²³²

The predilection for birds to die from secondary or opportunistic pathogens has been interpreted to indicate an immunosuppression that is thought to be induced by damage to the thymus and bursa.^{187,308,316,386} Only limited work has been performed to document the suspected immunosuppression; however, PBFV patients were found to have low concentrations of pre-albumin and gammaglobulin as indicated by serum electrophoresis.¹⁸⁷ Other investigations with serum electrophoresis in birds with PBFV virus indicated that some birds had hypogammaglobulinemia (usually birds with severe beak necrosis or other clinical abnormalities) and some birds had hypergammaglobulinemia (Ritchie BW, unpublished).

PBFV-positive birds with inclusion bodies located only within the nucleus of infected epithelial cells have been found to spontaneously recover. On the other hand, larger psittacine birds with intracytoplasmic inclusion bodies located in macrophages usually succumb to the disease. Because the macrophage is critical for the initial processing and presentation of viral antigen to the immune system, it can be postulated that the determining factor in whether an infected bird develops a chronic fatal PBFV virus

infection, or develops a protective immune response is based on how the body processes the virus before it begins to persist in the cytoplasm of macrophages (see Figure 5.4).³³⁹

Some birds exposed to the PBFV virus remain clinically normal and develop HI and precipitating antibody titers. In fact, the detection of anti-PBFV virus antibodies in most adult Psittaciformes of a susceptible species suggests that these birds were exposed to the virus at some point in their lives and that the exposure resulted in a subclinical infection with the development of an effective immunologic response (Table 32.11). The factors that determine whether a bird mounts an immune response or is fatally infected could depend on the age at the time of exposure, the presence and levels of maternal antibodies, the route of viral exposure and the titer of the infecting virus.

An age-related susceptibility to the virus has been suggested by some experimental transmission studies. Neonatal budgerigars infected at less than seven days of age were found to develop severe disease, while birds infected at 10 to 14 days were reported to experience lower levels of morbidity, and some remained asymptomatic.^{339,443} It was suggested that this age-related susceptibility might be due to the ability of the neonatal bursa to take up particulate matter from the cloaca.³⁵⁵ Other transmission studies have indicated that the apparent age-related resistance to the virus was due to the birds' not being followed through an appropriate incubation period and may have had nothing to do with an age-related resistance.³³⁹

Incubation Period

Infected chicks and fledglings may show the first signs of disease during their feather development after replacing the neonatal down. Following experimental infection, the minimum incubation period is 21 to 25 days.³³⁹ The maximum incubation period may be months to years (Figure 32.17).

Rose-breasted Cockatoo chicks experimentally infected with PBFV virus have been reported to develop clinical signs of PBFV approximately four weeks after infection.⁴⁴³ African Grey Parrot chicks infected at three to eight days of age became depressed by 30 days old and developed progressive feather dystrophy by 33 to 44 days old. Umbrella Cockatoo chicks infected at three to eight days of age became depressed by 40 days old and developed progressive feather dystrophy from 42 to 47 days old.

TABLE 32.11 Information and HI titer of Clinically Normal, PBFD-Negative Birds Naturally Exposed to PBFD Virus

Species	PBFD Virus Exposure	HI titer
Umbrella Cockatoo	PBFD+ mate	1,280
Moluccan Cockatoo	PBFD+ bird in collection	2,560
Moluccan Cockatoo	PBFD+ bird in collection	1,280
Umbrella Cockatoo	PBFD+ bird in collection	80
Umbrella Cockatoo	PBFD+ bird in collection	640
Umbrella Cockatoo	PBFD+ mate	>5,120
Goffin's Cockatoo	PBFD+ mate	2,560
Cockatoo species	PBFD+ bird in collection	160
Cockatoo species	PBFD+ bird in collection	>5,120
Moluccan Cockatoo	PBFD+ mate	2,560

The time variance in developing clinical signs associated with PBFD among different psittacine chicks may be attributed to differences in concentrations of maternally transmitted antibodies, titer of virus in the inoculum or host responses to the virus.³³⁹

Clinical Disease

It appears that the avian species listed in Table 32.10 are of various susceptibilities; therefore, clinical (and pathological) signs may vary greatly. Generally, PBFD is a disease of young birds (up to three years), but older individuals (up to 20 years of age) may also develop clinical lesions. Older birds that develop clinical signs later in life may have been infected at a young age and remained latently infected.

In some Psittaciformes with pigmented feathers, abnormal coloration has been associated with histologic lesions consistent with PBFD virus infection. This is particularly true in African Grey Parrots, where affected feathers may be red instead of grey.^{18,338}

The feather changes, typical lesions of the beak (if present), and more rarely also of the nails, occur symmetrically in most instances. Based on markedly different clinical presentations, peracute, acute and chronic forms of PBFD have been described (Figure 32.18).^{315,316} The type of clinical disease appears to be influenced by the age of the bird when clinical signs first appear.

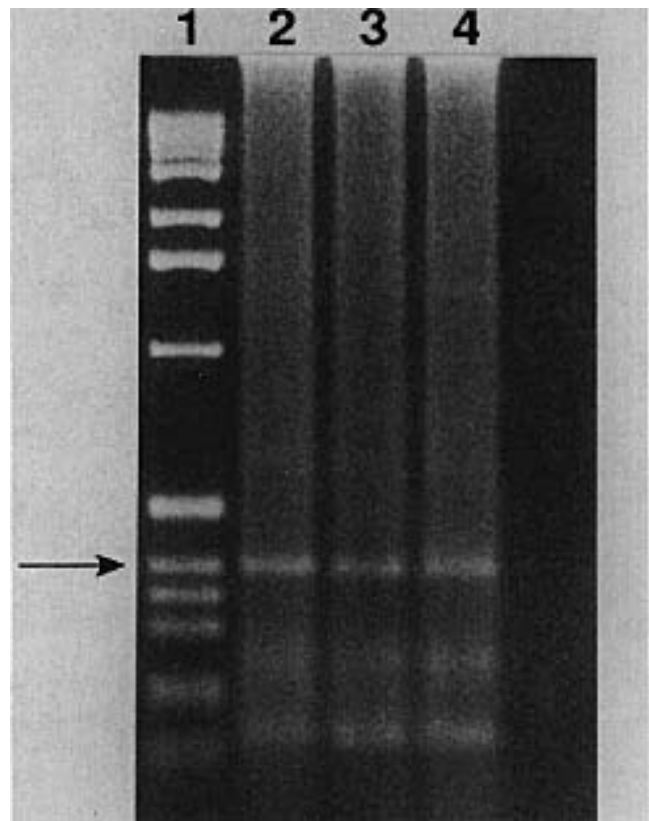


FIG 32.17 Three eggs from a Bare-eyed Cockatoo hen with PBFD virus were artificially incubated. PBFD virus nucleic acid was detected in the blood of all three of the chicks by DNA probe at 20 days of age (lanes 2,3,4; lane 1 is a control). The lane 1 and lane 3 chicks developed clinical signs of PBFD starting at 32 days of age, and infections were characterized by a two- to three-week course of progressive feather changes followed by death. The lane 2 chick (below), shown here with the lane 1 chick, did not develop clinical signs of disease until 80 days of age. Because all three of these chicks were presumably infected by the hen, and all three chicks were blood-positive at 20 days of age, these findings suggest that the time from infection to the development of clinical signs can vary.



FIG 32.18 Some birds can live with PBFD virus for many years. Birds with long-term infections frequently appear bald as feather pathology progresses through successive molts.

Peracute disease is suspected in neonatal psittacines that show signs of septicemia accompanied by pneumonia, enteritis, rapid weight loss and death.³⁰⁸ Histologic lesions in these cases may be limited. The peracute syndrome appears to be particularly common in young cockatoos and African Grey Parrots. Peracute cases of PBFD may be missed if a complete necropsy and thorough histologic exam are not performed on young of susceptible species that die suddenly.

The acute form of PBFD, commonly called French moult in Australia, is most frequently reported in young or fledgling birds during their first feather formation after replacement of the neonatal down, and chicks as young as 28 to 32 days of age have been described with classic lesions (Color 32.2).^{309,315,339} Acute infections are characterized by several days of depression followed by sudden changes in developing feathers, including necrosis, fractures, bending, bleeding or premature shedding of diseased feathers. In some acute cases of PBFD, birds with minimal feather changes may be depressed, develop crop stasis and have diarrhea, followed by death in one to two weeks.²³⁰ Gross feather lesions in the acute form of the disease can be quite subtle with only a few feathers showing dystrophic changes. This clinical picture is particularly common in young Sulphur-crested Cockatoos and lovebirds.³¹⁶ In African Grey Parrots a non-regenerative anemia is reported (PCV=14-25%)

with typical inclusion bodies in the bone marrow;³⁹¹ however, it has not been determined if these changes are caused by the PBFD virus or if they are a result of secondary pathogens. Another observation is the irregular necrosis of the reticular cells in the lymphocytically depleted spleen, which would suggest permanent immunosuppression.

Experimentally infected Rose-breasted Cockatoo neonates became acutely depressed and anorectic approximately four weeks post-infection. Twenty-four hours later, the feathers appeared to lose their luster and became pale and brittle. Subsequently, dystrophic feathers began to appear as the neonates developed their adult plumage.⁴⁴³ A similar disease progression has been defined for experimentally infected Umbrella Cockatoos and African Grey Parrot chicks (Color 32.5).³³⁹ Chicks that develop clinical lesions while the majority of feathers are still in a developmental stage exhibit the most severe feather pathology. These birds may appear totally normal one day and exhibit 80 to 100% feather dystrophy within a week (Color 32.2).³³⁹ The clinical progression of disease is less dramatic in neonates that develop clinical signs after body contour feathers are mature. In these birds, feather changes may be limited to the still-developing flight and tail feathers.^{309,317}

Chronic PBFD is characterized by the progressive appearance of abnormally developed feathers during each successive molt. Gross changes include retention of feather sheaths, hemorrhage within the pulp cavity, fractures of the proximal rachis and failure of developing feathers to exsheathe. Short, clubbed feathers, deformed, curled feathers, stress lines within vanes and circumferential constrictions may also be present (Figure 32.19) (Color 32.3).^{309,317,443} Replacement feathers become increasingly abnormal, and if birds live long enough they will eventually develop baldness as the feather follicles become inactive.^{309,317,443} Free-ranging birds with severe feather pathology may have an accompanying brownish discoloration of the skin that is thought to occur from exposure of normally sheltered skin to sunlight.^{271,309}

The distribution of dystrophic feathers within individual pterylae is variable and depends upon the stage of molt when the bird begins to develop clinical signs. In older birds, the first sign of PBFD is the replacement of normal powder down and contour feathers with dystrophic, necrotic, non-viable feathers that stop growing shortly after emerging from the follicle (Color 32.3). The disease then progresses to involve the contour feathers in most tracts, followed

by dystrophic changes in the primary, secondary, tail and crest feathers (Color 32.4). Primary feathers are usually the last to manifest the disease.^{187,309,317,339} It has been assumed that the susceptibility of the powder down feathers is based on their consistent molt pattern, compared to the seasonal molt found in other feather tracts. In contrast to the classic presentation just described, some birds have substantial involvement of the flight, tail and crest feathers, with only minimal changes in the powder down feathers.^{187,271,309}

Clinical changes in the beak and oral mucosa of PBF D-positive birds are characterized by progressive elongation, transverse or longitudinal fractures, palatine necrosis and oral ulceration (Color 32.11).^{187,309,317} Necrosis of the upper beak progresses proximally to the palatine area and may involve the premaxilla in severe cases. The distal end of the lower beak is less severely involved.¹⁸⁷ If the powder down feathers in cockatoos are dystrophic, the beak may appear to be semi-gloss or gloss black, instead of its normal grey color. The beak may elongate or show transverse delamination or fractures, with or without bacterial or fungal infections in the clefts (see Figure 19.5). Necrosis of the palatine may follow. Likewise, deformities, fractures, necrosis and sloughing of the nails can be seen occasionally.²³⁰

Classically, beak deformities develop in birds following a protracted course of PBF D where substantial feather changes have occurred; however, some individuals develop severe beak lesions with relatively minor feather pathology, and cracking of the hard corneum at the distal portion of the beak may be the initial complaint requiring veterinary attention.^{187,309,317}

Depending on the avian species involved and other factors that remain unresolved, beak changes may or may not be present. In one study involving 22 cockatoos of mixed Asian origin, birds older than one year of age had a lower incidence of beak lesions than did birds that were under one year of age.¹⁸⁷ Beak pathology does not routinely occur with some affected species, while with others, such as the Sulphur-crested Cockatoo, Rose-breasted Cockatoo, Bare-eyed Cockatoo and Moluccan Cockatoo, beak lesions are relatively common.^{187,271,309,316,317}

Pathology

Gross feather and beak changes associated with PBF D are described under clinical features. Predominant histologic lesions have been described in

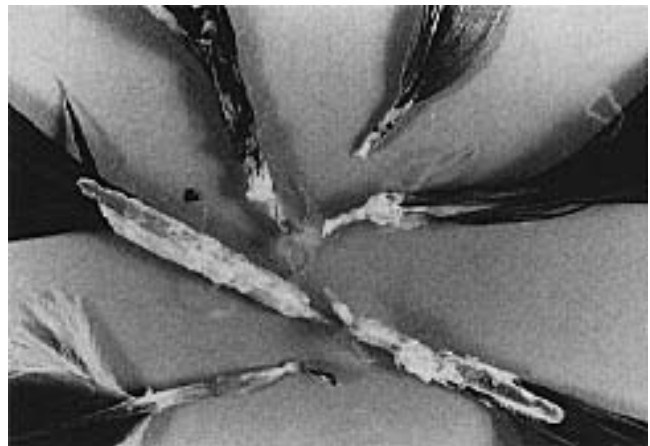


FIG 32.19 Feather lesions suggestive of PBF D virus include retention of the feather sheaths, hemorrhage within the pulp cavity, fractures of the proximal rachis and failure of the developing feather to exsheath; however, it must be stressed that any damage to the follicular epithelium can cause a similar appearing gross lesion. DNA probe testing (whole blood) or feather biopsy is necessary to confirm a diagnosis. Polyomaviral, adenoviral, bacterial and fungal folliculitis can cause similar lesions.

the feather shaft, where necrosis and ballooning degeneration of epithelial cells in the epidermal collar and epidermal, basal and intermediate zones of the developing rachis are seen.^{187,229,271,309,317} The follicular epithelium may also be necrotic, but this lesion is less commonly reported.²²⁹ Feather sheath hyperkeratosis prevents the feather from exsheathing and results in the terminal clubbing and midshaft constrictions of the developing feather, which are clinically evident.¹⁸⁷ Feather pulp lesions are characterized by suppurative inflammation, including perivascular accumulations of heterophils, plasma cells, macrophages and rarely lymphocytes. Granulomatous dermatitis with vesicle formation was described in a group of infected lovebirds.³⁰⁵

In peracute cases, histologic lesions may be limited to severe bursal or thymic necrosis with the presence of viral-induced inclusion bodies. Feather pathology in these cases may not occur, or may be limited to edema in the follicular epithelium (if present).^{187,229,271,306}

Histologic lesions in the beak of PBF D birds are similar to those described in their feathers, including necrosis and hyperplasia of epithelial cells in the basal and intermediate epithelial layers. Hyperkeratosis and separation of the cornified outer layer from the underlying tissues and bone may also be evident, and are often accompanied by secondary necrosis and osteitis of associated tissues.^{187,271,306,309}

In birds with beak pathology, necrosis and inflammation of the epithelial lining of the tongue, beak cavity and crop have also been reported.^{187,306,317} Secondary gram-negative bacteria and fungi are commonly isolated from beak lesions and may be associated with acute or chronic inflammatory reactions.^{187,306,309,316}

At necropsy, internal lesions are variable and differ with age and the type of secondary infection. In young birds, the cloacal bursa may be small with poorly developed folds and the thymus may reveal small lobes with pale necrotic tissue. In mature birds the spleen is frequently small and depleted of lymphocytes, and occasionally necrosis of the reticular cells can be observed. Extracutaneous inclusions demonstrated to be PBFD virus were found mainly in macrophages in the beak, palate, esophagus, crop, nail, tongue, parathyroid gland, bone marrow, Kupffer's star cells of the liver, spleen and thyroid gland. In the intestinal tract inclusion bodies were mainly found in epithelial cells.²³²

Inclusion Bodies

Basophilic intranuclear and intracytoplasmic inclusion bodies have been consistently demonstrated by hematoxylin and eosin staining in sections of the feathers, beak, thymus and bursa taken from birds with clinical signs of PBFD.^{187,229,271,306,317} Immunohistochemical staining with viral-specific antibodies was used to confirm that intracytoplasmic basophilic inclusion bodies and some intranuclear inclusion bodies observed in hematoxylin and eosin-stained tissue sections contain PBFD viral antigen (Color 32.7).²³²

Intracytoplasmic inclusion bodies have been reported to be more consistently demonstrated, particularly in early cases, than are intranuclear inclusion bodies.^{187,271} Intranuclear and intracytoplasmic inclusion bodies were identified in 23 of 32 birds examined in one study. In this group, intranuclear inclusion bodies were restricted to epithelial cells, and intracytoplasmic inclusion bodies were found only within macrophages.²²⁹ Inclusion bodies have not been demonstrated in feather or beak samples taken from clinically normal birds.^{187,271,306,309}

In addition to being localized in the feather and follicle epithelium and lymphatic tissues, PBFD viral inclusion bodies have also been demonstrated by viral-specific antibody staining in the beak, hard palate, bursa, thymus, tongue, parathyroid gland, crop, esophagus, spleen, intestines, bone marrow, liver, thyroid and adrenal glands.²³²

Intracytoplasmic inclusions are thought to originate in epidermal cells and attain their greatest size within macrophages, which engulf these infected cells.^{187,229,306,309} It has been postulated that PBFD virus replicates in the nuclei of infected epidermal cells, and inclusions are then released when necrotic cells are phagocytized by macrophage-like cells in the pulp and epidermis,^{187,232,309} however, the occurrence of viral antigen within macrophages in the bone marrow and within circulating monocytes suggests that these cells may be directly infected (Color 32.6).

Diagnosis

Feather lesions that appear grossly similar can be caused by PBFD virus and avian polyomavirus. Feather lesions seen with polyomavirus typically resolve after one or two molts whereas PBFD lesions as a rule progress from molt to molt. Dual infections with PBFD virus and polyomavirus do occur. Noninfectious causes of similarly appearing feather lesions include nutritional deficiencies, endocrine abnormalities and drug reactions.

PBFD should be suspected in any psittacine bird with progressive feather loss involving malformed feathers. A tentative diagnosis of PBFD involves the identification of basophilic intracytoplasmic or intranuclear inclusion bodies in the feather pulp or follicular epithelium from birds with clinical signs of dystrophic, nonviable feathers.^{187,229,271,306,316} Basophilic intracytoplasmic inclusion bodies are considered diagnostic. Because several viruses may result in similarly appearing intranuclear inclusion bodies, a confirmatory diagnosis of PBFD requires the use of viral-specific antibodies to demonstrate PBFD virus antigen or the use of DNA probes to detect PBFD virus nucleic acid (Colors 32.6, 32.7).^{230,341} Viral-specific DNA probes are most sensitive for detecting PBFD virus and can be used on biopsy samples to confirm an infection or on blood samples from a live bird to detect viremia (Color 32.6).

PBFD virus has hemagglutination activity for cockatoo and guinea pig, but not chicken or sheep erythrocytes. The HA test can be used to demonstrate and quantify the amount of virus recovered from PBFD-positive birds. The hemagglutination-inhibition (HI) test was found to provide a rapid, specific technique to assess the immunologic response of psittacine birds to the PBFD virus (see Figure 32.2). Precipitating antibodies can be demonstrated using an agar-gel immunodiffusion test (see Figure 32.1).³⁴⁰ A suitable culture system for the PBFD virus has yet to be discovered.

The recommended sample to submit for DNA probe detection of active or subclinical (birds that are showing no feather abnormalities) infections is whole anticoagulated blood (0.2 to 1.0 ml of blood in heparin). In addition, in birds that have feather abnormalities, biopsy samples of diseased feathers should be placed in 10% formalin and held for further diagnostic testing should any be needed.

Therapy

Numerous therapeutic trials have been attempted for PBFD virus-infected birds. Recoveries have been reported principally in birds with only intranuclear inclusion bodies. While feather lesions can be tolerated as long as the animal is kept in a controlled environment, beak lesions (also nail lesions) can be painful, particularly when secondarily infected. Euthanasia is suggested under these conditions. Secondary infections should be treated accordingly, and special examinations for cryptosporidiosis might be indicated.²³¹

Control

The chicken anemia agent (CAA), which is similar in ultrastructure and DNA composition to the PBFD virus, has been found to be environmentally stable, and infectivity remains unchanged when the virus is heated to 60°C for one hour and following treatment with detergents, enzymes and many commercial disinfectants.⁴⁴⁶ While the environmental stability of the PBFD virus is unknown, it would be prudent to consider its stability to be similar to that described for CAA. Psittacine neonates, which seem to be most susceptible to the PBFD virus, should definitely not be exposed to areas that may have been contaminated by feces or feather dust from a PBFD-positive bird.^{339,342,443}

A DNA probe for PBFD virus provides the best technique available for controlling infections until a vaccine is available (see Chapter 6). In an effort to reduce the number of cases of PBFD, all birds of a susceptible species should be tested to determine if they are latently infected with the PBFD virus. This is particularly true with respect to breeding birds, birds being sent to pet shops and birds being evaluated during post-purchase examinations. The test is simple, inexpensive and relatively noninvasive.

The DNA probe can also be used to screen walls, caging, air circulating ducts and equipment in the home or hospital to determine if PBFD virus is contaminating these surfaces. The appropriate sample for this test is a swab collected from the test location.

A negative DNA probe test for PBFD virus indicates that viral nucleic acid was not detected in the submitted sample. A positive DNA probe test for PBFD virus indicates that viral nucleic acid has been detected in the submitted sample. A positive test in a bird that has feather abnormalities suggests that the bird has an active PBFD viral infection. A positive blood test in a bird that does not have feather abnormalities may indicate that the bird is latently infected or that it recently has been exposed to the PBFD virus and is viremic. A bird that tests positive and has no feather abnormalities must be retested in 90 days. If the bird is still positive, then it should be considered to be latently infected. A negative test 90 days later would indicate that the viral nucleic acid was no longer detected in the blood and that the bird has probably eliminated the virus.

A companion bird that is diagnosed as a PBFD virus carrier can live a long life when provided a stressor-free environment and supportive medical care. These birds should be restricted from contact with other susceptible birds, particularly neonates. PBFD virus-infected birds should not be maintained in breeding facilities or where they may expose susceptible neonates or adults. Infected birds should be removed from the breeding collection and nursery immediately (see Figure 30.21).

It has been suggested by one author that this disease can be eradicated from a collection by removing patients with clinical signs of disease;¹³⁴ however, in the same discussion, this author mentions that the virus may have a two- to three-year incubation period, and that the virus genome can be detected in cells from clinically asymptomatic birds (carrier state). It is obvious that these conclusions are contradictory, and true eradication can be achieved only by testing for carriers.

High HI and precipitating antibody titers can be induced by injecting birds with beta-propiolactone-treated PBFD virus by the intramuscular or subcutaneous routes (Table 32.12). Immunized hens pass maternally derived antibodies to their chicks that offer at least temporary immunity to the virus (Color 32.5).

Because PBFD appears to be restricted in host range to psittacine birds and most of these birds are restricted to enclosures, it is likely that a widespread and continued testing and vaccination program can be used to control this disease in companion birds.

TABLE 32.12 Post-vaccination PBF D Titers

Species	Age	0	21
Moluccan Cockatoo	Adult	640/10	5120/80
Umbrella Cockatoo	Adult	160/1	5120/80
African Grey Parrot	Adult	320/0	5120/80
Moluccan Cockatoo	Adult	160/1	1280/10
Umbrella Cockatoo	Adult	80/0	1280/80
Umbrella Cockatoo	Adult	320/1	2560/80
Umbrella Cockatoo	Adult	80/1	2560/10
Amazon parrot	Adult	320/0	2560/10
African Grey Parrot	Adult	160/0	5120/80
Umbrella Cockatoo	45 days	<40/0	1280/0
Sulphur-crested Cockatoo	45 days	80/0	2560/0
African Grey Parrot	45 days	160/0	5120/0
African Grey Parrot	45 days	80/0	2560/0
African Grey Parrot	30 days	640/0	5120/0
African Grey Parrot	30 days	640/0	2560/0

Hemagglutination inhibition (HI) and precipitating antibody titers before and 21 days after vaccination with B-propionolactone-treated PBF D virus. Titers are listed as HI/precipitating.³⁴⁰

Adenovirus

The Adenoviridae family consists of two genera: Mastadenovirus (contains mammalian strains) and Aviadenovirus. The two genera have a distinct group antigen. Most mastadenovirus strains have hemagglutination activity; most aviadenovirus strains do not. Aviadenovirus are divided into three groups according to common group antigens as detected by virus neutralization, growth in cell culture and nucleic acid characteristics.^{267,419,449}

Group I: Fowl adenovirus (FAV) consists of 12 serotypes (numbered 1-12) that have been isolated from chickens, turkeys (3 serotypes), pigeons, budgerigars, Mallard Ducks, guineafowl, pheasants, geese (3 serotypes) and Muscovy Ducks.^{43,51,264,265,304,449}

Group II: Turkey hemorrhagic enteritis virus, marble spleen disease virus and chicken splenomegaly virus. The common group antigen is distinct from that of group I.

Group III: contains only the virus associated with infectious salpingitis (Galliformes) and a similar virus isolated from ducks (see Color 29). This virus

subtype shares some common antigenic sites with group I adenoviruses. This group of aviadenoviruses has hemagglutination activity.

Adenovirus particles are 70 to 90 nm, nonenveloped and contain double-stranded DNA. Virions are icosahedral and are composed of 252 capsomeres arranged in triangular facets with six capsomeres along each edge. There are 240 nonvertex capsomeres (hexons) and 12 vertex capsomeres (penton bases). The latter contain projections (called fibers). Members of Aviadenovirus group III contain one fiber and group I has two fibers (one long and one small). There appears to be a relative relationship between the length of the fibers and the antigenicity of the virus.^{109,267}

Adenovirus replicates in the nucleus producing basophilic intranuclear inclusions. The strains have been divided into two subgroups, A and B, on the basis of their cytopathogenicity (the same as with human strains): Subgroup A (eg, FAV 1, FAV 2, FAV 4, FAV 5, FAV 8); Subgroup B (eg, FAV 5, FAV 6, FAV 7, FAV 9, Turkey [TAV] 1, TAV 2.). The differentiation in subgroups A and B may also reflect some differences in pathogenicity. Subgroup A viruses induce refractive, small, roundish inclusions surrounded by a clear halo and tend to cause persistent infections with sporadic disease. Subgroup B viruses induce nonrefractive, irregular, eosinophilic inclusions that fill the nucleus and may cause epornitics, with a tendency not to persist in the host.

Aviadenovirus are distributed around the world, and many avian species of all age groups are known to be susceptible. Because the isolation of previously uncharacterized aviadenovirus is to be expected, it is likely that the current host range is incomplete.

Transmission

Transmission is known to occur through the oral route, and inhalation is suspected. The virus is excreted mainly in the feces. Latently infected birds experience cyclic changes of the amount of humoral antibodies and virus titers and vice versa. Egg transmission plays a role in the maintenance of infections in a flock. A breeder hen may pass either virus or antibodies to the egg. The primary change in infected eggs is reduced hatchability.

Pathogenesis

Infection with aviadenovirus does not necessarily produce clinical disease, although defined diseases have been characterized, and variability in virulence is known to occur. The factors that govern virulence





FIG 32.20 A Moluccan Cockatoo was presented with a progressive neurologic disease characterized by ataxia, tremors, head pressing and death. Intranuclear inclusion bodies suggestive of adenovirus were demonstrated by histopathology (see Color 32.13).

have not been conclusively defined; however, in addition to intrinsic damage caused by virus replication in the cells, the structural proteins of the pentons are thought to be directly toxic to host cells. During the lytic cycle of many adenoviral infections, host synthesis of macromolecules (cellular DNA, various proteins, mRNA) stops causing the host cells to die.¹⁷⁷

Aviadenovirus is generally considered to be an opportunistic pathogen. Identified triggering factors in chickens include immunosuppression caused by infectious bursal disease and the chicken anemia virus.²⁶⁷ Reoviridae have been implicated as factors in nondomesticated avian species. Some highly virulent strains of aviadenovirus are capable of producing disease alone (hydropericardium syndrome). Aviadenovirus can trigger secondary infections by inducing mild histopathologic lesions without clinical signs. Common microscopic lesions are degeneration of hepatocytes, enterocytes and respiratory epithelial cells. These lesions allow secondary bacteria, fungi and protozoa to enter the host. Parvoviruses that require an adenovirus for replication have decreased *in vitro* growth and pathogenicity.^{29,267}

Clinical Disease and Pathology - Group I

Many avian species are known or are suspected to harbor adenovirus. A large number of strains have not been typed and in many instances, the etiologic importance of the virus is unknown. Group I strains have been associated with respiratory signs, anemia, inclusion body hepatitis, intestinal disease, pancreatitis and nephropathies. Histopathologic lesions without clinical signs are also common. The majority of aviadenovirus infections may be latent and subclinical. In other cases, adenoviruses have been iso-

lated or detected by inclusion bodies or electron microscopy from birds with CNS signs (Figure 32.20) (Color 32.13).¹⁴³

Gross lesions are nonspecific including tracheitis, swelling of the liver or kidneys and catarrhal enteritis. Histopathology reveals mononuclear cellular infiltrates in the lamina propria of the trachea, hypertrophy of the mucosal glands and finally loss of the epithelium. Liver lesions vary with the virulence of the strain, but may include vacuolated degeneration of the hepatocytic cytoplasm with lymphocytic infiltration in Glisson's triangles. In more severe cases, hepatocytes show intranuclear eosinophilic inclusions, which increase in size and become basophilic before developing a halo around the inclusion. In the pancreas, irregular necrosis, mainly of the exogenic cells, with and without intranuclear inclusions, has been described.¹⁴³ It should be emphasized that in avian species, inflammatory lesions generally develop more slowly than in mammals, and in many cases death occurs prior to inflammation so that hepatitis and enteritis may not occur.

Species-specific Considerations

- **Guineafowl:** FAV 1 is the principal isolate and will experimentally cause disease. The main lesion is necrotic pancreatitis, but some respiratory signs (air sacculitis) also occur. Intracerebral infections induce clonic-tonic type CNS signs. Young chicks are highly susceptible. Older birds are more resistant, and disease has been established only by parenteral routes.^{304,329,447}
- **Japanese Quail:** An adenovirus was isolated from chicks with CNS signs. The strain could not be se-

rologically typed, but nucleic acid analysis showed that it is closely related to FAV 4.²⁴³

- **Quail Bronchitis (QB):** Quail bronchitis virus was first described in 1950 and only Bobwhite Quail (captive and free-ranging) are susceptible.²⁹⁷ Mortality can reach 90% in young birds up to six weeks of age. Older quail show an age-linked resistance. The virus is serologically related to FAV 1, but nucleic acid sequences are different.²⁴³ These nucleic acid differences might be the cause of an adaptation to Bobwhite Quail, a slow replication in chicken tissue and the failure of vaccination with CELO-type vaccines.

QB is highly infectious and spreads to young quail mainly through direct contact. Vertical transmission should be expected, although this route has not yet been confirmed.

Clinical signs include sudden death or signs of respiratory disease, such as tracheal rales, coughing, ballooning skin over the infraorbital sinus, sneezing, increased lacrimation and conjunctivitis. The severity of disease depends on the age of the host, and milder signs may be observed in birds older than three weeks. Gross lesions may not occur or can include catarrhal tracheitis with an excess of clear mucus in the air sacs or pulmonary edema.^{143,186,432} Hepatic necrosis has been described.²¹⁴ Intranuclear inclusion bodies suggestive of adenovirus may be seen in the tracheal epithelium two to five days post-infection as well as in the epithelial cells of the bronchi. Proliferation of lymph follicles and lymphocytic infiltrations are evident.

- **Pigeons:** FAV 8 has been isolated from pigeons, and other reports have suggested infections based on histologic lesions from cases in which virus could not be isolated.^{121,265} Virus particles morphologically suggestive of adenovirus have been reported in the nuclei of hepatocytes from pigeons although the typical paracrystalline arrays could not be demonstrated. The adenovirus failed to grow in culture but reovirus was isolated.¹²⁰ Pigeon herpesvirus has also been isolated from birds suspected of having adenovirus, suggesting that the role of FAV strains in causing inclusion body hepatitis and inclusion body enteritis in pigeons requires further documentation.^{265,411} An FAV strain isolated from pigeons²⁶⁷ did not cause lesions in chickens following experimental infection.²⁵⁹

Pigeons have been described with clinical signs of anorexia, a “crouching position” for one to two days, ruffled plumage, slimy green droppings, polydipsia,

polyuria, watery overload of the crop, vomiting and respiratory distress.⁸⁰ At necropsy, affected birds had hepatomegaly and splenomegaly, with the former being friable and mottled. In one case, the only lesion was swelling of the respiratory tract mucosa and in another, hemorrhagic enteritis and ecchymosis in the liver were observed. Histopathologically, liver degeneration or coagulative necrosis with basophilic intranuclear inclusion bodies was the main lesion. The kidneys sometimes showed degeneration of the tubular epithelium. In one case, intranuclear inclusions were also found in the pancreas.

Six strains of an adenovirus were recovered from these birds, four of which were serologically related to chicken adenovirus, and two of which could not be serologically typed. Interestingly, these strains were isolated from the pigeons with atypical macroscopic lesions.

A chronic enteritis was described in mainly young pigeons with some adults affected.³⁶ Diarrhea and lethargy were the main clinical signs. Necropsy lesions were nonspecific. Histopathologically, club-shaped, damaged villi in the duodenum and jejunum became vacuolated, pycnotic and desquamated. Intranuclear inclusion bodies containing adeno-like virus particles (basophilic and in part eosinophilic) may be seen in apical and medial enterocytes. Lymphocytic, heterophilic infiltrates occur in the intestine, liver and other parenchymatous organs.

Differences in clinical signs and pathology associated with adenovirus infections in pigeons suggest that more than one virus with varied organ affinity may infect these birds. Further studies are needed to elucidate the importance of adenovirus in pigeons.

- **Goshawk:** FAV 1 was isolated from a free-ranging Goshawk that experienced clonic-tonic type CNS signs and died shortly after being recovered from the wild. The brain showed neuronal necrosis, satellitosis and proliferation of glial cells.³⁹⁶ Adenovirus was suspected in a captive American Kestrel with hemorrhagic enteritis and in a Merlin with hepatitis.³⁷⁹
- **Psittaciformes:** Clinical and histopathologic lesions suggestive of adenovirus infections have been described in several members of the order.

Pancreatitis and nephropathies have been the two main lesions described in lovebirds. Gross necropsy findings were enlargement of the proventriculus and the duodenum. Acute necrotizing pancreatitis with large basophilic intranuclear inclusion bodies in the

exocrine cells was the main histopathologic lesion. Similar inclusions were described in enterocytes. Adenovirus (serotype not reported) was isolated from Nyassa Lovebirds with inclusions in hepatocytes and splenocytes.^{132,143}

Adenovirus-like intranuclear inclusions have also been described in the otherwise normal renal tubular epithelium of clinically normal lovebirds. In other birds, numerous inclusions were associated with tubular necrosis and subacute interstitial nephritis.²⁴⁶ Renal lesions were also described in Masked Lovebirds with a severe edematous conjunctivitis (30% mortality).¹⁸⁹ The endothelial cells of the conjunctiva and renal epithelium contained inclusion bodies suggestive of adenovirus. Inclusions in the renal tubules have been shown to be located also within the rami ureterici.²⁸⁰

Adenovirus-like particles have been connected with acute onsets of mild diarrhea and lethargy in Eclectus Parrots. Hepatitis with subcapsular hemorrhage and enteritis (in some birds hemorrhagic) were the main lesions. Inclusions were evident in hepatocytes and enterocytes together with diffuse inflammatory invasion of the intestinal mucosa. Irregular, discrete interstitial pneumonia and rapid death were also described.³²⁶

Basophilic intranuclear inclusions were observed mainly in enterocytes of *Pionus* spp. and *Neophema* spp. with persistent torticollis and other CNS signs.²⁴⁷ Clinical changes were similar to those described with paramyxovirus infections. Lymphoplasmacytic meningoencephalomyelitis and pancreatitis were the main histologic lesions.

Adenovirus was isolated from two budgerigars with individual histories of enteritis and sudden death.²⁶⁵ An adenovirus epizootic of one year's duration was described in budgerigars, generally adults one to three years old, in Germany. Clinical signs included acute torticollis, opisthotonus, tremor and convulsions. Birds that were able to maintain sufficient orientation to eat and drink usually survived. Gross lesions were unremarkable. Nonpurulent encephalitis, proliferation of glial cells and degeneration and lysis of ganglion cells were the principle histologic lesions. Nonspecific hepatitis with infiltration of mononuclear cells was evident in prolonged cases. Adenovirus was isolated from two affected birds. One isolate was serologically related to FAV 2 and FAV 11, and the other to FAV 4.¹⁰⁷

Restriction enzyme analysis of the DNA from these isolates revealed similarities to other FAV isolates; however, the budgerigar strains were found to contain unique nucleic acid sequences. Experimental infections resulted in the induction of histopathologic lesions in the absence of clinical disease. Adenovirus-like particles were demonstrated by electron microscopy in large basophilic intranuclear inclusion bodies in the hepatocytes of cockatiels with enlarged necrotic livers.³⁷²

An epizootic of adenovirus-induced hepatitis has been described in a group of Psittaciformes in a collection of zoo birds.⁴⁷ Affected birds included Green-cheeked Amazon, Patagonian Conure, Eastern Rosella, Hyacinth Macaw and a Lesser Sulphur-crested Cockatoo. Hepatitis and enteritis suspected to be caused by adenovirus has been described in Moluccan and Rose-breasted Cockatoos. Adenovirus was described as the cause of acute pancreatic necrosis in an Umbrella Cockatoo.^{122,305a,320a}

- **Waterfowl:** An epornitic of adenovirus was described in captive Muscovy ducklings in France. Affected animals were lame and emaciated. Birds began to die suddenly at about 35 days of age, and mortality rates averaged 1 to 1.5% of the flock daily for about ten days. A serologically distinct adenovirus was isolated from affected birds.⁴³ Tracheitis (diphtheroid) accompanied in some cases by bronchitis and pneumonia was described in 10% of two- to three-week-old Muscovy ducklings in another outbreak. Adenovirus-like particles were located within the epithelial cells of the trachea.³⁷

Three serotypes of adenovirus have been described in goslings;⁴⁴⁹ but virus isolated from the cases did not produce clinical or pathologic lesions in experimentally infected birds. Inclusion body hepatitis was described in goslings with high mortality and adenovirus-like particles in the nuclei of the hepatocytes.³³⁵ Adenovirus-like inclusion bodies have been found in hepatocytes of free-ranging Herring Gulls²³⁵ and the Tawny Frogmouth.³²⁸

Diagnosis

A definitive diagnosis based on clinical or pathologic changes is not possible. Virus isolation is best achieved from the feces, pharynx, kidneys and liver. Chicken embryo liver or kidney cells and embryonated chicken eggs are suitable for recovering FAV 1 (chickens). Serotypes can be identified using VN or plaque reduction assays. Adenovirus-specific DNA probes have been developed for demonstrating viral

nucleic acid in infected tissues and clinical samples (Niagro FD, unpublished).

Group-specific antibodies can be demonstrated by ID and ELISA. The presence of antibodies indicates that an infection has occurred but does not indicate what part, if any, an Aviadenovirus may have played in a disease process. Histopathology, together with *in situ* hybridization, electron microscopy or virus isolation are necessary for this differentiation. With the number of adenovirus serotypes, a monovalent vaccine would be of questionable value. Vertical transmission and the continuous cycle of viremia followed by antibody production in infected birds makes it exceedingly difficult to produce uninfected offspring.

■ Group II

The adenovirus that cause hemorrhagic enteritis in turkeys, marble spleen disease (MSD) in pheasants (captive birds only, not documented in free-ranging birds), and chicken adenovirus group II splenomegaly are considered serologically identical;^{78,185} however, restriction endonucleases can be used to show that there are genetic differences between the viruses isolated from varying hosts.^{78,448}

In the Common Pheasant, MSD virus replicates mainly in reticular cells of the spleen. Young birds are most frequently infected between ten to twelve weeks of age. Acute death may occur without clinical signs or preceded by a brief period of anorexia and dyspnea caused by severe pulmonary edema. Grossly, the spleen may be enlarged two to three times its normal size and is frequently mottled with multiple, grayish, confluent foci. The lung may be congested, edematous and in rare cases, hemorrhagic. Histopathologically, the spleen shows a distinct lymphoreticular hyperplasia with intranuclear inclusion bodies in RES cells (also in liver, lung and proventriculus).¹⁴³ Extensive deposits of a slightly fibrinous material (moderately PAS-positive) may be present. These deposits are considered to be amyloid.^{185,442} Multiple small foci of necrosis may be present in epithelial and endothelial cells in the lungs.

Suspected adenovirus infections in White and Pearl Guinea fowl are characterized by acute pulmonary edema, splenomegaly and ascites. The postmortem and histopathologic findings resemble those seen with MSD and avian adenovirus group II splenomegaly in chickens. Suggestive intranuclear inclusion bodies may be seen in hepatocytes, splenocytes and pneumocytes. Antigen could not be demon-

strated by cultural and serologic methods. Pearl Guinea fowl experimentally infected with pheasant or turkey group II adenovirus developed lesions that were identical to those described in a natural outbreak.⁶⁶

■ Diagnosis

The clinical and pathologic signs are suggestive of the disease. The principal rule-outs are various intoxications and reticuloendotheliosis. The virus is difficult to demonstrate in culture (lymphoblastoid B-cells derived from Marek-induced tumors are best for isolation). The agent forms intranuclear inclusion bodies, particularly in splenic cells, and the presence of viral particles consistent with adenovirus can be demonstrated by electron microscopy. Adenovirus-specific DNA probes designed to document infections in Psittaciformes can also be used in pheasants and chickens (Niagro FD, unpublished).

■ Group III

The natural host of adenovirus group III appears to include various ducks from Europe and Asia that are asymptotically infected.^{30,54} In contrast to other aviadenoviruses, group III strains have hemagglutination activity. Serologic evidence suggests group III strains may also infect turkeys, domesticated geese, Muscovy Ducks, chickens and Cattle Egret.^{142,251,267} Like ducks, these hosts appear to become infected without developing clinical or pathologic signs. Adenovirus antibodies were demonstrated in flocks of guinea fowl laying soft-shelled eggs. Similar problems occurred when 86-week-old guinea fowl were infected orally with EDS 76 strain 127 adenovirus.¹⁴¹ Experimental birds seroconverted following infection. Virus recovery is necessary for a definitive diagnosis. Cloacal swabs or material from the female genital tract are good diagnostic samples. HI using virus-specific antibodies can be used to confirm the presence of the virus in a cell culture. Group-specific antibodies cross-react with FAV, and the HI test is best suited for demonstrating group III specific antibodies.²⁷⁹

■ Unclassified

Viral particles suggestive of adenovirus have been demonstrated electron microscopically from captive American Kestrels with hemorrhagic enteritis. The antigen does not react with aviadenovirus group II antibodies. Clinical signs include melena, regenerative anemia and high mortality. Gross lesions include

hyperplasia of the white pulp in the spleen and petechiation in the mucosa of the esophagus, colon and coprodeum. Histopathology reveals diffuse hepatocellular necrosis with two types of intranuclear inclusions: eosinophilic Cowdry type A and basophilic Cowdry type B. In addition, disseminated intravascular thrombi and necrosis of the myocardium may be evident.

A disease that clinically mimics MSD has been described in Blue Grouse. Nonenveloped, 100-110 nm viral particles have been observed in the nuclei of splenocytes. The disease has not been experimentally reproduced and it is uncertain if an adenovirus is involved. Clinical signs are lethargy, ruffled plumage, foamy, watery diarrhea and death. Some birds may develop rales or other respiratory signs. At necropsy, the lungs are dark red and firm, and the spleen is enlarged with whitish foci. The lumen of the intestines may be filled with a brownish, liquid material. Histopathology reveals multifocal fibrinoid necrosis, destruction of lymphocytes and reticular cells with basophilic or eosinophilic inclusions within the nuclei of RES cells. In addition to congestion and edema of the lungs, interstitial pneumonia and fibrinous pleuritis may also be noted.¹⁴³

Parvoviridae

The family Parvoviridae consists of nonenveloped, single-stranded DNA viruses of hexagonal morphology with an estimated 32 capsomeres and a size of 19 to 25 nm. Members of the genus Parvovirus are self-replicating, in contrast to the genus Dependovirus, which require helper viruses. Parvovirus replicates in the nucleus of the host cells and depends on rapidly dividing host cells. Avian parvoviruses induce intranuclear inclusion bodies of the Cowdry A type, and form syncytia in cell cultures. Among others, parvovirus has been associated with disease in chickens and enteropathy in turkeys.^{218,406}

Goose Parvovirus Infection (Derzsy's Disease)

This virus has been associated with all major goose-farming countries in Europe and Asia. The main host is probably the domesticated goose, but the Canada Goose, Snow Goose and Muscovy Duck are also susceptible. Experimental infection is possible in cyg-

nets of the Mute Swan. The virus is strongly host-specific and requires rapidly dividing cells (DNA synthesis) to replicate. Currently, the virus is considered serologically uniform.

Transmission and Pathogenesis

This virus is highly infectious, and transmission is possible horizontally via oral and nasal routes and transovarially by freshly infected, non-immune breeder geese. Latent infections in adults is epizootologically important. Non-immune goslings or Muscovy ducklings between 1 to 21 days of age are most susceptible to infection. In older birds (two to ten weeks), infections are characterized by mild, protracted signs or are subclinical and latent. Following entry into the host, virus is distributed to the target organs including the liver, spleen, heart, adrenal gland, thyroid gland and thymus. Therefore, viremia is normally not demonstrable. Virus is shed from the fifth to sixth day following infection, and shedding may persist in some individuals for approximately six months. The intensity, course and mortality rate of the disease is governed by maternal immunity; however, age-related resistance is independent of humoral antibodies beyond the age of four to six weeks. The half-life of the maternal antibodies is between two and one-half to three days.³⁶⁰

Clinical Disease and Pathology

Anorexia and polydipsia followed by cessation of water intake are the earliest clinical signs. Goslings appear chilled and occasionally develop conjunctivitis, diarrhea and diphtheroid membranes on the tongue. Somnolence, weakness and giddiness occur prior to death (up to 100% mortality). In older birds that survive, down feathers may fall out, particularly on the neck, wings and back. The skin may be hyperemic and the uropygial gland swollen. The chronic disease is characterized by growth retardation, difficulties in standing or walking and occasionally, convulsions. An accumulation of ascitic fluid may cause a penguin-like posture. Newly developing feathers may be brittle.^{123,143,359}

Clinical and pathologic signs may be influenced by the age and immune status of the host as well as concomitant infections with other goose viruses (see reovirus or "nephroenteritis") or opportunistic pathogens including bacteria, *Mycoplasma* spp. and fungi.

Gross lesions include hepatomegaly with subcapsular petechial hemorrhage and bile congestion together with a small, limp spleen and a highly enlarged thyroid gland. Chronic disease can cause the

formation of serofibrinous fluid in the abdominal cavity. Hemorrhagic fibrinous enteritis, pin head-sized necrotic foci in the pancreas, hemorrhage within the cloacal bursa, degeneration of the myocardium and viscous mucus in the nasal cavity and on the surface of the proventriculus may be noted.¹⁴⁶

Histopathology reveals a serous hepatitis with necrosis of the hepatocytes and intranuclear inclusion bodies, which can stain eosinophilic or basophilic with HE. Perivascular infiltrations of inflammatory cells occur in prolonged cases and occasionally proliferations of connective tissue occur. Necrosis of the pancreas and edema of the lung are typical of the acute disease. Hyperactive follicular epithelium with a large quantity of cytoplasm and large, lightly colored nuclei are common in the thyroid gland. The follicles are either completely filled with colloid or empty. Bud-like proliferation of the epithelium can be seen at certain sites. There is no interstitial cellular reaction with inflammatory cells. Lesions in the myocardium including degeneration with loss of the striation and interstitial edema, especially around the capillaries, are common with chronic disease. An increase in histiocytes and lymphocytes can be observed in these areas.¹⁴⁶

Diagnosis

Liver, pancreas and thyroid glands are suitable material for virus isolation. Virus identification can be carried out with VN, ELISA or IF. Latently infected birds can be identified by demonstrating humoral antibodies. Antibodies appear five to ten days following infection and persist for approximately one year. Persistent titers indicate that the animal in question is a carrier or has been exposed.

Clinical signs associated with parvovirus in goslings are similar to those caused by reovirus and nephroenteritis, but the three diseases can be differentiated. Because mixed infections are possible, virus isolation might be necessary to clarify the inciting organisms. Reovirus infection of goslings causes predominantly respiratory signs and changes on the cutaneous mucosa and striated muscles (including heart muscle). Parvovirus infection of the gosling is a hepatic disease (with intranuclear inclusion bodies), small spleen and changes in the thyroid gland. Nephroenteritis of the gosling occurs later in life than the other two diseases and is characterized by hemorrhagic nephritis and enteritis.^{123,359,407}

Control

Because maternal antibodies successfully prevent the disease in goslings, vaccination of the breeder geese at least six weeks before the beginning of egg production is recommended. An attenuated strain, which is actually an apathogenic mutant, is available as a vaccine. This strain is effective only when given intramuscularly.²¹⁷ Breeding geese without antibody titers should be vaccinated twice. A booster vaccination might be necessary for the second half of the breeding season to prevent hepatitis in goslings hatched late in the breeding season.

Myocarditis and Encephalopathy in Canaries

Myocarditis and encephalitis were described in association with a virus that morphologically resembled parvovirus in three adult canaries from different origins. It is unusual, however, that a parvovirus would cause disease in an adult bird.¹⁶⁸

The clinical picture was different among affected birds and ranged from sudden death to depression, emaciation and ruffled plumage. Some birds had no gross lesions while others had splenomegaly (three times normal size). Histopathology revealed nonsuppurative myocarditis with intranuclear eosinophilic inclusion bodies. Neurons in the brain stem contained similar inclusions, but there was no inflammatory reaction in the brain. The enlarged spleen of one bird showed increased numbers of macrophages and amyloid deposits.¹⁶⁸

Hepadnaviridae

The Hepadnaviridae virion is 40 to 60 nm in diameter with an icosahedric, enveloped, symmetric nucleocapsid consisting of one highly immunogenic protein. The virus contains partially double-stranded circular DNA.^{368,430}

Closely related taxons of Orthohepadnavirus (formerly hepatitis B virus) have been recovered from humans, ground squirrels, woodchucks and tree squirrels. Related avian taxons (formerly duck hepatitis B group now in the newly formed genus Avihepadnavirus) have been described in the Pekin Duck and domestic goose.^{177a} Another strain has been recovered from the Grey Heron. Avihepadnavirus is

strongly host-specific, and infected birds should pose no danger to humans. Avihepadnavirus is less oncogenic than mammalian strains. It has been suggested that avian strains require co-carcinogenic factors to induce neoplasms. One of those hypothetical co-carcinogens could be, for instance, high doses of aflatoxins.³⁹³ Infection with Avihepadnavirus is a triggering factor for clinical and pathologic changes of the new duck syndrome (see Chapter 33).

The Avihepadnavirus are distributed worldwide in commercial duck and goose farms. Generally, infections are subclinical in ducks and geese. Transmission takes place vertically and leads to chronic viremia without the development of humoral antibodies. This pathogenesis is different from human infections in which lesions are partially induced by the elimination of virus-infected cells by the immune system. This mechanism explains why experimentally infected ducks can develop mild hepatic lesions. The Grey Heron strains are different but related to duck and goose strains.

Infected birds with chronic viremia have extremely high viral titers (10^{11} particles/ml serum) so that the virus is directly demonstrable without enrichment procedures.⁴³⁰ Demonstration of antibodies in birds with vertically derived infections is not possible. Serum and egg yolk are suitable material for diagnosis.

Reoviridae

The family Reoviridae consists of three genera: Orthoreovirus,^{176a} Orbivirus and Rotavirus.

Avian Orthoreovirus

Members of the genus Orthoreovirus are divided into mammalian or avian strains. Orthoreovirus virions are nonenveloped, icosahedral, double-capsid particles measuring 75 nm in diameter. The genome is a double-stranded RNA segregated into at least three size classes.³⁴⁹ The virus replicates in the cytoplasm of the host cells. Avian orthoreoviruses are serologically different, although most strains share a common antigen, which can be demonstrated by immunodiffusion. Hemagglutination activity is not present in avian strains. Because frequent cross-reactions are reported, it seems that avian orthore-

ovirus strains exist as antigenic subtypes rather than as distinct serotypes.³⁴⁹ At least 11 of these subtypes have been differentiated.

Avian orthoreoviruses occur worldwide; the current host range include chickens, pheasants, quail, turkeys, ducks, geese, pigeons, birds of prey, Psittaciformes and other companion and aviary birds. Two reovirus strains isolated from Muscovy Ducks were found to be closely related to each other, but did not cross-react with a chicken strain (BIII3). One of the isolated strains was found to be virulent for Muscovy ducklings while the other strain was avirulent.¹⁶⁴

Transmission

Ingestion of viral particles is probably an important route of infection, but respiratory transmission is also possible. Vertical transmission is epornitically fundamental in chickens and turkeys and has been proven to occur in Muscovy Ducks and domesticated geese. The methods of transmission for many avian reovirus strains are only speculative. Psittacine birds experimentally infected by IM injection were found to shed virus in the feces two days post-infection, with shedding persisting for 15 days. Pigeons infected orally with reovirus were found to shed virus in the feces two to five days post-infection.

Pathogenicity

Orthoreovirus infections are prevalent in many avian species, but their role in the disease process for most hosts is uncertain. Replication of the virus takes place in the intestinal tract, and the role of orthoreovirus in a variety of enteric conditions in poultry has been discussed.³⁴⁹ The pathogenesis of orthoreovirus infections has not been clearly defined, although strain differences in virulence are known to occur. Many strains may induce latent infections, which may impair the immune system and result in immunosuppression.³⁵⁰ Chicks infected during the first week of life have a depletion of lymphocytes in the cloacal bursa, hyperplasia of various reticular cells and inhibition of lymphocyte immigration as well as hyperplasia of reticular cells in the spleen (Montgomery, unpublished). The occurrence of cryptosporidiosis in Bobwhite Quail infected with orthoreovirus also suggests an immunosuppressed state.^{237,239} Infected chickens develop hypoglycemia presumably caused by lesions in the pancreas.^{112,258}

Development of humoral antibodies may provide protection from the disease; however, fecal shedding occurs in persistently infected birds even though antibody titers are present.^{112,211}

Clinical Disease and Pathology

- Psittaciformes:** The clinical signs reported in Psittaciformes vary among infected hosts. An infected cockatoo (species not given) and Grey-cheeked Parakeet developed non-specific clinical signs including emaciation, incoordination, labored breathing and diarrhea. Reovirus and *Chlamydia* sp., were recovered from the Grey-cheeked Parakeet. Only reovirus was recovered from the cockatoo.²⁷⁸ Enteritis, liver congestion, necrosis and in some cases, a swollen spleen are common pathologic changes in African Grey Parrots (mortality up to 100%), Senegal Parrots, Jardine's Parrots, Alexandrine Parakeets (mortality up to 70%), Rose-ringed Parakeets, Hawk-headed Parrots, Rosy-faced Lovebirds, rosellas (up to 69% mortality) and Yellow-fronted Parakeets.^{61,62,275,423} Chronic respiratory infections have been described in Amazon parrots (Figure 32.21).⁴²³ African Grey Parrots may develop uveitis, although this is rare in uncomplicated reovirus infections.^{61,62} Ophthalmic lesions are characterized by a fixed, dilated pupil and reticular hemorrhages followed by uveitis, hypopyon and fibrous exudates in the anterior and posterior chambers.

It has been suggested that Old World Psittaciformes are highly susceptible to orthoreovirus, while New World Psittaciformes may be infected but are more resistant to disease.⁶¹ Clinical pathology associated with infections include anemia, leucopenia (with 90-100% lymphocytes), hypoalbuminemia, hyperglobulinemia and increased levels of AST and LDH late in the disease process. In many cases, orthoreovirus is not the only infectious agent involved in a disease process, complicating the interpretation of lesions; however, African Grey Parrots have been infected with isolated virus, fulfilling Koch's postulates.¹³³

Necropsy findings in affected cockatoos, African Grey Parrots and other Psittaciformes include exsiccosis, swollen liver, swollen kidneys with urate depositions and splenomegaly.^{61,133} Necrotic foci may be located in the lungs in association with thrombi.

Histopathologic findings include multifocal coagulative necrosis of the liver and occasionally nephritis with infiltrates of macrophages, heterophils and lymphocytes. Similar infiltrates may be noted in the lamina propria of the intestine.²⁷⁸ The spleen is frequently congested with necrosis of the reticular sheaths around blood vessels. Splenic lymphocyte depletion may occur and is probably governed by the chronicity of the infection. The frequent occurrence of

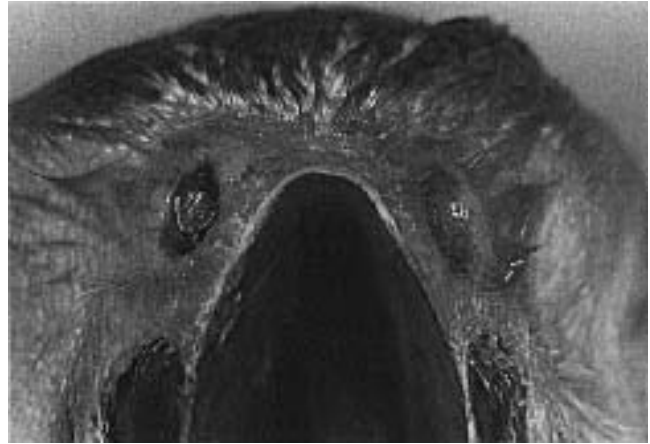

FIG 32.21 Reovirus has been suggested as a cause of chronic respiratory infections in Amazon parrots. Diagnosis requires virus isolation from samples collected from affected respiratory tissues.

thrombi are indicative of a consumptive coagulopathy.¹³³

- Pigeons:** In infected pigeons, the most frequent clinical signs are diarrhea and dyspnea.^{265,370,408} Virus is found mainly in the cloaca, but can occasionally be recovered from the respiratory system. A catarrhal enteritis is a common necropsy finding. A strain isolated from a pigeon liver lesion did not produce recognizable macroscopic or histopathologic lesions following oral inoculation.^{161,416} A serologic survey in Belgium and West Germany revealed carriers of antibodies among homing pigeons as 8% and 16%, respectively.^{161,416}
- Muscovy Ducks and Mullards:** Mullards are a cross between Muscovy Ducks and Mallards, raised (particularly in France) as table birds because of their fine meat. While Mallards are resistant to the disease, Mullards are highly susceptible. Growth inhibition and impaired development of the plumage has been described in affected three-week-old Muscovy ducklings. In severe outbreaks, up to 90% mortality may occur. At necropsy, pericarditis and air sacculitis of the anterior air sacs are the main findings, frequently accompanied by hyperplasia of the spleen and perihepatitis.¹⁰⁸ A similar disease has been described in Muscovy ducklings between ten days and six weeks of age.²⁵⁰ Hepatomegaly and splenomegaly with slightly elevated pinhead-sized necrotic foci were consistent lesions. Histopathologic lesions, if present, included coagulative necrosis and a mild lymphocytic infiltration. Experimentally exposed geese, Pekin Ducks and chickens did not succumb to disease.

▪ **Geese:** A reovirus has been found to cause infectious myocarditis in geese.²²⁴ Five- to twenty-one-day-old goslings may develop clinical signs following infection. Older birds appear to be resistant. After an incubation time of three to six days, sudden death or somnolence, anorexia, increased water consumption, mild nasal discharge and conjunctivitis, dyspnea and, more rarely, watery, grayish-white diarrhea can be observed. The body temperature decreases to 38°C. The skin of the beak and feet becomes brownish and peels off. Weakness of the legs caused by myositis and occasionally paresis of the neck musculature or tremors can be observed. Survivors are stunted. Muscovy Ducks were also found to be susceptible. In these birds, the virus replicates in the intestinal tract but does not cause clinical or pathologic lesions.

At necropsy, besides dehydration, a distinct dilatation and gray discoloration of the heart is seen, as well as pericarditis, catarrhal rhinosinusitis, pulmonary edema, air sacculitis of the thoracic air sacs and dystrophy of the liver.

Histopathology reveals Zenker's degeneration and necrosis of the myocardium and skeletal muscle, proliferation of the myocardial syncytium, inflammation that is restricted to the subepicardial connective tissue and as pericardial and subendocardial edema. Hemorrhagic interstitial nephritis or coagulative necrosis may also be noted.¹⁵⁰

▪ **Finches (*Estrildidae* and *Ploceidae*):** Clinical signs in finches are associated with enteritis and swelling of the liver, which can be severe enough to be noted through the abdominal skin. At necropsy, disseminated yellowish, greasy or soft foci, which histopathologically represent focal coagulative necrosis, can be observed. Infiltration by monocytes and lymphocytes is seen in the liver, the kidneys and the lamina propria of the intestinal tract. In the spleen, destruction of the reticular cells can be observed as well as ecchymosis in the subcutis, epicardium and other serosal membranes.¹⁵⁰

Diagnosis

Lesions in ducks and geese can be similar to those caused by parvovirus and nephroenteritis, respectively. Cloacal swabs and samples from the rectum and affected parenchymatous organs are best for viral isolation. Demonstration of viral antigen in affected tissues is possible by IF; however, only positive results provide conclusive evidence because the test is not sensitive enough to demonstrate small numbers of viral particles.

The presence of virus in cell culture can be confirmed by the detection of group specific antigen in the ID test.

Most reovirus strains isolated from Psittaciformes show no serologic relationship with those in gallinaceous birds.^{61,275}

Specific antibodies can be demonstrated by ID, but their presence is difficult to interpret because of the frequent occurrence of strains that are not pathogenic. A more than four-fold increase in titer of paired serum samples would be indicative of an active infection, but there might be some doubt as to the importance in a recent disease process.

Control

Commercially available vaccines for poultry are ineffective in Psittaciformes because of antigenic variance among strains. An inactivated vaccine produced from a reovirus recovered from parrots was found to reduce losses associated with an outbreak. Live vaccines designed for use in chickens (viral arthritis) increased survivability (85% survivors if given 100 chicken doses per bird) when used in Muscovy ducklings.²⁵⁵ Goslings may be provided with passive immunity at hatch by subcutaneous administration of hyperimmune serum.

The use of chlorhexidine in the drinking water (20 ml per gallon of water) was thought to reduce the transmission of reovirus infection in a flock of African Grey Parrots. Long-term use (up to 30 days) may be necessary, and there were no observable side effects from this length of chlorhexidine exposure.⁶¹

Orbivirus

Orbivirus is a genus of the Reoviridae that depends on insects such as culicoides, phlebotomus and ticks for transmission. An orbivirus has been isolated from a cockatiel and a budgerigar.¹⁷⁴ The cockatiel died suddenly and at necropsy displayed degeneration of the myocardium, a swollen liver and spleen and cloudy air sacs. In the case of the budgerigar, dyspnea, photophobia and ruffled plumage was observed prior to death. Postmortem examination revealed atrophy of the pectoral muscles, catarrhal enteritis and a slightly swollen liver. Experimentally infected budgerigars developed severe greenish diarrhea for four to eight days with no pathologic lesions noted on postmortem examination. Infected birds seroconverted, and reisolation of the virus was possible from the feces.

The viruses isolated from both these birds were serologically related but were distinct from other orbiviruses tested.¹⁷⁴

Rotavirus

Rotaviruses have more clearly defined outer edges than other Reoviridae, which can be used to differentiate them by electron microscopy. The outer capsid may not be present in noninfectious single-shelled particles. These can morphologically resemble orbivirus and are about 10 nm smaller than the intact virus. The double-stranded genome has 11 segments. During replication within the cytoplasm, some particles appear to bud through ribosome-free areas of endoplasmic reticulum. Virus is released by cell lysis.²⁷⁰

Avian rotaviruses are thought to be serologically unique from each other and from mammalian rotaviruses. Only chicken and turkey strains have been classified.²⁷⁰ Some avian group A rotaviruses agglutinate erythrocytes (human type 0 or guinea pig).

Rotaviruses are distributed worldwide and have been documented in chickens, turkeys, Helmeted Guineafowl, pheasants, ducks, pigeons and lovebirds. Avian strains are resistant to ether, chloroform, sodium deoxycholate, pH 3 and 56°C for 30 minutes.^{270,276} The persistence of infectivity in the environment is not known.

Transmission and Pathogenesis

Rotavirus is excreted in the feces in high numbers, and can be transmitted by both direct and indirect contact. Ingestion may be the most important portal of entry. Infections in three-day-old poults suggest egg transmission, which has not been proven. The cross transmissibility between mammalian (including human strains) and avian strains is undetermined.

Rotavirus is a cause of enteritis and diarrhea in a variety of mammalian and avian species. The virus replicates mainly within the enterocytes of the small intestines. Some strains are known to replicate in the colon and cecum. Certain strains prefer the duodenum for replication, while others replicate in the upper portion of the jejunum. The virulence of the strains varies (in ducks they are nonvirulent). Because viral replication causes lysis of the host cell, the intestinal absorption in infected birds is dependent on the number of infected enterocytes. A decrease in the absorption of D-xylosis has been suggested as an indicator of enterocyte damage. Birds that over-

come infections develop intestinal immunity via IgA and humoral antibodies (IgG), which are also transferred via egg yolk to the chick. Humoral antibodies do not protect against infection, even in the newly hatched chick.^{270,286,357} Cell-mediated immunity is necessary for full protection.³⁵⁷

Incubation periods are short (one to three days) in chickens and turkeys. No information is available for companion or aviary birds.²⁷⁰

Clinical Signs and Pathology

Infected ducks do not develop clinical or pathologic signs of disease.⁴⁰⁰ A short-term (five- to eight-day), self-limiting, transmissible enteritis has been described in the Helmeted Guineafowl.³⁰³ This virus was serologically not related to a bovine strain as other strains were. Pheasants and partridges, especially those infected as chicks, may develop diarrhea and stunting and have increased levels of mortality (up to 30%).^{129,408} In infected pigeons, a watery diarrhea may occur.⁴¹⁵ Rotavirus antibodies have been demonstrated in approximately 10% of the pigeons examined. A rotavirus isolated from a lovebird caused the death of a chicken embryo following yolk sac inoculation. The lovebird showed no clinical signs.¹²⁸

Necropsy findings are nonspecific and are restricted to the intestinal tract in uncomplicated cases. The lumen of the intestine is filled with watery fluid and some gas, and the walls may appear pale. Histopathology reveals cellular infiltrates into the lamina propria, vacuolization of the epithelial cells of the villi and loss of enterocytes from the villi.

Diagnosis

Infection with astrovirus and several genera of the Picornaviridae can cause similar clinical signs. The rotavirus causes a shortened disease with a rapid recovery. Survival depends on the titer of infecting virus and the age and species of the host. Because many avian strains have not been grown in cell culture, electron microscopy is still a common method of identification. The contents of the colon and cecae are examined following treatment with fluorocarbon and ultracentrifugation. The demonstration of viral RNA by means of electrophoresis is also possible. Serologic diversity among strains, difficulties in propagating the virus and the widespread occurrence of the virus make the detection of antibodies to the virus difficult to interpret.

Birnaviridae

The virus of the infectious bursal disease is a member of this family. Disease is seen only in chickens. The virus destroys mainly the cloacal bursa of growing chicks causing a passing or (rarely) permanent immunosuppression (refer to textbooks on poultry disease).

Coronaviridae

The family Coronaviridae contains only the genus Coronavirus. Recognized taxons are the infectious bronchitis virus (IBV), turkey coronavirus and at least nine mammalian species. A coronalike-virus isolated from Japanese Quail has not yet been characterized.³⁰² Isolates from guineafowl and pheasants are serologically different from chicken strains.^{124,287} Coronavirus has been reported as a cause of disease in Psittaciformes.¹⁷⁴ An enterotropic IBV was recently recognized as being distinct from other serotypes of IBV.¹⁹³

Coronavirus has a pleomorphic but mainly rounded morphology and is 90 to 200 nm in diameter. It is enveloped with club-shaped surface projections (peptomers) about 20 nm long. It contains a single-stranded RNA.²¹³ Coronavirus replicates in the cytoplasm of the host cells.

Coronavirus is rather unstable at room temperature and samples for isolation should be stored below -20°C. Shipment of infected material is recommended on dry ice or in 50% glycerol. Lyophilization, preferably in 10% glucose (also for deep freezing), provides adequate stability; however, lyophilized IBV has to be stored in a refrigerator for long-term survival. Coronavirus is sensitive to ether and chloroform, and it is assumed to be sensitive to commonly used disinfectants.²¹³

IBV is distributed worldwide and is not antigenically uniform. Chickens are the main host and may develop respiratory signs, interstitial nephritis, visceral gout or egg shell problems with decreased albu-

men quality. In central Europe, antibodies against IBV have been demonstrated in owls and some Passeriformes.¹⁴⁵

Coronal enteritis is distributed primarily in turkey-raising countries, and the turkey is the only recognized host.³²⁴

- **Pheasants:** IBV has been isolated from pheasants in Great Britain with some regularity.^{124,324} Seven isolates are antigenically closely related, but differ considerably from 12 chicken IBV reference and field strains.

In adult birds, reduced egg production, poor egg quality, slight to moderate respiratory signs and low mortality associated with egg peritonitis, urolithiasis, visceral gout and swollen kidneys are typical. Mortality is highest in eight- to ten-week-old birds (up to 40%) with renal lesions being conspicuous.^{124,241,389} An experimental infection of two-week-old pheasant chicks resulted in a short-term respiratory disease and production of long-term high antibody titers. Virus could not be recovered from the infected birds.¹²⁴

- **Guineafowl:** IBV has been recovered from guineafowl with enteritis and hepatopancreatitis.^{20,96} Anorexia and high mortality in young birds were common in affected flocks. Emaciation, pancreatitis, enteritis, dehydration and nephritis are common findings at necropsy. Clinical signs may start as early as three days of age. Experimental infections of chicks and guineafowl poults by the intranasal route resulted in mild respiratory distress and polyuria. The virus was characterized as an avian coronavirus but distinct from the Massachusetts serotype.
- **Psittaciformes:** Two coronavirus strains have been isolated from parrots (one unspecified species and a Cape Parrot). The two parrot strains appeared to be in the same taxon (which was not related to IBV and several mammalian coronaviruses).¹⁷³

Preliminary studies indicated that the virus is pathogenic for both chickens and budgerigars. The Japanese Quail proved to be refractory. Principal lesions were associated with necrotic hepatosplenitis. One-day-old chicks were particularly susceptible and died. Older chicks and budgerigars survived at least four weeks in spite of severe lesions in the liver and spleen. Interestingly, the experimental infection was easily established by ocular exposure, and contact spread occurred with both chickens and budgerigars.¹⁷³

- **Pigeons:** IBV has been isolated from racing pigeons.²⁶ The strain was serologically identical to chicken strains in Australia (ie, subtype B). Isolated virus caused respiratory disease in experimentally infected chickens.

Clinically affected pigeons showed ruffled plumage, dyspnea and excess mucus at the commissures of the beak. Eleven birds died during the first 24 hours following clinical signs. The rest of the flock (size not mentioned) recovered over the next two to three weeks. At necropsy, the birds were in average condition and had recently eaten, but the linings of the crop and esophagus were ulcerated. Mucoid pharyngitis and tracheitis were seen, and the lower intestines contained fluid. Secondary trichomoniasis was probably responsible for part of the lesions in the upper digestive tract.

- **Ostrich Chicks:** A coronavirus was identified by electron microscopy in a group of two-week-old ostrich chicks with enteritis.⁹⁹ The history revealed weight loss, anorexia, lethargy and weakness. Several affected chicks died. Clinically, two chicks were approximately 5% dehydrated and showed loose droppings. Clinical pathology findings included hypoalbuminemia, low albumin globulin ratio, elevated AST activities, hyperglycemia, hyperkalemia, anemia and normal WBC counts with degranulating heterophils.

At necropsy, the proventriculus was enlarged, thin-walled and filled with ingesta. The ventriculus was empty. The lower jejunum was filled with a thick brownish paste and had thickened walls. The kidneys were mottled pinkish-white. Both tibiotarsal bones were soft and contained a large band of cartilage extending from the proximal growth plate into the metaphysis. Histopathology revealed hypotrophic villi and crypts of Lieberkühn containing cellular debris in the distal jejunum. Eosinophilic inclusion bodies could be recognized in the apical cytoplasm of enterocytes. The proventricular mucosa was thin and depleted in glands. The moderately swollen hepatocytes revealed increased, clear intracytoplasmic spaces. A pectoral focal myodegeneration, necrosis and mild mineralization was considered to be a nutritional myopathy. The bone lesions were comparable with tibial dystrophy in chickens. The cloacal bursa showed a depletion of lymphocytes. *E. coli*, *Aeromonas* sp. and *D-Streptococcus* sp. were isolated from the intestine and the liver. Unsuccessful therapy included systemic support (fluids, bis-

muth subsalicylate, tube-feeding and trimethoprim-sulfamethoxazole).

- **Japanese Quail:** A coronalike-virus was isolated from Japanese Quail with respiratory signs.³⁰² The virus replicates in the yolk sac of the embryonated chicken egg and in chicken embryo liver or kidney cells. It was classified as a coronavirus based on morphologic and physicochemical studies. Serologic examinations revealed that the virus is not related to other avian or mammalian strains.

Togaviridae and Flaviviridae (Arbovirus A and B)

These viruses are spheroid, enveloped (lipid-containing) particles, 40 to 70 nm in diameter, with a genome of a positive-sense, single-stranded RNA. The virus replicates in the cytoplasm. Most of the Togaviridae and Flaviviridae isolated from birds are arthropod-borne viral taxons, which implies that they can be transmitted by arthropod vectors and that the virus in question can replicate in the arthropod host. In birds, ornithophilic arthropods are the main vectors. A strict host specificity might be confused with “spillover” hosts because of a habitat rich in potential arthropod vectors. Only the more important members of the group are described. For other avian arboviruses refer to Ianconescu.¹⁸²

Eastern and Western Equine Encephalomyelitis (EEE, WEE)

EEE (genus Alphavirus of the Togaviridae) is mainly transmitted by *Culiseta melanura*, but may also be transmitted by other mosquitoes (*Aedes* spp. and *Culex* spp.). For WEE (genus Alphavirus of the Togaviridae) the main vector appears to be *Culex tarsalis*. Both viral taxons are serologically distinct but some cross-reaction does occur. EEE and WEE occur mainly in the Americas, but cases have been reported on other continents. Viral isolates or antibodies against both EEE and WEE viruses have been recovered from more than 60 avian species, with antibody titers being common in various species of birds from aquatic habitats. Rates of infection vary from 25 to 100% depending on the host. Ducklings of *Anas platyrhynchos* are susceptible to natural infection

only during the first 18 days of life, while many gallinaceous birds are always susceptible.

Infections in quail species, pheasant species and many New World finch species are characterized by a short, low-titered viremic phase in which birds remain clinically normal and develop effective antibody titers. The House Sparrow, which has been introduced only recently in the New World, develops a long and high-titered viremia, and chronic carriers may be observed. In addition to the natural host, (the Yellow-crowned Night Heron), the House Sparrow is also considered a reservoir of the virus. EEE and WEE produce cross-reacting antibodies, which may reduce the duration and titer of viremia and result in a rapid antibody response in birds that are immune to one virus and infected with the other.^{114,182,346}

Pathogenesis

The virus can be ingested by mosquitoes with the blood of infected hosts from 24 hours post-infection throughout the viremic period (average two to five days) and transmitted to new hosts 7 to 20 days later. The hemagglutinating virus is probably distributed by erythrocytes through the whole body including the brain. Encephalomyelitis mainly develops in young birds.¹⁵² Infections principally occur through insect bites, but horizontal spread following feather picking and other forms of cannibalism have been shown to occur in pheasants. The virus is shed in the feces and occurs in the feather quills. Debeaking, which is not recommended for humane reasons, helps to limit the horizontal distribution of the virus in pheasants.³⁴⁶

Clinical Disease, Pathology and Diagnosis

Outbreaks of EEE are seen mainly in pheasants, but also have been documented in ducks, Chukars, turkeys, Whooping Cranes, emus, finches and pigeons. These birds may die peracutely or acutely with mortality of up to 80%, depending on the age. An age-linked resistance has been demonstrated in pheasants beginning at 28 days. Clinical changes in a group of infected Lady Gouldian Finches included severe paresis and dyspnea.⁶⁹ Lesions caused by WEE are rare, but are essentially the same as those due to EEE: depression, incoordination, paresis and paralysis, torticollis, tremor, polydipsia and somnolence. Mortality rates in turkeys with ataxia and paralysis is about 6% whereas quail show up to 90% mortality. Clinical chemistry tests reveal anemia with normal numbers of leukocytes. AST, LDH and uric acid values are distinctly elevated. EEE has been associated with the acute onset of depression, profuse hemorrhagic enteritis, anorexia and ataxia,

followed by prostration and hyperemesis prior to death in emus.⁴⁰⁹

At necropsy, EEE and WEE lesions are similar (swollen liver, mucoid duodenitis, dehydration) in most species. In the Whooping Crane, a clear yellow fluid is seen in the anterior abdominal air sac, and diffuse necrosis is present in many parenchymatous organs. Pheasants typically develop a neurotropic disease, while lesions in chickens are mainly myocardiotropic.³⁴⁶ Histopathology reveals a nonpurulent encephalitis with edema, meningitis, perivascular infiltrates, diffuse gliosis (also in the spinal cord) and necrosis in the cerebral cortex.¹⁵² Histologic changes occur principally in the rostral brain with a “descending” tendency, which stands in contrast to other avian encephalitis with a typically “ascending” encephalitis.³⁴⁶

In Lady Gouldian Finches, necropsy findings included consolidation in the lungs and a pale liver and kidney. Histologic lesions included hemorrhage, bronchopneumonia and multifocal centrolobular hepatitis (brain was not submitted for histopathology).⁶⁹

Diagnosis

Because EEE and WEE viruses are sensitive to temperature, pH and many solvents, transport of virus for isolation is difficult. Homogenates of blood, liver, spleen and brain are best for virus isolation. The virus can be identified in cell culture by HI, ELISA, radioimmune assay or molecular hybridization. Humoral antibodies can be identified by the same methods; however, IgM can persist longer than IgG and methods for demonstrating IgM should also be used.¹⁴⁰

Treatment

Administration of hyperimmune serum was not shown to have any effect on mortality levels in infected pheasants.³⁴⁶ Emus should be treated symptomatically with fluids, vitamins (probably vitamin K) and supportive alimentation.⁴⁰⁹

Control

Control of insects, mites and ticks is important in preventing infections. Sentinel birds (some pheasant chicks) may be used to indicate the presence of infected mosquitos. There is some conflicting evidence on the use of vaccines. Formol-inactivated vaccine for horses (five pheasants per one horse dose) is reported to be efficacious (national legal implications notwithstanding). A formalized bivalent chicken embryo vac-

cine was found to protect only 60% of the experimentally vaccinated birds.³⁴⁶

Several recommendations have been made to vaccinate ratites in endemic areas with an inactivated equine EEE vaccine.^b Neither the efficacy nor safety of this vaccine when used in ostriches has been established. Written permission should be obtained from the insurance carrier of an ostrich before vaccination is carried out. The recommended vaccination protocol includes vaccination at three months of age followed by a booster one month later and every six months thereafter.⁴⁰⁹

Zoonotic Potential

Human disease is rare and occurs following bites from infected mosquitoes. EEE and WEE both cause an acute infection of the CNS ranging from mild meningoencephalitis to lethal encephalitis or encephalomyelitis. In endemic areas, extensive vaccination of horses has reduced the levels of infection in humans.

Venezuela Equine Encephalomyelitis (VEE)

The causative agent of EEE is a member of the genus Alphavirus (Togaviridae). Birds play a minor role; the main reservoir is rodents. Vectors are *Culex* spp. with preference for rodents. However, in swamp areas some egrets and herons are known to be carriers. The main avian reservoir is the Striated Heron.¹¹⁴ Human cases are characterized by a general benign course with acute but short fever, headache, myalgia, arthralgia, lymphadenopathy and frequently exanthema, but rarely CNS signs or hemorrhage.

Avian Viral Serositis (AVS)

A toga-like virus is suspected to cause a disseminated serositis in some Psittaciformes.¹⁰⁴ Electron microscopic studies of infected cell cultures revealed viral nucleocapsids (25-31 nm in diameter) accumulating near intracytoplasmic and plasmatic membranes. Mature enveloped particles are 45 to 54 nm in size.

The host spectrum currently includes several juvenile macaw species, macaw hybrids and a Rose-ringed Parakeet. Experimentally, chickens, mice and rats were susceptible to infections. Interestingly, all the naturally affected birds came from nurseries or were parent-raised on farms where neuropathic gastric dilatation was endemic, and many of the contact birds were known to have died from this disease.

TABLE 32.13 Pathologic Changes Associated with AVS

Liver	Multifocal degeneration (may be vacuolar), hepatocellular necrosis
Lung	Interstitial pneumonia and edema, bronchitis, pleuritis
Proventriculus/ventriculus	Lymphocytic proventriculitis, multifocal myositis and necrosis, lymphohistiocytic myositis
Serosa	Mesenteritis and serositis (intestinal, hepatic)
Spleen	Heterophilic infiltrates, multifocal lipogranulomas, lymphoid necrosis
Brain	Focal cerebral meningitis, necrotizing encephalitis, nonsuppurative encephalitis
Bursa	Lymphoid necrosis
Heart	Fibrinous epicarditis, lymphohistiocytic epicarditis and myocarditis, degenerative necrosis
Skeletal muscle	Multifocal myositis with necrosis, lymphohistiocytic myositis

Various histologic findings in a group of naturally infected macaws and a Ring-necked Parakeet and experimentally infected chicks with avian serositis virus. Adapted from Gaskin J, JAAV 5:27-34, 1991.¹⁰⁴

Clinical Signs and Pathology

Affected birds die acutely or lose weight and have distended abdomens containing ascitic fluid (Color 32.18, Figure 32.22). Some birds develop respiratory distress.

At necropsy, the presence of serosal fluid in the abdomen with or without fibrinous clots was the prominent finding. In some cases, the liver was swollen and the lungs edematous (Color 32.16).

Histopathology revealed multifocal degenerative lesions (some vacuolated), necrosis of hepatocytes, interstitial pneumonia and edema, lymphocytic proventriculitis and splenic lymphoid necrosis (Table 32.13).¹⁰⁴ In experimentally infected chicks lymphoid necrosis was common, which may result in immunocompromised birds.

The importance of this virus for parrots and any role this virus may play in neuropathic gastric dilatation require further investigation. Viral particles assumed to belong to the Togaviridae have been described in chicken embryo fibroblasts and also in the epithelial cells of the jejunum and the pancreatic duct in broiler chickens.¹⁰⁰

Rubivirus, German Measles

Rubivirus (formerly rubellavirus) is classified as a member of the Togaviridae. It is not known to cause disease in any avian species. However, antibodies indicating a carrier state with possible shedding of

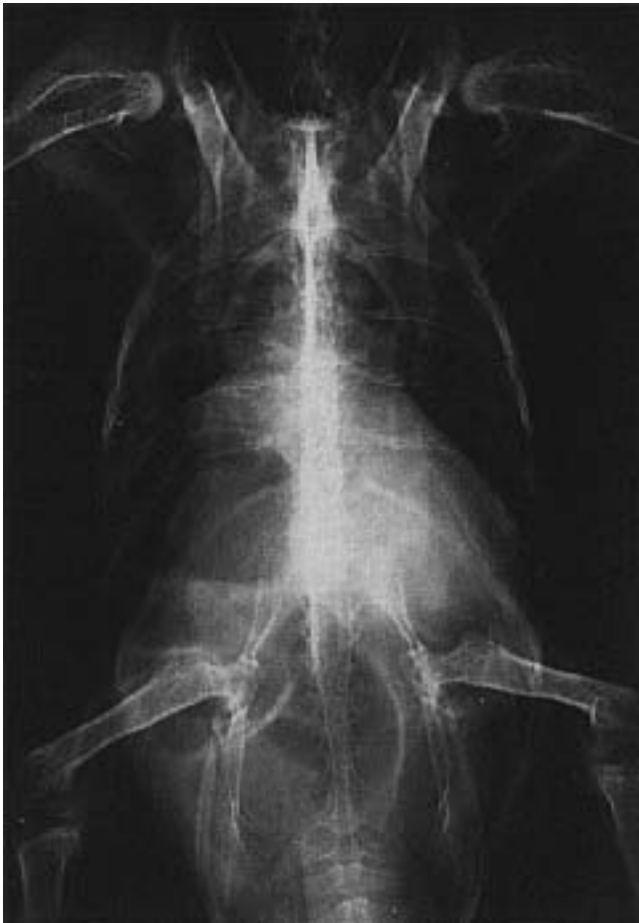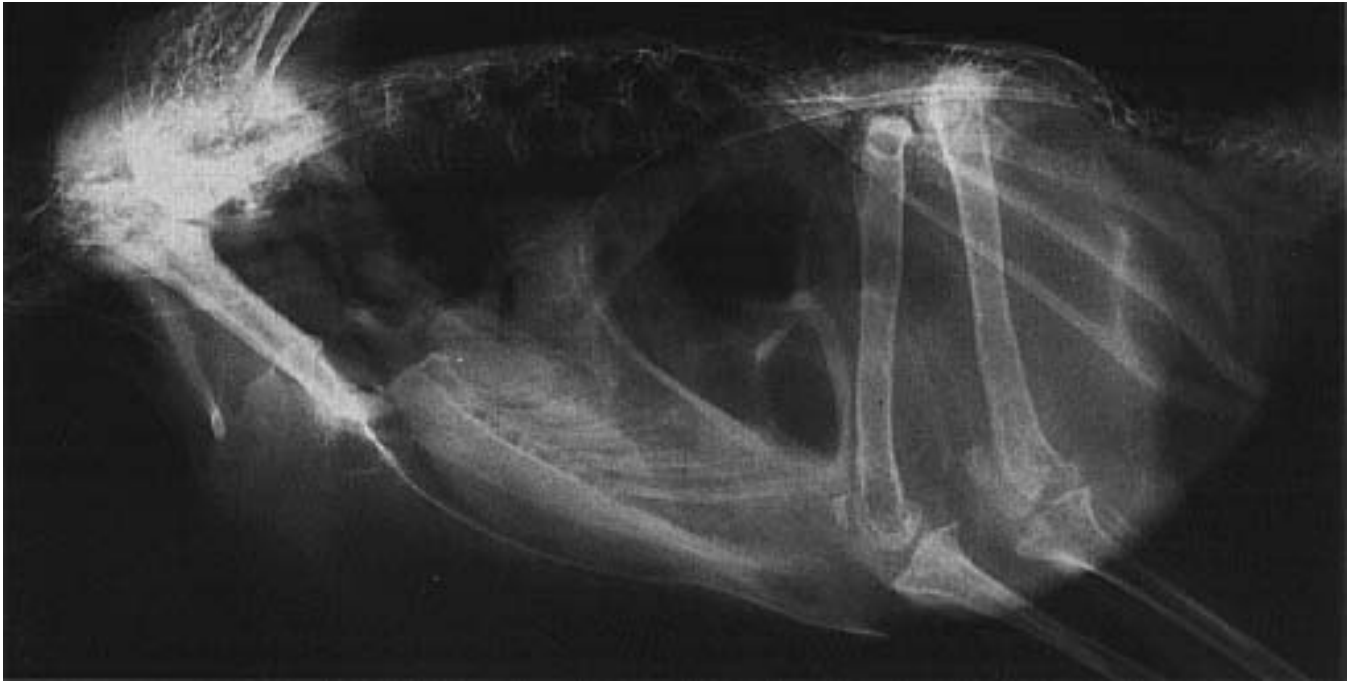


FIG 32.22 Ileus and severe bowel loop distension in a Blue and Gold Macaw with avian viral serositis (see Color 32.18). Note the cranial displacement of the proventriculus and ventriculus.

the virus have been found in urban pigeons (1.2% of population) in Germany.¹⁶¹ In Munich, antibody titers average 1:16 and the carriers may average 7% of the birds examined.⁷⁹ Because rubivirus is a human pathogen, the occurrence of antibodies in free-flying urban pigeons suggests that these birds may be a reservoir for human infections. On the other hand, it has been suggested that pigeons may be infected by virus-shedding humans.¹⁶¹

■ Israel Turkey Meningoencephalitis (ITM)

ITM virus belongs to the flaviviridae. *Aedes aegypti* and *Culex molestus* are the main vectors. The disease was initially described in northern Israel (in season with its vectors), but has now been documented in southern Israel and South Africa. The main host is the domesticated turkey, which under field conditions becomes sick after ten weeks of age. Poults and Japanese Quail are highly susceptible experimentally. The incubation period is five to eight days following experimental infection.

Clinical changes include progressive paresis and paralysis and spastic, uncoordinated movements. Mortality averages 10 to 30%, but can reach 80% in some flocks. Breeders can show a significant drop in egg production. Necropsy findings are unremarkable. Histopathology reveals a meningoencephalitis with perivascular and submeningeal lymphoid infiltration. Clinical and histologic changes are similar to

those described with EEE virus, WEE virus and Newcastle disease virus.

The ITM virus can be detected in the blood and various organs from 24 hours up to 8 days following infection. Blood and parenchymal organs can be used for virus isolation. Virus identification in cell culture can be accomplished by VN. Serologic diagnosis can be made in survivors by using the HI test with goose erythrocytes and an antigen made from infected mouse brains.¹⁸² An attenuated (quail) live vaccine is available and reported to be effective.

■ Louping Ill Virus Infection

The Louping Ill virus belongs to the Flaviviridae and is serologically related to the Siberian tick encephalitis virus (Russian spring-summer encephalitis) and the Central European tick-borne encephalitis virus. *Ixodes ricinus* ticks are the main vector.³³² The established avian host spectrum includes the Willow Grouse and the subspecies Red Grouse, Rock Ptarmigan, capercaillie, Black Grouse and the Common Pheasant. The first three birds discussed are very susceptible and usually develop CNS signs. The most susceptible birds inhabit moorland and tundra, compared to the less susceptible species that inhabit woodland and forest areas.³³²

■ St. Louis Encephalitis (SLE), Japanese B-Encephalitis (JBE), Murray Valley Encephalitis (MVE)

The agents belong to the family Flaviviridae. They occur on three different continents and are serologically related. Birds living in the breeding grounds of the vectors (for SLE: *Culex quinquefasciatus*, *C. pipiens*, *C. tarsalis*; for JBE: *C. tritaeniorhynchus*, *C. pipiens*, *C. gelidus*; for MEV: *C. annulirostis*, *C. tarsalis*, *Aedes* spp.) are important reservoirs. There are more than 30 species of susceptible birds that do not become sick. Avian reservoirs include Brown-headed Cowbird, House Sparrow, some egret and heron species, and in Australia, ibises and cormorants.¹¹⁴ Outbreaks of SLE in humans can be predicted by an increase of seroconversion in sentinel birds and can be prevented or abated by controlling mosquitoes.¹⁸² The human disease is similar to EEE.

■ Other Arboviruses

Table 32.13a gives a survey on the viral groups, the host spectrum and the main vectors. None of the birds cited in the table develop disease, even if viremic. Migrating birds are responsible for the distribu-

tion of the West-Nil virus outside the African endemic area. Because virus or antibodies can be documented in nonmigratory birds in new areas, endemic vectors are at least transitory transmitters. The influence of birds in distributing virus of the Bunyamvera group is limited to the function of transport hosts. Migrating birds carry infected ticks. The Crimean-Congo hemorrhagic fever is transmitted this way.^{114,182}

The human disease by Siberian tick encephalitis virus resembles EEE. West-Nil fever is a mild febrile disease in humans and has a promising prognosis. CNS signs occur only rarely, but maculopapular exanthema and lymphadenitis are more common. Crimean-Congo hemorrhagic fever causes clinical signs in humans. The Uukuniemi virus can cause febrile conditions partly with hemorrhage and CNS signs. The California encephalitis group virus (important member: LaCrosse fever) causes clinical conditions similar to VEE. The Tahyna virus shows signs such as fever, headache, vomiting, pharyngitis and more rarely, interstitial pneumonia.

TABLE 32.13a Avian Arboviruses — Zoonotic Potential

Viral Group	Avian Hosts	Important Vectors
Flaviviridae Tick-borne encephalitis; European, Far Eastern subtype	Guillemot; probably other bird species	<i>Ceratixodes putes</i> , <i>Ixodes</i> spp.
West-Nil virus	At least 27 avian species, including migratory birds and domestic pigeons	<i>Aedes</i> spp., <i>Culex univittatus</i>
Bunyaviridae Crimean-Congo hemorrhagic fever	Birds refractory, only transport host for infected ticks	<i>Hyalomma</i> spp.
Uukuniemi virus	Passerine migratory birds (5 species)	<i>Ixodes</i> spp.
California encephalitis virus	Chicken, Canada Goose	<i>Aedes triseriatus</i>
Tahyna fever virus	Chicken, Starling	<i>Aedes</i> spp., <i>Culex modestus</i>
Reoviridae Kemerovo virus	Passerine migratory birds particularly Redstarts	<i>Ixodes</i> spp.

Rhabdoviridae

Birds are not considered natural reservoirs for the rabies virus, but they can nonetheless develop active infections while remaining asymptomatic. Virus isolation has been reported from common buzzards, Goshawks, ducks, a Red Kite and a Barn Owl.¹⁵² Rabies virus infections have been experimentally reproduced in hawks, falcons, ravens, songbirds, pigeons, geese, ducks, chickens and peafowl.

Rabies antibodies have been described in free-ranging populations including Prairie Falcon, Goshawk, Golden Eagle, Short-eared Owl, crow, raven and starling.¹²⁶ In one survey, rabies virus titers were detected in six orders of birds representing 22 species. Twenty-three percent of the raptors had titers and eight percent of the non-predatory scavengers including starlings, crows and ravens had rabies antibody titers. These findings suggest that viral exposure occurs through contact with infected prey species.

Infection may occur from bites or from ingestion of infected prey. The virus spreads from the area of trauma via endoneural lymphatic vessels into the gray matter of the CNS. The self-limiting nature of the virus in avian species is believed to be due to a rapid production of antibodies. VN antibodies can be demonstrated within the neural tissue and can neutralize freshly replicated virus released from the neural cells. This explains the limitation of the infection to one area and the inhibition of viral distribution throughout the body.

The natural incubation period in ducks is three weeks to eleven months.¹⁵²

Clinical Disease and Pathology

The clinical course in species naturally and experimentally infected can take 2 to 42 days. A short excitable period with jumping, crying, trying to flee, aggressiveness toward humans and epileptiform convulsions is followed 24 hours later by ataxia, weakness of the limbs, falling on the flanks and, finally, flaccid paresis (including head and neck). Two weeks later somnolence, apathy, compulsive movements and death can occur. Spontaneous recovery has also been reported.¹⁵²

At necropsy, anemia, cachexia and hyperemia of the brain are noted. Histopathology reveals a nonpuru-

lent encephalitis, which is distinct only two weeks after the outbreak of the clinical disease. Negri bodies are not regularly found. There has been no documented case of human rabies from an avian exposure.

Paramyxoviridae

The Paramyxoviridae family consists of two subfamilies:^{325a} Paramyxovirinae with the genera Paramyxovirus and Morbillivirus (mammalian only); and Pneumovirinae with the mammalian respiratory syncytial viruses and turkey rhinotracheitis virus.

Members of this family have nonsegmented single-stranded RNA of negative polarity and an enveloped, helical, capsid symmetry. Virions are generally pleomorphic, rounded and 100 to 500 nm in diameter. A filamentous form 100 nm wide and variable in length has been described but may be an artifact. The virion surface is covered with 8 nm projections (so-called "herring bone") nucleocapsids that may be released from disrupted particles. The members of the Paramyxovirus (PMV) genus have neuraminidase, which is absent in the other genus.⁹

Virus replication takes place entirely in the cytoplasm in accordance with the scheme employed by negative-strand RNA viruses. Virus attaches to host cells through the "HN" polypeptide of the virus. Fusion of the virus and host cell membranes takes place (mediated by the "F" protein of the virus) and the nucleocapsid enters the host cell. The "F" and "HN" proteins require cleavage by host-derived enzymes and these procedures control pathogenicity in some strains.

Avian Paramyxovirus

Newcastle disease virus (NDV) is the type strain for avian paramyxoviruses. Numerous, serologically different strains of this virus have been isolated worldwide.⁸¹ Hemagglutination inhibition (HI) tests, neuraminidase inhibition tests, serum neutralization tests and comparison of structural polypeptides have resulted in the identification of nine serotypes (PMV-1 to PMV-9).⁴ Strains are designated according to serotype: species or type of birds from which virus was isolated/geographic location of isolation (usually

TABLE 32.14 Avian PMV Prototypes⁷³

Virus Strain	Host Spectrum
PMV-1 (Newcastle Disease)	Hundreds of species/27 orders
PMV-1/pigeon/Munich/14/83	Pigeons, doves (see text)
PMV-2/chicken/California/Yucaipa/56	Passeriformes, turkeys, chickens, Psittaciformes, rails
PMV-3/turkey/Wisconsin/68**	Turkeys
PMV-3/parakeet/Netherlands 75**	Psittaciformes, Passeriformes
PMV-4/duck/Hong Kong/D3/75	Ducks, geese, rails
PMV-5/budgerigar/Japan/Kunitachi/75	Budgerigar
PMV-6/duck/Hong Kong/18/199/77	Ducks, geese
PMV-7/dove/Tennessee/4/75	Pigeons, doves
PMV-8/goose/Delaware/1953/76	Ducks, geese
PMV-9/duck/New York/22/78	Domestic duck

** Host-related differences shown by monoclonal antibodies

country or state)/reference number or name/year of isolation.⁸ Table 32.14 lists the prototypes of various avian PMV serotypes.

Avian PMV, particularly NDV, are important pathogens in domestic poultry and have prompted control measures that have had serious effects on international trade and movement of birds. Environmental and chemical stability, routes of transmission and pathogenesis of infections have been studied only with NDV. Comparisons with other serotypes are subjectively based.

PMV-1

PMV-1 consists of NDV and related strains that are serologically, molecular biologically and pathogenically unique. They are found in Columbiformes and some Psittaciformes. Strain-specific monoclonal antibodies are necessary to distinguish infection caused by these strains of PMV-1, which have been divided into nine distinct groups.⁸ Group P contains the pigeon isolates, which are no longer considered to be classic NDV.

Newcastle Disease

NDV is distributed worldwide with the possible exception of the various islands of Oceania. Birds from these islands should be considered immunologically naive with respect to NDV. NDV is serologically uniform and isolates are divided based on their virulence and epizootiologic importance (velogenic, mesogenic or lentogenic). These divisions are applicable only to the domestic chicken. Virulence is host-specific and varies considerably with experimental infections in other species.⁴⁶

The host spectrum includes hundreds of species from at least 27 orders.¹⁹⁵ Susceptibility and the clinical course of disease are highly variable between species and apparently depend on the epitopes and the enzymatic status of the host. Birds of all ages are susceptible to infection. Although overheating may be a triggering factor, no real seasonal peaks have been described. Table 32.15 shows the susceptibility of a variety of orders.^{91,148} Some mammals are susceptible to NDV, and humans may develop a severe conjunctivitis.

Transmission

Virus enters the host mainly through the respiratory and gastrointestinal tracts. Embryos can be infected if their shells are contaminated with virus. Vertical transmission can occur, but is rare with velogenic strains because viremic hens usually stop laying. Lentogenic and apathogenic NDV might be egg transmitted via the vitelline membrane. This route of transmission is thought to occur regularly following vaccination with live lentogenic strains (Hitchner B₁). Although virus can be found in respiratory secretions, the main route of viral shedding is the feces.

Mechanical vectors that may spread the virus include wind, insects, equipment and humans. Immune birds can function as carriers and intermittently shed virus. Persistent infections are limited to weeks or months. The most common carriers (reservoirs) include free-ranging waterfowl, Pittidae, Psittaciformes, some Passeriformes and Strigiformes.^{21,45,59,90,157,158,183, 249,269,296,354,366,394}

Pathogenesis

NDV has an affinity for erythrocytes allowing the virus to be widely distributed throughout the host's body. Dyspnea may be caused by lung congestion and damage to the respiratory center. Petechiation results from viral adherence and damage to the vascular endothelium. The highly variable virulence of a given strain in a particular host is governed by the amino acid sequences of the "F" and "HN" viral proteins and the type of proteases available in the host for cleavage of the protein precursors.¹³ The incubation period varies depending on the host species, previous virus exposure, pathotype of virus and titer of infecting virus.

Clinical Disease and Pathology

Lentogenic, mesogenic and velogenic strains of NDV produce varying clinical disease in chickens. The clinical expression varies widely in other birds, even between two species of the same genus. Several clini-

TABLE 32.15 Newcastle Disease (ND) Susceptibility*

Order	Susceptibility
Struthioniformes (ratite)	Moderate (10,11)
Cariamiformes (seriema)	Low (13) to high (1)
Gruiformes (crane)	Latency (14)
Ralliformes (rail)	Latency (2)
Lariformes (gull, tern)	Low (13)
Sphenisciformes (penguin)	Low (13) to high (12)
Pelecaniformes (pelican)	Low (13)
Columbiformes (pigeon, dove)	Low (5), moderate (4), high (1 - experimental)
Psittaciformes	
Lovebird	Low (13), high (7 - experimental)
Macaw, conure	High (5 or 7 - experimental)
Amazon parrot	High (5 or 6)
Caique	Moderate
Psittaculidae	High (5)
Eclectus Parrot	Moderate
Lory	Refractory
Platyercidae	Latency
Budgerigar	Low (natural), high (6 - experimental)
Cockatoo	High (5)
Cockatiel	Moderate
Strigiformes (owl)	Latency, low (16), high
Falconiformes (falcon)	Low (13), moderate (9)
Accipitriformes (vulture, hawk)	Low (13 or 15), moderate (8)
Sagittariiformes (secretary bird)	Low (13)
Ciconiformes (stork)	Low (13)
Anatiformes	
Geese	Latency (17), moderate (3)
Surface ducks	Latency (20,21)
Bay ducks	Latency
Phasianiformes	
Guineafowl	Moderate (1)
Peafowl	High (1)
Pheasant	High (1 or 2)
Grouse	Latency (15), high (1)
Cuculiformes (cuckoo)	Latency (13)
Upupiformes (hornbill)	Low (16), moderate (10)
Alcediniformes (kingfisher)	Low (15)
Piciformes (toucan)	Low (16)
Passeriformes	
Crow	Latency (17), moderate (12 or 19)
Finch	Latency, low (11 or 17)
Weaver finch	Latency, high (18), low (22)
Others	Latency, low (23), moderate (16)

*The clinical presentations and associated pathology are listed by a number. The number corresponds to the first column of Table 32.16.

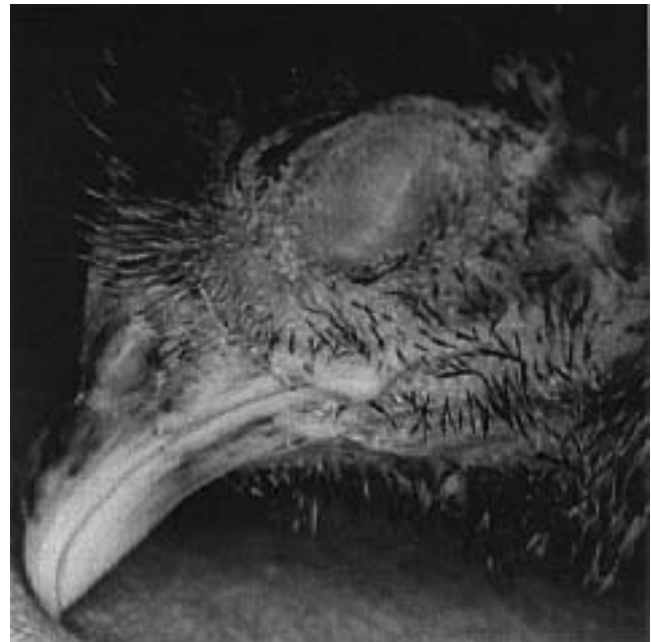

FIG 32.23 The clinical signs associated with Newcastle disease virus vary with the virulence of the virus and the infected host. Acute respiratory infections with clinical changes, including depression and dyspnea, are characteristic.

cal presentations are characteristic, but may vary considerably in their severity. In short, these can be summarized as follows:

- Peracute death; several hours of depression caused by viremia.
- Acute gastrointestinal disease (VVND); voluminous greenish diarrhea accompanied by anorexia, lethargy and cyanosis.
- Acute respiratory disease; upper respiratory exudates, rales and dyspnea.
- Acute gastrointestinal and respiratory disease.
- Chronic central nervous system (CNS) disease characterized by opisthotonos, torticollis, tremors and clonic-tonic paralysis of the limbs.

CNS signs generally occur with the development of humoral antibodies and may occur following an acute or subclinical infection. Virus may not be recovered once CNS signs develop. Partial immunity can alter the clinical progression of disease and pathologic lesions (Figure 32.23).

Affected birds typically have petechia on serosal surfaces and fatty tissues and on the mucosa of the larynx, trachea and proventriculus. Egg follicle hemorrhage may also be noted in protracted cases. Hemorrhagic necrotizing enteritis, mainly within the je-

junum, is common with virulent strains. Lymphatic tissue in association with the hemorrhagic lesions forms “boutons,” which are pathognomonic in Phasianiformes. Birds with CNS signs may have no gross lesions, or hyperemia of the brain may occur.

The histopathologic lesions are as variable as the clinical signs. Table 32.16 provides a summary of gross and microscopic changes in a variety of birds. CNS lesions are generally characterized by a nonpurulent encephalitis with vascular and perivascular infiltrates of mononuclear cells. Increased numbers of glial cells and pseudoneuronophagia may occur. Histologic lesions rarely correlate with the severity of clinical signs.

Diagnosis

For the rule-out list, infectious and noninfectious causes of gastrointestinal or respiratory tract disease should be considered. One differentiating factor is that ND is not associated with sinusitis. CNS lesions are typical for ND in a variety of bird species. As a rule, the incubation time is prolonged in these cases, and histopathologic lesions may be difficult to document. Comparable clinical signs may be seen with chlamydiosis (meningitis), salmonellosis (encephalitis purulenta) encephalomalacia, lead toxicity and calcium deficiencies. Histopathologic differentiation is only possible following thorough examination of a variety of affected tissues.

Antemortem diagnosis of NDV can be performed by culturing virus from feces or respiratory discharge (swabs) from affected birds. The number of samples required for a diagnosis depends on the size of the flock, the clinical signs (CNS) and the quarantine situation.

Feces or respiratory swabs should be placed in appropriate transport media, and any sample for virus isolation or serology should be shipped on ice (4°C). Serology results (HI or AGP) generally require two days, while culture results may take from three to five days to several weeks. Postmortem samples for virus isolation should include trachea, lung, spleen, liver and brain shipped in transport media on ice. Fixed tissues from the brain and trachea can be used for histopathology. Cryofrozen sections of the nasal or tracheal mucosa may be processed for staining with fluorescent antibodies (nonspecific reactions can occur). Fluid from the aqueous humor can be collected for HA (detect virus) and HI (antibodies to virus) and can provide the most rapid diagnosis (hours to days), if sufficient antigen is present in the sample.

▪ **Direct Virus Demonstration:** Virus isolation can be achieved using feces, cloacal swabs or discharge from the respiratory tract. Isolation of the virus is required for complete classification. The ability of NDV to adapt to a variety of host systems can make it difficult to demonstrate directly. The fact that latently infected birds have low virus titers and that vaccine strains (even mesogenic ones in imported or migratory birds) may be present, complicate the evaluation of virus isolations.

Isolates determined to be PMV-1 by HI should be sent to designated laboratories for further differentiation. Specific characterization can be accomplished with monoclonal Abs and by determining virulence for chickens (mean death time of chicken embryos, intracerebral pathogenicity index [Hansen Test], intravenous pathogenicity index, plaque formation test).

▪ **Indirect Virus Demonstration:** The response to antigens by the production of humoral antibodies varies within taxonomic groups and individually. Therefore, indirect virus demonstration by humoral antibodies may be difficult. HI titers can be present by the fourth day post-infection and may vary considerably. Titers may be nonexistent or low (birds of prey, domesticated pigeons, budgerigars), even in birds that have survived the disease. The development of HI antibodies may be delayed, and latent infections can result in the formation of antibodies. The HI titers that develop in Psittaciformes may be low with Amazon parrots and Psittaculidae, having average titers of 1:8 to 1:64, while cockatoos may have titers of 1:320.

Treatment

Hyperimmune serum (2 ml/kg body weight IM) can be used to protect exposed birds but is of no benefit once clinical signs are present. CNS signs occur in the presence of humoral antibodies. Use of B vitamins and anticonvulsants for treating NDV-induced nonpurulent encephalitis is discouraging; in controlled studies, there was no difference in treated or untreated groups. Following improvement (which may take a year), any disturbance or stressful event may cause a bird to have severe convulsions or tremors.¹¹¹

Control

NDV occurs worldwide and many free-ranging birds can function as carriers. Effective vaccination regimens would be helpful in controlling infections in aviaries, breeding farms and zoo collections; however, ND is a notifiable disease in many countries and governmental regulations may control vaccination protocols. Most birds in orders other than Phasiani-

TABLE 32.16 Newcastle Disease Clinical Signs and Pathology

Number-strain	Clinical Signs	Pathology
1-velogenic strains	Systemic disease (peracute-acute) with fever, depression, dull plumage, cyanosis, edema of eyelids and face, severe dyspnea caused by pulmonary edema and catarrhal or fibrinous tracheitis, watery diarrhea. Nervous signs only in survivors after 1-2 weeks. Mortality: 50-90% in 4-8 days.	Gross: muscles conspicuously dark, petechia of serous membranes, edema, tracheitis, cloudy air sacs, enteritis, necrotizing ulcers in Peyer's patches and cecal tonsils (pathognomonic); petechia of mucosa of proventriculus, ventriculus and intestine; leukopenia. Histology: Hyperemia of parenchyma, larynx, ovary, brain and endothelium of blood vessels; hyperemia and necrosis of lymph follicles; tracheitis with epithelial hyperplasia, lymph follicle proliferation or necrosis; with acute death no brain lesions.
1-mesogenic strains	Acute respiratory signs, discharge of mucus, nervous signs (paresis and paralysis of limbs, ataxia, torticollis, myoclonia, tremor) after 2-3 weeks. Mortality: 5-50%.	Gross: dehydration, catarrhal enteritis, airsacculitis, tracheitis, pneumonia, cloudiness of the cornea, petechia of serous membranes and adipose tissue, necrotic foci at the sides of the choanal cleft. Histology: nonpurulent encephalitis with dense cellular infiltration (monocytes, lymphocytes, plasma cells, rarely heterophils) into the walls of the blood vessels (cuffing). CNS lesions are seen in the gray and white matter particularly in the basal parts (thalamus, cerebral peduncle, medulla oblongata); swelling and karyorrhexis of capillary endothelia, hyalinization of the arteriolar walls; frequent degeneration of ganglial cells, but rarely gliosis; neuronophagia within the lumbar spinal cord (posterior gray matter). Proliferation of the tracheal epithelium and slight desquamation. In the lymphatic tissue, edema and necrosis of the reticular cells situated within the lymph-follicles, disappearance of lymphocytes. Pulmonary hyperemia, edema and hemorrhage; edema and cellular exudate in bronchioles and parabronchi.
2-velogenic	Free-ranging pheasants contract the disease rarely; they are unable to stand and refuse to feed; dyspnea (acute tracheitis) may be distinct or totally absent; occasionally hemorrhagic diarrhea.	See number 1.
3	Spontaneous disease rare and without respiratory signs; ataxia and paresis; in geese spontaneous drowning is typical; ducks may develop CNS signs.	Often no lesions, rarely encephalitis.
4-velogenic	CNS signs only; the acute disease is, as a rule, not observed, but if so: emaciation, whitish diarrhea, paresis of one wing, tremor, convulsions of the head muscles, later total paralysis; failure of positioning reflexes; may recover within 1-2 days or death within 5-6 days.	Gross: petechia, hemorrhagic to diphtheritic enteritis. Histology: nonpurulent encephalitis.
5-velogenic or mesogenic	CNS signs such as tremor, enlargement of the pupils, torticollis, reluctance to fly, incoordination of movement, cramps of the toes, convulsive dyspnea, general convulsions and paralysis; bloody feces occasionally; death 4-5 hours following total paralysis. Mortality: up to 100% within 2 weeks.	Gross: hyperemia within the skull's lacunae, hemorrhages in the brain, swollen spleen; hyperemia, petechia or ecchymosis in the intestinal tract (only rarely necrosis); rarely hemorrhagic enteritis or tracheitis, air sacculitis, fibrinous serositis. Histology: only in birds that have been sick for some time: disseminated nonpurulent encephalitis with perivascular cuffing, gliosis in the cerebellum and brain stem, status cribrosus in the medulla of the cerebellum and in the corpus striatum. Degeneration of ganglion cells and pseudoneuronophagia. Hyperemia and perivascular infiltration in the gray matter of the spinal cord. Hemorrhage and necrosis in spleen, liver and intestine.
6-velogenic or mesogenic	CNS signs, see number 5.	Enteral lesions caused by velogenic strains are not distinct.
7-velogenic or mesogenic	Slight ataxia, but high mortality up to 55%.	
8-velogenic or mesogenic	CNS signs 5-7 days post-infection. Starvation due to incoordination (accidents). Birds may recover with supportive care.	See number 5.
9-velogenic or mesogenic	Birds become sick after incubation of 5-13 days and die soon after the onset of CNS signs.	Cause of death is cerebral hemorrhage.

table continued on next page

Number-strain	Clinical signs	Pathology
10-mesogenic	Onset of disease with enteritis followed by sudden ataxia with a body temperature of 41°C, may hold the neck in a corkscrew-like fashion. Spontaneous healing can occur after weeks.	Gross: Petechia, hemorrhagic to diphtheroid enteritis. Histology: Nonpurulent encephalitis.
11-mesogenic	Respiratory signs and watery diarrhea.	Massive hyperemia of the pulmonary vessels with hemorrhage into the interstitium; edema in some parabronchi.
12-velogenic	Peracute death without clinical signs during viremia.	Petechia of serous membranes.
13-velogenic or mesogenic	Totally atypical course of disease, slight apathy, failure of heart and circulation.	Gross: bird in good condition; enteritis, swollen spleen, traumatic skin lesions, rarely tracheitis. Histology: hyaline degeneration of cordal muscle fibers; pulmonary edema and hemorrhage.
14-mesogenic	Anorexia, apathy, diarrhea.	
15-mesogenic	Conjunctivitis, impairment of general condition.	
16-velogenic or mesogenic	Apparently harmless disease (anorexia, torticollis) followed by sudden death. Clinical signs may be completely absent; fecal excretion for months.	Histology: nonpurulent encephalitis.
17-velogenic, mesogenic or lentogenic	As a rule, no clinical disease, but virus is propagated and excreted from the third day onward and totally eliminated by the sixth day; antibodies are present; occasionally signs as with number 11.	No pathologic lesions.
18-velogenic or mesogenic	Acute course of disease, edema of the eyelids with watery to purulent discharge from narrowed lid clefts; photophobia, no CNS signs; cause of death is asphyxia. Mortality: about 40%.	Gross: icterus, catarrhal enteritis, swollen liver and spleen, fibrinous plugs filling syrinx or larynx. Histology: cellular infiltration into iris, edema of cornea, hyperemia of the choroidea, protein and erythrocytes in the aqueous humor.
19-velogenic or mesogenic	Sudden death without prior clinical signs. Mortality: about 20%.	
20-mesogenic	Stable coexistence between mallard and ND virus; virus may be excreted for six months (probably in a few specimens only).	
21-velogenic	Normal latent infection only, but may be 4% mortality in some free-ranging birds.	Pectoral muscles and leg muscles dark. Hemorrhages of serous membranes and fatty tissues.
22-mesogenic	CNS signs following experimental infection.	
23-mesogenic	Mortality up to 20% without prior clinical signs following experimental infection.	

formes must be vaccinated parenterally for an effective antibody response to occur. Inactivated vaccines produced for chickens are useful, provided that there are no governmental regulations that restrict vaccination. Oil-adjuvanted vaccines have been shown to cause abscesses surrounding the injection site in some birds and must be used with caution. Abscesses secondary to subcutaneous infections are easier to treat than those that occur following IM injections.¹¹¹

Live vaccines produced for chickens (and used for other Galliformes) should not be used in other avian orders. The potential infectivity of the vaccine strain of virus in a non-adapted host has not been determined. Vaccines administered to Psittaciformes in the drinking water have been shown to be ineffective.

As a general consideration in an active outbreak, emergency vaccination with Hitchner B₁ and truly

apathogenic LaSota strains is possible via ocular or nasal drops (five chicken doses per bird). These strains function as competitive inhibitors, and the local protection induced cannot be determined by an increase in humoral antibodies. In a recent outbreak on a farm with ornamental birds (more than 2000 birds of more than 200 species), this vaccination method successfully protected birds that were not yet clinically sick.^{65a}

Dosing with live virus vaccine followed by a booster after three weeks provides three to four months of immunity. Inactivated vaccines provide five to seven months of immunity. A live vaccine followed two to three weeks later by an inactivated vaccine might provide 9 to 12 months of protection. These data are applicable only to gallinaceous birds. Increases in HI titers following vaccination are indicative of a host response and may not correlate with immunity.

Zoonotic Potential

Virulent poultry as well as vaccine strains of NDV can cause severe conjunctivitis in humans. Infected people usually recover with few problems.

PMV-1 Pigeon

A PMV-1 strain that is closely related to NDV but serologically, biochemically and pathogenically unique was first recognized in domesticated pigeons in the late 1970's, probably having arisen in the Middle East.^{4,10,196} The virus reached Europe by 1981 and spread all over the world, affecting particularly racing and show pigeons.^{40,333}

Monoclonal antibodies have shown PMV-1 pigeon strains recovered in many European countries to be fairly uniform. The host spectrum includes domesticated pigeons, feral doves and the Wood Pigeon. Sensitive (but more or less inadvertently infected) species include Cracidae, Pavoninae, Phasianinae, Common Blackbird, House Sparrow, Barn Swallow, European Kestrel, Common Buzzard, Vinaceous Amazon and Eastern Rosella.³⁶⁷ The virus is infectious to chickens, particularly immunocompromised individuals.^{333,414} Experimentally infected chickens do not become latent carriers.²⁷⁴ Some infections occur from ingestion of contaminated feces. Feed contaminated with pigeon or dove feces can be a source of infection for other avian species, particularly chickens.⁷

Clinical Disease and Pathology

Affected Columbiformes have nondescript clinical signs including polydipsia, polyuria, anorexia, diarrhea and vomiting. These frequently unrecognized acute signs are followed by clonic-tonic paralysis of the wings (more rarely the hind limbs), head tremors and torticollis. In contrast to ND, flaccid paresis and paralysis may occur, probably from a peripheral neuropathy.⁹⁵ Other less frequent signs are unilateral blepharodema, egg deformation, embryo mortality and dystrophic molt. Dyspnea, which is common with ND, does not occur. Mortality is highest in nestlings. Affected older birds may spontaneously recover within three to four weeks after the onset of clinical signs. Gross lesions include hyperemia of the brain and large parenchymatous organs, catarrhal enteritis, swelling of the kidneys and hemorrhage and necrosis of the pancreas.

Histologic lesions are variable. Edema of the meninges and brain and swelling of the vascular endothelium in the meningeal vessels may be noted. Lymphocytic perivascular infiltrates and demyelination

of the white matter may occur in the cerebrum, diencephalon, optic lobe, medulla oblongata, intumescencia cervicalis and lumbaris of the spinal cord. Degenerative and inflammatory lesions also occur in the peripheral nerves (plexus brachialis, plexus ischiadicus).⁹⁵ Lysis of Purkinje cells in the cerebrum, which was reported initially with PMV-1 pigeon, may have been caused by herpesvirus that was also isolated from affected birds.²⁷⁷

Diagnosis

Procedures designed for isolating NDV are effective for PMV-1 pigeon. The HI test can be used to differentiate between NDV and PMV-1 pigeon. Final differentiation is possible only by the use of monoclonal antibodies.

Treatment

LaSota vaccine strains administered via eye or nasal drop are not as efficacious in protecting from infections as expected. The LaSota strains replicate poorly in pigeon tissue so that high vaccine doses are necessary for interference and antibody production (protection only for 8 to 12 weeks).¹⁷⁰ Vaccination with live vaccines may exacerbate latent chlamydia or pigeon herpesvirus infections.²²² Parenteral administration of live Hitchner B₁ vaccine has similar side effects but may provide six months of immunity.

Inactivated vaccines are preferable for pigeons. In an active outbreak, vaccination with an inactivated vaccine will decrease the length of the disease and mitigate the clinical signs.¹⁷⁰ Once CNS signs develop, vaccination is of no value; however, spontaneous recoveries do occur.

Control

For vaccination, homologous, inactivated oil emulsion vaccines are commercially available.²²⁰ Annual boosters are necessary.²²⁰ All birds in a loft, and competitive traveling groups of homing pigeons, should be vaccinated. Squabs from hens vaccinated three months before laying may not have protective antibodies.²²⁰ Squabs can be vaccinated with homologous vaccine by four weeks of age.²²² Inactivated NDV vaccines provide only six months of protection.¹⁶⁶

Vaccines are best applied subcutaneously in the neck. Intramuscular injections in homing pigeons can cause severe irritation of the pectoral muscles. To prevent fatal hemorrhage from the plexus subcutaneous collaris (see Chapter 44), injections must be given in the caudal third of the neck, near the middle of the dorsal aspect. Oil-emulsion adjuvants produce

superior antibody titers and have fewer side effects than aqueous carbomers.^{48,319} An effective oral vaccine has not been developed and requires the isolation of an apathogenic PMV-1 pigeon strain.

PMV-2

PMV-2 strains that occur worldwide display considerable antigenic and structural diversity.⁹ Preliminary classification using monoclonal antibodies has identified four groups.³⁰⁰ Isolates from Psittaciformes, some Passeriformes, one Gadwall as well as several turkey isolates from Israel together with a Mallard and a Coot strain belong to group 1. Group 2 consists of chicken strains from the Arabic Peninsula, and two strains from Passeriformes have been assigned to group 3. In group 4, a variety of strains from Passeriformes has been placed. The type strain PMV-2/Chicken/California/Yucaipa/56 belongs to group 1. The host spectrum includes chickens, turkeys, Passeriformes, Psittaciformes and more rarely, rails and ducks.

PMV-2 strains are endemic in Passeriformes (Ploceidae, Zonotrichiinae, Zosteropidae and Estrildidae), particularly those originating from Senegal. Isolates have been recovered from clinically healthy imported companion and aviary birds (Estrildidae, Viduidae, Ploceidae and Carduelidae). Experimentally, these isolates cause a mild upper respiratory tract disease. PMV-2 infections are more severe in Psittaciformes, particularly in African Grey Parrots, where emaciation, weakness, pneumonia, mucoid tracheitis and mortality are common findings.⁶⁴ The Bangor isolate from finches was proposed as a cause of death in a Blue Waxbill. Experimentally the Bangor isolate caused only mild respiratory signs and no pathologic lesions.²⁶³ Further investigations in a variety of bird species are necessary in order to evaluate the virulence of the various strains.

The host spectrum may be much wider than has been shown by direct virus demonstration. Antibodies against PMV-2 have been demonstrated in homing pigeons, healthy Passeriformes (many of them free-ranging) and some birds of prey. Isolates from various finches have not been shown to be pathogenic for chicks.^{116,204} Diagnostic methods used for PMV-1 are also applicable to PMV-2.

PMV-3

PMV-3 strains have been isolated from chickens and turkeys in North America, Great Britain, France and

Germany. Most isolates from nondomesticated species originated from imported Psittaciformes (lovebirds, cockatiels, budgerigars, macaws, *Psittacula* spp, *Neophema* spp.). Some Passeriformes are also susceptible. Antibodies to PMV-3 have not been documented in feral birds, but a free-ranging avian reservoir probably exists.

Two groups of PMV-3 strains, one consisting mainly of turkey strains and the other of strains isolated from companion birds, can be differentiated using monoclonal antibodies.¹⁹ The virus is serologically related to NDV. PMV-3/Parakeet/Netherlands/449/75 will protect chickens against NDV.⁸ Intracerebral pathogenicity indices vary from 0.25 to 0.35³⁵⁸ up to 1.3.³⁸⁵

Clinical Disease and Pathology

The pathogenicity of this virus group varies with the infected species and (probably) virus strain. Conjunctivitis is the initial clinical sign in finches and Weaver Finches (eg, Gouldian Finch, Red-cheeked Blue Waxbill, Canary, White-rumped Canary, Orange-cheeked Waxbill, Black-throated Grassfinch, Double-barred Finch and Avadavat). Yellowish diarrhea, dyspnea and dysphagia occur as the disease progresses. Some affected birds die within a few days, while others recover over a period of weeks.³⁵⁸ CNS signs are not regularly seen in finches (Black-eared Wheater, Grey-headed Wheater, Red-breasted Flycatcher).³⁶⁷ Infected Psittaciformes develop CNS signs similar to those with ND. Susceptibility in Psittaciformes is variable. African Grey Parrots may develop ocular lesions (dilated pupils, hemorrhages around the pecten, uveitis and fibrinous exudate into the anterior chamber), unilateral or bilateral paralyses and hemorrhagic nasal discharge.¹⁴⁸

Latent carriers have been described in Siberian Rubythroat, Long-tailed Grass Finch, Nutmeg-Manikin and Cutthroat Finch; Japanese Quail and domesticated pigeon.^{358,367,385}

Detailed pathologic descriptions are not available. Liver and kidney lesions accompanied by an enteritis with blood in the intestinal lumen are common. Small birds are frequently cachectic, suggesting a chronic disease course or the inability to eat and drink. Histopathologically, hyperemia and a mild proliferation of glial cells in the brain may be seen. The typical nonpurulent encephalitis described with the CNS form of ND is not recognized with PMV-3 infections.

Diagnosis and Control

Salmonella spp., NDV, chlamydia and mycotoxins should be considered in the list of differential diagnoses. The methods for demonstration of the virus are the same as with other PMV groups. Serologically, there are cross reactions with PMV-1. An exact differentiation is possible with monoclonal antibodies. An oil emulsion vaccine was developed in Great Britain to counteract the decrease of egg production in affected turkeys. Another inactivated vaccine produced sufficient immunity in budgerigars and canaries to withstand challenge.³⁵

PMV-5

Budgerigars are considered the host of PMV-5. The type strain is called Kunitachi virus²⁸⁹ and has been since lost. Possibly related strains have been isolated from free-ranging Rainbow Lorries and budgerigars from the same area of Australia.^{284,285}

Natural and experimental infections in budgerigars are characterized by acute diarrhea, dyspnea, torticollis and death. Affected budgerigars in Australia had severe diarrhea with a 50% mortality rate. Affected Rainbow Lorries became depressed, lethargic and had three to four days of diarrhea followed by death. Birds were typically anorexic but drank liberally.

Necropsy findings in budgerigars were limited to hyperemia of the parenchymatous organs. Rainbow Lorries had swollen livers and spleens and necrotizing-to-ulcerative or diphtheroid-to-hemorrhagic enteritis, with hemorrhages within the mucosa of the ventriculus and proventriculus as well as edema of the intestinal wall.

Histopathologic lesions included multiple necrotic foci in the liver and kidney with the development of giant cells. In Rainbow Lorries, extensive loss of the intestinal epithelium with desquamated necrotic material and erythrocytes in the lumen was common. Mild perivascular infiltration with lymphocytes was common in edematous intestinal walls. The differential diagnosis list should include *Salmonella* spp., NDV, *E. coli* and nutritional deficiencies. PMV-5 cannot be isolated via all the same methods as other PMV strains.

PMV-7

PMV-7 has been isolated only from Columbiformes. The type strain was isolated from doves in Tennessee,

and another isolate from the Rock Pigeon in Japan. All strains have a heat-stable hemagglutinin, and are considered apathogenic. Whether or not the Japanese and the New World strains are the same has not been determined.⁶

PMV-4, PMV-6, PMV-8 and PMV-9

These groups contain virus strains recovered from clinically healthy waterfowl located in the United States and Asia. PMV-4 is rather uniform and is apathogenic in chickens.⁵ The duck strains of PMV-6 may cause a mild respiratory disease and decreased egg production in turkeys.¹³ Isolates have been recovered by culture of tracheal and cloacal swabs.³⁷⁷ Details on PMV-8 and PMV-9 are limited. Carriers of PMV-4 and PMV-6 include Canada Goose, Common Teal, Common Pintail, Mallard, American Black Duck, Ring-necked Duck and Hooded Merganser.¹⁴⁸

Parainfluenza-2-virus (PI-2-virus)

The PI-2-virus, which belongs to the genus PMV, does not cause clinical disease or decrease in egg production in chickens. The virus can, however, be egg transmitted without influencing the embryonal development. The chicken PI-2-virus is identical to the agent that causes croupous pneumonia in humans. The PI-2-virus is important because it is not easily recognizable as a source of human infections and may be a contaminant in embryonated chicken eggs used for vaccine production.^{203,421,422}

Twirling Syndrome

This disease of uncertain etiology has been described in the African Silverbill, Zebra Finch, Gouldian Finch and related species.²⁷ Clinically, the sudden onset of torticollis and circling is conspicuous, but depression and weight loss are also evident. Clinical signs typically occur within one week of shipment from their place of origin. Some birds will be affected while others from the same shipment remain unaffected. Mortality may reach 20%. Some birds recover completely while others retain a permanent head tilt. Individual companion birds are also known to suffer from this disease. WBC may range between 2,000 and 14,000. Antibiotic therapy does not change the course of the disease. Pathology and histopathology have failed to implicate a specific etiologic agent, but a virus is suspected. PMV should always be considered in Passeriformes with neurologic signs.

■ Avian Pneumoviruses

The viruses of turkey rhinotracheitis and the swollen head syndrome in chickens are considered to belong to the same group and are classified as avian pneumoviruses. No other hosts have been incriminated as carrying this virus.¹⁴

Orthomyxovirus

The family Orthomyxoviridae consists of avian influenza virus (AIV) and all other influenzavirus taxons. Orthomyxoviridae are 80 to 120 nm diameter, segmented RNA viruses with helical symmetry containing glycoproteins that project from the envelope and have hemagglutinating and neuraminidase activity. Influenzavirus can be classified into two groups designated A and C.¹⁴¹ The specificity is provided by the nucleoprotein and matrix antigens. The nucleoprotein and matrix antigens of the influenza A virus isolated from birds, humans, pigs, horses, mink, seals and whales are closely related. Influenzavirus has a high rate of genetic recombination (particularly with regard to the hemagglutinins), so that “new” sero- and pathotypes (antigenic shift) frequently appear.⁸⁶

Hemagglutinin and neuraminidase antigenic sites may also vary slightly, possibly as expression of mutant selection under the pressure of increasing immunity within a given population (ie, antigenic drift).^{283,364} Many avian species, particularly large congregations of migrating birds, may serve as main reservoirs for virus recombination.^{22,23,88,154,209,210,221,288,322,387,398}

Influenza C is usually restricted to humans, but there are exceptions.⁸⁶ During a human outbreak of influenza (formerly called B) in Hungary, 4.1% of zoo and free-ranging birds examined had antibodies against the same virus type. Infections could be experimentally induced in Common Pheasants and Mallard Ducks.³⁴⁸

■ Avian Influenza A (AIV)

Infections with influenza A virus can cause subclinical to mild respiratory diseases, loss of egg production or generalized acute lethal disease. Acute lethal infection in domesticated chickens is called fowl

plague and is a reportable disease in many countries. The recovery of numerous virus strains of identical antigenicity from many avian populations for up to ten years indicates a continuing circulation of those strains.

Influenza A virus is divided into subtypes according to the antigenicity of its hemagglutinin and neuraminidase. Thirteen hemagglutinins and nine neuraminidases have been distinguished to date (H1 to H13 and N1 to N9).⁴²⁹ The nomenclature proposed by the same committee includes the type (A or C), host of origin (except human), geographic origin, strain number (if any), the year of isolation, and in parenthesis, the antigenic description of the hemagglutinin (H) and neuraminidase (N).

The presence of closely related surface antigens does not correlate with virulence in various avian species;² therefore, attempts to classify them according to virulence have been made. However, the interaction among a given virus strain, the host species and environmental factors is poorly understood. AIV with H1, H5 and H7 antigens are considered pathogenic for chickens but there are many exceptions.²

A/turkey/Ontario/7732/66/H5N is highly virulent for chickens and turkeys (up to 100% mortality) but is avirulent for ducks. One reason for this difference may be the tissue affinity. Strains staying “locally” in the respiratory or digestive tract usually have a low virulence; those that generalize have a high virulence. Tissue receptors in humans and many mammals differ, and this may be also true in birds. Highly virulent AIV strains possess a hemagglutinin that is readily cleaved and recombined in various host cells. The type of host proteases is important to cleavage and governs the extent of virus replication.⁸⁶

AIV is distributed worldwide and has a large host spectrum that includes domesticated ducks and geese, free-ranging ducks and geese, chickens, turkeys, guineafowl, chukars, quail, pheasants, sandpipers and sanderlings, turnstones, terns, swans, gulls, herons, guillemots, puffins and shearwaters.^{3,32,33,34,147,172,374,383} Latent infected carriers also occur. AIV has been isolated from captive birds including Indian Hill Mynahs, various Psittaciformes (Sulphur-crested Cockatoo, African Grey Parrot, budgerigar), Passeriformes, Accipitriformes and Musophagiformes (Lady Ross’s Turaco, Purple-crested Turaco, White-crested Turaco, Black-billed Turaco, Guinea Turaco).^{86,87,147}

Transmission and Pathogenesis

AIV is distributed around the world by migration of many avian species. Infected birds can shed the virus via respiratory secretions, conjunctiva and feces. Transmission through direct contact and indirect transmission through vectors is possible. There is no information on vertical transmission, although contaminated egg shells can distribute the agent (probable exception is the Helmeted Guineafowl). Clinically normal free-ranging birds such as ducks, geese and Passeriformes (mainly starlings) have been shown to transmit the virus to chickens and turkeys. Clinically affected free-ranging birds have been known to infect domesticated birds. Birds can serve as reservoirs for human and mammalian influenza A infections. Theoretically, humans may also be able to infect their companion birds.

Highly virulent strains of influenza A induce a viremia that is more prolonged than that caused by paramyxovirus. Thrombocytopenia occurs and is followed by a terminal hemorrhagic diathesis. The pathogenesis of less virulent strains in avian species has not been determined.

Clinical Signs and Pathology

For chickens and turkeys refer to Easterday, et al.⁸⁶

A/Tern/South Africa/1961/H5N3 was isolated from common terns and caused an acute to peracute disease in these birds in South Africa. The AIV strain was very closely related to A/chicken/Scotland/1959/H5N3 which, 17 months earlier, had caused a serious epornitic in chickens that was traced to sea birds (Herring Gulls and Kittiwakes). Experimental infections of chickens with the ternvirus caused clinical signs and pathologic lesions similar to fowl plague.³⁴

A/pheasant/Washington/1985/H9N9 was isolated from young (two- to eight-week-old) Common Pheasants experiencing a 25 to 35% mortality rate. Adult birds did not show any clinical signs although they were infected and probably excreted the virus over several weeks. Gross pathology included severe air sacculitis, catarrhal tracheitis, purulent rhinitis, fibrinopurulent polyserositis and splenomegaly. Histopathology revealed fibrinous polyserositis with predominant infiltrations of heterophils. Diffuse congestion and interstitial fibrinous secretion were evident in the lungs. The tunica propria of the ventriculus contained multifocal aggregations of lymphocytes.⁷⁵ The strain was nonvirulent for chickens and domesticated ducks.

Several flocks of Helmeted Guineafowl in Hungary had decreased egg production (30 and 40%) with normal and reduced hatchability (40 to 50%). Embryonic death following two weeks of incubation was common. Birds died with no clinical signs or following a period of respiratory disease characterized by listlessness and cyanosis. Nervous involvement was observed in the form of incoordination. Some affected birds had no pathologic lesions while others had air sacculitis and petechiation of the serosal and mucosal surfaces of the proventriculus. The virus could not be transmitted experimentally to chickens, ducks, mice or guinea pigs. The virus strains isolated from two flocks were antigenically variable.⁴⁰² The strains were closely related to A/quail/Italy/1117/65.³³⁶

Infections have been documented in breeding flocks of Japanese Quail in Northern Italy. Two different AIV strains have been isolated, with one being A/quail/Italy/1117/65. Environmental factors influence the severity of an outbreak with mortality varying from 15 to 80%. Clinical signs are somnolence, sneezing, nasal discharge, swelling of the sinus infraorbitalis, lacrimation and dyspnea. A few birds are ataxic and have convulsions. At necropsy, a catarrhal-to-fibrinous-to-purulent rhinosinusitis and tracheobronchitis is seen as well as a focal-to-confluent, disseminated, cellular, fibrinous pneumonia. Fibrinous pericarditis, air sacculitis, submiliary pancreatic necrosis, hyperemia and edema of the brain with focal demyelination may also be seen.¹⁴⁷

The clinical and pathologic lesions associated with AIV infections in Psittaciformes vary with the virus strain. A/Sittich/Germany/433/70 was isolated from a Sulphur-crested Cockatoo.¹⁴⁷ The majority of viruses isolated from parakeets and parrots have H5- or H7-related hemagglutinins. Affected birds have a two-week course of lethargy and CNS signs (loss of balance, ataxia, torticollis). Mortality rates may reach 30% with virulent strains. At necropsy, hemorrhages in the brain and swelling of the spleen are characteristic. Encephalitis is usually not present.

An AIV related to A/chicken/Brescia/65 was isolated from an African Grey Parrot. The bird was depressed, had dark green feces and died a few days after clinical signs developed. Congestion of the digestive tract was the only gross lesion noted. AIV was also isolated from Yellow-crowned Amazons, Plum-headed Parakeets, Rose-ringed Parakeets, Singing Parrots and Lesser Sulphur-crested Cockatoos.¹⁴⁷

Experimental infections of budgerigars with A/Budgerigar/Hokkaido/1/77/H4N1 showed that virus replication occurred principally within the nasopharyngeal cavity, trachea, esophagus and lungs. Only birds that were in poor condition developed clinical signs including rough plumage, diarrhea and death. The infected budgerigars did not develop HI antibody titers, which were also poor following booster infection. Generally, budgerigars do not have good humoral antibody responses to many antigens.

Anatiformes are relatively resistant to influenza and are considered a natural reservoir.²⁹⁹ About 25 to 30% of all free-ranging ducks and geese in the Northern hemisphere carry AIV. The isolated strains have highly variable hemagglutinin and neuraminidase antigens. Chariidriiformes (21.4% in Russia) are also considered to be reservoirs.¹⁴⁷ Infected waterfowl may not show clinical signs unless severely stressed by concomitant infections or transportation. Birds shed the virus by the fifth day post-infection and continue to shed for several weeks.

If clinical signs occur, they include depression, anorexia, dyspnea, swelling of the sinus infraorbitalis, lacrimation and diarrhea. Occasionally, CNS signs occur, but because these are a common premortal finding in ducks and geese, these CNS signs are considered nonspecific. The disease lasts about three weeks with mortality rates from 10 to 40%.¹⁴⁷ At necropsy, caseous exudation within the sinus infraorbitalis, fibrinous air sacculitis, polyserositis and tracheitis are common. Microscopically, an interstitial pneumonia may be present.

Replication of AIV in waterfowl takes place in the mucosa of the caudal part of the intestinal tract. Affected birds do not develop humoral antibodies, suggesting that the antigen does not contact cells of the immune system or does not elicit an immunologic reaction (Kösters, unpublished).

AIV with H3 or H11 has been isolated from Musophagiformes (turacos). These strains are pathogenic only for Musophagiformes and experimentally are not transmissible to Gruiformes, Columbiformes, Psittaciformes or Piciformes. Clinically, anorexia, somnolence and severe dyspnea occur. Mortality can reach 20%. The disease takes a course of approximately two weeks and survivors develop HI antibodies. Pathology reveals a heavy bilateral congestion of the lungs as well as hyperemia of the liver and kidneys.¹⁴⁷

A/carduelis/Hannover/1/72/H1N also designated Co-Ca-Virus (Co=conjunctivitis; Ca=Carduelis-Canary)

has been isolated from a Siskin and is experimentally infectious to canaries.⁸⁷ Severe conjunctivitis is the principal clinical sign. Death occurs after two to four days. The postmortem examination does not reveal any lesions.

Diagnosis

The differential diagnosis list should include respiratory and gastrointestinal pathogens as well as PMV, *Chlamydia* sp. and *Mycoplasma* spp.

A definite diagnosis depends on the isolation and identification of the strain in question. Fowl plague-like conditions caused by highly virulent strains may be suspected due to the acute to peracute course and the hemorrhages at necropsy. Swabs from the cloaca and the upper respiratory tract are suitable for direct virus demonstration from live birds. Parenchymatous organs (lungs, liver, spleen, brain) provide the best postmortem sample for virus isolation. Samples are to be placed in sterile transport medium containing high levels of antibiotics to inhibit bacterial growth and shipped at no more than 4°C. For storage, -70°C or lyophilization is recommended. The final classification must be made by specialized laboratories (WHO reference laboratories).⁴²⁹ With high titer infections, virus can be demonstrated in the tissues by IF.

Indirect virus demonstration by serology is hampered by the fact that HI test does not recognize all antibody classes and reacts with nonspecific inhibitors. An ELISA is very sensitive but is no more specific than the ID (only group-specific antigen recognized), which is easier to run.^{86,401} Paired samples (acute and convalescent phase) are necessary to document an infection. A four-fold rise in titer is indicative of a recent infection. Sera should be kept frozen (-20°C) and 0.01% sodium azide should be added as a preservative.

Retroviridae

Avian retrovirus is separated into two genera. Avian type C retrovirus group (avian leukosis-related viruses) includes avian sarcoma and leukemia virus (SLV). The type species is avian leukosis virus.^{63a} A type C retrovirus that is unrelated to SLV is the causative agent of the lymphoproliferative disease

(LPD) in turkeys.^{41,63a,291} The avian reticuloendotheliosis virus is now a species within the genus mammalian type C viruses in the subgenus reticuloendotheliosis viruses.^{63a}

Retroviridae are enveloped viruses with knobs on the surface that form the outer part of membrane-associated protein spikes, which connect the capsid membrane and envelope. The helical virion measures 90-120 nm in diameter. The genome consists of a negative-sensed, single-stranded RNA. Retrovirus is further characterized by a reverse transcriptase (reverse transcriptase) that is necessary for the formation of a DNA provirus during viral replication, which takes place in the cytoplasm. Some retroviruses, particularly the sarcomaviruses, have an incomplete genetic code and need a helper virus (frequently an avian leukosis virus) for the production of infectious viral particles. The helper viruses serve mainly for the development of the envelope, and in such cases the new envelope can contain antigens from the helper virus. Type C retrovirus is assumed to have oncogenic taxons. Defective virus can transform the host cells, but infectious particles are not produced (ie, nonproducer cells). In addition to inducing neoplasms, avian retrovirus can also be immunosuppressive, which is enhanced by concomitant infection with other tumor-inducing viruses or infectious agents. All the immunologic organs can be involved (anemia, bone marrow fibrosis and bursal and thymic atrophy). Immunosuppression is probably due to cessation of B-cell maturation and a block in the development of T-cells, possibly because of interference with the synthesis of interleukin-2.³¹³

■ Avian Sarcoma/Leukosis Virus (SLV)

Avian SLV's share a common group-specific (gs) antigen and can induce neoplasms in chickens and to a lesser extent in other avian species. The group is differentiated into several types or subspecies based on susceptibility of genetically varied chicken fibroblasts, interference patterns with members of the same and different subgroups and viral envelope antigens recognized by VN antibodies.³¹³

Subgroup A and B occur as common exogenous viruses (infective viruses released by host cells without damage to the cell). Subgroup A is more commonly encountered. Antibodies to subgroup A and B are common among free-ranging wild fowl and domestic chickens. Subgroup C and D are rare. Subgroup E includes the ubiquitous, endogenous (retroviral genes that are integrated in the genome of gonad

cells and can be vertically transmitted to the offspring) leukosis virus. This virus has a low pathogenicity and functions principally as a helper virus for defective avian leukosis virus, allowing the production of group-specific antigens. Subgroup F has been isolated from the Common Pheasant and the Green Pheasant. Subgroup G is assumed to be different from the chicken strains. These strains have been recognized in Lady Amherst's Pheasant, Golden Pheasant and Silver Pheasant. Subgroup H consists of an endogenous virus isolated from a Hungarian Partridge. Subgroup I was isolated as an endogenous virus from Gambel's Quail. Endogenous viruses isolated from the Mongolian Pheasant, Swinhoe Pheasant, Painted Quail and chickens have not been classified.

The host spectrum is dependent on autosomally transmitted susceptibility or resistance of avian cells to receptors of avian retroviral subgroups (susceptibility = dominant, resistance = recessive). Genetic resistance can be selected for or manipulated.^{101,313} Subgroups may produce varying types of tumors, and many neoplasms occur in connection with defective viral strains that require a helper virus for replication.¹⁶⁵ Despite high rates of infection (more than 50% in some flocks), few birds (1 to 3%) actually die from a neoplastic disease. The types of neoplasias induced by the avian SLV group include fibrosarcoma/mesenchymoma, chondroma, osteochondrosarcoma, osteopetrosis, mesothelioma, endothelioma, hemangioma, undifferentiated stem-cell leukemia, lymphoid leukemia, myeloblastosis/monocyte leukemia, myelocytosis, myelocytomatosis, erythroblastosis (medullary or leukemic), nephroblastoma, renal adenoma/adenocarcinoma, ovarian cystadenoma/adenocarcinoma, thecoma, granulosa cell tumor, seminoma, hepatoma, pancreatic adenoma and carcino-/fibrosarcoma of the intestinal mesentery.³¹

Etiologic confirmation of neoplastic induction has been conducted only for the chicken and turkey. In all other species, the leukotic sarcomatous disease processes are classified according to pathomorphologic and histologic lesions. Virus isolation has been successful only within the order Phasianiformes. Some neoplasms documented in captive-bred companion and aviary birds may prove to be induced by SLV. Because many birds bred in captivity are endangered, more investigations are necessary in order to recognize genetically resistant host groups. The gs antigen of SLV has been described in budgerigars; however, the birds in question were aleukotic.²⁹⁰

Lymphoid leukosis is the most common type of retroviral-induced tumor seen in birds. This neoplastic condition has been described in Gruiformes, Sphenisciformes, Columbiformes, Psittaciformes, Strigiformes, Falconiformes, Ciconiiformes, Anati-formes and Passeriformes.^{28,55,150,179,420}

Erythroblastosis, myeloblastosis and stem-cell leukemia have been documented in canaries, and erythroblastosis has been diagnosed in a Sulphur-crested Cockatoo. Myeloblastic leukosis has been reported in the Sulphur-crested Cockatoo, budgerigar, Turquoise Parrot and Pacific Parrotlet. Leukemic erythroblastosis has been observed in the Rufous-tailed Weaver and Ultramarine Grosbeak. It is unclear if “erythremic myelosis” in conures (hemorrhagic conure syndrome)³⁵¹ should be classified with this group of tumors.

Osteopetrosis has been induced experimentally in guineafowl chicks infected with a virus originating from chickens. Beside the typical bone lesions, the infected birds developed epithelial tumors of the pancreas and the duodenal mucosa.²¹⁵

Transmission

Vertical transmission by gonadal cells (virus in the albumen of the egg) or virus genome (also incomplete) in the haploid egg and semen cells is important. Chicks infected as embryos or very early post-natally remain viremic and do not produce antibodies (immune tolerance). Horizontal infection takes place through contaminated feces and saliva, and antibodies are produced that are not protective. Life-long infections are common.

Decisive age resistance is probably due to the regression of the cloacal bursa. Females are more susceptible to infection than males. Testosterone administration decreases susceptibility and castration of males increases susceptibility. SL affects birds mainly at the time of sexual maturity or later. The incubation period requires months; however, depending on the species involved, virus strain, dose and susceptibility of the host, the incubation period can be short, resulting in an “acute” onset of disease.

Pathogenesis

Depending on the type of oncogenic genes (erythroblastosis, myeloblastosis, myelocytoblastosis), infections with oncogenic strains produce either very small foci of transformed B-lymphocytes (lymphoid strains that have no specific oncogene) in the cloacal bursa or leukocytic precursor cells in other organs,

which can disappear or metastasize into a variety of organs (mainly liver, spleen, kidneys) where macroscopic neoplasms are being developed. These tumors are usually malignant and ultimately kill the affected bird.

Clinical Disease and Pathology

A clinical diagnosis depends on identifying visible or palpable tumors. The patient’s general condition and ability to fly are frequently undisturbed for a relatively long time. Abdominal enlargement and dyspnea caused by the space-occupying tumors can occur in advanced cases. A massively distended liver may be palpable. Hematology, especially differential smears, are frequently nondiagnostic because avian leukosis rarely results in a leukemic blood picture (ie, tumorous blood cells or their precursors in the peripheral blood). An increase in leukocytes (heterophilia, lymphocytosis and monocytosis) is common. In many instances, the lymphocytes are mature, but in Amazon parrots and chickens, bow-formed pseudopodia may be visible. The AST may be increased if the liver is affected.

SLV causes a variety of non-neoplastic conditions, of which immunosuppressive disorders and suppression of thyroid function are the most important. The latter is considered one cause of stunting in growing chickens.³¹³ At necropsy, multiple tumors of the liver and spleen, more rarely the kidneys, subcutis, periorbital cavity, heart, lungs, ovary, intestine and cloacal wall are seen. A retained cloacal bursa is suggestive. Affected organs are diffusely swollen with or without a grayish mottled surface and a soft consistency.^{244,313} The differentiation of myeloblasts is difficult. One method is based on location: erythrocyte-series myeloblasts develop intravascularly, myeloblasts of the other series develop extravascularly.

Diagnosis

Neoplasms induced by other agents are solitary, while SLV generally causes multiple tumors. In chickens, Marek’s disease virus usually affects younger birds and involves nervous tissue, which is rare with SLV-induced tumors (see Chapter 25).

Plasma, serum and neoplastic tissues are best for demonstrating the presence of virus. The virus can also be isolated from oral washings, feces, feather pulp and from the albumen of freshly laid eggs. Samples should be shipped immediately in cooled containers because the virus is heat labile.^{244,313} Antemortem diagnosis can be determined using biopsy, endoscopy or differential blood smears. Pathologic

and histopathologic lesions are suggestive. The presence of a retrovirus can indirectly be determined by the demonstration of the reverse transcriptase from neoplastic organs.

Treatment and Control

Treatment is generally ineffective in advanced cases. Experimental application of an androgen analogue “mibolerone” in chicks between the 1st and 49th days of life has been shown to prevent leukosis. The drug is anabolic and had no deleterious effect on egg production.³¹³ This drug has not been investigated in companion birds. Selection of genetic resistance in the presence of the virus is a useful tool and should be applied wherever possible. The subtype in question should be determined, and the help of a geneticist is necessary. Another hypothetical method includes testing of all breeders for antibodies and antigen in the reproductive cells (female: egg albumen; male: semen), and infected birds should be excluded from breeding. This would allow the production of virus-free flocks; however, this situation may increase the susceptibility of the flock. Vaccines are not available.

Erythremic Myelosis in Conures (Hemorrhagic Conure Syndrome)

This condition has been recognized as an endemic disease in Blue-crowned Conures, Peach-fronted Conures, Orange-fronted Conures and Patagonian Conures. Periodic recurrence of eventually fatal bleeding is characteristic of the disease.³⁵¹ During these bleeding episodes, proliferations of erythroblasts are present in the hepatic sinus and in the pancreas. Normal bone marrow is replaced by immature red blood cells suggesting erythroleukosis. A viral etiology (retrovirus) has been suggested, but has not been proven. Calcium deficiencies are believed to trigger the disease.

Clinical Disease, Pathology and Diagnosis

Epistaxis, dyspnea, severe weakness, intermittent polyuria and diarrhea and occasionally ataxia are common. Clinical pathologic changes include packed cell volume of approximately 26%, leukocytosis represented by heterophilia (84%), severe polychromasia and anisocytosis, decrease of the total protein, hypoglycemia and hypocalcemia, elevated creatinine and large numbers of immature erythrocytes in the peripheral blood.

At necropsy, multiple pulmonary hemorrhage, development of pseudocysts in the pectoral muscles and

pericarditis are common. Histopathology reveals large numbers of erythroblasts in the sinus of the liver and in the pancreas. Hemorrhages may be noted in the lungs, and hemosiderin has been described in pulmonary macrophages around blood vessels, bronchi and in the air sacs. Hyperplasia of the bone marrow by proliferation of immature erythrocytes can take place.

Clinical pathology changes, bone marrow aspiration and histopathology are the only currently available diagnostic tests. All therapeutic regimes have been unsuccessful. Administration of calcium can prolong a bird's life and may stabilize the patient's condition.

Avian Reticuloendotheliosis Virus (REV)

REV differs from SLV and is related to certain mammalian REV. As with SLV, several subspecies or subgroups that are closely related, but differ in antigenicity and pathogenicity exist. These include reticuloendotheliosis virus (Twiehaus),^{84,436} duck infectious anemia virus, spleen necrosis virus, chicken syncytial virus (CSV),^{84,436} nonclassified isolates from Muscovy Duck, visceral lymphomatosis of the Common Shelduck¹⁵¹ and racing pigeon (serologic evidence in 0.1% of examined sera).¹⁶¹

Some of the viruses in this group have oncogenic properties and induce tumors principally of lymphoreticular or reticuloendothelial cells. Occasionally, these viruses are associated with other neoplasms such as histiocytic sarcoma, fibrosarcoma or myxosarcoma.^{434,435} Non-neoplastic lesions due to degenerative-inflammatory processes are common. As with SLV, defective strains that require helper viruses to replicate do occur.^{84,436}

The natural hosts are probably turkeys and waterfowl; however, chickens, ducks, geese and Japanese Quail are also susceptible to natural infection. Experimental infection is possible in pheasants and guinea fowl.

Transmission and Pathogenesis

Horizontal transmission occurs among young birds when viremic animals shed the virus via feces or in body fluids. Mosquitos, particularly *Culex annulirostis*, are reported to be capable of transmitting the virus after feeding on a viremic bird. Vertical transmission is possible, but only at a low rate with eggs (albumen) and semen. The virus replicates primarily in the reticular and endothelial cells along the capillary walls. There is no detailed knowledge on the

mechanisms for entering the host cells, but differentiated receptors are indicated by different reactions in various genetic host lines. Following adhesion of the virus there is a proliferation of cells originating from primitive mesenchymal type or the reticulum associated with lymphoid tissue. The type of cells is the same in all susceptible bird species. These proliferating cells can also invade nervous tissues but, in contrast to Marek's disease virus, are not lymphocytes. In contrast to SL, most REV-induced neoplasms occur in young birds, although some chronic cases have been reported. Infections of neonates or young birds that are not immunocompetent result in immunosuppression triggering a rapid proliferation of cells carrying the appropriate oncogene. Infection with REV induces a transient or permanent disturbance of the immune system. The mitogenic stimulation of B- and T-cells is inhibited, as is the activity of the cytotoxic T-lymphocytes (the portion of the immune system directed against neoplastic cells). Suppressor T-lymphocytes are activated, which inhibits the normal proliferation of lymphocytes.⁸⁴

Diseases Caused by the Twiehaus-type Strains

Twiehaus-type strains are transmissible to chickens, Japanese Quail, ducks, pheasants and guinea fowl.

- **Turkeys:** A case in a free-ranging turkey has been reported.²³⁸ Incubation period in turkeys is 8 to 11 weeks. Morbidity can reach 10 to 33%, but the mortality of clinically ill birds is high (30 to 60%). Turkeys suffer from diarrhea and occasionally from lameness. Some animals die without prior clinical signs. The highly distended liver is palpable. Clinical chemistry shows an increase in serum transferrin and globulin levels, but a decrease in albumin. Hematologic changes are evident only shortly before death.⁴³⁶

At necropsy the liver is several times larger than normal or it may show multiple small tumors that may also be present in the spleen, kidneys, gonads, thymus, cloacal bursa and bone marrow.

Histopathology shows infiltration of lymphoreticular cells (vesicular nucleus with mainly two nucleoli, light blue cytoplasm following HE staining and numerous mitoses) that replace a high amount of the parenchymal tissue. These cellular infiltrates are also present in peribronchial and pulmonary interstitial tissue as well as in the mucosa, submucosa, tunica muscularis and serosa of the intestine. The villi may be club-shaped. Focal infiltrates may occur in the kidneys and peripheral nerves.

- **Differential Diagnosis:** The rule-out list includes SL and LPD. In addition to microbiologic methods for viral demonstration and identification, SL can be suggested histopathologically by the appearance of uniform cells in tumorous tissues. RE and LPD are difficult to differentiate. Splenomegaly (pale pink, mottled surface) and minor swelling of the liver are characteristic for LPD. In many cases of LPD, the thymus is enlarged, although the cloacal bursa is normal. RE usually induces neoplasia in the digestive tract, which is less common with LPD, in which more severe lesions occur in the pancreas. In both diseases, pleomorphic cells (lymphocytes, lymphoblasts, RES cells and plasma cell) are common; however, in LPD, less mitosis is present in the more mature cells.¹⁸¹

- **Japanese Quail:** It is assumed that strains from these birds belong to the Twiehaus-type because of their high neoplastic potential. Because the REV are serologically related, cross-reactions between subgroups are to be expected.^{57,356} In contrast to outbreaks in other birds, the disease appears shortly after sexual maturity (six weeks in Japanese Quail) and lasts for several months. Mortality can reach 100% in birds with depression, anorexia and dyspnea.⁵⁷

The most striking and consistent lesions are thickenings and nodular foci along the digestive tract (crop, proventriculus, ventriculus and intestine, including the ceca), liver, spleen, lung, heart, pancreas, kidney, ovary, testes, mesentery, thyroid gland, skin and ischiatic nerve. Histopathologic examination reveals the same type of cells as described in turkeys.

- **Pheasants:** An etiologic agent related to the REV Twiehaus-type strains has been isolated from pheasants (Pheasant-REV-Hungary-1) (Ph-REV-H-1).⁸³ The disease occurred in approximately six-month-old pheasants that displayed compact nodules in the skin of the head and on the oral mucosa. The infraorbital sinuses were filled with inspissated material, which caused bulging of the cheeks and the anterior aspect of the eye sockets. The surface of the nodules was occasionally necrotic and covered with pseudomembranous deposits reminiscent of fowl pox. Small grayish nodules in many other organs (ingluveal wall, spleen, liver, kidney, lung, air sacs and skeletal muscles) were evident at necropsy. Histopathology revealed extensive infiltration of neoplastic lymphoblast cells into the corium of the skin or the oral mucosa. Hemorrhage and inflammatory cells were infrequently recognizable in the neoplastic tissue. The presence of a few PSA-positive cells suggests

Russel bodies consistent with plasma cells. No Bollinger bodies were demonstrable in the epithelial cells of the affected cutaneous regions.⁸³

- **Ducks:** The disease has been observed mainly in Australian free-ranging and domestic ducks. The incubation period is estimated at five to nine weeks. The final classification of the virus is still pending. Clinically, depression and ruffled plumage are noted prior to death. At necropsy, the liver and spleen are soft and enlarged. The surface and cross-sections display multiple, yellow-white foci. Tumors in heart and skeletal muscles are present as well as in the duodenum, pancreas, ventriculus and proventriculus. Histopathology reveals the same type of cells as described for turkeys in the form of perivascular foci in the liver, spleen, lungs, kidneys, brain, spinal cord and the sciatic plexus.
- **Domesticated Goose:** The virus is related to the Twiehaus-type strains and is designated REV-Hungary-2.⁸² The disease starts at 17 weeks of age and the mortality rate increases to 40% by the 22nd week of life. Affected birds are listless, emaciated, have ruffled plumage and are frequently lame. The spleen and liver are usually enlarged and mottled with irregular yellow-white areas throughout the organs. Other organs show predominantly nodular foci (pancreas, intestine and occasionally heart, kidney and lung). Histopathology reveals primarily lymphoblast-type cells in the organs affected by visible tumors, but the adrenal and thyroid glands, bone marrow, gonads, thymus and cloacal bursa may also be involved. The nervous system is unaffected. Occasionally, amyloid deposits are seen in the walls of the capillaries in the liver and spleen.⁸²

■ Duck Infectious Anemia Virus (DIA)

DIA can be transmitted by *Plasmodium lophurae*, one of the agents of avian malaria. Its main host is the Crested Fireback, but it can also parasitize chickens and ducks. The virus remains present even if the *Plasmodium* is experimentally passaged through canaries, turkeys or mosquitoes. In ducks, the virus can be found in peripheral blood cells and in the plasma. The disease is extremely rare and non-neoplastic.²⁴⁸

Anemia is severe and frequently followed by death, even if the plasmodium infection has been treated successfully. The virus can be neutralized by antiserum.

■ Spleen Necrosis Virus (SNV)

Transmission of SNV takes place by direct contact. The incubation period is seven to ten days. Clinically affected birds have a short course of depression, anorexia and anemia, followed by exitus. Anemia may be diagnosed shortly before death. At necropsy, the birds display conspicuous hemorrhages and necrotic lesions of the spleen. Histopathologically, a proliferation of reticuloendothelial cells in the liver, spleen and kidneys is evident.

■ Unclassified Isolates

Muscovy Ducks

About 10% of six-month-old Muscovy Ducks (700 birds) died within a 13-week period. Nucleic acid hybridization experiments indicated the presence of REV.²⁵² After one year without any new cases, a second outbreak occurred at the beginning of the next laying period. Undifferentiated blast cells, assumed to be of lymphoid origin, were prominent in peripheral blood smears of affected birds. These cells were cytochrome-oxidase negative and contained coarse and fine granules of PAS-positive material.

At necropsy, tumors were seen in the thymus (40%), liver, spleen, lung, kidney, pancreas and intestines. Histologic examination showed virtually all organs to be diffusely infiltrated by cells of a fairly uniform appearance with intensely basophilic cytoplasm (can be indented) and nuclei with distinct nucleoli. Numerous mitotic figures were evident. Electron microscopy revealed neoplastic cells consistent with undifferentiated lymphoblasts.²⁵²

■ Diagnosis (All REV)

The lack of characteristic lesions, variability of lesions and similarity of lesions caused by different etiologies make diagnosis difficult. Direct and indirect methods of viral demonstration are necessary. Heparinized blood, plasma, leukocytes or homogenates from tumorous tissues are suitable for virus isolation. Cell-free material should be stored at minus 60°C. Cellular material can be stabilized by being treated with 7.5 to 10% dimethylsulfoxide followed by storage in liquid nitrogen. REV normally does not cause CPE, necessitating IF or ELISA to demonstrate the presence of intracellular antigen in cell culture. Monoclonal antibodies have been used to classify antigenic relationships between the groups. ELISA, IF or ID can be used for demonstrating antibodies.

Picornaviridae

Picornaviridae are the second smallest RNA virus known, with a diameter of 20–40 nm. They are nonenveloped, have a cubic morphology with 32 capsomeres and single-stranded RNA. Five genera (Enterovirus, Hepatovirus, Rhinovirus, Aphthovirus and Cardiovirus) can be distinguished.^{276a} Of the five genera only Enterovirus has been shown to cause problems in birds. Infections may be asymptomatic or can be characterized by gastrointestinal involvement; CNS signs and hepatopathy may or may not occur.

Information is available elsewhere on turkey viral hepatitis and infectious nephritis.^{388,184}

Avian Encephalomyelitis (AE)

The classification of AE is still uncertain. The four virus-specific proteins are larger than those usually associated with Picornaviridae.⁵² The AE virus is distributed worldwide. The main host is the chicken, but natural infections have been documented in pheasants, Japanese Quail, waterfowl and turkeys. Antibodies following natural infection (without clinical disease) were found in partridges, probably Rock Partridge and Red-legged Partridge, as well as pheasants and turkeys.^{42,395} Egg transmission plays the main role in epornitics. Horizontal transmission distributes the virus within the flock inducing latent carriers. Flocks infected during the breeding season will produce two to four infected clutches.

Pathogenesis

Age resistance occurs by six weeks. Only young birds without maternal antibodies or those that are not immunocompetent develop CNS signs, probably because these circumstances allow the virus to reach the brain. Virus in the intestinal tract does not induce clinical signs in nonproducing birds. Infected layers will have a decrease in egg production (five to ten percent). Humoral antibodies induce immunity. Vertical transmission in chickens results in life-long CNS signs (such as incoordination and visual defects) together with good egg production. These birds have no detectable antibodies (Kösters J, unpublished).

Clinical Disease and Pathology

Descriptions are available only for the chicken.⁵² Survivors can develop ocular lesions including enlarge-

ment of the eyeball, marked opacity of the lens, seemingly fixed pupils and total blindness. Blindness may also occur in Black Grouse and capercaillie raised with AE-vaccinated chickens. In domesticated turkeys, 1% of the poults may show CNS signs including tremors, ataxia and incoordination. About 30% of the sick turkeys may die.¹⁴⁴ It is unknown if free-ranging turkeys in the United States have contracted the disease. Spontaneous recovery from CNS signs has been observed, especially in non-chickens.

Differential Diagnosis and Diagnosis

Encephalomalacia (vitamin E and selenium deficiencies) is the main rule-out. Diagnostic therapy might be indicated. Intoxications, particularly those with a heavy metal (lead) must be considered. In pheasants, infections with Togaviridae are possible in the appropriate season.

Histologic changes are strongly suggestive. Nonpurulent encephalitis, degeneration of the large motoric nerve cells within the cervical and lumbar medullary marrow, central chromolysis and degeneration of Purkinje cells, focal proliferation of microglia (particularly in the cerebellum) and perivascular mononuclear cell infiltrates in the proventriculus, pancreas and heart are characteristic. Perivascular infiltrates consist mainly of lymphocytes, and proliferation of lymph follicles may also be noted.¹⁴⁴ Virus can also be demonstrated indirectly by serologic means (IF).

For confirming the immunity of breeding flocks, an egg neutralization test with an egg-adapted virus strain can be performed. In eggs that are free of antibodies, a characteristic dystrophy of the skeletal muscles is seen. Serologic examinations are possible with ID and ELISA.

Control

Several types of vaccine are available. Inactivated vaccine injected IM is suitable for birds without humoral antibodies that are ready for breeding and under conditions where the spread of the virus is to be prevented. Live vaccines given orally may also be suitable, but the vaccine should not contain egg-adapted strains, because these have lost the ability to infect via the intestinal tract. Live, adapted, field strains given by wing web can cause clinical signs, and therefore are not recommended for fancy chicken breeds or non-gallinaceous birds.

■ Duck Virus Hepatitis (DH)

Three types of DH infection are distinguished.

Type I has a worldwide distribution and causes high mortality (up to 100%) in domesticated *Anas platyrhynchos* ducklings, mainly during the first week of life. A distinct age resistance (three to six weeks) is seen in which younger birds are protected by maternal antibodies. In Europe, where chlamydial infections are endemic in ducks, the typical course of the disease can be altered. Infection with *Chlamydia psittaci* concurrently with DH virus can overcome the immunity to DH virus in ducklings older than four weeks. In these birds, hepatopathy as well as duck fatty kidney syndrome and focal pancreatic necrosis have been described.⁹² Clinical signs include peracute onset of depression followed by CNS signs (nonspecific) and death. Postmortem findings include hepatomegaly, splenomegaly and petechial hemorrhages on most parenchymatous organs.

Mallard ducklings are susceptible to the virus, but generally remain asymptomatic.¹²⁹ The same is true for domesticated *Anser anser* goslings. Experimental infection in turkeys and quails induces low mortality. High mortality occurs in experimentally infected pheasants, geese and guineafowl.¹⁸⁰ The virus has been isolated occasionally from several duck species maintained in zoos, although it is questionable whether or not this virus was the cause of death. The Brown Rat may serve as a vector. Two variant strains have been isolated; their relationship to Type I has not been established.⁴⁴¹

Type II has been isolated only in East Anglia, United Kingdom. In contrast to Types I and III, it is an astrovirus (antigenically different from astrovirus isolated from chickens and turkeys) that has been associated with 10-50% mortality in ducklings, depending on their age. All the recorded outbreaks have initially involved ducks kept in open enclosures, so that all free-ranging birds and gulls are suspected to be vectors.⁴⁴¹

Type III has been isolated only in the United States. The virus is not related to Type I. Diseases are generally less severe than those caused by type I with mortality rates rarely exceeding 30%. *Anas platyrhynchos* ducklings appear to be the only susceptible species.⁴⁴¹

Control

Viral-specific convalescent serum can be used in newly hatched ducklings. A vaccine is available for

Type I that can be used in breeder stock to ensure high titers of maternal antibodies. A live avirulent vaccine can also be used in ducklings in the face of an outbreak.⁴⁴¹ Recovered ducklings are considered immune.

■ Viral Enteritis in Cockatoos

Free-ranging Sulphur-crested Cockatoo and galah (Rose-breasted Cockatoo) chicks (seven to nine weeks old) developed profuse diarrhea and wasting and died shortly after being captured. The incidence of this disease (1,000 to 2,000 birds) is considered to be 10-20% annually in which galahs represented the higher percentage of affected birds. Clinical signs included yellow-green and mucoid feces beginning two to seven days after capture. Affected birds were anorexic, depressed, lost weight and became dehydrated following the onset of diarrhea. All affected birds eventually died or were euthanatized after one to four weeks of clinical disease. The birds failed to respond to treatment with various antibiotics and electrolytes.²⁷²

At necropsy, the duodenum and the upper jejunum were dilated by yellow-green mucoid fluid and gas, and the walls were distinctly thickened. The birds were dehydrated, and the liver, kidneys, thymus and cloacal bursa were hypoplastic.

Histopathologically, the villi of the duodenum and the upper jejunum were short, occasionally with some fusions. The crypts of Lieberkühn were markedly elongated. Proliferation of the epithelial cells in the crypts resulted in a thickened layer of enterocytes. Mild-to-moderate infiltrates of macrophages and lymphocytes were present in the lamina propria. Hyperplasia of cortical cells in the adrenal gland was seen in some birds.⁷²

Particles with the morphologic features of an enterovirus were detected in 18 out of 31 birds by electron microscopy. Because no virus could be isolated in embryonated chicken eggs, as is frequently the case with entero-like virus, the etiologic importance of the particles could not be determined.

TABLE 32.17 Reference Data on Common Avian Viruses

Virus	Incubation	Environmental Stability	Disinfectants	Control
Adenovirus	Natural infection 24-48 hours, slow spread in flock	Stability varies with isolate, resistant to many disinfectants, resistant to chloroform, 60-70°C, pH 3, pH 9	Formalin, aldehydes, iodophors (requires 1 hour of contact)	No vaccine, vertical transmission, continuous infectivity cycle
EEE & WEE virus	1-7 days	Stable when refrigerated	0.2% formalin, 3% phenol	Horse vaccine for pheasants
Enterovirus	1-7 days transovarial, 11 days with horizontal transmission	Extremely stable, resistant to chloroform, pH 3, 56-62°C for hours	1% formaldehyde, 2% caustic soda, 2% calcium hypochlorite (3 hours), 5% phenol, undiluted clorox	AE vaccine, several types, see text
Herpesvirus - PDV	Natural outbreak, 3-7 days, experimental, 48 hours	Unstable, cell associated or mucus coated virus more stable, 56°C for 1-5 minutes	Most disinfectants probably effective	Killed vaccine
Herpesvirus - AT	Experimental, 3-4 days			ILT vaccine protects chickens from AT, efficacy of ILT vaccine in Amazon parrots is unknown
Budgerigarherpes	Unknown	Unknown		Interrupt breeding to increase Ab titers
Herpesvirus - DVE	3-4 days			Live attenuated vaccine, protect ponds from free-ranging waterfowl
Herpesvirus - ILT	6-15 days			Chicken vaccine, but not for pheasants
Herpesvirus - PHV	Experimental, 7 days Natural outbreaks, 5-10 days	56°C for 30 minutes		Experimental vaccines decrease clinical signs
Herpesvirus - FHV/OHV	Experimental, 3-10 days depending on virus and host			No vaccine, avoid mixing infected and non-infected birds, artificial incubation and hand-rearing
Influenza	Few hours to 3 days, varies with virulence, route of exposure and avian species	Unstable	Most disinfectants	Ultraviolet radiation, temperature increases
MSD pheasants Adenovirus Group II	6 days with oral infection			Oral vaccination of chicks (4-6 wks), chicks with THE or avirulent MSD
Newcastle disease virus	Experimental, 3-7 days, 25 days in some	Daylight, up to 4 weeks room temperature, 56°C sensitive	Lysol, cresol, phenol, 2% formalin, oxygen, cleaving compound, resistant to most disinfectants	
Orbivirus	Experimental, 4-8 days	Extremely stable	pH 3, resistant to lipolytics	
Papillomavirus	Unknown, probably prolonged	Stable, ether, temperature extremes	See text	
Polyomavirus	Unknown, suspected to be days to weeks	Stable, 56°C for 2 hours	Chlorine dioxide, phenolic disinfectants, Clorox	Experimental vaccine protects macaws from BFD virus
Parvovirus	5-15 days, varies with age and antibody titer	Stable, resistant to organic solvents, pH 3, 56°C for 3 hours, Na hypochlorite, H ₂ O ₂ (1%)	Resistant to many disinfectants	Vaccinate breeder geese six weeks before egg laying (IM vaccine)
PBFD virus	Experimental (min 2-4 weeks), maximum unknown, may be months to years	Probably very stable, CAV stable to 60°C for 1 hour	Unknown	Experimental killed vaccine effective
Poxvirus	Varies (virus strain and host species) generally 1-2 weeks, canaries 4 days (10-12 days for hybrids)	Stable in soil for one year	Steam, 1% KOH, 2% NaOH, 5% phenol	Homologous or heterologous vaccines (see text)
Reovirus	Psittacine infected IM shed virus 2 days PI, geese 3-6 days, experimental, 3-9 days post-infection	Stable, pH 3, H ₂ O ₂ , 60°C for 8-10 hours	70% ethanol, 0.59% iodine, aldehydes/alcohols (2 hours)	Experimental inactivated vaccine may be effective
Retrovirus	Unknown	Unstable, stable pH 5 to pH 9, moderate ultraviolet radiation stability	Lipid solvents (detergents), thermolabile, freeze-thawing destroys	

Diseases with Infectious Characteristics but Uncertain Etiology

There are many clinical conditions that suggest a viral infection, and new ones are certain to be recognized with the advent of better diagnostic methods. Few of these conditions have been described sufficiently to be considered as reproducible pathologic processes. The so-called twirling syndrome²⁷ in the African Silverbill, Zebra Finch, Gouldian Finch and closely related species manifests signs that indicate the possibility of a paramyxovirus as the etiologic agent. The most important disease described in Psittaciformes of uncertain etiology but suspected to be a virus is the neuropathic gastric dilatation or proventricular dilatation (see Chapter 19).

Neuropathic Gastric Dilatation (NGD)

This disease has been observed since 1977.¹³² It is suggested that the problem has been imported with macaws from Bolivia. The various *Ara* spp. are considered most susceptible but the disease has been described in many other Psittaciformes including *Aratinga* spp., Nanday Conure and other conures, *Amazona* spp., *Pionus* spp., Hawk-headed Parrot, Grey-cheeked Parakeet, African Grey Parrot, Senegal Parrot and other *Poicephalus* spp., Eclectus Parrot, *Coracopsis* spp., *Alisterus* spp., *Cacatuninae* spp. and cockatiel.¹¹⁵ A disease with clinical and histologic lesions similar to those described with Psittaciformes has also been confirmed in free-ranging Canada Geese.⁷⁰

Since its first description in South America, the disease has spread to North America and European countries (United Kingdom, Germany, Switzerland, The Netherlands). Several possible viral agents have been described by electron microscopy, but none has been confirmed as the etiologic agent. Approximately 100 nm-sized particles were described in the neuronal perikaryon of the spinal cord.⁵⁰ Virus-like particles of 70-80 nm were described in the nuclei of the tubular epithelium of the kidney which were morphologically consistent with an adenovirus.¹⁶⁷ Intracellular and extracellular eosinophilic inclusion bodies were described in the neuronal perikaryon of

the celiac ganglion and the myenteric plexus, which revealed electron microscopically virus-like particles both inside and outside those inclusions. The morphology of those particles is consistent with paramyxovirus.²⁵³

Pathogenesis

The pathogenesis can be reconstructed only by means of the lesions. Generally, this is a disease of young birds (nestlings to juveniles),³⁹⁰ but adults may also develop clinical signs. The destruction of the intramural ganglia of the proventriculus, ventriculus and to a lesser extent the descending loop of the duodenum explains the loss of peristalsis followed by obstruction of the proventriculus, atrophy of the ventricular wall and insufficiently digested food. The obstruction of the proventriculus can cause vomiting (see Color 8). The involvement of autonomic ganglia of the heart, brain, particularly the cerebellum and medulla oblongata, and the spinal cord may cause acute death with 100% mortality in affected birds. It has been suggested that the neurologic lesions may be caused by an autoimmune reaction.¹³²

Destruction of the intramural ganglia of the organs mentioned is considered pathognomonic for the disease, and allows morphologic differentiation from other conditions in the region, even those with the loss of peristalsis. Secondary infections may complicate the diagnosis. Because the etiologic agent has not been confirmed, it is impossible to define an "incubation period." Epizootiologic evidence suggest that clinical changes may take from four to twenty-four months to develop.

Clinical Disease and Pathology

NGD is a chronic disease that may be associated with an acute onset of clinical signs. Clinical signs vary with the host and the severity of the condition, but generally include depression, progressive weight loss, vomiting or the passing of undigested food in the droppings (Figure 32.24) (see Color 8). Some birds have an excellent appetite yet continue to lose weight. Anorexia may occur shortly before death. Polydipsia and polyuria may occur as well as neurologic signs such as leg weakness, incoordination and lameness. Diarrhea may occur late in the disease process and is usually the result of secondary bacterial or fungal enteritis. The obstruction of the pro-ventriculus can lead to pressure atrophy of the mucosa, sometimes followed by ulceration and even rupture (Colors 32.14, 32.19). Cachexia may induce cardiovascular failure due to energy deficiencies.^{153,167,253}

The hemogram reveals a two- to three-fold increase in leukocytes (heterophils, monocytes and basophilic granulocytes). The negative caloric balance results in hypoglycemia and anemia.¹⁵³ An elevation in creatine phosphokinase (CPK) levels has been suggested as a diagnostic tool;¹⁹¹ however, CPK concentrations are not believed to increase from damage to smooth muscles, and atrophy of striated muscle usually does not cause increased CPK activities.

Necropsy findings include emaciation, cachexia and a distended, frequently impacted proventriculus, ventriculus or crop (Color 32.14). Erosions and ulcerations with or without hemorrhage can be observed on the proventricular mucosa, occasionally even causing ruptures. The muscular layer of the hypotrophic ventriculus appears whitish in color.

Histopathologically, the proventriculus, ventriculus and the descending loop of the duodenum exhibit varying degrees of loss of nervous cells in the myenteric plexus (Auerbach) and substitution by infiltrates of lymphocytes, monocytes and sometimes plasma cells. Similar lesions are present in the minimally developed submucosal plexus (Meissner) and the celiac ganglion; however, not all ganglia are affected, and some are only partially involved. The ventriculus shows multifocal lymphocytic leiomyositis with degeneration of the smooth muscle cells and lymphocytic infiltration of the intrinsic nerves of the tunica muscularis. In some cases, extrinsic nerves are involved as well. A nonpurulent myocarditis with mononuclear infiltration of the ganglia occurs occasionally. Independent of clinical signs, lymphocytic encephalitis with perivascular cuffing can be detected in the cerebellum and medulla oblongata, but rarely in the cerebrum. Gliosis and pseudoneuronophagia have been described in the brain stem. Occasionally asymmetric lymphocytic poliomyelitis or leukomalacia are observed in the lumbar spinal cord. Intranuclear (with halo) and intracytoplasmic inclusion bodies have been described in nerve cells.^{153,167,253}

Diagnosis

In the experience of the author, about 10% of dead birds with signs indicative of NGD are not suffering from that disease (see Chapter 19). Any cause of intestinal blockage can cause similar-appearing clinical changes and gross necropsy findings. Neoplasms, scars or larvae migrans have also been found as the cause of impeded passage either in the ventriculus or the jejunum. Clinical signs in combination with contrast radiographs that indicate a dilated proventriculus and slowed gastric emptying time

provide only a suggestive diagnosis. In some early cases, hypermotility of the gastrointestinal tract may be noted.¹⁶⁷ Antemortem diagnosis requires histopathologic examination of biopsies of the ventriculus, which is difficult to sample. The absence of histologic lesions with suggestive clinical signs can indicate that the proventricular dilatation is of another etiology, or that the biopsy sample was collected from unaffected tissue.

Treatment and Control

Apart from hygienic considerations, symptomatic treatment can be attempted consisting of removal of stagnant ingesta, feeding soft or liquid feed and control of secondary infections. Supportive care has been efficacious in keeping birds alive for more than one year. In breeding flocks, affected birds should be removed as soon as possible. Birds that are in contact with patients that have confirmed infections should be placed in quarantine for at least six months together with cockatiel fledglings or breeding pairs as sentinels. New additions to the aviary should be quarantined for at least six months; however, this quarantine period may be insufficient to detect latently infected birds. Numerous cases have occurred in birds from stable flocks with no access to birds outside the collection (with the exception of free-ranging birds) for many months to years. These findings may cast a doubt on the infectious etiology.

Nephroenteritis of the Domestic Goose

This disease has been described in Hungary and was differentiated from goose hepatitis and goose myocarditis.^{360,407} Although the agent has not been isolated to date, it is possible to reproduce the disease with filtrated material from the kidneys and intestine of sick goslings. The agent does not serologically react with duck plague virus. The incubation period following experimental infection with organ homogenates of ill birds is 6 to 18 days. Contact birds need six weeks and sometimes even more before clinical signs develop.³⁵⁹

Clinical Disease and Pathology

Affected goslings seem to develop normally. The watery feces observed at the onset of the disease is frequently overlooked. Lethargy occurs only a few hours prior to death. Eight to ten hours before death, the feces become malodorous, fibrinous or bloody. In natural outbreaks, the peak of the mortality (up to 100%, but dependant on age) is reached at between 18 to 21 days of age. In contrast to the other diseases mentioned, mortality in contact birds can be ob-

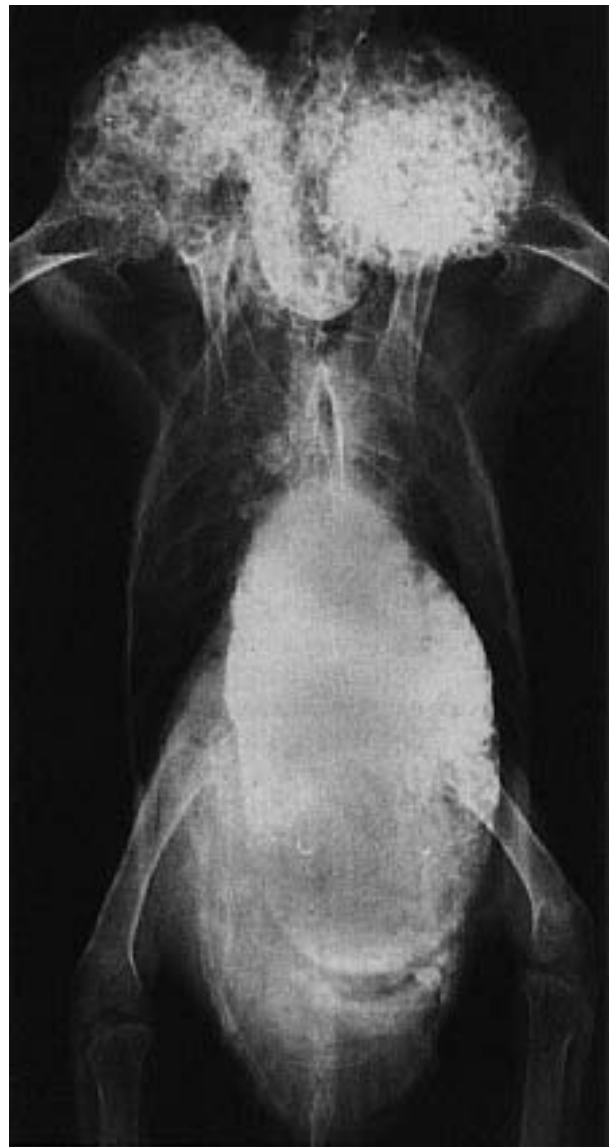

FIG 32.24 A Severe Macaw hen was presented for an acute onset of severe depression and reluctance to move. The bird had been part of a closed breeding aviary for over eight years and had recently fledged a clutch of chicks. The bird was severely emaciated (above). Survey radiographs indicated a large ventral abdominal soft tissue mass. Radiographs (right and below) taken three hours after administration of barium indicated dilatation of the proventriculus and a slowed gastric-emptying time. The histologic diagnosis was neuropathic gastric dilatation.

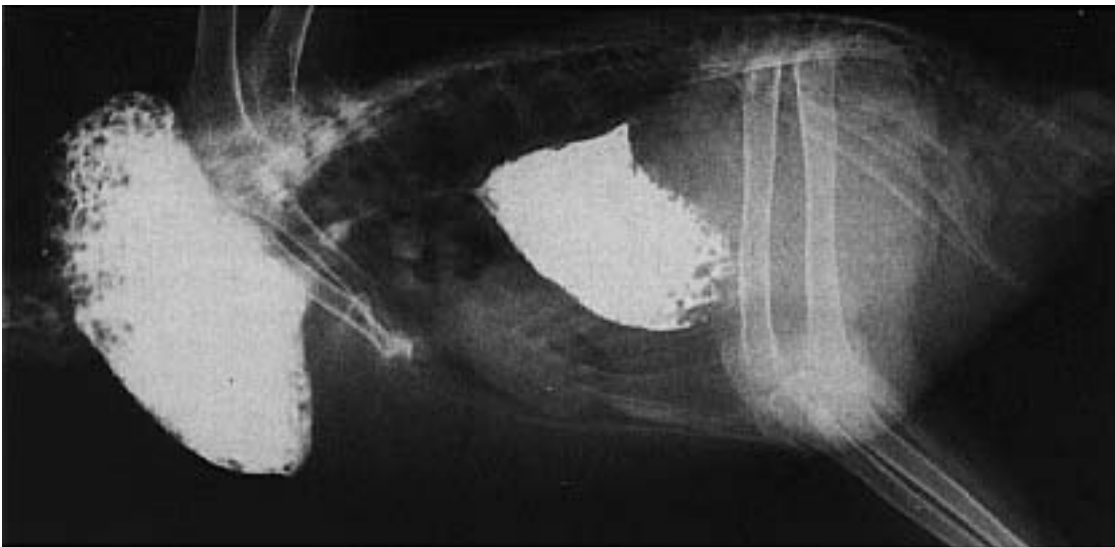


TABLE 32.18 Viruses with Specific Treatments

Virus	Therapy
Avipoxvirus	See text
Herpesvirus	Herpesviruses that code for their own DNA polymerase are sensitive to acyclovir; Baypamun* IM 3 injections within 2 days, 1 ml/kg
PDV	Both Baypamun* and acyclovir can be tried
ILT	None reported
DEV	None reported
AT	Not attempted
PHV	Try Baypamun,* treat secondary trichomoniasis
FHV	Try Baypamun;* acyclovir has renal toxicity; pay special care to birds that consume little water

Therapy for other virus infections consists of supportive care and antimicrobials to control secondary infections.
*Available only in Europe.

served beyond the sixth week of age. At necropsy, a massive mucoid-hemorrhagic, fibrinoid necrotizing enteritis as well as hemorrhagic nephritis is typical. The intestinal mucosa displays irregularly distributed confluent necrotic areas. The kidneys are enlarged, dark red in color and have multiple gray-greasy foci. Edema of the mesentery is considered to be typical as well as edema of the subcutis. Petechia and ecchymosis may be seen in the subcutis and the skeletal musculature. The spleen is moderate to massively enlarged. The consistency of the liver is friable.

A hemorrhagic change of the cloacal bursa and the thymus is considered characteristic for the disease. In goslings older than six weeks, the kidney is more severely affected than the intestine. Visceral gout is seen in these birds frequently as a sign of the renal tubular damage.^{359,360,407} Uricemia is considered to be a major cause of death.

Histopathology shows serous-to-hemorrhagic interstitial “nephritis.” Cellular reactions are rarely seen, because the birds die before the migration of inflammatory cells into the damaged tissue. The tubular epithelium is exfoliated, causing detritus casts in the lumina. The intestinal lesions consist of loss of epithelial cells and the structure of the villi. The result is necrotizing-to-pseudomembranous hemorrhagic enteritis. Lymphocytic cells can be seen in increased numbers in the submucosa. Hyperemia and edema can also be observed in other parenchymatous organs. Details on the daily course of an experimental infection have been reported.⁴⁰⁷ Parvoviral hepatitis and reoviral myocarditis should be ruled out. Because of the intestinal lesions duck plague must be considered. The age of the goslings, clinical signs and histopathology, including lesions of the cloacal bursa and the thymus, are indicative. Attempts at viral isolation are encouraged and experimental infections with cell-containing material might be necessary.

References and Suggested Reading

1. **Adair BM:** Studies on the development of avian adenoviruses in cell cultures. *Avian Pathol* 7:541-550, 1978.
2. **Alexander DJ, et al:** Experimental assessment of the pathogenicity of eight avian influenza A viruses of H5 subtype for chickens, turkeys, ducks and quail. *Avian Pathol* 15:647-662, 1986.
3. **Alexander DJ, et al:** Isolation of avian Influenza virus from birds in Great Britain. *Vet Rec* 118:537-538, 1986.
4. **Alexander DJ, et al:** Antigenic and biological characterization of avian paramyxovirus type 1 isolates from pigeons 7 an international collaborative study. *Avian Pathol* 14:365-376, 1985.
5. **Alexander DJ, et al:** Antigenic and structural relationship between avian paramyxoviruses isolated from ducks in Hong Kong and Mississippi. *J Gen Virol* 44:8339-842, 1979.
6. **Alexander DJ, et al:** Identification of paramyxoviruses isolated from birds dying in quarantine during 1980-1981. *Vet Rec* 111:571, 1982.
7. **Alexander DJ, et al:** Newcastle disease outbreaks in fowl in Great Britain during 1984. *Vet Rec* 117:429-434, 1985.
8. **Alexander DJ, et al:** Relationship of parakeet/Netherlands/449/75 virus to other avian paramyxoviruses. *Res Vet Sci* 25:105-106, 1978.
9. **Alexander DJ, et al:** The structural polypeptides of avian paramyxoviruses. *Arch Virol* 67:309-323, 1981.
10. **Alexander DJ, et al:** The use of monoclonal antibodies in the characterization of avian paramyxovirus type 1 (Newcastle disease virus) isolates submitted to an international reference laboratory. *Avian Pathol* 16:553-565, 1987.
11. **Alexander DJ:** Avian influenza: Recent developments. *Vet Bull* 52:341-359, 1982.
12. **Alexander DJ:** Avian paramyxoviruses. *Proc 34th West Poultry Dis Conf*, 1985, pp 121-124.
13. **Alexander DJ:** Newcastle disease and other paramyxovirus infections. *In* Calnek BW, et al (eds): *Diseases of Poultry* 9th ed. Ames, Iowa State University Press, 1991, pp 496-519.
14. **Alexander DJ:** Pneumovirus infections (turkey rhinotracheitis and swollen head syndrome of chickens). *In* Calnek BW, et al (eds): *Diseases of Poultry* 9th ed. Ames, Iowa State University Press, 1991, pp 669-673.
15. **Alexander DJ:** Taxonomy and nomenclature of avian paramyxoviruses. *Avian Pathol* 16:547-552, 1987.
16. **Alfalluji HH, et al:** Pox infection among captive peacocks. *J. Wildl Dis* 15:597-600, 1979.
17. **Allen B, et al:** An unusual presentation of avian poxvirus in breeder toms. *Proc 39th West Poultry Dis Conf*, 1990, pp 41-42.
18. **Allen SK:** Psittacine beak and feather disease in an African grey parrot. *J Assoc Avian Vet* 4:18-19, 1990.
19. **Anderson C, et al:** Antigenic variation in avian paramyxovirus type 3 isolates detected by mouse monoclonal antibodies. *Avian Pathol* 16:691-698, 1987.
20. **Andral B, et al:** Maladie foudroyante de la pintade: Recherche étiologique. *La Point Vétérinaire* 19:515-520, 1987.
21. **Arenas A, et al:** Prevalence of antibodies to PMV-1 (NDV) in wildfowl captured in southern Spain. *Verh Bericht 33. Intl Symp Erkrankungen Wild- und Zootiere*, 1991, pp 221-223.
22. **Arenas AJ, et al:** Circulation of some strains of avian influenza in wild waterfowl in Donana (Spain). *Verh Berichte 33. Intl Symp Erkrankungen Wild- und Zoovogel*, 1991, pp 217-224.
23. **Arenas AJ, et al:** Type A influenza viruses in birds in southern Spain: serological survey by enzyme-linked immunosorbent assay and hemagglutination inhibition tests. *Avian Pathol* 19:539-546, 1990.
24. **Arnold ID:** An outbreak of psittacine herpesvirus in rosellas. *Proc Assoc Avian Vet*, 1990, pp 283-291.
25. **Bagust TJ:** Immunodepressive diseases of poultry. *Proc Austral Vet Poultry Assoc* 66:285-293, 1983.
26. **Barr DA, et al:** Isolation of infectious bronchitis virus from a flock of racing pigeons. *Aust Vet* 65:228, 1988.
27. **Bauck L:** Diseases of the finch as seen in a commercial import station. *Proc Assoc Avian Vet*, 1989, pp 196-202.
28. **Bauck L:** Lymphosarcoma/avian leucosis in pet birds: Case reports. *Proc Assoc Avian Vet*, 1986, pp 241-245.
29. **Bauer HJ, et al:** Avian adeno-associated virus (AAAV) and fowl adenovirus (FAV): Studies of viral interactions in chicken cell cultures. *Avian Pathol* 15:357-366, 1986.
30. **Baxendale W:** Egg drop syndrome 76. *Vet Rec* 102:285-286, 1978.
31. **Beard JW:** Biology of avian oncoviruses. *In* Klein G: *Viral Oncology*. New York, Raven Press, 1980, pp 55-87.
32. **Becker WB, et al:** Experimental infection of Common Terns with Tern virus: Influenza virus A/Tern/South Africa/1961. *J Hyg Camb* 65:61-65, 1967.
33. **Becker WB et al.:** Experimental Infection of chickens with Influenza A/Tern/South Africa/1961 and Chicken/Scotland/1959 viruses. *J Comp Path* 77:159-165, 1967.
34. **Becker WB:** The isolation and classification of tern virus: influenza virus A/tern/South Africa/1961. *J Hyg Camb* 64:309-320, 1966.
35. **Bennewitz D:** Zur Immunprophylaxe der Paramyxovirus-3-Infektion bei Sittichen und Passeriformes. VI. DVG-Tagung Vogelkrrht. München, 1988, pp 86-103.
36. **Bergmann V, et al:** Einschlußkörperchenentzündis bei Tauben, hervorgerufen durch Adeno- und Parovirus. *Arch Exper Vet Med* 36:445-453, 1982.
37. **Bergmann V, et al:** Pathomorphologische und elektronenmikroskopische Feststellung einer Adenovirus-Tracheitis bei Moschusenten

- (*Cairina moschata*). *Mh Vet Med* 40:313-315, 1985.
38. **Bernier G, Morin M, Marsolais G:** A generalized inclusion body disease in the budgerigar (*Melopsittacus undulatus*) caused by a papovavirus-like agent. *Avian Dis* 25:1083-1092, 1981.
 39. **Bernier G, Morin M, Marsolais G:** Papovavirus-induced feather abnormalities and skin lesions in the budgerigar: Clinical and pathological findings. *Can Vet J* 25:307-310, 1984.
 40. **Biancifiore F, et al:** An occurrence of Newcastle disease in pigeons: Virological and serological studies on the isolates. *Comp Immunol Microbiol Infect Dis* 6:247-252, 1983.
 41. **Biggs PM:** Lymphoproliferative disease of turkeys. In Calnek BW, et al (eds): *Diseases of Poultry* 9th ed. Ames, Iowa State University Press, 1991, pp 456-459.
 42. **Bodin G, et al:** Etude de la contamination expérimentale du gibier à plumes (faisans, perdrix rouges, perdrix grises) par le virus de l'encephalomyélite infectieuse aviaire. *Rev Med Vet* 132:805-816, 1981.
 43. **Bouquet JF, et al:** Isolation and characterization of an adenovirus isolated from muscovy ducks. *Avian Pathol* 11:301-307, 1982.
 44. **Bozeman LH, et al:** Characterization of a papovavirus isolated from fledgling budgerigars. *Avian Dis* 25:972-980, 1981.
 45. **Bozorgmehr-Fard MH, et al:** Isolation of Newcastle disease virus from teal (*Anas crecca*) in Iran. *J Wildl Dis* 15:335-337, 1979.
 46. **Brugh M, et al:** Atypical disease produced in chickens by Newcastle disease virus isolated from exotic birds. *Avian Dis* 28:482-488, 1984.
 47. **Bryant WM, et al:** Outbreak of a fatal inclusion body hepatitis in zoo psittacines. *Proc 1st Intl Conf Zool & Avian Med*, 1987, p 473.
 48. **Bückner D:** Topographie der Blutgefäße von Kopf und Hals der Taube und deren Bedeutung bei der Injektion von Paramyxovirus-1-Impfstoffen. *Europ Symp Bird Diseases*, 1987, pp 47-57.
 49. **Burtscher H:** Die virusbedingte Hepatosplenitis infectiosa strigum. I. Mitteilung: Morphologische Untersuchungen. *Path Vet* 2:227-255, 1965.
 50. **Busche R, et al:** Zur Pathologie des Macaw wasting syndromes. *Verhandlungsbericht 27. Internat Symp Erkrankungen Zootiere*, 1985, pp 325-329.
 51. **Cakala A:** Szczep wirusa CELO wysoobniony z bazantow. *Med Vet* 22:261-264, 1966.
 52. **Calnek BW, et al:** Avian encephalomyelitis. In Calnek BW, et al (eds): *Diseases of Poultry* 9th ed. Ames, Iowa State University Press, 1991, pp 520-531.
 53. **Calnek BW, et al:** Marek's disease. In Calnek BW, et al (eds): *Diseases of Poultry* 9th ed. Ames, Iowa State University Press, 1991, pp 342-385.
 54. **Calnek BW:** Hemagglutination-inhibition antibodies against an adenovirus (virus 127) in white Pekin ducks in the United States. *Avian Dis* 22:798-801, 1978.
 55. **Campbell TW:** Lymphoid leukemia in an Amazon parrot: A case report. *Proc Intl Conf Avian Med*, 1985, pp 229-234.
 56. **Cappucci DT, et al:** Highlights on rabies, including Mid-Atlantic States outbreak in Raccoons. *Military Medicine* 151:1ff, 1986.
 57. **Carlson HC, et al:** Reticuloendotheliosis in Japanese quail. *Avian Pathol* 3:169-175, 1974.
 58. **Castro AE, et al:** Isolation and identification of a strain of influenza virus A/quail/California/4794/90(H4N6) antigenically similar to A/duck/Czechoslovakia/56(H4N6) from a quail flock in California. *Proc 40th West Poultry Dis Conf*, 1991, pp 42-43.
 59. **Chu HP, et al:** Isolation of Newcastle disease virus from birds of prey. *Avian Pathol* 5:227-233, 1976.
 60. **Clipsham R:** Degenerative anemia in African greys. *J Assoc Avian Vet* 3:73, 1989.
 61. **Clubb S, et al:** Psittacine reovirus: An update including a clinical description and vaccination. *Proc Assoc Avian Vet*, 1985, pp 83-90.
 62. **Clubb S:** A multifactorial disease syndrome in African Grey parrots (*Psittacus erithacus*) imported from Ghana. *Proc Intl Conf Avian Med*, 1984, pp 135-149.
 63. **Clubb SL, et al:** Outbreak of a papovavirus-like viral infection in a psittacine nursery: A retrospective view. *Proc Intl Conf Avian Med*, 1984, pp 121-129.
 - 63a. **Coffin MJ:** Retroviridae. In: Francki RIB, et al (eds): *Classification and nomenclature of viruses*. Springer Verlag Wien-New York pp. 290-295, 1991.
 64. **Collins BF, et al:** Preliminary characterization of a paramyxovirus isolated from a parrot. *Res Vet Sci* 19:219-221, 1975.
 65. **Cooper JE:** Papillomas in psittacine birds. *Vet Rec Nov*, 1986.
 - 65a. **Cornelissen H:** Vaccination of over 200 bird species against Newcastle disease: methods and vaccination reactions. *Proc Europ Conf Avian Med & Surf* pp. 275-287, 1993.
 66. **Cowen BS, et al:** A case of acute pulmonary edema, splenomegaly and ascites in guinea fowl. *Avian Dis* 32:151-156, 1988.
 67. **Crawshaw, et al:** Infectious laryngotracheitis in peafowl and pheasants. *Avian Dis* 26:397-401, 1982.
 68. **Cribb PH:** Cloacal papilloma in an amazon parrot. *Proc Intl Conf Avian Med*, 1984, pp 35-37.
 69. **Curris-Velasco M:** Eastern equine encephalomyelitis in a lady gouldian finch. *J Assoc Avian Vet* 6(4):227-228, 1992.
 70. **Daoust PY, et al:** Proventricular impaction associated with nonsuppurative encephalomyelitis and ganglionneuritis in two Canada geese. *J Wildl Dis* 27(3):513-517, 1991.
 71. **Davidson, WR, et al:** An epornitic of avian pox in wild Bobwhite quail. *J Wildl Dis* 16:293-298, 1980.
 72. **Davis RB, et al:** Budgerigar fledgling disease (BFD). *Proc 32nd West Poultry Dis Conf*, 1983, p 104.
 73. **Decaesstecker M, et al:** An ELISA for the detection of antibodies to avian nephritis virus and related enteroviral viruses. *Avian Pathol* 20:523-530, 1991.
 74. **Desmidt M, et al:** Cytomegalovirus-like conjunctivitis in Australian finches. *J Assoc Avian Vet* 5:132-136, 1991.
 75. **Dhillon AS, et al:** Mortality in young pheasants and avian influenza infection. *Proc 35th West Poultry Dis Conf*, 1986, p 38.
 76. **Docherty DE, et al:** Isolation of a herpesvirus from a bald eagle nestling. *Avian Dis* 27:1162-1165, 1983.
 77. **Docherty DE, et al:** The isolation of a herpesvirus from captive cranes with an inclusion body disease. *Research Note Avian Dis* 24:278-283, 1980.
 78. **Domermuth CH, et al:** Hemorrhagic enteritis and related infections. In Calnek BW, et al (eds): *Diseases of Poultry* 9th ed. Ames, Iowa State University Press, 1991, pp 567-572.
 79. **Dorrestein G, et al:** Einige Befunde zum Gesundheitszustand von freilebenden Stadttauben (*Columba livia*). *DVG VII. Tagung Vogelkrankheiten*, München, 1990, pp 77-87.
 80. **Dorrestein GM, et al:** Adenovirus inclusion body hepatitis: A new pigeon disease? *VII DVG-Tagung Vogelkrankheiten*, München, 1992, pp 7-14.
 81. **Doyle TM:** A hitherto unrecorded disease of fowl due to a filter-passing virus. *J Comp Pathol Ther* 40:144-169, 1927.
 82. **Dren, CS, et al:** Isolation of a reticuloendotheliosis-like virus from naturally occurring lymphoreticular tumors of domestic geese. *Avian Pathol* 17:259-277, 1988.
 83. **Dren CS, et al:** Lymphoreticular tumor in pen-raised pheasants associated with a reticuloendotheliosis like virus infection. *Avian Pathol* 12:55-71, 1983.
 84. **Dren CS:** Reticuloendothelioses. In Heider G, et al (eds): *Krankheiten des Wirtschaftsgeflügels, ein Handbuch für Wissenschaft und Praxis*. Stuttgart, Gustav Fischer Verlag Jena, 1992, pp 770-781.
 85. **Dykstra MJ, Bozeman LH:** A light and electron microscopic examination of budgerigar fledgling disease virus in tissue and in cell culture. *Avian Pathol* 11:11-18, 1982.
 86. **Easterday BC, et al:** Influenza. In Calnek BW, et al (eds): *Diseases of Poultry* 9th ed. Ames, Iowa State University Press, 1991, pp 532-551.
 87. **Eckert A:** Charakterisierung eines hämagglutinierenden Agens aus einem Erlenzeisig (*Carduelis spinus*) - Beirgang zur Ätiologie einer Erkrankung von Sperlingsvögeln (Passeriformes). *Vet Diss*, Hannover, 1979.
 88. **Elezzer TH:** Avian flu spread by wild waterfowl. *Poultry Dig*, 1984, p 16.
 89. **Engelhard E:** Charakterisierung eines aus einem Wellensittich (*Melopsittacus undulatus*) isolierten paramyxovirus. *Vet Med Siss*, München 1982.
 90. **Erickson DA, et al:** Velogenic viscerotropic Newcastle disease in selected captive avian species. *Proc Am Assoc Zoo Vet*, 1975, pp 133-136.
 91. **Estudillo J:** A Newcastle disease outbreak in captive exotic birds. *Proc 21th West Poultry Dis Conf*, 1972, pp 70-73.
 92. **Farmer H, et al:** Aspects of the pathogenesis of duck viral hepatitis. *Proc VII Intl Congr WVPA Jerusalem*, 1985, p 38.
 93. **Fenner F, et al (eds):** *Veterinary Virology*. Orlando, Academic Press, 1987.
 94. **Fischer E, et al:** Zur Histopathologie der spontanen PMV-1 Infektion der Taube. *DVG V Tagung Vogelkrankheiten*, München, 1986, pp 141-149.
 95. **Fleury HJA, et al:** Unidentified viral particles could be associated with enteritis of various commercial bird species. *Ann Inst Pasteur/Virol* 139:449-453, 1988.
 96. **Foerster S:** Untersuchungen an Kranich-Hepatitis-Herpesviren. *VI DVG-Tagung Vogelkrankheiten*, München, 1988, pp 204-211.
 97. **Forshaw D, et al:** Infection with a virus resembling papovavirus in gouldian finches (*Eythymia gouldiae*). *Aust Vet J* 65:26-28, 1988.
 98. **Frank RK, et al:** Coronalviral enteritis in an ostrich (*Struthio camelus*) chick. *J Zoo Wildlife Med* 23:103-107, 1992.
 99. **Frazier JA, et al:** The ultrastructure of cultures of chick embryo fibroblasts containing togavirus-like particles. *Avian Pathol* 16:679-689, 1987.
 100. **Freeman BM, et al:** Breeding for disease resistance: The prospective role of genetic manipulation. *Avian Pathol* 16:353-365, 1987.
 101. **French EL, et al:** A new herpesvirus isolated from a nestling cormorant (*Phalacrocorax melanoleucos*). *Avian Pathol* 2:3-15, 1973.
 102. **Fudge AM:** Psittacine vaccines. *Proc Assoc Avian Vet*, 1990, pp 292-300.
 103. **Gaskin JM, et al:** Preliminary findings in avian viral serositis: A newly recognized syndrome of psittacine birds. *J Assoc Avian Vet* 5:27-34, 1991.
 104. **Gaskin JM:** Psittacine viral disease: A perspective. *J Zoo Wildl Med* 20:249-264, 1989.
 105. **Gaskin JM:** The serodiagnosis of psittacine viral infections. *Proc Assoc Avian Vet*, 1988, pp 7-10.
 106. **Gassmann R, et al:** Isolierung von Adenoviren bei Wellensittichen mit zentralnervösen Ausfallserscheinungen. *II. DVG-Tagung Vogelkrankheiten*, München, 1981, pp 44-47.
 107. **Gaudry D, et al:** Essential characteristics of three viral strains isolated from Muscovy Ducks. *5th Intl Kongr WVPA* pp 1400-1405, 1973.
 108. **Gelderblom H, et al:** The fibers of fowl adenoviruses. *Arch Virol* 72:289-298, 1982.
 109. **Gerlach H:** Papovavirus. In Harrison GJ, Harrison LR (eds): *Clinical Avian Medicine and Surgery*. Philadelphia, WB Saunders Co, 1986, pp 426-428.
 110. **Gerlach H:** Paramyxovirus. In Harrison GJ, Harrison LR (eds): *Clinical Avian Medicine and Surgery*. Philadelphia, WB Saunders Co, 1986, pp 421-426.
 111. **Gerlach H:** Reovirus. In Harrison GJ, Harrison LR (eds): *Clinical Avian Medicine and Surgery*. Philadelphia, WB Saunders Co, 1986, pp 430-431.
 112. **Gerlach H:** Viral diseases. In Harrison GJ, Harrison LR (eds): *Clinical Avian Medicine and Surgery*. Philadelphia, WB Saunders Co, 1986, pp 409-414.
 113. **Gerlach H:** Vögel als Reservoir und Verbreiter von Krankheitserregern. *Berl Münch Tierärztl Wschr* 92:169-173, 1979.
 114. **Gerlach S:** Macaw wasting disease: A 4-year study on clinical case histories, epizootiology, analyses of species, diagnosis and differential diagnosis, microbiological and virological results. *Proc 1st Conf Europ*, 1991, pp 273-281.
 115. **Goodman BB, et al:** Isolation of avian paramyxovirus-2 from domestic and wild birds in Costa Rica. *Avian Dis* 32:713-717, 1988.
 116. **Goodpasture EW, et al:** Isolation of a wild avian pox virus inducing both cytoplasmic and nuclear inclusions. *Am J Path* 40:437-453, 1962.
 117. **Goodwin MA, McGee ED:** Herpes-like virus associated with a cloacal papilloma in an orange-fronted conure (*Aratinga canicularis*). *J Assoc Avian Vet* 7(1):23-26, 1993.
 118. **Goodwin MA:** Adenovirus particles and inclusion body hepatitis in pigeons. *J Assoc Avian Vet* 6:37-39, 1992.
 119. **Goryo M, et al:** Inclusion body hepatitis due to adenovirus in pigeons. *Avian Pathol* 17:391-401, 1988.
 120. **Gough RE, et al:** Routine virus isolation or detection in the diagnosis of diseases in birds. *Avian Pathol* 17:893-907, 1988.
 121. **Gough RE:** Goose parvovirus infection. In Calnek BW, et al (eds): *Diseases of Poultry* 9th ed. Ames, Iowa State University Press, 1991, pp 684-690.
 122. **Gough RE, et al:** Pheasant coronavirus in Great Britain. *WVPA II Intl Symp IB Rauschholzhausen Germany*, 1991, pp 308-314.
 123. **Gough JF:** Outbreaks of budgerigar fledgling disease in three aviaries in Ontario. *Can Vet J* 30:672-674, 1989.
 124. **Gough PH, et al:** Rabies antibodies in Wild-birds. *J Wildl Dis* 12:392-395, 1976.
 125. **Gough RE, Collins MS, Gresham AC:** A parvovirus-like agent associated with psittacine beak and feather disease. *Vet Rec* 125:41, 1989.
 126. **Gough RE, et al:** Isolation of a chicken embryo-lethal rotavirus from a Lovebird (*Agapornis* sp.). *Vet Rec* 122:363-364, 1988.

CHAPTER 32 VIRUSES

129. **Gough RE, et al:** Viruses and virus-like particles detected in samples from diseased game birds in Great Britain during 1988. *Avian Pathol* 19:331-342, 1990.
130. **Graham DL, Calnek BW:** Papovavirus infection in hand-fed parrots: Virus isolation and pathology. *Avian Dis* 31:398-410, 1986.
131. **Graham DL, et al:** Herpesvirus infections in captive birds. 1st Intl Birds in Captivity Symp, Seattle USA, 1978, pp 526-530.
132. **Graham DL:** An update on selected pet bird virus infections. *Proc Intl Conf Assoc Avian Vet*, 1984, pp 267-270.
133. **Graham DL:** Characterization of a reovirus and its isolations and pathogenicity for parrots. *Avian Dis* 31:441-449, 1987.
- 133a. **Graham DL:** Internal papillomatous disease (abstract). *Proc Assoc Avian Vet* 1988, p 31.
134. **Graham DL:** Feather and beak disease: Its history, management and an experiment in its eradication from a breeding aviary. *Proc Assoc Avian Vet*, 1990, pp 8-11.
135. **Graham DL:** Papillomatous disease: A pathologist's view or cloacal papillomas and then some! *Proc Assoc Avian Vet*, 1991, pp 141-143.
136. **Graham DL:** Infiltrative splanchic neuropathy, a component of the "wasting macaw" complex. *proc Intl Conf Avian Med*, 1984, p 275.
137. **Graham DL:** Update on pet avian viral diseases. *Proc 34th West Poult Dis Conf*, 1985, pp 75.
138. **Green RG, et al:** A virus disease of owls. *J Immunol* 29:68-69, 1935.
139. **Greenacre C, et al:** Psittacine beak and feather disease in a scarlet macaw (*Ara macaco*). *J Assoc Avian Vet* 6(2):95-98, 1992.
140. **Griffiths BB, et al:** Immunological response of chickens to eastern equine encephalomyelitis virus. *Res Vet Sci* 38:65-68, 1985.
141. **Guiffet M, et al:** Experimental soft-shelled eggs disease (EDS₇₆) in guinea fowl (*Numida meleagris*). Abstracts VII th Internat Cong WVPA, 1981, p 22.
142. **Gulka CM, et al:** Evidence of exposure of waterfowl and other aquatic birds to the hemagglutinating duck Adenovirus identical to EDS 76 virus. *J Wildl Dis* 20:1-5, 1984.
143. **Gylstorff I:** Adenoviridae. In Gylstorff I, Grimm F: *Vogelkrankheiten*. Stuttgart, Eugen Ulmer, 1987, pp 275-278.
144. **Gylstorff I:** Aviäre Encephalomyelitis. In Gylstorff I, Grimm F: *Vogelkrankheiten*, 1987, pp 253-254.
145. **Gylstorff I:** Coronavirus. In Gylstorff I, Grimm F: *Vogelkrankheiten*, Stuttgart, Verlag Eugen Ulmer, 1987, p 263.
146. **Gylstorff I:** Derzsy's Krankheit - Hepatitis der Gänse. In Gylstorff I, Grimm F: *Vogelkrankheiten*. Stuttgart, Verlag Eugen Ulmer, 1987, pp 279-280.
147. **Gylstorff I:** Orthomyxoviren. In Gylstorff I, Grimm F: *Vogelkrankheiten*. Stuttgart, Verlag Eugen Ulmer, 1987, pp 249-253.
148. **Gylstorff I:** Paramyxoviren. In Gylstorff I, Grimm F: *Vogelkrankheiten*. Stuttgart, Verlag Eugen Ulmer, 1987, pp 210-249.
149. **Gylstorff I:** Poxviridae. In Gylstorff I, Grimm F: *Vogelkrankheiten*. Stuttgart, Verlag Eugen Ulmer, 1987, pp 263-267.
150. **Gylstorff I:** Reoviridae. In Gylstorff I, Grimm F: *Vogelkrankheiten*. Stuttgart, Verlag Eugen Ulmer, 1987, pp 257-259.
151. **Gylstorff I:** Retroviridae. In Gylstorff I, Grimm F: *Vogelkrankheiten*. Stuttgart, Verlag Eugen Ulmer, 1987, pp 259-263.
152. **Gylstorff I:** Virusinfektionen. In Gylstorff I, Grimm F: *Vogelkrankheiten*. Stuttgart, Verlag Eugen Ulmer, 1987, pp 255-257.
153. **Gylstorff I:** Vormagendilatation und Auszehrung (Macaw-Wasting-Syndrom): Myenterische Ganglio und Encephalomyelitis der Psittaciden. In Gylstorff I, Grimm F: *Vogelkrankheiten*. Stuttgart, Verlag Eugen Ulmer Stuttgart, 1987, pp 285-286.
- 154a. **Halliwell WH:** Lesions of Marek's disease in a great-horned owl. *Avian Dis* 15:49-55, 1971.
154. **Halvorson D:** Epizootiology of avian influenza. *Avian Dis* 27:77-85, 1983.
155. **Hanson LE, et al:** Fowlpox and latency. *Proc 24th West Poult Dis Conf*, 1975, pp 43-45.
156. **Hanson LE, et al:** Laryngotracheitis. In Calnek BW, et al (eds): *Diseases of Poultry* 9th ed. Ames, Iowa State University Press, 1991, pp 485-495.
157. **Hanson RP:** Avian reservoirs of Newcastle disease. *Proc 3rd Intl Wildl Dis Conf*, Munich, 1975.
158. **Hanson RP:** Issues related to control of velogenic viscerotropic Newcastle Disease (VVND) and the importation of pet birds. *Proc 31th West Poult Dis Conf*, 1982, pp 165-166.
159. **Harrison GJ:** The vaccine dilemma. *J Assoc Avian Vet* 5:10-14, 1991.
160. **Hartig F, et al:** Beitrag zur Pathologie der Lungenform der Kanarienvogel. *Berl Münch Tierärztl Wschr* 85:352-355, 1972.
161. **Heffels U, et al:** Serologische Untersuchungen zum Nachweis virusbedingter Infektionen bei der Taube in der Bundesrepublik Deutschland. *Dtsch tierärztl Wschr* 88:97-102, 1981.
163. **Heffels-Redmann U, et al:** Infektiöse Myocarditis der Gossel. In Heider, et al: *Krankheiten des Wirtschaftsgeflügel*, ein Handbuch für Wissenschaft und Praxis. Stuttgart, Gustav Fischer Verlag Jena, 1992, pp 538-540.
164. **Heffels-Redmann U, et al:** Structural and biological characteristics of reovirus isolated from muscovy ducks. *Avian Pathol* 21:481-491, 1992.
165. **Heider G:** Molekulare Grundlagen aviärer Retrovirusinfektionen. In Heider G, et al: *Krankheiten des Wirtschaftsgeflügel*, ein Handbuch für Wissenschaft und Praxis. Stuttgart, Gustav Fischer Verlag Jena, 1992, pp 683-695.
166. **Heil U:** Untersuchungen zur Charakterisierung und Klassifizierung des "Tauben-Paramyxovirus" sowie Überprüfung der Schutzwirkung verschiedener Newcastle-Disease-Impfstoffe bei Tauben (*Columba livia* Gmel. 1789 var. dom.). *Vet Diss*, München, 1984.
167. **Heldstab A, et al:** Pathologie einer endemieartig verlaufenden Neuritis im Magen/Darmbereich bei Großpapageien (wasting macaw complex, infiltrative splanchic neuropathy). *Verhandlungsberichte 27 Intl Symp Erkrankungen Zootiere*, 1985, pp 317-324.
168. **Helper DH, et al:** Myocarditis-encephalopathy in canaries. *Proc 30th West Poult Dis Conf*, 1981, p 92.
169. **Helper DH:** A new viral respiratory infection in parakeets. *Avian Dis* 24:781-783, 1980.
170. **Hermann-Dekkers, et al:** Vaccination of pigeons against Paramyxovirus infection in infected areas, a comparative trial. *Europ Symp Avian Dis*, Beerse, 1987, pp 32-38.
171. **Hillyer EV:** Cholangiocarcinoma in association with cloacal papilloma in two amazon parrots. 1st Conf Europ Assoc Avian Vet, 1991, p 332.
172. **Hinshaw, et al:** Antigenic and genetic characterization of a novel hemagglutinin subtype of Influenza A viruses from gulls. *J Virol* 42:865-872, 1982.
173. **Hirai K, et al:** Characterization of a new corona-like agent isolation from parrots. *Avian Dis* 23:515-515, 1979.
174. **Hirai K, et al:** Characterization of paramyxo-, herpes- and orbiviruses isolated from psittacine birds. *Avian Dis* 23:148-163, 1979.
175. **Hirai K, et al:** Isolation of a papovavirus-like agent from young budgerigars with feather abnormalities. *J Vet Sci* 46:577-587, 1984.
176. **Hofstad ML (ed):** *Diseases of Poultry* 8th ed. Ames, Iowa State University Press, 1986.
- 176a. **Holmes LF:** Reoviridae. In: Francki RIB, et al (eds): *Classification and nomenclature of viruses*. Springer Verlag Wien-New York pp 186-192, 1991.
177. **Horwitz MS:** Adenovirus. In Fields NB, et al: *Virology* 2nd ed. New York, Raven Press Ltd, 1990, pp 1723-1740.
- 177a. **Howard CR:** Hepadnaviridae. In: Francki RIB, et al (eds): *Classification and nomenclature of viruses*. Springer Verlag Wien-New York pp 186-192, 1991.
178. **Huff DG, et al:** Psittacine beak and feather syndrome in a blue-fronted Amazon (*Amazona aestiva*). *Assoc Avian Vet Today* 2:84-86, 1988.
179. **Hughes EP, et al:** Hemoproliferative disease in captive and wild birds. *Proc 35th West Poult Dis Conf*, 1986, pp 83-84.
180. **Hwang J:** Active immunization against duck hepatitis virus. *Am J Vet Res* 33:2539-2544, 1972.
181. **Ianconescu M, et al:** Reticuloendotheliosis and lymphoproliferative disease of turkeys - pathology and differential diagnosis. *Refuah Veterinarith* 36:2-9, 1979.
182. **Ianconescu M:** Arbovirus infections. In Calnek BW, et al (eds): *Diseases of Poultry*. Ames, Iowa State University Press, 1991, pp 674-679, 1991.
183. **Ibrahim AL:** Issues related to control of velogenic viscerotropic Newcastle disease (VVND) and the importation of pet birds. *Proc 31th West Poult Dis Conf*, 1982, pp 165.
184. **Imada T, et al:** Infectious nephritis. In Calnek BW, et al (eds): *Diseases of poultry*. Iowa State University Press pp 680-682, 1991.
185. **Ishibashi M, et al:** Adenoviruses of animals. In Ginsberg HS (ed): *The Adenoviruses*. New York, Plenum Press, pp 497-562.
186. **Jack SW, et al:** Pathology of quail bronchitis. *Proc 37th West Poult Dis Conf*, 1988, pp 102-104.
187. **Jacobson ER, et al:** Feather and beak dystrophy and necrosis in cockatoos. *Clinicopathologic evaluations*. *J Am Vet Med Assoc* 189:999-1005, 1986.
188. **Jacobson ER, et al:** Epormitic of papovavirus-like virus-associated disease in a psittacine nursery. *J Am Vet Med Assoc* 185:1337-1341, 1984.
189. **Jacobson ER, et al:** Adenovirus-like infection in white-masked lovebirds (*Agapornis personata*). *J Assoc Avian Vet* 1(2):33, 1989.
190. **Jacobson ER, et al:** Papilloma-like virus infection in an African Grey parrot. *J Am Vet Med Assoc* 183:1037-1038, 1983.
191. **Jenkins T:** Creatinine kinase as a diagnostic indicator of splanchic neuropathy. *J Assoc Avian Vet* 5:49, 1991.
192. **Johnston KM, Riddell C:** Intranuclear inclusion bodies in finches. *Can Vet J* 27:432-434, 1986.
193. **Jones RC, et al:** An enterotropic avian infectious bronchitis. In McFerran (ed): *Acute Virus Infections of Poultry*. Martinus Nijhoff Publishers, 1986, pp 113-121.
194. **Kaal:** Venereal disease of parrots. *Procl Intl Avicultural Meeting*, Tenerife, Spain, 1990.
195. **Kaleta EF, et al:** Newcastle disease in free-flying and pet birds. In Alexander DJ (ed): *Newcastle Disease*. Boston, Kluwer Academic Publ, 1988, pp 197-246.
196. **Kaleta EF, et al:** The first isolation of the avian PMV-1 virus responsible for the current panzootic in pigeons. *Avian Pathol* 14:553-557, 1985.
197. **Kaleta EF, et al:** Newcastle disease in a zoo affecting demoiselle cranes (*Anthropoides virgo*), greater flamingoes (*Phoenicopterus ruber*) and a pied imperial pigeon (*Ducula bicolor*). *Avian Pathol* 10:395-401, 1981.
198. **Kaleta EF, et al:** A new herpesvirus isolated from black storks (*Ciconia nigra*). *Avian Pathol* 9:301-310, 1980.
199. **Kaleta EF, et al:** Herpesvirus and Newcastle disease viruses in white storks (*Ciconia ciconia*). *Avian Pathol* 12:347-352, 1983.
200. **Kaleta EF, et al:** Isolation and serological differentiation of a herpesvirus from bobwhite quail (*Colinus virginianus*). *Arch Virology* 66:359-364, 1980.
201. **Kaleta EF, et al:** Persistent viraemia of a cell-associated herpesvirus in white storks (*Ciconia ciconia*). *Avian Pathol* 15:447-453, 1986.
203. **Kaleta EF:** Aviäre Paramyxoviren: Typen und Subtypen. *Seminar Über Isolierung und Charakterisierung von aviären Paramyxoviren*. Gießen, 1989, pp 57-70.
204. **Kaleta EF:** Detection of antibodies against avian paramyxovirus-1, -2, -3 in sera from pigeons. *Deutsch Tierärztl Wschr* 89:31-32, 1982.
205. **Kaleta EF:** Hepatosplenitis infectiosa strigum und andere Krankheiten der Greifvogel und Eulen. *Zbl V Med Suppl* 25:173-180, 1976.
206. **Kaleta EF:** Herpesviruses of birds: A review. *Avian Pathol* 19:193-211, 1990.
207. **Kaleta EF:** Taubenherpesvirus (Plaques groß-klein- Impfstoff). *Brieftaube*, 1991.
208. **Karpinski LG, et al:** An outbreak of pox in imported mynahs. *Proc Assoc Avian Vet*, 1986, pp 35-38.
209. **Karunakaran D, et al:** The bioecology of avian influenza in migratory waterfowl. *Proc 30th West Poult Dis Conf*, 1981, p 46.
210. **Kelleher C, et al:** Epizootiology of avian influenza: Simultaneous monitoring of sentinel ducks and turkeys. *Proc 32th West Poult Dis Conf*, 1983, pp 83-84.
211. **Kibenge FSB, et al:** Effects of experimental immunosuppression on reovirus-induced tenosynovitis in light-hybrid chickens. *Avian Pathol* 16:73-92, 1987.
212. **Kiel H:** Pockeninfektion bei Jagdfalken - Klinik, pathomorphologische Ergebnisse, Prophylaxe und Therapie - IV DVG-Tagung Vogelkrt München, 1985, pp 202-206.
213. **King DJ, et al:** Infectious bronchitis. In Calnek BW, et al (eds): *Diseases of Poultry* 9th ed. Ames, Iowa State University Press, 1991, pp 471-484.
214. **King DJ, et al:** Adenovirus isolation and serology from wild bobwhite quail (*Colinus virginianus*). *Avian Dis* 25:678-682, 1981.
215. **Kirev TT:** Neoplastic response of guinea fowl to osteopetrosis virus strain MAV-2(0). *Avian Pathol* 17:101-112, 1988.
216. **Kirmse P:** Host specificity and pathogenicity of pox viruses from wild birds. *Bull Wildl Dis Assoc* 5:376-386, 1969.
217. **Kisary J, et al:** Failure of orally administered attenuated goose parvovirus strain B to induce a humoral immune response in adult geese. *Avian Pathol* 10:91-93, 1981.
218. **Kisary J:** Parvovirus infections in chickens. In Calnek BW, et al (eds): *Diseases of Poultry* 9th ed. Ames, Iowa State University Press, 1991, pp 683-684.
219. **Kitzing D:** Neuere Erkenntnisse über das Falkenpockenvirus. *Prakt Tierärztl* 61:952-954, 1980.
- 219a. **Klenk HD:** Orthomyxoviridae. In: Francki RIB, et al (eds): *Classification and nomenclature of viruses*.

- Springer Verlag Wien-New York pp 261-272, 1991.
220. **Knoll M**, et al: Immunitätsdauer nach Impfung gegen die Paramyxovirose der Tauben mit einer homologen öemulsionsvakzine - Ergebnisse eines Langzeitversuches unter Laborbedingungen. V. DVG-Taugung Vogelkrrhth, München, 1986, pp 168-177.
221. **Kocan AA**, et al: Influenza A viruses isolated from migrating ducks in Oklahoma (reservoir of a virus that infects domestic species also). *J Wildl Dis* 16:281-285, 1980.
222. **Kösters J**, et al: Erfahrungen mit der Impfung gegen Paramyxovirus-Infektion bei Tauen in der Bundesrepublik Deutschland. Die Brieftaube 108:1165-1168, 1991.
223. **Kraft V**, et al: Nachweis eines Pockenvirus bei Zwergpapageien (*Agapornis personata* und *Agapornis roseicollis*). *Berl Münch Tierärztl Wschr* 84:83-87, 1971.
224. **Krauss H**: Eine verlustreiche Aufzuchtkrankheit bei Gänseküken. *Berl Münch Tierärztl Wschr* 78:372, 1965.
225. **Krautwald ME**, et al: Heterogeneity of Pacheco's disease and its causative agents. *Proc Assoc Avian Vet*, 1988, pp 11-22.
226. **Krautwald ME**, et al: Polyomavirus infection in budgerigars (*Melopsittacus undulatus*): Clinical and aetiological studies. *J Vet Med B* 36:, 1989.
227. **Kronberger H**: Haltung von Vögeln. Krankheiten der Vögel 2. Auflage Verlag Fischer Jena, 1978.
228. **Landowska-Plazewska E**, et al: Ausbruch von Vogelpecken bei Humboldt-Pinguinen im Warschauer Zoo. *Verhber X Intl Symp Erkrankungen Zootiere*, Salzburg, 1968, pp 157-160.
229. **Lafimer KS**, et al: A novel DNA virus associated with feather inclusions in PBFD. *Vet Pathol* 28:300-304, 1991.
230. **Lafimer KS**, et al: An updated review of psittacine beak and feather disease. *J Assoc Avian Vet* 5:211-220, 1991.
231. **Lafimer KS**, et al: Cryptosporidiosis in four cockatoos with psittacine beak and feather disease. *J Am Vet Med Assoc* 200:707-710, 1992.
232. **Lafimer KS**, et al: Extracutaneous viral inclusions in psittacine beak and feather disease. *J Vet Diagn Invest* 2:204-207, 1990.
233. **Lehn H**, et al: Cloning and characterization of budgerigar fledgling disease virus (BFDV), an avian polyomavirus. *Virology* 151:362-370, 1986.
234. **Leibovitz L**: Duck virus enteritis (duck plague). In Calnek BW, et al (eds): *Diseases of Poultry* 9th ed. Ames, Iowa State University Press, 1991, pp 609-618.
235. **Leighton FA**: Adenovirus-like agent in the bursa of Fabricius of herring gulls (*Larus argentatus pontoppidan*) from Newfoundland, Canada. *J Wildl Dis* 20:226-230, 1984.
236. **Lester T**, et al: Isolation of a virus from feathers of a cockatoo with feather loss syndrome. *ISR J Vet Med* 42:120-123, 1986.
237. **Ley DH**, et al: Experimental production of enteritis in bobwhite quail (*Colinus virginianus*) with cryptosporidium and reovirus. *Proc 35th West Poult Dis Conf*, 1986, pp 107-109.
238. **Ley DH**, et al: Histomoniasis and reticuloendotheliosis in a wild turkey. *J Wildl Dis* 25:262-265, 1989.
239. **Ley DH**: Intestinal cryptosporidiosis and reovirus isolation from young pen-raised bobwhite quail with severe diarrhea and high mortality. *Proc 34th West Poult Dis Conf*, 1985, pp 93-95.
240. **Lina P**, et al: Detection of virus in squamous papillomas of wild bird species *Fringilla coelebs*. *J Natl Cancer Inst* 50:567-571, 1973.
241. **Lister SA**, et al: Outbreaks of nephritis in pheasants (*Phasianus colchicus*) with a possible coronavirus aetiology. *Vet Rec* 117:612-613, 1985.
242. **Lister SA**, et al: Paramyxovirus type 1 infection in racing pigeons and associated outbreaks in domestic poultry in the United Kingdom during 1984. *Proc 8th Intl Cong WVPV*, 1985, pp 118.
243. **Logemann K**, et al: Comparative studies for the characterization of avian adenovirus from quail and chickens. DVG VII Tagung Vogelkruhy München, 1990, pp 294-295.
244. **Löfger H-CH**: Aviäre Onkovirosen. In Heider G, et al: *Krankheiten des Wirtschaftsgeflügels*, ein Handbuch für Wissenschaft und Praxis. Stuttgart, Gustav Fischer Verlag Jena, 1992, pp 695-770.
245. **Lowenstine L**: Diseases of psittacines differing morphologically from Pacheco's disease but associated with herpesvirus-like particles. *Proc 31st West Poult Dis Conf*, 1982, pp 141-142.
246. **Lowenstine LJ**, et al: Adenovirus-like particles associated with intranuclear inclusion bodies in the renal tubules of lovebirds (*Agapornis* spp.) and a common murre (*Uria aalga*). *Proc 33rd West Poult Dis Conf*, 1984, pp 105-106.
247. **Lowenstine LJ**: A potpourri of interesting avian cases. *Proc 1st Intl Conf Zool & Avian Med*, 1987, pp 105-107, 1987.
248. **Ludford CG**, et al: Duck infectious anemia virus associated with *Plasmodium lophurae*. *Exp Parasitol* 31:29-38, 1972.
249. **Lukas GN**: Observation on detection of VVND and chlamydia in birds. *Proc 11th West Poult Dis Conf*, 1982, pp 127-127.
250. **Malkinson M**, et al: Reovirus infection of young muscovy ducks (*Cairina moschata*). *Avian Pathol* 10:433-410, 1981.
251. **Malkinson M**, et al: Serological survey for the prevalence of antibodies to egg drop syndrome 1976 virus in domesticated and wild birds in Israel. *Avian Pathol* 9:421-426, 1980.
252. **Malkinson M**: An outbreak of an acute neoplastic syndrome accompanied by undifferentiated leukemia in a flock of muscovy ducks. *Proc 31st West Poult Dis Conf*, 1982, p 110.
253. **Mannl A**, et al: Neuropathic gastric dilatation in Psittaciformes. *Avian Dis* 31:214-221, 1987.
254. **Mare CJ**, et al: Falcon herpesvirus, the etiologic agent of inclusion body disease of falcons. *Infection & Immunity* 7:118-126, 1973.
255. **Marius V**: Characterization of a reovirus isolated from muscovy ducks. Study of virulence for different species of fowl and waterfowl. Study of immunity afforded by Reovirus vaccine (S1133). *WPSA Europ Waterfowl Dis Symp*, 1981.
256. **Marshall R**: Papova-like virus in a finch aviary. *Proc Assoc Avian Vet*, 1989, pp 203-207.
257. **Mathey WJ**, et al: Tremors of nestling budgerigars with BFD. *Proc 33rd West Poult Dis Conf*, 1984, p 102.
258. **Maslin WR**, et al: Effect of a reovirus isolated from broilers with pale bird syndrome on SPF chicks. *Proc 33th West Poult Dis Conf*, 1984, pp 67-68.
259. **McCracken**, et al: Experimental studies on the aetiology of inclusion body hepatitis. *Avian Pathol* 5:325-339, 1976.
260. **McDonald SE**: Clinical experience with cloacal papillomas. *Proc Assoc Avian Vet*, 1988, pp 27-30.
261. **McDonald SE**: Pacheco's parrot disease. *Assoc Avian Vet Aviculture Seminar*, 1991, pp 81-87.
262. **McFerran JB**, et al: Isolation of adenoviruses and reoviruses from avian species other than domestic fowl. *Avian Dis* 20:519-524, 1976.
263. **McFerran JB**, et al: Studies on a paramyxovirus isolated from a finch. *Arch ges Virusforsch* 46:281-290, 1974.
264. **McFerran JB**, et al: Avian adenoviruses: A review. *Avian Pathol* 6:189-217, 1977.
265. **McFerran JB**, et al: Isolation of adenoviruses and reoviruses from avian species other than domestic fowl. *Avian Dis* 20:519-524, 1976.
266. **McFerran JB**, et al: Isolation of viruses from clinical outbreaks of inclusion body hepatitis. *Avian Pathol* 5:315-324, 1976.
267. **McFerran JB**: Adenovirus infections. In Calnek BW, et al (eds): *Diseases of Poultry* 9th ed. Ames, Iowa State University Press, 1991, pp 552-582.
268. **McFerran JB**: Egg drop syndrome. In Calnek BW, et al (ed): *Diseases of Poultry* 9th ed. Ames, Iowa State University Press, 1991, pp 573-582.
269. **McKeen WD**: Considerations for wild bird control during a Newcastle disease epidemic. *Proc 21th West Poult Dis Conf*, 1972, pp 52-56.
270. **McNully MS**: Rotavirus infections. In Calnek BW, et al (eds): *Diseases of Poultry* 9th ed. Ames, Iowa State University Press, 1991, pp 628-635.
271. **McOrist S**, et al: Psittacine beak and feather dystrophy in wild sulphur-crested cockatoos (*Cacatua galerita*). *J Wildl Dis* 20:120-124, 1984.
272. **McOrist S**, et al: Viral enteritis in cockatoos (*Cacatua* spp.). *Avian Pathol* 20:531-539, 1991.
273. **McOrist S**: Some diseases of free-living Australian birds. *ICBP Technical Publication* 16:13-68, 1989.
274. **Meister JA**: Untersuchungen zur Diagnose, Differentialdiagnose, Klinik, Epizootiologie und Immunprophylaxe der Paramyxovirus-1-Infektion der Hausstaube (*Columba livia* Gmelin, 1789 variatio domestica). *Vet Diss*, Gießen, 1987.
275. **Meulemans G**, et al: Isolation of orthoreovirus from psittacine birds. *J Comp Pathol* 93:127-134, 1983.
276. **Minamoto N**, et al: Isolation and characterization of rotavirus from feral pigeons in mammalian cell cultures. *Epidemiol Infect* 100:481-492, 1988.
- Minor P**: Picornaviridae. In: Francki RIB, et al (eds): *Classification and nomenclature of viruses*. Springer Verlag Wien-New York pp 320-322, 1991.
277. **Mohammed MA**, et al: Contagious paralysis of pigeons. *Avian Pathol* 7:637-643, 1978.
278. **Mohan R**: Clinical and laboratory observations of reovirus infection in a cockatoo and a grey-cheek parrot. *Proc Intl Conf Avian Med*, 1984, pp 29-33.
279. **Monreal G**: Adenovirusinfektionen. In Heider, et al: *Krankheiten des Wirtschaftsgeflügels*, ein Handbuch für Wissenschaft und Praxis. Stuttgart, Gustav Fischer Verlag Jena Bd. 1, 1992, pp 379-414.
280. **Mori F**, et al: Inclusion bodies containing adenovirus-like particles in the kidneys of psittacine birds. *Avian Pathol* 18:197-202, 1989.
281. **Müller H**, et al: A polyoma-like virus associated with acute disease of fledgling budgerigars (*Melopsittacus undulatus*). *Med Microbiol Immunol* 175:1-13, 1986.
- 281a. **Müller H**: Budgerigar fledgling disease virus, (BFDV). V. DVG-Tagung Vogelkrrhth., München pp 294-298, 1986.
282. **Müller H**: Strukturelle Eigenschaften des Virus der Nestlingskrankheit der Wellensittiche, eines aviären Polyomavirus mit ungewöhnlichen biologischen Eigenschaften. *2nd Europ Symp Avian Med Sur*, 1989, pp 193-197.
283. **Mumme J**, et al: Anthroprozoonosen vom Menschen auf Tiere übertragen
- bare Krankheiten (3). *Tierärztl Prax* 8:13-20, 1980.
284. **Mustaffa-Babjee A**, et al: Acute enteritis in rainbow lorikeets. *Kajian Vet* 5:16-19, 1973.
285. **Mustaffa-Babjee A**, et al: A pathogenic paramyxovirus from a budgerigar. *Avian Dis* 18:226-230, 1974.
286. **Myers TL**, et al: Intestinal IgA response and immunity to rotavirus infection in normal and antibody deficient chickens. *Avian Pathol* 19:697-712, 1990.
287. **Nair M**, et al: Studies on broilers' IBV and IB-like virus from Guinea Fowl. *WVPA II Intl Symp IB Rauschholzhausen Germany*, 1991, pp 302-307.
288. **Nerome K**, et al: Isolation and serological characterization of influenza A virus from birds that were dead on arrival at Tokyo airport. *Arch Virol* 57:261-270, 1978.
289. **Nerome K**, et al: Isolation of a new avian paramyxovirus from budgerigars. *J Gen Virol* 38:293-301, 1978.
290. **Neumann U**, et al: Neoplasms in budgerigar (*Melopsittacus undulatus*): Clinical, pathomorphological and serological findings with special consideration of kidney tumors. *Avian Pathol* 12:353-362, 1983.
291. **Neumann U**: Lymphoproliferative Krankheit der Puten. In Heider G, et al: *Krankheiten des Wirtschaftsgeflügels*, ein Handbuch für Wissenschaft und Praxis. Stuttgart, Gustav Fischer Verlag Jena, 1992, pp 781-784.
292. **Niagro FD**, et al: Avian polyomavirus. Discordance between neutralizing antibody titers and viral shedding in an aviary. *Proc Assoc Avian Vet*, 1991, pp 22-26.
293. **Niagro FD**, et al: Use of polymerase chain reaction for detection of BFD in suspect birds. *Proc Assoc Avian Vet*, 1990, pp 25-37.
294. **Norton TM**, et al: Acyclovir pharmacokinetics and the efficacy of acyclovir against Pacheco's disease virus in quaker parakeets. *Proc Assoc Avian Vet*, 1989, pp 3-5.
295. **Nuttall PA**, et al: Poxvirus infections in the manx shearwater (*Puffinus puffinus*). *J Wildl Dis* 21:120-124, 1985.
296. **Okoh AE**: Newcastle disease in falcons (as vectors of the disease to poultry in Nigeria). *J Wildl Dis* 15:479-480, 1979.
297. **Olson NO**: A respiratory disease (bronchitis) of quail caused by a virus. *Proc 54th US Lefst San Assoc*, 1990, pp 171-174.
298. **Osterhaus A**, et al: Identification and characterization of a papillomavirus from birds (Fringillidae). *Intervirology* 8:351-359, 1977.
299. **Otis K**, et al: Isolation and characterization of ortho- and paramyxovirus from feral birds in Europe. *Zbl Vet Med B* 30:22-35, 1983.
300. **Ozdemir I**, et al: Monoclonal antibodies to avian paramyxovirus type 2. *Avian Pathol* 19:395-400, 1990.
301. **Pacheco G**, et al: Epizootie chez les perroquets du Brésil. Relations avec la psittacose. *CR Soc Biol*, (Paris) 105:109-111, 1930.
302. **Pascucci S**, et al: Characterization of a coronavirus-like agent isolated from coturnix quail. *Proc VIII Intl Congr WVPA*, Jerusalem, 1985, p 52.
303. **Pascucci S**, et al: Transmissible enteritis of guinea-fowl: Electron microscopic studies and isolation of a Rotavirus strain. *Proc 7th Intl Congr WVPA*, 1981, p 57.
304. **Pascucci S**, et al: CELO virus in guinea-fowl: Characterization on two isolates. *Proc 5 Intl Kongreß WVPA Vol II*, 1973, pp 1524-1531.
305. **Pass DA**, et al: Granulomatous dermatitis in peach-faced lovebirds. *Aviat Vet J* 64:285-287, 1987.

CHAPTER 32 VIRUSES

- 305a. **Pass DA:** Inclusion bodies and hepatopathies in psittacines. *Avian Pathology* 16:581-597, 1987.
306. **Pass DA, et al:** The pathology of psittacine beak and feather disease. *Aust Vet J* 61:69-74, 1984.
307. **Pass DA, et al:** A papova-like virus infection of splendid parakeets (*Neophema splendida*). *Avian Dis* 31:680-684, 1987.
308. **Pass DA, Perry RA:** Psittacine beak and feather disease. An update. *Aust Vet Pract* 15:55-60, 1985.
309. **Pass DA, Perry RA:** The pathogenesis of psittacine beak and feather disease. *Proc Assoc Avian Vet* 1984, pp 113-119.
310. **Pass DA:** A papova-like virus infection of lovebirds (*Agapornis* sp.). *Aust Vet J* 82:318-319, 1985.
311. **Pass DA:** Inclusion bodies and hepatopathies in psittacines. *Avian Pathol* 16:581-597, 1987.
312. **Payne LN (ed):** Marek's Disease. Boston, Martinus Nijhoff, 1985.
313. **Payne LN, et al:** Leucosis/sarcoma group. In Calnek BW, et al (eds): *Diseases of Poultry* 9th ed. Ames, Iowa State University Press, 1991, pp 386-349.
314. **Perelman B, et al:** Pox in ostriches. *Avian Pathol* 17:735-739, 1988.
315. **Perry RA:** Some feather characteristics of acute french molt in fledgling budgerigars (*Melopsittacus undulatus*). *Aust Vet Pract* 13:128, 1983.
316. **Perry RA:** A psittacine combined beak and feather disease syndrome with particular reference to the Australian cockatoos *Cacatua galerita* (Sulphur-crested Cockatoo), *Cacatua leadbeateri* (Major mitchell or Pink Cockatoo), *Cacatua roseicapilla* (Galah or Rose-breasted Cockatoo) and *Cacatua sanguinea* (Little Corella). Univ Sydney. Post-grad Comm Vet Sci. Refresher Course on Aviary and Caged Birds Proc No 55, 1981, pp 81-104.
317. **Perry RA, Pass DA:** Psittacine beak and feather disease including French molt in parrots in Australia. *Proc Aust Vet Poultry Assoc*, 1985, pp 35-38.
- 317a. **Perry RA:** Beak rot in Sulfur Crested Cockatoos. The University of Sydney. The post-graduate committee in veterinary science. Control and therapy article 2:329 (No 329), 1975.
318. **Petrak ML (ed):** Diseases of Caged and Aviary Birds 2nd ed. Philadelphia, Lea & Febiger, 1982.
319. **Pfister R:** Zur Verträglichkeit und Wirksamkeit einiger Adjuvantien in Impfstoffen gegen die Paramyxoviriose der Tauben. *Vet Diss*, München, 1987.
320. **Phalen DN, Wilson DG, Graham DL:** Polymerase chain reaction assay for avian polyomavirus. *J Clin Micro* 29:1030-1037, 1991.
- 320a. **Phalen DN:** Acute pancreatic necrosis in an umbrella cockatoo. *Proc Assoc Avian Vet* pp 203-205, 1988.
321. **Phalen DN, Wilson DG, Graham DL:** Avian polyomavirus biology and its clinical applications. *Proc Europ Conf Avian Med & Surg*, 1993, pp 200-216.
322. **Philpott, MS et al:** Antigenic and phenotypic variants of a virulent avian influenza virus selected during replication in ducks. *J Wildl Dis* 25:507-513, 1989.
323. **Pieper K, et al:** Directions for use: Pacheco's disease vaccine, killed virus. 1st Conf Europ Assoc Avian Vet, 1991, pp 210-211.
324. **Pomeroy BS, et al:** Coronavirus enteritis of turkeys (bluecomb disease). In Calnek BW, et al (eds): *Diseases of Poultry* 9th ed. Ames, Iowa State University Press, 1991, pp 621-627.
325. **Potel K:** Geflügelpocken, Variola avium. In Rohrer H: *Hanbuch der Virusinfektionen bei Tieren*. Vol II. Gustav Fischer Verlag, Jena, 1967, pp 603-613.
- 325a. **Pringle CR:** Paramyxoviridae. In: Francki RIB, et al (eds): *Classification and nomenclature of viruses*. Springer Verlag Wien-New York pp 242-246, 1991.
326. **Ramis AJ, et al:** Inclusion body hepatitis (IBH) in a group of *Electus roratus*. *Proc Europ Assoc Avian Vet*, 1991, pp 444-446.
327. **Randall CJ, et al:** Papovavirus-like infection in budgerigars (*Melopsittacus undulatus*). *Avian Pathol* 16:623-633, 1987.
328. **Reece RL, et al:** Inclusion body hepatitis in a tawny frogmouth (*Podargus strigoides*: Caprimulgiformes). *Aust Vet J* 62:426, 1985.
329. **Reece RL, et al:** Inclusion body hepatitis in guinea fowl (*Numida meleagris*). *Aust Vet J* 63:26-27, 1986.
330. **Reed WM:** Characterization of pox viruses isolated from recent outbreaks of avian pox. *Proc West Poultry Dis Conf Supplement*, 1991, pp 11-12.
331. **Reed WM:** Pathogenicity and immunologic relationship of quail and mynah pox viruses to fowl and pigeon pox viruses. *Proc 37th West Poultry Dis Conf*, 1988, pp 5-8.
332. **Reid HW, et al:** Experimental Louping-ill virus infection of black grouse (*Tetrao tetrix*). *Arch Virology* 78:, 1983.
333. **Richter R:** Paramyxovirusinfektion bei Tauben. DVG III Tagung Vogelkrankheiten, München, 1983, pp 86-95.
334. **Richter R:** Untersuchungen zur Steigerung der Immunantwort durch den Paramunitätsinducer PIND Off beim Geflügel. *Diss med vet*, München, 1983.
335. **Riddell C:** Virus hepatitis in domestic geese in Saskatchewan. *Avian Dis* 28:774-782, 1984.
336. **Rinaldi A, et al:** Atti della Societa Italiana delle Scienze Veterinarie 22:77-782, 1968.
337. **Ritchie BW, et al:** A review of psittacine beak and feather disease. *J Assoc Avian Vet* 3:143-149, 1989.
338. **Ritchie BW, et al:** Advances in understanding the PBFD virus. *Proc Assoc Avian Vet*, 1990, pp 12-24.
339. **Ritchie BW, et al:** Antibody response to and maternal immunity from an experimental psittacine beak and feather disease vaccine. *Am J Vet Res* 53:1512-1518, 1992.
340. **Ritchie BW, et al:** Hemagglutination by psittacine beak and feather disease virus and use of hemagglutination inhibition for detection of antibodies against the virus. *Am J Vet Res* 52:1810-1815, 1991.
341. **Ritchie, BW, et al:** Production and characterization of monoclonal antibodies to psittacine beak and feather disease virus. *J Vet Diagn Invest* 4:13-18, 1992.
342. **Ritchie BW, et al:** Routes and prevalence of shedding of psittacine beak and feather disease virus. *Am J Vet Res* 52:1804-1809, 1991.
343. **Ritchie BW, et al:** Ultrastructural, protein composition and antigenic comparison of Psittacine Beak and Feather Disease virus purified from four genera of psittacine birds. *J Wildl Dis* 26:196-203, 1990.
344. **Ritchie BW, et al:** Polyomavirus infections in adult psittacine birds. *J Assoc Avian Vet* 5:202-206, 1991.
345. **Ritchie BW, Niagro FD, Lukert PD, et al:** Characterization of a new virus from cockatoos with psittacine beak and feather disease. *Virology* 171:83-88, 1989.
346. **Ritchie BW:** A review of eastern equine encephalomyelitis in pheasants. *Assoc Avian Vet Today* 1:152-154, 1987.
347. **Roizman B, et al:** Herpesviridae, definition, provisional nomenclature and taxonomy. *Intervirology* 16:201-217, 1981.
348. **Romvary J, et al:** The role of wild birds in the spread of influenza viruses. *Acta Microbiol Acad Sci Hung* 27:269-277, 1980.
349. **Rosenberger JK, et al:** Reovirus infections. In: Calnek BW: *Diseases of poultry*. 9th ed., Wolfe Publishing Ltd pp 639-647, 1991.
350. **Rosenberger JK:** Reovirus interference with Marek's virus vaccination. *Proc 32th West Poultry Dis Conf*, 1983, pp 50-51.
351. **Roskopf WJ, et al:** Erythremic myelosis in conures, the "hemorrhagic conure syndrome" - a preliminary report. *Proc Intl Conf Avian Med*, 1984, pp 213-228.
352. **Roskopf WJ Jr:** Vaccine therapy for papillomas. *Assoc Avian Vet Today* 1:202, 1987.
353. **Rotz von A, et al:** Letal verlaufende Herpesvirusinfektion bei Gouldsamadinen (*Chloebia gouldinae* [Gould]). *Schweiz Arch Tierheilk* 126:651-658, 1984.
354. **Sabban MS:** Susceptibility and possible role of doves in transmission of Newcastle disease in Egypt. *Zbl Vet Med* 29:193-198, 1982.
355. **Schaffner T, Herring J, Gerber H, Cottier H:** Bursa of Fabricius: Uptake of radioactive particles and radiotoxic sealing of basal follicles. *Adv Exp Med Bio* 66:33-39, 1976.
356. **Schat KA, et al:** A tumor-like disease in the Japanese quail. *Proc 24th West Poultry Dis Conf*, 1975, pp 5-6.
357. **Schat KA, et al:** Intestinal immunity in avian species. *Proc West Poultry Dis Conf* pp. 21-22, 1990.
358. **Schemera B et al:** A paramyxovirus of the serotype 3 from African, Australian and Indian finches. *Proc Europ Symp Avian Dis*, Beerse, 1987, pp 89-97.
359. **Schettler CH:** Die Virushepatitis der Gänse. *Vet Hab Schrift*, München, 1973.
360. **Schettler CH:** Virus hepatitis of geese. 3. Properties of the causal agent. *Avian Pathol* 2:179-193, 1973.
361. **Schettler H:** Eine infektiöse Leberentzündung (Hepatitis) der Eulen. *Tierärzt Umsch*, 1969, p 163.
362. **Schmidt RE:** Pathologist's view of PBFD in African greys. *J Assoc Avian Vet* 4:18, 1990.
363. **Schmidt RE, et al:** Morphologic identification of a papovavirus in a Moluccan cockatoo (*Cacatua moluccensis*) with neurologic signs. *Assoc Avian Vet Today* 1:107-108, 1987.
364. **Schmidt J, et al:** Immunologische Probleme der Influenzavirusinfektion. *Arch Exp Vet Med* 32:377-390, 1978.
365. **Schneegans D:** Erfahrungen mit der Paramunisierung Bei Vogeln. *Tierärzt Praxis* 17:293-295, 1989.
366. **Schneegans D:** Nachweise von Paramyxovirus-1 bei Bartgeiern (*Gypaetus barbatus*) DVG VII. Tagung Vogelkrankheiten, München 1990, pp 262-269.
367. **Schneegans D, et al:** Zum aktuellen Vorkommen aviärer Paramyxoviren. *Tierärzt Prax* 16:159-160, 1988.
368. **Schödel F, et al:** The biology of avian hepadna viruses. In *Molecular Biology of Hepatitis B Virus*. Raton, CRC Unisience, 1990.
369. **Schönbauer M, et al:** Über eine Virusinfektion bei Prachtfinken (Estrildidae). *Kleintierpraxis* 27:149-152, 1982.
370. **Schraishuhm P, et al:** Ergebnisse virologischer Untersuchungen und ca. 1012 Brieftauben. DVG VII Tagung Vogelkrankh. München, 1990, pp 114-119.
371. **Schroder D:** Untersuchungen am Hepesvirus der Hepatosplenitis infectiosa strigum. VII DVG-Tagung Vogelkrankh, München, 1990, pp 298-304.
372. **Scott PC, et al:** Inclusion body hepatitis associated with adenovirus-like particles in a cockatiel (Psittaciformes: *Nymphicus hollandicus*). *Aust Vet J* 63:337-338, 1986.
373. **Several Authors:** Open forum on the use of Pacheco's disease vaccines in psittacines. *J Assoc Avian Vet* 5:10-14, 1991.
374. **Shablovskaja EA, et al:** Isolation von semiantropischen Viren von semiantropischen Vogelarten in der Rovnregion der Ukrainischen SSR. *Vopr Virusol Moskva* B14:414-418, 1977.
375. **Shakal M:** Zur Isolierung und Charakterisierung von aviären Paramyxovirus-Stämmen aus ägyptischen und deutschen Hausstauben (*Columba livia* Gmel. 1789 var. dom.) unter Verwendung von permanentzellen. *Vet Diss*, München, 1989.
376. **Show K:** Papovaviruses. In *Fields BN, et al (eds): Virology*. Raven Press, New York, 1985, pp 371-391.
377. **Shortridge KF, et al:** Isolation and properties of viruses from poultry in Hong Kong which present a new (sixth) distinct group of avian paramyxoviruses. *J Gen Virol* 50:410-418, 1981.
378. **Siegmann O:** Kompendium der Geflügelkrankheiten 4th ed. Hannover, Verlag M&H Schaper, 1983.
379. **Sileo L, et al:** Hemorrhagic enteritis in captive American kestrels (*Falco sparverius*). *J Wildl Dis* 19:244-247, 1983.
380. **Simpson CF, et al:** Psittacine herpesvirus infection resembling Pacheco's parrot disease. *J Infect Dis* 131:390-396, 1975.
381. **Sironi G, et al:** Papovavirus-like splenohepatic infection in greenfinches (*Carduelis chloris*). *Clinica Veterinaria* 110:79-82, 1987.
382. **Sironi G:** Concurrent papavirus-like and atoxoplasma infections in a gold finch (*Carduelis carduelis*). *Avian Path* 20:725-729, 1991.
383. **Slemons RD, et al:** Type A-Influenza virus in wild free-flying birds. 3rd Intl Wildl Dis Conf, Munich, 1975.
384. **Smadel JE, et al:** A new virus disease of pigeons: I Recovery of the virus. *J Exp Med* 81:385-398, 1945.
385. **Smit TH, et al:** Studies on a virus isolated from the brain of a parakeet (*Neophema* sp.). *Avian Pathology* 5:21-30, 1976.
386. **Smith RE:** Psittacine feather and beak disease: A cluster of cases in a cockatoo breeding facility. *Proc Assoc Avian Vet*, 1986, pp 17-20.
387. **Smilka CW, et al:** Ortho- and paramyxoviruses in the migratory waterfowl of Michigan (Possible transfer to domestic fowl). *J Wildl Dis* 17:147-151, 1981.
388. **Snoyenbos GH:** Turkey liver hepatitis. In Calnek BW, et al (eds): *Diseases of Poultry* 9th ed. Ames, Iowa State University, 1991, pp 699-701.
389. **Spackman D, et al:** Isolation of infectious bronchitis virus from pheasants. *Ver Rec* 113:354-355, 1983.
390. **Speer B:** Proventricular dilatation as a pediatric disease. *J Assoc Avian Vet* 4:15, 1990.
391. **Speer B:** Unusual expression of PBFD. *J Assoc Avian Vet* 4:19, 1990.
392. **Speer BL:** The eclectus parrot, medicine and avicultural aspects. *Proc Assoc Avian Vet*, 1989, pp 239-247.
393. **Sprengel R, et al:** Hepatitis B Viren bei Enten, Gänsen und Graureihern: Epidemiologie, Diagnostik und Pathogenese. VI DVG-Tagung Vogelkrankh, München, 1988, pp 176-187.
394. **Stallknecht DE, et al:** Avian paramyxoviruses from migrating and resident ducks in coastal Louisiana. *J Wildl Dis* 27:123-128, 1991.
395. **Steenis van G:** Survey of various avian species for neutralizing antibody and susceptibility to avian encephalomyelitis virus. *Res Vet Sci* 12:308-311, 1971.
396. **Stehle S:** Krankheiten bei Greifvögeln (Accipitres) und bei Eulen (Strages) mit Ausnahme der

- parasitären Erkrankungen. Vet Diss, Hannover, 1965.
397. **Stoll R, et al:** Molecular and biological characteristics of avian polyomaviruses: Isolates from different species of birds indicate that avian polyomaviruses form a distinct subgenus within the polyomavirus genus. *J Gen Virol* in press.
398. **Stünzner D, et al:** Isolierung von Influenzaviren aus exotischen und mitteleuropäischen Vogelarten. *Zbl Bakt Hyg I Abt Orig A* 247:8-17, 1980.
399. **Sundberg JP, et al:** Cloacal papillomas in psittacines. *Am J Vet Res* 47:928-932, 1986.
400. **Takase K, et al:** Cytopathic avian rotavirus isolated from duck feces in chicken kidney cell cultures. *Avian Pathol* 15:719-730, 1986.
401. **Tanyi J, et al:** Influenzavirus-A-Infektion. In Heider, et al: *Krankheiten des Wirtschaftsgeflügels, ein Handbuch für Wissenschaft und Praxis*. Stuttgart, Gustav Fischer Verlag Jena, 1992, pp 669-682.
402. **Tanyi J:** Type A Influenza virus infection in guinea fowls. *Acta Vet Acad Sci Hung* 22:125-131, 1972.
403. **Tikasingsh ES, et al.:** Avian pox in birds from Trinidad. *J Wildl Dis* 18:133-139, 1982.
404. **Todd D, et al:** Comparison of three animal viruses with circular single-stranded DNA genomes. *Arch Virol* 117:129-135, 1991.
406. **Trampel DW, et al:** Parvovirus-like enteropathy in Missouri turkeys. *Avian Dis* 27:49-54, 1983.
407. **Trötschel A:** Pathomorphologie der akuten Form der Nephro-Enteritis der Junggänse. Vet Diss, München, 1973.
408. **Tudor DC:** Pigeon Health and Disease. Ames, Iowa State University Press, 1991, pp 47-49.
409. **Tully TN:** Eastern equine encephalomyelitis in emus. *Proc Assoc Avian Vet*, 1992, pp 316-317.
410. **Tumova B, et al:** A further member of the Yucaipa group isolated from the common wren (*Troglodytes troglodytes*). *Acta Virol* 23:504-507, 1979.
411. **Uytenbroek E, et al:** Epidemiology of Adenovirus infections in pigeons. *Proc Europ Assoc Avian Vet*, 1991, 289-292.
412. **VanDerHeyden N:** Psittacine papillomas. *Proc Assoc Avian Vet*, 1988, pp 23-26.
413. **VanDerHeyden N, et al:** Paramyxovirus group 3 infection in cockatiels. *Assoc Avian Vet Today* 1:53-54, 1987.
414. **Vasicek L:** Paramyxovirus 1 in pigeons and its influence on Newcastle disease (ND)-unvaccinated poultry flocks. *Proc 8th Intl Cong WVPA*, 1985, pp 118.
415. **Vindevogel H, et al:** Incidence of rotavirus, adenovirus and herpesvirus in pigeons. *Vet Rec* 109:285-286, 1981.
416. **Vindevogel H, et al:** Reovirus infection in the pigeon. *Ann Rech Vet* 13:149-152, 1982.
417. **Vindevogel H, et al:** Comparison de trois souches de virus herpétique isolées des psittacides avec le virus herpétique du pigeon. *Avian Pathol* 9:385-394, 1980.
418. **Vogel K, et al:** Herpesvirus-1-Infektion der Tauben. In Heider, et al: *Krankheiten des Wirtschaftsgeflügels. Ein Handbuch für Wissenschaft und Praxis*. Stuttgart, Gustav Fischer Verlag, Jena, 1992, pp 439-450.
419. **Waddell G, et al:** Genetic variability of adenoviruses. *Ann N Y Acad Sci* 354:16-42, 1980.
420. **Wadsworth PF, et al:** Some cases of lymphoid leukosis in captive wild birds. *Avian Pathol* 10:499-504, 1981.
421. **Wagner K, et al:** Ein im Hühnerrei vorkommendes Parainfluenzavirus. *Zbl Vet Med B* 13:215-218, 1966.
422. **Wagner K, et al:** Zur Epidemiologie des Parainfluenza-II-Virus der Hühner. *Dtsch tierärztl Wschr* 72:486-488, 1965.
423. **Wainright PO, et al:** Identification of viruses from amazon parrots with a hemorrhagic syndrome and a chronic respiratory disease. *Proc 1st Intl Conf Zool & Avian Med*, 1984, pp 15-19.
424. **Wainwright PO, et al:** Serological evaluation of some psittaciformes from budgerigar fledgling disease virus. *Avian Dis* 31:673-676, 1987.
425. **Wallner-Pendleton E, et al:** An inclusion-body pancreatitis in *Agapornis*. *Proc 32nd West Poult Dis Conf*, 1983, p 99.
426. **Ward FP, et al:** Inclusion body hepatitis in a prairie falcon. *J Wildl Dis* 7:120-124, 1971.
427. **Weingarten M:** Entenpest: Klinik, Diagnose, Bekämpfung. VI. DVG-Tagung Vogelkrhrt, 1988, pp 197-203, München.
428. **White DO, Fenner F (eds):** *Medical Virology* 3rd ed. Orlando, Academic Press Inc, 1986, pp 381-388.
429. **WHO Expert Committee:** A revision of the system of nomenclature for Influenza viruses: A WHO memorandum. *Bull WHO* 58:585-591, 1980.
430. **Will H, et al:** Hepatitis-B-Virus-Infektion der Enten. In Heider G, et al: *Krankheiten des Wirtschaftsgeflügels*. Stuttgart, Gustav Fischer Verlag Jena, 1992, pp 361-377.
431. **Winterfield RW, et al:** Immunization against psittacine pox. *Avian Dis* 29(3):886-890, 1985.
432. **Winterfield RW, et al:** Quail bronchitis. In Calnek BW, et al (eds): *Poultry Diseases* 9th ed. Ames, Iowa State University Press, 1991, p 564.
433. **Winteroll G, et al:** Schwere durch Herpesvirus verursachte Erkrankung des Respirationsapparates bei Amazonen. *Berl Münch Tierärztl Wschr* 92:277-280, 1979.
434. **Witter RL, et al:** Lymphomas resembling lymphoid leukosis in chickens inoculated with reticuloendotheliosis virus. *Int J Cancer* 23:6763-678, 1979.
435. **Witter RL, et al:** Tolerance, viral shedding and neoplasia in chickens infected with non-defective reticuloendotheliosis virus. *Avian Dis* 25:374-394, 1981.
436. **Witter RL:** Reticuloendotheliosis. In Calnek BW, et al (eds): *Diseases of Poultry* 9th ed. Ames, Iowa State University Press, 1991, pp 439-456.
437. **Woelfling P:** Über die Wirkung verschiedener Desinfektionsmittel und einige geflügelpathogene Virusarten. DVG-Tagung Fachgruppe "Geflügelkrankheiten" Oldenburg, 1976, pp 69-82.
438. **Wolter, HE:** Die Vogelarten der Erde. Hamburg und Berlin, Paul Parey, 1975-1982.
439. **Woods L, et al:** Comparison of PBFD virus and pigeon circovirus. In preparation.
440. **Woods L:** Case report: Papova-like virus in a painted finch. *Proc Assoc Avian Vet*, 1989, pp 218-219.
441. **Woolcock PR, et al:** Duck virus hepatitis. In Calnek BW, et al (eds): *Diseases of Poultry* 9th ed. Ames, Iowa State University Press, 1991, pp 597-608.
442. **Wyand DS, et al:** Marble spleen disease in ring-necked pheasants: Histology and ultrastructure. *Avian Dis* 16:319-329, 1972.
443. **Wyllie SL, Pass DA:** Experimental reproduction of psittacine beak and feather disease/French molt. *Avian Pathol* 16:269-281, 1987.
444. **Wyllie SL, Pass DA:** Investigations of an enteric infection of cockatoos caused by an entero-like agent. *Aust Vet J* 66:321-324, 1989.
445. **York SM, et al:** Pacheco's virus vaccine studies. *Proc 32th West Poult Dis Conf*, 1983, pp 101-103.
446. **Yuasa N, et al:** Isolation and some characteristics of an agent inducing anemia in chicks. *Avian Dis* 23:366-385, 1979.
447. **Zellen GK, et al:** Adenoviral pancreatitis in guinea fowl (*Numida meleagris*). *Avian Dis* 33:586-589, 1989.
448. **Zhang C, et al:** Differentiation of avian adenovirus type II strains by restriction endonuclease fingerprinting. *J Am Vet Med Assoc* 50:1466-1470, 1989.
449. **Zsak L, et al:** Characterization of adenovirus isolated from geese. *Avian Pathol* 13:253-264, 1984.
450. **Zwart P, et al:** Sialolithen (weiße Punkte) im Munddach bei Tauben III DVG-Tagung. Vogelkrhrt München, 1983, pp 39-45.