

EPIDIDYMAL CYSTS IN CHILDHOOD – CONSERVATIVE OR SURGICAL APPROACH?

JERZY NIEDZIELSKI, MIECZYŚŁAW MIODEK, MAREK KRAKÓŚ

Department of Pediatric Surgery and Urology, Chair of Pediatric Surgery, University School of Medicine in Łódź, University Children's Hospital No 4 in Łódź
Kierownik: prof. dr hab. J. Niedzielski

The aim of the study. To decide on the accurate way of treatment and to establish criteria for operation in boys with pubertal epididymal cysts (ECs).

Material and methods. Results of scrotal ultrasound of 363 boys and adolescents, aged 2 months to 18 years, were reviewed retrospectively.

Results. Of all 363 patients with scrotal ultrasound 59 (16.2%) at mean age of 14.03 yrs had ECs. The EC incidence increased with age and 42 out of 124 boys (33.8%) older than 14 yrs had cysts ($\chi^2=27.627$, $p=0.000$). Out of 59 patients, in 30 (50.8%) cysts were diagnosed incidentally at the time of scrotal US, 29 boys (49.2%) presented with scrotal mass and/or pain. 31 patients with ECs (52.5%) underwent elective surgery and the remaining 28 boys (47.5%) received conservative treatment. The age of boys with ECs who underwent surgery ranged from 8 to 18 years (mean 14.32). The age range of patients treated conservatively was 7-18 (mean 13.71). There was no statistical difference in age between boys treated surgically and conservatively ($t=0.924$, $p=0.36$). ECs resolved in 17 patients out of 28 boys treated conservatively, in remaining 11 boys the size of cysts was stable and they remain asymptomatic. Clinical and ultrasonographic follow-up were carried out from 11 months to 5 years.

Conclusions. ECs are more common in older boys (over 14 years). Management of ECs smaller than 10 mm should be conservative with clinical and ultrasound controls, leaving surgery for cysts increasing in size over 10 mm which did not involute with time.

Key words: epididymal cysts, childhood, scrotal ultrasound, operation, conservative treatment

Epididymal cysts (EC) usually develop in adult men. Although uncommon in children they occur in a number of boys in a pubertal age (1, 2). They present as single or multiple, uni- or bilateral spherical cysts localized in the head of the epididymis. Although the cause of EC and spermatocele is often unknown, it may be caused by obstruction of the epididymal ducts. They are usually of lymphatic origin. When small, ECs remain undetected and can be found in appr. 30% of asymptomatic patients having scrotal ultrasound for other reasons (3, 4). On the contrary to adolescent cysts most of these cysts detected in adults are spermatocele (5). ECs are less common than spermatoceles and are indistinguishable from the latter both at palpation and at US (6, 7). ECs contain clear serous fluid and may arise

throughout the epididymis while spermatoceles are filled with sperm and almost always arise in the epididymal head. However, authors do not recommend aspiration because its result does not change management (5).

When large, EC is noticed by patient as a scrotal mass which causes a great deal of anxiety and make him present to doctor. ECs while examine clinically present as extratesticular, fluctuant, firm swellings which usually can be easily palpable separate from the testicle. Scrotal ultrasound is recommended to confirm or help diagnosis in unclear cases (6, 7, 8). ECs and spermatoceles are differentiated from acute or chronic epididymitis, hydroceles, varicoceles, extratesticular scrotal masses (lipomas, lymphangiomas), epididymal tumours (adenomatoid tumour), testicular tumours (9, 10). ECs are

associated defects in children with cystic fibrosis (11), von Hippel-Lindau disease (12), and polycystic kidney disease (13). An increased incidence of ECs has been reported in boys who are exposed in utero to diethylstilbestrol (14).

Treatment is not usually necessary unless EC becomes painful or suddenly starts increasing in size. Then ECs should be treated surgically or by sclerotherapy (15, 16, 17). In children, most small ECs involute with time and a conservative approach is recommended (2). The large and symptomatic ECs should be surgically excised (1, 2, 4).

We performed this retrospective study to analyze the incidence of ECs in the population of boys and adolescents referred to urological OPD, usefulness of US examination in differential diagnosis, and to decide on the accurate way of treatment.

MATERIAL AND METHODS

We retrospectively reviewed records of 7364 boys and male adolescents referred to our urological OPD in 6 years between 2005 and 2010. We selected 363 patients aged 2 months to 18 years with scrotal ultrasounds done due to different reasons i.e. cryptorchidism, varicocele, inguinal hernia, hydrocele etc. Ultrasound examination was carried out with Philips iU22, linear transducers 12 MHz and 17 MHz, along with color flow Doppler.

We analyzed the incidence of ECs in this group of patients, age and mode of presentation, size of ECs, the way of treatment and outcome.

Statistical analysis was performed with t-test and chi-square test with use of STATISTICS PL 6.0 for Windows.

RESULTS

A total of 59 patients were identified with ECs. Average patient age at presentation was

14.03 years, range 7-18. Out of 59 patients, in 30 (50.8%) cysts were diagnosed incidentally at the time of scrotal US, 29 boys (49.2%) presented with scrotal mass and/or pain. In 26 boys (44.1%) left testicle, in 25 (42.4%) right testicle and in 8 instances (13.5%) both testes were involved. 45 patients (76.3%) were diagnosed to have 1 cysts, 9 boys with 2 cysts and 5 boys have 3 or more cysts in both testicles.

Cysts were between 3 and 29 mm; 28 patients (47.5%) have cysts of diameter 3-9 mm and 31 boys (52.5%) have cysts between 10-29 mm.

Of all 363 patients with scrotal ultrasound done 59 (16.2%) had ECs. The EC incidence increased with age and 42 out of 124 boys (33.8%) older than 14 years had cysts ($\chi^2=27.627$, $p=0.000$).

31 patients with ECs (52.5%) underwent elective surgery and the remaining 28 boys (47.5%) received conservative treatment (tab. 1). We arbitrarily established the criteria for operation, which were: ECs with diameter in US bigger than 10 mm, which didn't resolve in 12 months, or even increased size, persistent pain and palpable scrotal mass causing patient's anxiety (fig. 1A and 1B.).

The age of boys with ECs who underwent surgery ranged from 8 to 18 years (mean 14.32, $SD=2.31$, $Me=15$). Most of the boys were older than 14 years (23/31 – 74.2%) and all but one were older than 10 years (30/31 – 96.8%). All excised cysts were examined histopathologically; in 29 boys ECs with the wall lined with cuboid and/or cylinder epithelium were found. In 2 instances spermatocele was diagnosed.

We operated on two more boys who were excluded from present series. First was 2-year-old boy with acute scrotum caused by orchiepididymitis in which 8 mm EC was found and excised, and the other was 5-year-old boy in whom 5 mm EC was excised during orchiopexy.

The age range of patients treated conservatively was 7-18 (mean 13.71, $SD=2.76$, $Me=14$) Most of the boys were older than 14 years

Table 1. Boys with epididymal cysts with consideration to age and way of treatment

Patient's age (in years)	Operative treatment				Conservative treatment				Total
	left side	right side	bilateral	total	left side	right side	bilateral	total	
0-9	-	1 (2)	-	1 (2)	1	1	-	2	3 (5,1%)
10-13	3	4	-	7	3	2	2	7	14 (23,7%)
14-18	11	11	1	23	8	6	5	19	42 (71,2%)
Total	14	16	1	31	12	9	7	28	59

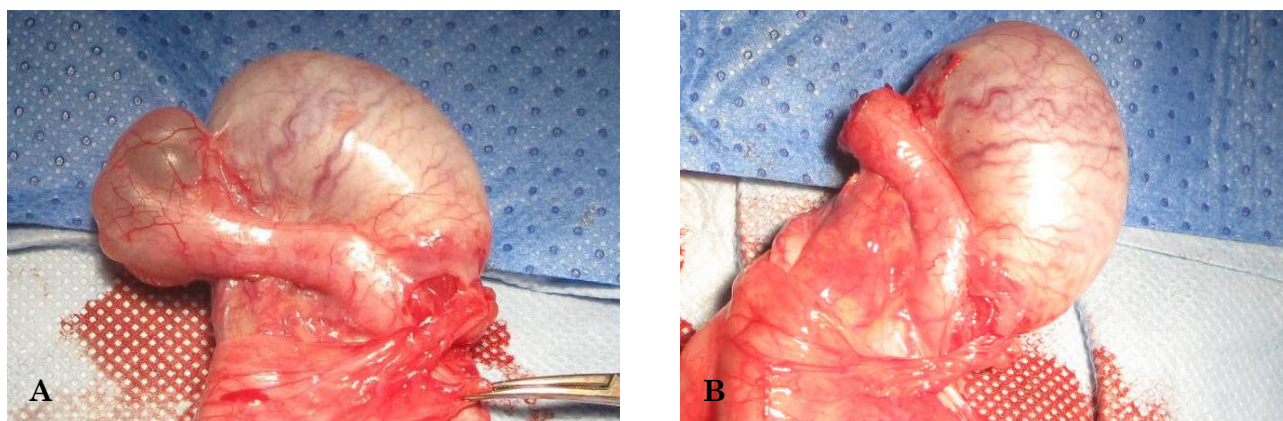


Fig. 1. Intraoperative view of 19 mm EC localized in the head of right epididymis in 17-year-old adolescent presenting with scrotal mass and pain: A – before excision; B – after excision

(19/28 – 67.8%) and all but two were older than 10 years (26/28 – 92.8%). There was no statistical difference in age between boys treated surgically and conservatively ($t=0.924$, $p=0.36$).

ECs resolved in 17 patients out of 28 boys treated conservatively, in remaining 11 boys the size of cysts was stable and they remain asymptomatic. Clinical and ultrasonographic follow-up were carried out from 11 months to 5 years (fig. 2.).

None of our patients had a history of exposure to diethylstilbestrol, cystic fibrosis or von Hippel-Lindau disease. In one 8-year-old boy EC was associated with bronchial asthma.

DISCUSSION

Still, there is no consensus about the most adequate therapy of pubertal EC. Most of ECs in children involute with time and therefore

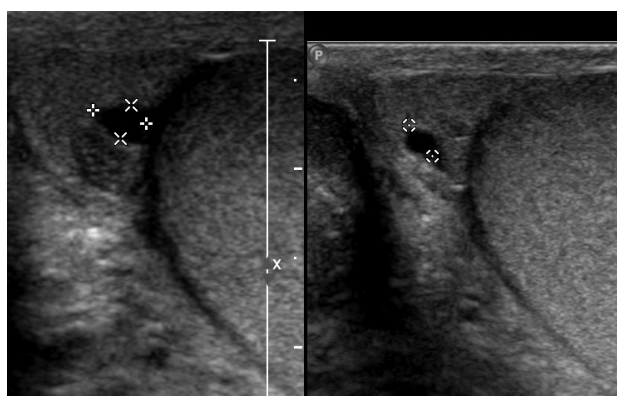


Fig. 2. Sagittal and longitudinal sonograms of right testis in 10-year-old boy show 3 mm EC observed for 18 months

don't require treatment (1, 2, 4). If EC becomes symptomatic and / or doesn't resolve or suddenly starts increasing in size, should be treated surgically or by sclerotherapy. Although the number of authors recommend sclerotherapy as a procedure of choice in ECs, we are skeptical about using this method in the developing gonads of boys and adolescents. Especially, that these authors indicate that sclerotherapy is a primary treatment for hydroceles, spermatocele and epididymal cysts in elderly men in whom fertility is not important (15, 18).

Sclerosant solutions used include tetracycline, phenol, sodium tetradecyl sulphate, polidocanol and ethanolamine oleate (15-18). However, the use of sclerosants for purpose other than treatment of varicocele is unlicensed and no reports proved effectiveness of one sclerosant over another.

The other reason that we don't recommend sclerotherapy for ECs are diagnostic mistakes reported in literature and the ones we experienced. Although scrotal ultrasound proved to be a method of choice in diagnostics of ECs (3, 8) it is not free of false positive results. There are cystic tumors which can present like EC on scrotal ultrasound, i.e. adenomatoid tumor of epididymis (10), simple cyst of the testis, cyst of the tunica albuginea, epidermoid cyst (monodermal teratoma) of the testis (9, 19, 20, 21). According to Heidenreich (20) and Reinberg (21) the ultrasonographic appearance of epidermoid cyst of the testis is not specific and exploratory surgery is recommended in all cases.

We operated on 16-year-old boy with 18 mm EC diagnosed in US which appeared to be a small hydrocele "imprisoned" near the head of

epididymis by adhesions probably due to past history of orchiepididymitis (fig. 3). The other case of misleading ultrasound finding was 14-year-old patient with double EC (fig. 4A) which turned out to be two pedicled cystic appendages of epididymis (fig. 4B).

Thus, we would rather observe EC with repeated scrotal US than use sclerotherapy, especially that ECs do not become infected (22) and complications such as torsion of the cyst are extremely rare (23).

Basing on our experience and opinions shared in literature we established criteria for operation (see: Material and methods) which were met by 31 patients with ECs (52.5%) who underwent elective surgery. Chillon et al. operated 6 of 15 patients (40%) with ECs over 5 years (1). In Homayoon et al. series only one out of 20 patients (5%) with ECs required surgery in twelve years (2). Jelloul et al. operated on 3 boys with symptomatic ECs pointing that “the treatment of symptomatic epididymal cyst in children must be surgical” (4).

Our findings confirmed observations of other authors, that ECs occur in older boys and adolescents. In our series 94.9% of patients with ECs were older than 10 years, and 71.2% of these boys were older than 14 years, with mean 14 yrs. Chillon et al. reported 15 patients with ECs with mean age 11.5 years, and Homayoon et al. – 20 patients with average age of 10.5 (1, 2).

In Posey's et al. series the incidence of ECs was 14.4% and increased to 35.5% in boys older than 15 years (3). Kalina-Faska et al. found ECs in 5.5% boys, aged 2-17 years with

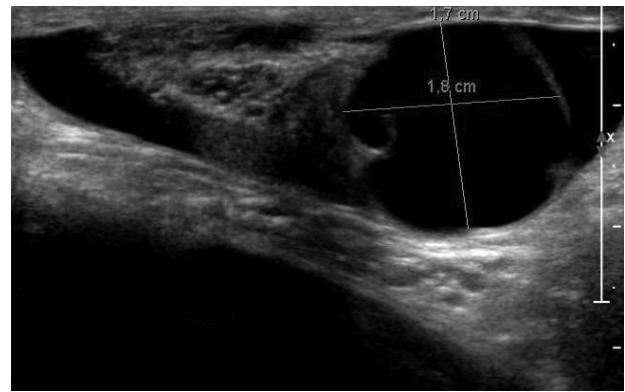


Fig. 3. Transverse sonogram of left testis in 16-year-old adolescent showing 18 mm EC, which intraoperatively appeared to be a small hydrocele “imprisoned” by adhesions near the head of epididymis

scrotal ultrasounds performed because of different scrotal pathology (8). Blau et al. reported 25% occurrence of ECs in boys with cystic fibrosis comparing with no cysts found in 16 healthy controls. They were more frequent in pancreatic insufficient than in pancreatic sufficient cystic fibrosis patients (11). We observed ECs in 16.2% of patients with scrotal ultrasound and the incidence increased to 33.8% in boys older than 14 years.

CONCLUSIONS

1. Epididymal cysts are more common in older boys (over 14 years).
2. We believe that the treatment of big and/or symptomatic pubertal epididymal cyst must be surgical.

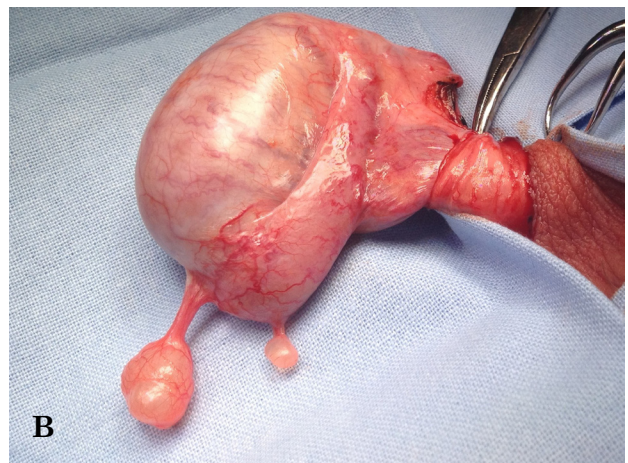
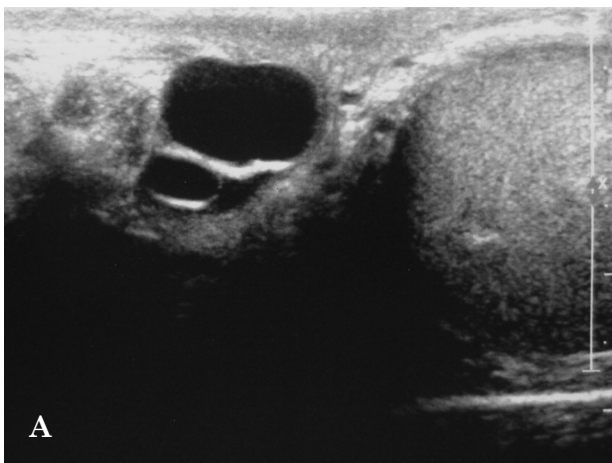


Fig. 4. A – transverse sonogram of left testis in 14-year-old patient shows two cysts of the head of epididymis; B – intraoperative view of two pedicled cystic appendages of epididymis in the same patient

3. For small asymptomatic cysts, clinical and sonographic follow-up to document stability of the mass is justified.
4. If the cyst increases in size (over 10 mm) and doesn't involute with time, it should be excised.

REFERENCES

1. Chillón Sempere FS, Domínguez Hinarejos C, Serrano Durba A et al.: Epididymal cysts in childhood. *Arch Esp Urol* 2005; 58(4): 325-28.
2. Homayoon K, Suhre CD, Steinhardt GF: Epididymal cysts in children: natural history. *J Urol* 2004; 171(3): 1274-76.
3. Posey ZQ, Ahn HJ, Junewick J et al.: Rate and associations of epididymal cysts on pediatric scrotal ultrasound. *J Urol* 2010; 184(4 Suppl): 1739-42. Epub 2010 Aug 21.
4. Jelloul L, Billerey C, Ait Ali Slimane M et al.: Epididymal cysts in adolescents. *Ann Urol* 1999; 33(2): 104-08.
5. Walsh TJ, Seeger KT, Turek PJ: Spermatocetes in adults: when does size matter? *Arch Androl* 2007; 53(6): 345-48.
6. Lee JC, Bhatt S, Dogra VS: Imaging of the epididymis. *Ultrasound Q* 2008; 24(1): 3-16.
7. Muttarak M, Chaiwun B: Painless scrotal swelling: ultrasonographical features with pathological correlation. *Singapore Med J* 2005; 46(4): 196-201.
8. Kalina-Faska B, Januszek-Trzciakowska A, Kalina M et al.: Ultrasound examination of the scrotum in boys. *Endokrynol Diabetol Chor Przemiany Materii Wieku Rozw* 2002; 8(1): 35-40.
9. Woodward PJ, Schwab CM, Sesterhenn IA: From the archives of the AFIP: extratesticular scrotal masses: radiologic-pathologic correlation. *Radiographics* 2003; 23(1): 215-40.
10. Vick CW 3rd, Klein FA, Schneider V: Adenomatoid tumor of epididymis simulating benign cyst on scrotal ultrasound. *Urology* 1991; 38(4): 369-71.
11. Blau H, Freud E, Mussaffi H et al.: Urogenital abnormalities in male children with cystic fibrosis. *Arch Dis Child* 2002; 87(2): 135-38.
12. Joerger M, Koeberle D, Neumann HP et al.: Von Hippel-Lindau disease-a rare disease important to recognize. *Onkologie* 2005; 28(3): 159-63.
13. Belet U, Danaci M, Sarikaya S et al.: Prevalence of epididymal, seminal vesicle, prostate, and testicular cysts in autosomal dominant polycystic kidney disease. *Urology* 2002; 60(1): 138-41.
14. Conley GR, Sant GR, Ucci AA et al.: Seminoma and epididymal cysts in a young man with known diethylstilbestrol exposure in utero. *JAMA* 1983; 11, 249: 1325-26.
15. Sigurdsson T, Johansson JE, Jahnson S et al.: Polidocanol sclerotherapy for hydroceles and epididymal cysts. *J Urol* 1994; 151(4): 898-901.
16. Freedman D: A lovely bunch of coconuts. *Scand J Urol Nephrol Suppl* 1991; 138: 227-29.
17. Braslis KG, Moss DI: Long-term experience with sclerotherapy for treatment of epididymal cyst and hydrocele. *Aust N Z J Surg* 1996; 66(4): 222-24.
18. Tammela TL, Hellström PA, Mattila SI et al.: Ethanolamine oleate sclerotherapy for hydroceles and spermatocetes: a survey of 158 patients with ultrasound followup. *J Urol* 1992; 147(6): 1551-53.
19. Masuda H, Yamada T, Nagahama K et al.: Three cases of cystic testicular disease: simple cyst of the testis, cyst of the tunica albuginea and mature cystic teratoma. *Hinyokika Kiyo* 1993; 39(3): 265-68.
20. Heidenreich A, Engelmann UH, Vietsch HV et al.: Organ preserving surgery in testicular epidermoid cysts. *J Urol* 1995; 153(4): 1147-50.
21. Reinberg Y, Manivel JC, Llerena J et al.: Epidermoid cyst (monodermal teratoma) of the testis. *Br J Urol* 1990; 66(6): 648-51.
22. Gunaydin G, Ozyurt C, Kocak I et al.: Antibacterial activity of the fluid contents of spermatocetes and epididymal cysts. *Br J Urol* 1995; 75(1): 68-70.
23. Yilmaz E, Batislam E, Bozdogan O et al.: Torsion of an epididymal cyst. *Int J Urol* 2004; 11(3): 182-83.

Received: 24.07.2012 r.

Adress correspondence: 91-738 Łódź, ul. Sporna 36/50