



Hepatozoon procyonis INFECTIONS IN TEXAS *

Authors: CLARK, KEITH A., ROBINSON, R. M., and WEISHUHN, L. L.

Source: Journal of Wildlife Diseases, 9(2) : 182-193

Published By: Wildlife Disease Association

URL: <https://doi.org/10.7589/0090-3558-9.2.182>

BioOne Complete (complete.BioOne.org) is a full-text database of 200 subscribed and open-access titles in the biological, ecological, and environmental sciences published by nonprofit societies, associations, museums, institutions, and presses.

Your use of this PDF, the BioOne Complete website, and all posted and associated content indicates your acceptance of BioOne's Terms of Use, available at www.bioone.org/terms-of-use.

Usage of BioOne Complete content is strictly limited to personal, educational, and non - commercial use. Commercial inquiries or rights and permissions requests should be directed to the individual publisher as copyright holder.

BioOne sees sustainable scholarly publishing as an inherently collaborative enterprise connecting authors, nonprofit publishers, academic institutions, research libraries, and research funders in the common goal of maximizing access to critical research.

Hepatozoon procyonis INFECTIONS IN TEXAS*

KEITH A. CLARK, R. M. ROBINSON, L. L. WEISHUHN, Department of Veterinary Pathology

T. J. GALVIN, Department of Veterinary Parasitology, and

KALMAN HORVATH, Department of Biology, Texas A & M University, College Station, Texas, 77843, U.S.A.

Abstract: The literature related to *Hepatozoon* infections is reviewed; observations from the study of spontaneous hepatozoonosis in 57 raccoons (*Procyon lotor*) and one white-tailed deer (*Odocoileus virginianus*) are presented, with special reference to pathogenesis.

INTRODUCTION

Hemogregarine parasites of the genus *Hepatozoon* have been recorded from a wide variety of vertebrate and invertebrate hosts. The range of vertebrate hosts includes reptiles, rodents, insectivores, marsupials, carnivores and ungulates. Infections of rodents and reptiles are most commonly reported. Tables I and II are partial compilations of *Hepatozoon* species described for rodents and reptiles, respectively.

Hepatozoonosis in carnivores has been less frequently reported but has been well documented in some parts of the world. *Hepatozoon canis* infections are found in dogs in India,^{10,17,37,63} Africa,⁶⁰ Ceylon,²⁹ Iraq,⁷⁰ France,⁶⁷ Egypt,²⁷ and Malaya.^{32,44} A hepatozoon, *H. chattoni*, of the jackal (*Canis aureus*),^{53,58} was described in African hyenas (*Crocuta crocuta*),^{40,43} Wild foxes (*Vulpes bengalensis*) in India were found to be naturally infected with a parasite morphologically identical to *H. canis*.⁶⁴ Hepatozoonosis (species undetermined) has also been reported in lions (*Panthera leo*)^{12,13,43} and leopards (*Panthera parda*)^{13,40} in Africa.

H. hoogstraali has been described from an insectivore, *Hemicentetes semispinosus*,⁷¹ and *Hepatozoon* infections have been reported in genet cats (*Gentta tigrina* and *G. rubiginosa*)^{13,39,40} palm civets

(*Paradoxurus hermaphroditus*),⁴⁴ South American opossums (*Didelphys didelphys*),⁷² and eight species of Australian mammals.⁴⁵ Rabbits and domestic cats have also been reported to have *Hepatozoon* infections, but detailed information is lacking.^{59,60,66} In the Americas, *Hepatozoon* infections in carnivores occur principally in raccoons.^{66,70} The species is *H. procyonis*, and it has been reported from *Procyon lotor* in Georgia and from *P. cancrivorus* in Panama.

Hepatozoon infections in ungulates are apparently rare: A hepatozoon found in impala (*Aepyceros melampus*) was presumed to be *H. canis* on the basis of similar morphology.⁹ Presumed gametocytes of *Hepatozoon* sp. were found in monocytes of a reedbuck (*Redunca arundinum*) and in the lymphocytes of a giraffe (*Giraffa camelopardalis*).⁹

Hepatozoon infection is not reported to have harmful effects on rodents with the exception of *H. muris*,^{14,44,51,59} which reportedly caused anemia, hepatic lipodosis and death, and *H. balfouri*, which caused hepatic necrosis.³⁰ *H. canis* is reported to cause fever, anemia, icterus, and fatal infections in some dogs,^{32,60,63} while other dogs are less severely affected.^{29,67,77} Active inflammation was associated with hepatic infections in impala,⁹ although hepatozoonosis in African carnivores is considered non-pathogenic.⁴⁰

* A contribution of a cooperative project between the Texas Parks and Wildlife Department and the Department of Veterinary Pathology, College of Veterinary Medicine and the Texas Agricultural Experiment Station, Texas A&M University; supported by Texas Pittman-Robertson Project W-93-R.

TABLE 1. *Hepatozoon* spp. of Rodents.

Host	Hepatozoon	Reference
<i>Rattus norvegicus</i>	<i>H. muris</i>	2, 20, 21, 33, 44, 48, 61
<i>Rattus rattus</i>	<i>H. muris</i>	44, 48
<i>Rattus assimilis</i>	<i>H. muris</i>	44, 48
<i>Rattus conatus</i>	<i>H. muris</i>	44, 48
<i>Mus musculus</i>	<i>H. musculi</i>	59
<i>Mus decumanus</i>	<i>H. muris</i>	4, 51
<i>Mus rattus</i>	?	1
<i>Peromyscus boylii boylii</i>	<i>H. muris</i>	78
<i>Peromyscus truei gilberti</i>	<i>H. muris</i>	78
<i>Peromyscus maniculatus gambelii</i>	<i>H. leptosoma</i>	78
<i>Sigmodon hispidus</i>	?	41
<i>Mus sylvaticus</i>	<i>H. sylvatici</i>	21
<i>Gerbillus indicus</i>	<i>H. gerbilli</i>	16
<i>Jaculus jaculus</i>	<i>H. balfouri</i>	4, 36
<i>Cricetus frumentarius</i>	<i>H. criceti</i>	52
<i>Microtus agrestis</i>	<i>H. microti</i>	21
<i>Microtus californicus marposae</i>	<i>H. citellicola</i>	52
<i>Microtus oeconomus</i>	?	55
<i>Clethrionomys glareolus</i>	<i>H. erhardovae</i>	42
<i>Citellus beecheyi</i>	<i>H. citellicola</i>	75
<i>Citellus suslicus buttarius</i>	<i>H. mereschkowski</i>	14
<i>Sciurus carolensis</i>	<i>H. griseisciuri</i>	20, 34
<i>Sciurus vulgaris</i>	<i>H. sciuri</i>	20, 21
<i>Sciurus niger</i>	?	66
<i>Funambulus pennantii</i>	<i>H. funambuli</i>	57
<i>Atlantoxerus getulus</i>	<i>H. gaetulum</i>	20
<i>Petaurista petaurista</i>	?	20
<i>Meriones libycus erythrorus</i>	?	20
<i>Spermophilopsis leptodactylus</i>	?	20
<i>Tatera afra</i>	?	42

TABLE 2. *Hepatozoon* spp. of Reptiles.

Host	Hepatozoon	Ref.
<i>Boa constrictor</i>	<i>H. fusifex</i>	6, 7
<i>Drymarchon corais</i>	<i>H. rarefaciens</i>	6
<i>Crocodilus niloticus</i>	<i>H. pettiti</i>	35
<i>Crotaphopectis degeni</i>	<i>H. minchini</i>	31
<i>Tarentola mauritanica</i>	<i>H. burneti</i>	45
<i>Anolis carolinensis</i>	?	11
<i>Varanus tristis orientalis</i>	<i>H. breinli</i>	50
<i>Varanus varius</i>	<i>H. breinli</i>	50
<i>Varanus gouldii</i>	<i>H. breinli</i>	50
<i>Gecko verticillatus</i>	<i>H. mesnili</i>	68
<i>Sauromalus obesus</i>	<i>H. sauromali</i>	47
<i>Crotalus viridis</i>	?	3, 54
<i>Pituophis melanoleucus</i>	<i>H. rarefaciens</i>	3, 54
<i>Thamnophis sirtalis</i>	?	3, 54
<i>Thamnophis couchi</i>	?	3, 54
<i>Sceloporus occidentalis</i>	?	3, 54
<i>Madagascarophis colubrina</i>	<i>H. domerguei</i>	54

*There may be other hepatozoon species infecting reptiles, but these are presently confused with other hemogregarines since it is necessary to ascertain both vertebrate and invertebrate hosts in order to place a hemogregarine in the genus *Hepatozoon*,⁵ and in many cases, this has not been done.

H. procyonis was reported to cause no evidence of harm to host in *Procyon lotor*,⁶⁸ while an active myocarditis was reported in Panamanian raccoons.⁷⁰

A wide variety of invertebrate hosts have been identified, including the following hematophagous arthropods: ticks,^{7, 18, 19, 68, 77} fleas,^{24, 42} mites,^{20, 30, 30, 44, 47, 51, 65} mosquitoes,^{6, 7, 8, 11} biting flies,^{3, 35} and lice.^{16, 59}

Schizogony occurs in the vertebrate hosts, with schizonts developing in liver,^{6, 20, 30, 40, 44, 47, 51, 55, 63} bone marrow,^{17, 20, 63, 70} cardiac muscle,^{12, 13, 39, 40, 68, 70} skeletal muscle,³⁸ lung,^{7, 40, 68} spleen,^{20, 48, 63, 78} lymph node,^{9, 43} and intestine⁵⁸ in various hosts.

Two types of schizonts have been described, one producing a few macromerozoites, and the other producing many micromerozoites. There is uncertainty as to which schizont produces gametocytes, but it is believed that one produces gametocytes and the other produces merozoites capable of perpetuating schizogony.^{49, 78} Gametocytes which are characterized by highly refractile cyst walls^{10, 17, 20, 34, 37} are found in leukocytes in carnivores and most rodents, and in erythrocytes in marsupials, reptiles and some rodents.^{48, 53} Both schizonts and gametocytes have structures which are sudanophilic and PAS-positive.²⁴

Sporogony, occurring in the arthropod host, is characterized by the development of large oocysts with sporocysts. (This is the feature which separates this genus from the genus *Haemogregarina*.⁵) Infection of the vertebrate host reportedly occurs after ingestion of the parasitized arthropod although there is an unconfirmed report of transmission of *H. canis* by tick bites.⁶³ Following schizogony, trophozoites may undergo schizogony again^{14, 49} or form gametocytes which enter blood cells and are ingested by the arthropod host, where they undergo sporogony following zygote formation.^{49, 51, 76}

Previously, detection of a *Hepatozoon* species in a new host was considered sufficient reason for designating it as a new species, since host specificity was considered to be an important taxonomic criterion.^{14, 34, 42, 44} However, recent work has

shown that certain species of *Hepatozoon* are not host specific,^{11, 28, 44, 54} casting doubt upon the validity of some species designations.

MATERIALS AND METHODS

Sixty-five adult raccoons (*Procyon lotor*) obtained over a 2-year period from 14 Texas counties (Figure 1) were necropsied and sections of selected tissues were examined microscopically. In addition to routine hematoxylin-eosin staining, selected sections were stained by periodic acid-Schiff, Grocott's methenamine-silver, Gridley, Warthin-Starry, Giemsa, and azure-eosin procedures.

Examination of blood for gametocytes was accomplished by a leukocyte concentration technic.³⁴ The degree of parasitemia was estimated by placing 1 ml of whole raccoon blood into 5 ml of 2% formalin, preparing a smear stained with aqueous methylene blue, and counting the number of gametocytes visible in 5 minutes of microscopic examination (by one individual). Thick and thin Giemsa-stained blood smears from naturally infected raccoons were examined for the presence of gametocytes.

Twelve wild-caught infected raccoons were held in captivity for an extended period of time and concentrated leukocytes from peripheral blood were periodically examined for presence of gametocytes. One captive raccoon with a high parasitemia was splenectomized and periodic checks of gametocyte numbers were made. Two other raccoons with relatively low parasitemias were given daily injections of 30 mg prednisone* for 1 week.

Wild raccoons and nests in den trees were examined for the presence of ectoparasites in an attempt to find a common species which might be the arthropod host. Ticks (*Amblyomma americanum*) taken from wild-caught infected raccoons were fed to four white rats in an attempt to infect the rats. After 90 days, the rats were killed and necropsied. Ticks (*Dermacentor variabilis* and *A. americanum*) from infected raccoons were examined

* Meticorten (Schering Corp., Bloomfield, N.J.).

for *Hepatozoon* oocysts by making squash preparations and by embedding in paraffin and sectioning by conventional tissue sectioning techniques.

Blood and leukocyte fractions from two infected raccoons were placed on STB mediumSM and held at room temperature for 28 days. Smears were prepared from the surface of these, Giemsa-stained and examined microscopically.

OBSERVATIONS

Fifty-seven of 65 adult raccoons (88%) examined had developing gametocytes in microgranulomas in the myocardium. All adult raccoons examined from low, river

bottom land had hepatozoonosis. Forty-four (68%) had schizonts in cardiac muscle. Thirty-nine (60%) had granulomas in skeletal muscle (most often diaphragm or tongue), and twenty-four (37%) had schizonts in skeletal muscle. Schizonts were found in splenic trabeculae of two animals.

On initial observation, 9 of 15 raccoons from high-prevalence areas had circulating gametocytes in enlarged monocytes, and rarely in neutrophils or free. Whenever gametocytes were present in the blood, organisms were present in microgranulomas in the myocardium, and vice versa. No gametocytes were detected in microscopic examination of routine (unconcentrated) blood films.

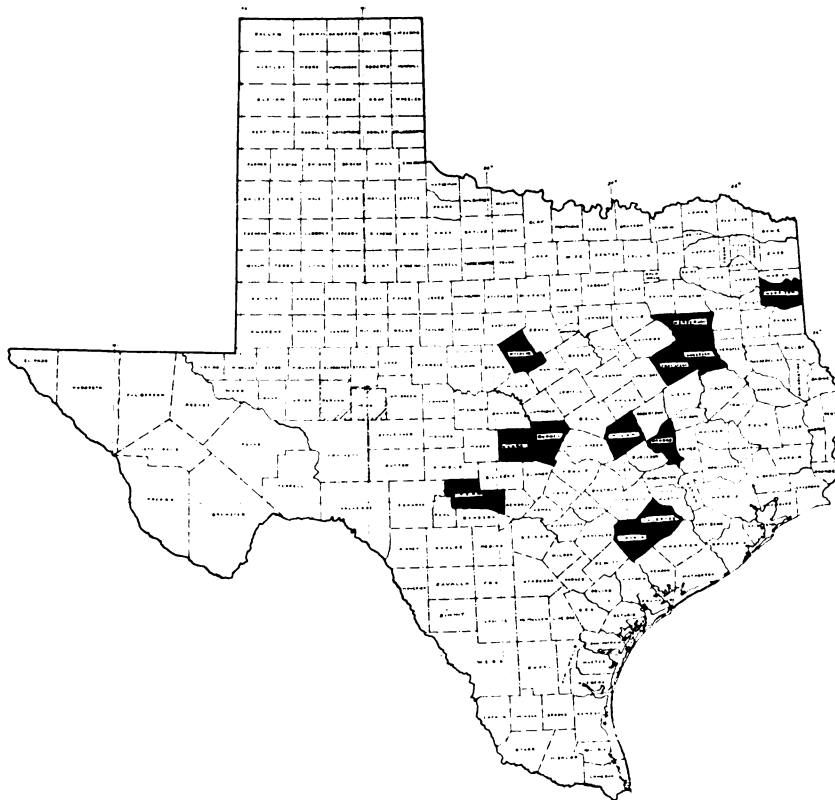


FIGURE 1. Distribution of observed hepatozoonosis by county in Texas. Cross-hatched counties had one or more confirmed case. The shaded areas were counties from which animals were examined and found not infected.

Effect on host

No clinical signs of illness attributable to *Hepatozoon* infection were observed in captive raccoons. Three raccoons which had circulating gametocytes on initial examination had a decrease in numbers of gametocytes (circulating gametocytes being rare or absent) after 3 months of captivity. The animal which underwent splenectomy had a threefold increase in circulating gametocytes 10 days after surgery. Ten months after splenectomy, no gametocytes were detectable. However, 12 months post-surgery (and following parturition) gametocyte numbers in the circulation were at about the same level as at initial examination. Necropsy revealed typical lesions of mild hepatozoonosis, with schizonts and gametocytes in the myocardium.

The two animals which received prednisone had a marked increase in gametocyte numbers. One raccoon was maintained in the laboratory for 16 months; initially and at necropsy, circulating gametocytes were present (but rare), and typical lesions, including schizonts, were present at necropsy.

The most common ectoparasite found on raccoons was the Lone Star tick, *A. americanum*. Nests in den trees were surprisingly free of parasites. The distribution of the Lone Star tick corresponds roughly with the observed distribution of infected raccoons, but feeding Lone Star ticks from infected raccoons to white rats did not produce infection in the rats. Furthermore, squash preparations and sections of ticks (both *D. variabilis* and *A. americanum*) did not reveal characteristic *Hepatozoon* oocysts.

No growth occurred on STB slants.

Lesions

No gross lesions referable to *Hepatozoon* infection were observed. Microscopically, in myocardium, skeletal muscle, and splenic red pulp, focal accumulations of macrophages were found containing phagocytized individual organisms within their cytoplasm. The organisms appeared as having a dark blue nucleus surrounded by a zone of clear light pink cytoplasm (Fig. 2). Lymphocytes, and rarely, neutrophils and eosinophils, were

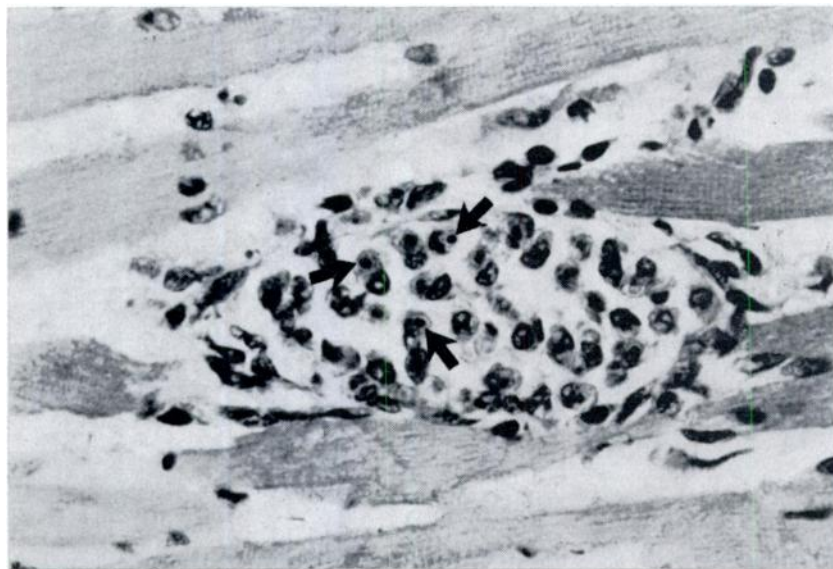


FIGURE 2. Focal granuloma in raccoon myocardium. Individual organisms are present in macrophages (arrows). H & E X 400.

found in association with these microgranulomas. Multinucleated foreign-body giant cells were present in a few instances. Inflammation varied from intense, active inflammation to well-contained, apparently quiescent microgranulomas.

In a few instances, the granulomas were associated with focal myocardial necrosis and severe local inflammation, but in these cases, concomitant disease, usually canine distemper, was present.

Intact schizonts ($31.2 \pm 7.8 \mu \times 22.7 \pm 5.5 \mu$) were not accompanied by any inflammatory response, and were found within myofibers (Fig. 3). The majority of these were X type schizonts¹⁰ with many micromerozoites ($\bar{X} = 20 \pm 4.7$). Some mature schizonts were surrounded by a mild zone of inflammatory cells and newly-ruptured schizonts were accompanied by intense focal inflammation with phagocytes of merozoites and/or gametocytes (Fig. 4).

Organisms

Special staining techniques were utilized to facilitate differentiation of structures of the organisms. The nuclei of organisms within macrophages stained

with hematoxylin-eosin and Giemsa, and was slightly PAS positive. Silver staining by the Warthin-Starry method allowed visualization of the capsule, revealing a characteristic "tadpole" morphology, with a recurved "tail" and a nucleus separated from each end by light-staining cytoplasm (Fig. 5A).

The staining characteristics of schizonts were similar, with merozoite nuclei staining with H&E, Giemsa and azure-eosin. The residual material was PAS positive, as was the cytoplasm of merozoites. However, no capsule or "tadpole" morphology was demonstrable in schizogonic stages.

Gametocytes found in circulating monocytes ($7.5 \pm 0.5 \mu \times 3.9 \pm 0.4 \mu$) or in tissue macrophages have a refractile cyst wall which gives the gametocyte the characteristic "tadpole" morphology (Fig. 5B). Neither the cyst wall nor the tadpole shape is found in organisms in mature schizonts. There has been speculation that the host cell forms this "cytocyst" for the parasite.¹³ Slow rotational movement of gametocytes in monocytes was frequently observed in concentrated leukocyte preparations.

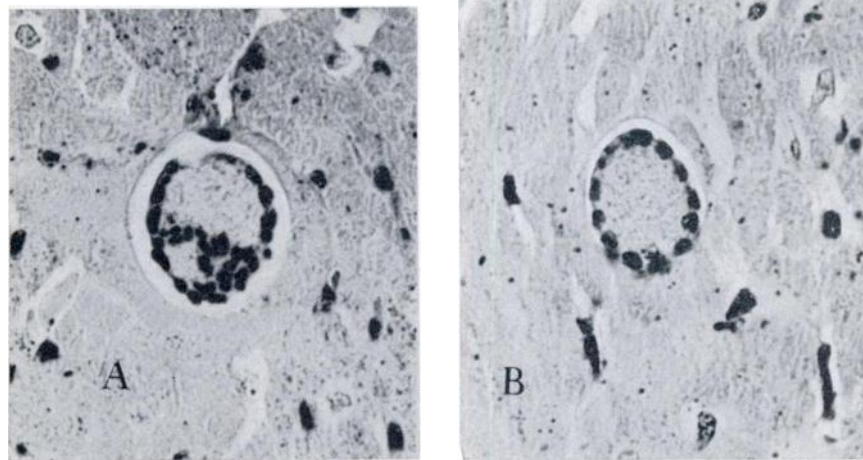


FIGURE 3. Schizonts. A. X-schizont, within myofiber with no inflammatory response. B. Y-schizont. Warthin-Starry X 400.

Infection in Other Species

Necropsy of a severely emaciated senile female white-tailed deer from Llano County revealed typical lesions of hepatozoonosis with gametocytes and schizonts

in the myocardium. Other debilitating conditions (malnutrition, theileriasis, lungworms, pneumonia, and chronic nephritis) were present. No other infected deer have been found in over 500 necropsies of white-tailed deer.

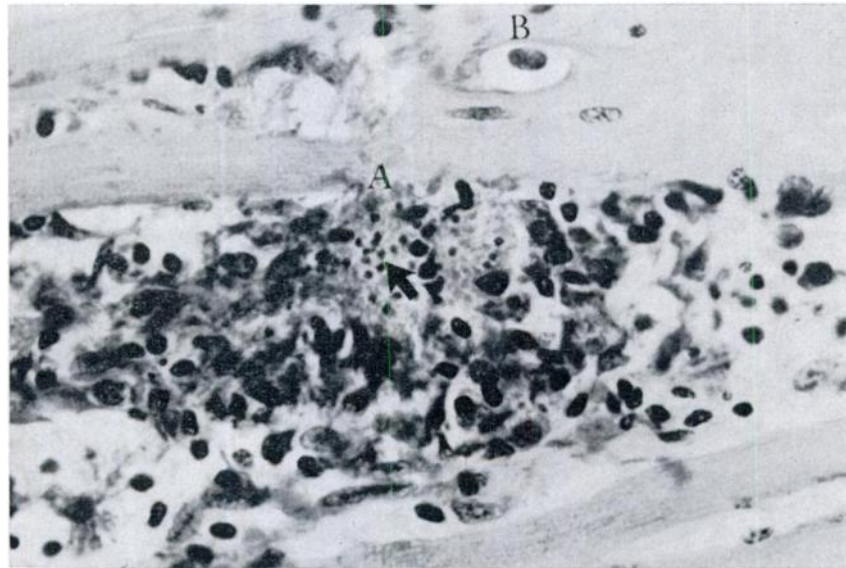


FIGURE 4. A newly-ruptured schizont with intense local inflammatory response around Merozoites (arrow). B. Immature schizont within myofiber with no inflammation.

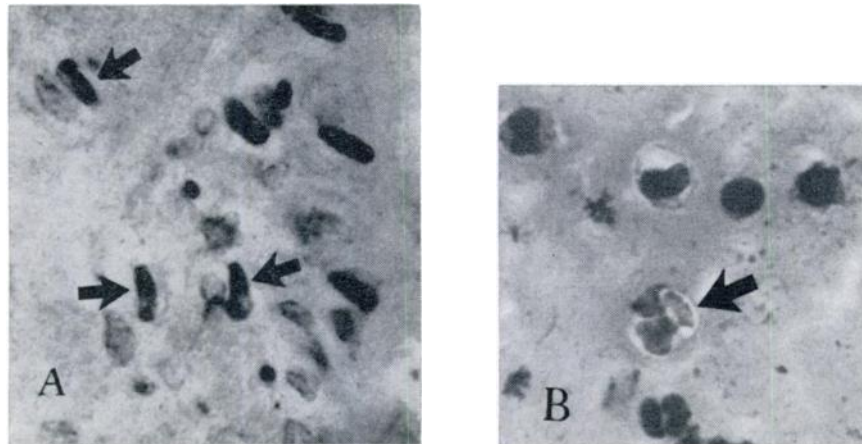


FIGURE 5. Gametocytes. A. In myocardium. Warthin Starry X 970. B. In concentrated leukocyte smear. X 970.

One opossum was examined which had organisms resembling *Hepatozoon* merozoites in microgranulomas in the myocardium. However, neither gametocytes nor schizonts were demonstrable, and it was impossible to definitely identify the organisms.

DISCUSSION

The high rate of infection in raccoons in specific areas, and the duration of infections within the population suggest that the virulence of the organisms is low, and that exposure is frequent. The low rate of parasitemia previously reported in raccoons⁶⁶ was observed. Consequently, blood films proved to be diagnostically unreliable. Both the leukocyte concentration technique and microscopic examination of myocardium are good diagnostic tools.

The mechanism by which splenectomy and corticosteroid administration temporarily increased the numbers of circulating gametocytes is uncertain. The stresses of surgery may have been more important than the removal of the spleen, and the increase in gametocytes following prednisone administration may have merely been a reflection of the leukocytosis which follows corticosteroid administration. On the other hand, splenectomy and corticosteroid administration may have caused immunosuppression, which allowed increased schizogony.

The disagreement of other authors as to the effect of hepatozoonosis on the host is understandable when some of the facts herein presented are considered: There was no evidence of inflammation or cellular damage associated with immature schizonts. There was, however, an intense inflammatory response associated with release of merozoites resulting in a marked lesion characterized by accumulations of macrophages containing phagocytized organisms. These organisms have been considered young schizonts,⁶⁸ but differential staining revealed that they are gametocytes (and/or merozoites). It was further demonstrated that all schizonts occurred in myofibers, and were not accompanied by inflammation. The infection was well-tolerated and caused no

clinical signs of illness in raccoons which were held in captivity on a high nutritional plane, without constant reinfection, and in the absence of other diseases. However, in concomitant infection with canine distemper (or other debilitating disease), the severity of lesions of both diseases were enhanced, and in many previously reported cases in other species, the possibility of concomitant disease could not be discounted.

There is no reason to assume that the *Hepatozoon* found in the single white-tailed deer was a new or different species. The rarity of this infection in white-tailed deer, with the high prevalence in raccoons, strongly suggests accidental infection in the affected individual.

The arthropod host (or hosts) of hepatozoonosis in Texas is unknown; therefore, only limited studies have been possible. The true significance of hepatozoonosis on the wild raccoon population is uncertain, but the recognition of this infection is important for at least two reasons: (1) It may be an important predisposing factor rendering raccoons more susceptible to other diseases, and (2) the myocardial lesions of hepatozoonosis are somewhat similar to the lesions of American trypanosomiasis and toxoplasmosis, both of which have great public health significance. American trypanosomiasis has been reported in raccoons,^{69,70} and there is no evidence that raccoons are immune to toxoplasmosis. Therefore, it is important to be able to differentiate hepatozoonosis from both of these diseases. This differentiation is easily accomplished by the demonstration of the characteristic gametocytes, either in concentrated leukocyte preparations or in sections of myocardium stained by the Warthin-Starry method.

Much of the pathogenesis of the lesions associated with *Hepatozoon procyonis* infection is obscure. The earliest recognizable phase of the life cycle within raccoon tissues is the schizont within a myofiber, and it is not associated with inflammation or damage to host tissues. The maturing schizont apparently becomes chemotactic, as evidenced by infiltration of mononuclear inflammatory cells into the adjacent tissues. When

merozoites are released from the schizont, intense granulomatous inflammation occurs, with subsequent phagocytosis of the merozoites. The fate of these phagocytized merozoites appears to be important to the course of the infection. Presumably, some of these macrophages containing gametocytes re-enter the circulation as monocytes with gametocytes. This appears to be a very small proportion of infected cells, since parasitemia is always relatively low, while numbers of parasitized cells in the myocardium are relatively high. By the same logic, it seems that few of these cells re-enter schizogony, since the ratio of granulomas to schizonts is approximately 20:1 in wild raccoons.

This state of equilibrium may develop as a result of either or both of two mechanisms; schizogony resulting in merozoites capable of reinfecting myofibers and initiating schizogony may be unusual; or phagocytosis of infective

merozoites may prevent them from reaching cells when they are capable of initiating schizogony. This latter mechanism has been suggested in white rats.⁶¹

It seems then, that uncomplicated *Hepatozoon* infection results in the formation of multifocal microgranulomas in myocardium and skeletal muscle, with host and parasite in a state of equilibrium, with little or no damage to either occurring. Although macrophages remain at the site of merozoite release, there is little indication of continued active inflammation. However, when a raccoon with hepatozoonosis contracts canine distemper, the dual infection may localize within the microgranulomas, producing focal myocardial necrosis. This may, in part, explain the apparent hypersusceptibility of wild raccoons to canine distemper and the high mortality associated with canine distemper in wild raccoon populations.

Acknowledgement

The authors gratefully acknowledge the assistance of the following personnel of the Texas Parks and Wildlife Department, who contributed freely of their time and energies in support of this investigation: David Rideout, John Nerren, Larry Boyd, Ernie Davis and Rod Marburger.

LITERATURE CITED

1. ADIE, J. R. 1906. Note on a leucocytozoon found in *Mus rattus* in the Punjab. *J. trop. Med.* 9: 325.
2. ANDREWS, J., and H. F. WHITE. 1936. An epidemiological study of protozoa parasitic in wild rats in Baltimore, with special reference to *Endamoeba histolytica*. *Amer. J. Hyg.* 24: 184-206.
3. AYALA, S. C. 1970. Hemogregarine from sandfly infecting both lizards and snakes. *J. Parasitol.* 56: 387-388.
4. BALFOUR, A. 1906. A hemogregarine of mammals. *J. trop. Med.* 9: 81-84.
5. BALL, G. H. 1967. Some blood sporozoans from East African reptiles. *J. Protozool.* 14: 198-210.
6. BALL, G. H., J. CHAO, and S. R. TELFORD, JR. 1967. The life history of *Hepatozoon rarefaciens* from *Drymarchon corais* and its experimental transfer to *Constrictor constrictor*. *J. Parasitol.* 53: 897-909.
7. BALL, G. H., J. CHAO, and S. R. TELFORD, JR. 1969. *Hepatozoon fusifex* sp. n., a hemogregarine from *Boa constrictor* producing marked morphological changes in infected erythrocytes. *J. Parasitol.* 55: 800-813.
8. BALL, G. H., and S. N. ODA. 1971. Sexual stages in the life history of the hemogregarine *Hepatozoon rarefaciens*. *J. Protozool.* 18: 697-700.
9. BASSON, P. A., R. M. McCULLEY, R. D. BIGALKE, and J. W. NIEKERK. 1967. Observations on a *Hepatozoon*-like parasite in the impala. *J. S. Afr. vet. med. Assoc.* 38: 12-14.
10. BENTLEY, C. A. 1905. Preliminary note upon a leucocytozoan of the dog. *Brit. med. J.* May 6, 1905, p. 988.

11. BOODEN, T., J. CHAO, and G. H. BALL. 1970. Transfer of *Hepatozoon* sp. from *Boa constrictor* to a lizard, *Anolis carolinensis* by mosquito vectors. J. Parasitol. 56: 832-833.
12. BROCKLESBY, D. W. 1971. Illustrations of a *Hepatozoon* species in the heart of a lion. J. Zool. Lond. 164: 525-528.
13. BROCKLESBY, D. W., and B. O. VIDLER. 1963. Some new host records for *Hepatozoon* species in Kenya. Vet. Rec. 75: 1265.
14. BRUMPT, E. 1946. Contribution à l'étude d'*Hepatozoon muris*. Utilisation du xenodiagnostic pour l'identification des espèces d'hémogregarines. Ann. parasit. humaine et comparée. 21: 1-24.
15. CHAO, J., and G. H. BALL. 1969. Transfer of *Hepatozoon rarefaciens* from the indigo snake to a gopher snake by a mosquito vector. J. Parasitol. 55: 681-682.
16. CHRISTOPHERS, S. R. 1905. *Hemogregarina gerbilli*. Sci. Mem. Officers Med. & San. Dept. Govt. India. No. 18.
17. CHRISTOPHERS, S. R. 1906. *Leucocytozoon canis*. Sci. Mem. Officers Med. & San. Dept. Govt. India. No. 26.
18. CHRISTOPHERS, S. R. 1907. The sexual cycle of *Leucocytozoon canis* in the tick. Sci. Mem. Officers Med. & San. Dept. Govt. India. No. 28.
19. CHRISTOPHERS, S. R. 1912. The development of *Leucocytozoon canis* in the tick with a reference to the development of *Piroplasma*. Parasitol. 5: 37-48.
20. CLARK, G. M. 1958. *Hepatozoon griseisciuri* n. sp., a new species of *Hepatozoon* from the grey squirrel (*Sciurus carolinensis*) with studies on the life cycle. J. Parasitol. 44: 52-63.
21. COLES, A. C. 1914. Blood parasites found in mammals, birds and fishes in England. Parasitol. 7: 17-61.
22. DASGUPTA, B. 1960. Lipids in different stages of the life cycles of malaria parasites and some other sporozoa. Parasitol. 50: 501-508.
23. DASGUPTA, B. 1960. Polysaccharides in the different stages of the life cycles of certain sporozoa. Parasitol. 50: 509-514.
24. DASGUPTA, B., and K. MEEDENIYA. 1958. The vector of *Hepatozoon sciuri*. Parasitol. 48: 419-422.
25. DIAMOND, L. S., and R. RUBIN. 1958. Experimental infection of certain farm animals with a North American strain of *Trypanosoma cruzi* from the raccoon. Exper. Parasitol. 7: 383-390.
26. DISSANAIKE, A. S. 1961. *Hepatozoon canis* infection in dogs in Ceylon. Ceylon Vet. J. 9: 144-145.
27. EL HINDAWAY, M. R. 1951. Studies on the blood of dogs. VI. Haematological findings in some diseases caused by specific blood parasites: (a) *Babesia canis*; (b) *Hepatozoon canis*. Brit. vet. J. 107: 303-309.
28. ERHARDOVA, B. 1955. *Hepatozoon microti* in our small mammals. Folia Biol., Prague 1: 282-287.
29. EYLES, D. E. 1952. Incidence of *Trypanosoma lewisi* and *Hepatozoon muris* in the Norway rat. J. Parasitol. 38: 222-225.
30. FURMAN, D. P. 1966. *Hepatozoon balfouri*: Sporogonic cycle, pathogenesis, and transmission by mites to Jerboa hosts. J. Parasitol. 52: 373-382.
31. GARNHAM, P. C. C. 1950. Blood parasites of East African vertebrates, with a brief description of exo-erythrocytic schizogony in *Plasmodium pitmani*. Parasitol. 40: 328-337.
32. GERRARD, P. N. 1906. On a protozoan parasite found in the polymorphonuclear leukocytes of a dog. J. Hyg. 6: 229-230.
33. HERMAN, C. M. 1939. A parasitological survey of wild rats in the New York Zoological Park. Zoologica 24: 305-308.
34. HERMAN, C. M., and D. L. PRICE. 1955. The occurrence of *Hepatozoon* in the gray squirrel (*Sciurus carolinensis*). J. Protozool. 2: 48-51.

35. HOARE, C. A. 1932. On protozoal blood parasites collected in Uganda. *Parasitol.* 24: 210-224.
36. HOOGSTRAAL, H. 1957. The life cycle and incidence of *Hepatozoon balfouri* in Egyptian jerboas (*Jaculus* spp.) and mites (*Haemolaelaps aegyptius*). *J. Protozool.* 8: 231-248.
37. JAMES, S. P. 1905. On a parasite found in the white corpuscles of the blood of dogs. *Sci. Mem. Officers Med. & San. Dept. Govt. India.* No. 14.
38. KEEP, M. E. 1970. Hepatozoonosis of some wild animals in Zululand. *Lammergeyer* No. 12: 70-71.
39. KEYMER, I. F. 1964. *Hepatozoon* species in wild African mammals. *Vet. Rec.* 76: 641.
40. KEYMER, I. F. 1971. Blood protozoa of wild carnivores in Central Africa. *J. Zool., Lond.* 164: 513-524.
41. KITCHINGS, J. T. III, P. B. DUNAWAY, and J. D. STORY. 1970. Blood changes in irradiated cotton rats and rice rats. *Radiat. Res.* 42: 331-352.
42. KRAMPITZ, H. E. 1964. The distribution and behavior of *Hepatozoon* in Middle- and South-European small mammals. *Acta Trop. Basel.* 21: 114-154.
43. KRAMPITZ, H. E. 1968. Distribution of *Hepatozoon* in East African wild mammals. *Z. Parasitenk.* 31: 203-210.
44. LAIRD, M. 1959. Malayan protozoa 2. *Hepatozoon* Miller (Sporozoa: Coccidia), with an unusual host record for *H. canis* (James). *J. Protozool.* 6: 316-319.
45. LAVIER, G., and J. CALLOT. 1938. *Hepatozoon burneti* n. sp. hémogrégarine parasite de *Tarentola mauritanica*. *Arch. Inst. Pasteur Tunis.* 27: 444-449.
46. LEGER, A. 1912. Leucocytozaire de l'hyène tachetée de l'Haut-Sénégal et Niger. *C. r. Séanc. Soc. Biol.* 72: 1060-1062.
47. LEWIS, T. E., and E. D. WAGNER. 1964. *Hepatozoon sauromali* sp. n., a hemogregarine from the Chuckwalla (*Sauromalus* spp.) with notes on the life history. *J. Parasitol.* 50: 11-14.
48. MACKERRAS, M. J. 1959. The hematozoa of Australian mammals. *Aust. J. Zool.* 7: 105-135.
49. MACKERRAS, M. J. 1961. The haematozoa of Australian reptiles. *Aust. J. Zool.* 9: 61-122.
50. MACKERRAS, M. J. 1962. The life history of a hepatozoon of varanid lizards in Australia. *Aust. J. Zool.* 10: 35-44.
51. MILLER, W. W. 1908. *Hepatozoon perniciosum* (n.g., n. sp.)—A hemogregarine pathogenic for white rats; with a description of the sexual cycle in the intermediate host, a mite (*Lelads echnidninus* Berlese). *U.S.P.H.S., Hyg. Lab. Bull.* No. 46.
52. NOLLER, W. 1912. Die Blutprotozoen des Hamsters (*Cricetus frumentarius*) und ihre Ubertragung. *Arch. Protist.* 25: 377-385.
53. NUTTALL, G. H. F. 1910. On haematozoa occurring in wild animals in Africa. *Parasitol.* 3: 108-116.
54. ODA, S. N., J. CHAO, and G. H. BALL. 1971. Additional instances of transfer of reptile hemogregarines to foreign hosts. *J. Parasitol.* 57: 1377-1378.
55. OHBAYASHI, M. 1971. *Hepatozoon* sp. in Northern Voles, *Microtus oeconomus*, on St. Lawrence Island, Alaska. *J. Wildl. Dis.* 7: 49-51.
56. PATTON, W. S. 1906. Cited in Reference 17, p. 2.
57. PATTON, W. S. 1906. On a parasite found in the white corpuscles of the blood of palm squirrels. *Sci. Mem. Officers Med. & San. Dept. Govt. India.* No. 24.
58. PATTON, W. S. 1910. Preliminary report on a new piroplasm (*Piroplasma gibsoni* sp. nov.) found in the blood of the hounds of the Madras hunt and subsequently discovered in the blood of the jackal (*Canis aureus*). *Bull. Soc. Path. Exot.* 3: 274-281.

59. PORTER, A. 1908. *Leucocytozoon musculi*, sp. n., a parasitic protozoon from the blood of white mice. Proc. Zool. Soc. Lond. 3: 703-716.
60. PORTER, A. 1919. Leucocytogregarines, and their occurrence in South Africa. S. African J. Sci. 15: 335-336.
61. PRICE, E. W., and B. G. CHITWOOD. 1931. Incidence of internal parasites in wild rats in Washington, D.C. J. Parasitol. 18: 55.
62. RAHIMUDDIN, M. 1942. *Hepatozoon canis* and its treatment. Indian Vet. J. 19: 153-154.
63. RAU, M. A. N. 1925. *Haemogregarina canis*. Vet. J. 81: 293-307.
64. RAU, M. A. N. 1926. Experimental infection of the jackal (*Canis aureus*) with *Piroplasma canis*. Indian J. med. Res. 14: 243-244.
65. REDINGTON, B. C., and L. A. JACHOWSKI, JR. Syngamy and sporogony of *Hepatozoon griseisciuri* in its natural vector, *Haemogamasus reidi*. J. Parasitol. 57: 953-960.
66. RICHARDS, C. S. 1961. *Hepatozoon procyonis*, n. sp., from the raccoon. J. Protozool. 8: 360-362.
67. RIOUX, J. A., Y-J GOLVAN, and R. HOUIN. 1964. Mixed *Hepatozoon canis* and *Leishmania canis* infection in a dog in the Sete area, France. Annl. Parasit. Hum. Comp. 39: 131-135.
68. ROBIN, L. A. 1936. Cycle évolutif d'un *Hepatozoon* de *Gecko verticillatus*. Ann. Inst. Pasteur. 56: 376-394.
69. SANGIORGI, G. 1914. *Leucocytogregarina cuniculi*, n. sp. Pathologica 6: 49-50.
70. SCHNEIDER, C. R. 1968. *Hepatozoon procyonis* in a Panamanian raccoon, *Procyon cancrivorus panamensis*. Rev. Bioil. Trop. 15: 123-135.
71. UILENBERG, G. 1970. Quelques protozoaires parasites de Mammifères sauvages à Madagascar. Annl. Parasit. Hum. Comp. 45: 183-194.
72. d'UTRA E SILVA, O., and J. B. ARANTES. 1917. Sôbre uma hemogregarina da gamba, *Haemogregarina didelphidis* n. sp. Mem. Inst. Oswaldo Cruz, 8: 61-63.
73. WALTON, B. C., P. M. BAUMAN, S. DIAMOND, and C. M. HERMAN. 1958. The isolation and identification of *Trypanosoma cruzi* from raccoons in Maryland. Amer. J. trop. Med. & Hyg. 7: 603-610.
74. WELLMAN, C., and W. B. WHERRY. 1910. Some new internal parasites of the California ground squirrel (*Otospermophilus beecheyi*). Parasitol. 3: 417-422.
75. WENYON, C. M. 1910. Some remarks on the genus *Leucocytozoon*. Parasitol. 3: 63-72.
76. WENYON, C. M. 1911. Oriental sore in Bagdad, together with observations on a gregarine in *Stegomyia fasciata*, the hemogregarine of dogs, and the flagellates of house flies. Parasitol. 4: 273-344.
77. WENYON, C. M. 1931. Experimental infection of dogs with *Hepatozoon canis*. Trans. Soc. trop. Med. Hyg. Lond. 25: 6.
78. WOOD, S. F. 1962. Blood parasites of mammals of the Californian Sierra Nevada foothills, with special reference to *Trypanosoma cruzi* and *Hepatozoon leptosoma* sp. n. Bull. So. Calif. Acad. Sci. 61: 161-176.

Received for publication January 16, 1973