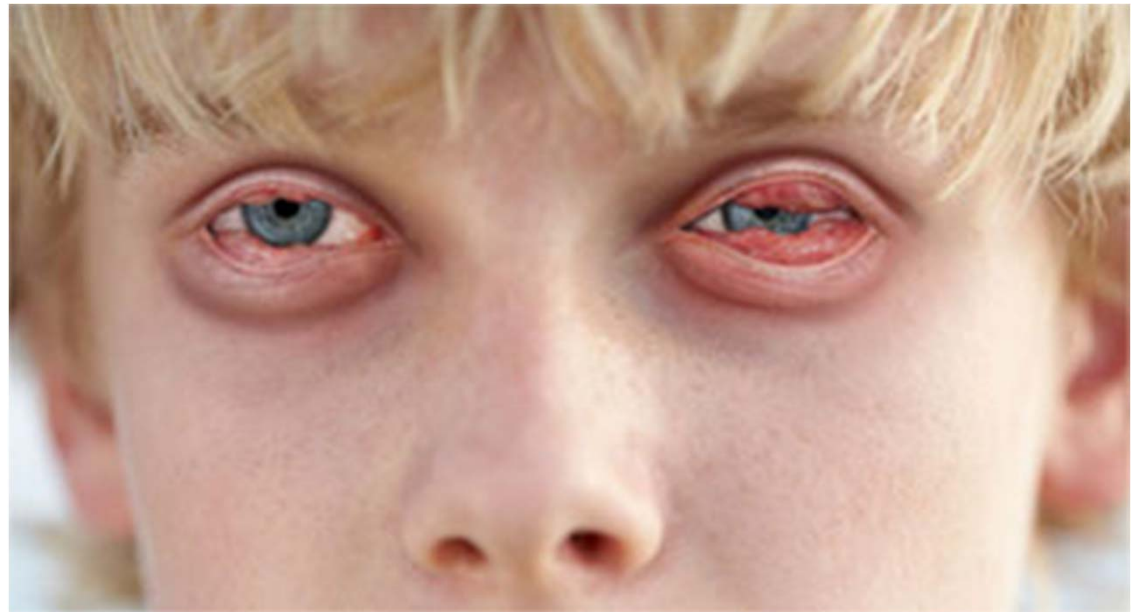

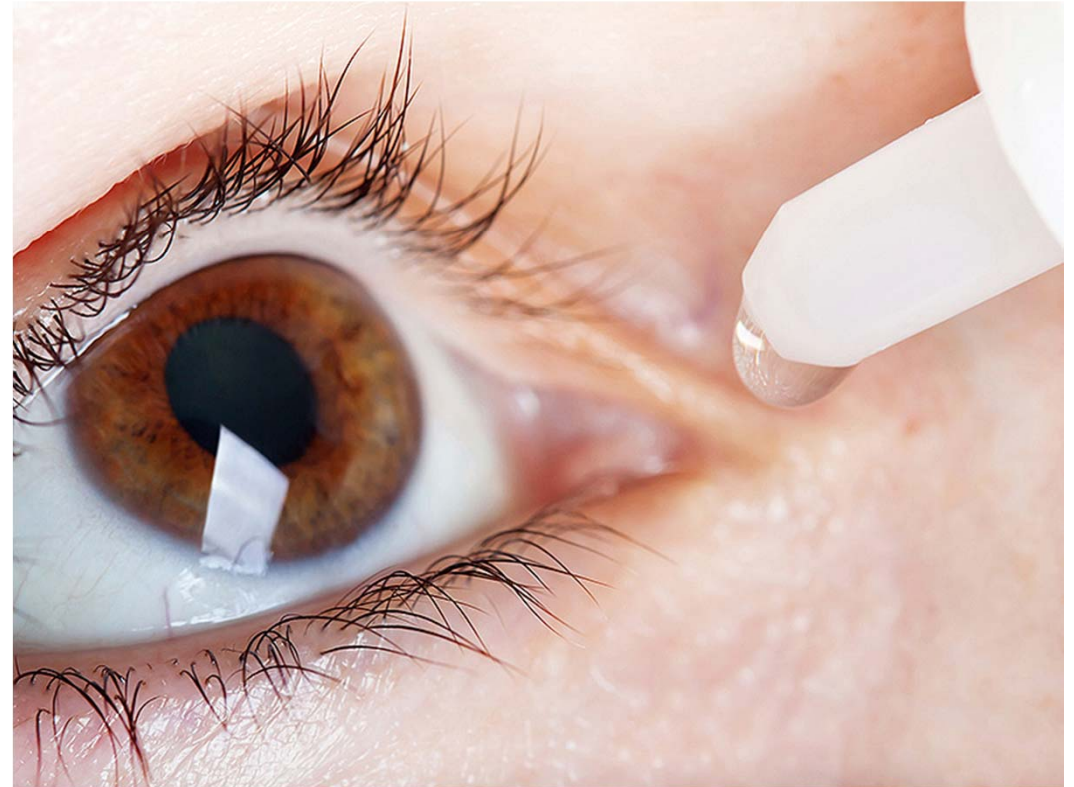
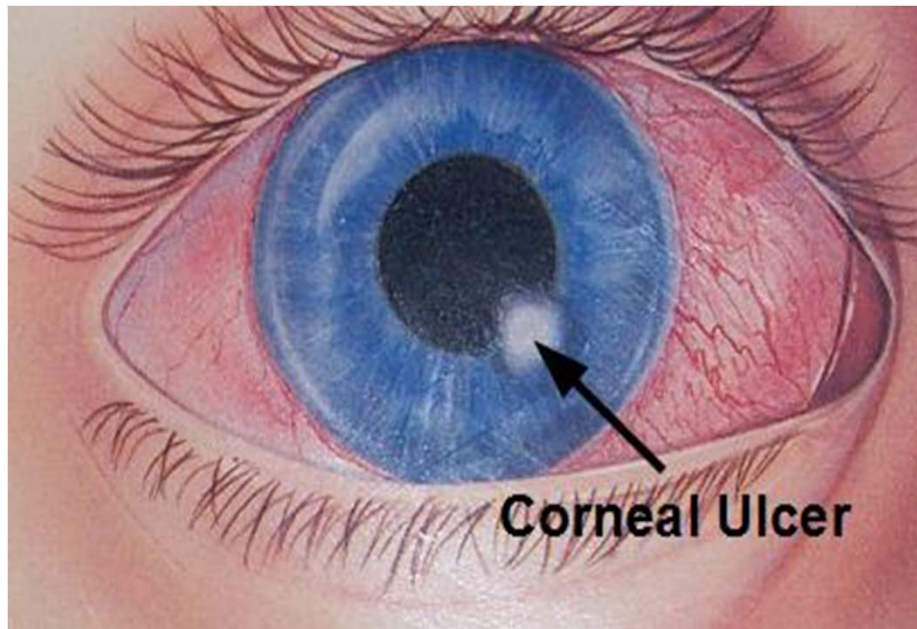
# Plasminogen Deficiency Ligneous Conjunctivitis & Plasma Eye Drops

NICE Brisbane 2017  
Rebecca Davidson



## Serum eye drops

- Severe dry eye syndrome
- Non-healing corneal ulcers
- Recovery post LASIK surgery
- Usually autologous



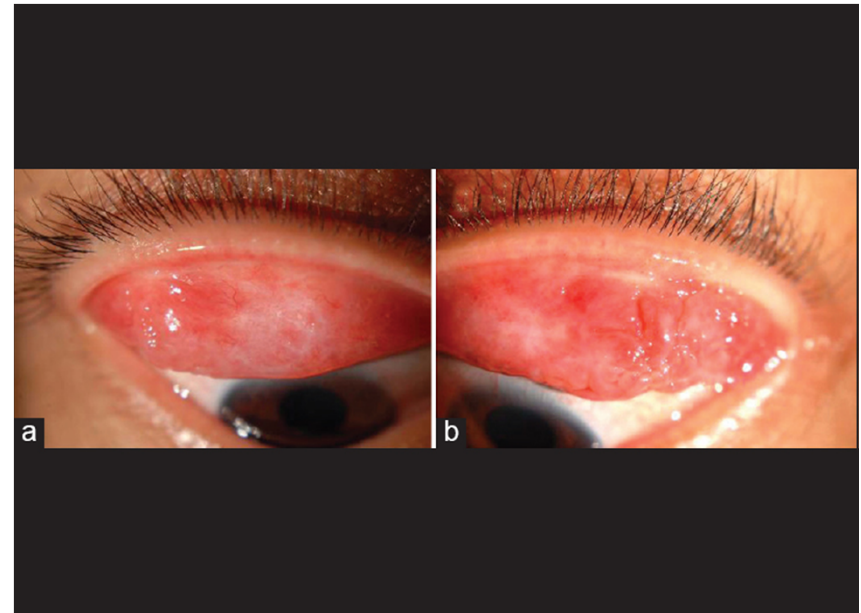
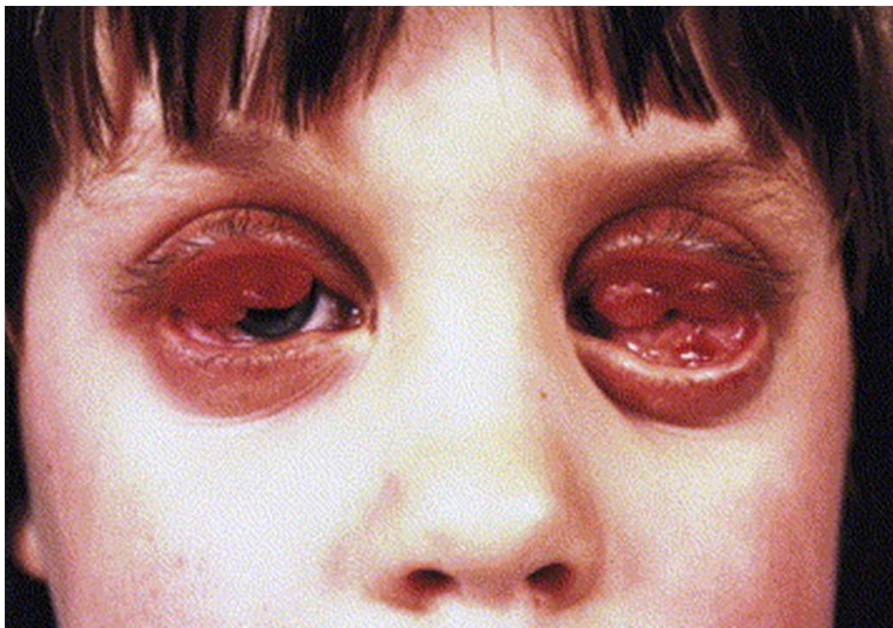
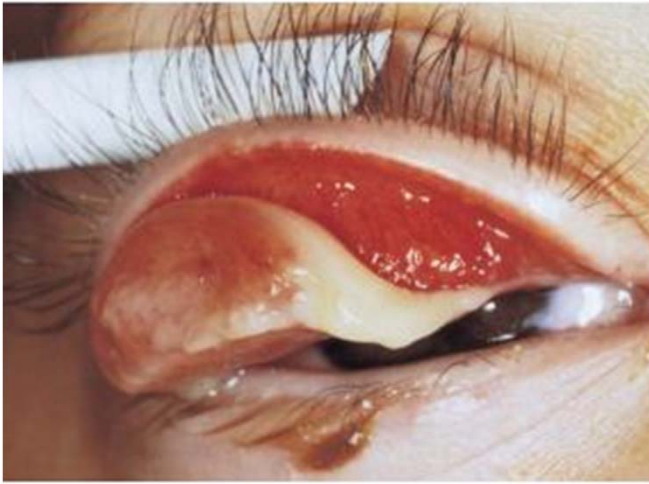# Frozen serum eye drops

Serum from a whole blood donation is fully segmented and then frozen as per a unit of FFP





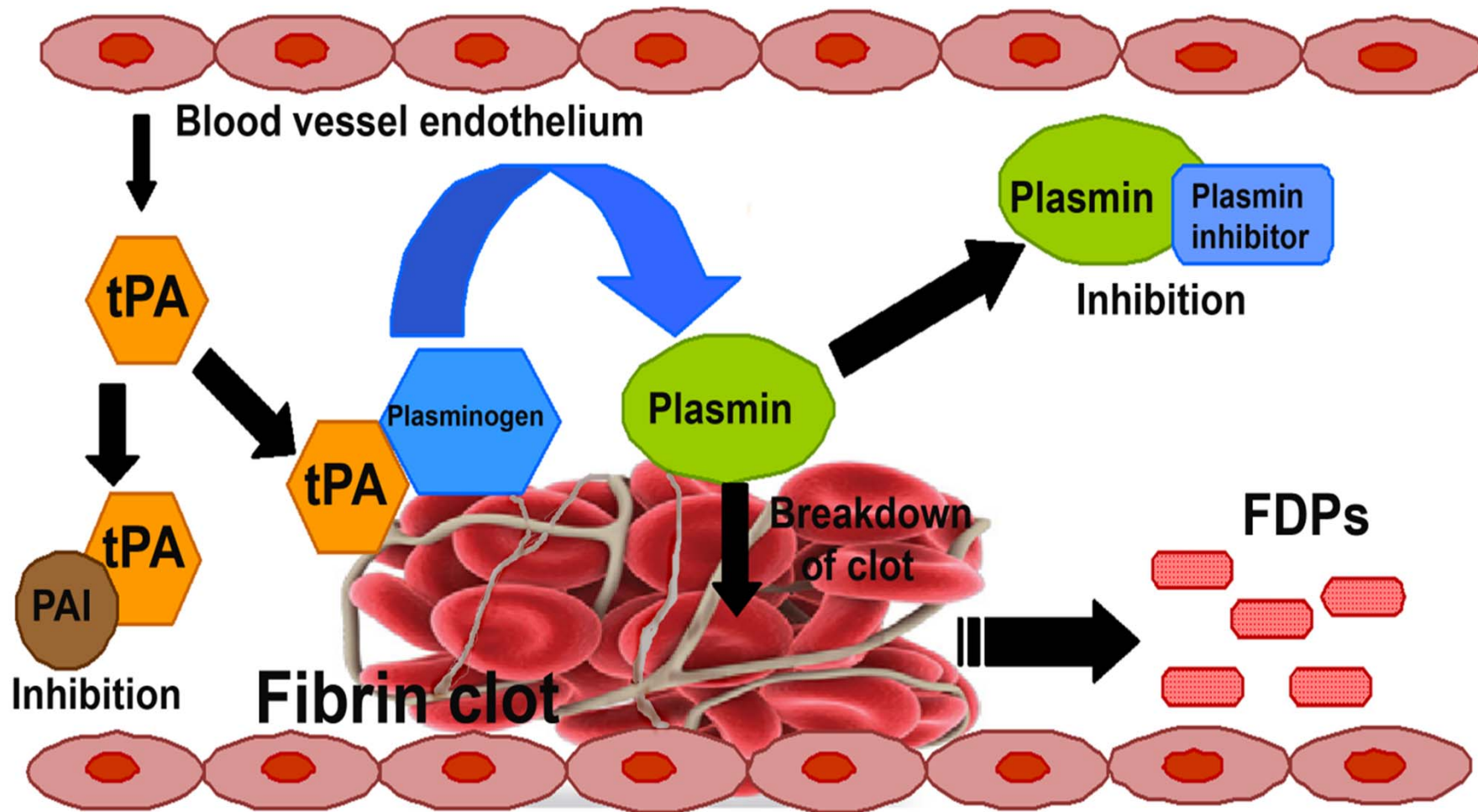
# Ligneous Conjunctivitis



# Plasminogen in tears

- Plasminogen activators in tear fluid convert plasminogen into plasmin, which rapidly clears the cornea of fibrin deposits
- In the absence of plasmin activity, fibrin-rich viscous or membranous material accumulates = ligneous conjunctivitis
- The wood like appearance is caused by the drying out of the fibrin and the products of the provoked inflammatory response

# Fibrinolysis



# Plasminogen Deficiency

- Congenital, rare
- 1-2 cases per million people
- Autosomal recessive inheritance of homozygous or compound heterozygous mutations in the plasminogen gene, *PLG*, located on chromosome 6q26
- first presentation of complications usually in the paediatric population

# Common clinical manifestations

- Ligneous conjunctivitis – 80%
- Ligneous gingivitis – 80%
- Do not experience intravascular thromboembolic episodes despite severe deficiency of a key component of the fibrinolytic system



# Less common clinical manifestations

- Tracheobronchial fibrin deposits impair the ciliary system of the tracheobronchial tree and support bacterial growth – 16%
- Fibrin deposition in the ears can occur – 14%
- Ligneous vaginitis – 8%
- Occlusive hydrocephalus caused by fibrin deposition in the cerebral ventricular system

# Treatment of laneous conjunctivitis

Disappointing therapies:

- Hyaluronidase eye drops
- Corticosteroids
- Cyclosporine
- Immunosuppressants
- Antiviral agents
- Surgical resection – often causes accelerated recurrence of the pseudomembranes

# Treatment of ligneous conjunctivitis

Variably effective therapies:

Topical solutions of-

Corticosteroids, heparin, fresh frozen plasma, plasminogen and immunosuppression.

# Our patient – 4 year old Miss CC

- March 2016 – chronic membranous conjunctiva
- October 2016 - ?allergic/toxic, amyloid, ligneous, pyogenic granuloma
- 7 months after various treatments for chronic membranous conjunctival inflammation her grossly thickened conjunctival tissue was surgically resected



# Histopathology of debrided membranes

- Pathologist's comment:

*“Features of ligneous conjunctivitis with a pyogenic granuloma. The histological and clinical features are most suggestive of ligneous conjunctivitis associated with plasminogen deficiency and plasminogen gene mutations.”*

- *“This condition usually manifests in children. There have been reports of successful treatment with fresh frozen plasma.”*

- This report lead the treating ophthalmologist to investigate the child's plasminogen activity
- ? therapeutic eye drops for topical replacement of plasminogen

# Plasminogen activity

	<b>Plasminogen level</b>	<b>Reference Range</b>
Miss CC	0.14, 0.18	0.75-1.50 U/mL
Mother	0.72	0.75-1.50 U/mL
Father	0.52	0.75-1.50 U/mL

# Plasma eye drops

- Plasma from her parents was considered unsuitable as both were found to have slightly low plasminogen levels
- A screened donor was considered the better option
- With input from Monash Health Paediatric Haematologists, the ARCBS TMS and the ARCBS product preparation team an appropriate donation of apheresis, group matched, CMV negative plasma was collected.



# Frozen plasma eye drops



# References

[Marks DC](#)<sup>1</sup>, [Fisher J](#)<sup>2</sup>, [Mondy P](#)<sup>2</sup>, [Segatchian J](#)<sup>3</sup>, [Dennington PM](#)<sup>2</sup>. Serum eye drop preparation in Australia: Current manufacturing practice. *Transfus Apher Sci* 2015;53(1):92-4

Magdum R, Gahlot A, Mushtaq I, Iqbal B, Arun S. Ligneous conjunctivitis: A rare case report. *Trop J Med Res* 2015;18:119-120

Heidemann DG, Williams GA, Hartzler M, Ohanian A, Citron ME. Treatment of ligneous conjunctivitis with topical plasmin and topical plasminogen. *Cornea*. 2003;22:760–762.

Watts P, Suresh P, Mezer E, et al. Effective treatment of ligneous conjunctivitis with topical plasminogen. *Am J Ophthalmol*. 2002;133:451–455.

Pergantou H, Likaki D, Fotopoulou M, Katsarou O, Xafaki P, Platokouki H. Management of ligneous conjunctivitis in a child with plasminogen deficiency. *Eur J Pediatr*. 2011;170:1333-1336.

Tabarra KF. Prevention of ligneous conjunctivitis by topical and subconjunctival fresh frozen plasma. *Am J Ophthalmol*. 2004;138(2):299-300.

Shuster V, Hügle B, Tefs K. Plasminogen deficiency. *J Thromb Haemost*. 2007;5(12):2315-2322.