

# Esophageal Motility Disorders



Steven P. Bowers, MD

## KEYWORDS

- High-resolution manometry • Esophageal motility • Achalasia
- Spastic motility disorder • Peristalsis • Fundoplication

## KEY POINTS

- The esophageal motility study is an important component of the evaluation of patients presenting with thoracic dysphagia.
- The Chicago classification includes an algorithm for diagnosis of primary esophageal motility disorders, designed primarily to be more clinically relevant and identify motility disorders that are pathologic or not found in normal patients.
- High-resolution esophageal motility studies and the Chicago classification have clarified the definitions of spastic esophageal motility disorders; however, it is not clear if revised definitions of hypomotility disorders will or have affected surgical decision making.
- The esophageal motility disorder is still thought to be an essential part of the evaluation of any patient considered for antireflux surgery.
- Achalasia has a revised classification scheme that has a correlation with surgical and medical therapies.

## INTRODUCTION: NATURE OF THE PROBLEM

The diagnosis of esophageal motility disorders has historically been closely linked to the development of technology, with diagnostic criteria changing at each technological breakthrough. For most of the modern era of laparoscopic foregut surgery, esophageal motility disorders were defined in terms of water-perfused catheters using a hydraulic capillary infusion system developed in 1977.<sup>1</sup> Careful manometric evaluation of the esophagus and the lower esophageal sphincter (LES) became an essential part of the preoperative evaluation before antireflux surgery and surgeons used the study of esophageal motility to guide which antireflux operation best suited their respective patients. Because more than 50% of patients presenting with dysphagia without signs of mechanical esophageal obstruction have been found to have abnormal esophageal motility, the esophageal manometry study (EMS) became an essential diagnostic test in the study of patients with esophageal origin chest pain and/or dysphagia.<sup>2</sup>

---

Mayo Clinic Florida, Department of Surgery, 4500 San Pablo Road, Jacksonville, FL 32224, USA  
E-mail address: [bowers.steven@mayo.edu](mailto:bowers.steven@mayo.edu)

Surg Clin N Am 95 (2015) 467–482  
<http://dx.doi.org/10.1016/j.suc.2015.02.003>

[surgical.theclinics.com](http://surgical.theclinics.com)

0039-6109/15/\$ – see front matter © 2015 Elsevier Inc. All rights reserved.

### Abbreviations

|      |  |
|------|--|
| CDP  | Contractile deceleration point           |
| CFV  | Contractile front velocity               |
| DCI  | Distal contractile integral              |
| DES  | Distal esophageal spasm                  |
| DL   | Distal latency                           |
| EMS  | Esophageal manometry study               |
| EPT  | Esophageal pressure topography           |
| GEJ  | Gastroesophageal junction                |
| GERD | Gastroesophageal reflux disease          |
| IEMD | Ineffective esophageal motility disorder |
| IRP  | Integrated relaxation pressure           |
| LES  | Lower esophageal sphincter               |
| POEM | Peroral endoscopic myotomy               |

With the exception of esophageal achalasia and scleroderma esophagus, disorders that are associated with distinct pathologic findings designating them as disease processes, all esophageal motility disorders are defined by the use of the EMS. Thus, the development of the high-resolution manometry study obligated the redefinition of all esophageal motility disorders. This article discusses esophageal motility disorders in the light of 2 important breakthroughs: high-resolution manometry studies and the diagnostic algorithm of the Chicago classification.<sup>3</sup>

Esophageal motility disorders have been classified as primary or secondary, or as hypocontractility, disordered contractility, or hypercontractility disorders. For the surgeon it is far more rational to group these in terms of the impact they have on surgical decision making, either as part of the evaluation for antireflux surgery or for planning operations for the relief of dysphagia. The author has grouped the esophageal motility disorders according to diagnostic criteria included in the Chicago classification.

### HIGH-RESOLUTION MANOMETRY

The high-resolution manometry catheter is a solid state pressure detection system, with sensors closely spaced (1 cm or less) along the length of the catheter and radially, allowing simultaneous pressure readings of the lower and upper esophageal sphincters and the esophageal body. The high-resolution manometry systems allow pressures interpolated between measurement points to create a continuous 3-dimensional (time, distance down the axis of the esophagus, and pressure) graphic display called esophageal pressure topography (EPT).<sup>4</sup> Whereas water-perfused catheter systems reported esophageal pressures in terms of mm Hg of amplitude, analysis of high-resolution manometry is done by integrating the volume under the isobaric map for a given esophageal segment. Isobaric curves are created and, for ease of use, the color green is designated as 30 mm Hg pressure, based on the simultaneous video-radiographic and manometric data showing that ineffective bolus movement is associated with distal esophageal contraction amplitudes of less than 30 mm Hg.<sup>5</sup>

Aside from the diagnostic calculations, which must be done using a computer interface, the process of performing the study has been simplified by eliminating the need for multiple catheter manipulations (pull-throughs). Once the catheter has been placed through the gastroesophageal junction (GEJ) and into the intraabdominal stomach, the patient is placed supine and given 10 5 mL aliquots of fluid to swallow. The analysis of the study consists of evaluation (similar to water-perfused EMS) of the GEJ with measurement of LES pressure and length, assessment of

the adequacy of LES deglutitive relaxation, and assessment of esophageal body function and adequacy of propagation of peristalsis.<sup>6</sup>

To better understand the assessment of esophageal body function, it is important to understand the metrics that have been developed to quantify esophageal function in the setting of EPT.<sup>7</sup> Propagation of esophageal peristalsis is faster in the more proximal esophagus and midesophagus, and slows in the distal esophagus (the ampulla of the esophagus). The contractile deceleration point (CDP) is calculated as the point where the slope of the isobaric contour line of the upper esophagus meets that of the lower esophagus. The speed of the propagation of the peristaltic wave is called the contractile front velocity (CFV), which is the slope of the 30 mm Hg isobaric curve proximal to the CDP. Distal latency (DL) is calculated as the time between upper esophageal sphincter relaxation and the CDP, and is a measure of deglutitive inhibition. DL has been found to be a more consistent measure of the simultaneous or premature nature of a peristaltic wave.

The amplitude of esophageal peristalsis is measured as the distal contractile integral (DCI), which is the integrated volume under the EPT map of that respective esophageal segment (measured as mm Hg  $\times$  centimeter  $\times$  second). For assessment of LES relaxation, esophageal manometry cannot distinguish pressures caused by the diaphragmatic crura (or other external compressive force such as fundoplication wrap) as being separate from the LES, thus the metric used is called the integrated relaxation pressure (IRP). The IRP is the average from 10 swallows of the lowest mean pressure at the GEJ during a 4-second period after deglutition.

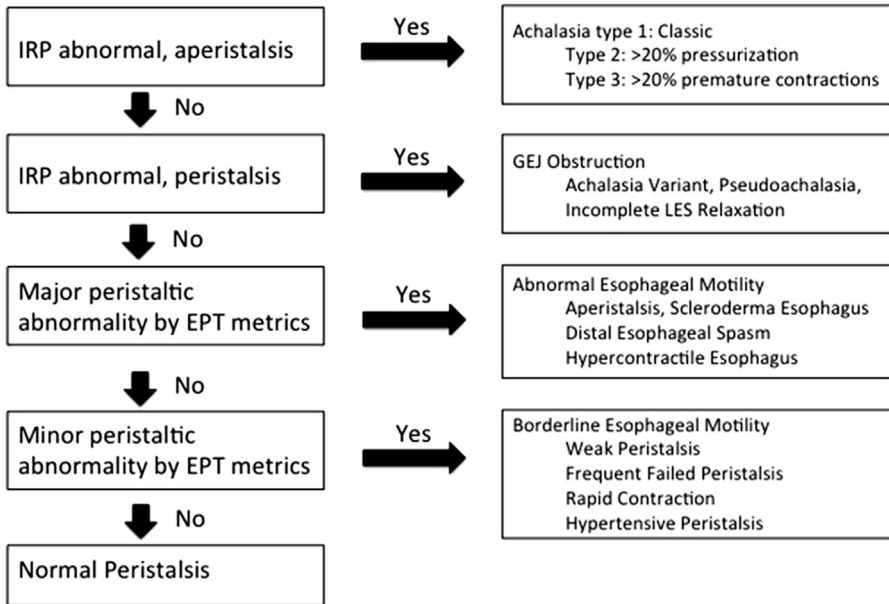
Assessment of adequacy of esophageal body peristalsis includes visualization of continuity of the 20 mm Hg isobaric curve and assessment of each swallow as intact peristalsis, weak peristalsis (with discontinuity of the 20 mm Hg IBC in either small [2–5 cm] or large [ $>5$  cm] breaks), or failed peristalsis. Intact peristaltic waves are further characterized by the above metrics and each peristaltic wave is assessed for esophageal pressurization to greater than 30 mm Hg. Esophageal pressurization is further assessed as being panesophageal or compartmentalized. Esophageal impedance can also be measured during the high-resolution manometry study and each peristaltic wave is assessed by whether there is associated complete bolus clearance.

### **Chicago Classification Scheme**

---

Based on the categorical assessment of 10 swallows, the manometry studies are applied to the Chicago classification scheme. Most patients can be classified as having normal esophageal motility, having an abnormal GEJ relaxation state, a major motility disorder with normal GEJ relaxation, or borderline peristaltic function (**Fig. 1**).

The Chicago classification prioritizes the identification of abnormal EPT metrics into a hierarchy. The highest priority is given to identification of abnormal IRP-designating disorders of GEJ relaxation. This would serve to reduce the frequency of misdiagnosed esophageal achalasia variants. If IRP and, therefore, GEJ relaxation are normal, then priority is given to identification of the 3 major esophageal body motility disorders not seen in normal individuals. These include absent peristalsis, distal esophageal spasm (DES), and hypercontractile or jackhammer esophagus. Finally, the Chicago classification designates as borderline esophageal motility those abnormalities that can be seen in fewer than 5% of normal asymptomatic individuals.<sup>7</sup> Borderline esophageal motility includes weak peristalsis and frequent failed peristalsis (previously known as ineffective esophageal motility disorder [IEMD]), hypertensive peristalsis or nutcracker esophagus, and rapid contraction (previously known as nonspecific spastic motility disorder).



**Fig. 1.** Chicago classification diagnostic algorithm. The Chicago classification includes a diagnostic algorithm based on hierarchical analysis of EPT metrics. (Adapted from Brede-noord AJ, Fox M, Kahrilas PJ, et al. Chicago classification criteria of esophageal motility disorders defined in high resolution esophageal pressure topography. *Neurogastroenterol Motil* 2012;24(Suppl 1):57; with permission.)

### ***Implications for the Surgeon***

In patients considered for antireflux surgery, an assessment of esophageal motility is considered the standard of practice. This is primarily done to identify patients for whom antireflux surgery is contraindicated. The motility study is also very useful in identifying the cause of nonreflux esophageal symptoms and setting patient expectations for recovery after antireflux surgery. Using high-resolution motility study as a preoperative test before proposed antireflux surgery, up to 7% of patients were identified as having an esophageal motility disorder that contraindicated Nissen fundoplication.<sup>8</sup> There is a significant correlation between preoperative dysphagia and the presence of a hypocontractile esophageal motility disorder.<sup>9</sup> Also, it has been demonstrated that patients with nonspecific spastic esophageal motility disorders are more likely to have postoperative typical reflux symptoms after antireflux surgery.<sup>10</sup> When also considering the disastrous consequences of performing fundoplication in a patient with achalasia, there can be little doubt of the benefit of routine esophageal motility assessment before antireflux surgery.

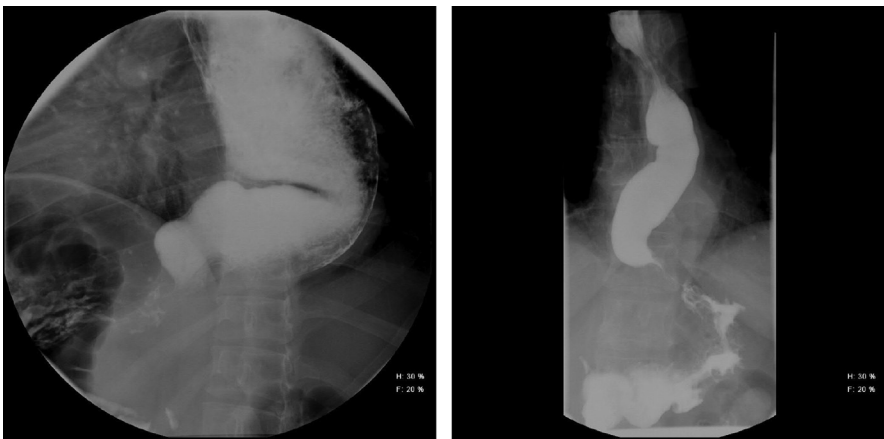Compared with the water-perfused esophageal motility systems of the past, high-resolution esophageal manometry studies have some distinct advantages but also some disadvantages. The EPT graphics do not reproduce by copy or transmit by facsimile well. A computer interface is required to interpret the EPT data. Thus, the surgeon depends more on interpretation by the provider reading the study. The summary EPT, an average of the 10 swallows, is generally not helpful for surgical planning. Thus, from the high-resolution motility study report, the surgeon still is required to make decisions mainly based on the reported LES pressure, LES

relaxation pressure (IRP), the classification of peristaltic waves, and the final diagnosis according to the Chicago classification. Disorder-specific surgical implications are separately discussed.

## ESOPHAGEAL ACHALASIA

Esophageal achalasia is a disease characterized by esophageal outflow obstruction caused by inadequate relaxation of the LES and a pressurized and dilated hypomotile esophagus with nonprogressive swallow responses. Pathophysiologically, there is degeneration of ganglion cells in the myenteric plexus of the esophageal wall, related to absence in the LES of the neurotransmitters nitric oxide and vasoactive intestinal polypeptide.<sup>11</sup> Experimental models have long suggested that the peristaltic abnormalities seen in esophageal achalasia are secondary to the outflow obstruction.<sup>12</sup> However, by the water-perfused manometry study and standard motility classification, aperistalsis was used as the most important motility abnormality identified in achalasia. Use of high-resolution manometry studies and the Chicago classification have redirected the diagnosis to reflect the pathophysiologic findings of achalasia.<sup>7</sup>

Esophageal achalasia had previously been classified into subtypes, classic and vigorous achalasia, based on the finding in the esophageal body of vigorous repetitive and high-amplitude swallow responses. This classification had no clinical significance, however. The Chicago classification has refined the subclassification of achalasia into subtypes based on the finding of esophageal pressurization and premature contractions.<sup>13–15</sup> Whereas type 1 represents classic achalasia, type 2 identifies patients with panesophageal pressurization (to >30 mm Hg) in 20% or greater swallows. Type 3, or spastic achalasia identifies patients who have no intact peristalsis but have the finding, in 20% or greater swallows, of premature or simultaneous contractions (with DL <4.5 seconds). Further, type 3 achalasia represents patients who may have been previously diagnosed as having diffuse esophageal spasm with incomplete LES relaxation. These patients are more likely to present with chest pain as a prominent symptom. Of these subtypes, type 2 seems to be slightly more common than type 1, and type 3 is infrequent in most reported series (Fig. 2).



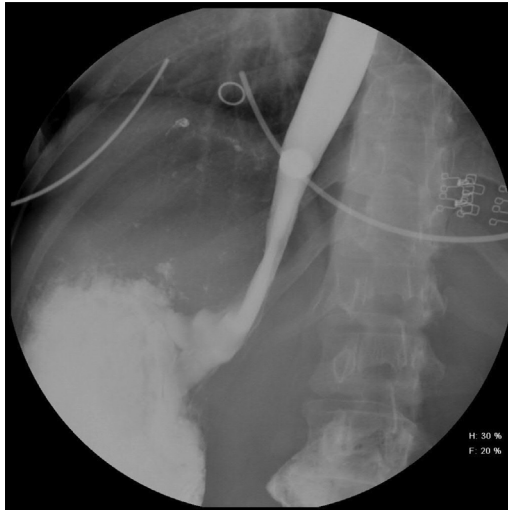
**Fig. 2.** Esophageal achalasia subtype I and II. Contrast esophagrams of patients with classic achalasia, subtype I (*left*) and achalasia with pressurization, subtype II (*right*). The greater esophageal body tone seen in subtype II may be preventative of esophageal dilation, and thus responsible for the observed better outcomes of therapy.

Additionally, the Chicago classification has allowed for the identification of patients with an achalasia variant, so designated because of the finding of nonrelaxing LES and some preservation of peristalsis.<sup>16</sup> The classification EGJ (esophagogastric junction) relaxation abnormality includes patients who are found on later study to have achalasia with aperistalsis, as well as those with pseudoachalasia and postoperative (post-fundoplication) states, and those with incomplete LES relaxation as the sole identified abnormality (**Fig. 3**).

### ***Implications for the Surgeon***

The development of high-resolution manometry and the Chicago classification has both broadened and simplified the definitions of achalasia and its subtypes. Additionally, the Chicago classification subtypes have some added prognostic value that may aid in the formulation of surgical planning. Type 1 achalasia seems to have better outcomes with myotomy as the initial treatment when compared with endoscopic therapies (botulinum toxin injection or pneumatic balloon dilation).<sup>13</sup> Type 2 achalasia seems to have the best outcomes regardless of the initial treatment strategy and type 3 has the worst outcomes irrespective of treatment strategy (botulinum toxin, pneumatic dilation, and myotomy). There are no available data on the association of type 1 achalasia with greater esophageal dilation than that seen in type 2 but it is intuitive that a greater degree of esophageal dilation would be associated with a decreased symptomatic response to treatment.

High-quality studies demonstrating greater effectiveness of surgical myotomy compared with botulinum toxin injection and pneumatic dilation were reported without the benefit of the Chicago classification. Based on the improved response of type 2 patients to any initial treatment, there is greater support among gastroenterologists for initial endoscopic therapy in type 2 achalasia patients, with myotomy relegated to treatment failures in type 2 patients. However, because there is a continuum between type 1 cases with pressurization to just below 30 mm Hg and type 2 cases,



**Fig. 3.** EGJ outflow obstruction, achalasia variant. Contrast esophagram of a patient presenting with dysphagia-note presence of 12.5 mm barium pill above LES. HRM revealed preserved peristalsis but elevated IRP, consistent with achalasia variant.

and marginal differences between type 3 cases and some achalasia variants, it is unrealistic to make a firm algorithm regarding treatment based on achalasia types.

Although laparoscopic Heller myotomy with partial fundoplication is accessible to most patients with achalasia in North America, the diffusion of centers offering peroral endoscopic myotomy (POEM) as a definitive treatment of achalasia has made this an option for most regions. Because POEM is reflexogenic in one-third of patients without hiatal hernia, the presence of a hiatal hernia should be seen as a relative contraindication for the POEM procedure.<sup>17</sup> Otherwise, analysis of the outcomes for POEM based on reports from high-volume centers and the growing international experience essentially equates POEM outcomes with surgical myotomy without fundoplication by other approach.<sup>17–20</sup>

In the setting of prefundoplication evaluation, the finding on high-resolution manometry of GEJ obstruction and intact peristalsis in a patient without dysphagia may be a false-positive, and the surgeon may consider a contrast esophagram with barium tablet to confirm that there is a functional delay in esophageal emptying before changing the surgical plan.

### **HYPERCONTRACTILITY STATES**

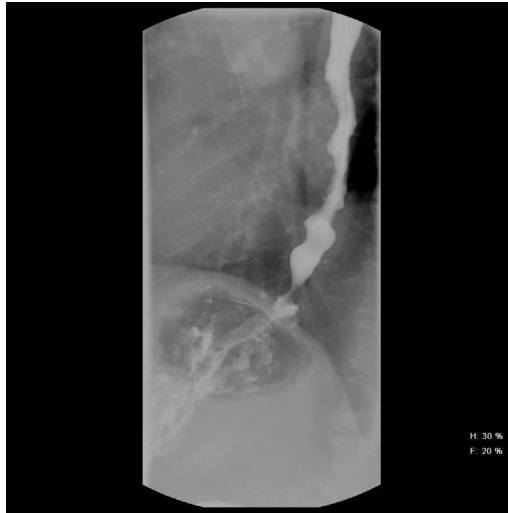
Gastroesophageal reflux disease (GERD) is the most common cause of noncardiac chest pain and hypercontractile motility disorders are rare; however, the symptoms of dysphagia and chest pain are clinical scenarios that are suspicious for hypercontractile esophageal motility disorders. Patients with chest pain usually have undergone a cardiac evaluation that is not consistent with coronary origin chest pain. All patients with dysphagia should have esophageal obstruction ruled out by upper endoscopy or contrast esophagram.

Although contrast esophagram may confirm a hypercontractile esophageal motility disorder, it is not sensitive enough to be used as a screening test. An esophageal motility study is required to establish a diagnosis and initiate treatment. The natural history of these disorders has seen some overlap and, classically, there were a substantial number of hypercontractile motility disorders identified in asymptomatic patients.<sup>21</sup> By classic water-perfused manometry, the clinical relevance of hypercontractile esophageal motility disorders could only be established when therapy based on motility study finding and directed at patient symptoms was successful in symptom resolution. Based on the Chicago classification and analysis of high-resolution manometry EPT metrics, there are 2 identified major hypercontractile abnormalities that are always associated with patient symptoms and never identified in normal individuals.<sup>22</sup> Using the new classification scheme, the number of patients diagnosed with hypercontracting motility disorders is markedly reduced and, because the most extreme cases have been selected, response to medications and natural history of the disorders as currently diagnosed are unknown.

#### ***Distal Esophageal Spasm***

---

The name diffuse esophageal spasm has been something of a misnomer because it is the distal esophagus that is spastic.<sup>23</sup> DES is now the preferred terminology but both are used interchangeably. Patients with DES commonly present with dysphagia. Because of the observed response in DES patients to nitroglycerin, it is thought that DES may be pathophysiologically linked to a defect in esophageal nitric oxide production.<sup>24,25</sup> Contrast esophagram may demonstrate the classic corkscrew esophagus or rosary bead esophagus; however, a normal contrast esophagram does not exclude DES (**Fig. 4**). The hallmark of DES by classic esophageal motility study has been the



**Fig. 4.** DES. Contrast esophagram of patient presenting with chest pain and dysphagia. HRM revealed normal IRP, but 30% of peristaltic waves had DL less than 4.5 seconds and 50% of waves with CFV greater than 9 cm/s, consistent with DES. Corkscrew pattern of esophageal contraction can also be seen with any hypercontracting esophageal motility disorder.

finding of frequent simultaneous peristalsis. Classically, in one-third of patients there has been some abnormality of the LES (either hypertensive LES or incompletely relaxing LES).<sup>26,27</sup> However, with high-resolution manometry and interpreted by the Chicago classification, some of these latter patients are now considered to have type 3 achalasia or an achalasia variant.

High-resolution manometry diagnostic criteria rely on measurement of DL to determine whether a peristaltic contraction is considered premature or simultaneous (DL <4.5 seconds). The Chicago classification designates DES as having 20% or greater of swallows with DL less than 4.5 seconds. This is in contrast to the characteristic manometry finding of high-velocity peristalsis (CFV > 8–9 cm/s) to identify simultaneous contractions, or the findings of repetitive contractions or contractions of long duration (>6 seconds) in greater than 20% of peristaltic waves that previously constituted DES. The Chicago classification requires that there also be normal LES relaxation to distinguish DES from achalasia variants. Greater than two-thirds of patients previously diagnosed as having DES will now receive a different diagnosis using the Chicago classification.<sup>28</sup> Rapid contraction, defined as 20% or greater swallows with CFV greater than 9 cm/s is considered borderline motility by the Chicago classification.<sup>7</sup>

Although patients with classically defined DES followed longitudinally show that the majority improve somewhat with time without directed medical therapy,<sup>29</sup> there are several classes of medication that have proven to be somewhat helpful in managing the disorder. The antidepressants trazodone and imipramine were found to decrease chest pain with DES, likely by modifying esophageal sensitivity.<sup>30,31</sup> The phosphodiesterase inhibitor sildenafil has been associated with symptoms relief.<sup>32</sup> Botulinum toxin delivered by endoscopic injection was found to decrease dysphagia.<sup>33</sup>

#### **Implications for the surgeon**

The diagnostic criteria for DES are now more restrictive and DES now refers to a more distinct clinical phenotype. With the more restrictive definition, it should be



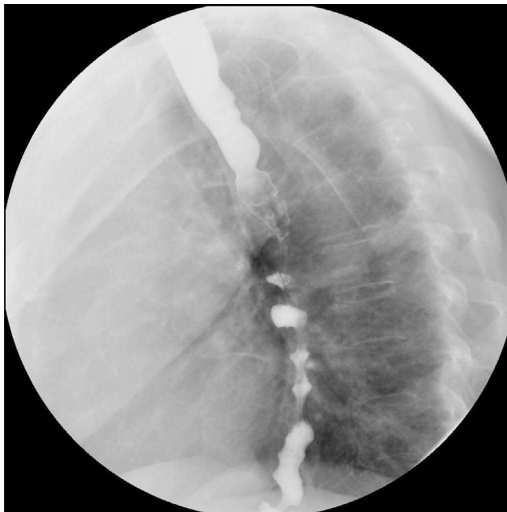
infrequent that the surgeon encounters a patient with documented GERD and DES. In a patient with documented GERD who has diagnostic criteria for DES on preoperative high-resolution manometry, the surgeon should reassess which symptoms may be due to DES and, therefore, unlikely to respond to antireflux therapy. For patients with GERD who have prominent dysphagia symptoms and DES, Nissen fundoplication is not recommended. In patients with noncardiac chest pain found to have DES and GERD that are failing medical therapy, the surgeon should consider starting an antidepressant before or after antireflux surgery.

More commonly, the surgeon encounters patients who previously would have been diagnosed with DES but are now classified as having a nonspecific spastic motility disorder or rapid contraction (CFV > 9 cm/s) because of rapid or simultaneous contractions not fulfilling criteria for DES (90% of swallows with DL > 4.5 seconds). Expectations should be revisited as to which symptoms are likely to improve after operation.

In patients presenting with DES and refractory symptoms of dysphagia and chest pain, it is reasonable to perform endoscopic botulinum toxin injection. Although there are reported small series of POEM surgery for DES,<sup>19,34</sup> this should be viewed as experimental and caution should be exercised because of the propensity for DES symptoms to lessen over time without intervention.

### ***Jackhammer Esophagus***

The hypercontractile esophagus is characterized by high-amplitude esophageal body peristaltic contractions associated with chest pain and/or dysphagia (Fig. 5). Using the water-perfused manometry system, the criteria for defining the disorder as nutcracker esophagus had undergone some evolution to a higher mean amplitude (from 180 mm Hg to 220 mm Hg) to decrease the number of patients diagnosed with the disorder who had reflux symptoms rather than chest pain.<sup>35</sup> Using the high-resolution manometry system, the Chicago classification used an entirely new metric, the DCI, and identified the threshold for which a single swallow with elevated DCI was always associated with dysphagia (DCI >8000 mm Hg/cm/s) and termed this disorder jackhammer



**Fig. 5.** Hypercontractile or jackhammer esophagus. Contrast esophagram showing rosary bead esophagus in a patient presenting with chest pain and dysphagia. HRM revealed 20% of swallows with DCI greater than 9000, consistent with hypercontractile esophagus.

esophagus. This is reflective of the finding of repetitive contractions in most spastic hypercontractile waves. Mean DCI greater than 5000 mm Hg/cm/s based on 10 swallows is termed hypertensive peristalsis and still nicknamed nutcracker esophagus; however, with the assumption that it is possible in asymptomatic patients.

The pathophysiology of the hypercontractile esophageal disorders is thought to be due to asynchrony in the circular and longitudinal smooth muscle of the esophagus during contraction. Because this is reversible with atropine, it thought to be due in part to a hypercholinergic state.<sup>36</sup> When using a mean amplitude of greater than 180 mm Hg as a threshold for defining nutcracker esophagus, there was an association with GERD.<sup>35</sup>

Classically, the nutcracker esophagus has been associated with hypertensive LES. Almost 50% of patients with hypertensive LES were found to have nutcracker esophagus and hypertensive LES was formerly classified as a hypercontracting motility disorder.<sup>37</sup>

Treatment of hypercontractile esophagus is similar to treatment of DES. Diltiazem was found to relieve chest pain in patients with nutcracker esophagus.<sup>38</sup> Sildenafil, trazodone, and imipramine have also been found to be helpful.<sup>30-32</sup> Based on the pathophysiology of the disorder, anticholinergics would be expected to have treatment benefit. Endoscopic botulinum toxin injection has a response rate greater than 70% and half of treated patients have, at least temporarily, complete relief of chest pain.<sup>39</sup> Failing medical therapy, patients with nutcracker esophagus with severe dysphagia may undergo Heller myotomy with good relief of dysphagia; however, relief of chest pain is less certain with laparoscopic Heller myotomy.<sup>40</sup> Small series of POEM for hypercontractile esophagus show promise, with high rates of relief of chest pain.<sup>19</sup>

### ***Implications for the surgeon***

The classically described nutcracker esophagus has been associated with GERD. The finding of hypertensive peristalsis in a patient with GERD should not alter the treatment plan for antireflux surgery. Because jackhammer esophagus is a finding always associated with chest pain or dysphagia, the treatment plan should reflect the expectation that this disorder will not resolve with treatment of GERD and should be specifically addressed. However, definitive treatment studies have not been performed using these specific criteria for hypercontractile esophagus.

## **HYPOCONTRACTILE STATES**

### ***Aperistalsis or Scleroderma Esophagus***

Esophageal manifestations of systemic sclerosis or scleroderma and collagen vascular disease should be considered separately from ineffective esophageal motility associated with GERD. Scleroderma esophagus is defined as aperistalsis with low or absent LES pressure (resting pressure <10 mm Hg). Esophageal findings are present in more than 70% of patients with typical skin manifestations of scleroderma.<sup>41,42</sup> Scleroderma esophagus is caused by atrophy and sclerosis of the smooth muscle of the esophagus; the striated proximal esophageal muscle is spared. Esophageal manometry findings similar to scleroderma esophagus may be found in other connective tissue diseases, such as polymyositis, dermatomyositis, and mixed connective tissue disorder.

### ***Implications for the surgeon***

The primary consideration in managing scleroderma esophagus is preventing development of peptic esophageal stricture and recurrent aspiration pneumonia and malnutrition. Although a loose Nissen fundoplication may be used,<sup>43</sup> more recent reports

recommend partial fundoplication,<sup>44</sup> and some consideration should be given to placement of feeding access via gastrostomy tube during antireflux surgery.<sup>45</sup>

### ***Weak Peristalsis and Frequent Failed Peristalsis***

Gastroesophageal reflux disease is associated with hypocontractile states and GERD is likely causative of impaired peristalsis and decreased peristaltic amplitude. Hypocontractile LES and inappropriate LES relaxation are similarly causative of GERD.

The most common hypocontractile conditions of the esophagus were grouped as IEMDs, the definition of which has changed several times during the era of laparoscopic antireflux surgery. Initially, the percentage of propagation of peristalsis and the mean distal esophageal pressures were reported. Abnormal esophageal peristalsis corresponded to propagation of peristalsis in fewer than 80% of swallows, or mean distal amplitude of less than 30 mm Hg.<sup>46</sup> Eventually these 2 metrics were combined with the concept of effective esophageal peristalsis, which is a continuous peristaltic wave with distal amplitude of greater than 30 mm Hg, and IEMD was defined as ineffective esophageal peristaltic waves in 30% or greater of swallows.<sup>47</sup>

Approximately 30% of patients with IEMD report dysphagia, whereas most patients with IEMD are asymptomatic of the motility disorder. When patients with IEMD were studied with simultaneous esophageal impedance, more than 30% had normal esophageal bolus clearance.<sup>47</sup> Manometric diagnosis of ineffective esophageal motility may not always correlate with the effectiveness of esophageal function and may be present in normal individuals.

By high-resolution manometry testing and interpretation using the EPT metrics, there are 2 categories of ineffective peristalsis: weak peristalsis and frequent failed peristalsis.<sup>7</sup> A weak peristaltic wave has been defined as a greater than 2 cm break in the 20 mm Hg isobaric contour line. This is based on the finding of incomplete bolus transport on simultaneous intraluminal impedance.<sup>48</sup> A diagnosis of weak peristalsis is given with 30% or greater swallows having small breaks (2–5 cm) or 20% or greater large breaks (>5 cm) in the 20 mm Hg isobaric contour line. Frequent failed peristalsis is defined as failed peristalsis in 30% to 90% of swallows. Interestingly, patients with weak peristalsis were more likely to be symptomatic than patients with a similar degree of failed peristaltic waves.<sup>48</sup> Whereas IEMD was graded as mild or severe based on the frequency of ineffective peristalsis (30% or greater vs 70% or greater, respectively), no such gradations of weak or failed peristalsis are considered in the Chicago classification.

### ***Implications for the surgeon***

Tailoring of the fundoplication in patients with GERD and ineffective esophageal motility has been long debated. This concept involved using Nissen fundoplication for patients with normal esophageal motility (defined as normal propagation of peristalsis in >80% of swallows and normal distal mean amplitude > 30 mm Hg) but using partial fundoplication for patients with demonstrated abnormal esophageal motility.<sup>49</sup> Because there is an association between severe GERD and esophageal hypomotility, tailoring the fundoplication in this way selected patients with the most severe GERD for partial fundoplication. Many large North American centers reported higher rates of failure of partial fundoplication when assessed at longer follow-up intervals.<sup>50–53</sup>

A large randomized trial comparing Nissen and Toupet fundoplication was conducted in Hamburg, Germany.<sup>9,54</sup> The investigators stratified subjects based on the presence of abnormal esophageal motility (defined somewhat liberally as mean distal amplitude <40 mm Hg). The investigators concluded that esophageal motility testing was not helpful in predicting dysphagia-related outcomes and that outcomes with Toupet fundoplication were superior. This study also established that preoperative

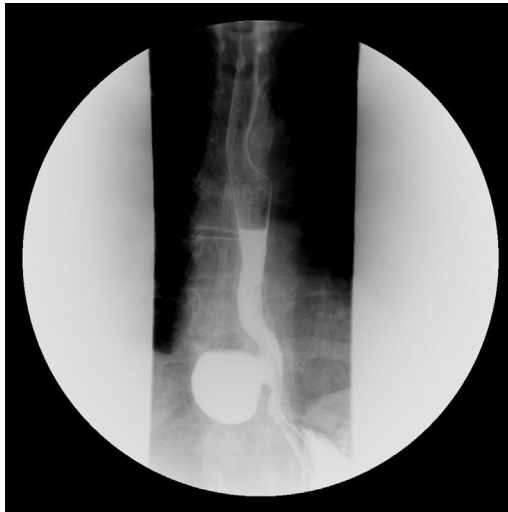dysphagia was more likely to improve with partial fundoplication and that the frequency of abnormal esophageal peristalsis is not likely to improve with Nissen but may improve with partial fundoplication.

From a randomized trial of achalasia patients treated with Heller myotomy, Nissen fundoplication was associated with greater severe, long-term dysphagia compared with partial fundoplication.<sup>55</sup> Therefore, for patients with aperistalsis due to scleroderma esophagus and severe GERD, partial fundoplication is also indicated. Patients with aperistalsis thought due to severe GERD, without any findings consistent with connective tissue disorder, may be treated intensively with proton pump inhibitor therapy for 3 to 4 months and a motility study repeated. If there is significant improvement in esophageal peristalsis, then Nissen fundoplication can be considered. Patients who have dysphagia and esophageal hypocontractile disorders, which are out of proportion to the severity of GERD, may have a primary esophageal motility disorder, and the motility disorder may be partially causative of GERD due to abnormal esophageal clearance. In such patients, a partial fundoplication may also be indicated.

The concept of tailoring a Nissen fundoplication, constructing the wrap to be more loose or floppy based on preoperative esophageal motility, has not been systematically studied. The novel technology of impedance planimetry has been used to measure the distensibility of the GEJ via the use of a functional luminal imaging probe.<sup>56,57</sup> It remains to be seen if this technology can add to surgeon experience in creating a fundoplication that is appropriate for patients with varying levels of esophageal peristaltic dysfunction.

#### HYPERTENSIVE LOWER ESOPHAGEAL SPHINCTER

The upper limit of normal LES pressure by high-resolution manometry is 35 mm Hg (45 mm Hg by water perfused systems). Although no longer considered an esophageal motility disorder by the Chicago classification, it is important for the surgeon to recognize the importance of this finding. Hypertensive LES had been grouped with DES



**Fig. 6.** Pulsion-type esophageal diverticulum. Contrast esophagram showing pulsion-type esophageal diverticulum. Water perfused esophageal motility study revealed resting LES pressure of 48 with normal LES relaxation, and 50% of swallows with CFV greater than 8 cm/s, consistent with hypertensive LES.

and nutcracker esophagus as a hypercontractile primary esophageal motility disorder, and has been found associated with epiphrenic diverticulum in up to 20% of reported cases (Fig. 6).<sup>58</sup> Hypertensive LES has been associated with dysphagia, particularly after Nissen fundoplication. In fact, even when measured to be within normal range, there is an association of increasing LES baseline pressure to postoperative dysphagia after Nissen fundoplication.<sup>59</sup>

## SUMMARY

Reports of outcomes are needed in patients treated with motility disorders diagnosed using high-resolution manometry and the Chicago classification. The new classification of achalasia has been associated with some prognostic value, and will increase the number of patients diagnosed with early achalasia rather than other spastic esophageal motor disorders, potentially increasing the frequency of surgical esophagogastric myotomy. Clarification of the diagnoses of DES and hypercontractility has decreased the overlap of these disorders with GERD, and it is hoped will eventually clarify the role of a surgical approach to these disorders. Surgeons reporting their results using the diagnostic criteria according to EPT metrics and the Chicago classification will enhance this effort. As for hypomotility of the esophagus, the Chicago classification has, if anything, muddied the water, creating an additional category, weak peristalsis, and eliminating gradations of peristaltic failure. Although weak peristalsis may have had a stronger association with dysphagia than frequent failed peristalsis, the diagnostic criteria seem overly sensitive and the disorder is likely to be underappreciated by surgeons.

## REFERENCES

1. Arndorfer RC, Steff JJ, Dodds WJ, et al. Improved infusion system for intraluminal esophageal manometry. *Gastroenterology* 1977;73:23–7.
2. Katz PO, Dalton CB, Richter JE, et al. Esophageal testing of patients with noncardiac chest pain or dysphagia. Results of three years' experience with 1161 patients. *Ann Intern Med* 1987;106:593.
3. Kahrilas PJ, Ghosh SK, Pandolfino JE. Esophageal motility disorders in terms of pressure topography: the Chicago Classification. *J Clin Gastroenterol* 2008; 42:627.
4. Clouse RE, Prakash C. Topographic esophageal manometry: an emerging clinical and investigative approach. *Dig Dis* 2000;18:64.
5. Kahrilas PJ, Dodds WJ, Hogan WJ. Effect of peristaltic dysfunction on esophageal volume clearance. *Gastroenterology* 1988;94(1):73–80.
6. ASGE Technology Committee, Wang A, Pleskow DK, et al. Esophageal function testing. *Gastrointest Endosc* 2012;76:231.
7. Bredenoord AJ, Fox M, Kahrilas PJ, et al. Chicago classification criteria of esophageal motility disorders defined in high resolution esophageal pressure topography. *Neurogastroenterol Motil* 2012;24(Suppl 1):57.
8. Chan WW, Haroian LR, Gyawali CP. Value of preoperative esophageal function studies before laparoscopic antireflux surgery. *Surg Endosc* 2011;25:2943–9.
9. Fibbe C, Layer P, Keller J, et al. Esophageal motility in reflux disease before and after fundoplication: a prospective, randomized, clinical, and manometric study. *Gastroenterology* 2001;121:5.
10. Winslow ER, Clouse RE, Desai KM, et al. Influence of spastic motor disorders of the esophageal body on outcomes from antireflux surgery. *Surg Endosc* 2003;17: 738–45.

11. Ghoshal UC, Daschakraborty SB, Singh R. Pathogenesis of achalasia cardia. *World J Gastroenterol* 2012;18(4):3050–7.
12. Khajanchee YS, VanAndel R, Jobe BA, et al. Electrical stimulation of the vagus nerve restores motility in an animal model of achalasia. *J Gastrointest Surg* 2003;7(7):843–9.
13. Pandolfino JE, Kwiatek MA, Nealis T, et al. Achalasia: a new clinically relevant classification by high-resolution manometry. *Gastroenterology* 2008;135:1526.
14. Salvador R, Costantini M, Zaninotto G, et al. The preoperative manometric pattern predicts the outcome of surgical treatment for esophageal achalasia. *J Gastrointest Surg* 2010;14(11):1635–45.
15. Pratap N, Kalapala R, Darisetty S, et al. Achalasia cardia subtyping by high-resolution manometry predicts the therapeutic outcome of pneumatic balloon dilatation. *J Neurogastroenterol Motil* 2011;17(1):48–53.
16. Scherer JR, Kwiatek MA, Soper NJ, et al. Functional esophagogastric junction obstruction with intact peristalsis: a heterogeneous syndrome sometimes akin to achalasia. *J Gastrointest Surg* 2009;13:2219.
17. Sharata AM, Dunst CM, Pescarus R, et al. Peroral Endoscopic Myotomy (POEM) for Esophageal Primary Motility Disorders: Analysis of 100 Consecutive Patients. *J Gastrointest Surg* 2015;19:161–70.
18. Inoue H, Tianle KM, Ikeda H, et al. Peroral endoscopic myotomy for esophageal achalasia: technique, indication and outcomes. *Thorac Surg Clin* 2011;21(4):519–25.
19. Ling TS, Guo HM, Yang T, et al. Effectiveness of peroral endoscopic myotomy in the treatment of achalasia: a pilot trial in Chinese Han population with a minimum of one-year follow-up. *J Dig Dis* 2014;15(7):352–8.
20. Von Renteln D, Fuchs KH, Breithaupt W, et al. Peroral endoscopic myotomy for the treatment of esophageal achalasia: an international multicenter study. *Gastroenterology* 2013;145(2):309–11.
21. Achem SR, Crittenden J, Kolts B, et al. Long-term clinical and manometric follow-up of patients with nonspecific esophageal motor disorders. *Am J Gastroenterol* 1992;87:825.
22. Roman S, Pandolfino JE, Chen J, et al. Phenotypes and clinical context of hypercontractility in high-resolution esophageal pressure topography (EPT). *Am J Gastroenterol* 2012;107(1):37–45.
23. Sperandio M, Tutuian R, Gideon RM, et al. Diffuse esophageal spasm: not diffuse but distal esophageal spasm (DES). *Dig Dis Sci* 2003;48:1380.
24. Orlando RC, Bozyski EM. Clinical and manometric effects of nitroglycerin in diffuse esophageal spasm. *N Engl J Med* 1973;289:23.
25. Swamy N. Esophageal spasm: clinical and manometric response to nitroglycerine and long acting nitrites. *Gastroenterology* 1977;72:23.
26. DiMarino AJ Jr. Characteristics of lower esophageal sphincter function in symptomatic diffuse esophageal spasm. *Gastroenterology* 1974;66:1.
27. Campo S, Traube M. Lower esophageal sphincter dysfunction in diffuse esophageal spasm. *Am J Gastroenterol* 1989;84:928.
28. Pandolfino JE, Roman S, Carlson D, et al. Distal esophageal spasm in high-resolution esophageal pressure topography: defining clinical phenotypes. *Gastroenterology* 2011;141:469.
29. Spencer HL, Smith L, Riley SA. A questionnaire study to assess long-term outcome in patients with abnormal esophageal manometry. *Dysphagia* 2006;21:149.
30. Clouse RE, Lustman PJ, Eckert TC, et al. Low-dose trazodone for symptomatic patients with esophageal contraction abnormalities. A double-blind, placebo-controlled trial. *Gastroenterology* 1987;92:1027.

31. Cannon RO 3rd, Quyyumi AA, Mincemoyer R, et al. Imipramine in patients with chest pain despite normal coronary angiograms. *N Engl J Med* 1994;330:1411.
32. Agrawal A, Tutuian R, Hila A, et al. Successful use of phosphodiesterase type 5 inhibitors to control symptomatic esophageal hypercontractility: a case report. *Dig Dis Sci* 2005;50:2059.
33. Miller LS, Pallela SV, Parkman HP, et al. Treatment of chest pain in patients with noncardiac, nonreflux, nonachalasia spastic esophageal motor disorders using botulinum toxin injection into the gastroesophageal junction. *Am J Gastroenterol* 2002;97:1640.
34. Minami H, Isomoto H, Yamaguchi N, et al. Peroral esophageal myotomy (POEM) for diffuse esophageal spasm. *Endoscopy* 2014;46(S 01):E79–81.
35. Agrawal A, Hila A, Tutuian R, et al. Clinical relevance of the nutcracker esophagus: suggested revision of criteria for diagnosis. *J Clin Gastroenterol* 2006;40:504.
36. Korsapati H, Bhargava V, Mittal RK. Reversal of asynchrony between circular and longitudinal muscle contraction in nutcracker esophagus by atropine. *Gastroenterology* 2008;135:796.
37. Freidin N, Traube M, Mittal RK, et al. The hypertensive lower esophageal sphincter. Manometric and clinical aspects. *Dig Dis Sci* 1989;34:1063.
38. Cattau EL Jr, Castell DO, Johnson DA, et al. Diltiazem therapy for symptoms associated with nutcracker esophagus. *Am J Gastroenterol* 1991;86:272.
39. Vanuytsel T, Bisschops R, Farré R, et al. Botulinum toxin reduces Dysphagia in patients with nonachalasia primary esophageal motility disorders. *Clin Gastroenterol Hepatol* 2013;11:1115.
40. Patti MG, Gorodner MV, Galvani C, et al. Spectrum of esophageal motility disorders: implications for diagnosis and treatment. *Arch Surg* 2005;140(5):442–8.
41. Zamost BJ, Hirschberg J, Ippoliti AF, et al. Esophagitis in scleroderma. Prevalence and risk factors. *Gastroenterology* 1987;92:421.
42. Yarze JC, Varga J, Stampfl D, et al. Esophageal function in systemic sclerosis: a prospective evaluation of motility and acid reflux in 36 patients. *Am J Gastroenterol* 1993;88:870.
43. Poirier NC, Taillefer R, Topart P, et al. Antireflux operations in patients with scleroderma. *Ann Thorac Surg* 1994;58(1):66–72.
44. Watson DI, Jamieson GG, Bessell JR, et al. Laparoscopic fundoplication in patients with an aperistaltic esophagus and gastroesophageal reflux. *Dis Esophagus* 2006;19(2):94–8.
45. Kent MS, Luketich JD, Irshad K, et al. Comparison of surgical approaches to recalcitrant gastroesophageal reflux disease in the patient with scleroderma. *Ann Thorac Surg* 2007;84(5):1710–5.
46. Hunter JG, Trus TL, Branum GD, et al. A physiologic approach to laparoscopic fundoplication for gastrointestinal reflux disease. *Ann Surg* 1996;223(6):673–87.
47. Tutuian R, Castell DO. Clarification of the esophageal function defect in patients with manometric ineffective esophageal motility: studies using combined impedance-manometry. *Clin Gastroenterol Hepatol* 2004;2:230.
48. Roman S, Lin Z, Kwiatek MA, et al. Weak peristalsis in esophageal pressure topography: classification and association with dysphagia. *Am J Gastroenterol* 2011;106:349–56.
49. Kauer WK, Peters JH, DeMeester TR, et al. A tailored approach to antireflux surgery. *J Thorac Cardiovasc Surg* 1995;110:141–7.
50. Horvath KD, Jobe BA, Herron DM, et al. Laparoscopic Toupet fundoplication is an inadequate procedure for patients with severe reflux disease. *J Gastrointest Surg* 1999;3(6):583–91.

51. Farrell TM, Archer SB, Galloway KD, et al. Heartburn is more likely to recur after Toupet fundoplication than Nissen fundoplication. *Am Surg* 2000;66(3):229–36.
52. Patti MG, Robinson T, Galvani C, et al. Total fundoplication is superior to partial fundoplication even when esophageal peristalsis is weak. *J Am Coll Surg* 2004;198:863–70.
53. Bell RC, Hanna P, Mills MR, et al. Patterns of success and failure with laparoscopic Toupet fundoplication. *Surg Endosc* 1999;13:1189–94.
54. Strate U, Emmerman A, Fibbe C, et al. Laparoscopic fundoplication: Nissen versus Toupet two-year outcome of a prospective randomized study of 200 patients regarding preoperative esophageal motility. *Surg Endosc* 2008;22:21–30.
55. Rebecchi F, Giaccone C, Farinella E, et al. Randomized controlled trial of laparoscopic Heller myotomy plus Dor fundoplication versus Nissen fundoplication for achalasia: long-term results. *Ann Surg* 2008;248(6):1023–30.
56. Ilcyszyn A, Botha AJ. Feasibility of esophagogastric junction distensibility measurement during Nissen fundoplication. *Dis Esophagus* 2014;27(7):637–44.
57. Kwiatek MA, Kahrilas PJ, Soper NJ, et al. Esophagogastric junction distensibility after fundoplication assessed with a novel functional luminal imaging probe. *J Gastrointest Surg* 2010;14:268–76.
58. D'Journo XB, Ferraro P, Martin J, et al. Lower oesophageal sphincter dysfunction is part of the functional abnormality in epiphrenic diverticulum. *Br J Surg* 2009;96:892–900.
59. Blom D, Peters JH, DeMeester TR, et al. Physiologic mechanism and preoperative prediction of new-onset dysphagia after laparoscopic Nissen fundoplication. *J Gastrointest Surg* 2002;6(1):22–7.