

Mitral Valve Repair

The French Correction Versus the American Correction



Sarah A. Schubert, MD^{a,*}, James H. Mehaffey, MD^b,
Eric J. Charles, MD^b, Irving L. Kron, MD^a

KEYWORDS

- Mitral valve repair • French correction • American correction
- Degenerative mitral valve disease

KEY POINTS

- Mitral valve repair is associated with better short- and long-term outcomes, fewer thromboembolic complications, and improved survival compared with mitral valve replacement.
- Carpentier's "French correction" of degenerative mitral valve pathology aims to restore normal valve anatomy through leaflet resection, chordal manipulation, and rigid annuloplasty.
- The "American correction" of degenerative mitral valve pathology intends to restore normal valve function through use of artificial chordae, minimal leaflet resection, and flexible annuloplasty.

Degenerative mitral valve disease is found in 2% to 3% of adults in the United States, making it the most common organic mitral valve pathology.¹ Although degenerative mitral valve pathology does not always progress to clinically significant mitral regurgitation (MR), patients who develop symptoms attributable to MR have a worse prognosis with mortality rates of 34% annually.^{2,3}

With surgery essentially unavoidable in these patients, mitral valve repair has demonstrated superior short-⁴⁻⁶ and long-term⁷⁻⁹ outcomes in a wide variety of patients with degenerative^{5,8,10,11} or functional^{9,12-15} mitral valve disease.^{6,16} Valve replacement, however, may be considered in patients with combined degenerative and ischemic MR, MR caused by papillary muscle rupture, or those undergoing reoperation following prior failed repair.¹⁷ Nevertheless, mitral valve repair for either

The authors have nothing to disclose.

^a Division of Thoracic and Cardiovascular Surgery, Department of Surgery, University of Virginia, 1215 Lee Street, Box 800679, Charlottesville, VA 22908, USA; ^b Department of Surgery, University of Virginia, Box 800709, Charlottesville, VA 22908, USA

* Corresponding author.

E-mail address: ss9kw@virginia.edu

Surg Clin N Am 97 (2017) 867–888
<http://dx.doi.org/10.1016/j.suc.2017.03.009>

surgical.theclinics.com

0039-6109/17/© 2017 Elsevier Inc. All rights reserved.

degenerative or ischemic MR has been consistently associated with lower risk of thromboembolism and improved survival.⁶

Not surprisingly, as the outcomes with mitral valve repair have surpassed those of mitral valve replacement, the methods of mitral valve repair have evolved and improved. The optimal methods for surgical repair of MR have varied over time and even across continents. Beginning with suture annuloplasty,¹⁸ then commissural fusion with suture,¹⁹ and open leaflet plication,²⁰ techniques of mitral valve repair have continued to multiply and progress.

Alain Carpentier's method of leaflet repair with quadrangular resection and rigid annuloplasty to correct annular dilatation emerged as the most successful and reproducible means of correcting MR.^{21–25} Developed through autopsy and pathology studies of the mitral valve, Carpentier's method of mitral valve repair aimed to restore normal dimensions to the mitral valve and apparatus,²² a so-called anatomic approach that has come to be known as the "French correction."²⁵

Yet, as imaging techniques have improved and knowledge of the dynamic structure and function of the mitral valve has grown, Lawrie and colleagues²⁶ turned to a functional correction of MR, which he referred to as the "American correction."^{27,28} The primary tenet of this repair is colloquially "respect, not resect," in reference to the mitral valve leaflets and chordae, which are generally spared with this approach. Furthermore, Lawrie's method relies on a flexible annuloplasty ring to correct annular dilatation and Gore-Tex (WL Gore and Associates, Inc, Newark, DE) artificial chordae to repair prolapse and realign leaflets.^{28,29}

Although these techniques are traditionally compared in opposition with one another, in reality, these methods of mitral valve repair simply reflect an evolution in principles as operative techniques are enhanced and as more is discovered about the mitral valve's dynamic structure and functions.

MITRAL VALVE ANATOMY

Located between the left atrium and left ventricle, the mitral valve apparatus is comprised of the mitral annulus, anterior and posterior leaflets, chordae tendinae, and the papillary muscles. The valvular apparatus works in concert with the subvalvular apparatus, namely the chordae tendinae and papillary muscles, to permit normal blood flow from the left atrium to the left ventricle during diastole and prevent reversal of flow during systole (**Fig. 1**).

The mitral annulus is an ovoid ring of fibrous tissue that is continuous with the fibrous skeleton of the heart. The right fibrous trigone is formed from the confluence of the mitral and tricuspid annuli to which the noncoronary leaflet of the aortic valve and the membranous interventricular septum are attached. The left fibrous trigone is formed from the fibrous continuity between the aortic and mitral valves. With the anterolateral and posteromedial commissures located at the lowest point in the mitral annulus, the normal configuration of the valvular annulus is in the shape of a saddle (**Fig. 2**). The mitral valve annulus is thinnest at the insertion of the posterior leaflet, thus making it the most mobile portion of the valve and consequently most vulnerable to dilatation.^{1,30}

The anterior leaflet of the mitral valve comprises approximately two-thirds of the area of the valvular orifice but only one-third for the annular circumference, whereas the posterior leaflet comprises the other two-thirds of the annular circumference (**Fig. 3**). A normal line of coaptation exists between the leaflets, ranging from 7 mm to 9 mm, thus allowing for valve competency with a variety of physiologic systolic pressures and volumes. Of note, the commissures do not extend into the annulus,

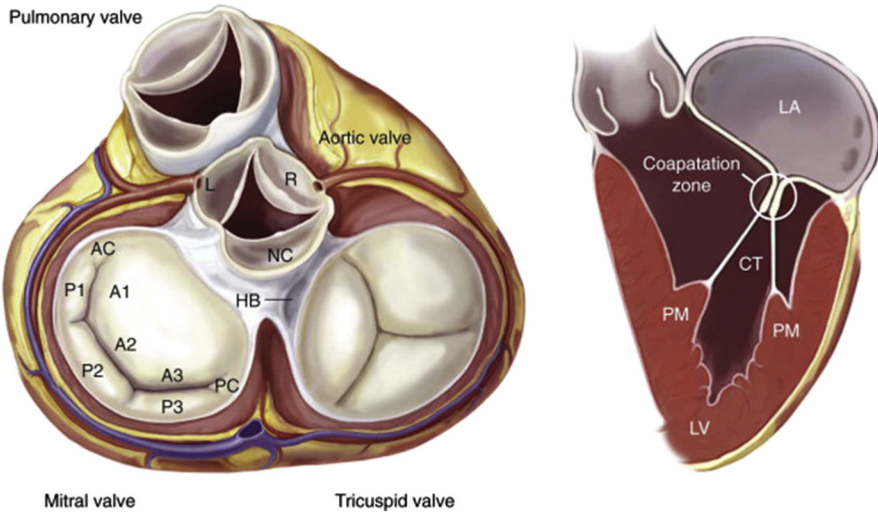


Fig. 1. Anatomy of the mitral valve and mitral apparatus. (Left) Anatomic view of the cardiac valves in systole with the left and right atrium cropped away and the great vessels transected. The mitral valve apparatus consists of the mitral leaflets, mitral annulus, chordae tendineae, the papillary muscles, and the left ventricle. (Right) Normal function of the mitral apparatus brings both leaflets together in systole and creates the coaptation zone. A1, A2, A3, segments of the anterior leaflet; AC, anterior commissure; CT, chordae tendineae; HB, His bundle; L, left coronary cusp; LA, left atrium; LV, left ventricle; NC, noncoronary cusp; P1, P2, P3, segments of the posterior leaflet; PC, posterior commissure; PM, papillary muscle; R, right coronary cusp. (From Castillo JG, Adams DH. Mitral valve repair and replacement. In: Otto C, editor. Valvular heart disease: a companion to Braunwald's heart disease. 4th edition. Philadelphia: Elsevier Saunders; 2014. p. 327; with permission.)

leaving so-called commissural leaflets that must be respected during commissurotomy to prevent subsequent leaflet tearing and valvular regurgitation.³⁰

The posterior leaflet is divided into three segments: P1, P2, and P3 based on normal indentations along the leaflet free edge, with corresponding segments A1, A2, and A3 in the anterior leaflet, albeit without visible anatomic delineations as those in the posterior leaflet (see Fig. 3). The posterior leaflet, also known as the mural leaflet, is attached to the ventricular free wall, thus directly subjecting it to the repeated stresses of ventricular contractions and making it more vulnerable to prolapse, particularly within the P2 leaflet.³⁰

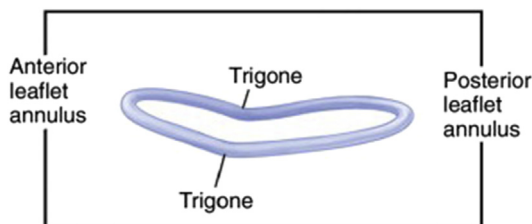


Fig. 2. Schematic configuration of the mitral annulus. (From Carpentier A, Adams DH, Filsoufi F. Surgical anatomy and physiology. In: Carpentier A, editor. Carpentier's reconstructive valve surgery: from valve analysis to valve reconstruction. Philadelphia: Elsevier Saunders; 2010. p. 30; with permission.)

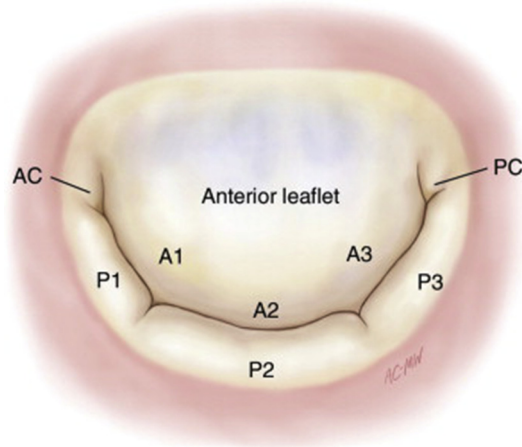


Fig. 3. Normal configuration of mitral valve leaflets. A1, A2, A3, segments of anterior leaflet; AC, anterior commissure; P1, P2, P3, segments of posterior leaflet; PC, posterior commissure. (From Carpentier A, Adams DH, Filsoufi F. Surgical anatomy and physiology. In: Carpentier A, editor. Carpentier's reconstructive valve surgery: from valve analysis to valve reconstruction. Philadelphia: Elsevier Saunders; 2010. p. 33; with permission.)

The subvalvular apparatus consists of the chordae tendinae, collagenous connections between the papillary muscles and the ventricular leaflet surface, and papillary muscles, which are part of the muscular ventricular wall (**Fig. 4**). Primary or marginal chordae attach to the free edge of the leaflet, thus preventing leaflet prolapse. Secondary or intermediary chordae attach to the ventricular leaflet surface and act to

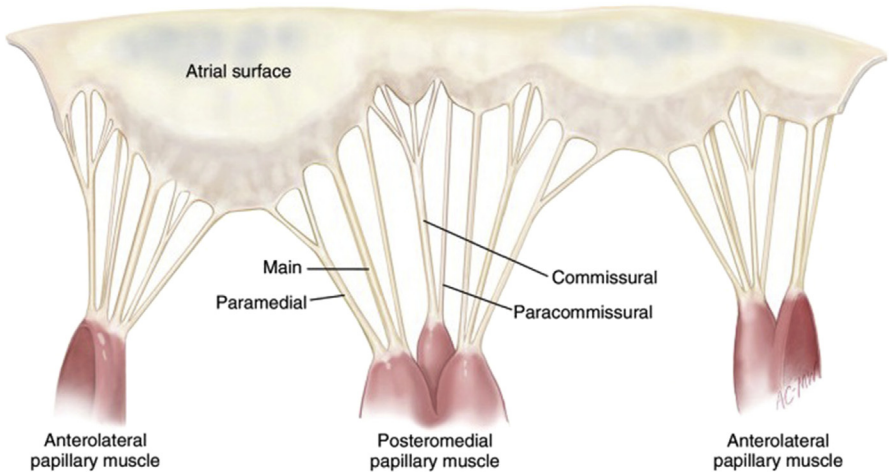


Fig. 4. Mitral subvalvular apparatus. The chordae tendinae attach the valve leaflets to the papillary muscles, with the main chordae originating from the middle of the leaflet free edge and others identified according to their position relative to the commissures and to the leaflet free edge. There is wide variability in chordal branching and attachments. (From Carpentier A, Adams DH, Filsoufi F. Surgical anatomy and physiology. In: Carpentier A, editor. Carpentier's reconstructive valve surgery: from valve analysis to valve reconstruction. Philadelphia: Elsevier Saunders; 2010. p. 37; with permission.)

reduce leaflet tension. Tertiary chordae (basal chordae), which are only present on the posterior leaflet, attach the leaflet base to the annulus and myocardium.¹

Two papillary muscles originate from the left ventricular myocardium: the anterolateral papillary muscle and the posteromedial papillary muscle (Fig. 5). Each papillary muscle anchors chordae from both leaflets, and the configurations of chordal attachments to each papillary muscle, and even to the ventricular wall, can widely vary.³⁰ Working in concert, all of these components of the mitral valve apparatus serve to maintain valvular competence and direct proper blood flow from the left atrium to the left ventricle.

THE FRENCH CORRECTION

Alain Carpentier was the first to systematically describe regurgitant mitral valve pathology and standardize the myriad of methods for repairing the mitral valve.^{25,31} He divided mitral valve pathology into three primary types based on leaflet motion (Table 1). Type I MR describes MR with normal leaflet motion. This type of MR develops from annular dilation, leaflet tear, leaflet perforation, or vegetation. These structural deficiencies are usually the result of ischemic or dilated cardiomyopathy, long-standing atrial fibrillation, trauma, or endocarditis (Fig. 6). Type II describes a valve with leaflet prolapse, which results from chordal rupture, papillary muscle rupture, chordal elongation, or papillary muscle elongation. Leaflet prolapse is usually secondary to degenerative processes, such as fibroelastic deficiency, Barlow disease, or Marfan syndrome, but it can also develop as a result of endocarditis, trauma, or ischemic cardiomyopathy (Fig. 7). Type III describes a valve with restricted leaflet motion. Type IIIa refers to restricted leaflet opening primarily during diastole, usually the result of rheumatic disease causing commissure fusion, chordae thickening, and chordae fusion. Type IIIb refers to restricted leaflet opening primarily during systole, resulting from leaflet tethering caused by papillary muscle displacement from localized ventricular dyskinesia or global ventricular dilatation from later stages of various cardiomyopathies (Fig. 8).^{1,25} Because the cause of valvular dysfunction determines prognosis and treatment strategy depends on this cause, Carpentier's classification scheme aids selection of appropriate surgical repair techniques.

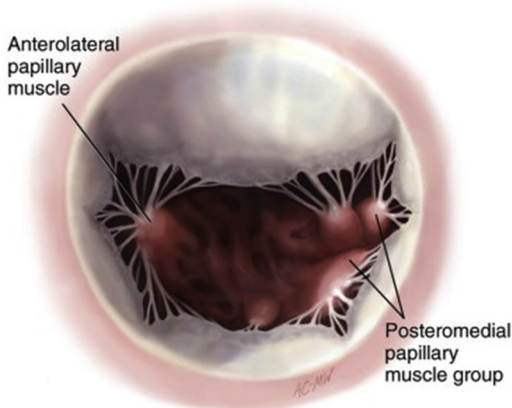
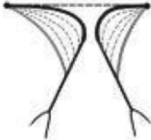
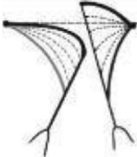




Fig. 5. View of the anterolateral and posteromedial papillary muscles through the mitral valve orifice. (From Carpentier A, Adams DH, Filsoofi F. Surgical anatomy and physiology. In: Carpentier A, editor. Carpentier's reconstructive valve surgery: from valve analysis to valve reconstruction. Philadelphia: Elsevier Saunders; 2010. p. 35; with permission.)

Table 1 Carpentier's functional classification of mitral regurgitation	
	
Type I	Type II
Normal leaflet motion	Leaflet prolapse (excess leaflet motion)
	
Type IIIa	Type IIIb
Restricted leaflet motion (diastolic)	Restricted leaflet motion (systolic)

From Carpentier A, Adams DH, Filsoufi F. Pathophysiology, preoperative valve analysis, and surgical indications. In: Carpentier A, editor. Carpentier's reconstructive valve surgery: from valve analysis to valve reconstruction. Philadelphia: Elsevier Saunders; 2010. p. 45; with permission.

The rationale behind Carpentier's French correction of a regurgitant mitral valve is restoration of the normal anatomic relationships within the valve apparatus, and the first step toward that restoration is a careful examination of the diseased valve. The atrium is examined for jet lesions indicative of prolapse of an opposing leaflet, and the annulus diameter is assessed for degree of dilatation. All leaflets are unfurled with a nerve hook and examined for thickening, tethering, or prolapse, and the chordae are inspected for rupture or elongation.

Repair of the valve proceeds with a quadrangular resection of the prolapsed portion of the posterior leaflet with corresponding annular plication, followed by suture reapproximation of the free leaflet edges (Fig. 9).

Correcting anterior leaflet prolapse depends on the causative lesion, whether it is chordal rupture or elongation. When chordal rupture has occurred, the free edge of the prolapsed leaflet is fixed to intact secondary chordae or chordae from the mural leaflet are transposed to the free edge of the prolapsed anterior leaflet, which requires sufficient mobilization of the corresponding papillary muscle (Fig. 10).

When anterior leaflet prolapse is the result of chordal elongation, the excess chordal length can essentially be tucked into an invagination created within the attached papillary muscle and then suturing each side of the divided papillary muscle back together around the extra chordal length (Fig. 11). Another method of mending chordal elongation is shortening of the papillary muscle (Fig. 12).

Restricted leaflet motion is another source of MR, and it is the result of four different lesions: (1) leaflet thickening, (2) chordal thickening, (3) commissural fusion, and (4) chordal fusion. Commissurotomy is done to correct commissural fusion. Chordal thickening, which occurs with the secondary chordae, is alleviated with resection of the thickened chordae or fenestration of thickened marginal chordae.

Type I - Normal Leaflet Motion

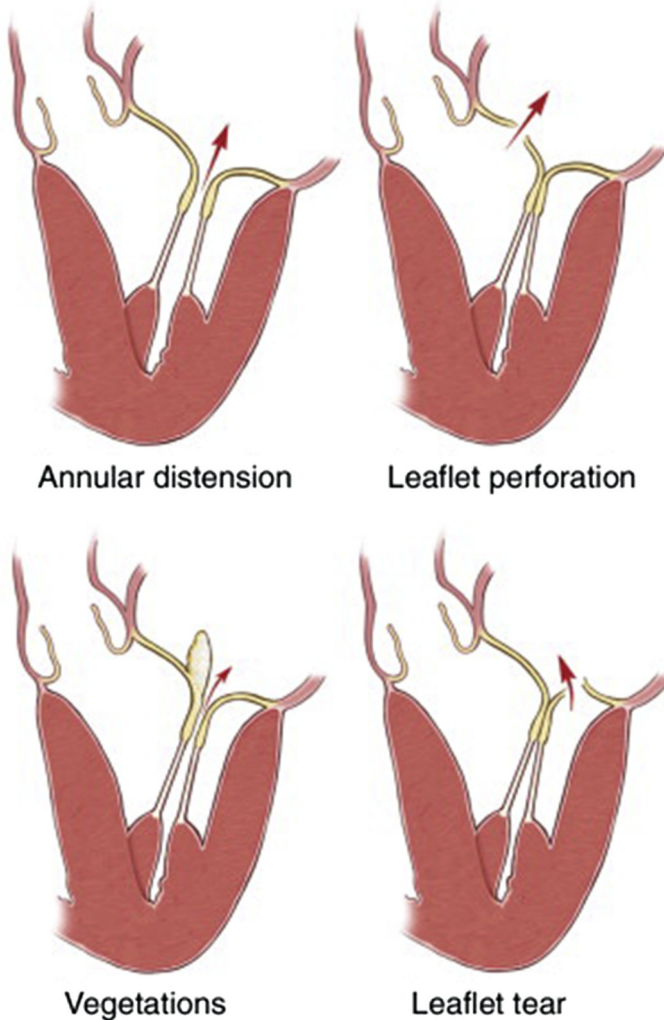
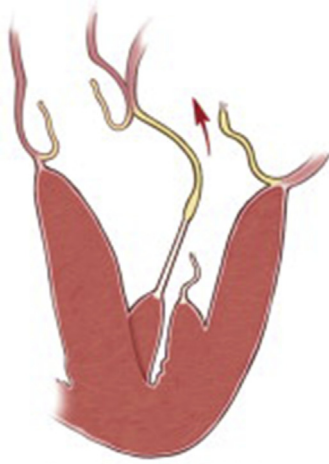

Fig. 6. Type I functional MR according to Carpentier's classification. Type I describes MR with normal leaflet motion, usually arising from annular dilatation, leaflet perforation, vegetation, or leaflet tear. (From Carpentier A, Adams DH, Filsoufi F. Pathophysiology, preoperative valve analysis, and surgical indications. In: Carpentier A, editor. Carpentier's reconstructive valve surgery: from valve analysis to valve reconstruction. Philadelphia: Elsevier Saunders; 2010. p. 47; with permission.)

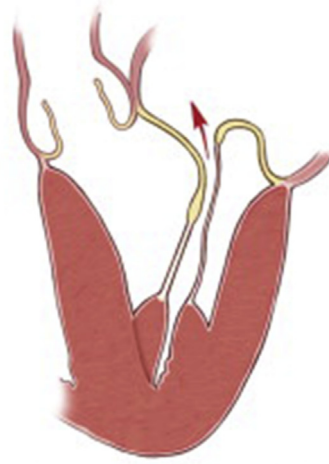Finally, to correct the annular dilatation that accompanies essentially all cases of mitral insufficiency, Carpentier pioneered the development of a rigid prosthetic annuloplasty ring. The ring is intended to restore the normal systolic size and shape of the annulus, thus also restoring leaflet coaptation and preventing further deformation of the annulus (Fig. 13).

Since first describing the use of a rigid annuloplasty ring, Carpentier has developed three different types of annuloplasty rings to refine repair according to the anatomic

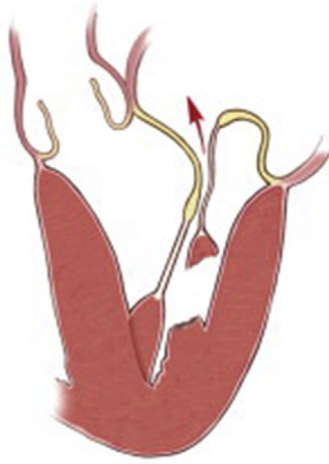Type II - Leaflet Prolapse



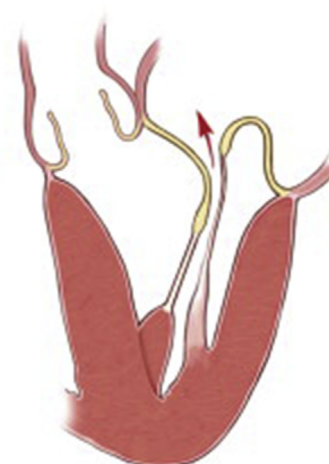Chordae rupture



Chordae elongation



Papillary muscle
rupture



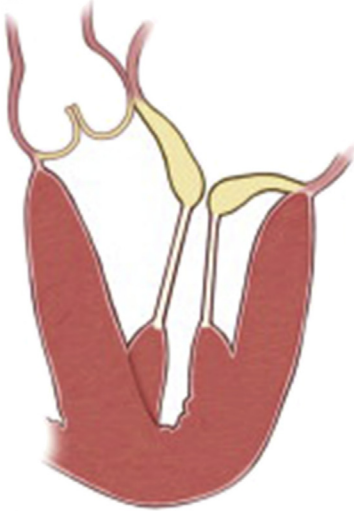Papillary muscle
elongation

Fig. 7. Type II functional MR according to Carpentier's classification. Type II describes MR from leaflet prolapse, usually the result of chordal or papillary muscle rupture or elongation. (From Carpentier A, Adams DH, Filsoufi F. Pathophysiology, preoperative valve analysis, and surgical indications. In: Carpentier A, editor. Carpentier's reconstructive valve surgery: from valve analysis to valve reconstruction. Philadelphia: Elsevier Saunders; 2010. p. 47; with permission.)

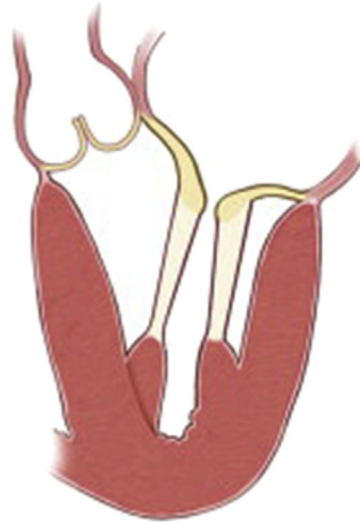deformation: (1) the Carpentier-Edwards Classic Ring, (2) the Carpentier-Edwards Physio Ring, and (3) the Carpentier-McCarthy-Adams Etiologix IMR Ring for ischemic MR (Edwards LifeSciences Corp, Irvine, CA). The Physio ring is designed for degenerative MR, with a large anteroposterior diameter and a slight saddle shape to restore normal systolic contour to the valvular annulus.³² Sizing of the annuloplasty ring is

Type III Restricted Leaflet Motion

Type IIIa - Diastolic

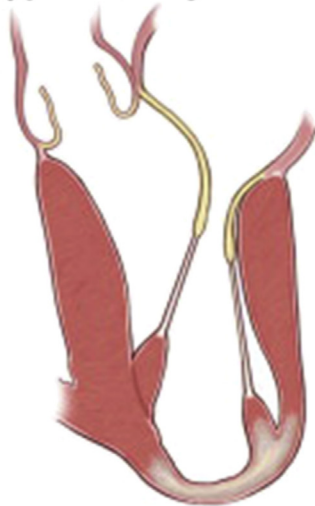

Commissure fusion/
leaflet thickening

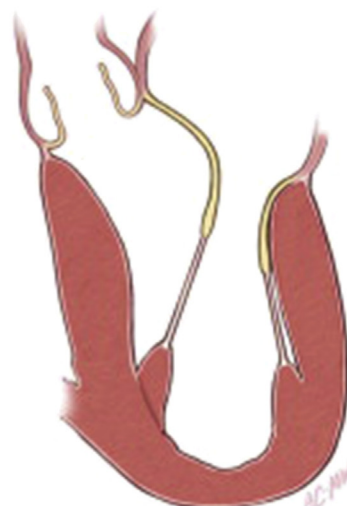


Chordae thickening/
fusion

Type IIIb - Systolic



Myocardial infarction



Ventricular dilatation

Fig. 8. Type IIIa and IIIb functional MR according to Carpentier's classification. Type IIIa describes MR from restricted leaflet motion during diastole and type IIIb describes MR from restricted leaflet motion during systole. (From Carpentier A, Adams DH, Filsoufi F. Pathophysiology, preoperative valve analysis, and surgical indications. In: Carpentier A, editor. Carpentier's reconstructive valve surgery: from valve analysis to valve reconstruction. Philadelphia: Elsevier Saunders; 2010. p. 48; with permission.)

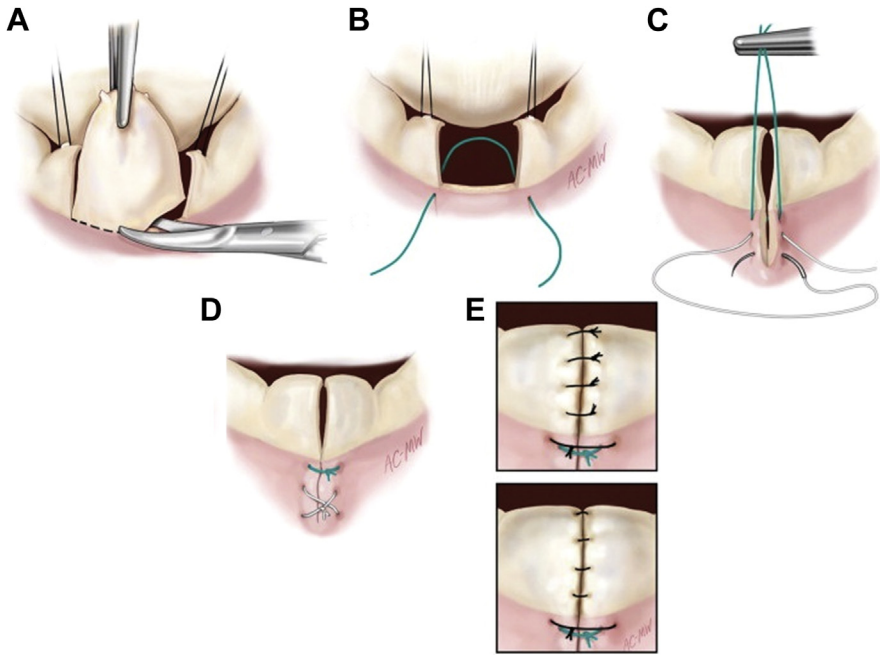


Fig. 9. Quadrangular resection of prolapsed P2 leaflet. (A) Quadrangular portion of prolapsed P2 leaflet is excised. (B) An interrupted mattress suture is placed through the annulus at the limits of the resected area. (C) A figure-of-eight suture is placed through the annulus to plicate the annulus. (D) Completed annular plication. (E) Interrupted sutures are placed to reapproximate the resected leaflet edges, with knots inverted or everted. (From Carpentier A, Adams DH, Filsoufi F. Techniques in type II posterior leaflet prolapse. In: Carpentier A, editor. *Carpentier's reconstructive valve surgery: from valve analysis to valve reconstruction*. Philadelphia: Elsevier Saunders; 2010. p. 118; with permission.)

based on precise measurement of the anterior leaflet surface area by unfurling the leaflet, thus approximating the size and shape of the mitral orifice.²⁵

Following correction of these annular and leaflet abnormalities, systolic anterior motion (SAM) of the mitral valve can result if there is a residual discrepancy between the annular area and the remaining leaflet tissue. SAM occurs when the anterior mitral valve leaflet prolapses into the left ventricular outflow tract (LVOT) during systole (Fig. 14).³³ The primary risk factors for the development of SAM following mitral valve repair are an undersized annuloplasty ring and/or excess leaflet tissue.^{34,35} Consequences of this pathologic leaflet motion include residual MR and LVOT obstruction, both of which are observed on intraoperative transesophageal echocardiography. If SAM is observed intraoperatively following mitral valve repair, most instances are corrected with optimization of ventricular filling via increasing preload and afterload, improving atrioventricular synchrony through atrioventricular pacing, and stopping pharmacologic inotropic support to reduce ventricular hypercontractility. These maneuvers are also effective postoperatively and are supplemented with β -blocker administration. SAM that appears with provocative testing (dynamic SAM) usually resolves within a few weeks after surgery through LVOT remodeling.³⁶

Instances of SAM that are irreversible, persist following surgery, or produce significant hemodynamic derangement must be surgically corrected. If the unfurled anterior

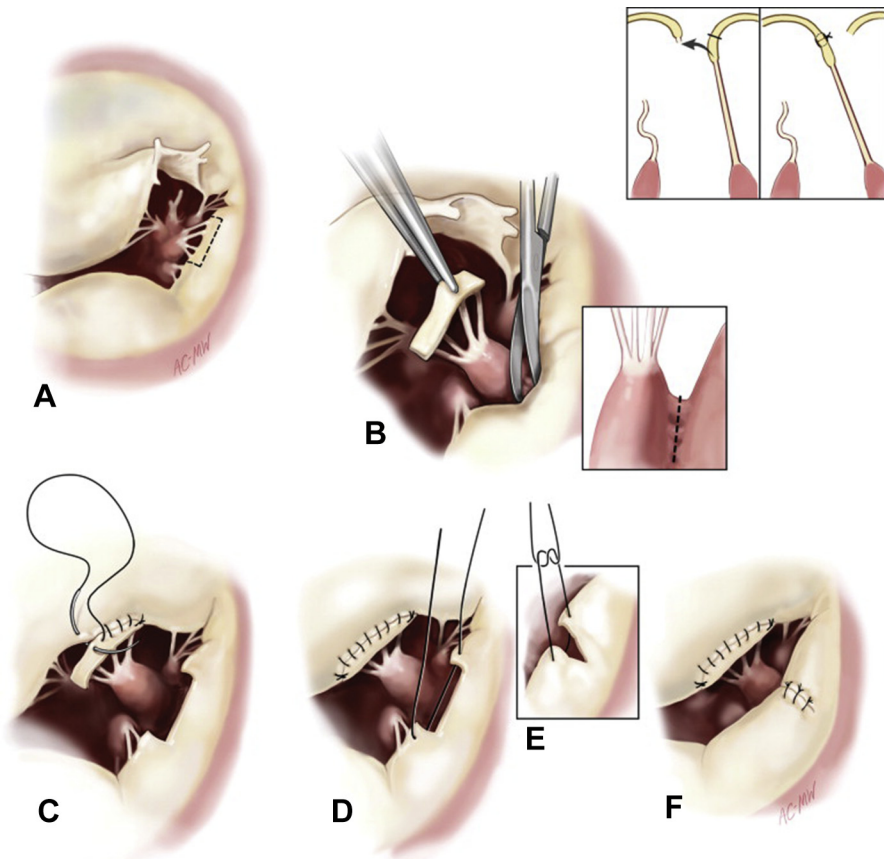


Fig. 10. Chordal transposition to correct chordal rupture. (A) Posterior leaflet adjacent to the area of prolapsed leaflet is identified. (B) Posterior leaflet tissue is mobilized with attached chordae, with mobilization of papillary muscle as necessary. (C) Reattachment of posterior chordae to prolapsed anterior leaflet. (D, E) Reapproximation of posterior leaflet edges. (F) Completed chordal transposition. (From Carpentier A, Adams DH, Filsoofi F. Techniques in type II anterior leaflet prolapse. In: Carpentier A, editor. Carpentier's reconstructive valve surgery: from valve analysis to valve reconstruction. Philadelphia: Elsevier Saunders; 2010. p. 101; with permission.)

leaflet is much larger than the annulus, the annuloplasty ring should be replaced with a ring of larger diameter³⁷ or the posterior leaflet height should be reduced. Carpentier advocated for a sliding annuloplasty to decrease the height of the posterior leaflet, which includes resection of a portion of the leaflet and annular plication with reapproximation of the resected leaflet edges (Fig. 15).^{36,38}

Since developing these methods of mitral valve repair, outcomes with these particular techniques have varied. Although the repair techniques demonstrate excellent short-term results with low rates of persistent MR and even lower mortality rates, durability with Carpentier's repair techniques declines over time.^{39–42} David and colleagues³⁹ report freedom from MR at 12 years ranging from 65% to 80%, depending on which leaflet is prolapsed. Flameng and colleagues⁴¹ cite a constant recurrence rate of regurgitation of 2% to 3% per year, with a freedom from MR of

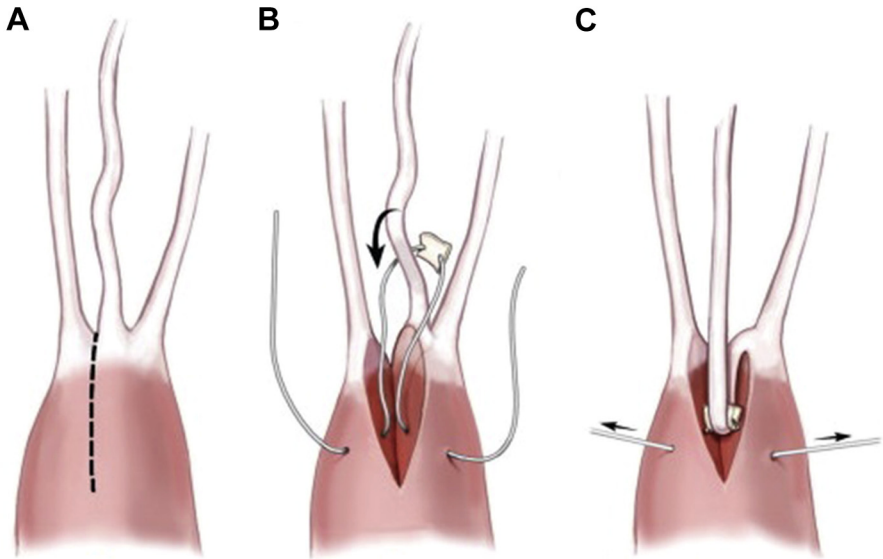


Fig. 11. Chordal shortening technique. (A) Papillary muscle is divided. (B) Pledged suture is passed around excess chord. (C) Pledged suture around excess chord is invaginated into divided papillary muscle, which is subsequently reapproximated. (From Carpentier A, Adams DH, Filsoufi F. Techniques in type II anterior leaflet prolapse. In: Carpentier A, editor. Carpentier's reconstructive valve surgery: from valve analysis to valve reconstruction. Philadelphia: Elsevier Saunders; 2010. p. 106; with permission.)

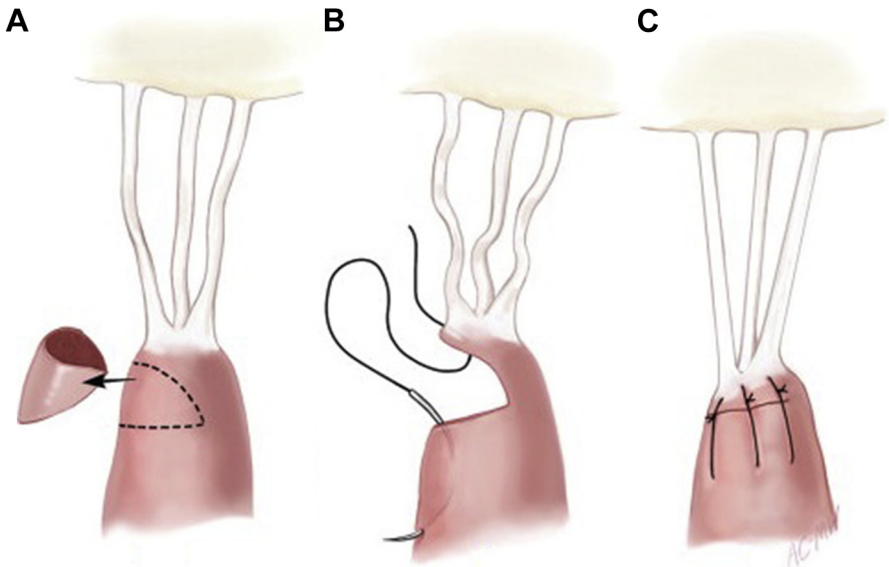


Fig. 12. Papillary muscle shortening technique. (A) Papillary muscle is resected. (B) Edges of resected papillary muscle are reapproximated. (C) Completed shortened papillary muscle. (From Carpentier A, Adams DH, Filsoufi F. Techniques in type II anterior leaflet prolapse. In: Carpentier A, editor. Carpentier's reconstructive valve surgery: from valve analysis to valve reconstruction. Philadelphia: Elsevier Saunders; 2010. p. 107; with permission.)

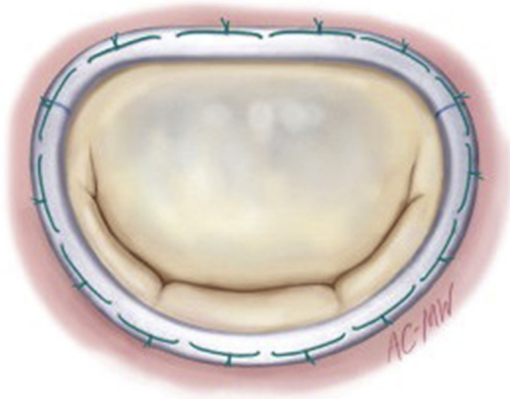


Fig. 13. Completed annuloplasty to correct annular dilatation. (From Carpentier A, Adams DH, Filsoufi F. Valve exposure, intraoperative valve analysis, and reconstruction. In: Carpentier A, editor. Carpentier's reconstructive valve surgery: from valve analysis to valve reconstruction. Philadelphia: Elsevier Saunders; 2010. p. 60; with permission.)

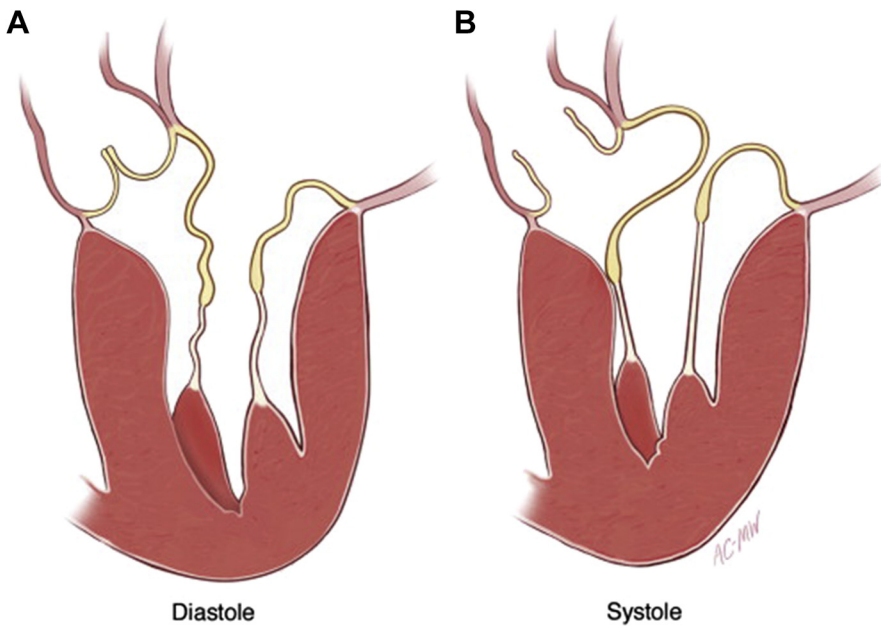


Fig. 14. SAM of the mitral valve. (A) Redundant chordal and leaflet tissue during diastole. (B) Left ventricular outflow tract obstruction from redundant chordal and leaflet tissue during systole. (From Carpentier A, Adams DH, Filsoufi F. Techniques in systolic anterior leaflet motion (SAM). In: Carpentier A, editor. Carpentier's reconstructive valve surgery: from valve analysis to valve reconstruction. Philadelphia: Elsevier Saunders; 2010. p. 157; with permission.)

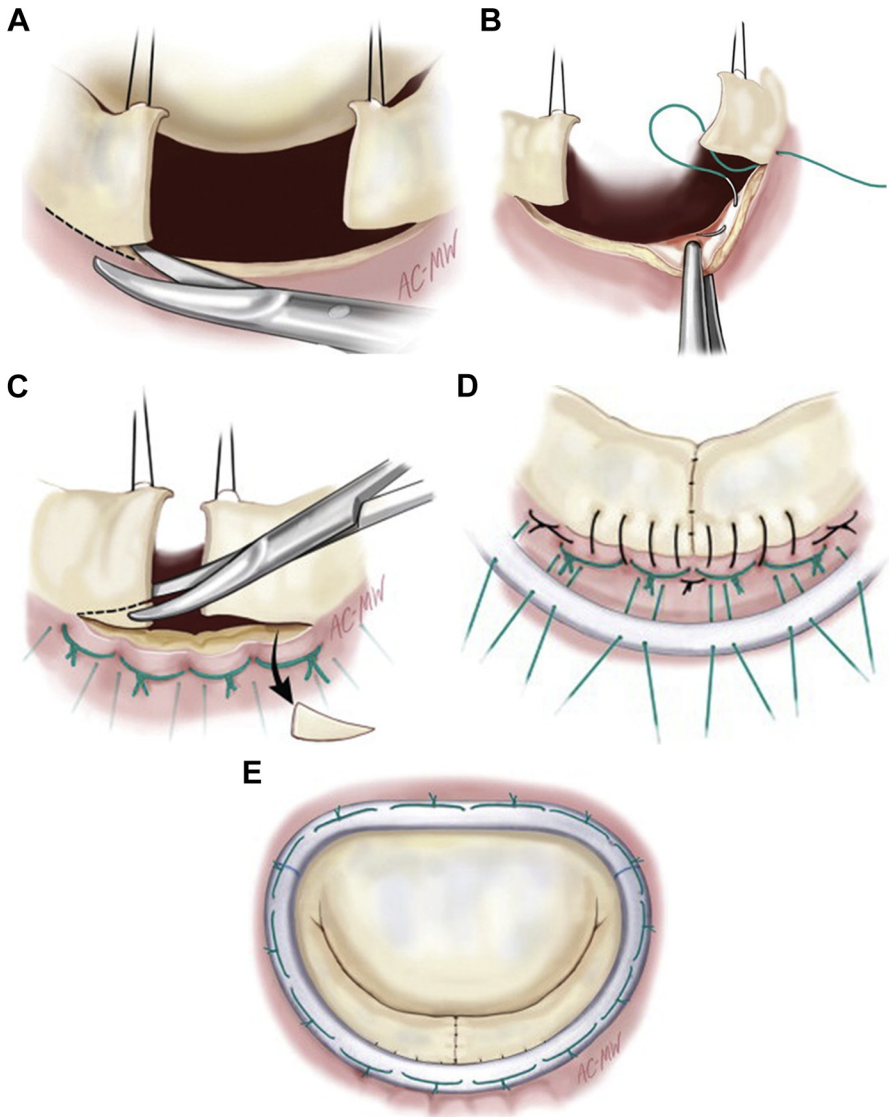


Fig. 15. Sliding leaflet annuloplasty. (A) Excess prolapsed leaflet is resected, and secondary chordae are resected as necessary. (B) Sutures are then passed successively through the annulus to reduce its diameter. (C) Annular sutures are tied to compress, not plicate, the annulus. (D) Completed sliding leaflet reconstruction with annuloplasty ring placement. (E) Completed sliding annuloplasty. (From Carpentier A, Adams DH, Filsofi F. Techniques in type II posterior leaflet prolapse. In: Carpentier A, editor. Carpentier's reconstructive valve surgery: from valve analysis to valve reconstruction. Philadelphia: Elsevier Saunders; 2010. p. 120–2; with permission.)

65% at 10 years. In patients with Barlow disease, Jouan and colleagues³¹ describe a recurrence rate of 9.8% of moderate or greater MR. Although there are varying estimates of the recurrence of MR and the subsequent need for reoperation in these patients, repairs of this type may be permanent, albeit with recurrent MR possibly

remaining clinically silent. As experience with Carpentier's repair techniques began to accumulate and advanced imaging techniques that allow better comprehension of the structural dynamics of the mitral valve became available, new ideas regarding the optimal means of repairing the mitral valve began to emerge. These new ideas of mitral valve repair eventually coalesced into what is known as the "American correction."

THE AMERICAN CORRECTION

In contrast to Carpentier's French correction of degenerative MR, Gerald Lawrie developed the so-called American correction as a means of functional restoration, as opposed to anatomic restoration, of the mitral valve. Primary tenets of this American correction consist of a flexible annuloplasty ring and maintenance of the entire mitral valve leaflets with artificial chordae used to correct areas of prolapse.^{26,27,29}

This idea of restoration of function developed over time as knowledge of the dynamic structure of the mitral valve throughout the cardiac cycle was elucidated. Enhanced imaging techniques, such as three-dimensional echocardiography, drove these developments. Visualization of the mitral valve *in vivo*, as opposed to autopsy examination, led to the understanding that movement of the entire valve apparatus determines its degree of proper function. Thus, a functional correction of the mitral valve became a more salient objective.

Valvular competency is based on leaflet coaptation, which is derived from the mitral annulus. A normally functioning mitral annulus varies in shape throughout the course of the cardiac cycle. The annulus is attached to the left ventricular myocardium posterolaterally, the aortic root anteriorly, and the left atrium superiorly, creating a saddle-shape. The commissural junction of the anterior and posterior leaflets is angulated, which becomes more acute during systole as the ventricle contracts and the aortic root and sinuses of Valsalva expand. These systolic changes displace the anterior annulus and leaflet, posteriorly, thus promoting leaflet apposition during systole.^{29,43,44}

The mitral valve annulus in patients with degenerative MR, however, can double in size, with significant flattening of the valvular orifice and diminished leaflet edge apposition.^{29,45,46} Without sufficient leaflet coaptation, additional stress is added to the leaflet bodies and marginal chordae during systole, thus predisposing these components to further dysfunction and future failure.⁴⁷⁻⁴⁹

As experience with Carpentier's techniques of rigid annuloplasty repair and leaflet resection began to accumulate, durability of the repair techniques was questioned, in light of a reoperation rate for recurrent MR of 43%.⁵⁰ Furthermore, additional investigation into mechanisms of mitral valve competence revealed that rigid annuloplasty rings induce high levels of leaflet and annular strain, thus predisposing the valvular repair to early mechanical failure.⁴⁸

In response to these high rates of reoperation, the American correction was devised to maintain normal three-dimensional geometry and permit normal movement of the valvular apparatus throughout the cardiac cycle. First and foremost, this American correction is a nonresectional or limited resection approach, characterized by maintaining an intact annulus and leaflets. This approach is thought to more closely mimic the function and movement of a normal mitral valve, with a similar distribution of stress throughout the leaflets and annulus.⁵¹

Similar to Carpentier's technique, the American correction begins with a detailed examination of the valve apparatus to determine the sources of valvular insufficiency. Transition zones along the leaflet coaptation edge are marked to determine the normal

points of leaflet coaptation, traction sutures are placed in the annulus, and the valve is tested with a bulb syringe (Fig. 16).

To correct areas of leaflet prolapse, artificial Gore-Tex cords are placed through the papillary muscle in two places and then each end of suture is brought up to the leaflet edge as a pair of chordae and secured with a double pass through the edge of the valve leaflet (Fig. 17). When the necessary sutures have been placed to correct the areas of prolapse, each chord length is adjusted according to intermittent examinations of leaflet coaptation. Of note, overshortening of the chordae can create a narrow regurgitant jet after weaning from bypass. This results in the papillary muscles and the leaflet edges being pulled into the ventricular lumen more than what is simulated with bulb syringe insufflation. After the chordae have been appropriately sized, the sutures are then tied, and the knots are tacked to the ventricular leaflet surfaces.²⁸

A limited resection technique can also be used with a triangular leaflet resection to correct leaflet prolapse (Fig. 18). This simplified technique is used to reduce the height of the posterior leaflet, with a reduced incidence of postoperative SAM. Furthermore, a limited resection reduces excessively redundant leaflet tissue, as occurs with Barlow disease, in the repair compared with the use of artificial chordae. Combining a triangular resection with a large (generally 36, 38, or 40 mm) annuloplasty ring prevents the development of SAM.⁵² Additionally, this type of resection is less technically complex compared with Carpentier's sliding annuloplasty to correct posterior leaflet prolapse, thus possibly prompting more surgeons to repair rather than replace some valves.⁵³

After correcting leaflet prolapse, attention is then turned to repair of the annulus. Following ventricular insufflation, a flexible annuloplasty ring that best approximates the entire surface of the valve is chosen. Interrupted sutures are placed to anchor the annuloplasty ring at the trigones of the valve, and a running suture is used to attach the ring within the intertrigonal portions of the annulus.²⁸

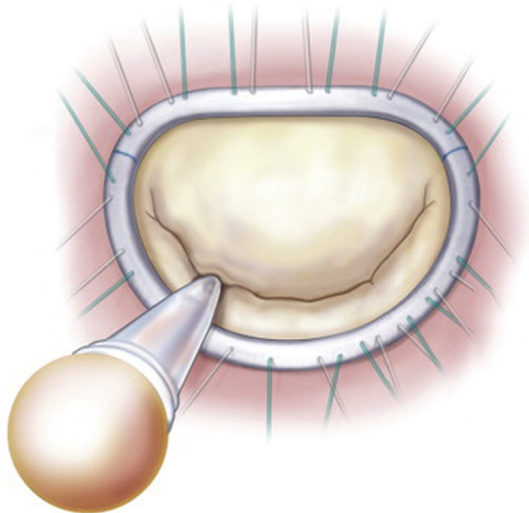


Fig. 16. Testing valve competency with a bulb syringe. (From Carpentier A, Adams DH, Filsoufi F. Techniques in type I dysfunction. In: Carpentier A, editor. Carpentier's reconstructive valve surgery: from valve analysis to valve reconstruction. Philadelphia: Elsevier Saunders; 2010. p. 78; with permission.)

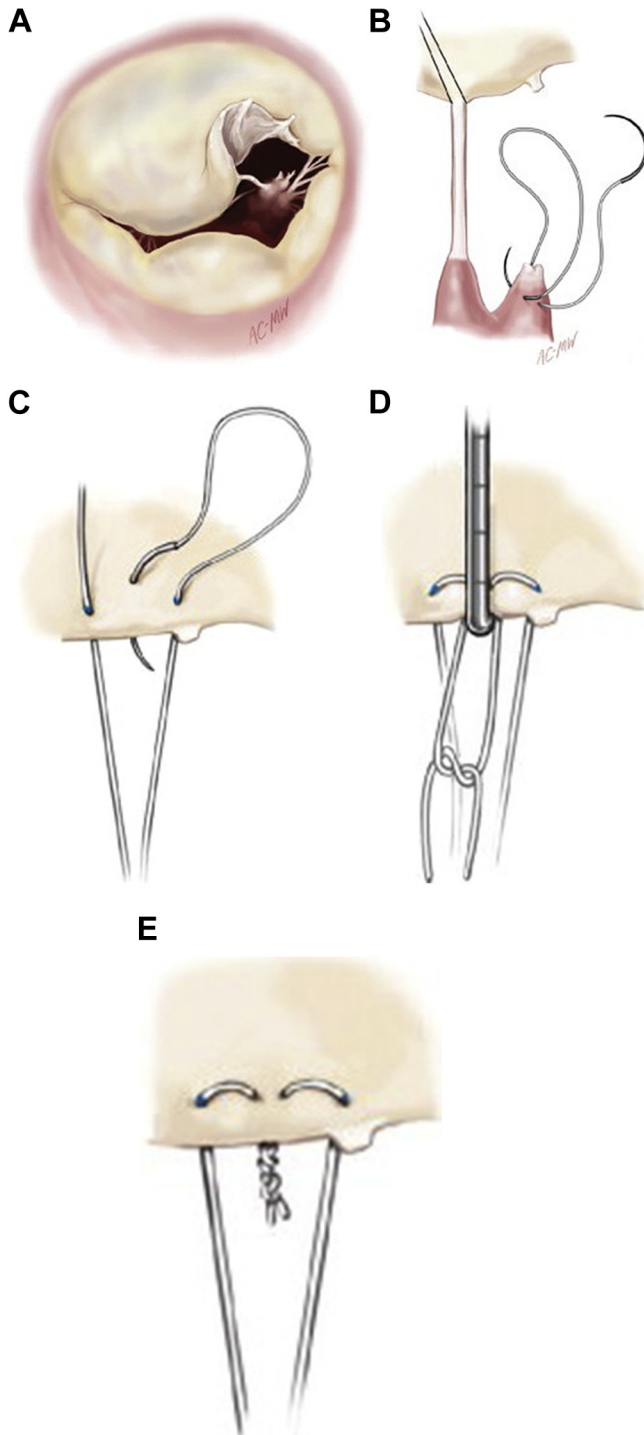


Fig. 17. Placement of artificial chordae to correct leaflet prolapse from chordal rupture. (A) Prolapsed anterior leaflet from ruptured chord. (B) A nonelongated chord is pulled taut for

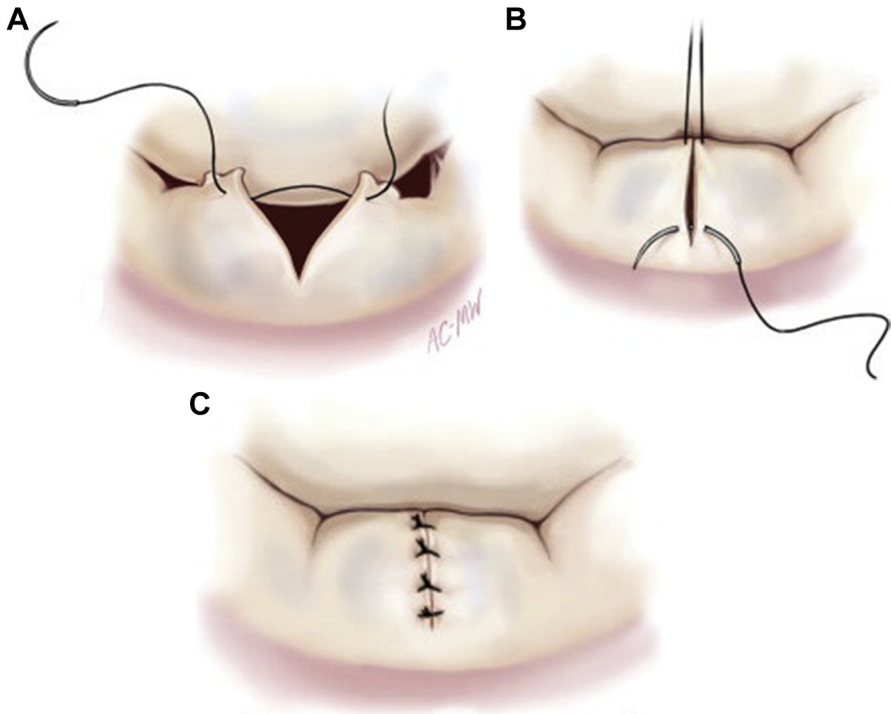


Fig. 18. Limited triangular resection of prolapsed posterior leaflet. (A) Triangular resection of prolapsed posterior leaflet. (B) Placement of interrupted sutures to reapproximate resected leaflet edges. (C) Completed triangular resection. (From Carpentier A, Adams DH, Filsoufi F. Techniques in type II posterior leaflet prolapse. In: Carpentier A, editor. Carpentier's reconstructive valve surgery: from valve analysis to valve reconstruction. Philadelphia: Elsevier Saunders; 2010. p. 116; with permission.)

This American correction has gained popularity over the past several years⁵⁴ as limited resection repair techniques continue to evolve.⁵⁵ Results demonstrate that these limited or nonresectional techniques perform at least as well as Carpentier's French correction. Freedom from reoperation and freedom from recurrent significant MR (as assessed by echocardiography) at 10 years have been reported at 90.1% and 93.9%, respectively. Additionally, studies have demonstrated almost no postoperative SAM when ventricular filling is optimized through adequate preload and afterload, there is atrioventricular synchrony, and hypercontractility is limited.⁵² Although this limited or nonresectional technique has only been cultivated over the past decade, it seems to be a reasonable and durable approach to repair of the mitral valve.

←
 reference, and a figure-of-eight suture is placed through the free papillary muscle head corresponding to the area of the ruptured chord. (C) The free ends of the suture are passed through to the ventricular side of the leaflet. (D) The first knot is tied while adjusting the length of the artificial chord to match that of the reference chord. (E) Completed artificial chordae. (From Carpentier A, Adams DH, Filsoufi F. Techniques in type II anterior leaflet prolapse. In: Carpentier A, editor. Carpentier's reconstructive valve surgery: from valve analysis to valve reconstruction. Philadelphia: Elsevier Saunders; 2010. p. 102; with permission.)

With the evidence supporting mitral valve repair over replacement for most degenerative mitral valve pathology, it is expected that these methods of valvular correction will continue to develop, given the wide variety of mitral valve pathology that exists. Carpentier was able to classify these various pathologies, thus providing a framework from which methods of mitral valve repair could develop in an organized and reproducible fashion. Relying on pathologic and autopsy specimens, the French correction aimed to restore normal valvular anatomy and has proven to be a durable method of repair. A purely anatomic correction, however, neglects the valve's functionality as an integral component of its competency. Furthermore, the technically demanding nature of Carpentier's techniques has remained an obstacle to widespread adoption of mitral valve repair techniques, leaving many patients who would have done well with a repaired mitral valve with a valve replacement.

With improved imaging capabilities and greater knowledge of the intricacies of mitral valve motion and function, the American correction was developed. This limited or nonresectional method of repair naturally follows the French correction as a consequence of innovation and reflects an evolution in the principles of mitral valve repair. Developed to first and foremost correct mitral valve function, these techniques may be somewhat technically less complex than Carpentier's methods, thus a greater number of surgeons will feel confident in repairing rather than replacing more mitral valves. These repair techniques will undoubtedly continue to evolve, ideally resulting in lower rates of recurrence and reoperation and better patient outcomes.

There are clearly many methods to repair a mitral valve, but the unifying principles include a comprehensive understanding of the valve pathology, correction of leaflet prolapse, and reduction of annular dilatation. Most importantly, one cannot leave the operating room with a leaky valve. If these essential principles are followed, a durable repair usually results.

REFERENCES

1. Goldstone AB, Woo YJ. Surgical treatment of the mitral valve in sabiston and spencer surgery of the chest. 9th edition. Philadelphia: Saunders; 2016.
2. Ling LH, Enriquez-Sarano M, Seward JB, et al. Clinical outcome of mitral regurgitation due to flail leaflet. *N Engl J Med* 1996;335(19):1417–23.
3. Enriquez-Sarano M, Avierinos JF, Messika-Zeitoun D, et al. Quantitative determinants of the outcome of asymptomatic mitral regurgitation. *N Engl J Med* 2005; 352(9):875–83.
4. Goldman ME, Mora F, Guarino T, et al. Mitral valvuloplasty is superior to valve replacement for preservation of left ventricular function: an intraoperative two-dimensional echocardiographic study. *J Am Coll Cardiol* 1987;10(3):568–75.
5. Gillinov AM, Blackstone EH, Nowicki ER, et al. Valve repair versus valve replacement for degenerative mitral valve disease. *J Thorac Cardiovasc Surg* 2008; 135(4):885–93, 893.e1-2.
6. Shuhaiber J, Anderson RJ. Meta-analysis of clinical outcomes following surgical mitral valve repair or replacement. *Eur J Cardiothorac Surg* 2007;31(2):267–75.
7. Vassileva CM, Mishkel G, McNeely C, et al. Long-term survival of patients undergoing mitral valve repair and replacement: a longitudinal analysis of Medicare fee-for-service beneficiaries. *Circulation* 2013;127(18):1870–6.
8. Zhou YX, Leobon B, Berthoumieu P, et al. Long-term outcomes following repair or replacement in degenerative mitral valve disease. *Thorac Cardiovasc Surg* 2010; 58(7):415–21.

9. Grossi EA, Goldberg JD, LaPietra A, et al. Ischemic mitral valve reconstruction and replacement: comparison of long-term survival and complications. *J Thorac Cardiovasc Surg* 2001;122(6):1107–24.
10. Zalaquett R, Scheu M, Campla C, et al. Long-term results of repair versus replacement for degenerative mitral valve regurgitation. *Rev Med Chil* 2005; 133(10):1139–46 [in Spanish].
11. Daneshmand MA, Milano CA, Rankin JS, et al. Mitral valve repair for degenerative disease: a 20-year experience. *Ann Thorac Surg* 2009;88(6):1828–37.
12. Gillinov AM, Wierup PN, Blackstone EH, et al. Is repair preferable to replacement for ischemic mitral regurgitation? *J Thorac Cardiovasc Surg* 2001;122(6): 1125–41.
13. Reece TB, Tribble CG, Ellman PI, et al. Mitral repair is superior to replacement when associated with coronary artery disease. *Ann Surg* 2004;239(5):671–5 [discussion: 675–7].
14. Magne J, Giererd N, Senechal M, et al. Mitral repair versus replacement for ischemic mitral regurgitation: comparison of short-term and long-term survival. *Circulation* 2009;120(11 Suppl):S104–11.
15. Al-Radi OO, Austin PC, Tu JV, et al. Mitral repair versus replacement for ischemic mitral regurgitation. *Ann Thorac Surg* 2005;79(4):1260–7 [discussion: 1260–7].
16. Nishimura RA, Otto CM, Bonow RO, et al. 2014 AHA/ACC guideline for the management of patients with valvular heart disease: executive summary: a report of the American College of Cardiology/American Heart Association Task Force on Practice Guidelines. *J Am Coll Cardiol* 2014;63(22):2438–88.
17. LaPar DJ, Kron IL. Should all ischemic mitral regurgitation be repaired? When should we replace? *Curr Opin Cardiol* 2011;26(2):113–7.
18. Davila JC, Glover RP. Circumferential suture of the mitral valve for the correction of regurgitation. *Am J Cardiol* 1958;2(3):267–75.
19. Lillehei CW, Gott VL, Dewall RA, et al. The surgical treatment of stenotic or regurgitant lesions of the mitral and aortic valves by direct vision utilizing a pump-oxygenator. *J Thorac Surg* 1958;35(2):154–91.
20. McGoon DC. Repair of mitral insufficiency due to ruptured chordae tendinae. *J Thorac Cardiovasc Surg* 1960;39:357–62.
21. Carpentier A. Reconstructive valvuloplasty. A new technique of mitral valvuloplasty. *Presse Med* 1969;77(7):251–3 [in French].
22. Carpentier A, Deloche A, Dauptain J, et al. A new reconstructive operation for correction of mitral and tricuspid insufficiency. *J Thorac Cardiovasc Surg* 1971; 61(1):1–13.
23. Carpentier A, Relland J, Deloche A, et al. Conservative management of the prolapsed mitral valve. *Ann Thorac Surg* 1978;26(4):294–302.
24. Carpentier A, Chauvaud S, Fabiani JN, et al. Reconstructive surgery of mitral valve incompetence: ten-year appraisal. *J Thorac Cardiovasc Surg* 1980;79(3): 338–48.
25. Carpentier A. Cardiac valve surgery: the “French correction”. *J Thorac Cardiovasc Surg* 1983;86(3):323–37.
26. Lawrie GM, Earle EA, Earle NR. Feasibility and intermediate term outcome of repair of prolapsing anterior mitral leaflets with artificial chordal replacement in 152 patients. *Ann Thorac Surg* 2006;81(3):849–56 [discussion: 856].
27. Lawrie GM, Earle EA, Earle NR. Nonresectional repair of the Barlow mitral valve: importance of dynamic annular evaluation. *Ann Thorac Surg* 2009;88(4):1191–6.
28. Spratt JA. Non-resectional repair of myxomatous mitral valve disease: the “American Correction”. *J Heart Valve Dis* 2011;20(4):407–14.

29. Lawrie GM. Structure, function, and dynamics of the mitral annulus: importance in mitral valve repair for myxomatous mitral valve disease. *Methodist Debaquey Cardiovasc J* 2010;6(1):8–14.
30. Carpentier A, Adams DH, Filsoufi F. *Surgical anatomy and physiology [of the mitral valve]*. Philadelphia: Saunders Elsevier; 2010.
31. Jouan J. Mitral valve repair over five decades. *Ann Cardiothorac Surg* 2015;4(4):322–34.
32. Carpentier AF, Lessana A, Relland JY, et al. The “physio-ring”: an advanced concept in mitral valve annuloplasty. *Ann Thorac Surg* 1995;60(5):1177–85 [discussion: 1185–76].
33. Gallerstein PE, Berger M, Rubenstein S, et al. Systolic anterior motion of the mitral valve and outflow obstruction after mitral valve reconstruction. *Chest* 1983;83(5):819–20.
34. Mihaileanu S, Marino JP, Chauvaud S, et al. Left ventricular outflow obstruction after mitral valve repair (Carpentier's technique). Proposed mechanisms of disease. *Circulation* 1988;78(3 Pt 2):178–84.
35. Lee KS, Stewart WJ, Lever HM, et al. Mechanism of outflow tract obstruction causing failed mitral valve repair. Anterior displacement of leaflet coaptation. *Circulation* 1993;88(5 Pt 2):1124–9.
36. Carpentier A, Adams DH, Filsoufi F. *Techniques in systolic anterior leaflet motion (SAM)*. Philadelphia: Elsevier; 2010.
37. Adams DH, Anyanwu AC, Rahmanian PB, et al. Large annuloplasty rings facilitate mitral valve repair in Barlow's disease. *Ann Thorac Surg* 2006;82(6):2096–100 [discussion: 2101].
38. Jebara VA, Mihaileanu S, Acar C, et al. Left ventricular outflow tract obstruction after mitral valve repair. Results of the sliding leaflet technique. *Circulation* 1993;88(5 Pt 2):1130–4.
39. David TE, Ivanov J, Armstrong S, et al. A comparison of outcomes of mitral valve repair for degenerative disease with posterior, anterior, and bileaflet prolapse. *J Thorac Cardiovasc Surg* 2005;130(5):1242–9.
40. Chang BC, Youn YN, Ha JW, et al. Long-term clinical results of mitral valvuloplasty using flexible and rigid rings: a prospective and randomized study. *J Thorac Cardiovasc Surg* 2007;133(4):995–1003.
41. Flameng W, Meuris B, Herijgers P, et al. Durability of mitral valve repair in Barlow disease versus fibroelastic deficiency. *J Thorac Cardiovasc Surg* 2008;135(2):274–82.
42. Chung CH, Kim JB, Choo SJ, et al. Long-term outcomes after mitral ring annuloplasty for degenerative mitral regurgitation: Duran ring versus Carpentier-Edwards ring. *J Heart Valve Dis* 2007;16(5):536–44 [discussion: 544–5].
43. Itoh A, Ennis DB, Bothe W, et al. Mitral annular hinge motion contribution to changes in mitral septal-lateral dimension and annular area. *J Thorac Cardiovasc Surg* 2009;138(5):1090–9.
44. Lansac E, Lim KH, Shomura Y, et al. Dynamic balance of the aortomitral junction. *J Thorac Cardiovasc Surg* 2002;123(5):911–8.
45. Kaplan SR, Bashein G, Sheehan FH, et al. Three-dimensional echocardiographic assessment of annular shape changes in the normal and regurgitant mitral valve. *Am Heart J* 2000;139(3):378–87.
46. Pini R, Devereux RB, Greppi B, et al. Comparison of mitral valve dimensions and motion in mitral valve prolapse with severe mitral regurgitation to uncomplicated mitral valve prolapse and to mitral regurgitation without mitral valve prolapse. *Am J Cardiol* 1988;62(4):257–63.

47. Nazari S, Carli F, Salvi S, et al. Patterns of systolic stress distribution on mitral valve anterior leaflet chordal apparatus. A structural mechanical theoretical analysis. *J Cardiovasc Surg (Torino)* 2000;41(2):193–202.
48. Salgo IS, Gorman JH 3rd, Gorman RC, et al. Effect of annular shape on leaflet curvature in reducing mitral leaflet stress. *Circulation* 2002;106(6):711–7.
49. Kunzelman KS, Reimink MS, Cochran RP. Annular dilatation increases stress in the mitral valve and delays coaptation: a finite element computer model. *Cardiovasc Surg* 1997;5(4):427–34.
50. Gillinov AM, Cosgrove DM, Blackstone EH, et al. Durability of mitral valve repair for degenerative disease. *J Thorac Cardiovasc Surg* 1998;116(5):734–43.
51. Ben Zekry S, Lang RM, Sugeng L, et al. Mitral annulus dynamics early after valve repair: preliminary observations of the effect of resectional versus non-resectional approaches. *J Am Soc Echocardiogr* 2011;24(11):1233–42.
52. Gazoni LM, Fedoruk LM, Kern JA, et al. A simplified approach to degenerative disease: triangular resections of the mitral valve. *Ann Thorac Surg* 2007;83(5):1658–64 [discussion: 1664–5].
53. Suri RM, Orszulak TA. Triangular resection for repair of mitral regurgitation due to degenerative disease. *Oper Tech Thorac Cardiovasc Surg* 2005;10(3):194–9.
54. Kshetry VR, Aranki SF. Current trends in mitral valve repair techniques in North America. *J Heart Valve Dis* 2012;21(6):690–5.
55. Woo YJ, MacArthur JW Jr. Simplified nonresectional leaflet remodeling mitral valve repair for degenerative mitral regurgitation. *J Thorac Cardiovasc Surg* 2012;143(3):749–53.