


Radiology of Periodontal Disease



Steven R. Singer, DDS
srs2@columbia.edu
212.305.5674

Periodontal Disease

- Includes several disorders of the periodontium
 - Gingivitis
 - Marginal Periodontitis
 - Localized Juvenile Periodontitis
- Bacterial plaque and inflammatory host response are essential for periodontal disease to occur



Periodontal Disease

- Factors that contribute to the severity of the disease include:
 - Poor oral hygiene
 - Diabetes
 - Smoking
- Disease process is episodic, with periods of exacerbation and remission
- The prevalence of periodontitis in the United States is approximately 23%

The Role of Radiology in Assessment of Periodontal Disease

- Both clinical and radiographic data are essential for diagnosing the presence and extent of periodontal disease.
- Clinical information includes:
 - Bleeding indices
 - Probing Depths
 - Edema
 - Erythema
 - Gingival Architecture



The Role of Radiology in Assessment of Periodontal Disease

- Radiographs are especially helpful in evaluation of the following points:
 - Amount of bone present
 - Condition of the alveolar crests
 - Bone loss in the furcation areas
 - Width of the PDL space
 - Local factors which can cause or intensify periodontal disease
 - Calculus
 - Poorly contoured or overhanging restorations
 - Caries

Adapted from White & Pharoah 5th ed. p315

The Role of Radiology in Assessment of Periodontal Disease

- Root length and morphology
- Crown to root ratio
- Anatomic issues:
 - Maxillary sinus
 - Missing, supernumerary and impacted teeth
 - Other pathoses
- Contributing factors
 - Caries
 - Apical inflammatory lesions
 - Root resorption

Adapted from White & Pharoah 5th ed. p315

Limitations of Radiographs

- Conventional radiographs provide a two dimensional image of complex, three dimensional anatomy. Due to superimposition, the details of the bony architecture may be lost
- Radiographs do not demonstrate incipient disease, as a minimum of 55-60% demineralization must occur before radiographic changes are apparent

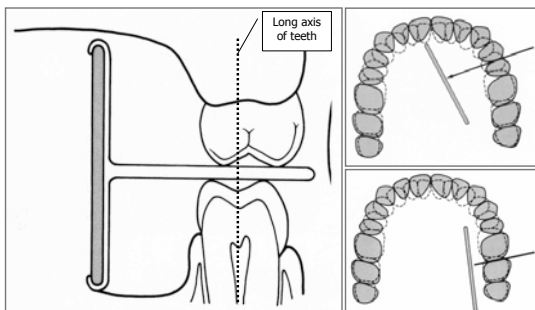
Limitations of Radiographs

- Radiographs do not reliably demonstrate soft tissue contours, and do not record changes in the soft tissues of the periodontium.
- Therefore, only a careful clinical examination, combined with a proper radiographic examination, can provide adequate data for diagnosing the presence and extent of periodontal disease. Since gingivitis is a lesion of soft tissue only, no radiographic changes will be seen.

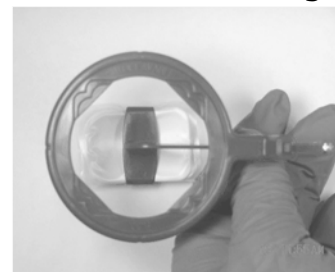
Radiographic Technique

- The optimal projections for periodontal diagnosis in the posterior teeth are bitewing radiographs
- If significant amounts of bone loss are suspected (based on clinically assessment including probing depths and gingival recession), vertical bitewing radiographs are indicated


XCP Bitewing Instrument – Premolar and Molar Views



XCP Bitewing Instrument – Horizontal Bitewings




XCP Bitewing Instrument -- Vertical Bitewings



- Same landmarks as horizontal (standard) bitewings

Radiation Physics



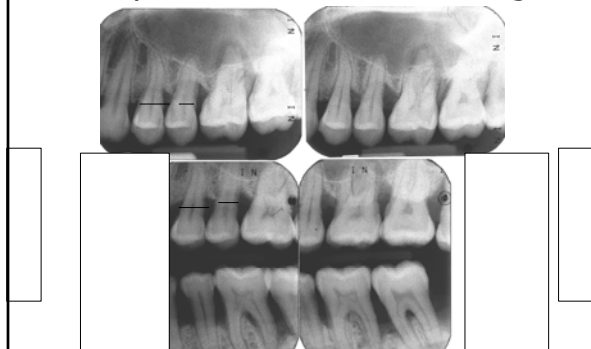Radiographic Technique

- In the anterior, anterior periapical projections, exposed using the paralleling technique, are adequate
- Anterior bitewing projections are also used for assessing periodontal disease

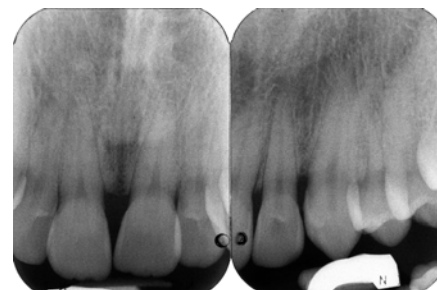
Radiographic Technique

- Posterior periapical projections tend to display somewhat foreshortened views of the maxillary molar teeth
- The foreshortening of the image tends to project the buccal plate of bone coronally.
- The resultant image displays greater bone height than actually exists

Periapicals and Vertical Bitewings



Radiographic Technique

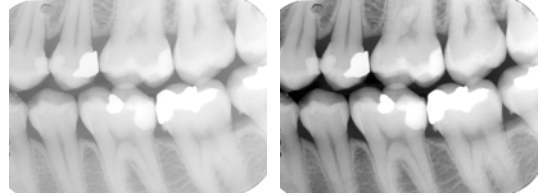


Anterior periapical projections

Radiographic Technique

- Exposure factors also play a role in increasing the diagnostic yield from the radiographs
- By using a higher kVp setting (90kVp), instead of the customary 70 kVp, and reducing the mAs, a radiograph with a wider gray scale will be produced.
- This allows subtle changes in bone density, as well as soft tissue outlines, to be discerned.

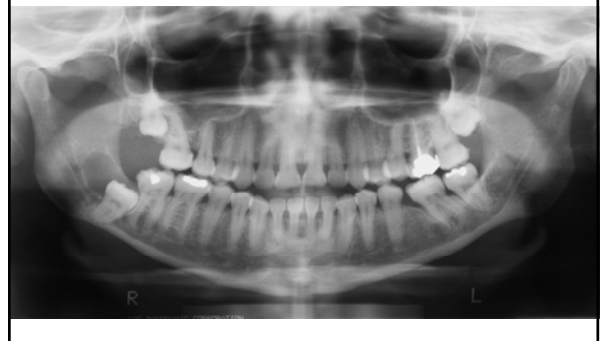Contrast



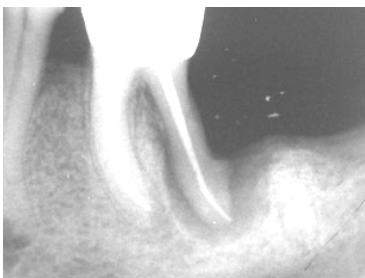
Radiographic Technique

- The x-ray beam must be perpendicular to the long axes of the teeth and the plane of the image receptor
- The image receptor must be parallel to the long axes of the teeth

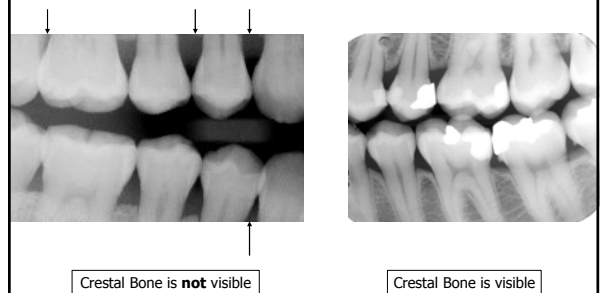
Panoramic Radiograph



Radiographic Technique



Bitewings





Normal Anatomy

- The bone height is within 2 millimeters of the cemento-enamel junction (CEJ)
- The crestal bone is a continuation of the lamina dura of the teeth, and is continuous from tooth to tooth
- Between the anterior teeth, the alveolar crest is pointed
- Between the posterior teeth, the lamina dura and the crestal bone form a box, with sharp angles

Normal Anatomy

- The periodontal ligament space varies along the length of the roots. It tends to be wider at the apex and alveolar crest, and narrower in the midroot areas.
- The joint between the tooth and alveolar bone is a gomphosis. The periodontal ligament allows movement around a center of rotation. The center of rotation is midroot. Therefore, the greatest movement will be at the apex and alveolar crest. As bone is lost, the center of rotation moves toward the apex

Normal Anatomy

Normal Anatomy

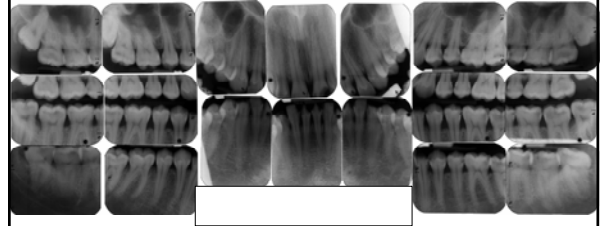
Radiographic Changes seen in Periodontal Disease

- Periodontal disease causes inflammatory lesions in the marginal bone
- Both osteoblastic and osteoclastic activity is seen
- Osteoclastic activity will cause changes in the morphology of the crestal bone
- Initial response is destruction of bone. Chronic lesions will show some osteosclerosis

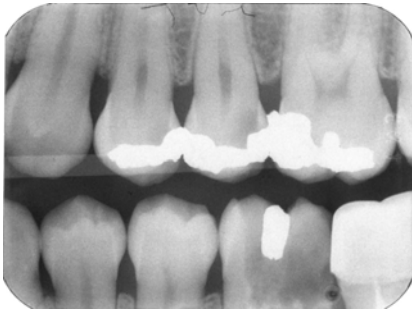
Mild Marginal Periodontitis

- Localized erosions of the marginal bone
- Thinning of crestal lamina dura
- Loss of sharp border with the lamina dura of the adjacent teeth
- Loss of spiking in the anterior
- Slight loss of bone height (<1/3)

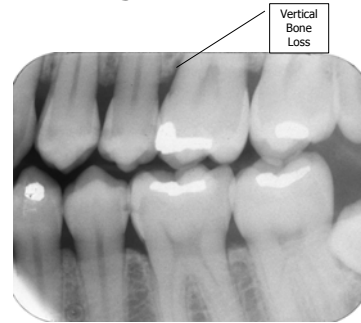
Mild Marginal Periodontitis



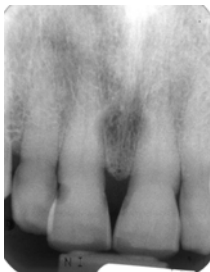Mild Marginal Periodontitis



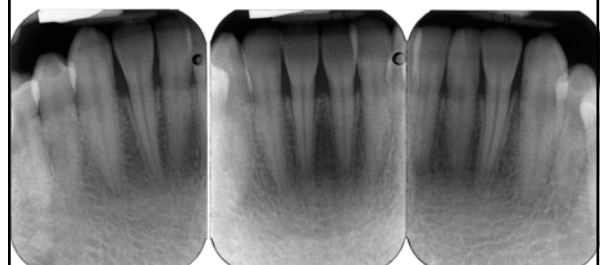
Mild Marginal Periodontitis



Mild Marginal Periodontitis



Mild Marginal Periodontitis



Moderate Marginal Periodontitis

- Generalized form demonstrates horizontal bone loss
- Localized defects include vertical bone loss and loss of buccal and lingual cortices
- Loss of buccal or lingual cortex is difficult to view radiographically. It may be seen as decreased density over the root surface

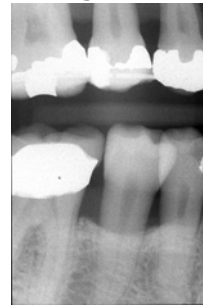Moderate Marginal Periodontitis

- Horizontal bone loss refers to the loss in height of the crestal bone around the teeth.
- Horizontal bone loss may be:
 - Mild
 - Moderate
 - Severe
- Crest remains generally horizontal

Moderate Marginal Periodontitis

- Bone loss seen on radiographs is an indicator of past disease activity
- Once periodontal treatment is initiated and the disease is in remission, bone levels will not increase.
- Therefore, clinical examination is necessary to determine the current disease status of the periodontium

Moderate Marginal Periodontitis

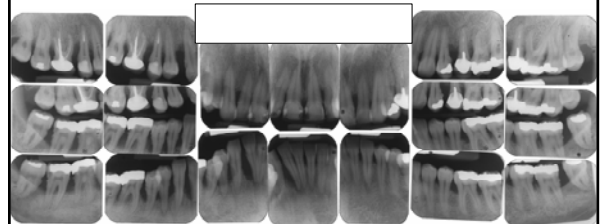


Moderate Horizontal Bone Loss

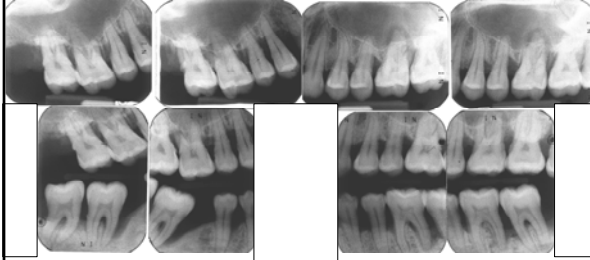
Severe Marginal Periodontitis

- Patient may have horizontal or vertical bone loss, or a combination of generalized horizontal bone loss with localized vertical defects
- Bone level is in the apical 1/3 of the root
- Clinically, the teeth may be shifting, tipping, or drifting
- Bone loss may be more extensive than is apparent on the radiographs

Moderate to Severe Marginal Periodontitis



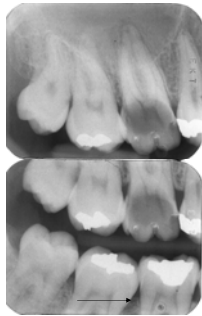
Severe Marginal Periodontitis



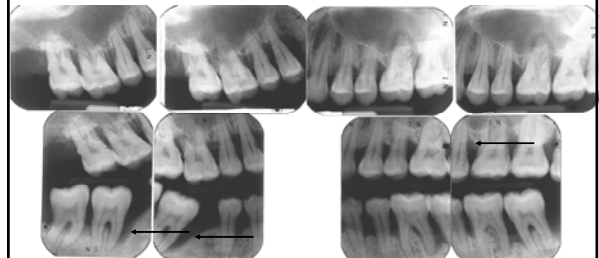
Vertical Bone Loss

- Usually localized to one or two teeth. May be several areas of vertical bone loss throughout the mouth
- Two general types:
 1. Interproximal crater
 1. Two walled defect
 2. Located between adjacent teeth
 2. Infrabony defect
 - Vertical Defect along root of tooth
 - Initial appearance is widened periodontal ligament space
 - May be one, two, or three walled, based on loss of the cortices

Mild Vertical Bone Loss



Severe Vertical Bone Loss



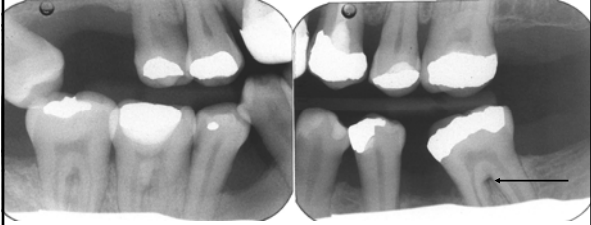Furcation Bone Loss

- Bone loss from periodontal disease may extend into the furcations of multirooted teeth (Molars and Premolars)
- Initially seen as widening of the periodontal ligament space at the crest of the furcation
- As lesion progresses, the bone loss progresses apically

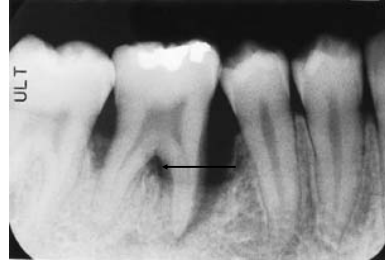Furcation Bone Loss

- May initiate from the buccal or lingual cortex
- Root anatomy may make radiographic detection of furcation bone loss difficult. Three rooted teeth, incorrect horizontal angulation of the radiograph, and overlying structures may interfere with detection

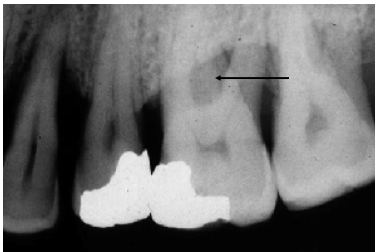Furcation Periodontitis



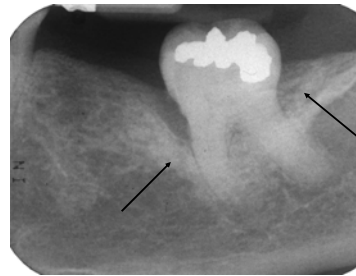
Furcation Periodontitis



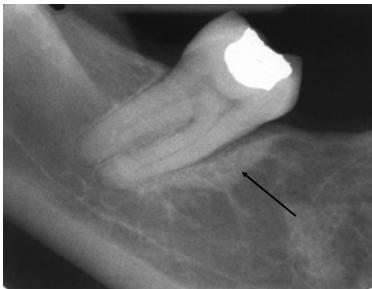
Furcation Periodontitis



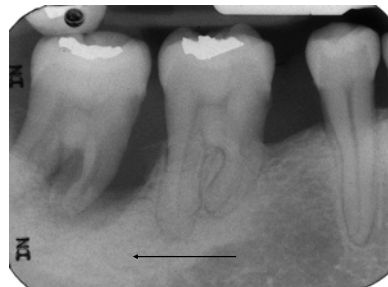
Condensing Periodontitis



Condensing Periodontitis



Condensing Periodontitis



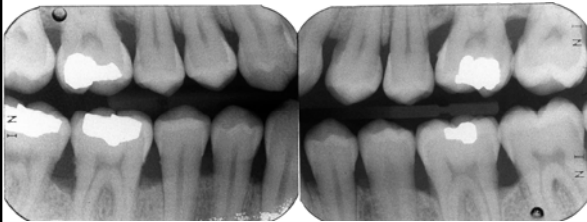
Aggressive Periodontitis

- Patients <30 years
- Exaggerated reaction to minimal plaque accumulation
- May result in early tooth loss
- Localized or generalized
- Localized form is also called Localized Juvenile Periodontitis (LJP)

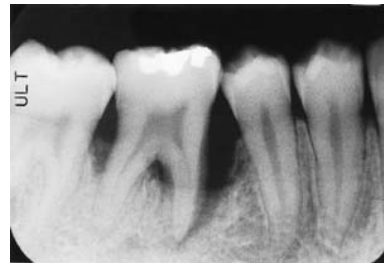Localized Juvenile Periodontitis

- Seen in second decade
- Primarily involves first molars and central incisors (teeth that erupt first)
- Rapid bone loss
- Minimal amounts of plaque
- Over time, other teeth are involved

Localized Juvenile Periodontitis



Localized Juvenile Periodontitis



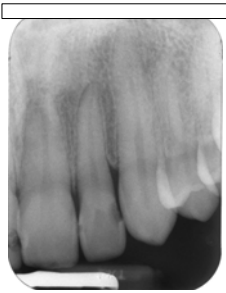Factors that contribute to periodontal disease

- Caries
- Open contacts
- Overhanging restorations
- Over or under contoured restorations
- Traumatic occlusion
- Calculus
- Malposed and crowded dentition

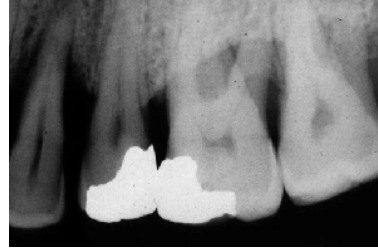Factors that contribute to periodontal disease

- Diabetes
 - May make patient more susceptible to periodontal disease
 - May increase the severity of the disease
 - Patients with diabetes tend to develop periodontal abscesses
- HIV Disease
 - Rapid progression of the disease
 - Poor response to therapy

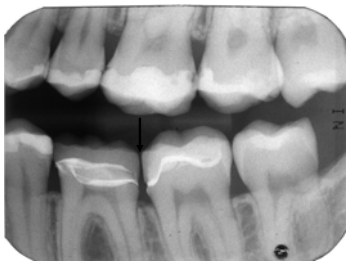
Caries



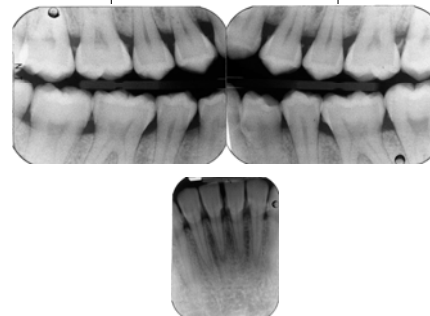
Overhanging Restorations



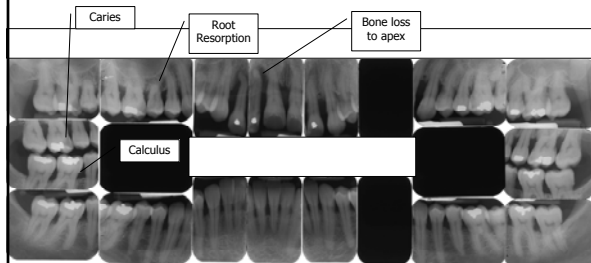
Open Contacts



Calculus



Moderate to Severe Marginal Periodontitis



Evaluation and Follow-up of Treatment

- It is generally appropriate to evaluate the outcome of care and the progress of disease by taking post-treatment radiographs
- Bitewing projections are usually optimal
- Interval is individually determined for each patient

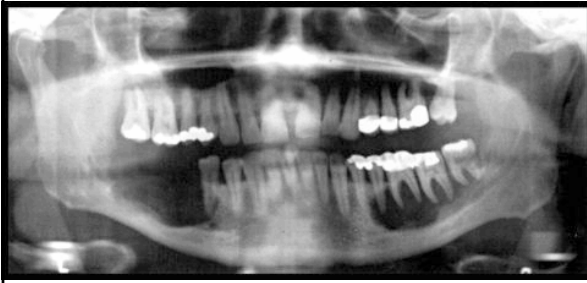Evaluation and Follow-up of Treatment

- Remission of periodontal disease can be radiographically demonstrated by the reformation of healthy architecture at the crest.
- Crestal lamina dura and sharp angles between the crestal lamina dura and the lamina dura of the adjacent teeth will reform

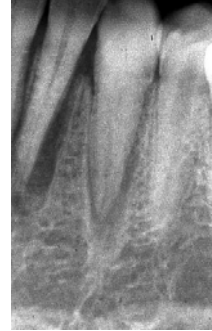Differential Diagnosis

- Langerhans Cell Disease
- Lymphomas and Leukemias
- Malignancies

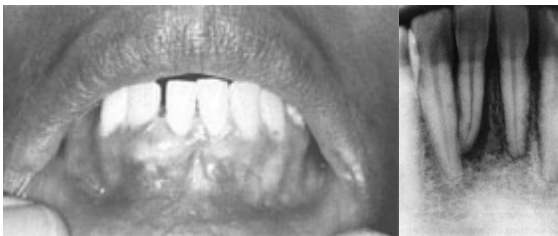Langerhans Cell Histiocytosis



Squamous Cell Carcinoma

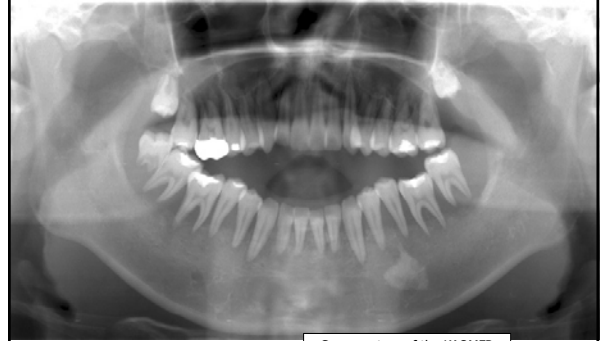

Chondrosarcoma



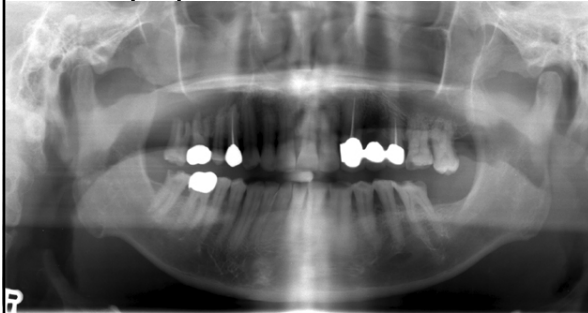
Images courtesy Marquette University School of Dentistry

Lymphoma v. Leukemia



Case courtesy of the KAOMFR

Lymphoma v. Leukemia



Case courtesy of the KAOMFR

Metastatic Lesions

