

Reiter's Syndrome

LT Joseph M. Schneider, MC, USNR; LCDR Jeanette H. Matthews, MC, USNR;
LCDR Bradley S. Graham, MC, USNR

Reiter's syndrome is a multisystem disease commonly triggered by a genitourinary infection or bacterial enteric infection. After a short latent period, ocular symptoms, oligoarthritis, and mucocutaneous involvement may occur. Classic cutaneous manifestations of Reiter's syndrome include keratoderma blennorrhagicum and balanitis circinata, both of which are microscopically similar to pustular psoriasis.

Case Report

A 22-year-old white man developed two small, moist, erythematous erosions on the corona of his glans penis. Over the next 4 weeks, the lesions became progressively larger, forming a thick-crust scale covering the glans penis. His medical history was significant for a diagnosis of non-gonococcal urethritis and bacterial conjunctivitis, both of which appeared 5 weeks earlier and were treated appropriately with antibiotics. One month prior to presentation, the patient had developed left knee synovitis diagnosed by arthroscopy. Review of systems was significant for persistent left heel pain, subjective fevers at night, general malaise, and a recent weight loss of 20 pounds. The patient denied back pain, headaches, blurry vision, palpitations, or diarrhea.

On physical examination, the patient was afebrile and had no inguinal adenopathy. On his glans penis, the patient had several thick-crust, yellowish-green, erythematous plaques, some arranged in a circinate configuration (Figure 1). The patient also had similar crusted plaques with erosions on

the distal shaft of his penis. The patient was circumcised. No additional skin lesions were noted, including on the nails and palmoplantar surfaces.

Laboratory tests included a blood cell count with differential and a complete metabolic panel, the results of which were within normal limits. Results of rapid plasma regain and human immunodeficiency virus enzyme-linked immunosorbent assay were negative. Urethral swabs were negative for gonococcus and chlamydia. An erythrocyte sedimentation rate was markedly elevated at 145 mm/h.

A punch biopsy specimen was obtained from the lesions on the glans penis for microscopic examination, which revealed marked parakeratosis with extensive neutrophilic infiltrates and large microabscesses forming a thick crust (Figure 2). There was irregular acanthosis of the epidermis with numerous spongiform pustules with confluence below the stratum corneum. In addition, spongiosis with exocytosis of neutrophils was present within the epidermis. The dermal infiltrate was mixed with numerous lymphocytes and neutrophils and scattered plasma cells. Regular acanthosis, clubbed rete ridges, and thinned suprapapillary plates were not identified. Results of a periodic acid-Schiff stain were negative for fungal elements.

Based on the clinical and microscopic findings, a diagnosis of Reiter's syndrome was made. The patient was subsequently found to be HLA-B27 positive. A complete eye examination by the ophthalmology department showed no signs of uveitis. The skin lesions were treated with desonide 0.05% cream, which resulted in significant thinning of the crusts and eventual resolution of the penile lesions.

Comment

Reiter's syndrome is a multisystem disease commonly triggered by a genitourinary infection, such as chlamydia, or a bacterial enteric infection caused by *Shigella*, *Campylobacter*, or *Salmonella*. It has been postulated that bacterial antigens persist within the synovium and other tissues, stimulating a proliferative T-cell response. This proliferative T-cell response eventually targets autoantigens, causing inflammation and tissue destruction. After a latent period of

Accepted for publication January 21, 2003.

Dr. Schneider is from Naval Hospital Camp Pendleton, San Diego, California. Dr. Matthews is from the Skin Surgery Center, Winston-Salem, North Carolina. Dr. Graham is in private practice in Tyler, Texas.

The opinions expressed are those of the authors and should not be construed as official or as representing those of the US Navy or the US Department of Defense.

Reprints: LCDR Jeanette H. Matthews, MC, USNR, Skin Surgery Center, 125 Sunnynoll Ct, Suite 100, Winston-Salem, NC 27106 (e-mail: jhmatthews@mac.com).

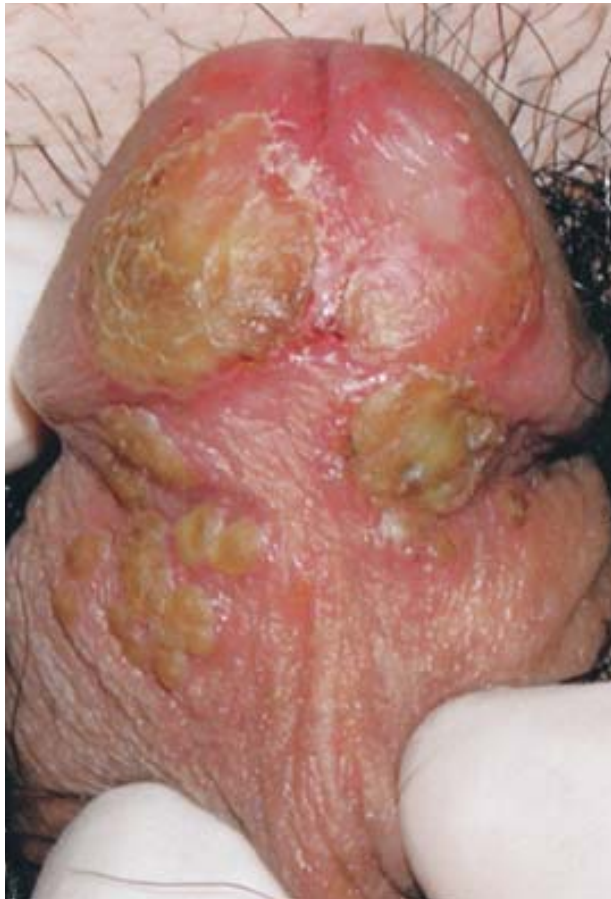

Figure 1. Thick-crusting plaques present on the glans penis.

one week to one month, ocular symptoms develop, such as sterile conjunctivitis or iritis, combined with oligoarthritis. The oligoarthritis is usually asymmetric and affects the lower extremities, including the knees or ankles. Enthesopathy, or inflammation of tendons at their insertions, especially the Achilles tendon, and dactylitis, or “sausage digits,” also may occur. Constitutional symptoms, such as fever and weight loss, are not uncommon during the acute phase of Reiter's syndrome.¹

Mucocutaneous involvement occurs in approximately 50% of patients with Reiter's syndrome.² It may occur before or after the onset of oligoarthritis. The two classic cutaneous manifestations of Reiter's syndrome are keratoderma blennorrhagicum and balanitis circinata, both of which are microscopically similar to pustular psoriasis. Keratoderma blennorrhagicum appears 1 to 2 months after the onset of arthritis and is present in about 10% of patients. It almost always involves the soles of the feet but may affect the legs, hands, nails, and scalp. Keratoderma blennorrhagicum typically begins as a red macule or vesicle and evolves into a

hyperkeratotic papule or plaque. The mature lesion appears as a crusted, hyperkeratotic plaque that grossly resembles psoriasis. Nail involvement is also common and may begin as painless red swelling along the nail fold followed by a thickening of the nail plate. Subungual pustules and onycholysis also may occur.^{3,4}

Balanitis circinata occurs in about 25% of men with Reiter's syndrome.⁵ In uncircumcised men, shallow, erythematous eroded plaques or ulcers may form on the glans penis. These lesions typically have well-defined borders and are often in a circinate configuration. In circumcised men, the erosions may develop into thick hyperkeratotic plaques and also may involve the penile shaft or scrotum. Similar lesions also may affect the vulva or vaginal mucosa in women. Oral involvement occurs in 15% to 30% of affected patients, appearing as transient, asymptomatic vesicles or ulcers on the soft palate, uvula, tongue, or buccal mucosa.⁶

Laboratory findings in patients with Reiter's syndrome are generally nonspecific and may include mild anemia, elevated erythrocyte sedimentation rate, and increased C-reactive protein. Synovial fluid analysis of the arthritic joints demonstrates a sterile inflammatory synovitis with 15,000 to 30,000 neutrophils/ μ L. Reiter's syndrome has been linked with HLA-B27 positivity, but evidence suggests this association may be related to more severe and chronic forms of the disease. HLA-B27 also may be more significantly associated with the spondyloarthropathic features of Reiter's syndrome, such as enthesitis or sacroiliitis.⁷ It is likely that multiple genetic, environmental, and infectious factors play a significant role in the predisposition and natural history of Reiter's syndrome.

Reiter's syndrome is most prevalent among Caucasians because of the higher incidence of HLA-B27 among that ethnic group. The sex ratio is approximately equal in the postdysenteric form but is greatly male-biased in the posturethritis form.⁸ Reiter's syndrome is the most common cause of inflammatory polyarthritis in young men. As many as 1% of all men with nonspecific urethritis may develop Reiter's syndrome.² The most frequent age of onset is in the early 20s, but Reiter's syndrome has been recognized from childhood into the sixth decade. Incidence of Reiter's syndrome varies greatly but has been estimated at about 3.5/100,000.⁹

Treatment for the joint symptoms of Reiter's syndrome includes nonsteroidal anti-inflammatory drugs, such as indomethacin, and intraarticular steroids. Adjunct therapies include rest, heel supports, and gentle non-weight-bearing exercises. The skin manifestations may be treated in a similar

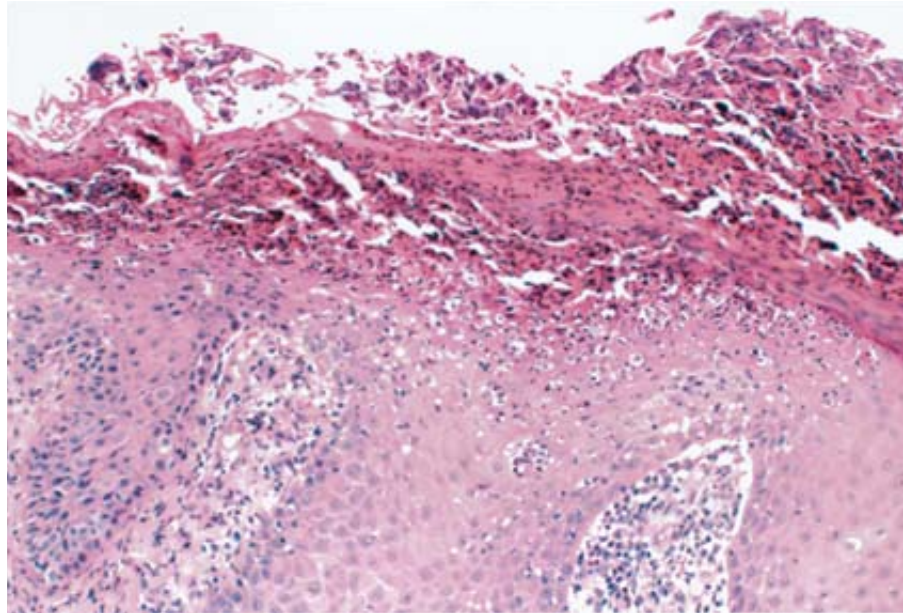


Figure 2. Parakeratosis and neutrophilic infiltrates forming a thick crust (H&E, original magnification $\times 40$).

fashion to psoriasis, using topical steroids, UVB phototherapy, coal tar, and etretinate.^{9,10} In persistent or severe disease, immunosuppressive agents such as azathioprine, sulfasalazine, methotrexate, or oral corticosteroids may be used.

The prognosis in Reiter's syndrome is variable but is less benign than previously thought. Most patients are symptom free within one year after the onset of disease. However, approximately 40% of patients have recurrent arthritis after the first year and 83% of patients have symptoms after 6 years.⁹ The most common recurring symptoms include arthritis, sacroiliitis, enthesopathy, and ocular symptoms.

We report this case because Reiter's syndrome often goes unrecognized and may result in significant morbidity. Reiter's syndrome should be considered if a patient has unusual plaques on the soles of the feet or penis and if the biopsy result is microscopically similar to pustular psoriasis. Additional history, including any history of conjunctivitis, arthritis, or urethritis, should be obtained.

REFERENCES

1. Winchester R. Reiter's syndrome. In: Freedberg IM, Eisen AZ, Wolff E, et al, eds. *Fitzpatrick's Dermatology in*

General Medicine. 5th ed. New York, NY: McGraw Hill; 1999:2085-2094.

2. Rothe MJ, Kerdel FA. Reiter's syndrome. *Int J Dermatol*. 1991;30:173-179.
3. Amor B. Reiter's syndrome diagnosis and clinical features. *Rheum Dis Clin North Am*. 1998;24:677-695.
4. Odom RB, James WD, Berger TG. *Andrews' Diseases of the Skin: Clinical Dermatology*. 9th ed. Philadelphia, Pa: WB Saunders; 2000:235-238.
5. Franks AG Jr. Psoriatic arthritis. In: Sontheimer RD, Provost TT, eds. *Cutaneous Manifestations of Rheumatic Diseases*. 1st ed. Baltimore, Md: Williams & Wilkins; 1996:236-241.
6. Huff R, Fretzin S, Lewis C. Penile erythematous eruption in a man with diabetes mellitus. *Arch Dermatol*. 1999;135:845, 848.
7. Sieper J, Kingsley G. Recent advances in the pathogenesis of reactive arthritis. *Immunol Today*. 1996;14:160-163.
8. Yunus M, Calabro JJ, Miller KA, et al. Family studies with HLA typing in Reiter's syndrome. *Am J Med*. 1981;70:1210-1214.
9. Kirchner, JT. Reiter's syndrome. A possibility in patients with reactive arthritis. *Postgrad Med*. 1995;97:111-112, 115-117, 121-122.
10. Barth WF, Segal K. Reactive arthritis (Reiter's syndrome). *Am Fam Physician*. 1999;60:499-503.