

## Calcinosis Universalis

Nasim Afsarmanesh, MD<sup>1</sup>

Alan Gorn, MD<sup>2</sup>

<sup>1</sup> Department of Internal Medicine, University of California Los Angeles, Los Angeles, California

<sup>2</sup> Department of Rheumatology, University of California Los Angeles, Los Angeles, California

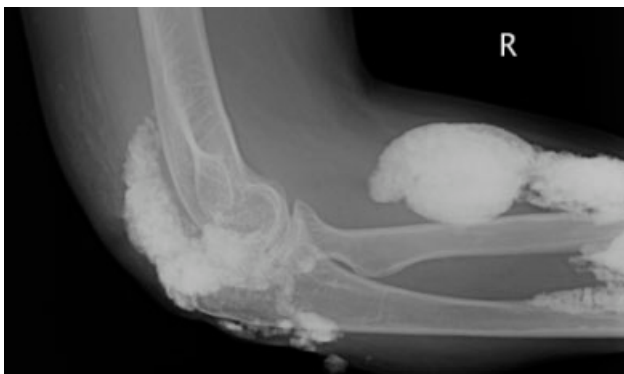
A 38-year-old woman with juvenile dermatomyositis (JDM) and calcinosis universalis presented with 3 days of drainage from a lesion on her right elbow. An examination of the elbow revealed diffuse and firm subcutaneous nodules with overlying erythema. X-rays illustrated soft-tissue calcifications in the forearm and elbow without evidence of osteomyelitis (Figure 1). Wound cultures grew *Staphylococcus aureus*, and the patient was started on intravenous antibiotics for abscess treatment.

Calcinosis universalis is soft-tissue calcification presenting as a complication of JDM. It is often detected in childhood in 30% to 70% of patients. It is hypothesized that calcinosis is due to chronic tissue inflammation, as seen in JDM, leading to muscle damage, releasing calcium, and inducing mineralization. Calcinosis universalis often presents as calcified nodules and plaques in areas of repeated trauma, such as joints, extremities, and buttocks (Figures 1–3). Calcification is localized in subcutaneous tissue, fascial planes, tendons, or intramuscular areas. It can cause

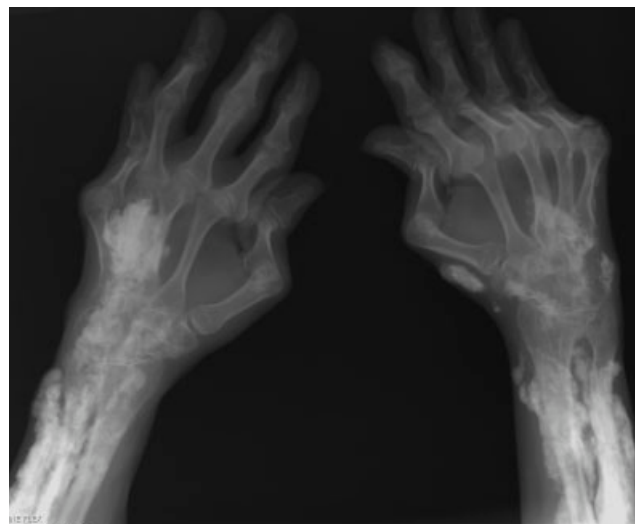
debilitating secondary complications such as skin ulcerations expressing calcified material, superimposed infections of skin lesions, joint contractures with severe arthralgias, and muscle atrophy. Calcinosis has been correlated with severity of JDM with presence of cardiac involvement and use of more than one immunosuppression medication.<sup>1</sup> It has also been associated with the degree of vasculopathy and delay in initiation of therapy for controlling inflammation in JDM.<sup>2</sup>

Soft-tissue calcification can be classified into 5 categories:

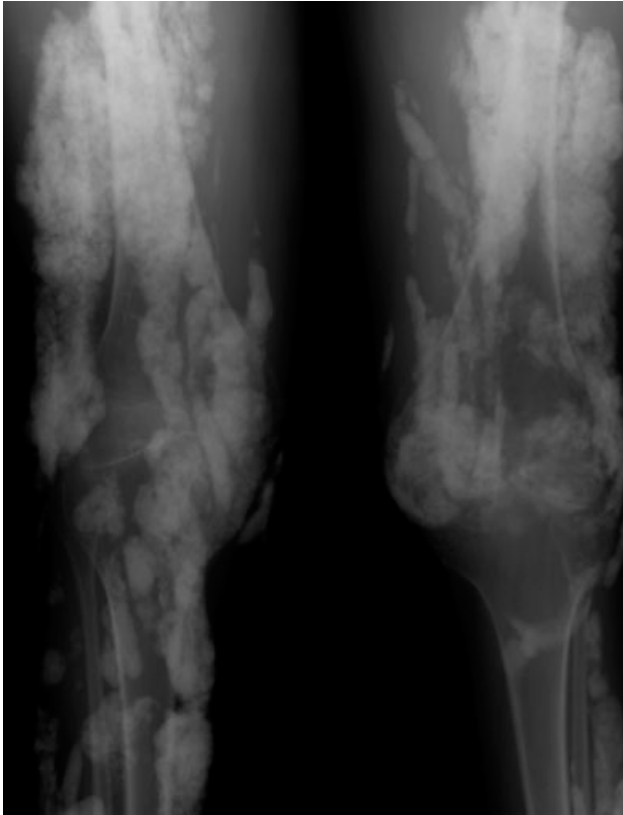1. Dystrophic calcification occurs in injured tissues with normal calcium, phosphorus, and parathyroid hormone levels, as seen in this patient. Calcified nodules or plaques occur in the extremities and buttocks. This is most often seen in JDM, scleroderma, and systemic lupus erythematosus.



**FIGURE 1.** X-ray of right elbow: soft-tissue calcification throughout the elbow and forearm.



**FIGURE 2.** X-ray of hands.



**FIGURE 3.** X-ray of legs.

2. Metastatic calcification affects normal tissues with abnormal levels of calcium and phosphorus. It is seen in large joints as well as arteries and visceral organs. It is associated with hyperparathyroidism, hypervitaminosis D, and malignancies.
3. Calciphylaxis with abnormal calcium and phosphorus metabolism causes small-vessel calcification in patients with chronic renal failure.
4. Tumoral calcification is a familial condition with normal calcium levels but elevated phosphorus levels. Large subcutaneous calcifications are seen near high-pressure areas and joints.
5. Idiopathic calcification is seen in healthy children and young adults with normal calcium metabo-

lism and appears as multiple subcutaneous calcifications.<sup>2</sup>

Although multiple therapeutic options have been tried for the management or prevention of calcinosis, there is currently no accepted standard of treatment. In patients with calcinosis, warfarin, probenecid, colchicine, bisphosphonates, minocycline, diltiazem, aluminum hydroxide, corticosteroids, and salicylate have been attempted with variable results. Other therapeutic options include carbon dioxide laser treatments and surgical excision of large plaques. Decreasing muscle inflammation with aggressive treatment of JDM may improve outcomes and decrease the incidence of calcification.<sup>3</sup> Unfortunately, once calcinosis has occurred, it is highly refractory to medical therapy.

Calcinosis universalis can lead to severe functional impairment. It can be distinguished from other types of calcinosis by diffuse involvement of muscle and fascia in connective tissue disease with normal calcium and phosphorus levels. New management modalities such as cyclosporine, intravenous immunoglobulin, and tumor necrosis factor alpha inhibitors are currently being evaluated.

Address for correspondence and reprint requests: Nasim Afsarmanesh, Department of Internal Medicine, University of California Los Angeles, 757 Westwood Plaza, Suite 7501, Los Angeles, CA 90095; Telephone: (310) 267-9643; E-mail: nafsarmanesh@mednet.ucla.edu

Received 31 January 2008; revision received 14 May 2008; accepted 26 May 2008.

## REFERENCES

1. Sallum AM, Pivato FC, Doria-Filho U, et al. Risk factors associated with calcinosis of juvenile dermatomyositis. *J Pediatr (Rio J)*. 2008;84(1):68-74.
2. Boulman N, Slobodin G, Rozenbaum M, Rosner I. Calcinosis in rheumatic diseases. *Semin Arthritis Rheum*. 2005; 34(6):805-812.
3. Fisler RE, Liang MG, Fuhlbrigge RC, et al. Aggressive management of juvenile dermatomyositis results in improved outcome and decreased incidence of calcinosis. *J Am Acad Dermatol*. 2002;47(4):505-511.