

Submitted on: 04/03/2018  
Approved on: 06/08/2018

INTERACTIVE CASE

## Unilateral hyperlucent lung - What is the diagnosis?

Thamiris Pessoa<sup>1</sup>, Valeska Pieve<sup>2</sup>, Izabel Cristina Drummond<sup>1</sup>, Rafaela Baroni Aurilio<sup>3</sup>, Cláudia Renata Penna<sup>4</sup>  
Coordinators: Sandra Mara Amaral<sup>5</sup>, Patrícia Fernandes Barreto Costa<sup>6</sup>

A previously healthy 2-year-old Caucasian female patient ALCS living in an urban area of Rio de Janeiro (Rocinha favela) visited the IPPMG pediatric outpatient clinic in April 2017; she had a 2-week history of productive cough and coryza, with improvement after 10-day use of amoxicillin. The patient did not present fever, weight loss, or other symptoms. She reportedly came into contact with pulmonary tuberculosis (PTB) through her 18-year-old brother who had finished treatment during the week of the consultation. The also submitted the result of the tuberculin test performed during diagnosis of the index case (2 mm).

Physical examination was unremarkable, except for respiratory auscultation with a slight reduction of vesicular murmur in the left hemithorax. The patient's weight was 12 kg.

Plain chest X-ray Figures 1 and 2.

1. Plain chest X-ray shows which of the following?

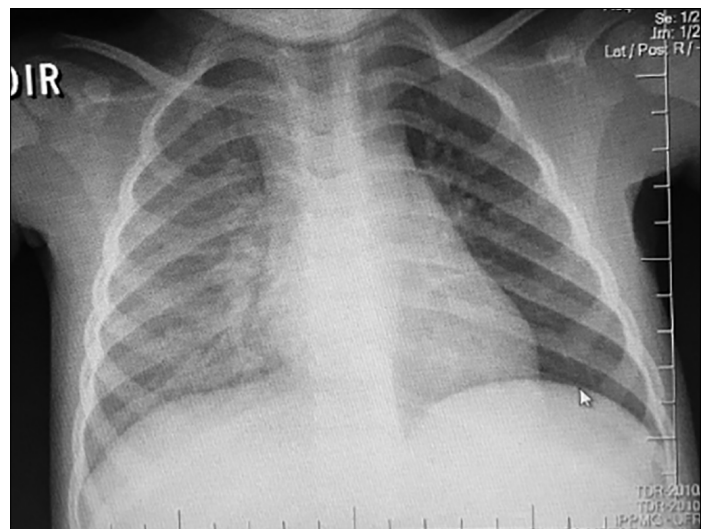


Figure 1. Chest X-rays: inspiration phase.

<sup>1</sup> Resident of the Pediatric Pulmonology Service of the Martagão Gesteira Institute of Childcare and Pediatrics (Instituto de Puericultura e Pediatria Martagão Gesteira-IPPMG).

<sup>2</sup> Specialist of the Pediatric Pulmonology Service of IPPMG.

<sup>3</sup> MD of the Pediatric Pulmonology Service of IPPMG.

<sup>4</sup> Radiologist responsible for the Pediatric Radiology Service of IPPMG.

<sup>5</sup> Retired pediatrician. Public Service Hospital of Rio de Janeiro, Rio de Janeiro, RJ, Brazil.

<sup>6</sup> Professor of Pediatric Pulmonology, Federal University of the State of Rio de Janeiro (UNIRIO). Physician, Department of Pediatric Pulmonology, Fernandes Figueira Institute/FIOCRUZ, Rio de Janeiro, RJ, Brazil

### Correspondence to:

Patrícia Barreto Costa.

IFF. Av. Rui Barbosa, nº 716, Flamengo. Rio de Janeiro, RJ, Brazil. CEP: 22250-020. E-mail: pfbcosta@gmail.com

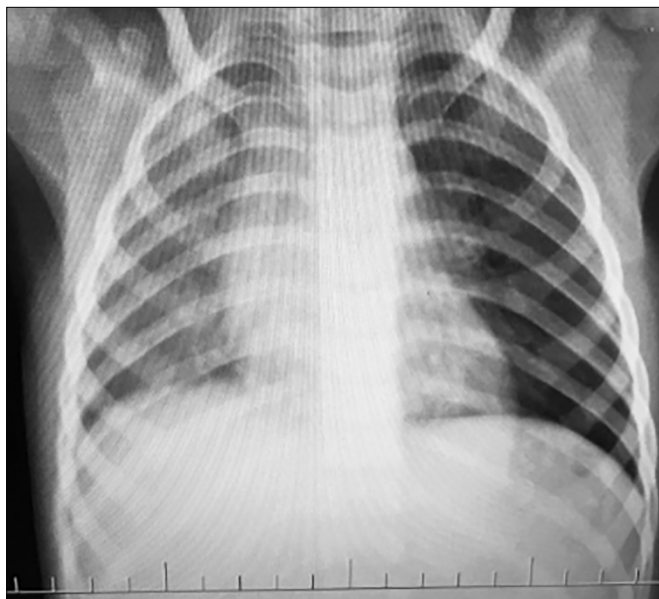


Figure 2. Chest X-rays: expiration phase.

- a) Reduced volume of the right lung
- b) Increased volume and reduced vascular network of the left lung
- c) Heterogeneous hypolucency in the right lung
- d) Normal chest radiograph
- e) Reduced volume of the left lung

Answer: B. Chest X-ray shows hyperlucent left lung with reduced vascular network and increased ipsilateral volume Figures 1.

2. Which complementary examination is indicated to confirm the previous diagnosis?

- a) Chest X-ray in maximum expiration
- b) Contrast-enhanced computed tomography of the chest
- c) Bronchoscopy
- d) Magnetic resonance imaging of the chest
- e) Angiotomography of the chest

Answer: A. Chest X-ray during maximum expiration showing an increase in the left lung volume, confirming air trapping in the left lung Figures 2.

3. What is the main diagnostic hypothesis based on the radiological findings?

- a) Agenesis of the right lung
- b) Bronchial atresia of the left upper lobe
- c) Obstructive hyperinflation in the left lung
- d) Swyer-James-MacLeod syndrome

e) Congenital lobar emphysema of the left lung

Answer: C

4. Which imaging examination is recommended considering the hypothesis of obstructive hyperinflation in the right hemithorax and epidemiological history?

- a) Contrast-enhanced computed tomography of the chest
- b) Angioresonance of the chest
- c) Ultrasound of the chest
- d) Magnetic resonance imaging of the chest
- e) Angiotomography of the chest

A computed tomography (CT) of the chest and new tuberculin skin test were requested, and the patient submitted these examination results three months after the request. Approximately 14 days before this visit, the patient's mother reported the onset of right cervical lymphadenopathy (approximate size, 4 × 4 cm) that was mobile, painless, of fibroelastic consistency, and without phlogosis (TST result = 20 mm). CT (obtained in May 2017) showed lymphadenopathy without contrast enhancement and calcification foci in subcarinal and hilar bilateral topography, predominant in the left lung. Lung parenchyma had no evidence of lesions Figures 3 a-d.

5. Which procedure is recommended considering the onset of cervical lymphadenopathy and the clinical and epidemiological history?

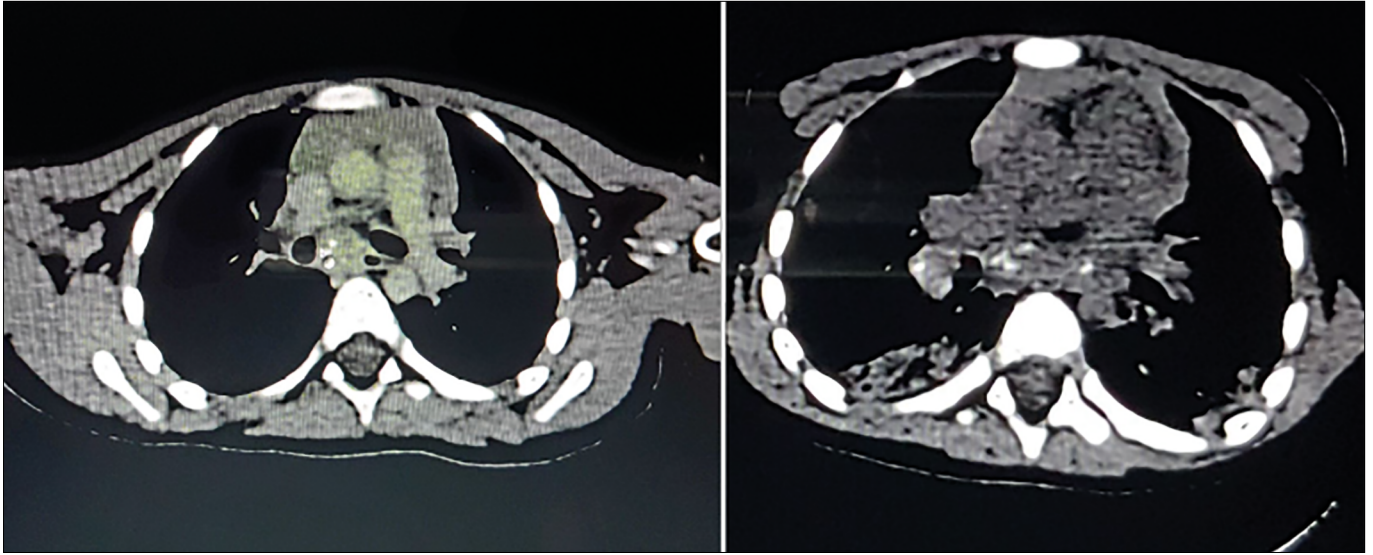
- a) Cervical ultrasound
- b) Lymph node biopsy
- c) No further examinations; perform clinical follow-up
- d) No further examinations; initiate antibiotic therapy for adenitis
- e) Initiate tuberculosis treatment with basic regimen

Cervical ultrasound was requested that showed evidence of bilateral cervical adenomegaly associated with the calcification foci Figuras4a-d.

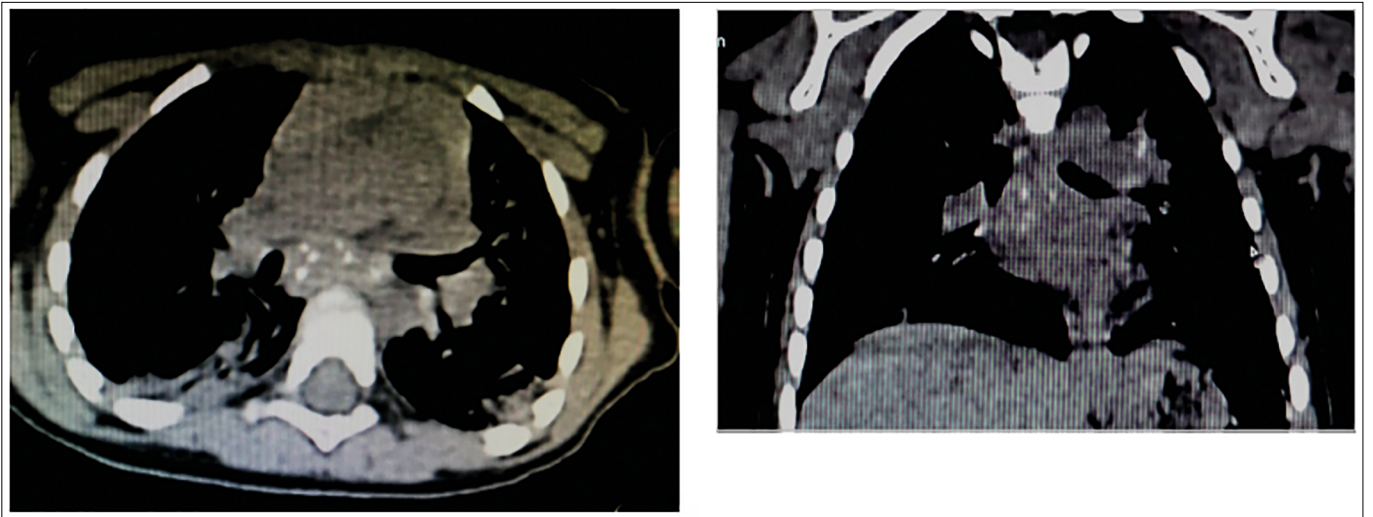
Tuberculosis (TB) treatment was initiated with basic regimen, resulting in regression of the cervical lesion after the second month, satisfactory weight gain, and normalization of the chest X-ray at the end of the treatment.

### Question 1

Unilateral hyperlucent hemithorax is characterized by the higher transparency of one hemithorax compared with the other due to increased transmission of X-ray.<sup>1</sup> Eliminating technical factors as causes of hyperlucency is essential to avoid further unnecessary investigation.<sup>1</sup>



Figures 3. a and 3b - contrast- enhanced CT.



Figures 3. c and 3d - Contrast-enhanced TC.

Patient rotation is the most common cause of hyperlucency and is observed in 1% of chest radiographs.<sup>1</sup>

When the lungs show distinct hyperlucency, it is important to determine whether the hyperlucency is real or whether there is opacity in the contralateral lung.<sup>2</sup> Two factors must be considered in the analysis of a hyperlucent hemithorax: vascular volume and vascular network.<sup>2</sup>

Unilateral hyperlucency may be caused by certain changes:

In the thoracic wall: Poland syndrome (agenesis of the pectoral muscle).

In the lung parenchyma: bronchial atresia, congenital lobar emphysema, cystic adenomatoid malformation,

pneumothorax, and Swyer-James-MacLeod syndrome after pneumectomy.

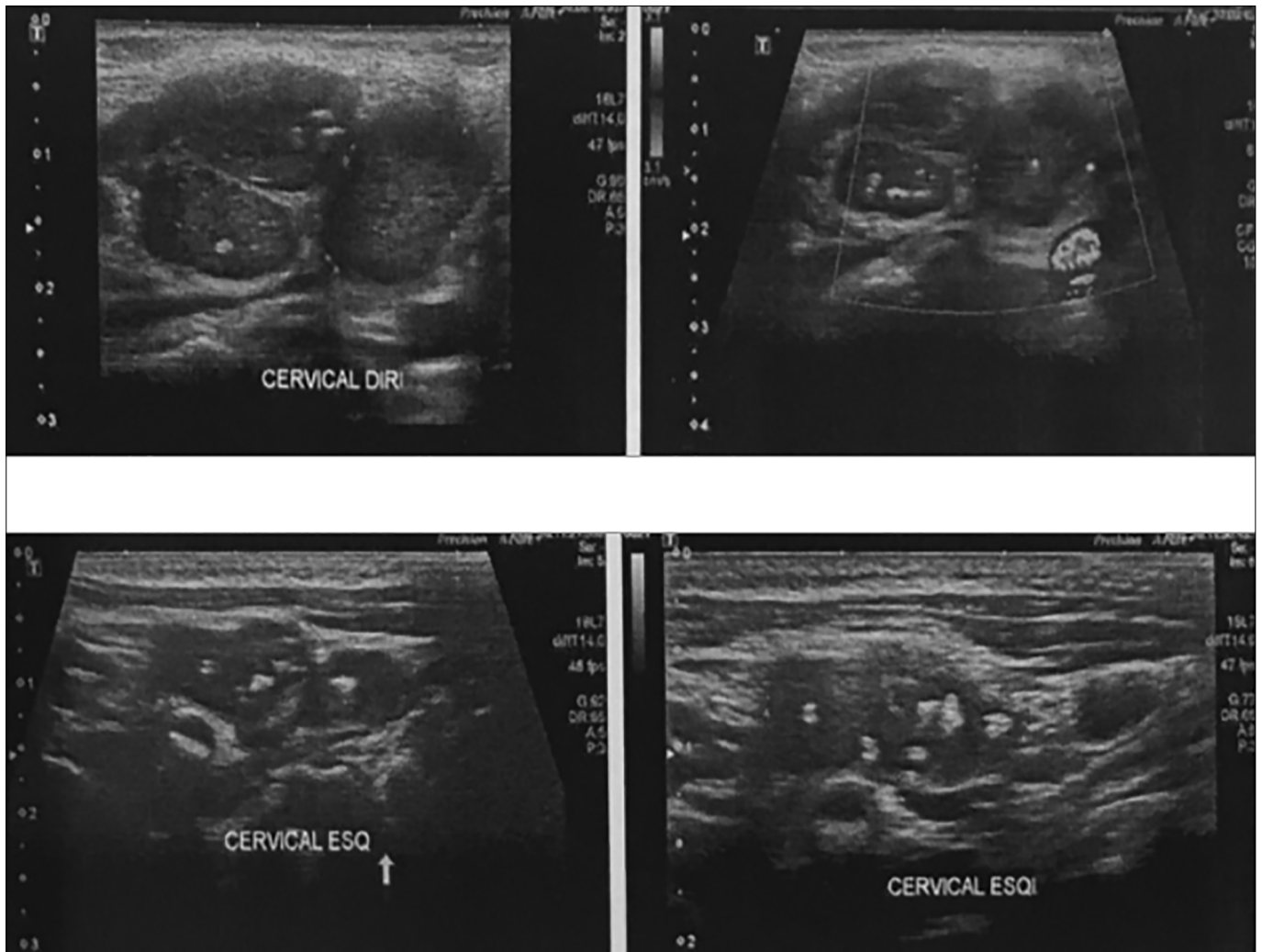
In the vasculature: pulmonary agenesis, proximal interruption of the pulmonary artery, pulmonary artery sling, and scimitar syndrome.

In airways: foreign body and endobronchial tumors.

In the mediastinum: malformations of the primitive gastrointestinal tract and lymphadenopathy.<sup>3</sup>

### Question 2

Chest X-ray in maximum expiration is the first examination to be performed when a hyperlucent area is observed. During inspiration, the lungs may appear normal;



Figures 4. a-d - Cervical US - cervical lymph gland enlargement with calcifications inside.

however, during forced expiration, hyperlucent lung does not deflate in the presence of an obstruction. Lateral decubitus is used in non-collaborative children.

Vasculature is examined to distinguish between compensatory and obstructive hyperinflation. The vascular network is reduced in cases of obstructive hyperinflation.<sup>4</sup>

### Question 3

Hyperinflation is obstructive because the increased volume of an affected (left) lung is maintained during expiration, and the cause may be intrinsic or extrinsic. In our case, compression was extrinsic owing to adenomegaly.

Pulmonary agenesis presents with asymmetric aeration of the lungs and opacity of the affected hemithorax on chest radiography. Moreover, there is a mediastinal deviation to the affected side, elevation of the diaphragmatic dome, and reduction of ipsilateral intercostal spaces.<sup>3</sup>

On radiography, bronchial atresia has an oval opacity on hilar topography (representing a bronchocele) associated with an adjacent area of hyperlucent lung.<sup>3</sup>

On chest X-ray, Swyer-James-MacLeod syndrome is characterized by a unilateral hyperlucent lung or lobe associated with a reduction of the vascular network and normal or reduced volume.<sup>3</sup>

Congenital lobar emphysema involves an asymmetric hyperlucency of the affected lobe that occurs after an initial lobar opacity related to fetal fluid retention after birth.<sup>3</sup>

### Question 4

CT is the examination of choice to identify hilar and mediastinal lymphadenopathy. In suspected TB, contrast-enhanced CT should be performed because in tuberculous lymphadenomegaly, the ganglia presents a hypodense center, representing caseous necrosis, surrounded by a contrast uptaking wall resulting from granulomatous inflammation. This finding is highly suggestive of TB, although it is not pathognomonic. Further, CT may identify calcifications, parenchymal and pleural alterations, and airway compression with air entrapment.<sup>5</sup>

Although CT is an informative and complementary examination used in cases of suspected thoracic TB, the diagnosis of PTB in childhood and adolescence (in cases without bacteriological confirmation) is primarily confirmed by the Health Ministry scoring system using the sum of clinical, epidemiological, radiological, and tuberculin skin test TST result. The diagnosis of PT should be considered very probable when the sum is  $\geq 40$  points, possible when 30–35 points, and unlikely when  $< 25$  points. Investigations should be further performed when the score is  $< 30$ . In this case, the differential diagnosis should be made with other pulmonary diseases. When pertinent and according to the availability of the services, complementary diagnostic methods may be used, including gastric lavage, bronchoscopy, induced sputum, punctures, and rapid tests.<sup>6</sup>

Mediastinal lymphadenopathy has many causes in children, but the two most common causes are tumors and infections. Lymphoma is the tumor most commonly associated with bronchial compression and unilateral hyperlucency. The infections that cause bronchial compression, characterized by unilateral hyperlucent lung, are fungal and mycobacterial infections in most cases.<sup>3</sup>

### Question 5

Extrapulmonary manifestations of childhood TB occur in approximately 25% of all TB cases, and the most common sites include peripheral ganglia, pleura, bones, and meninges.<sup>6,7</sup>

Ultrasound is the imaging method of choice to diagnose diseases affecting superficial tissues and organs, including lymph nodes.<sup>8</sup>

Excisional biopsy with histopathological examination and sample culture is the standard examination to confirm the diagnosis of tuberculous lymphadenitis. Another possible approach is thin-needle puncture, which is a safe, less invasive, and less costly method.<sup>9</sup>

In addition to histopathological analysis and culture, detection of acid/alcohol-resistant bacilli and the rapid molecular test may be used to analyze the lymph node affected by *Mycobacterium tuberculosis*. The latter test is based on DNA

amplification by real-time PCR using the Gene Xpert platform and facilitates combining three processes: sample preparation, amplification of *M. tuberculosis* DNA, and its detection. This technique does not require manipulation of mycobacterial DNA after amplification, thus reduces the complexity of the procedure and risk of cross-reactivity.<sup>10</sup> Moreover, this technique facilitates identifying *M. tuberculosis* in the laboratory within 2 hours and detecting bacterial resistance to rifampicin by PCR amplification of five overlapping probes complementary to the 81-bp region of the *rpoB* gene of *M. tuberculosis* involved in rifampicin resistance. This region is subsequently examined to identify mutations associated with rifampicin resistance.<sup>11</sup>

### REFERENCES

1. Saxena AK, Mittal V, Sodhi KS. Differential diagnosis of unilateral hyperlucent lung in children. *AJR Am J Roentgenol.* 2013;200(1):W95.
2. Dillman JR, Sanchez R, Ladino-Torres MF, Yarram SG, Strouse PJ, Lucaya J. Expanding upon the unilateral hyperlucent hemithorax in children. *RadioGraphics.* 2011;31(3):723–41.
3. Wasilewska E, Lee EY, Eisenberg R. Unilateral hyperlucent lung in children. *AJR Am J Roentgenol.* 2012;198(5):W400–14.
4. Altinsoy B, Altintas N. Diagnostic approach to unilateral hyperlucent lung. *JRSM Short Rep.* 2011;2(12):95.
5. Skouras E, Zumla A, Bomanji J. Imaging in tuberculosis. *Int J Infect Dis.* 2015;32:87–93.
6. Brasil. Ministério da Saúde. Manual de recomendações para o controle da tuberculose no Brasil. Brasília: Ministério da Saúde; 2011.
7. Sant'Anna CC, Loboguerrero MA. Tuberculose em Crianças e Jovens. 1ª ed. São Paulo: Atheneu; 2014.
8. Białek EJ, Jakubowski W. Mistakes in ultrasound diagnosis of superficial lymph nodes. *J Ultrason* 2017;17(68):59–65.
9. Dash SB, Das U, Rout N, Panda S. Extrapulmonary Tuberculosis of Lymph Node Coexist with Diffuse Large B-cell Lymphoma: A Case Report. *Indian J Med Paediatr Oncol.* 2017;38(3):391–3.
10. Nicol MP, Whitelaw A, Wendy S. Using Xpert MTB/RIF. *Curr Respir Med Rev.* 2013;9:187–92.
11. Brasil. Ministério da Saúde. Secretaria de Vigilância em Saúde. Perspectivas brasileiras para o fim da tuberculose como problema de saúde pública. *Bol Epidemiol.* 2016;47(13):1–15.