



Submitted on: 04/02/2018
Approved on: 06/28/2018

ORIGINAL ARTICLE

Hypotony in children

Regina Célia Beltrão Duarte¹

Keywords:

Muscle Hypotonia,
Child,
Muscle Tonus.

Abstract

Hypotonia in infants is a symptom of many systemic diseases or diseases of the nervous system (brain, anterior horn cell, peripheral nerve, neuromuscular junction, and muscle). Floppy infant syndrome refers to an infant with generalized hypotonia present at birth or in early life. Because of the multiple causes and clinical conditions in hypotonia, a systematic assessment is essential in the approach to the floppy infant. Treatment of an infant with hypotonia must be tailored to the specific condition causing it. In general, treatment is supportive, with the participation of several professionals.

¹ PhD in Neuroscience; MSc in Neuroscience from the Federal University of Pará (UFPA), Brazil. Assistant Professor of Neurology at UFPA. Pediatric neurologist at UFPA and Ofir Loyola Hospital. Professor of the Pará University Center (CESUPA) Medicine program. President of the Pará chapter of the Brazilian Association of Pediatric Neurology, Psychiatry and Related Professions (ABENEPI). Member of the Brazilian Society of Psychiatry (SBP) scientific department of Neurology. Full member of the Brazilian Academy of Neurology and a member of the Brazilian Society of Pediatric Neurology (SBNI) and the Brazilian League for Epilepsy (LBE).

Correspondence to:

Regina Celia Beltrão Duarte.
UFPA. Av. Nazaré, nº 491, Apto 1501, Belém, PA, Brasil. CEP: 66035-170. E-mail: rcbduarte@yahoo.com.br

INTRODUCTION

The term “hypotonia” refers to a decrease in muscle tone and is considered, in most cases, a symptom of neurological dysfunction¹.

Muscle tone is a constant state of tension within resting muscles. It is the amount of resistance to movement in a muscle. There are two types of muscle tone: phasic or action tone, characterized by rapid contraction and involving appendicular structures, and postural tone, resulting from prolonged contraction. Gravity keeps antigravity muscles in constant stretching, involving the muscles of the neck, torso, and back (axial muscles)².

When postural tone is decreased, children have difficulty sustaining their own bodies and limbs against gravity, resulting in hypotonia².

Maintaining muscle tone depends on the integrity of the central nervous system (CNS) and peripheral nervous system, making hypotonia a common symptom of neurological disorders involving the brain, brain stem, spinal cord, peripheral nerves, and muscles³.

Because several structures are involved, hypotonia is divided into two groups⁴:

1) Primary hypotonia: related to the involvement of structures composing the motor unit (anterior horn cell, nerve roots, peripheral nerves, and muscles)

2) Secondary hypotonia: resulting from CNS injuries, genetic disorders, systemic diseases, or conditions affecting tendons and ligaments

According to Dubowitz’s description of the floppy infant syndrome, there are two major groups of hypotonia with different clinical manifestations that help in the differential diagnosis of primary hypotonia (paralytic group) from secondary hypotonia (nonparalytic group)⁵.

The clinical manifestations are listed in Chart 1.

Etiology of hypotonia: central or peripheral⁶⁻⁸

The “floppy infant” presents a variable clinical picture, with multiple etiologies grouped into central causes, which account for 60%-88% of the cases of hypotonia, and the less frequent peripheral causes, which account for 15%-30% of the

causes of hypotonia, and as a whole, represent neuromuscular diseases.

The main central causes are hypoxic-ischemic encephalopathy, brain insults, brain malformations, intracranial hemorrhages, congenital syndromes, metabolic disorders such as inborn errors of metabolism (e.g., Zellweger syndrome and Lowe syndrome), and chromosomal disorders (e.g., Down syndrome).

The main peripheral causes include motor unit diseases such as infantile spinal muscular atrophy (anterior horn cell disease), Charcot-Marie-Tooth and Dejerine-Sottas diseases (nerves), myasthenia, and botulism (neuromuscular junction); they also include myopathies (muscle), such as congenital myopathies, congenital muscular dystrophies, and metabolic diseases (Pompe disease).

Some diseases may present signs and symptoms of both central and peripheral hypotonia, e.g., acid maltase deficiency (Pompe disease), giant axonal neuropathy, and mitochondrial diseases.

METHODS

A search was conducted in databases for articles published from 2000 to 2017 in English, Portuguese, or Spanish using the following keywords: “hypotonic child,” “floppy infant,” “newborn,” and “hypotonic infant.”

Clinical approach to the floppy infant^{5,8-10}

- Assessment of muscle tone: Newborn and infant

The premature newborn (NB) features physiological hypotonia from 26 to 36 weeks of gestational age. In the absence of prematurity, neonatal hypotonia is an alarming clinical picture, indicating that the baby is severely ill, including breathing and sucking impairment. This contrasts with a healthy NB, who presents physiological hypertonia due to semiflexion of the limb muscles.

Physiological hypotonia is not the most observed symptom in infants. In the case of an infant with pathological hypotonia, the symptoms observed are due to a delay or absence of motor skill acquisition during the child’s development. This may be associated with language and behavioral changes.

Chart 1. Hypotonia: Diagnostic Methods.

Diagnostic Methods	Successful Diagnosis (%)
History and Physical Examination: (STEP 1) Family history, birth conditions, and clinical and neurological examinations	50%
Imaging Tests (CT or MRI): (STEP 2)	13%
Clinical Genetic Evaluation: (STEP 3)	9%
Genetic Testing: Karyotype, FISH, comparative genomic hybridization (CGH) (STEP 4)	6%
Laboratory Tests: (STEP 5) Plasma amino acids, organic acids, acylcarnitine profile	6%
NEuromuscular Testing (STEP 6): CK, electroneuromyography (ENMG), DNA analysis for infantile spinal muscular atrophy and muscular dystrophies	6%

Source: Hannibal; Peredo⁹

Muscle tone assessment is one of the steps of neurological examination and will not be detailed in this article; however, some muscle tone assessment techniques are particularly used with children, including:

1) Traction response: This technique consists of holding the child's hands and pulling the child into a sitting position. The child should respond by being able to raise the head along with the body. When the sitting position is attained, the head should be erect in the midline (Figure 1 A). In floppy infants, a head lag is observed (Figure 1 A).

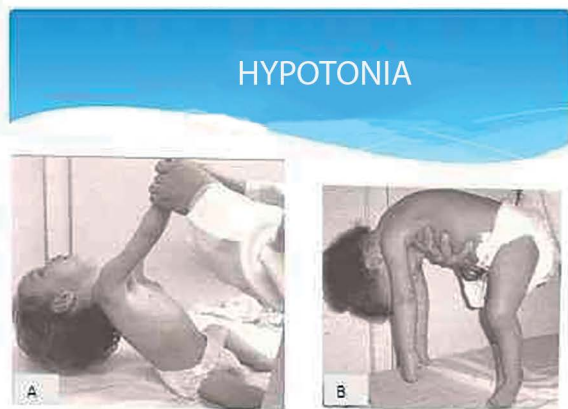


FIGURE A – Traction response

FIGURE B – Horizontal suspension

Figure C - Vertical suspension

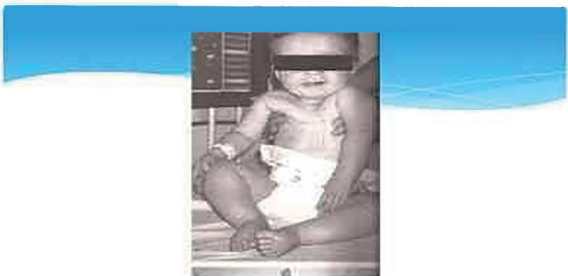
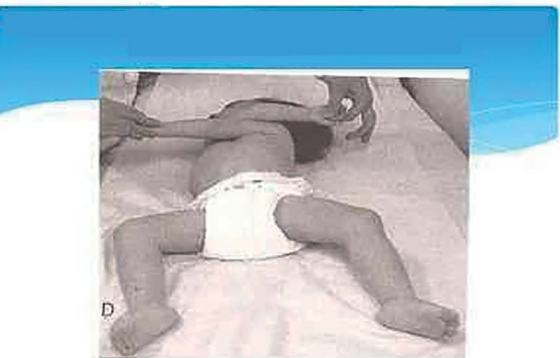

Figure D - Scarf sign



Figures 1A. D Hypotonia.

2) Horizontal suspension: When children are suspended horizontally, they should be able to maintain their heads in an erect position in the horizontal plane; backs in a straight posture; and elbows, knees, ankles, and hips in a flexed state. Floppy infants tend to drape over the examiner's hands, with the head and limbs hanging loosely (Figure 1 B).

3) Vertical suspension: This technique consists of holding the child by the armpits, without grasping the thorax, and pulling the child upwards. The normal response is semiflexion of the limbs, without slipping through the examiner's hands. In floppy infants, the head falls forward and legs are hypotonic; the child may slip through the examiner's hands owing to weakness in the shoulder muscles (Figure 1 C).

4) Scarf sign: Floppy infants lack resistance to the passive movement of their upper limbs, with elbows crossing the midline without forming joint angles, whereas lower limbs feature hyperabduction of the thighs, creating a frog-like posture (Figure 1D).

- Clinical history⁹⁻¹²

A few aspects are relevant in the clinical history of floppy infants:

1) Family history: parental consanguinity, history of previous pregnancies, family history of neurological disorders

2) Childbirth and pregnancy conditions: use of alcohol, tobacco, and illicit drugs during pregnancy; presence of maternal systemic and infectious diseases. Decreased fetal movement, increased or decreased amniotic fluid, intrauterine growth restriction, threat of a premature birth, miscarriage symptoms, presentation at birth, type of birth, obstetric trauma, primipara or multipara.

- General physical and neurological examination

General physical examination assessing facial dysmorphism; alertness; the cardiopulmonary, digestive, renal, and osteoarticular systems; skin; and skin appendages.

Neurological examination: assessment of motor function and muscle strength, sensitivity, deep tendon and superficial reflexes, presence of osteoarticular malformations, and presence of contractures.

- Additional tests and examinations in floppy infants¹³⁻¹⁶

Initial tests in floppy infants direct the diagnosis of systemic diseases. The routine tests are complete blood count, analyses and cultures (blood, urine, and cerebrospinal fluid), liver enzymes, blood glucose, sodium, potassium, phosphorus, calcium, magnesium, urea, and creatinine.

When congenital infections are suspected, serology tests should be requested for syphilis, toxoplasmosis, rubella,

cytomegalovirus, and herpes. In cases of central hypotonia with suspected metabolic or genetic disorders, additional specific tests should be requested according to the clinical suspicion, e.g., karyotyping by G-banding (in case of facial dysmorphism, as in Down syndrome), microarray, fluorescence *in situ* hybridization, and methylation test (Prader-Willi and Angelman syndromes).

When inborn errors of metabolism are suspected, their investigation consists of a few tests; for example, in case of acidosis, chromatography of amino acids (plasma) and measurement of urine organic acids should be requested; in case of organic acidemia and aminoacidopathy, tests should be requested for pyruvate and ammonia (urea cycle disorders), lactate (carbohydrate metabolism disorders and mitochondrial disorders), and acylcarnitine profile (organic acidemia and fatty acid oxidation disorders).

Very-long-chain fatty acid levels should be requested in case of peroxisomal disorders such as adrenoleukodystrophy.

In cases of peripheral hypotonia, creatine kinase (CK) levels should be requested, as well as other tests, depending on the suspected diagnoses. Specific tests such as DNA analysis are useful for infantile spinal muscular atrophy and myotonic dystrophies. Additional invasive tests should also be requested, such as electroneuromyography and muscle biopsy with immunohistochemistry and electron microscopy, which are the methods of choice for the differential diagnosis of myopathies and muscular dystrophies.

Imaging tests such as magnetic resonance imaging (MRI) are valuable tools to detect CNS abnormalities. Head MRI enables the detection of structural malformations, neuronal migration defects, and basal ganglia signal abnormality or brain stem and cerebellum malformations (Joubert syndrome). White matter degeneration (leukodystrophy) can be seen in peroxisomal disorders, and heterotopias in congenital muscular dystrophies and other CNS diseases. Magnetic resonance spectroscopy assists in the diagnosis of metabolic disorders.

Neuromuscular diseases represent a small part of the causes for hypotonia but are the main clinical conditions in hypotonia associated with muscle weakness. They are classified according to the affected region. Some of these diseases are associated with hypotonia in the newborn or infant stages. The main neuromuscular diseases are listed below:

- 1) Anterior horn diseases: infantile spinal muscular atrophy and infantile paralysis.
- 2) Neuropathies: Dejerine-Sottas disease and Guillain-Barré syndrome.
- 3) Neuromuscular junction diseases: transient neonatal myasthenia gravis, congenital myasthenic syndrome, myasthenia gravis, and botulism.
- 4) Myopathies: muscular dystrophies (congenital or non-congenital), congenital myopathies, metabolic myopathies, inflammatory myopathies such as polymyositis, and infectious myositis.

Many of the diseases mentioned above are definitively diagnosed through molecular analysis, as in the case of infantile spinal muscular atrophy, which is the second most frequent neuromuscular disease and is diagnosed when the molecular analysis shows deletion of the survival motor neuron gene. The clinical picture progresses to severe hypotonia, particularly in its most severe form, type 1 (Werdnig-Hoffmann disease).

Another neuromuscular disease that progresses to hypotonia, especially in its infantile form, is glycogen storage disease type 2, also known as acid maltase deficiency or Pompe disease, characterized by a deficiency of the enzyme acid alpha-glucosidase, responsible for the breakdown of glycogen in lysosomes. With the deficiency or absence of this enzyme, glycogen accumulates in striated muscle, cardiac muscle, and smooth muscle, leading to hypertrophic cardiomyopathy, hypotonia, muscle weakness, respiratory failure, and even death. The treatment of Pompe disease consists of intravenous enzyme replacement with alpha-glucosidase^{14,17}.

Steps to diagnosis Benign congenital hypotonia⁹

This is a common differential diagnosis of hypotonia. It is a nonprogressive neuromuscular disorder present at birth that delays neuropsychomotor development milestones. It is characterized by symmetrical muscle flaccidity. Deep tendon reflexes and laboratory test results are normal. It is a diagnosis of exclusion. There is an increased incidence in cases of intellectual disabilities and learning disorders.

TREATMENT

The treatment for floppy infant syndrome should be adapted according to the specific condition. It usually features support therapy and a rehabilitation team, involving numerous professionals. Nutritional intake is extremely important and must be administered by enteral probes or gastrostomy. Ventilatory support is equally important because hypotonia can impair breathing and swallowing.

Genetic counseling for parents is of utmost importance, especially in cases of peripheral hypotonia caused by neuromuscular diseases, the vast majority of cases being genetically determined.

CONCLUSION

Generally, the most frequent causes of hypotonia are central. Due to the wide range of clinical manifestations with multiple causes for hypotonia, the clinical history and general physical and neurological examinations are extremely important, aiding the differential diagnosis in a vast majority of cases. The selection of specific genetic tests, neuroimaging examinations, and laboratory tests assists and contributes in elucidating the cause of hypotonia. Additional specific and invasive exams, such as electroneuromyography and muscle biopsy, also play an important role in the diagnosis of hypotonia, mainly when the causes are peripheral.

REFERENCES

1. Saa KK, Benaprés MAA, De La Fuente ATP. Enfoque clínico del recién nacido y lactante hipotónico. *Rev Ped Elec*. 2014;11(3):39-54.
2. Pina-Garza JE. The Hypotonic Infant. In: Pina-Garza JE. Fenichel's Clinical Pediatric Neurology. 7th ed. London: Elsevier Saunders. 2013; p. 147-69.
3. Bodensteiner JB. The evaluation of the hypotonic infant. *Semin Pediatr Neurol*. 2008;15(1):10-20.
4. Wijesekara DS. Clinical approach to a floppy infant. *Sri Lanka J Child Health Clin*. 2013;41:211-6.
5. Reed UC. Síndrome da criança hipotônica: causas neuromusculares. *Rev Med (São Paulo)*. 2007;86(2):82-93.
6. De Vivo M, Rojo S, Rosso R, Chello G, Giliberti P. Floppy Infant Syndrome: new approach to the study of neonatal hypotonia through the analysis of a rare case of X-Linked Myotubular Myopathy. *J Pediatric Neonatal Individual Med*. 2014;3(1):e030114.
7. Kaur J, Punia S. Floppy Infant Syndrome: Overview. *Int J Physiother Res*. 2016;4(3):1554-63.
8. Núñez FA, Aránguiz RJ, Kattan SJ, Escobar HR. Síndrome hipotônico del recién nacido. *Rev Chil Pediatr*. 2008;79(2):146-51.
9. Peredo DE, Hannibal MC. The floppy infant: evaluation of hypotonia. *Pediatr Rev*. 2009;30(9):e66-76.
10. Harris SR. Congenital hypotonia: clinical and developmental assessment. *Dev Med Child Neurol*. 2008;50(12):889-92.
11. Laugel V, Cossée M, Matis J, de Saint-Martin A, Echaniz-Laguna A, Mandel JL, et al. Diagnostic approach to neonatal hypotonia: retrospective study on 144 neonates. *Eur J Pediatr*. 2008;167(5):517-23.
12. Leyenaar J, Camfield P, Camfield C. A schematic approach to hypotonia in infancy. *Paediatr Child Health*. 2005;10(7):397-400.
13. Prasad AN, Prasad C. The floppy infant: contribution of genetic and metabolic disorders. *Brain Dev*. 2003;25(7):457-76.
14. McDonald CM. Clinical approach to the diagnostic evaluation of hereditary and acquired neuromuscular diseases. *Phys Med Rehabil Clin N Am*. 2012;23(3):495-563.
15. Trabacca A, Losito L, De Rinaldis M, Gennaro L. Congenital hypotonia in a child with a de novo 22q13 monosomy and 2pter duplication: a clinical and molecular genetic study. *J Child Neurol*. 2011;26(2):235-8.
16. Swaiman K, Ashwal S, Ferriero DM, Shor NF. *Swaiman's Pediatric Neurology*. 5th. London: Elsevier Saunders; 2012. p. 1463-658.
17. van den Hout HM, Hop W, van Diggelen OP, Smeitink JA, Smit GP, Poll-The BT, et al. The natural course of infantile Pompe's disease: 20 original cases compared with 133 cases from the literature. *Pediatrics*. 2003;112(2):332-40.