

A Rare Case of Primary Cutaneous Blastomycosis Masquerading as Blastomycosis-Like Pyoderma

Christopher White, BA,* Emily Rubenstein, DO,** Ankita Patel, PA-C***

*Medical Student, 4th year, Chicago College of Osteopathic Medicine, Downers Grove, IL

**Dermatologist and Clinical Director, Swedish Skin Institute, Chicago, IL

***PA-C, Swedish Skin Institute, Chicago, IL

Disclosures: None

Correspondent: Christopher White, BA; cwhite76@midwestern.edu

Abstract

*Blastomycosis, a granulomatous disease caused by the organism *Blastomyces dermatitidis*, is well-recognized across various specialties due to its propensity for chronic infection. Despite the typified cutaneous manifestations following pulmonary or disseminated disease, primary cutaneous infections, though rare, have been reported, particularly among members of the veterinary and healthcare professions. Herein, we describe the case of a 35-year-old African American male presenting with primary cutaneous blastomycosis of the shoulder and thigh. Of interest, the patient had no classical physical or environmental exposures, nor any signs or symptoms of systemic infection. Antifungals remain the treatment standard for blastomycotic infections of the skin, though there have been rare reports of self-resolution.*

Introduction

Blastomycosis is a granulomatous infection caused by the dimorphic fungus *Blastomyces dermatitidis*. Most notable for affecting the lungs following inhalation of the conidia, the infection can disseminate to involve any organ system.¹ Spore-contaminated soil is the most common source of infection, particularly in the eastern region of the United States (classically, the Mississippi River Valley), where the disease is endemic, earning it the alternate moniker “North American blastomycosis.” In recent years, however, sporadic cases of infection throughout Latin America, Africa, and Asia have rendered that term irrelevant.²

Primary cutaneous blastomycosis, a rare manifestation of the disease, usually follows fungal invasion via direct, penetrating trauma.³ Most cases affect hospital and laboratory workers, with symptoms evolving over one to two weeks, generally presenting as erythematous, verrucous indurations.² Herein, we present a case of primary cutaneous blastomycosis along with a review of differential diagnoses and management options.

Case Report

A 35-year-old African American male presented to clinic with a four-month history of a bothersome lesion on the right posterior shoulder, and a similar lesion of one month's duration on the right upper lateral thigh. The patient did not identify a precipitating event, and noted the sole reason for his appointment was because the lesions were unsightly and occasionally pruritic. He had no relevant dermatologic history, nor any medical conditions that would predispose him to opportunistic infections.

Dermatologic evaluation revealed two well-demarcated, erythematous and verrucous plaques, one on the shoulder, measuring 2 cm, and one on the thigh, measuring 1.5 cm. The plaques had papulopustular infiltrates with scattered black crusting (Figure 1). Shave biopsies were performed on both locations to rule out verrucous vulgaris versus irritated seborrheic keratosis versus squamous cell carcinoma.

Microscopy demonstrated suppurative and granulomatous infiltrates in the dermis with pseudoepitheliomatous hyperplasia (Figure 2). Gram-positive cocci were found on Gram stain,

with negative GMS, PAS, and AFB stains. The diagnosis of blastomycosis-like pyoderma was suggested, with the possibility of a deep fungal or primary fungal infection with secondary impetiginization. Given these results, the patient was prescribed a two-week course of ciprofloxacin 500 mg PO BID. At follow-up, the lesions had not fully resolved.

A punch biopsy was performed, the results of which showed the presence of scarce spores on PAS stain, negative Gram stain, and morphology consistent with blastomycosis (Figure 3). Features of suppurative and granulomatous inflammation with pseudoepitheliomatous hyperplasia remained (Figures 4, 5). The patient was started on itraconazole 400 mg PO QD, and Infectious Diseases was consulted for additional investigation. Within one to two weeks of starting treatment, the patient was lesion-free. He reported that the infectious-disease specialist concurred with the diagnosis of primary cutaneous blastomycosis based on the isolated skin findings, lack of pulmonary or systemic symptoms, and

rapid resolution of the lesions with itraconazole. No further testing was ordered aside from routine lab work to monitor for treatment side effects. It was recommended that the patient continue his prescribed itraconazole therapy for a total of one year. At nine months of treatment, the patient had experienced complete resolution of skin lesions and had no additional findings or side effects.

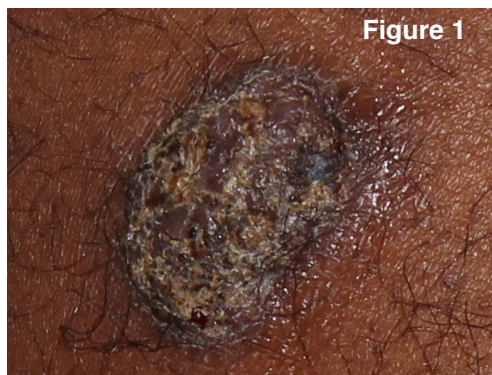


Figure 1

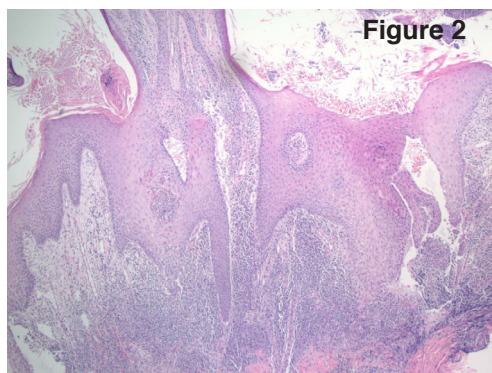


Figure 2

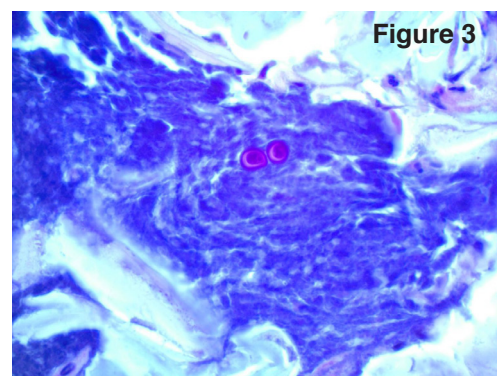


Figure 3

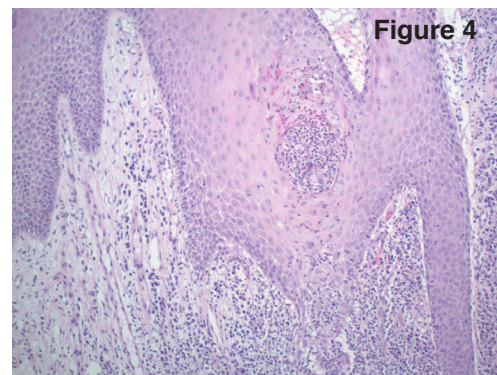


Figure 4

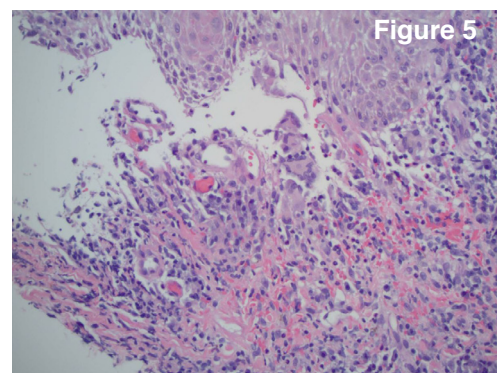


Figure 5

Discussion

Blastomycosis generally presents in pulmonary form, as this is the most common site of primary infection. Most cases arise in middle-aged men with significant outdoor exposures.⁴ Unlike many fungal infections, blastomycosis usually affects an immunocompetent host, causing chronic pulmonary infection that typically presents as a recurrent, pneumonia-like illness with concomitant night sweats, fever, and weightloss.⁵ Dissemination is infrequent but possible, particularly in HIV-positive, post-transplant, or otherwise immunocompromised hosts. The skin tends to be the most frequent extrapulmonary site of infection; other potentially affected sites include joints and the genitourinary and central nervous systems.⁶

Primary cutaneous blastomycosis is extraordinarily rare, typically the result of inoculation through direct penetrating trauma.⁷ While some of these infections may occur in the outdoor setting via animal bites, they more frequently result from laboratory or hospital exposure, specifically among persons performing autopsies on infected corpses.² Additionally, recent literature suggests that primary inoculation may be significantly underestimated because spontaneous resolution of lesions may occur.⁸

Diagnosis of any cutaneous form of infection requires adequate clinical suspicion to warrant biopsy, frequently with concurrent culture. A patient history including significant outdoor exposure or direct penetrating trauma with failed antibiotic treatment aids in diagnosis. Histopathology revealing non-caseating pyogranuloma formation with pseudoepitheliomatous hyperplasia is suggestive.^{6,9} Direct microscopy with staining is often helpful, revealing large budding yeast with thick cell walls.² However, the gold standard for diagnosis remains culture on Sabouraud agar, which is particularly helpful when microscopy is inconclusive or even negative.^{10,11} There are currently no serologic tests with diagnostic sensitivity or specificity, and imaging studies in patients without systemic symptoms have questionable benefit because subclinical pulmonary infections are possible.¹¹

Our patient endorsed none of the classic risk factors associated with blastomycosis infection. He denied significant outdoor activities, had an occupation unrelated to healthcare or disease exposures, and recalled no illness or trauma near the time his lesions developed. Despite having cutaneous symptoms for nearly a year, he experienced no pulmonary issues, weight loss, night sweats, unexplained fevers, or worsening of his original lesions. He also developed no additional skin findings, which is uncommon with disseminated disease. Taken together with the input of Infectious Diseases, these findings are highly suggestive of a primary cutaneous infection.

Differential diagnosis

Clinical differential diagnosis for the above presentation includes blastomycosis-like pyoderma (BLP), halogenoderma, and squamous cell carcinoma, among other conditions.^{2,6,11} A thorough physical examination, extensive history, and histology serve to exclude these alternatives.

A history of local or systemic immunosuppression lends itself to BLP diagnosis, which is further supported by successful antibiotic treatment and negative fungal stains or cultures.¹² As mentioned previously, histological examination

can be nondiagnostic.^{10,12} Halogenoderma, an exceedingly rare dermatosis in and of itself, can be differentiated via normal blood levels of halogens (most commonly iodine, fluoride, and bromide) and a histological evaluation revealing intraepidermal abscesses and dermal proliferation of neutrophils.² The most concerning differential, squamous cell carcinoma, requires tissue sampling for definitive diagnosis and is primarily why many studies support an early biopsy.¹⁰

Treatment

Despite instances of cutaneous lesions spontaneously regressing, treatment is recommended.¹⁰ Regardless of drug choice, systemic treatment is always required. Mild to moderate non-CNS disease is primarily managed with itraconazole 200 mg/day to 400 mg/day for six to 12 months, with a 90% cure rate after a median treatment duration of 6.2 months.^{2,6,14} Amphotericin B, while also a first-line option, is typically reserved for CNS or refractory non-CNS infections due to its side effect profile.¹⁴ Secondary regimens include oral voriconazole, fluconazole, or ketoconazole.¹⁴

Conclusion

With no definitive cutaneous or serologic tests for primary versus secondary cutaneous infection, dermatologic findings of blastomycosis are generally categorized based on patient history or predisposing factors; however, without penetrating trauma or fungal invasion of a known wound, the default labeling for these cases is typically a disseminated pulmonary infection. With up to 50% of pulmonary infections showing no respiratory symptoms and up to 80% of disseminated manifestations being cutaneous, this may be a safe assumption.⁶ Therapeutically, since identical treatment methods are used to manage both forms of cutaneous involvement, the significance of this distinction is often overlooked.

References

1. Longo D, Fauci A, Kasper D, et al. *Harrison's Principles of Internal Medicine*, 18th ed. New York, NY: McGraw-Hill, 2012.
2. Bologna J, Jorizzo J, Rapini R, et al. *Dermatology*, 2nd ed. Philadelphia, PA: Elsevier, 2003.
3. Kumar V, Abbas A, Aster J. *Robbins and Cotran pathologic basis of disease*, 9th ed. Philadelphia, PA: Elsevier, 2015.
4. Goldman L, Schafer A, et al. *Goldman's Cecil Medicine*, 24th ed. Philadelphia, PA: Elsevier, 2012.
5. Papadakis M, McPhee S, Rabow M, et al. *Current Medical Diagnosis & Treatment*, 53rd ed. New York, NY: McGraw-Hill, 2014.
6. James W, Andrews G, Berger T, et al. *Andrews' Diseases of the Skin: Clinical Dermatology*, 11th ed. Philadelphia, PA: Elsevier, 2011.
7. Stephens J, Huddleston H, Reeck M. Cutaneous blastomycosis in the absence of active pulmonary disease. *J Am Acad Dermatol*. 2007;56(2):130.
8. Gray N, Baddour L. Cutaneous inoculation blastomycosis. *Clin Infect Dis*. 2002;34:44-9.
9. Wang S, Martini M, Groth J, et al. Dermatoscopic and clinicopathologic findings of cutaneous blastomycosis. *J Am Acad Dermatol*. 2015;73(5):169-70.
10. Guidry J, Downing C, Tying S. Deep fungal infections, blastomycosis-like pyoderma, and granulomatous sexually transmitted infections. *Dermatol Clin*. 2015;33:595-607.
11. Mason A, Cortes G, Cook J, et al. Cutaneous blastomycosis: a diagnostic challenge. *Int J Dermatol*. 2008;47:824-30.
12. Sawalka S, Phishe M, Jerajani H. Blastomycosis-like pyoderma. *Indian J Dermatol Venereol Leprol*. 2007;73(2):117-9.
13. Alagheband M. Lithium and halogenoderma. *Arch Dermatol*. 2000;136:126-7.
14. Lebowitz M, Heymann W, Berth-Jones J. *Treatment of Skin Disease: Comprehensive Therapeutic Strategies*, 4th ed. Philadelphia, PA: Saunders, 2013.