

Cutaneous Blastomycosis: A Case Report and Review of the Literature

Shannon McKeen, DO,* Anthony McKeen, DO,** Mark A. Kuriata, DO, FAOCD***

*Dermatologist, Apex Dermatology, Concord, OH

**Family Medicine Doctor, Lakeland Family Medicine, Niles, MI

***Program Director, Lakeland Health Dermatology Residency Program/MSUCOM, St. Joseph, MI

Disclosures: None

Correspondence: Shannon McKeen, DO; 7580 Auburn Road, Ste. 301, Concord, OH 44077; (440)352-7546; snicolesharpe@gmail.com

Abstract

Blastomycosis is a chronic mycotic infection due to a dimorphic fungus, and it can affect the lungs as well as other organ systems. The vague clinical presentation of blastomycosis and the non-specific radiologic findings associated with the condition can lead to a delay in diagnosis and treatment. We will present a case of a 49-year-old Caucasian male with cutaneous dissemination of an undiagnosed, chronic, primary pulmonary blastomycosis infection. There is often a significant delay in diagnosing blastomycosis, even in endemic areas. We present this case to raise awareness amongst health care providers about the signs and symptoms of blastomycosis, allowing for prompt diagnosis and initiation of appropriate treatment, decreasing the risk of dissemination.

Introduction

Blastomycosis is a chronic mycotic infection caused by the thermally dimorphic fungus *Blastomyces dermatitidis*.¹⁻⁴ The annual incidence ranges from 0.2 per 100,000 persons to 1.94 per 100,000 persons; in endemic areas such as the Mississippi and Ohio River basins, Saint Lawrence River valleys and the Great Lakes region, incidence ranges from five per 100,000 persons to 100 per 100,000 persons.¹⁻⁴ Infection is usually secondary to inhalation of hyphal fragments. Pulmonary symptoms can be vague and easily attributed to more common diagnoses. This leads to a delay in diagnosis and subsequent dissemination of disease, requiring long-term treatment with antifungal agents.¹⁻⁴ We present a case of a 49-year-old male with blastomycosis in which diagnosis was delayed, resulting in dissemination.

Case Report

A 49-year-old Caucasian male with a past medical history of schizophrenia presented to the family medicine clinic for dizziness, darkened urine, chronic cough, insomnia and weight loss. Upon presentation, his physical examination and vital signs were within normal limits. The patient's primary care physician ordered a complete blood count, comprehensive medical panel, urinalysis and chest X-ray.

Nine days later, the patient presented to the emergency department, where he was found to be afebrile and tachycardic. His chest X-ray showed a non-specific, right upper lobe alveolar consolidation. A CT scan of the chest showed enlarged hilar lymph nodes and an "expansile cavitary pneumonic process." The working differential diagnosis included tuberculosis, necrotizing pneumonia and a malignant neoplasm. The infectious disease service placed the patient in isolation until sputum testing returned negative for acid-fast bacilli, ruling out tuberculosis. The patient was then started on a regimen of clindamycin and aztreonam. The cardiothoracic surgery service recommended continued antibiotics and follow-up bronchoscopy if a repeat chest X-ray showed no improvement. The patient was discharged from the hospital in stable condition, on further antibiotics, without a definitive etiology of the pulmonary process. No bronchoscopy was performed, as the three-week chest X-ray showed improvement after an antibiotic course.

The patient presented to his primary care physician two months later with facial lesions. He was referred to dermatology and found to have multiple centrofacial, well-demarcated, verrucous plaques with overlying

crust and central ulceration (Figure 1). A biopsy was obtained, showing acanthosis, papillomatosis, multinucleated giant cells and fungal organisms with refractile walls and evidence of broad-based budding, consistent with cutaneous blastomycosis (Figure 2). Gomori methenamine silver (GMS) and periodic acid-Schiff (PAS) stains positively labeled the organisms. The patient was diagnosed with disseminated cutaneous blastomycosis secondary to a primary pulmonary infection. The patient was then started on a 12-month course of itraconazole, and his lesions slowly improved.

Discussion

Blastomycosis is a chronic mycotic infection that can affect the lungs as well as other organ systems. It is caused by the thermally dimorphic fungus *Blastomyces dermatitidis*. Due to the varied clinical presentation and commonly associated subclinical illness, data regarding incidence from epidemiologic studies are limited. The annual incidence ranges from 0.2 per 100,000 persons to 1.94 per 100,000 persons; in hyperendemic regions, the incidence can range from five per 100,000 persons to 100 per 100,000 persons.¹ Endemic areas in North America include the

Mississippi and Ohio River basins, Saint Lawrence River valleys and the Great Lakes region.¹⁻³

When found in the environment, *B. dermatitidis* grows in the hyphal form at 22 °C to 25 °C.^{1,2} The hyphal form has a geographic predilection for forested areas near a water source with associated decayed or rotting wood.¹ Activities that disrupt the soil, such as construction or clearing of brush, cause aerosolization of *B. dermatitidis*. Infection is

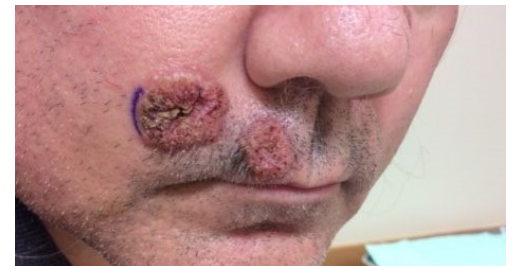

Figure 1. Multiple centrofacial, well-demarcated, erythematous, verrucous plaques with overlying crust and central ulceration.

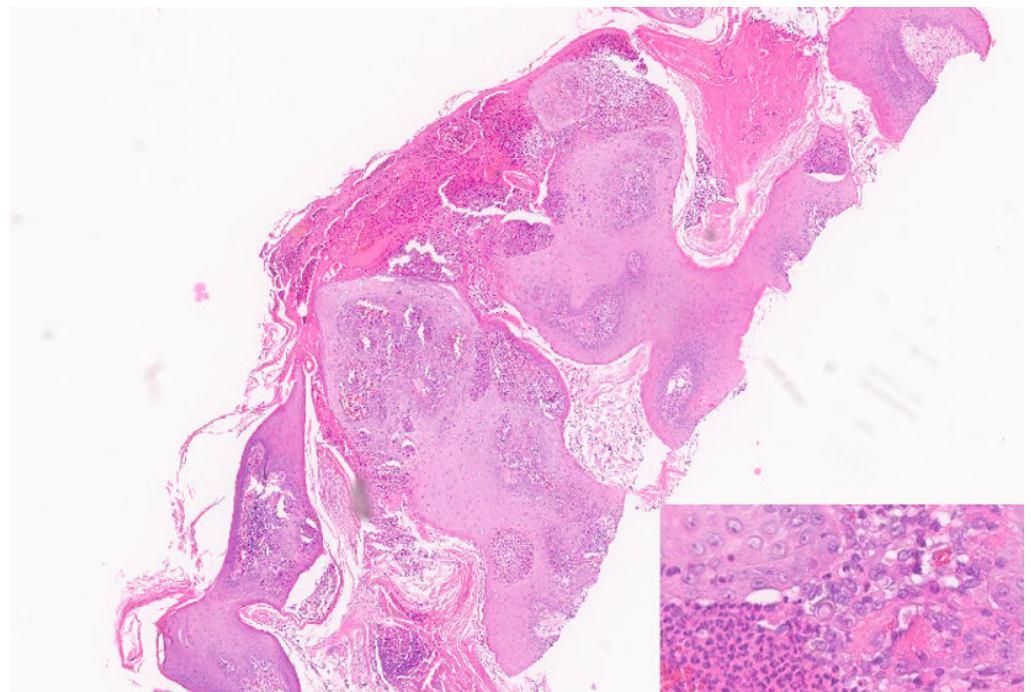


Figure 2. Shave biopsy showing acanthosis, papillomatosis and overlying compact parakeratosis with numerous neutrophils. Multinucleated giant cells and associated histiocytes are present. Inset: Fungal organisms with refractile walls are identified.

acquired mainly via inhalation, although rare cases of inoculation have been reported in lab workers or personnel performing autopsies. Upon inhalation, the temperature in the lungs (37 °C) is the main stimulus to convert the hyphal fragments into the yeast form.¹⁻³

The yeast form of *B. dermatitidis* expresses specific virulence factors that allow for disease in human hosts. DRK1 (dimorphism-regulating kinase), a gene discovered on *B. dermatitidis*, encodes histidine kinase. This gene is required for the conversion of the hyphal form to the yeast form following a thermal stimulus.¹ Blastomyces adhesion-1 (BAD-1) plays an important role in cell adhesion and alteration of the immune response. BAD-1 decreases TNF- α , blocks CD4+ T-cell activation and inhibits complement deposition on the yeast cell wall.¹ These virulence factors allow for the pathologic overgrowth of the organism, leading to clinical disease.

Most commonly, patients have a primary pulmonary infection, which can be either acute or chronic. While patients may present with cough, fever, night sweats, weight loss, chest pain, dyspnea, myalgias or hemoptysis, 50% of patients have no symptoms at all.¹⁻³ Imaging is non-specific and may show consolidation, a mass, or cavitation, which can be misinterpreted as pneumonia, malignancy or tuberculosis, respectively. Untreated pulmonary disease can disseminate to any organ system. The most common extra-pulmonary site of infection is the skin.¹⁻⁴

The clinical presentation of cutaneous dissemination of blastomycosis can be varied and requires pathologic confirmation. Lesions typically present as verrucous scaly plaques or nodules with raised borders and peripheral expansion with central scarring, with or without central ulceration.²⁻⁴ Any cutaneous surface may be involved, but lesions are most likely to be found on the exposed surfaces of the head, neck and upper extremities. The differential diagnosis includes keratoacanthoma, pyoderma gangrenosum, non-melanoma skin cancer and cutaneous tuberculosis.⁴ Findings on dermoscopy include overlapping papillomatous structures with a pink vascular hue, hemorrhagic crust, irregular vessels and thin plates of scale.⁵ Biopsy specimens stained with hematoxylin and eosin (H&E) will show evidence of pseudoepitheliomatous hyperplasia and microabscess formation on low power. At higher magnification, multinucleated giant cells will become apparent, as well as spores with thick, double-refractile walls and broad-based budding.^{5,6} Organisms may be highlighted by staining the specimen with either Gomori methenamine silver (GMS) or periodic acid-Schiff (PAS) stains.^{1,6}

Although cutaneous dissemination is the most common form of extra-pulmonary infection, other organ systems such as osseous structures, the genitourinary system and the central nervous system (CNS) may be involved. Twenty-five percent of disseminated cases involve the bone, most commonly the long bones and vertebrae. Lesions are often painful and can have overlying draining sinus tracts.^{1,2} Genitourinary involvement can be seen in approximately 10 percent of disseminated cases. Men are most often affected, and the most commonly involved sites are the prostate and epididymis.^{1,2} Central nervous system involvement is the least common form of dissemination and can lead to meningitis or brain abscesses. The risk of CNS involvement is increased in patients with co-existing

immunosuppression. CNS involvement warrants a more aggressive and extensive treatment regimen.^{1,2}

The vague clinical presentation of blastomycosis and non-specific radiologic findings can lead to a delay in diagnosis and treatment. In half of patients, the diagnosis is made more than one month after presentation.¹ The gold standard for definitive diagnosis of blastomycosis is a culture. Cultures can be performed on bronchial secretions or tissue culture from cutaneous lesions. Sabouraud dextrose agar is the preferred media, and incubation should occur at 30 °C. On average, growth is noted around one week to two weeks, but it may take up to one month.^{1,2} For a more rapid diagnosis, specimens can be stained to highlight the organisms. As discussed earlier, tissue specimens can be stained with either GMS or PAS. Sputum can be stained with 10% potassium hydroxide or calcofluor white.¹ Serologic testing is available but has poor sensitivity and specificity. Polymerase chain reaction assays have been developed but are not available for commercial use.¹ Once diagnosis is confirmed, a thorough review of systems should be obtained and targeted imaging performed based upon positive symptomatology.

The National Institute of Allergy and Infectious Diseases Mycoses Study Group and the Infectious Diseases Society of America presented a consensus for the recommended guidelines in treating blastomycosis. The organ systems affected, severity of infection, immune status of the patient and pregnancy are the factors guiding treatment regimens.^{1,7} Patients with mild to moderate pulmonary disease, with or without mild cutaneous involvement, should receive itraconazole 200 mg/day to 400 mg/day for a minimum of six months.⁷ Itraconazole can have variable serum concentrations, which should be monitored two weeks after therapy has begun. Itraconazole solution produces a 30% higher serum concentration and does not require an acidic milieu for absorption when compared to the capsules. Due to the increased risk for liver toxicity, liver function tests should be obtained at baseline and monitored at two weeks, four weeks and every three months thereafter.¹ Patients with life-threatening disease and CNS involvement should be treated with amphotericin B at a recommended dose of 0.7 mg/kg/day to 1 mg/kg/day for a total dose of 1.5 g to 2.5 g.⁷ Amphotericin B is also the recommended treatment of choice for pregnant patients with blastomycosis. Renal function should be monitored in patients receiving amphotericin B due to the risk of nephrotoxicity. The lipid formulation of amphotericin B is being used more frequently because it decreases the risk of renal injury.¹ After stabilization with amphotericin B, patients can be stepped down to itraconazole. Patients with immunosuppression may require long-term suppressive therapy with itraconazole.^{1,7}

Conclusion

The case presented here exemplifies the classic delay in diagnosis of blastomycosis, which increases the patient's risk for dissemination. Patients presenting with "pneumonia" in endemic areas should be questioned not only about recent travel and outdoor activities, but also about any construction or remodeling that may have occurred near home or work. Obtaining a more in-depth history will help raise suspicion in those with an increased risk. The diagnostic options discussed above, coupled with a heightened awareness of the infection, can aid in prompt diagnosis and initiation of therapy.

References

1. Smith JA, Gauthier, G. New Developments in Blastomycosis. *Semin Respir Crit Care Med.* 2015;36:715-28.
2. Motswaledi HM, Monyemangene FM, Maloba BR, et al. Blastomycosis: a care report and review of the literature. *Int J Dermatol.* 2012;51:1090-3.
3. Ortega-Loayza AG, Nguyen T. Cutaneous blastomycosis: a clue to a systemic disease. *An Bras Dermatol.* 2013;88(2):287-9.
4. Smith JA, Riddel J, Kauffman CA. Cutaneous Manifestations of Endemic Mycoses. *Curr Infect Dis Rep.* 2013;15:440-9.
5. Wang S, Martini MC, Groth JV, et al. Dermatoscopic and clinicopathologic findings of cutaneous blastomycosis. *J Am Acad Dermatol.* 2015;73:e160-70.
6. Elder DE, Elenitsas R, Johnson BL, Murphy GF, Xu X. *Lever's histopathology of the skin.* 10th ed. Philadelphia: Lippincott Williams & Wilkins; c2009. Chapter 23, Fungal Diseases; p. 603-5.
7. Chapman SW, Bradsher RW, Campbell GD, et al. Practice Guidelines for the Management of Patients with Blastomycosis. *Clin Infect Dis.* 2000;30:679-83.