

AUTOIMMUNE BLISTERING DISEASES; WINDOW TO SYSTEMIC DISEASE

Ron Feldman, MD, PhD

Assistant Professor of Dermatology

Emory University

ron.j.feldman@emory.edu



EMORY
UNIVERSITY

EMORY
HEALTHCARE

Disclosures

- I have no conflict of interest to declare
- I will be talking about off-label use of medications

Learning Objectives

- To define mechanisms of autoimmune blistering diseases (AIBD)
- To understand that bullous diseases can provide insight into systemic disease
- To review treatments for both bullous diseases and related systemic diseases

Autoimmune Blistering Diseases

Epidermal

Pemphigus foliaceus

- Endemic
- P. Erythematosus
- IgA Pemphigus
- P. Herpetiformis

Pemphigus vulgaris

- P. Vegetans

Paraneoplastic Pemphigus

Subepidermal

Bullous pemphigoid

Mucous membrane pemphigoid

Epidermolysis bullosa acquisita

Bullous systemic lupus

Linear IgA disease

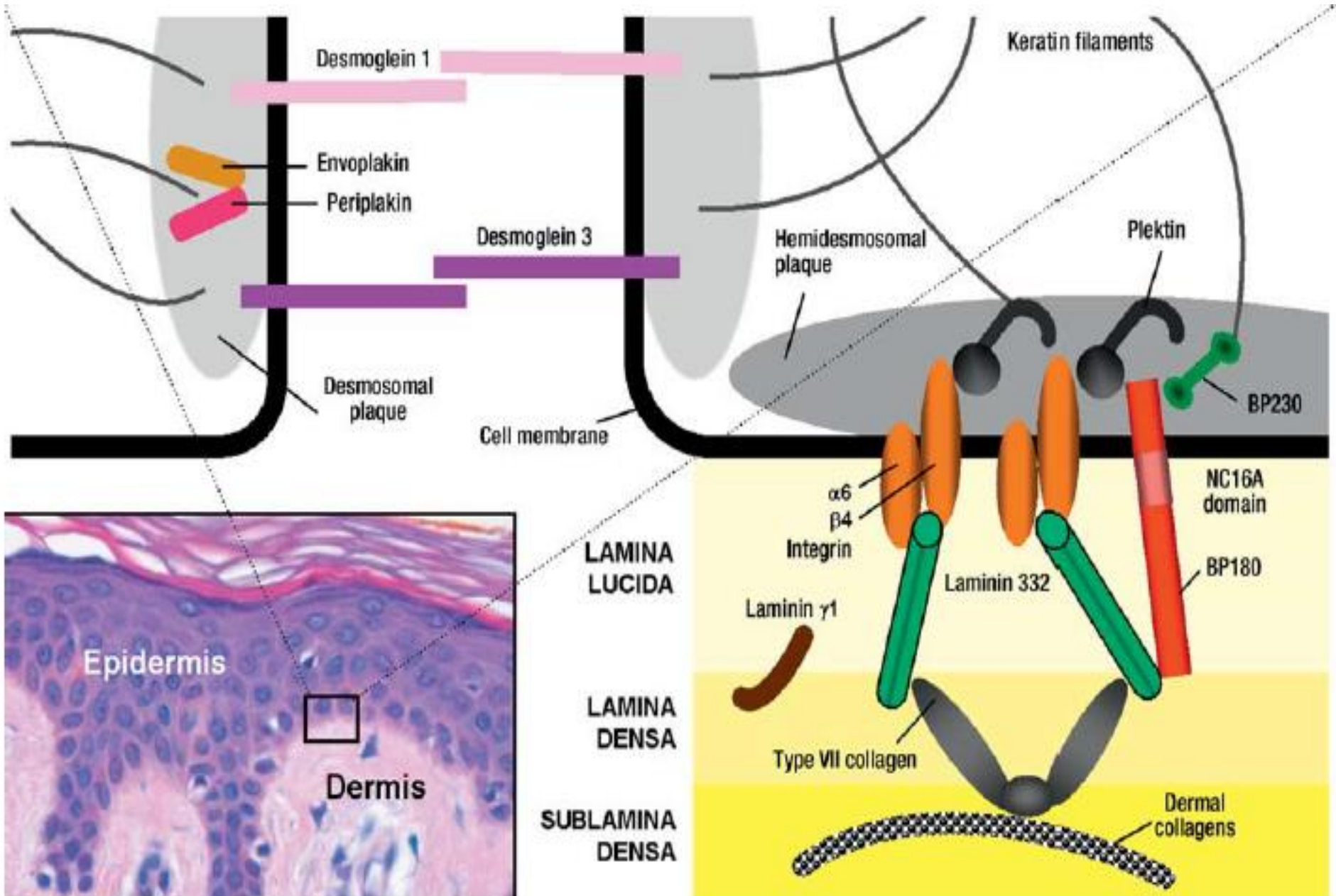
Pemphigoid gestationis

Dermatitis herpetiformis

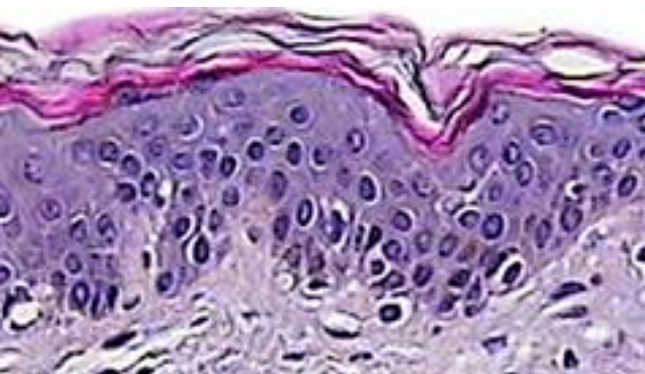
Lichen planus pemphigoides

p200/Laminin γ -1-pemphigoid

Adhesion Molecules in the Skin



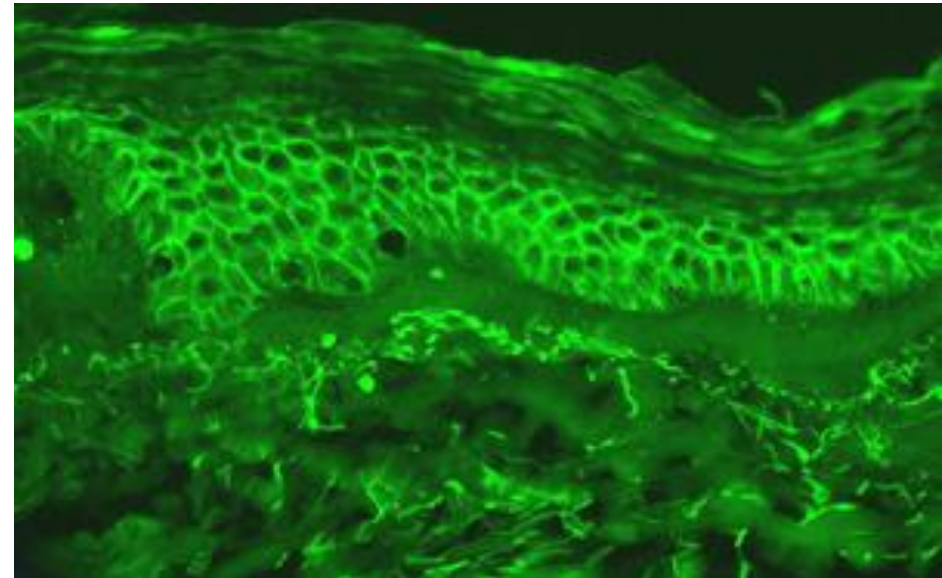
Epidermal Blistering Disease



Epidermis

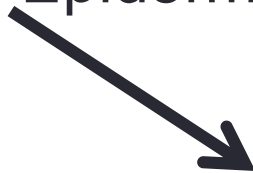

Dermis

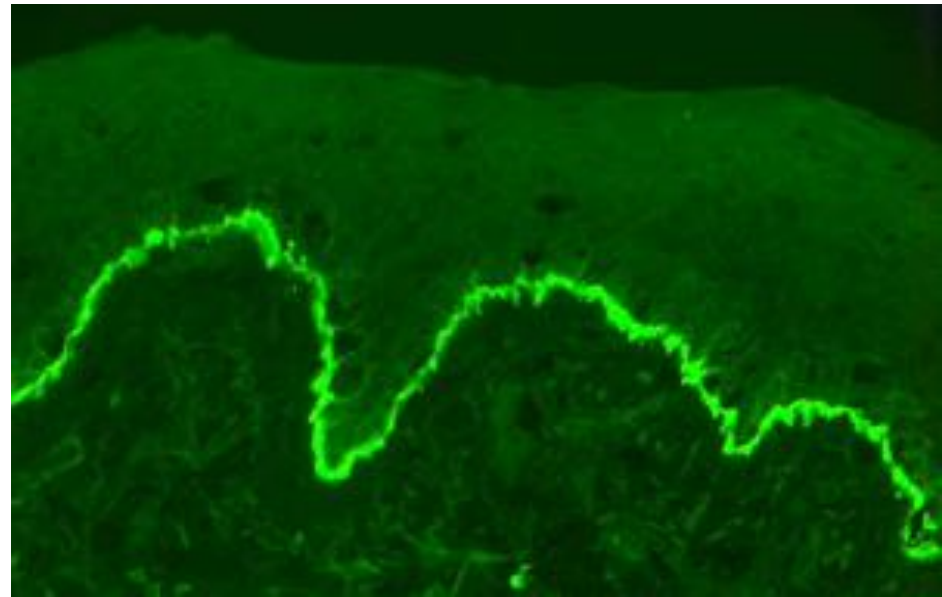


Subepidermal Blistering Disease

Epidermis

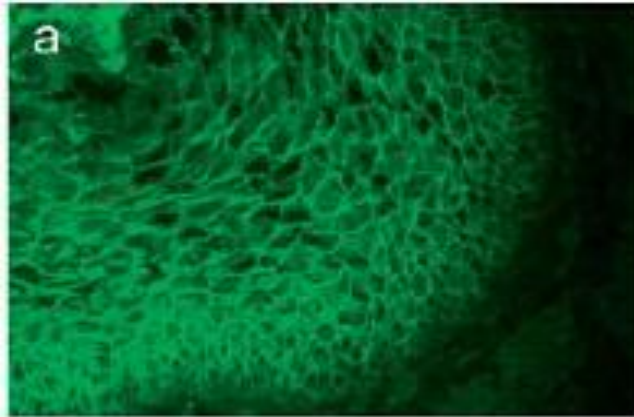


Dermis



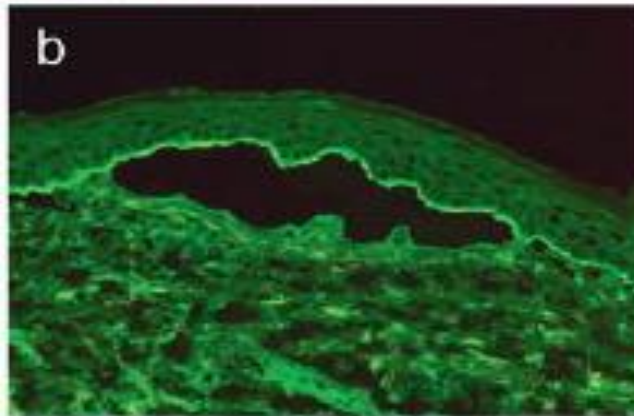
Indirect Immunofluorescence/ELISA

Schmidt and Zillikens,
The Diagnosis and
Treatment of
Autoimmune Blistering
Diseases, Dtsch
Arztebl Int 2011;
108(23): 399–405.

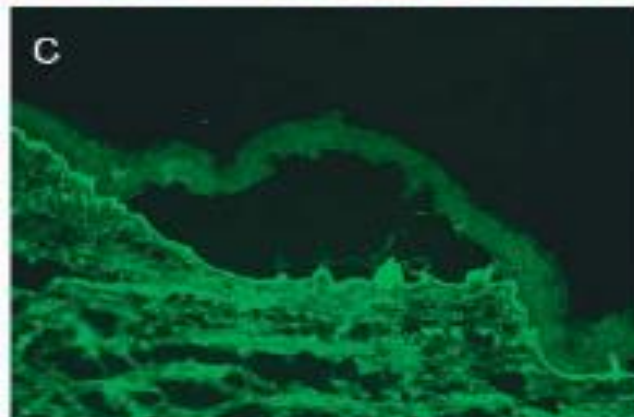


Pemphigus vulgaris
Desmoglein 3

Pemphigus foliaceus
Desmoglein 1



Bullous pemphigoid
Mucous membrane pemphigoid
Pemphigoid gestationis
Linear IgA dermatosis
Lichen ruber pemphigoides
BP180
BP230

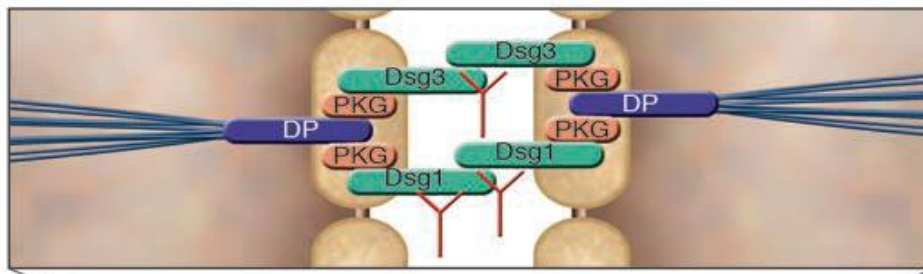


Mucous membrane pemphigoid
Laminin 332

Anti-p200 pemphigoid
Laminin γ 1

Epidermolysis bullosa acquisita
Type VII collagen

Pemphigus



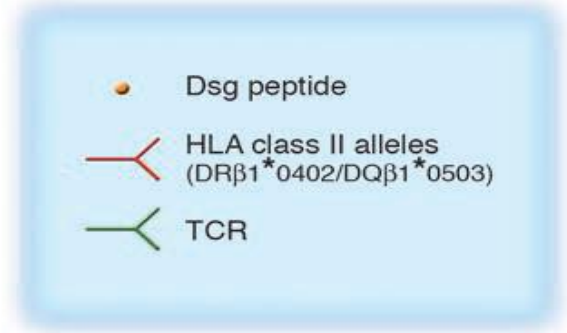
Desmosome

Stratum corneum

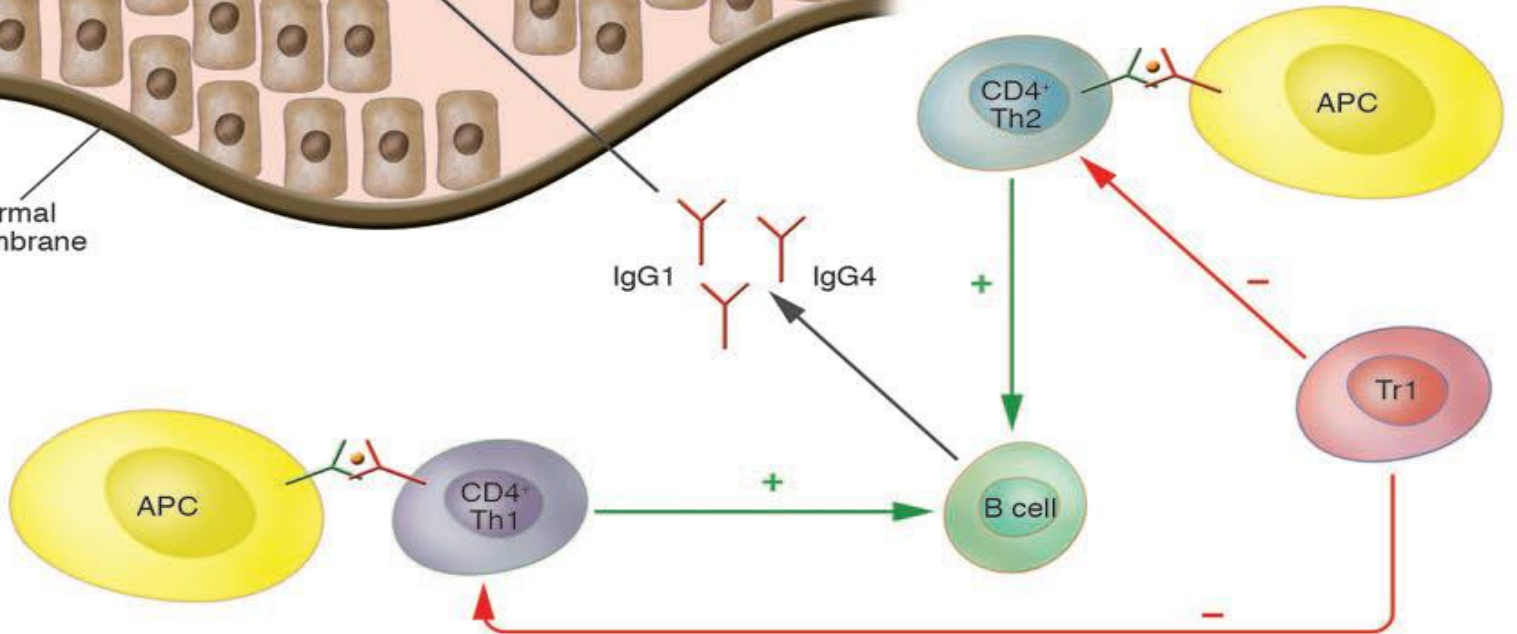
Epidermal keratinocyte

Epidermis

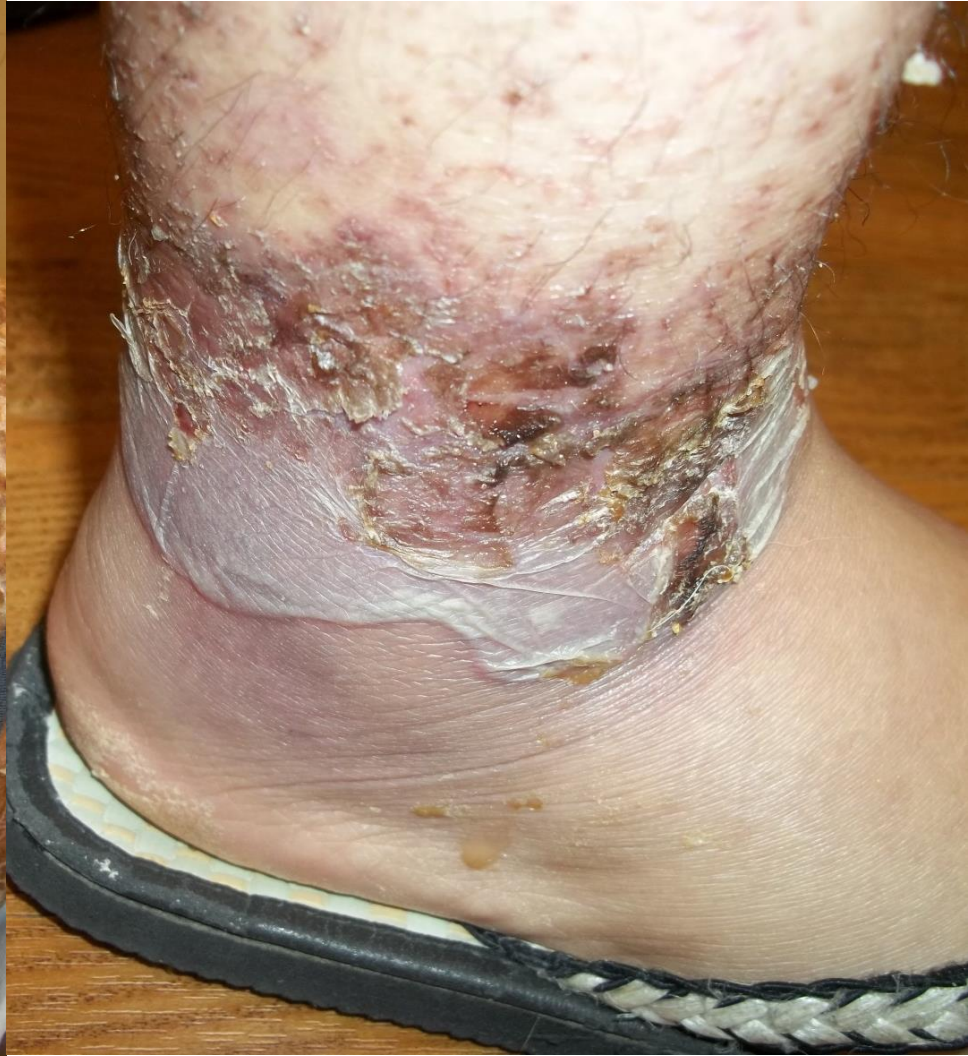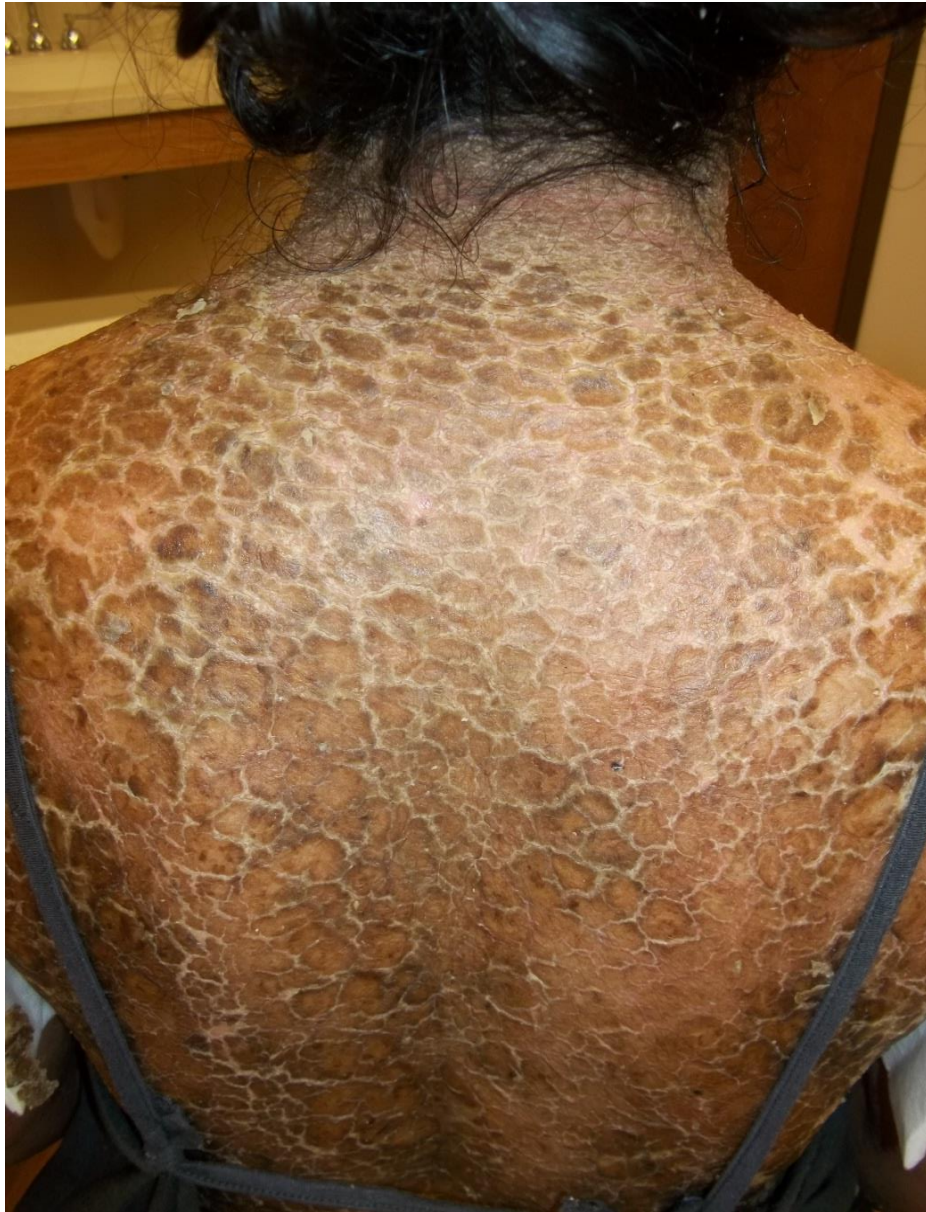Dermoepidermal basement membrane



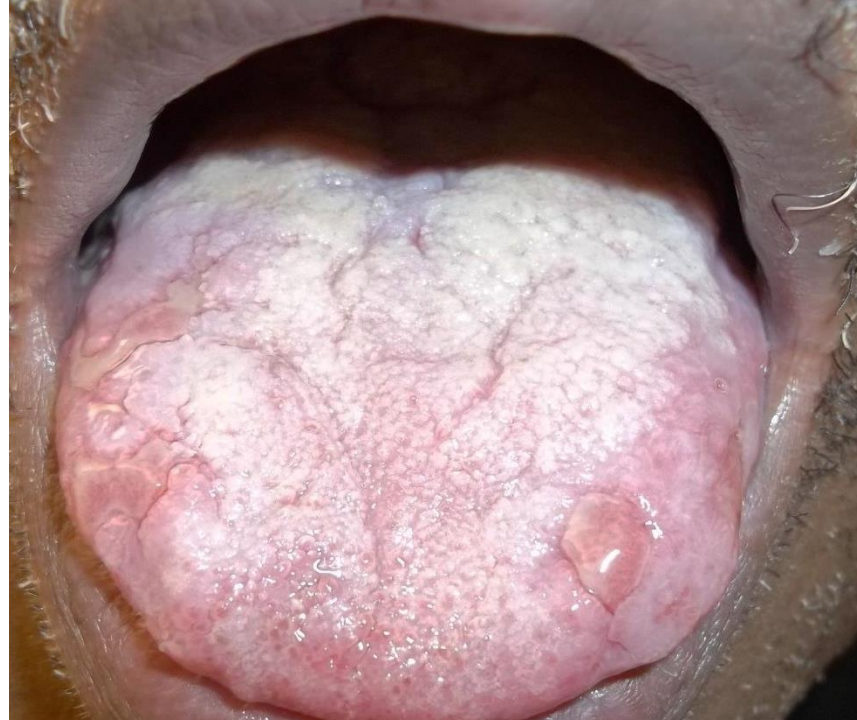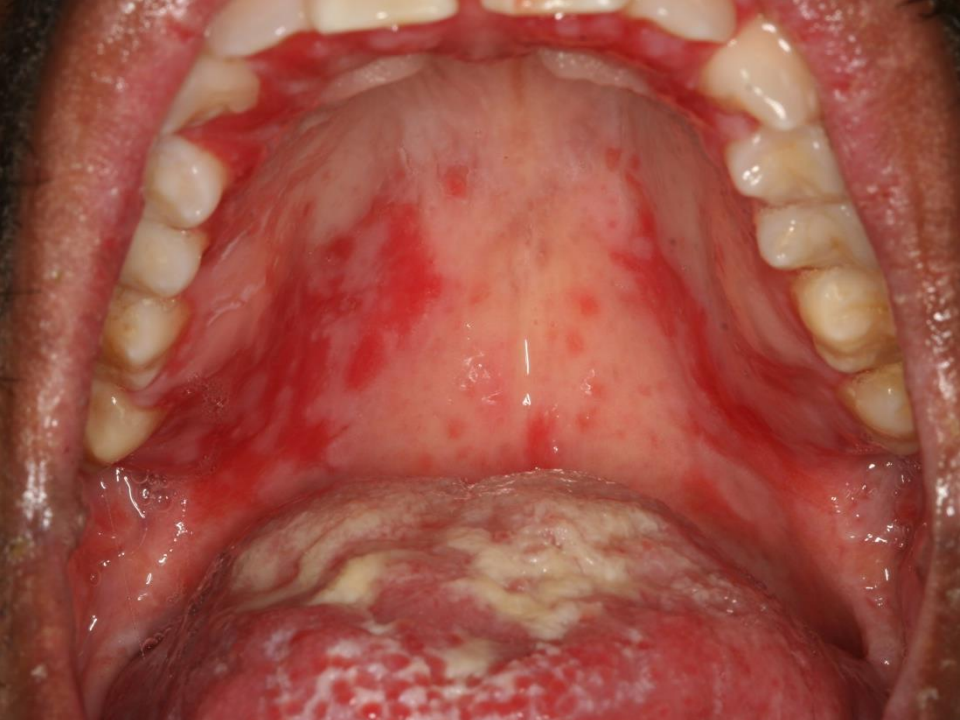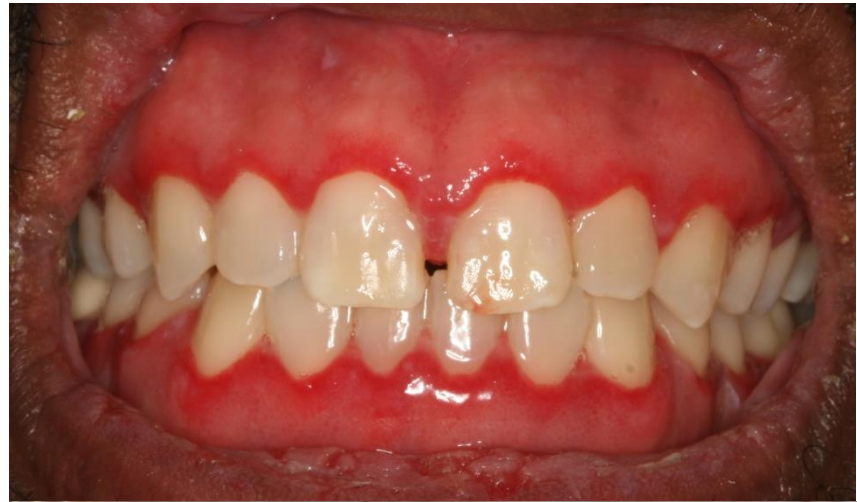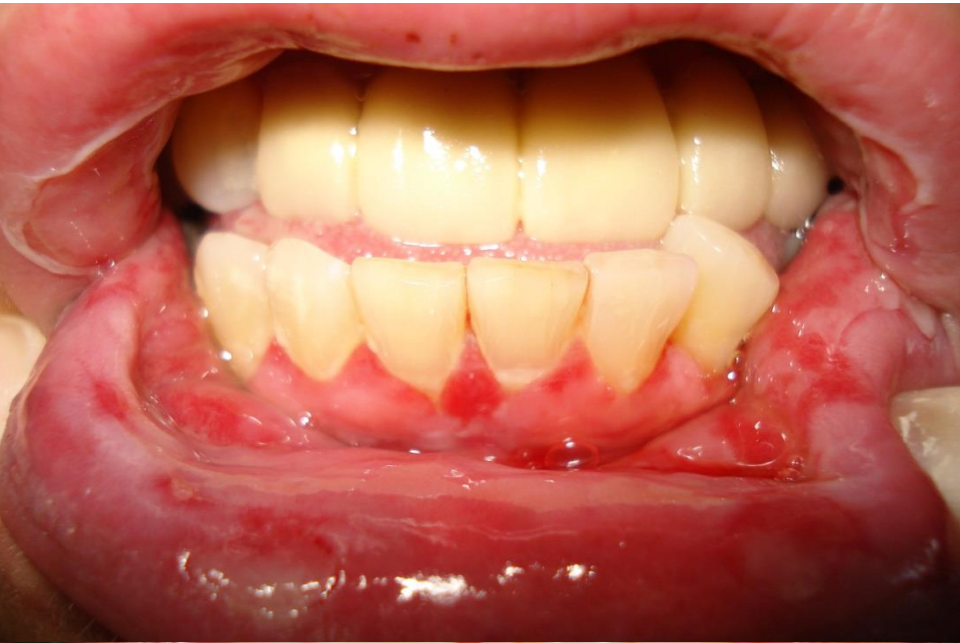Hertl M, Journal of Clinical Investigation, 2006



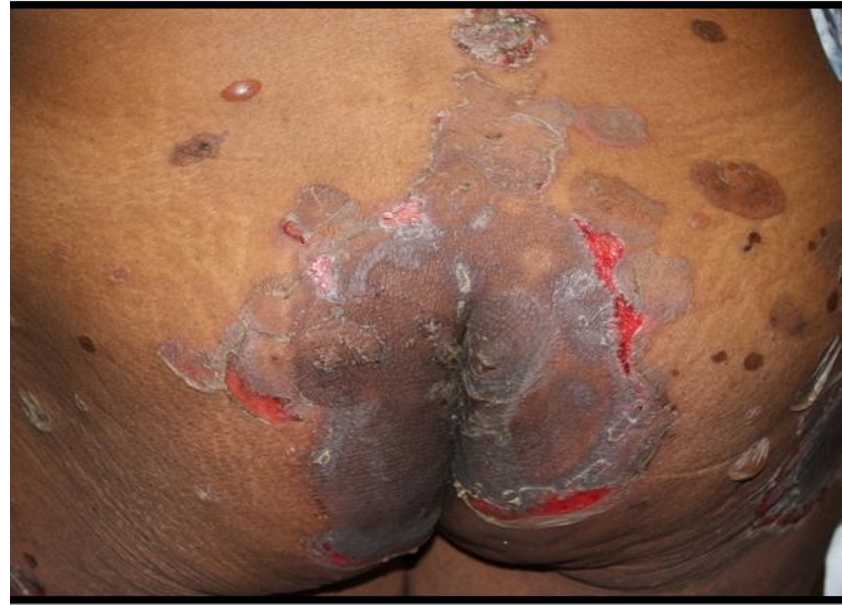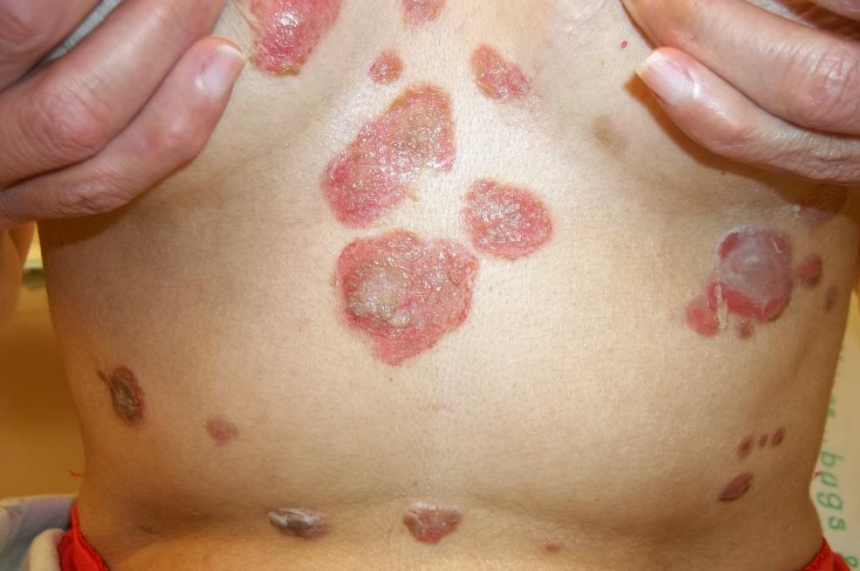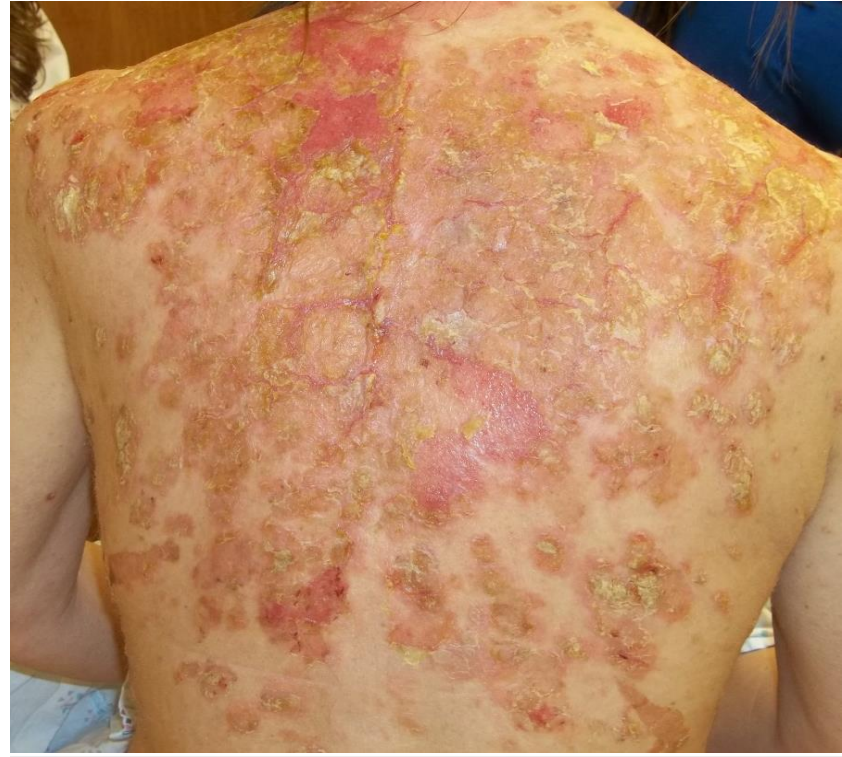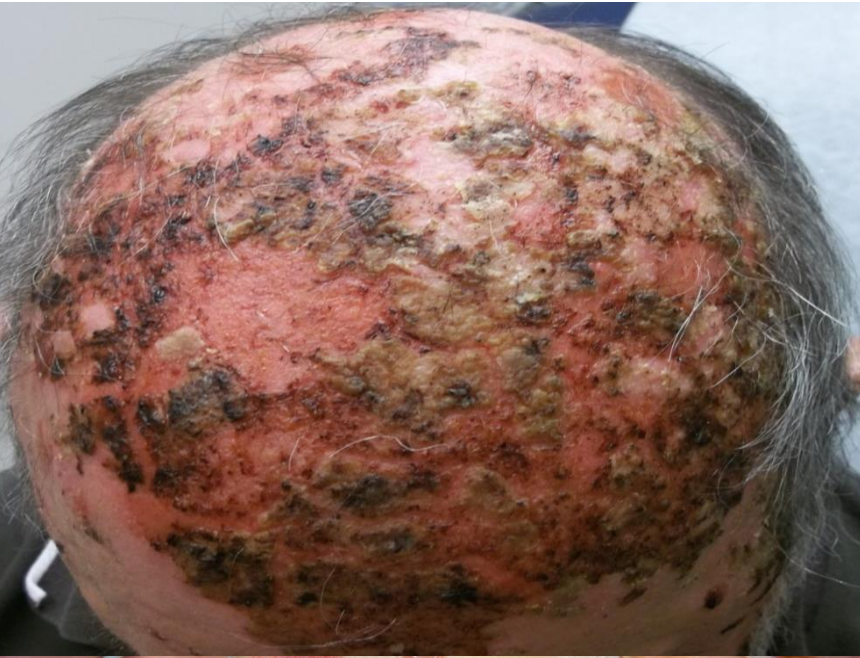
Pemphigus Foliaceus



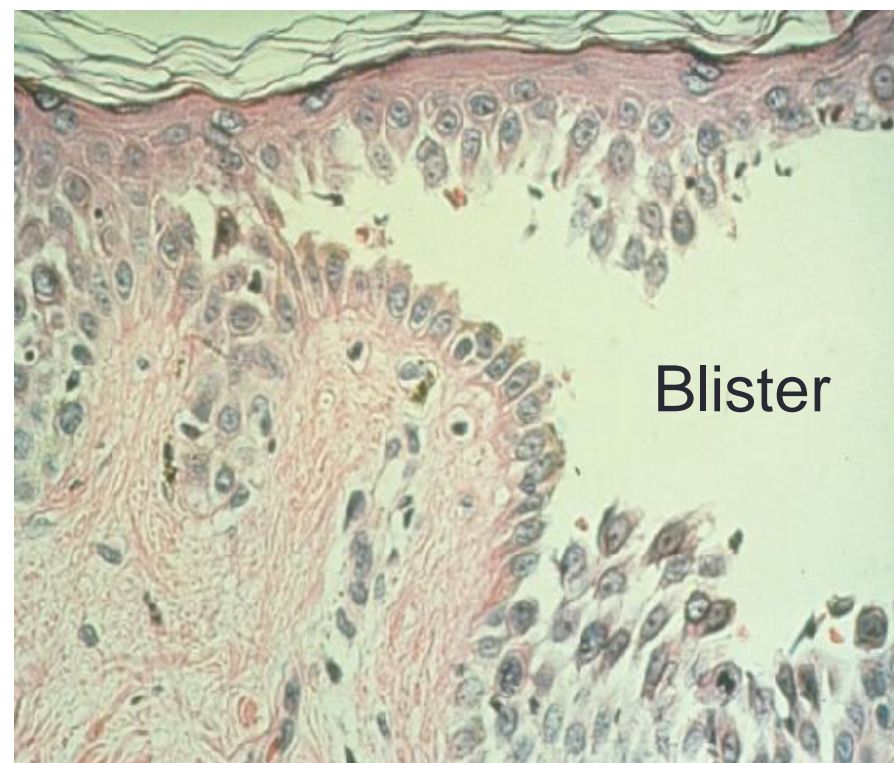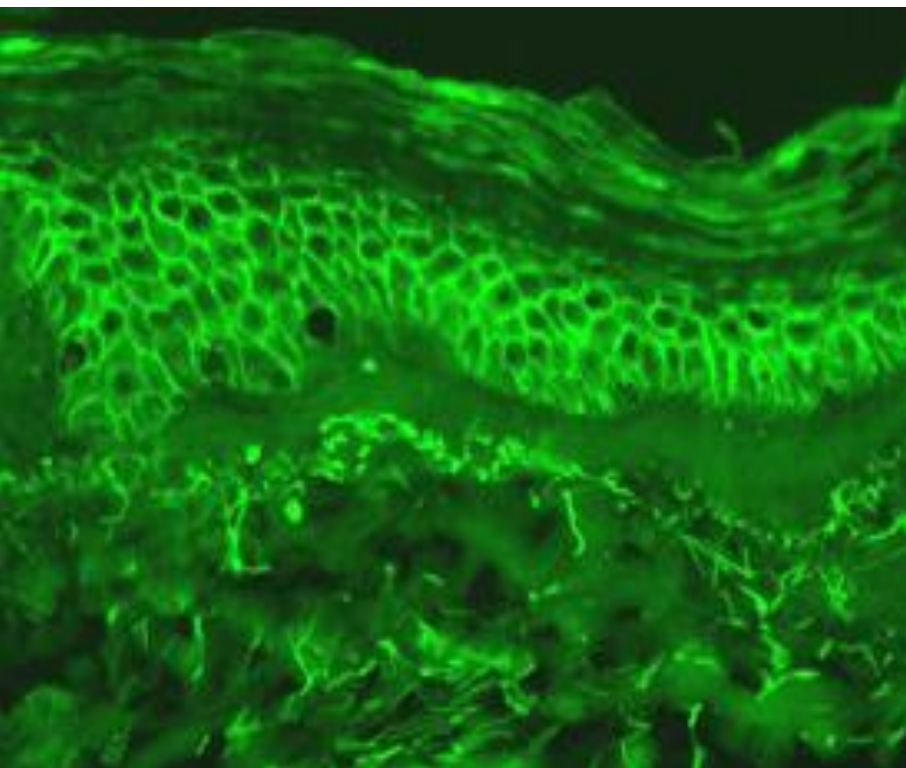
Pemphigus Vulgaris



Pemphigus Vulgaris



Direct Immunofluorescence—Intercellular IgG (IgA), C3

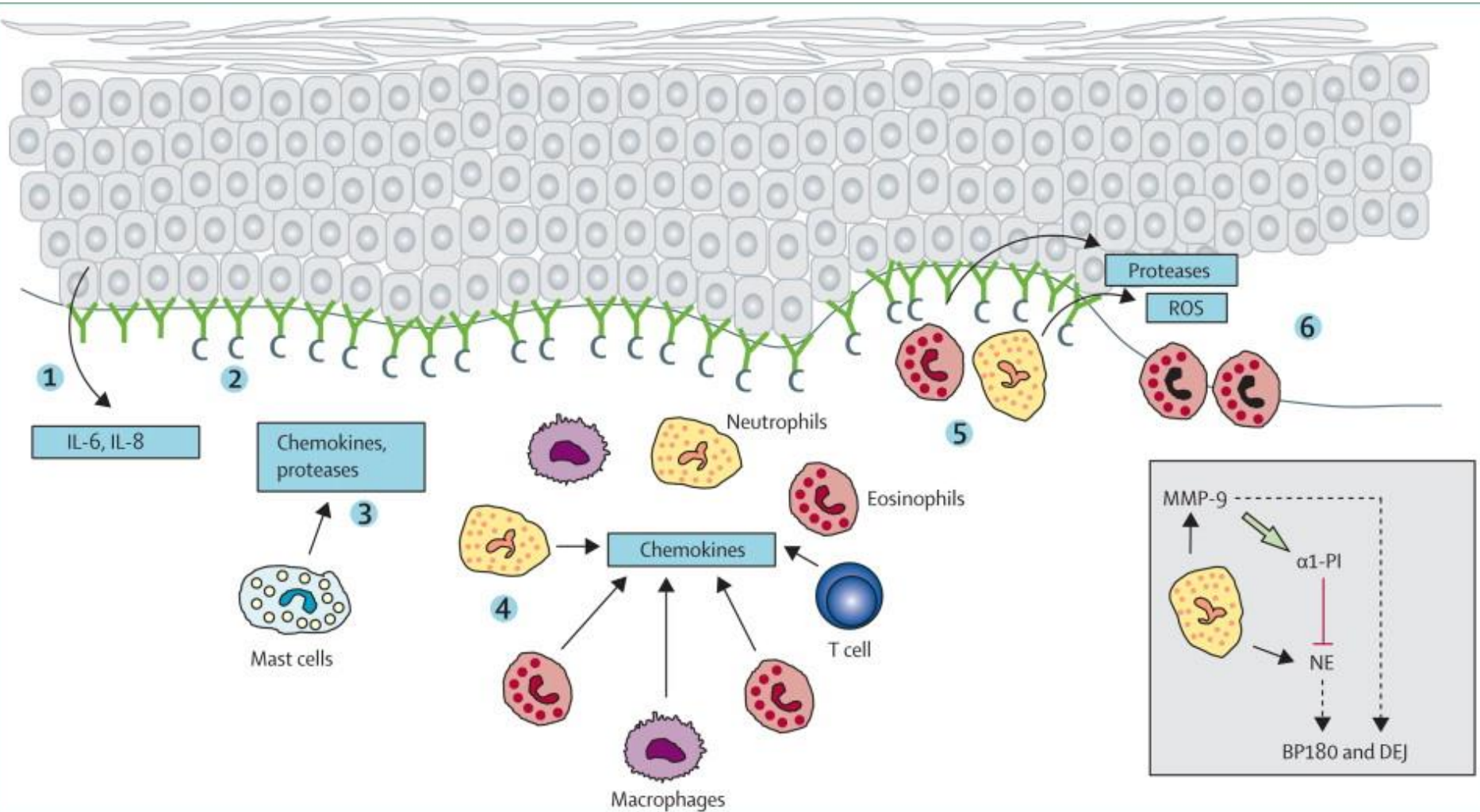


Pemphigus

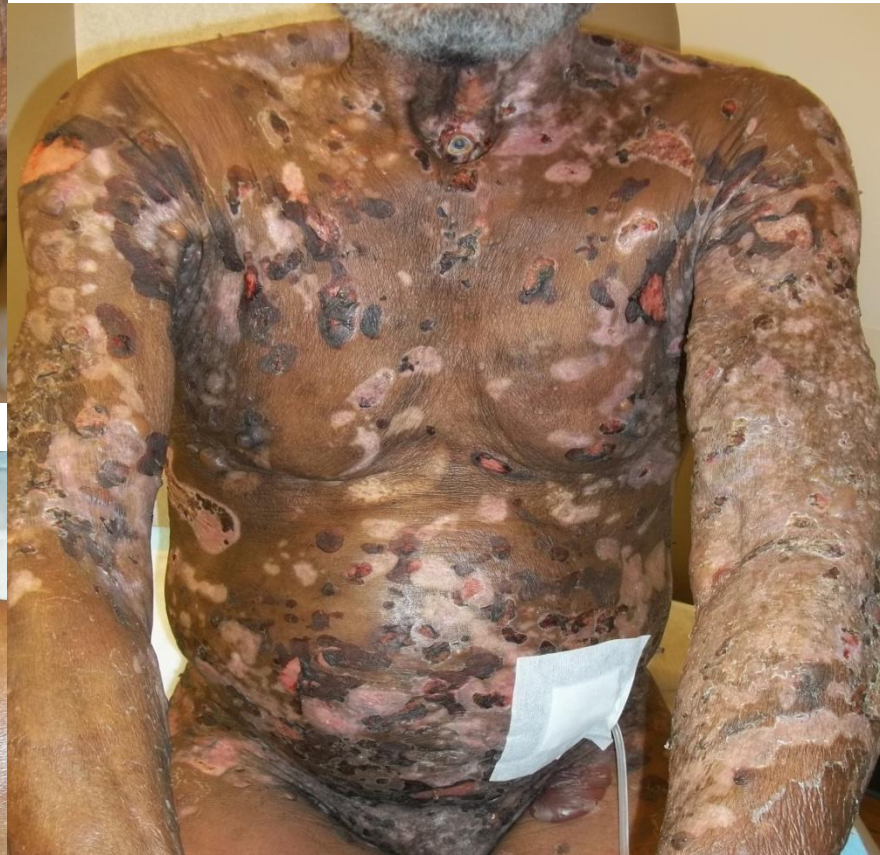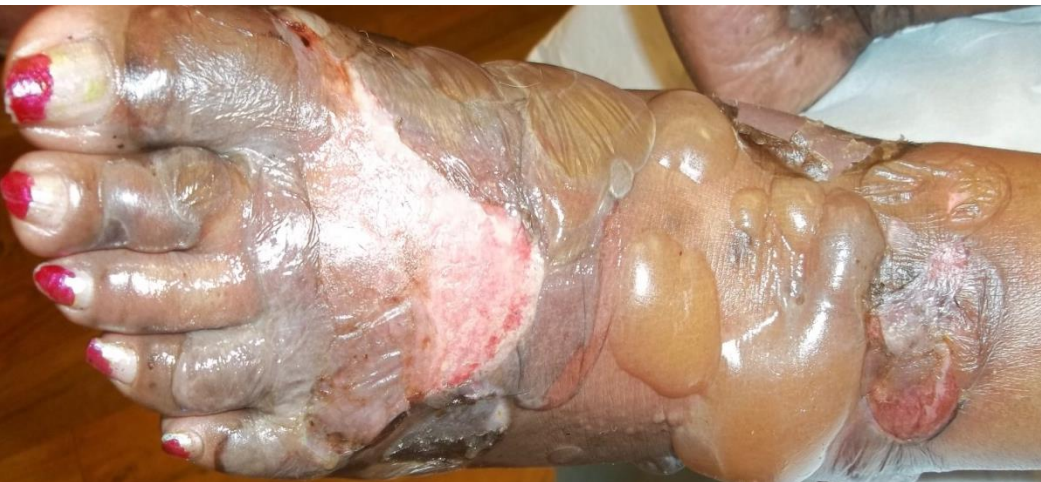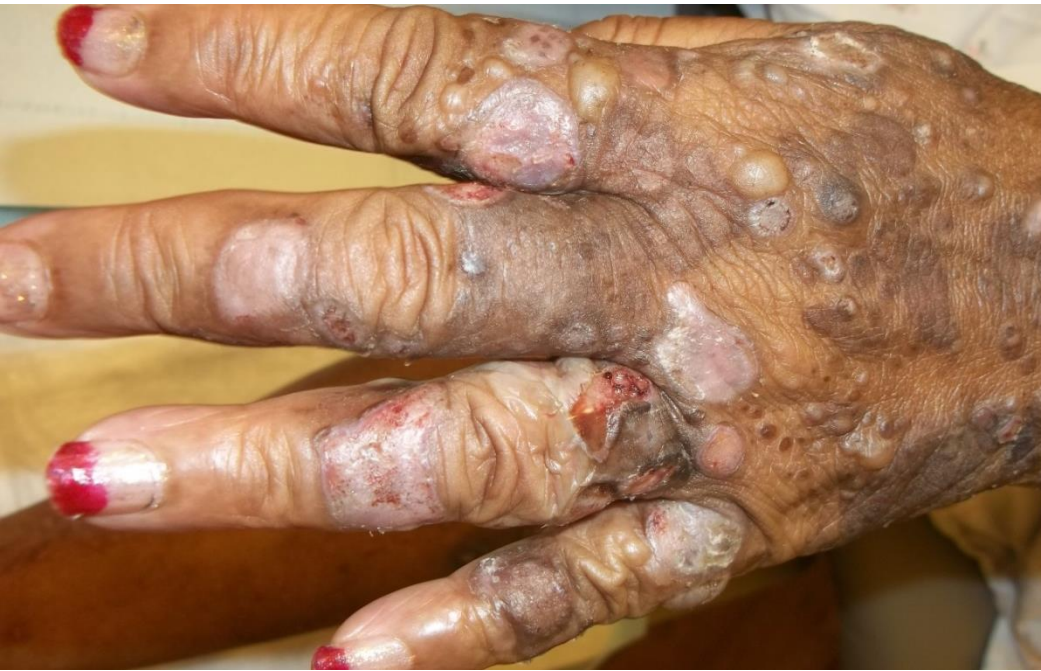Efficacy of Rituximab Therapy in Pemphigus

- Meta-analysis from 30 studies; 578 patients
- Complete Remission (CR) rates after one cycle: 76%
- Mean time to CR 5.8 months
- CR duration 14.5 months
- Relapse rate 40%
- Major adverse events: 3.3 %

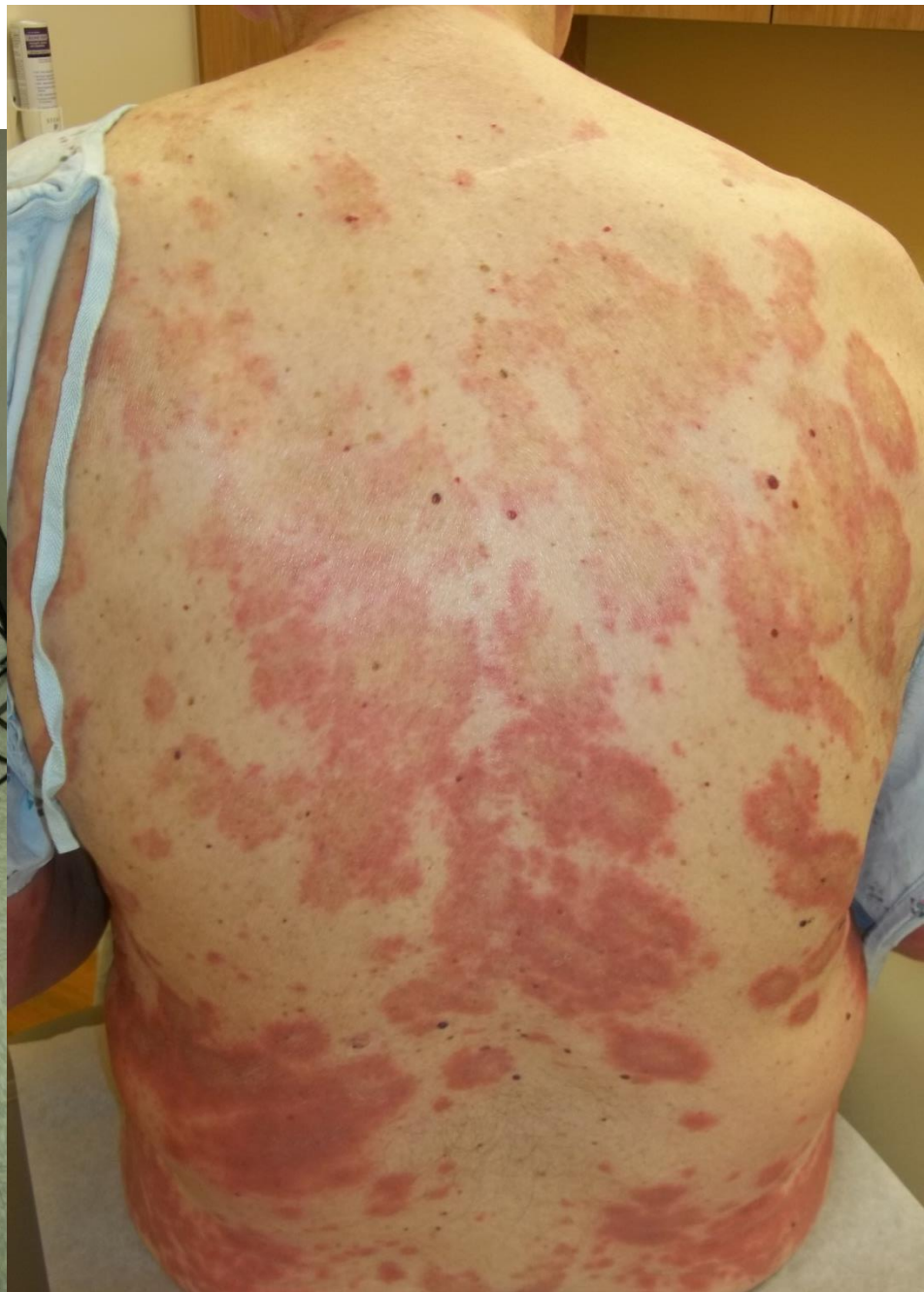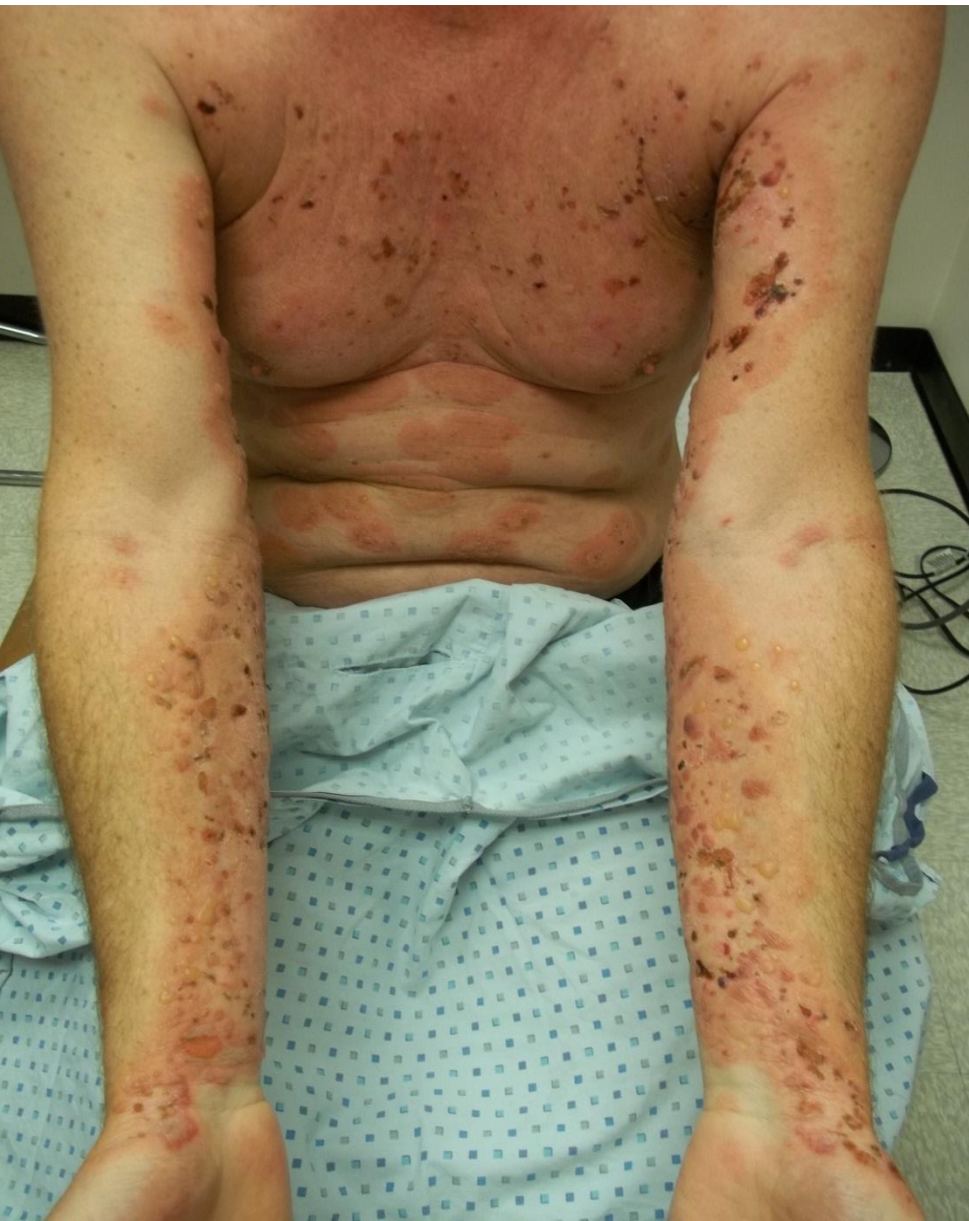Bullous Pemphigoid



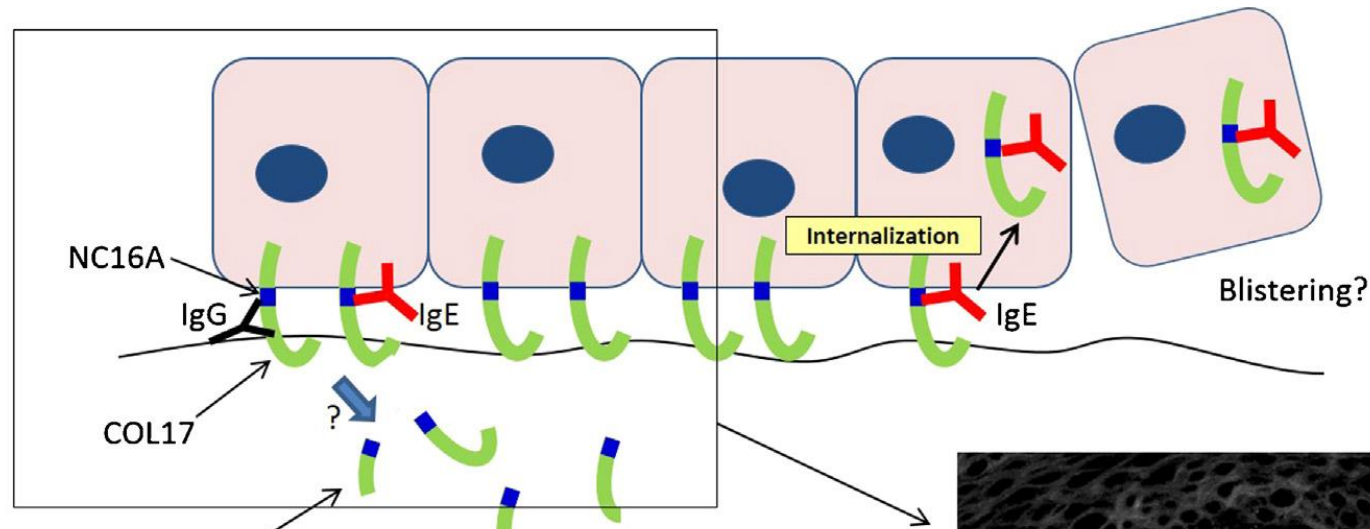
Bullous Pemphigoid



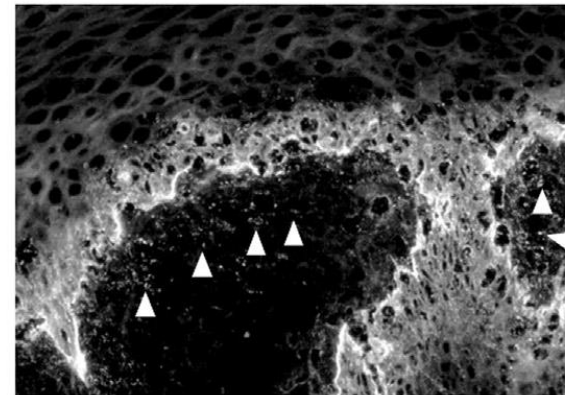
Bullous Pemphigoid



Role of IgE in Bullous Pemphigoid?



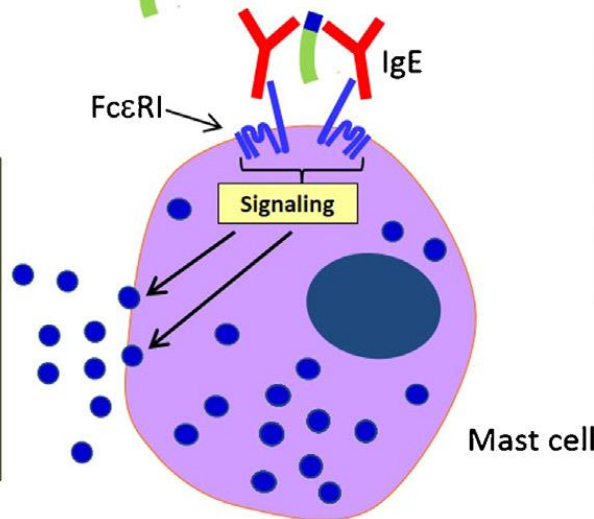
Released ectodomain of COL17



Immunostaining of COL17 on BP skin

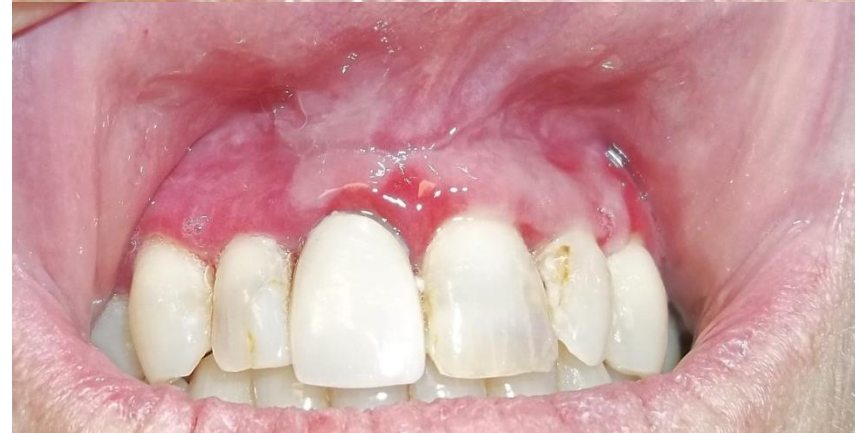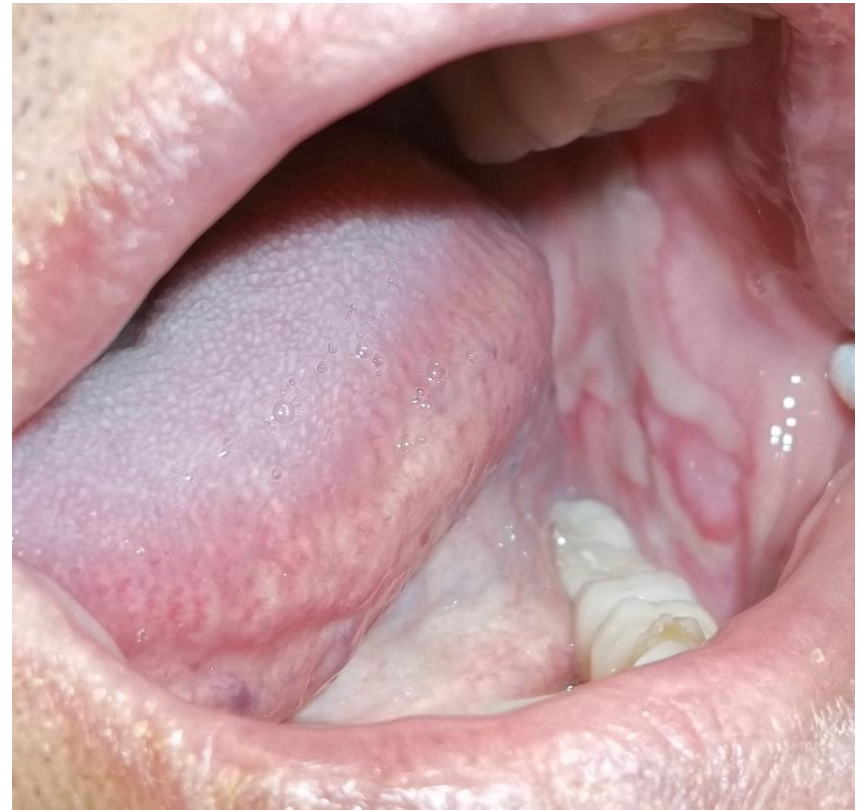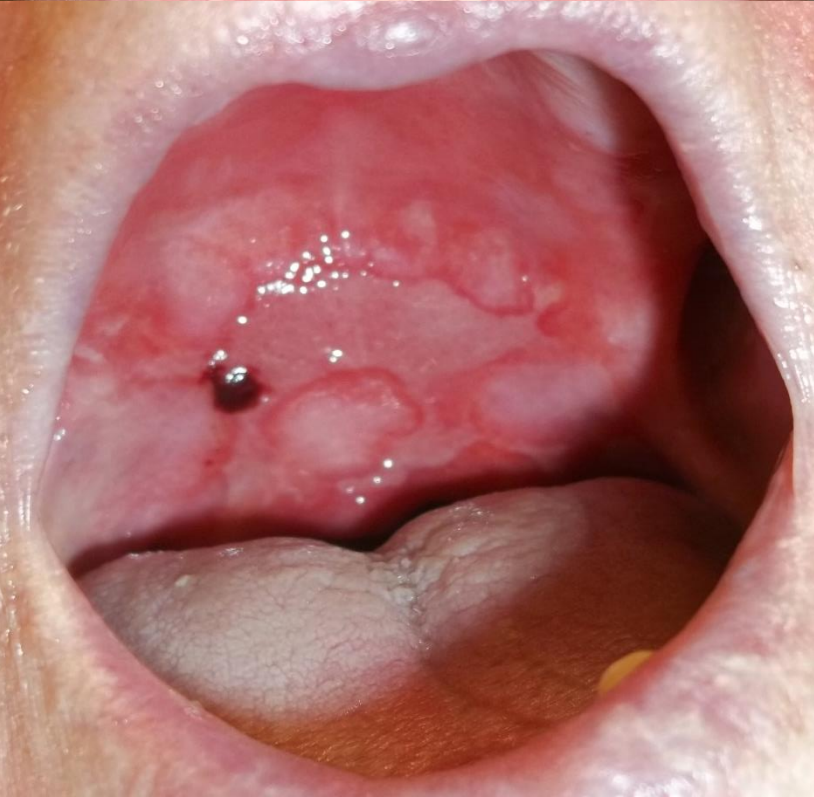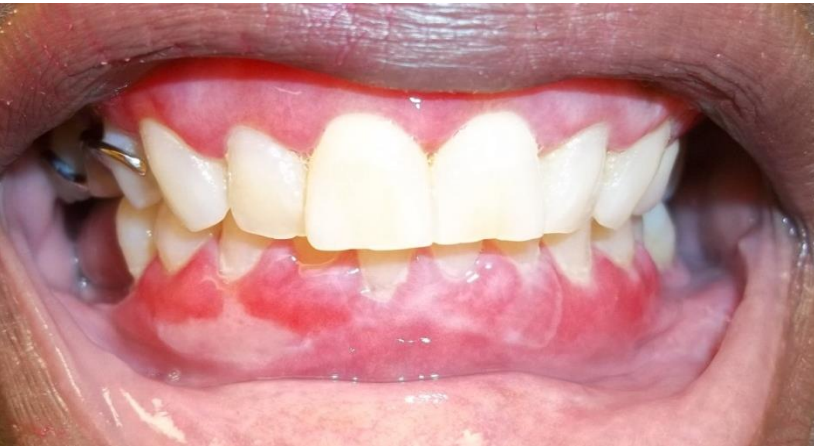- Degranulation**
- Histamines
 - Cytokines
 - Proteases
- de novo synthesis**
- Leukotriene
 - Prostaglandin
 - Platelet-activating factor

Vasodilation
Vascular permeability ↑
Leukocyte recruitment

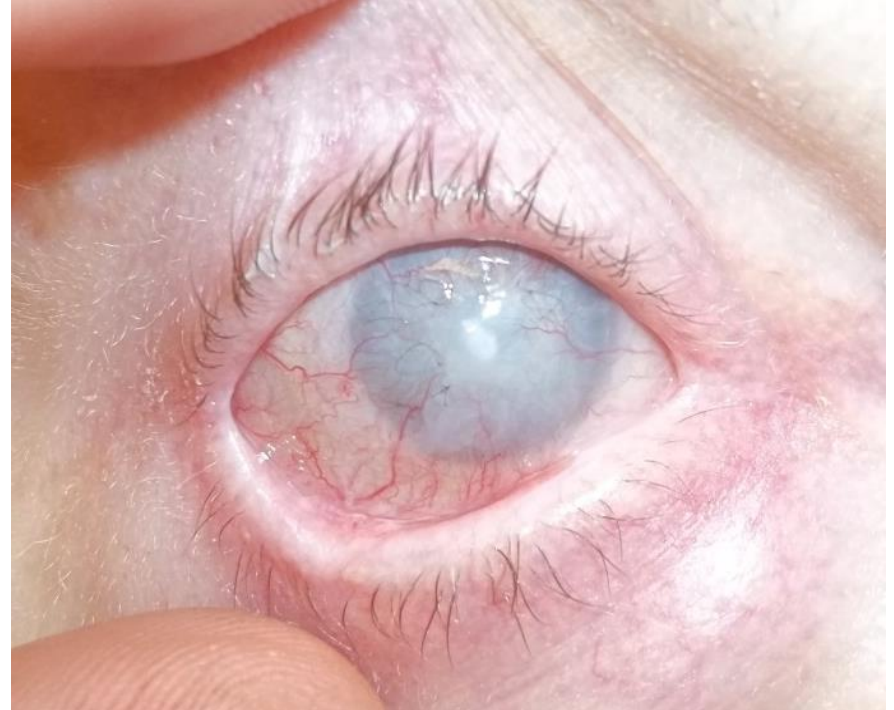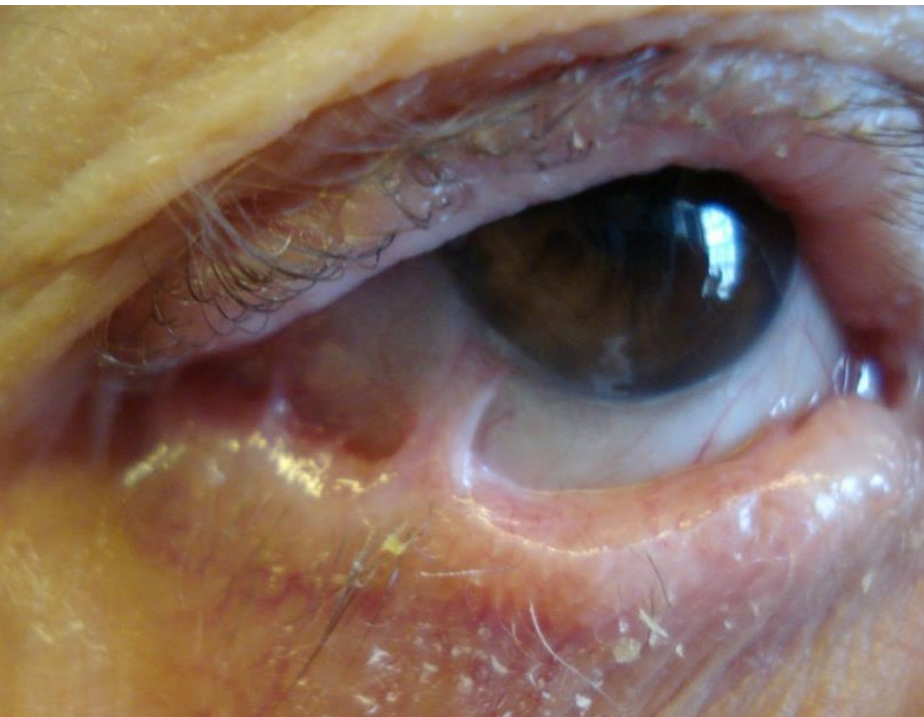
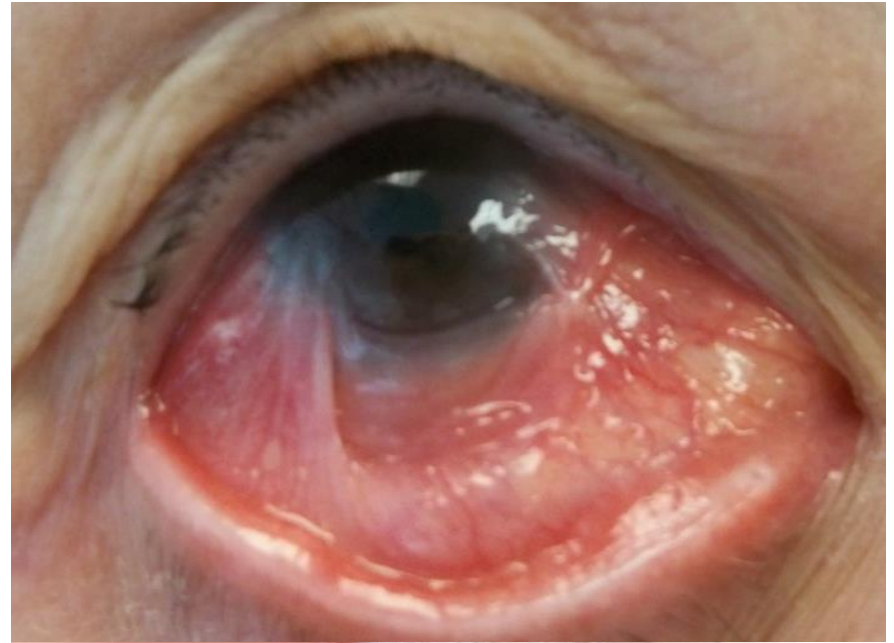


**Role for IgE Directed Therapies-
Omalizumab?**

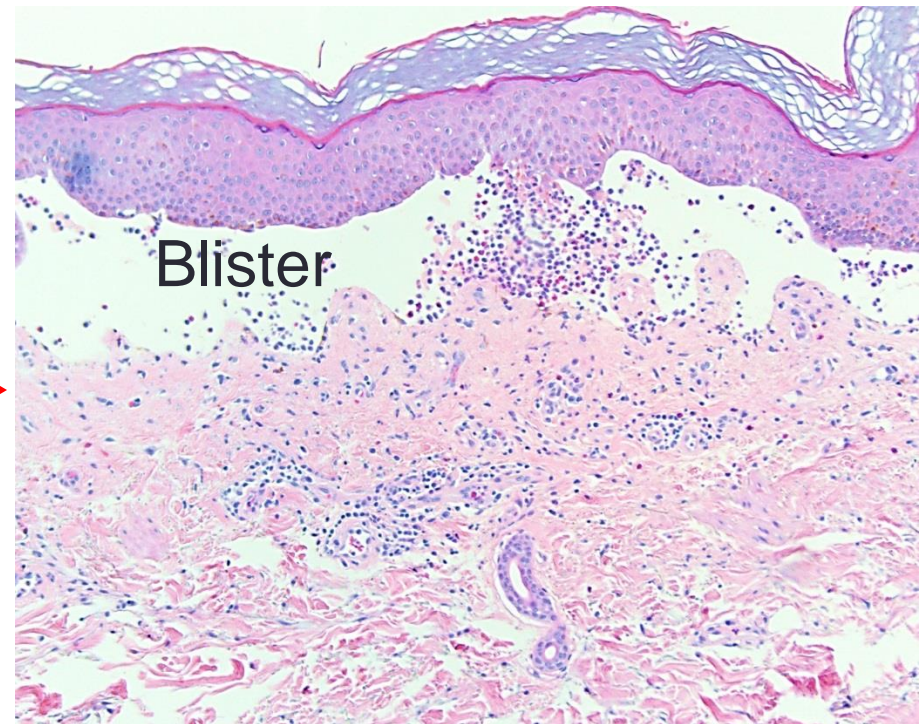
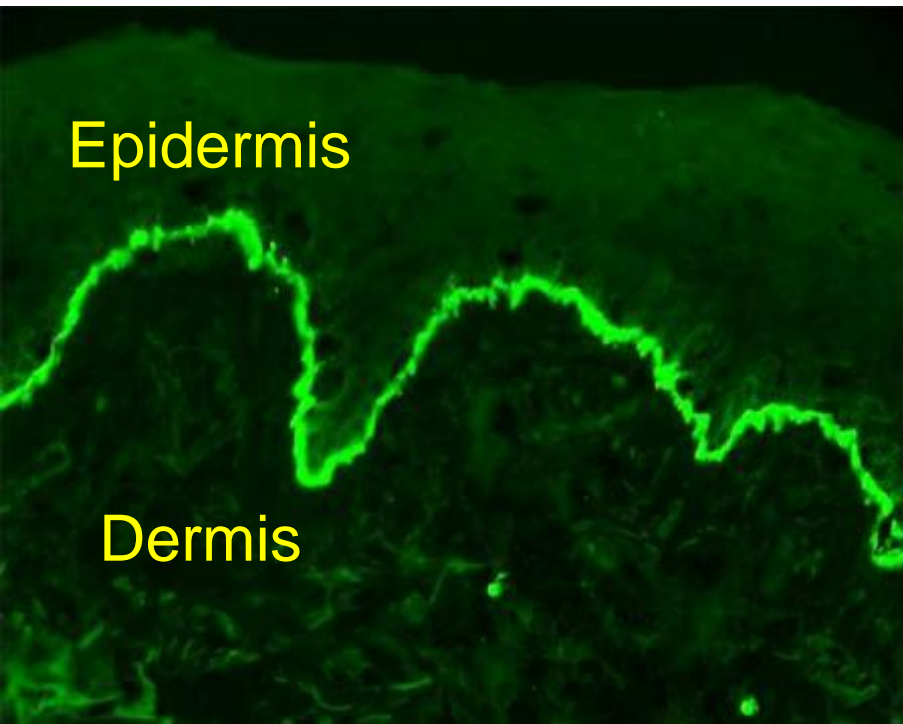
Mucous Membrane Pemphigoid



Mucous Membrane Pemphigoid +/- Ocular Cicatricial Pemphigoid



Linear IgG (IgA/IgM)/C3 at Basement Membrane Zone



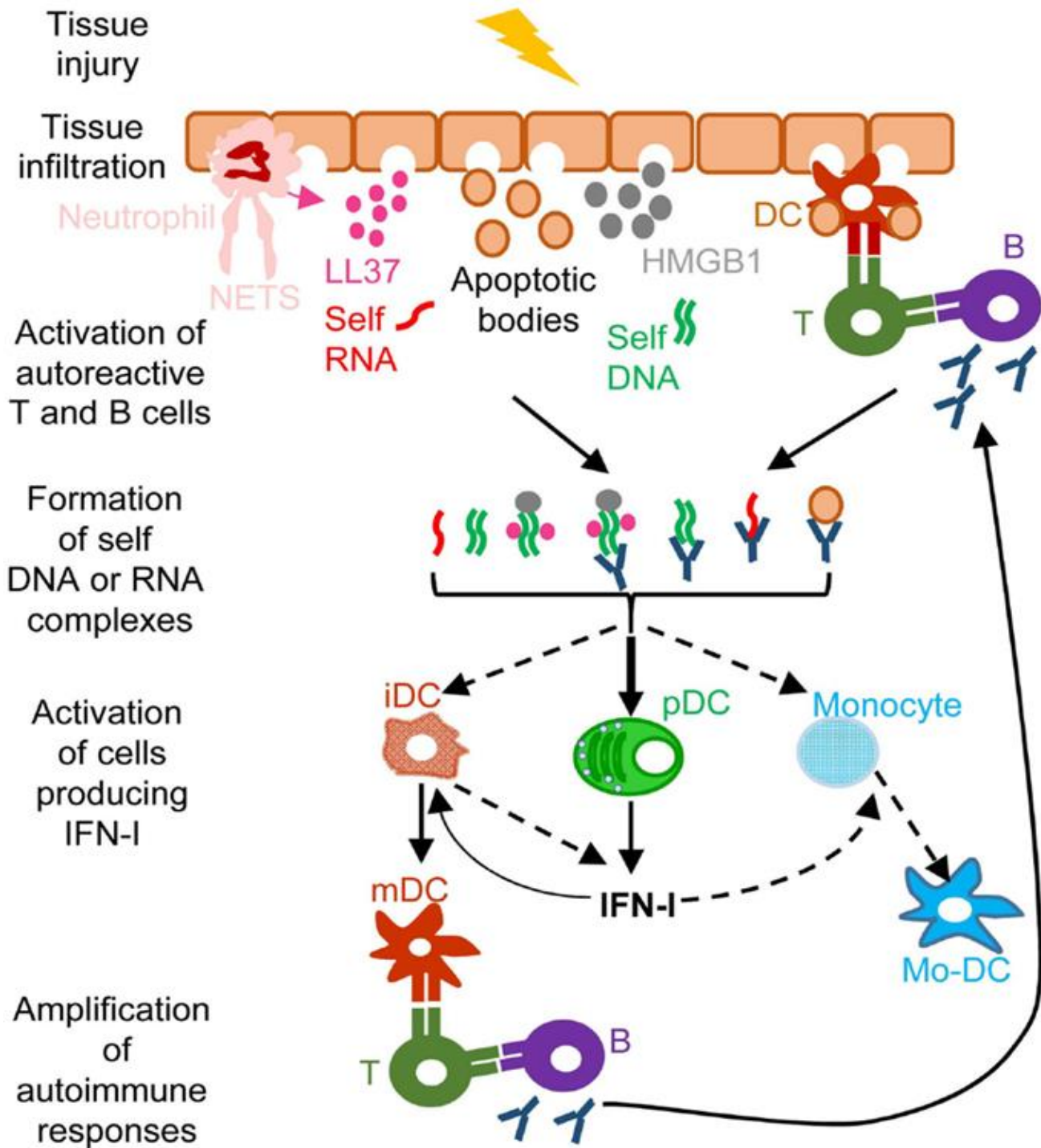
Subepidermal Blistering Diseases

Development of Autoimmunity

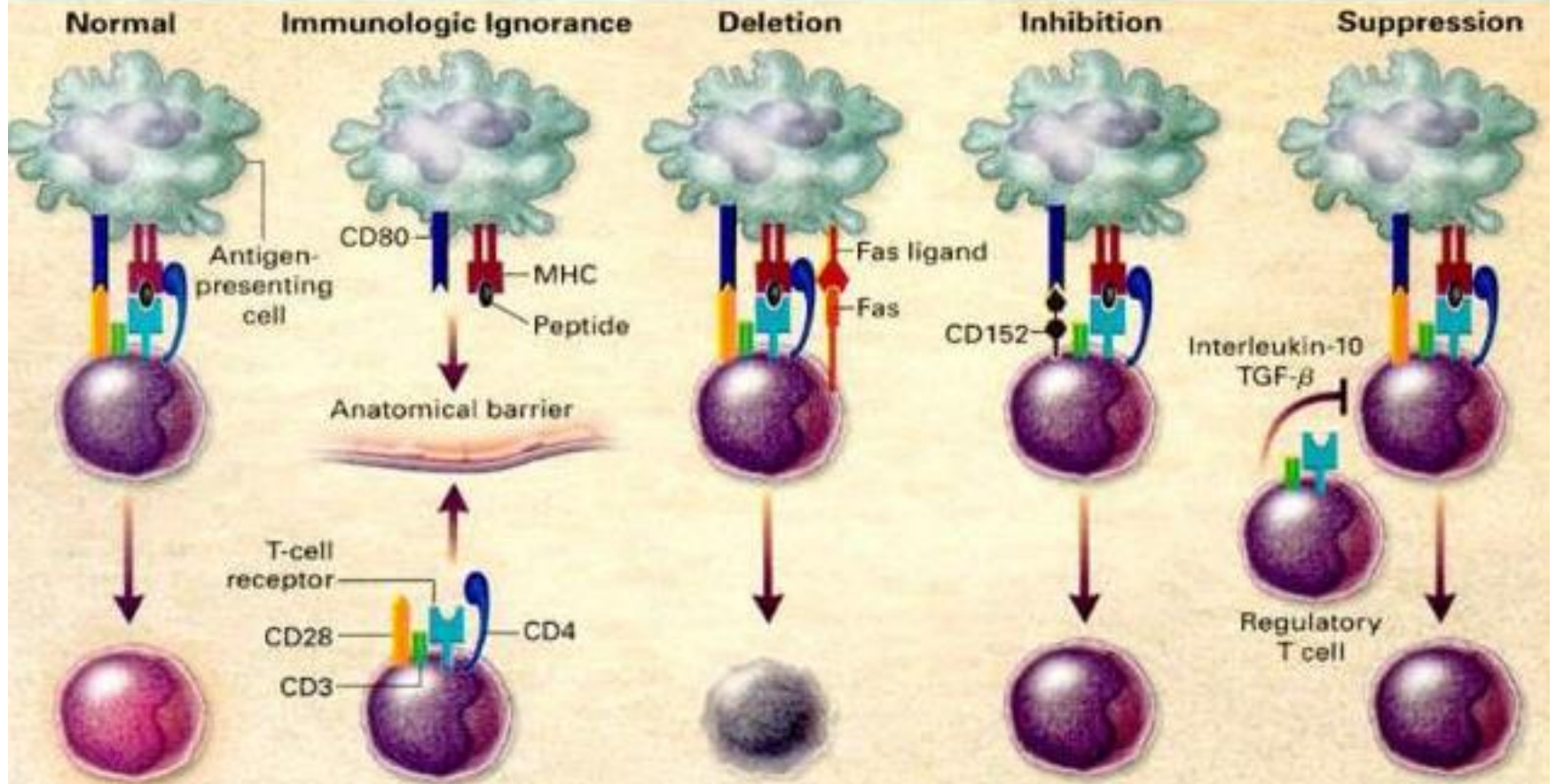
Genetic Susceptibility

Biologic Therapies

Tomasello E et al, Front Immunology, 2014



Pathways to Peripheral Tolerance



Activated T Cell

Indifferent T Cell

Dead T Cell

Sleeping T Cell

Suppressed T Cell

Genetic Susceptibility for Autoimmune Diseases

**Survey based registry; 61/393 (15.5%)
Patients with Pemphigus**

| | |
|------------------------------|------------|
| Thyroid Disease | 59% |
| Rheumatoid Arthritis | 24.6% |
| Psoriasis | 13.1 |
| Diabetes Type 1 | 8.2 |
| Ulcerative colitis | 3.3 |
| Vitiligo | 3.3 |
| Alopecia areata | 1.6 |
| Systemic lupus erythematosus | 1.6 |

Prevalence of Autoimmunity

- 295 pemphigus patients
- Comparing to age-standardized prevalence ratios (SPRs) in Canadian general population
 - Higher prevalence in pemphigus group
 - Thyroid disease : 1.53 (1.08-2.10)
 - Diabetes: 2.20 (1.64-2.87)
 - Inflammatory Bowel Disease: 1.48 (0.4-3.80)
 - Lower prevalence in pemphigus group
 - Rheumatoid arthritis: 0.74 (0.36-1.36)

Coexistence of AIBD and Psoriasis

- Retrospective cohort of 145 cases in Japan

| | | <u>BP</u> | <u>Laminin γ1</u> |
|--------------------------|-----|-----------|-------------------------------------|
| • Psoriasis vulgaris | 122 | 80 | 43 |
| • Pustular psoriasis | 13 | 5 | 8 |
| • Psoriatic erythroderma | 7 | 4 | 3 |
| • Psoriatic arthritis | 3 | 3 | 0 |

Bullous Pemphigoid

- Data from National Inpatient Sample, 2002-2012 (~72 million adults)
 - 2180 Primary diagnosis; 11234 Secondary Diagnosis
 - Commonly associated autoimmune diseases (Odds ratios/OR)
 - Cushing syndrome 10.72 (1.5-76.73)
 - Hidradenitis suppurativa 6.76 (1.68-27.17)
 - Systemic lupus erythematosus 8.68 (4.77-15.79)
 - Multiple sclerosis 4.07 (3.22-5.14)
 - Rheumatoid arthritis: 1.26 (1.12-1.42)
 - Hypothyroid: 1.21 (1.13-1.30)

Autoimmune Phenomenon

Targeted Biologic Therapies:

Checkpoint Inhibitors Targeting PD-1 and PD-L1

- Bullous pemphigoid

Following Rituximab Therapy for Pemphigus

- Psoriasis
- Sarcoid
- Multiple Sclerosis*

Guidelli G, Rheumatol Int 2013

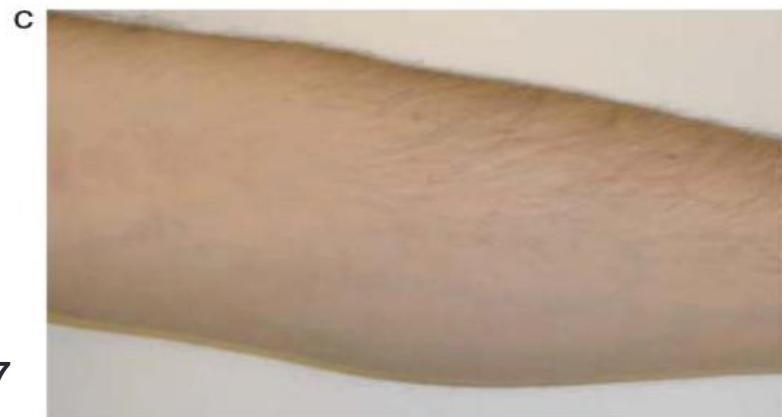
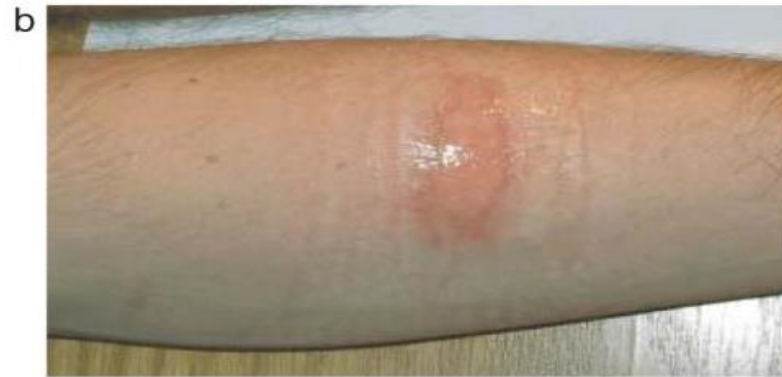Nadoo J et al, Cancer Immunology Research 2016

Galimberti F, Fernandez A, Clin Exp Dermatol 2016

*Unpublished observations

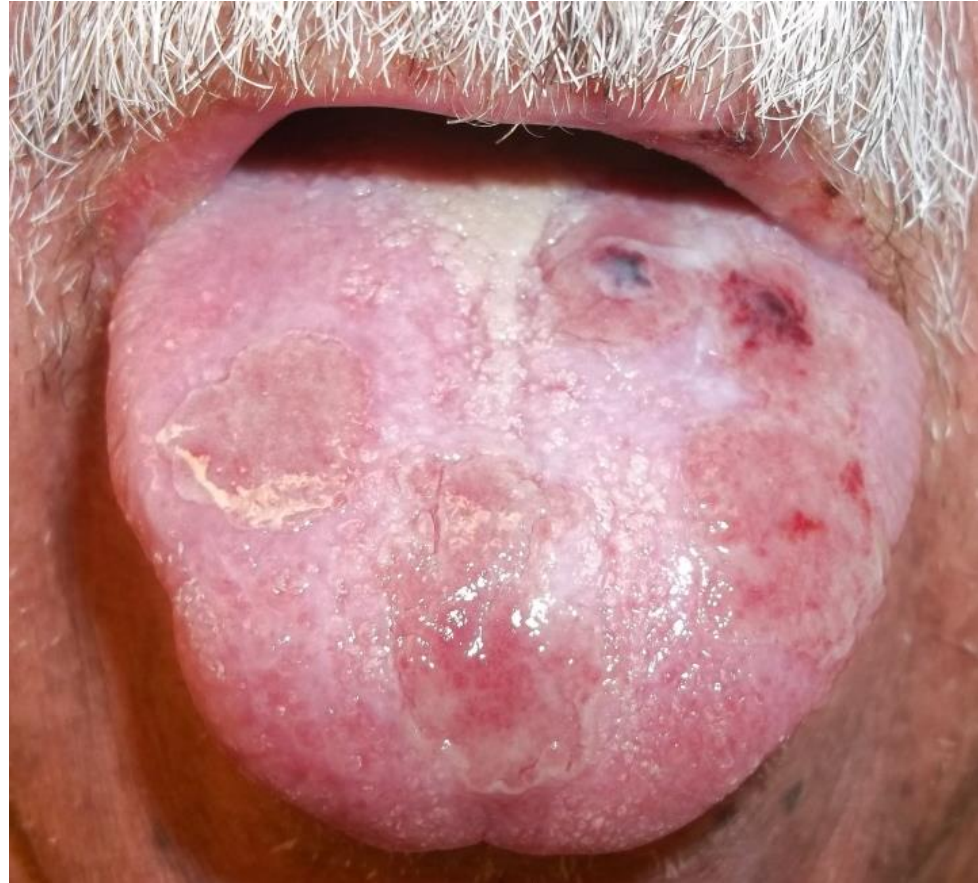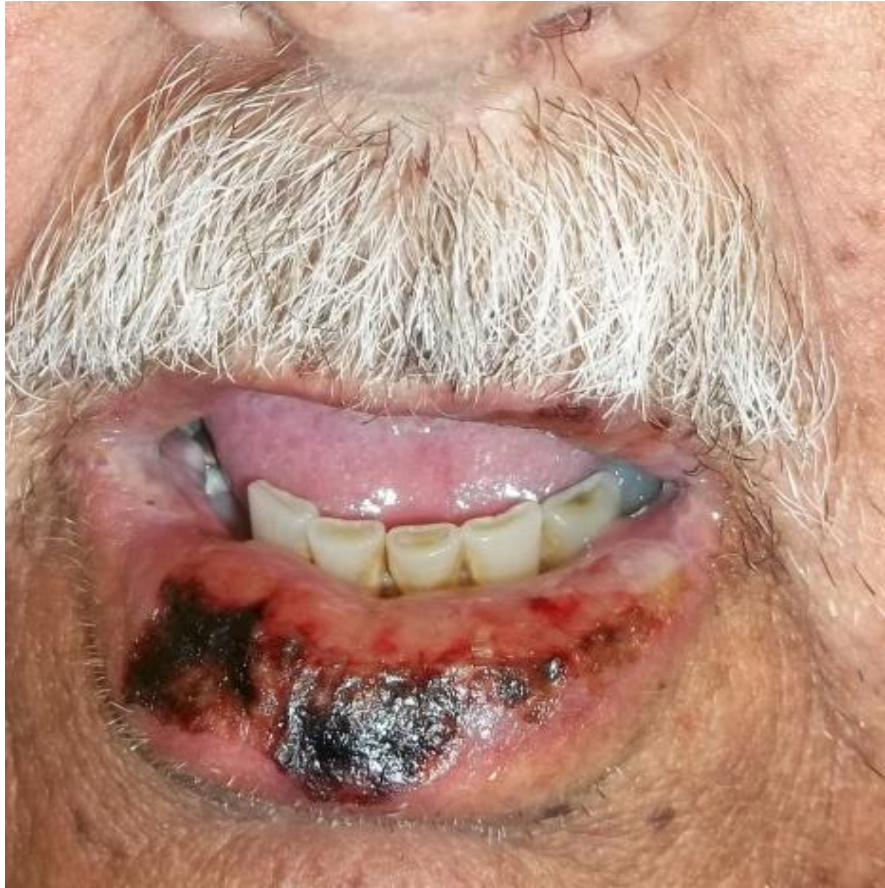Skin Windows →

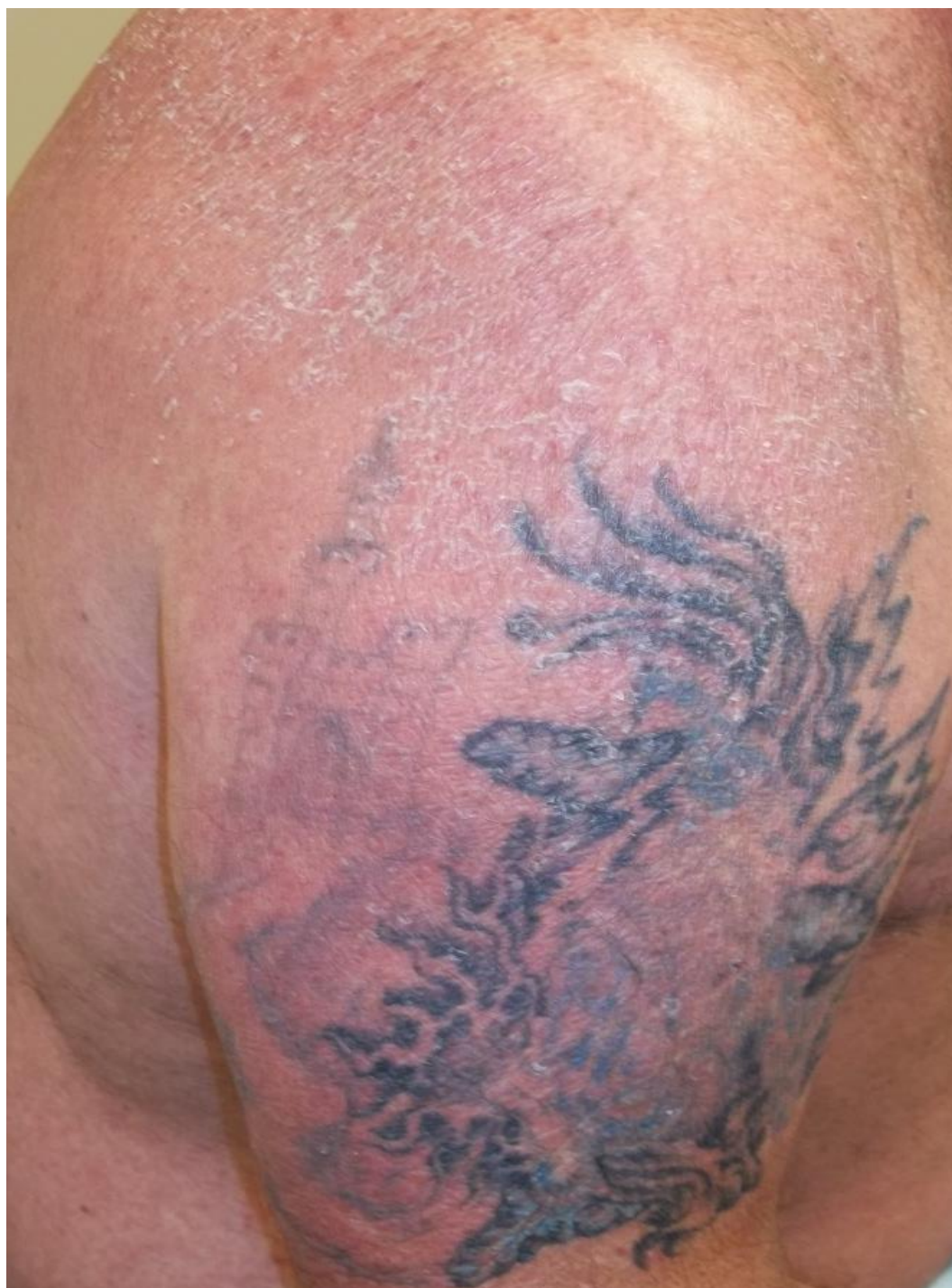“ Bullous Window to Systemic Disease”



Case History

- 66 year old male presented with worsening skin rash and oral erosions
 - History of chronic lymphocytic leukemia in 2008
 - Treated with fludarabine, cyclophosphamide and rituximab
 - Remission until Spring 2013
 - Developed axillary lymphadenopathy along with diffuse erythematous rash with areas of blistering
 - Retreated with rituximab in June 2013
 - Oral erosions with severe lip involvement; admitted for possible Steven's Johnson syndrome
 - Skin biopsies inconclusive
 - Treated with tapering courses of systemic corticosteroids

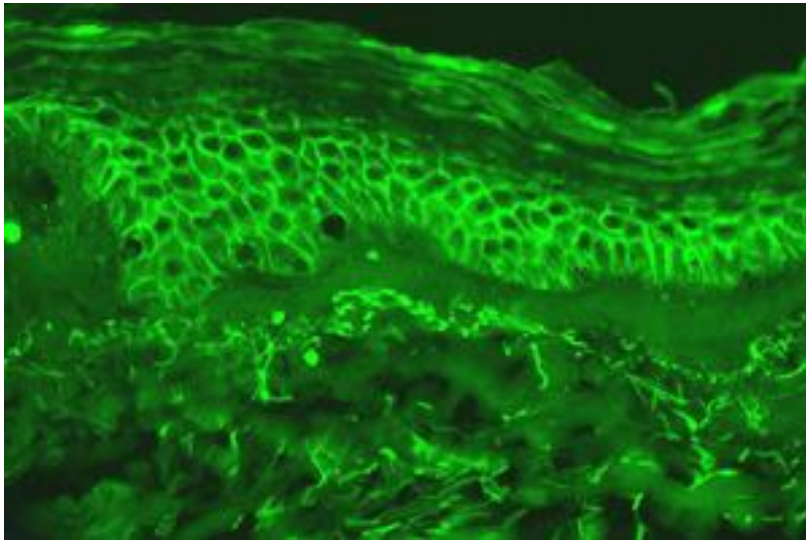




Paraneoplastic Pemphigus (PNP)

- Pemphigus in setting of malignancy:
 - NHL, CLL, Castleman disease, Thymoma, Retroperitoneal sarcomas
- Painful mucosal erosions with refractive mucositis
- Polymorphous skin eruptions
 - Blistering
 - Urticaria
 - Erythema multiforme
 - Lichen planus
- Cicatrizing conjunctivitis
- “Paraneoplastic autoimmune multiorgan syndrome”
- Confirm by histology--immunofluorescence

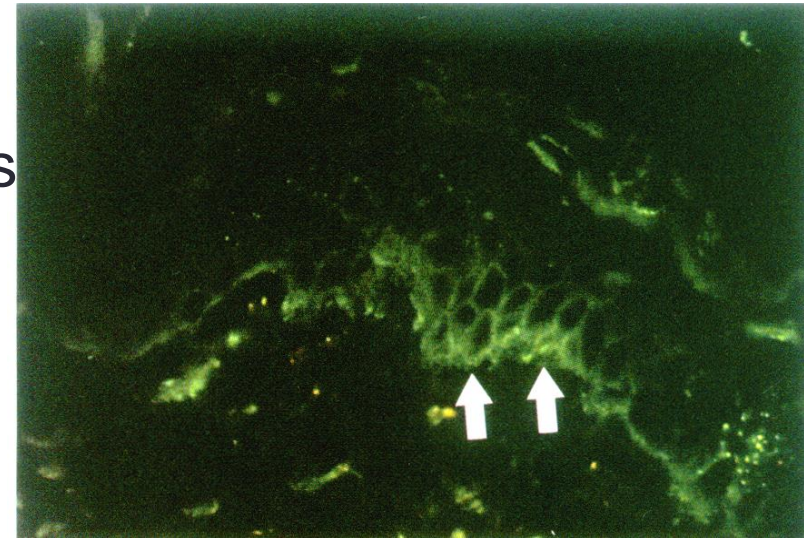
PNP



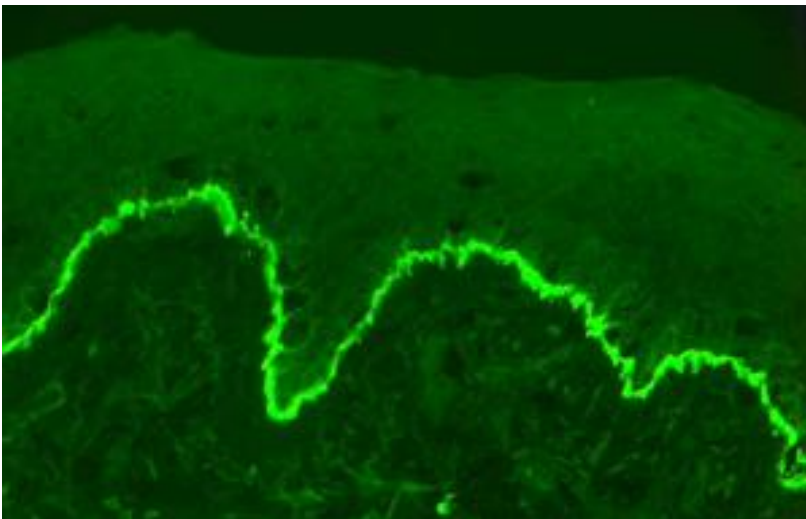
Epidermis



Dermis



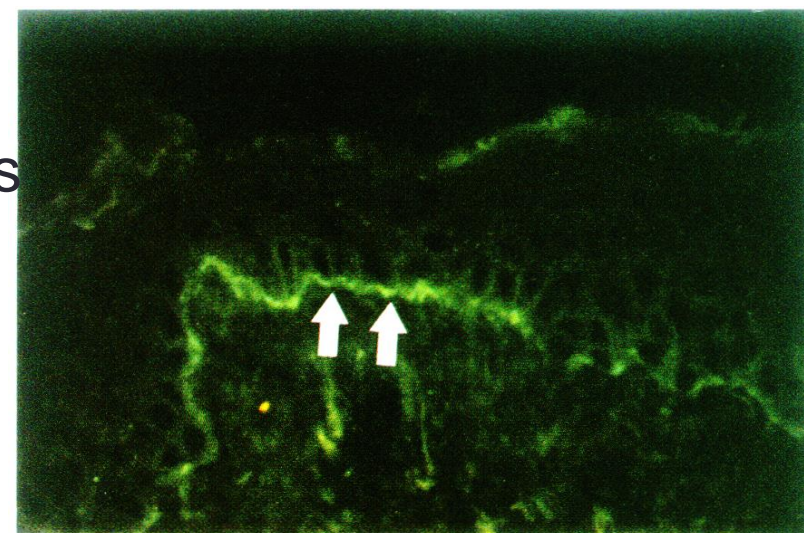
Can Look like both pemphigus and pemphigoid!



Epidermis



Dermis

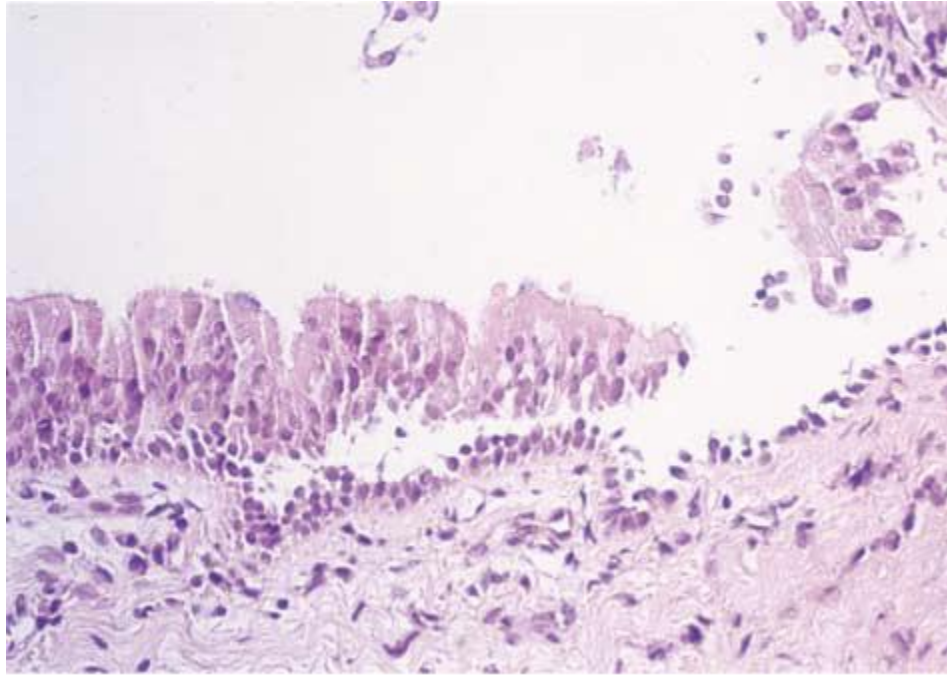


Anhalt G, et al, NEJM 1990

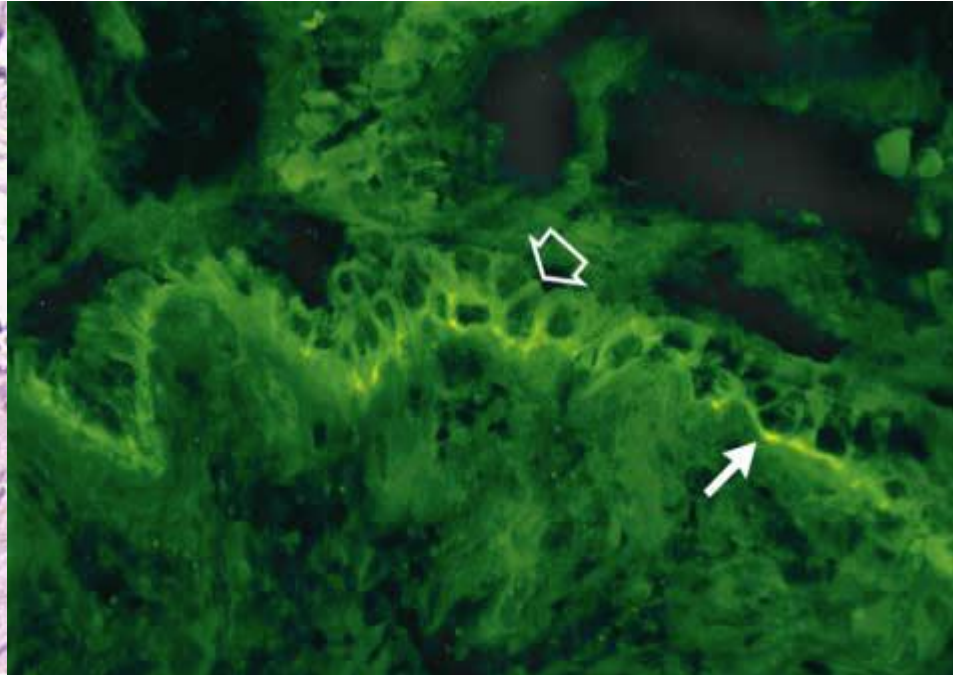
Paraneoplastic Pemphigus

- Pulmonary involvement later in course of disease in ~30% of patients
 - Respiratory failure
 - Features of bronchiolitis obliterans
 - Functional obstructive or restrictive bronchiolitis
 - Mostly irreversible
- Link with Pemphigus??

Respiratory Epithelium in PNP



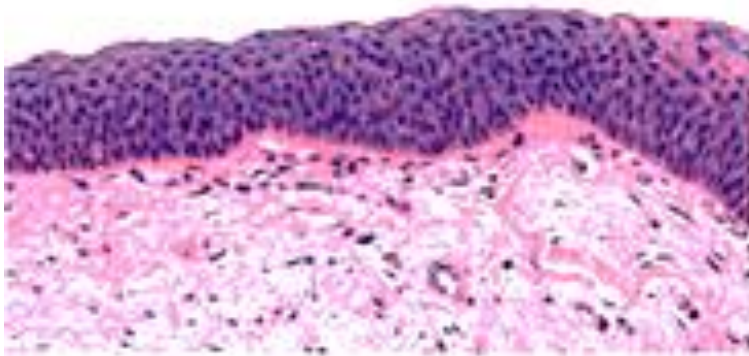
Loss of Cellular
Adhesion,
Similar to pemphigus



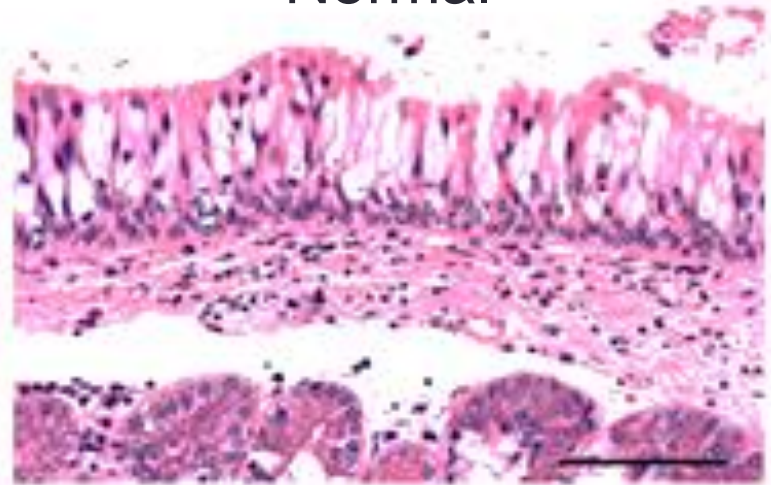
Autoantibodies
Deposited by
immunofluorescence

Increased Desmoglein 3 in areas of Squamous Metaplasia!

Squamous Metaplasia

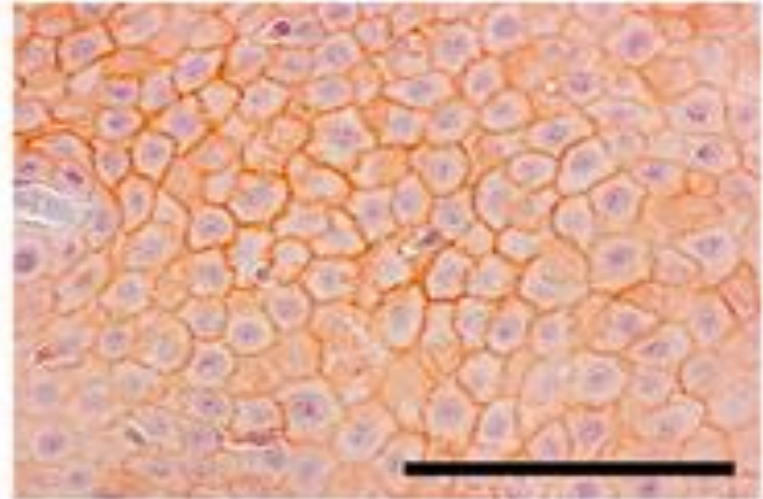
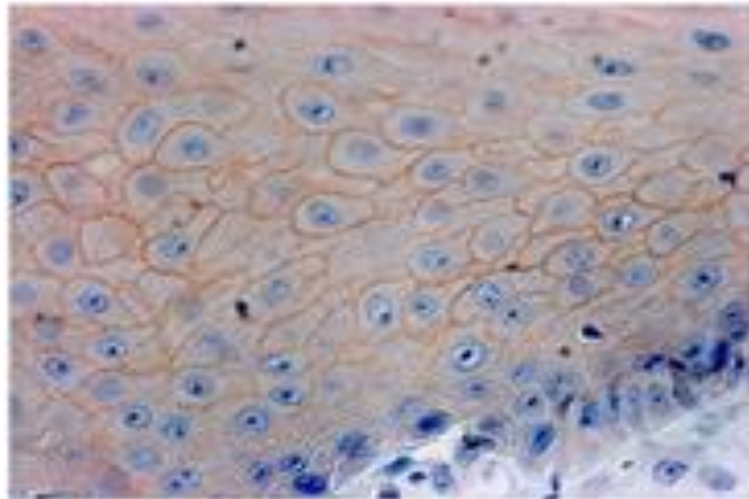


Normal



Hata T, et al, J Immunology, 2013

Squamous Metaplasia

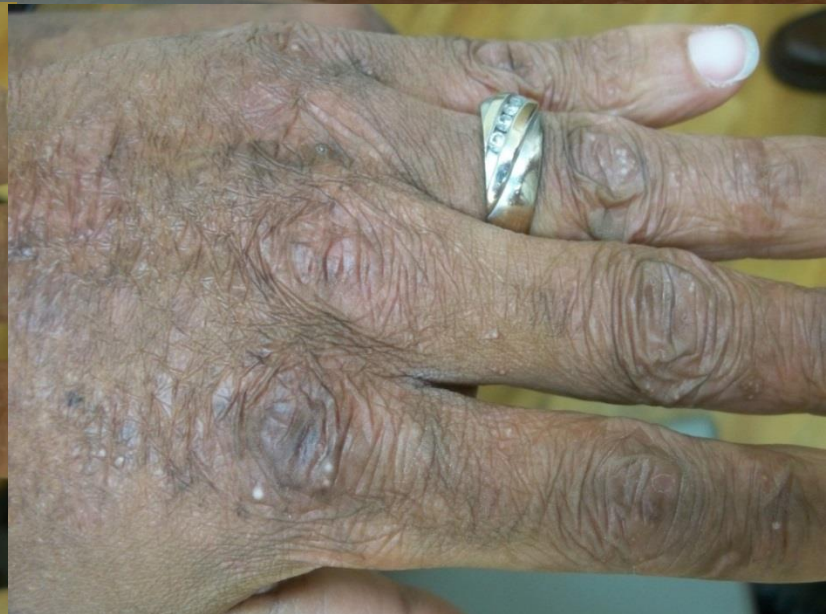
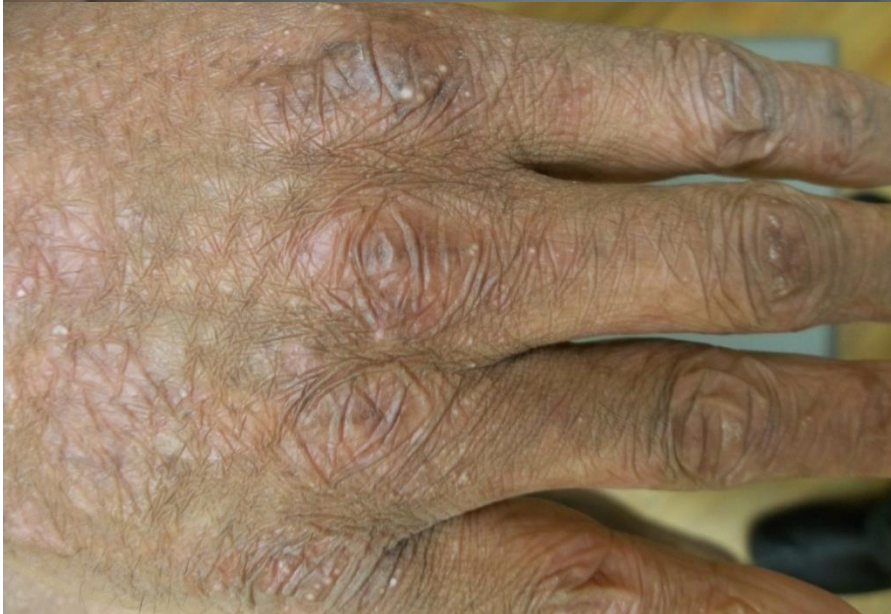
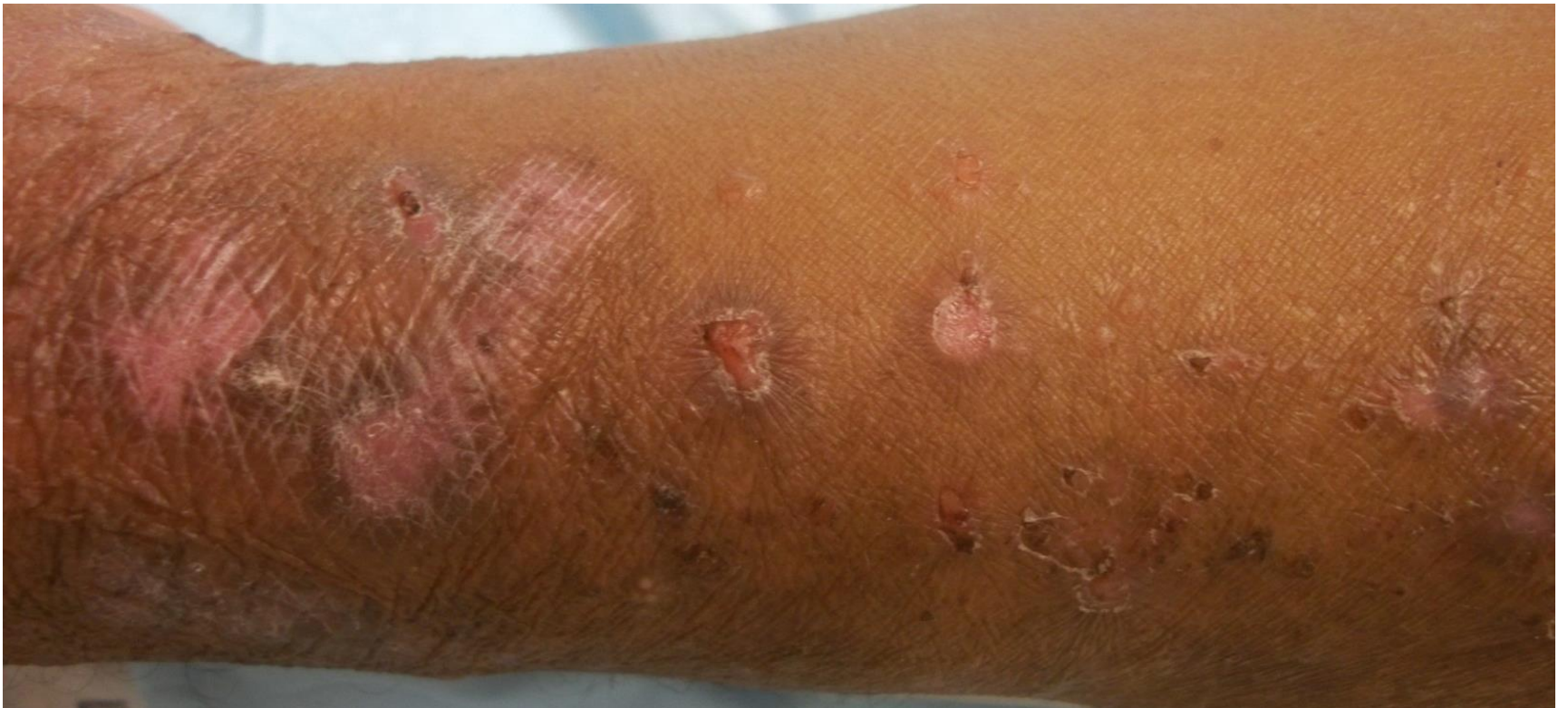Bullous Window to Systemic Disease

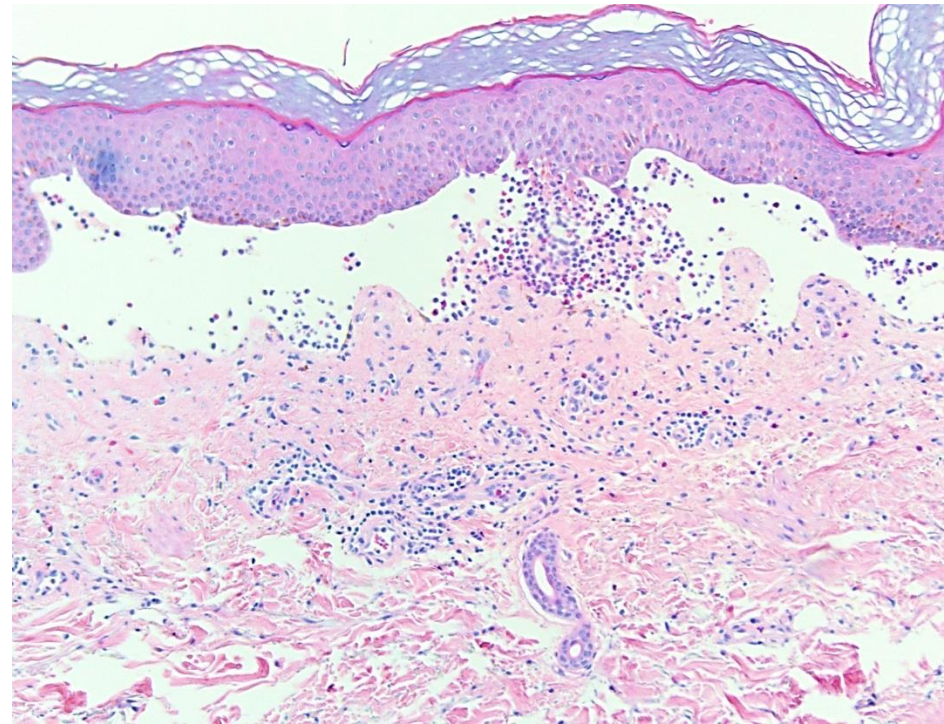
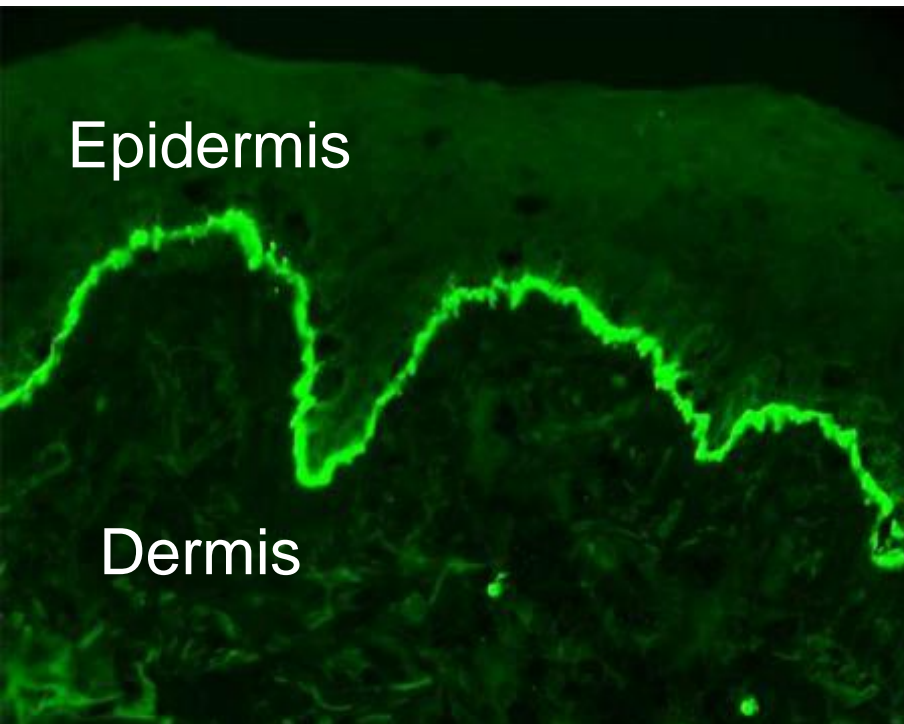
- Increased skin injury from autoantibodies
- Induction of various cytokines—Interleukin-22?
- Downstream effects on respiratory epithelium—
Squamous metaplasia?
- Induction of ectopic expression of Desmoglein 3 in
respiratory epithelium
- Humoral attack—similar to classic pemphigus
- Respiratory failure

Case History

- 44 year old African American male
- Referred for worsening blisters mostly on extremities
- Diagnosed with Crohn's disease shortly before blistering began
- Previously treated with courses of prednisone and sulfasalazine

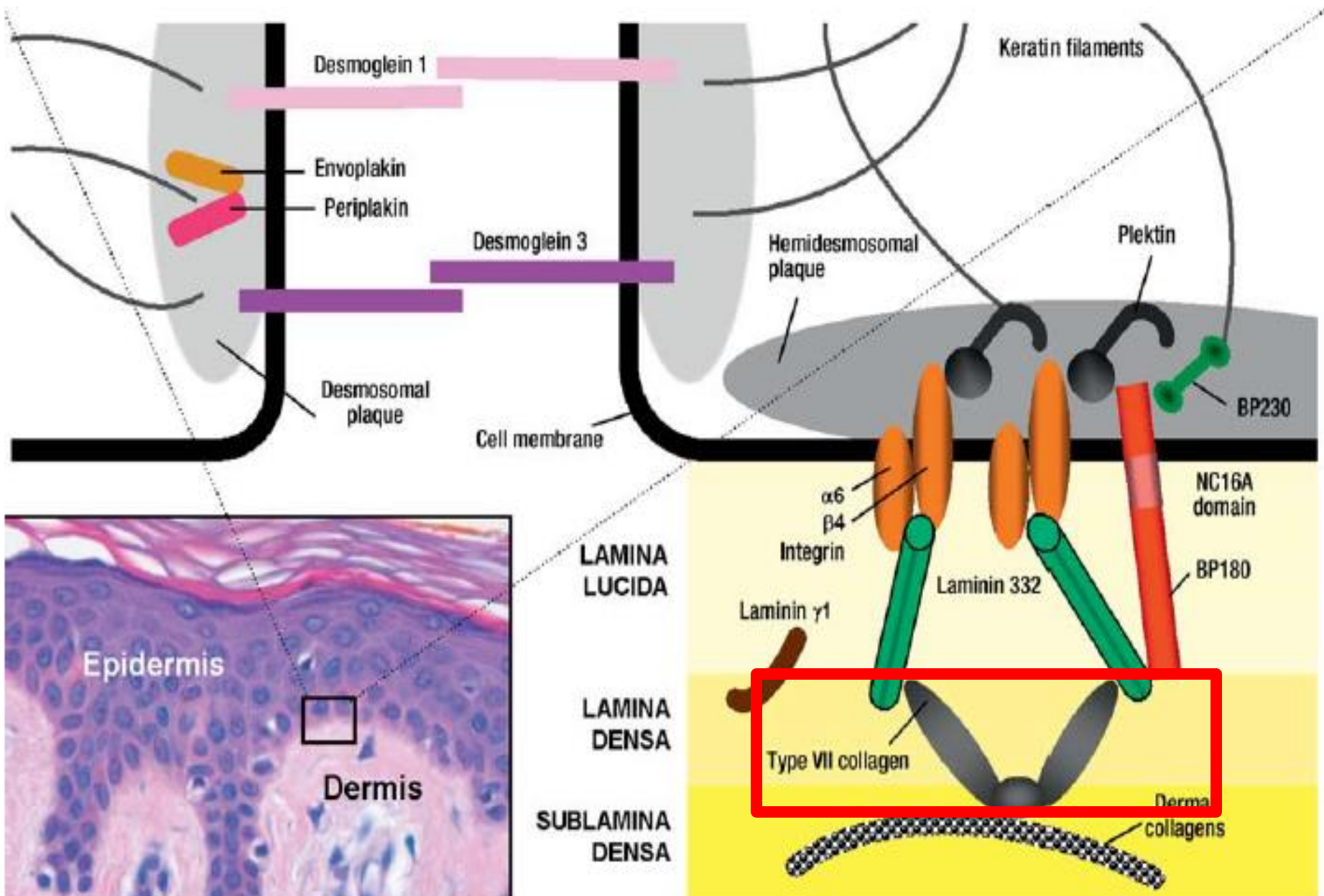


Linear IgG/C3 at Basement Membrane



Subepidermal Blistering Diseases

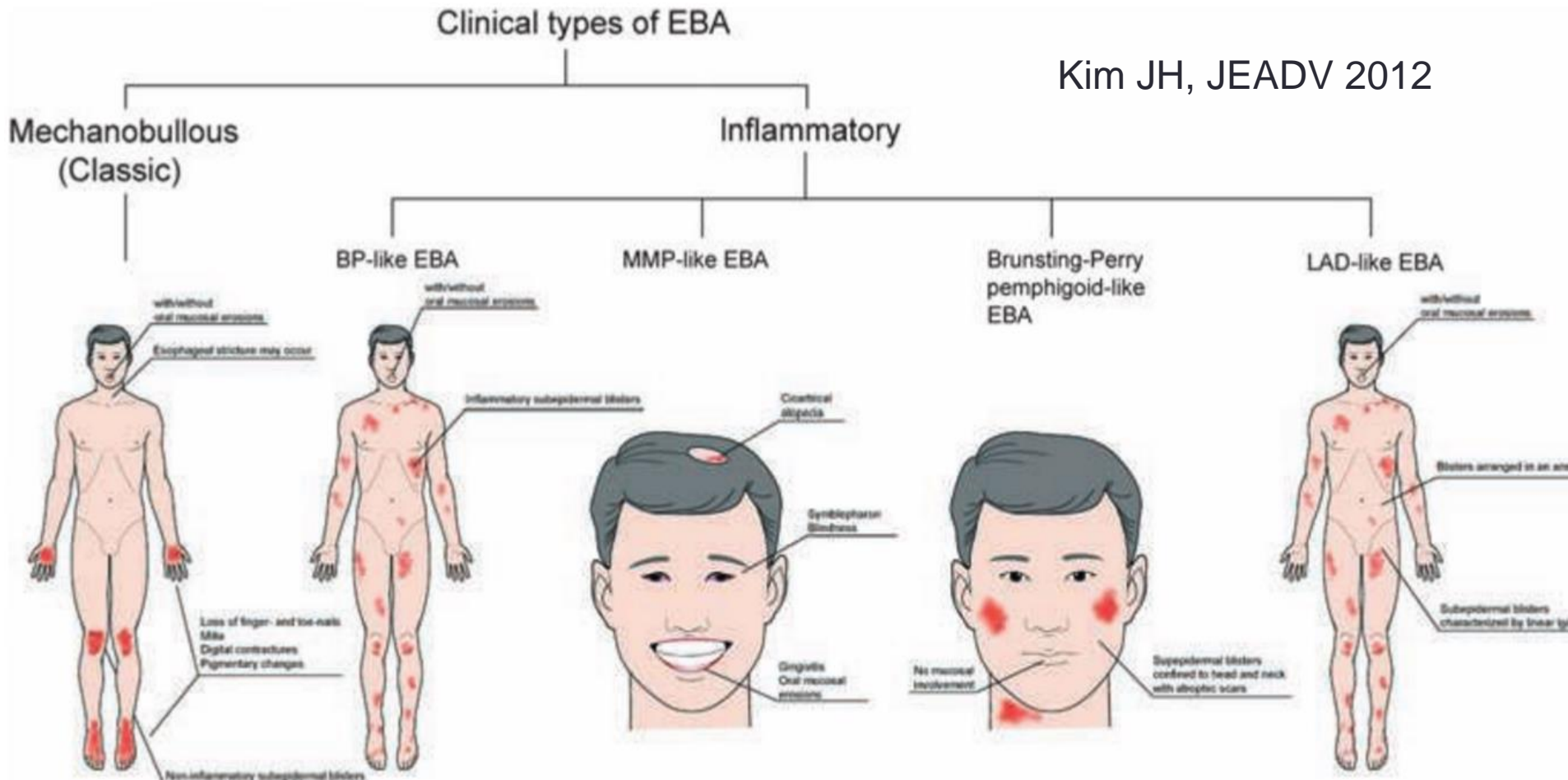
Adhesion Molecules in the Skin



Epidermolysis bullosa acquisita

- Autoantibodies bind to collagen VII in the dermis
- Potential for scarring
- Link with Inflammatory Bowel Disease?

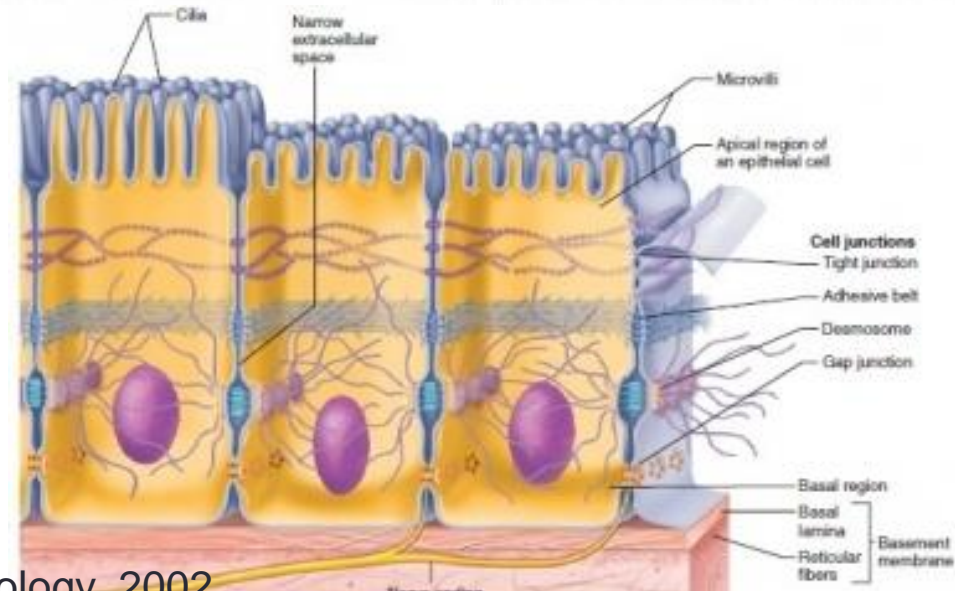
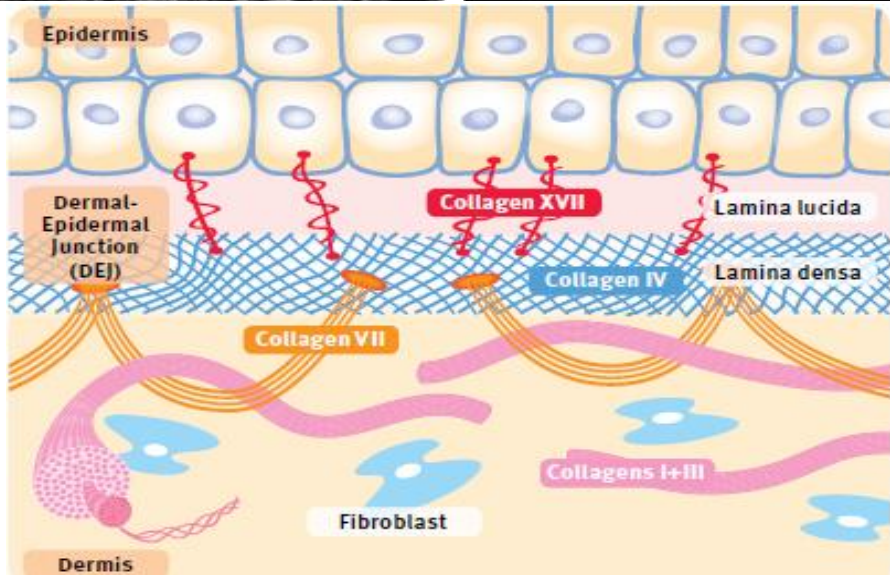
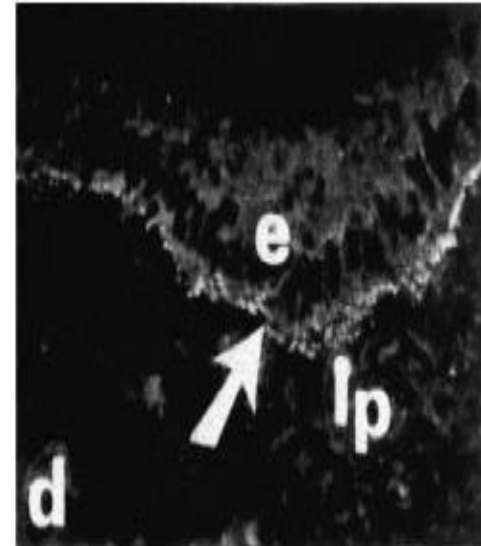
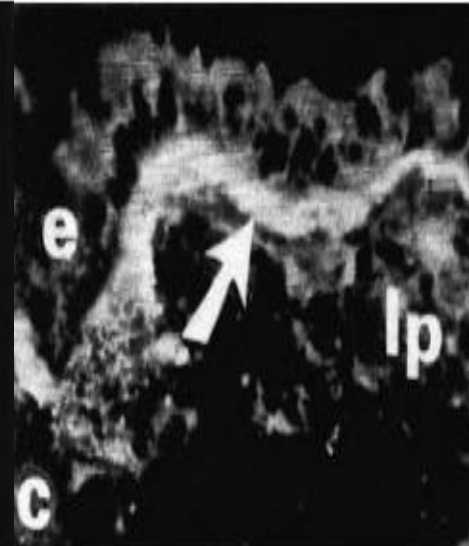
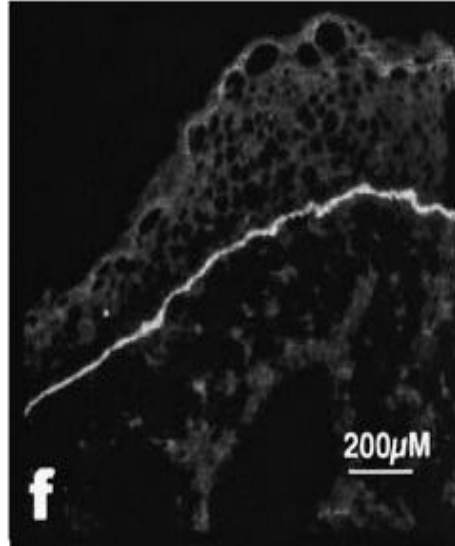
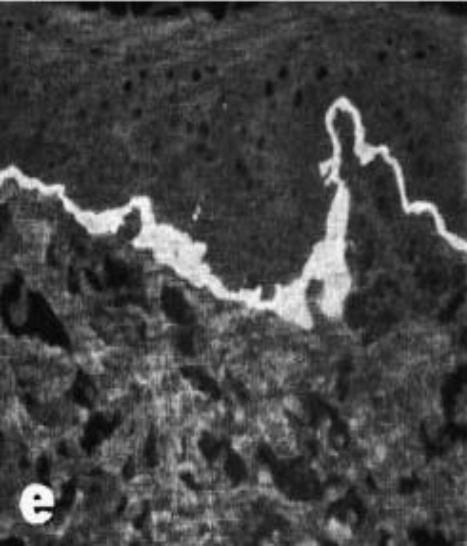
Kim JH, JEADV 2012



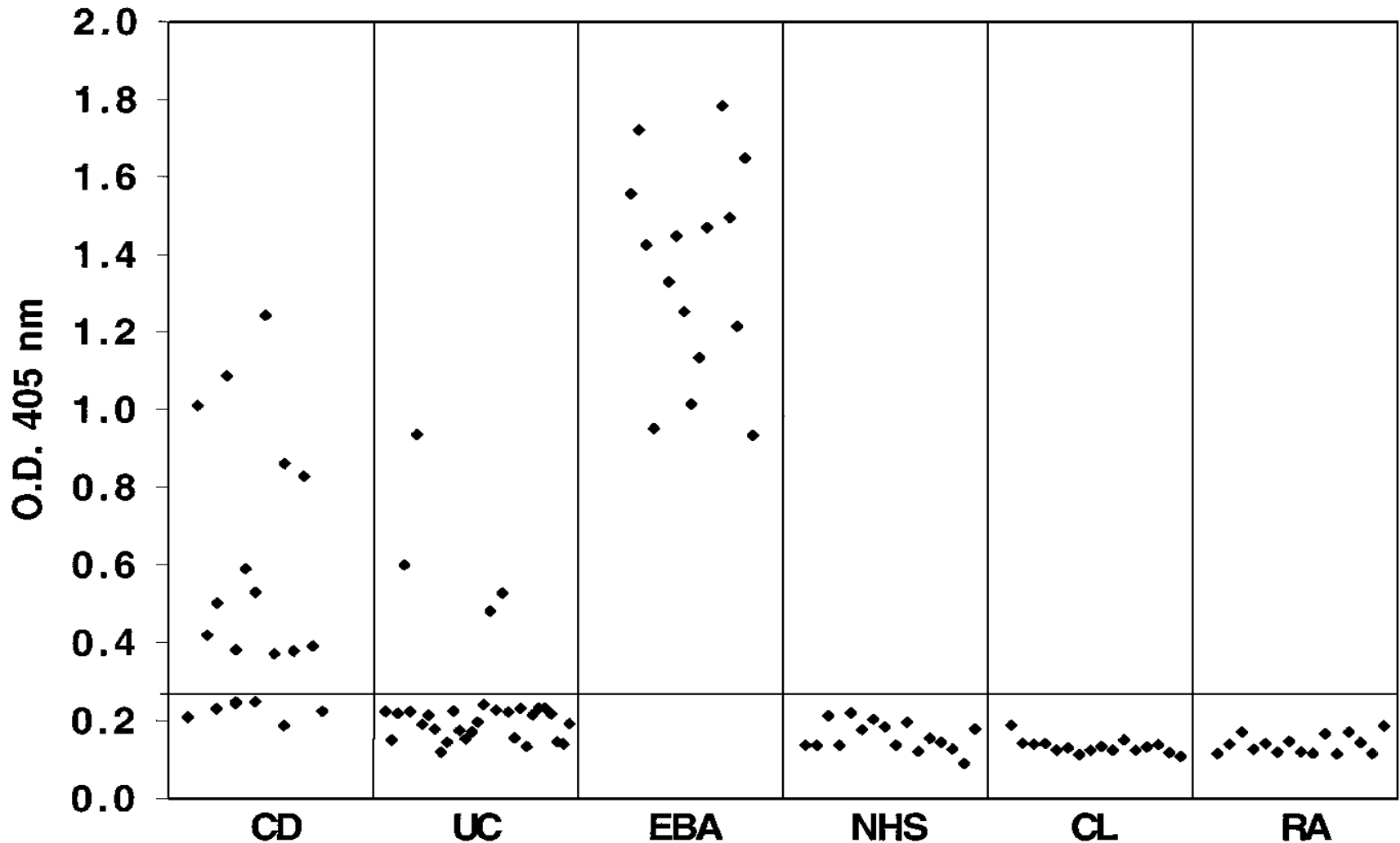
Type VII Collagen is Present in Skin and Colon

Skin

Colon



Serum autoantibodies to type VII collagen

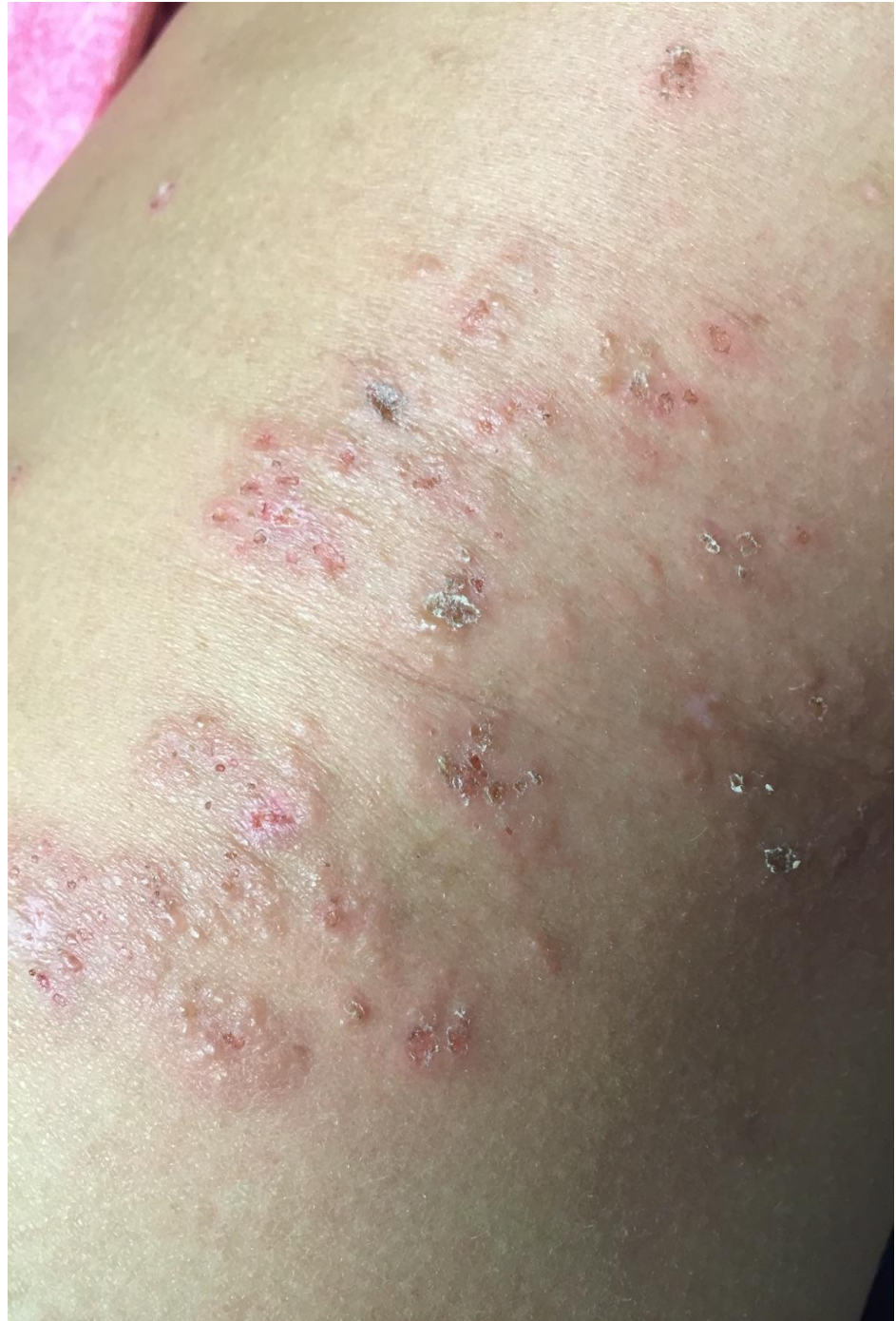
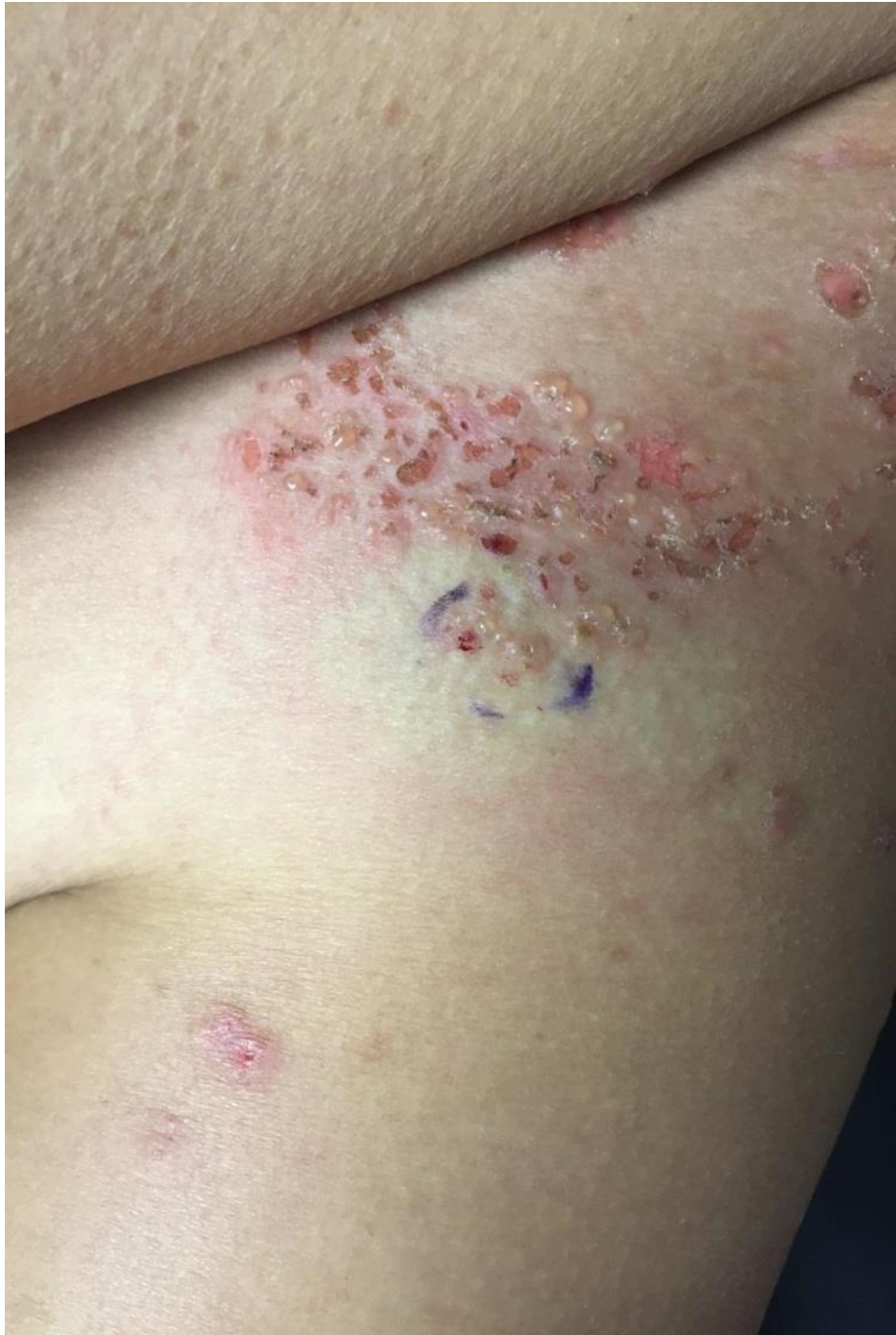
Bullous Window to Systemic Disease

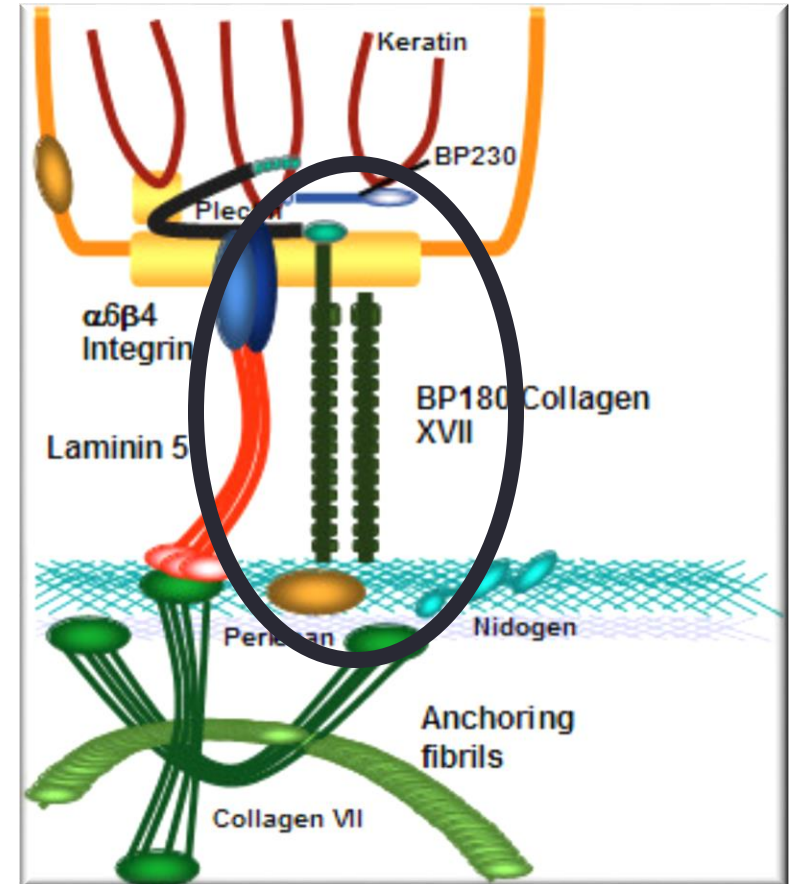
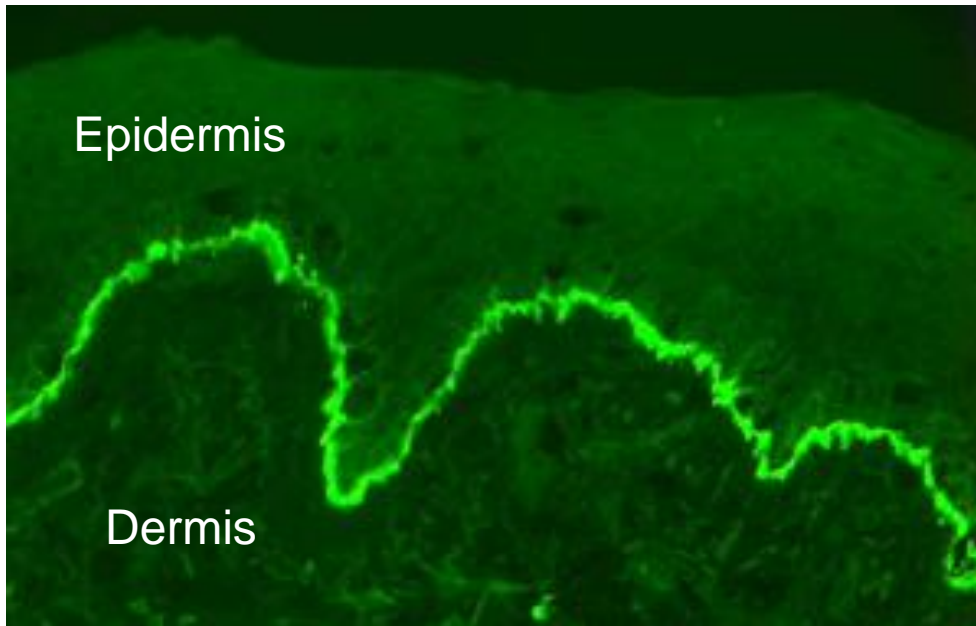
- Tissue injury, inflammation in skin or gastrointestinal tract, exposing epitopes on collagen VII
- Development of cross reactive antibodies?
- Exposure of other antigens during inflammation, development of other AIBD
 - Bullous pemphigoid--CD/UC
 - Linear IgA disease--UC
 - Dermatitis herpetiformis-Celiac disease
- EBA most commonly associated with CD
- Inflammatory bowel disease tends to precede AIBD

Case History

- 40 year old female
- 5 years post kidney/pancreas transplant for diabetes
- On prednisone and mycophenolate
- Attempted to wean down mycophenolate
- Creatinine levels increased to 3.3
- Developed widespread pruritic rash
- Subsequently developed tense blisters



Linear IgG/C3 at Basement Membrane Zone



Serum ELISA

Elevated anti-BP180 antibodies
(BPAG2/Collagen XVII)

Bullous Window to Systemic Disease

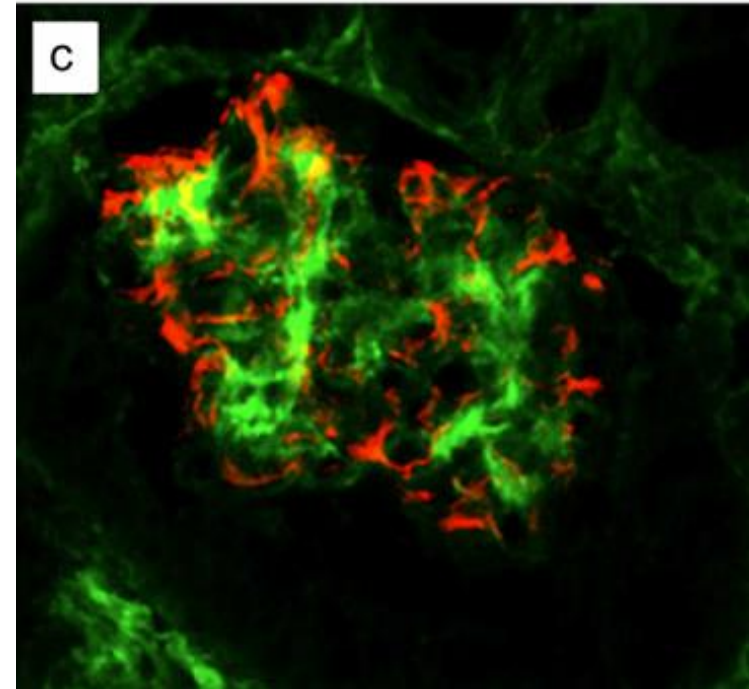
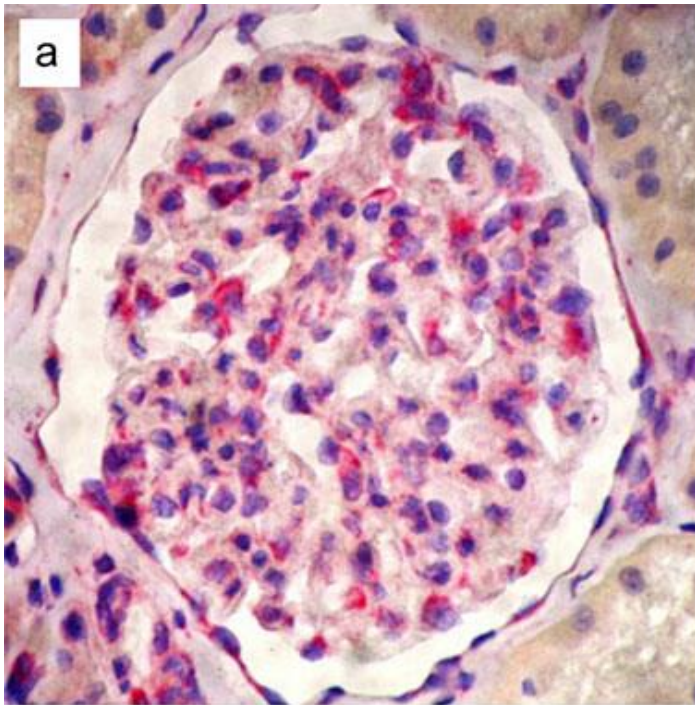
- Bullous pemphigoid in the setting of renal allograft failure?
- Usually with reduction in dose of immunosuppression
- Injury to glomerular basement membrane, epitope spreading?
- Common antigen between glomerular basement membrane zone and cutaneous? Collagen XVII, IV?

Devaux S, et al, Acta Derm Venereol 2011

Hurskainen T, et al, Cell Tissue Res 2012

Cavaliere G et al, Eur J Dermatol 2014

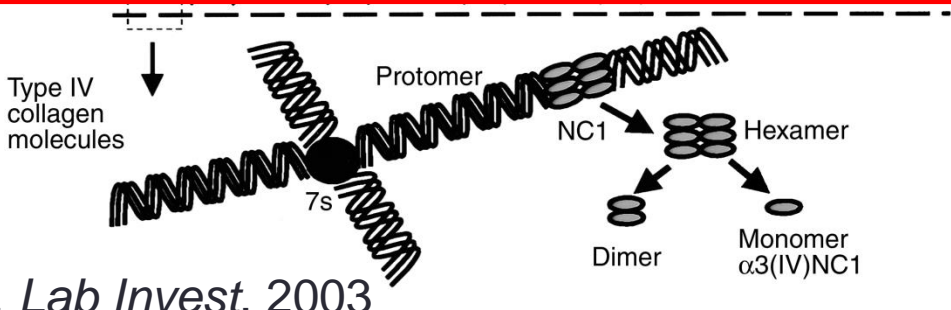
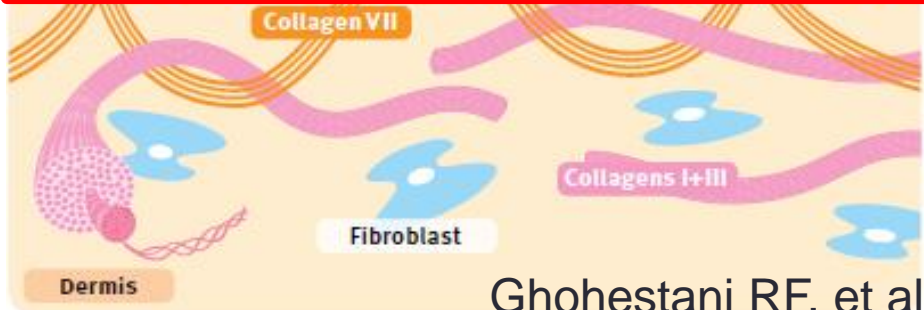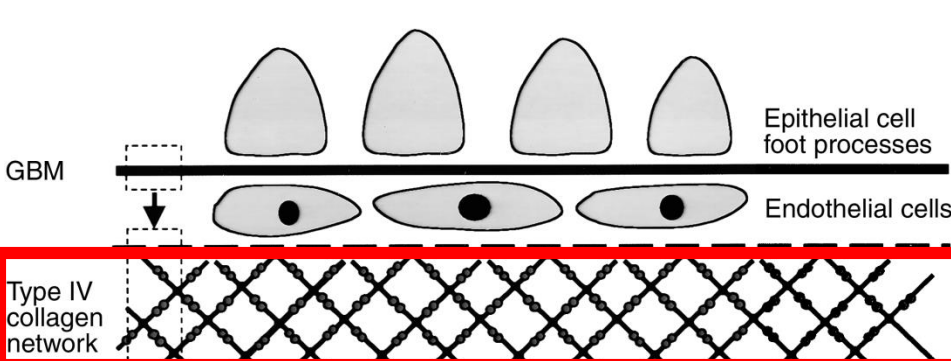
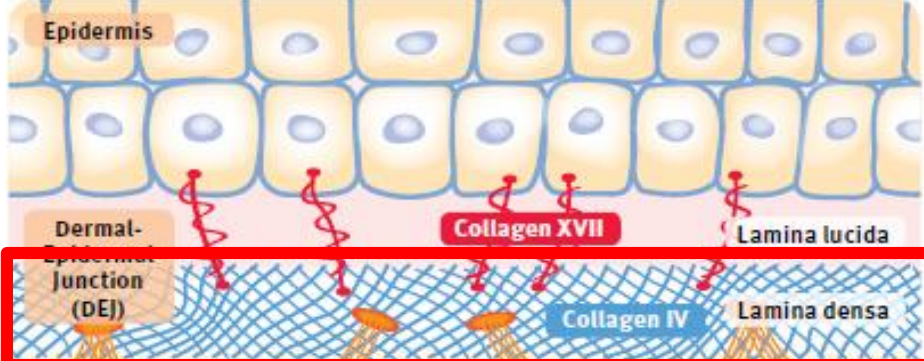
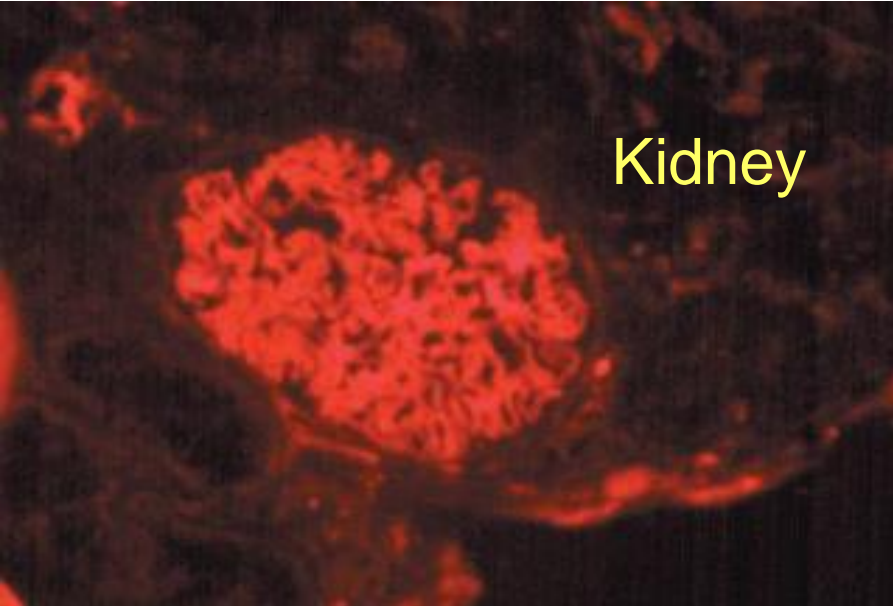
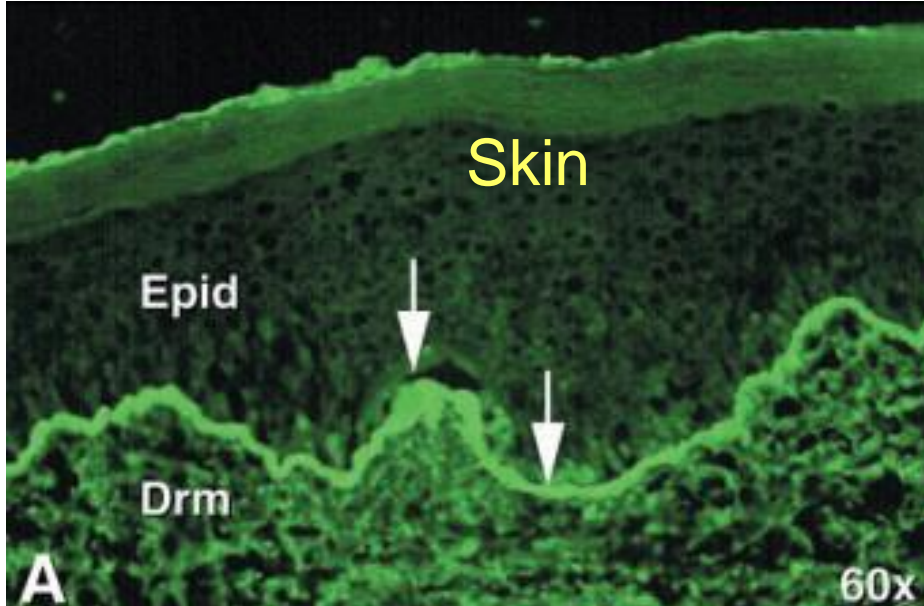
Bullous Window to Systemic Disease



Collagen XVII expressed in human and mouse glomerulus

Devaux S, et al, Acta Derm Venereol 2011
Hurskainen T, et al, Cell Tissue Res 2012

Antibodies against Type IV Collagen: Skin and Renal Glomerulus



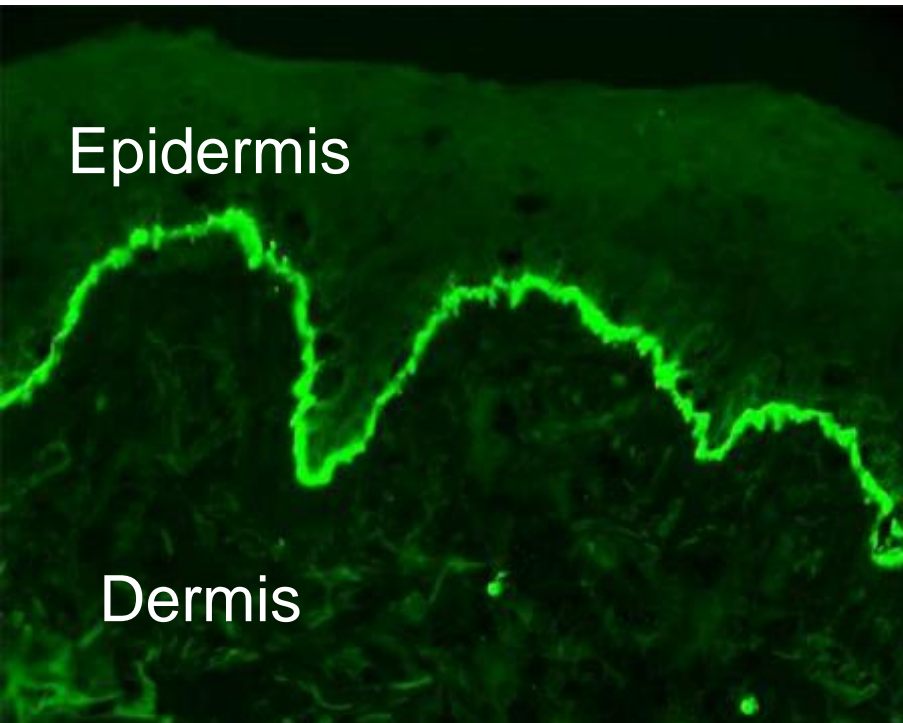
Ghohestani RF, et al, *Lab Invest.* 2003

Case History

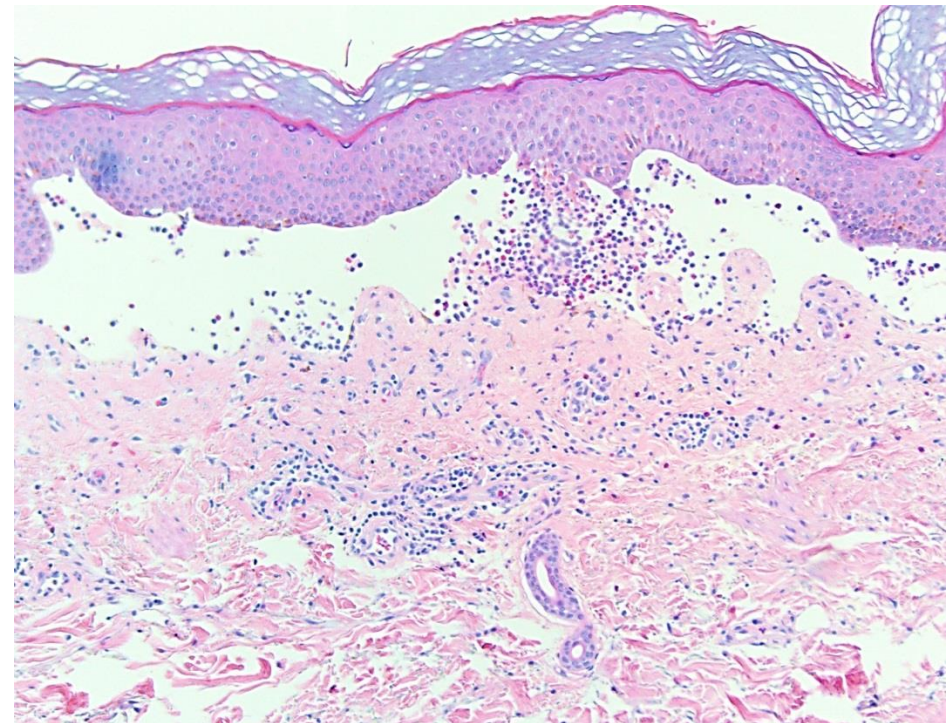
- 74 year old Caucasian female
- Diagnosed with Lewy Body Dementia in 2011
- Developed worsening pruritus in 2013
- Treated with antihistamines and topical steroids
- Developed gingival erosions and blisters on lower extremities
- Biopsied by oral surgery—inconclusive
- Seen by dermatology in 2014—widespread erosions on gingiva and across her abdomen and back

Linear IgG/C3 at Basement Membrane Zone

Tissue Bound Antibodies



Loss of Cellular Adhesion



Case History

- Bullous pemphigoid
- Bullous pemphigoid disease area index (BPDAI)
 - Cutaneous: 34/120
 - Oral: 16/120
- Age of onset >70 years

- Disease relationship with underlying dementia??

Bullous Pemphigoid

- Data from National Inpatient Sample, 2002-2012 (~72 million adults, cont)

Neuropsychiatric disorders!

- Demyelinating disorders: 3.57 (1.48-8.61)
- Presenile Dementias: 2.63 (1.34-5.18)
- Parkinson's disease: 1.86 (1.65-2.10)
- Epilepsy: 1.67 (1.41-1.98)
- Other neurological disorders: 1.98 (1.86-2.11)

Bullous Pemphigoid

- Significant increase in odds of developing BP in people with neurological diseases diagnosed more than 12 months previously
 - Dementia and Parkinson's-- 3 fold increase
 - Stroke and Epilepsy--2 fold increase
- Neurological disease precedes the BP
- Patients with Parkinson's have circulating autoantibodies to collagen XVII and localize to neurons

Laffitte E, et al, Br Journal of Dermatology, 2004

Langan SM, et al, Journal of Investigative Dermatology, 2011

Brick KE et al Journal of the American Acad Derm, 2016

Messingham KA, et al, Journal Investigative Derm, 2016


BPAG1 in the Central Nervous System?

- Knockout mice for BPAG1/BP230
 - Develop skin fragility as expected
 - Dystonia, ataxia?
 - Severe neurodegeneration and myelin abnormalities in CNS and peripheral nervous system?

Guo L et al, Cell 1995

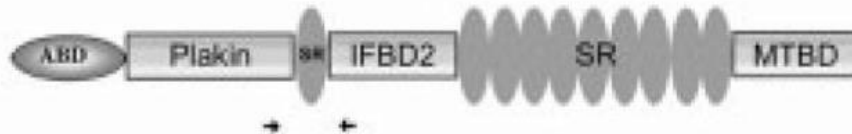Expression of BPAG1 (BP230)

BPAG1a




Brain, Spinal Cord

BPAG1b



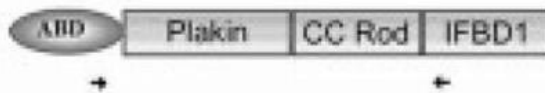
Striated muscle,
bone cartilage

BPAG1e



Epidermis

BPAG1n



“Dystonin”; peripheral sensory neurons, motor neurons, oligodendrocytes, Schwann cells

*BPAG2/Collagen XVII is also expressed in the Brain

Seppanen A, et al Matrix Biology 2006

Bousquet O and Coulombe P, Current Biology 1996

BP patients with neurological diseases recognize BPAG 1 protein in the brain

- Serum samples from BP and neurological diseases (BPND) compared with serum from BP without neurologic disease (BP)
 - Recognized BPAG1—epidermal extracts:
 - 72% BP/ND vs 50% BP
 - Recognized BPAG1—brain extracts:
 - 55% BP/ND vs 9% BP

Bullous Window to Systemic Disease

- Neurological disorders cause damage to blood brain barrier?
- Loss of immune privilege—inappropriate exposure of brain antigens—BPAG1 or BPAG2?
- Develop cross reactive autoantibodies to skin??

BP and Venous Thromboembolism

- **INVENTEP**

- Incidence of VENous ThromboEmbolic in bullous Pemphigoid study
- Cohort of 432 patients
- BP patients have four-fold increased risk of VTE compared to age, sex matched controls
- Increased during acute phase of disease up to 15-fold

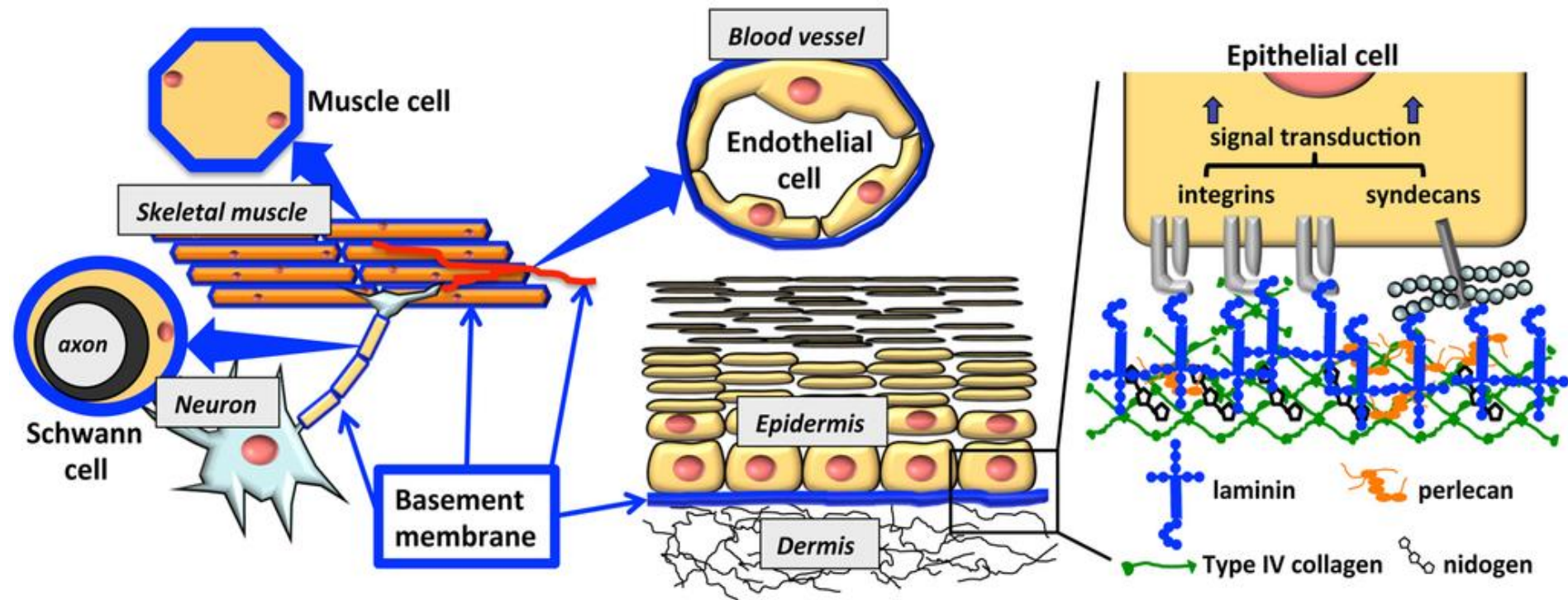
BP and Venous Thromboembolism

- Mechanism?
 - Related to increased expression of tissue factor by proinflammatory cytokines and eosinophils
 - Elevation of prothrombin fragments---coagulation activation
 - Anticoagulate patients with active disease?

Marzano AV, et al, Br J Derm, 2009

Zebrowska Z et al, Mediators Inflammation, 2015

- AIBD can be window into systemic inflammation/injury of multiple organ systems



Conclusion

- Bullous diseases fascinating group of autoimmune diseases
- Diagnostic and therapeutic decisions potentially affected

THANKS FOR THE INVITE!

Ron Feldman, MD, PhD
Assistant Professor of Dermatology
Emory University
ron.j.feldman@emory.edu



EMORY
UNIVERSITY

EMORY
HEALTHCARE