



VESICLES & BULLAE: A REVIEW OF DIFFERENTIAL DIAGNOSES AND TREATMENT OPTIONS

Kate Braunlich, DO, PGY4
Program Director: Dr. Richard Miller



I have no
relevant
disclosures

◦ All photos are taken from ***Andrews' Diseases of the Skin Clinical Atlas*** unless otherwise specified. The rights/copyright to these photos remains with the authors of this text.

Please Note

History

- How long have the bullae or vesicles been present?
- Has the patient had bullae/vesicles before?
- If chronic, does the eruption occur at the same site each time?
- Are the bullae/vesicles symptomatic?
- Is the patient taking medications? If so, which medications?

Physical Exam

- Patient age
- If female, childbearing status, i.e. pregnant, recently post-partum etc.
- Bullae/vesicle distribution
- Is there mucosal involvement
- Are the bullae/vesicles isolated or is there concomitant desquamation, erosions, fissures, scale or erythema
- Is there evidence of scarring

Fragile or tense bullae?

- **Fragile Bullae**

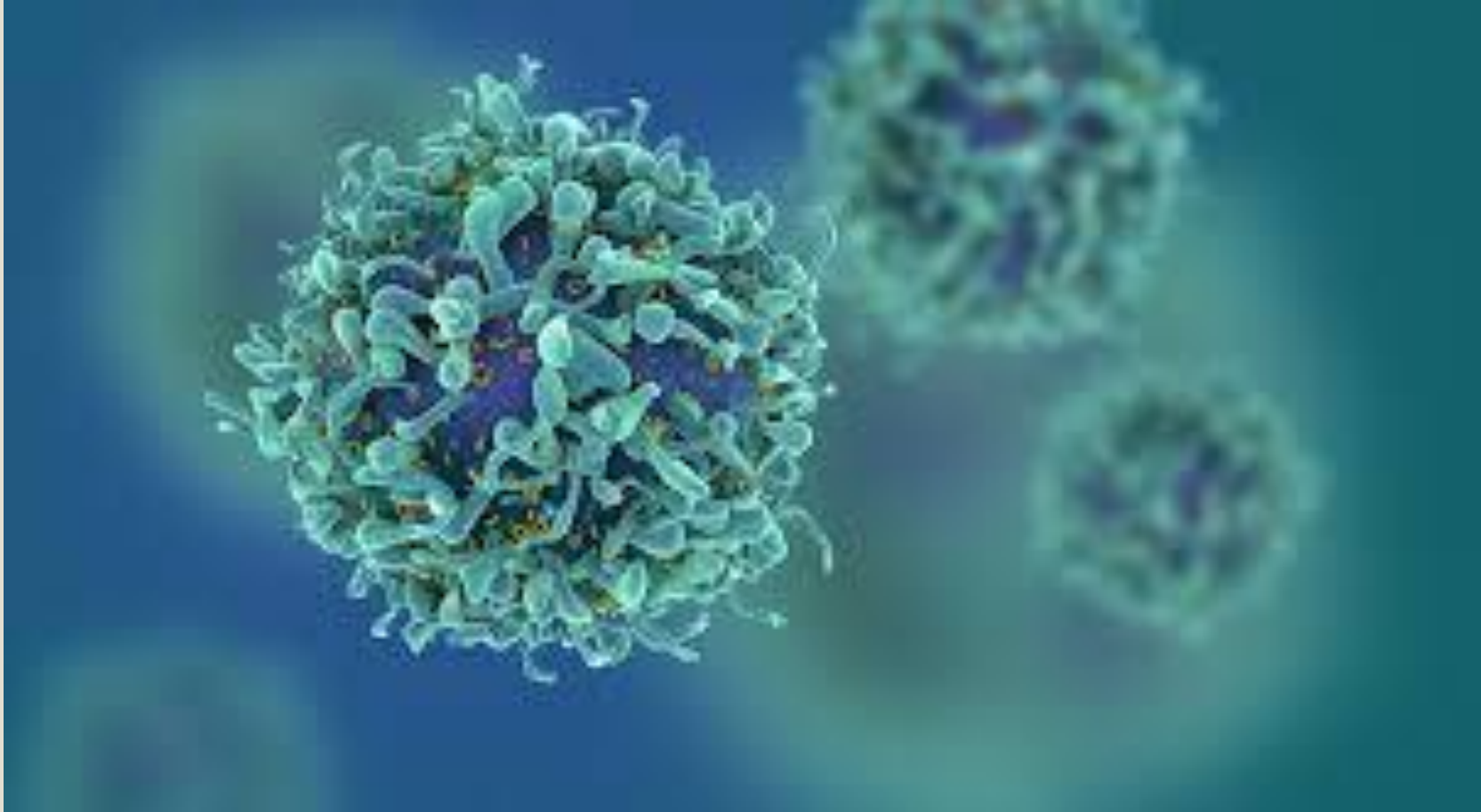
- Bullous Impetigo
- Pemphigus (all variants)
- SSSS
- Hailey-Hailey disease

- **Tense Bullae**

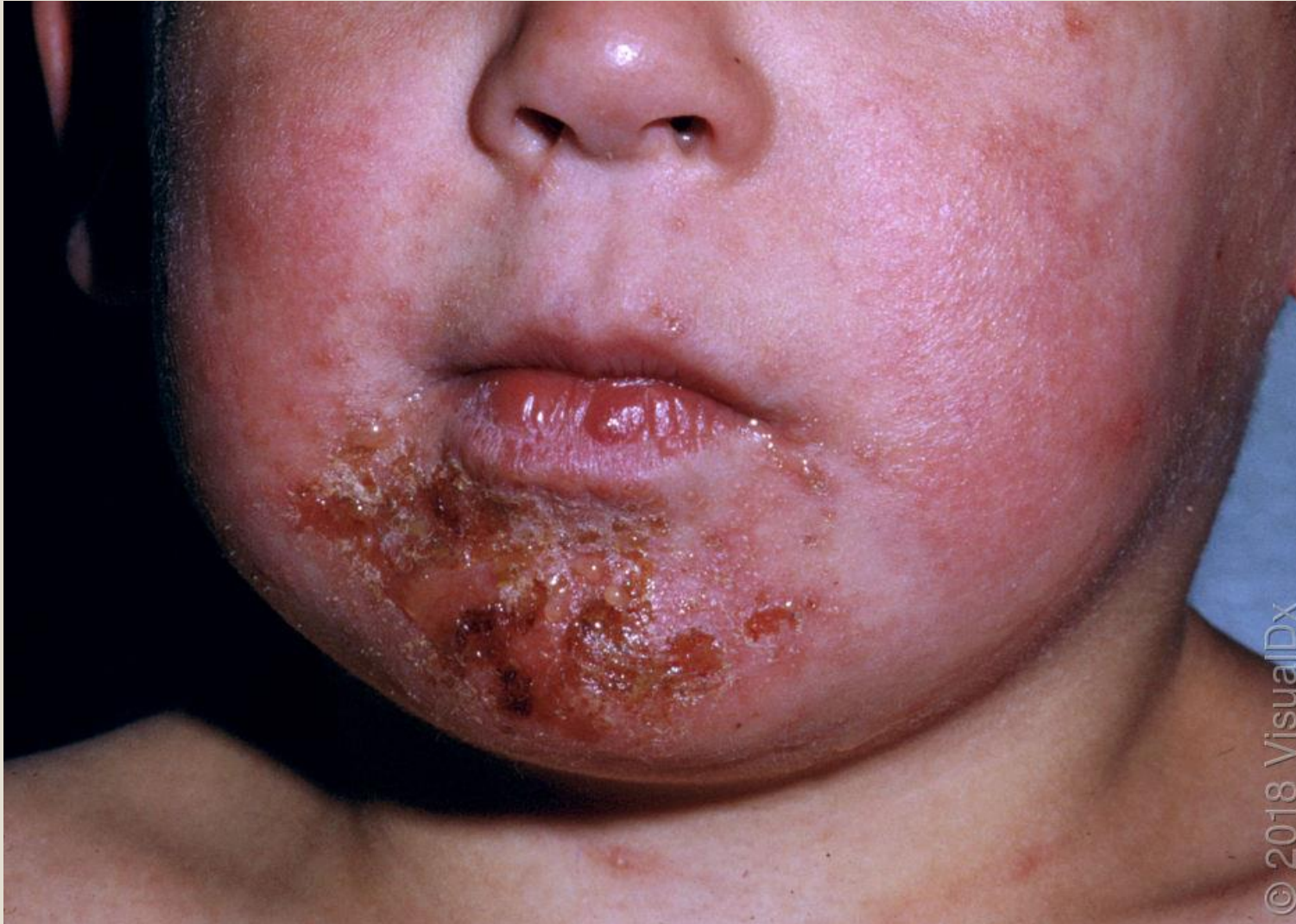- Contact dermatitis (allergic or irritant)
- Bullous pemphigoid
- Bullous drug/fixed drug
- Cicatricial pemphigoid/MMP
- DH
- Dyshidrotic dermatitis
- EBA
- EB
- EM
- Hand, foot, and mouth
- HSV/Zoster
- Herpes gestationis
- Linear IgA bullous dermatosis
- PCT
- Smallpox/Vaccinia
- TEN
- Second degree sunburn

Etiologies

- **Infectious: bacterial & viral**
- **External**
- **Autoimmune**
- Genetic
 - Porphyria cutanea tarda (PCT)
 - Epidermolysis bullosa (EB)
 - Epidermolysis bullosa acquisita (EBA)
- **Medication**
- Overlap/Multiple etiologies → Hospital consults
 - Bullous Erythema Multiforme
 - Stevens-Johnson syndrome/Toxic Epidermal Necrolysis



Infections



- **Honey-colored, weeping plaque on the chin with vesiculation on the lower lip.**

Bullous Impetigo

Pathogenesis:

- *S. aureus* phage propagating strain **group II (types 55 and 71)** → produce **exfoliatins A and B** (ETA and ETB) → cleaves **desmoglein 1** → **subcorneal acantholysis**

Clinical features:

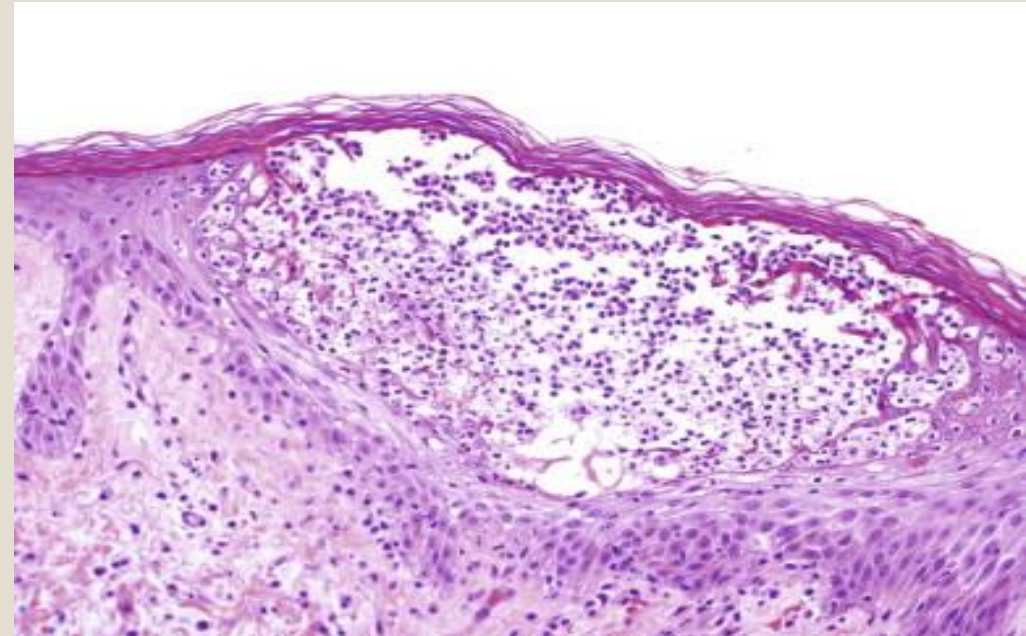
- Children > adults; **flaccid bullae** + erosions w/ **collarette of scale**, minimal surrounding erythema + **“honey-colored” crust**

Diagnosis:

- Clinical
- Bacterial culture
- Histology: **subcorneal/intragranular acantholysis**, **neutrophils** in blister cavity, Gram(+) cocci

Subcorneal Pustule DDX on H&E

- **CAT SIPS**
- **C**andida
- **A**cropustulosis of infancy
- **T**ransient neonatal pustular melanosis
- **S**neddon – Wilkinson
- **I**mpetigo
- **P**ustular psoriasis
- **S**taphylococcal-scalded skin syndrome



Bullous Impetigo: Tx

Treatment:

- Localized: topical **Mupirocin 2% ointment** BID-TID x 5 days (or) retapamulin
- Widespread:
 - PO B-lactamase resistant PCN → **Dicloxacillin** 250mg QID for 7-10 days
 - PO 1st generation CSN → **Cephalexin** 200-500mg TID-QID for 7-10 days
 - PO Lincosamides → **Clindamycin*** (C. Diff)
- Complicated: IV **Ceftriaxone**
- Penicillin allergic: **Erythromycin** or **Azithromycin**. NB erythromycin resistant staph are prevalent (19-50% of strains) in many regions of the USA
- If cx returns +MRSA: **Ciprofloxacin, Bactrim, Doxycycline** or topical **Mupirocin** (nasal carriers)



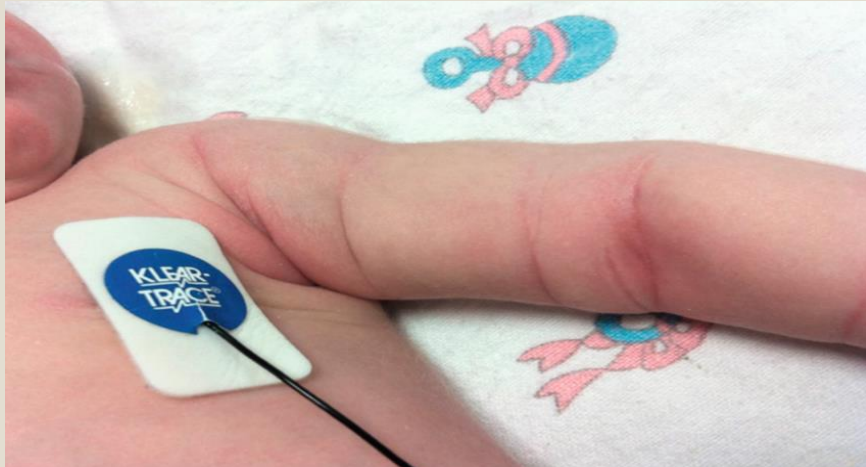Bullous Impetigo: Clinical Course

Clinical Course:

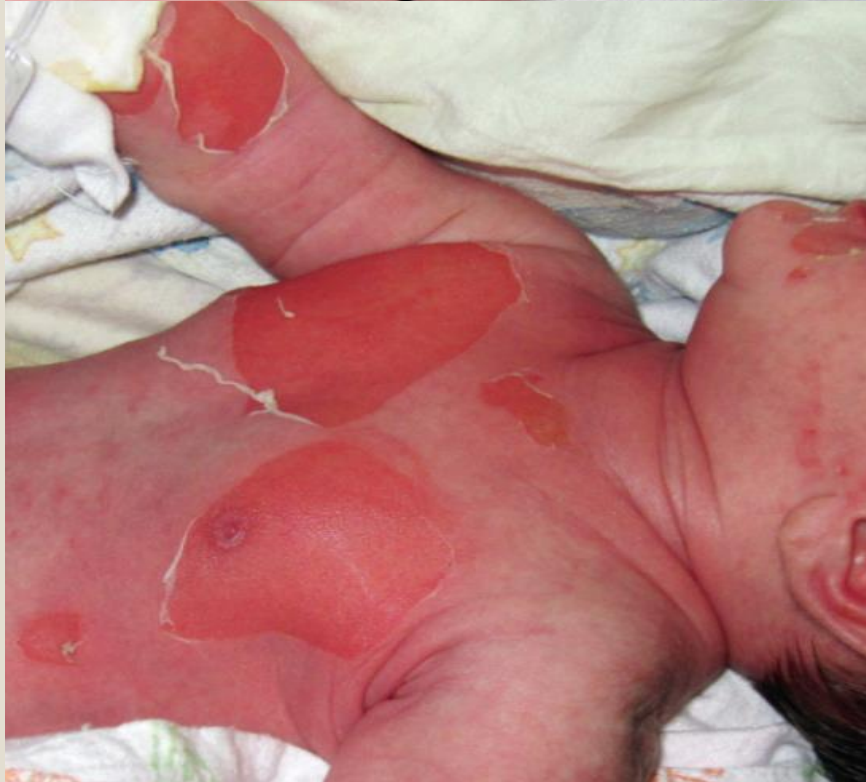- Self resolves in two weeks
- If the patient continues to develop new lesions 3 days beyond starting antibiotics, the veracity of the dx should be reassessed
- Correlate with culture and susceptibility. CHANGE abx as necessary.

Antibiotic	Sensitivity
Levofloxacin	++
Amikacin	-
Ciprofloxacin	-
Gentamicin	+++
Ceftriaxone	+++
Cefotaxime	-
Chloramphenicol	-
Cloxacillin	-
Amoxicillin & Clavulanic acid	++++
Enrofloxacin	++++
Moxiflox	-
Cefetrixone & Salbactam	-
Cobactan	++++

Intracellular	Inhibit peptidoglycan subunit synthesis and transport: NAM synthesis inhibition (Fosfomycin) · DADAL/AR inhibitors (Cycloserine) · bactoprenol inhibitors (Bacitracin)		
Glycopeptide	Inhibit PG chain elongation: Vancomycin [#] (Oritavancin · Telavancin) · Teicoplanin (Dalbavancin) · Ramoplanin		
β-lactams/ (inhibit PBP cross-links)	Penicillins (Penams)	Narrow spectrum	β-lactamase sensitive (1st generation) Benzylpenicillin (G) [#] · Benzathine benzylpenicillin [#] · Procaine benzylpenicillin [#] · Phenoxymethylpenicillin (V) [#] · Propicillin [‡] · Pheneticillin [‡] · Azidocillin [‡] · Clometocillin [‡] · Penamecillin [‡]
		Extended spectrum	β-lactamase resistant (2nd generation) Cloxacillin [#] (Dicloxacillin · Flucloxacillin) · Oxacillin · Nafcillin · Methicillin [‡]
			Aminopenicillins (3rd generation) Amoxicillin [#] · Ampicillin [#] (Pivampicillin · Hetacillin [‡] · Bacampicillin [‡] · Metampicillin [‡] · Talampicillin [‡]) · Epicillin [‡]
			Carboxypenicillins (4th generation) Ticarcillin · Carbenicillin [‡] / Carindacillin [‡] · Temocillin [‡]
			Ureidopenicillins (4th generation) Piperacillin · Azlocillin [‡] · Mezlocillin [‡]
	Other Mecillinam [‡] (Pivmecillinam [‡]) · Sulbenicillin [‡]		
	Penems	Faropenem [‡] · Ritipenem [§]	
	Carbapenems	Ertapenem · Antipseudomonal (Doripenem · Imipenem · Meropenem) · Biapenem [‡] · Panipenem [‡]	
	Cephalosporins / Cephamecins (Cephems)	1st generation	Cefazolin [#] · Cefalexin [#] · Cefadroxil · Cefapirin · Cefazedone [‡] · Cefazafur [‡] · Cefradine [‡] · Cefroxadine [‡] · Ceftezole [‡] · Cefaloglycin [‡] · Cefacetile [‡] · Cefalonium [‡] · Cefaloridine [‡] · Cefalotin [‡] · Cefatrizine [‡]
		2nd generation	Cefaclor · Cefotetan · Cephamecins (Cefoxitin · Cefprozil · Cefuroxime · Cefuroxime axetil · Cefamandole [‡] · Cefminox [‡] · Cefonicid [‡] · Ceforanide [‡] · Cefbuperazone [‡] · Cefuzonam [‡] · Cefmetazole [‡]) · Carbacephem [‡] (Loracarbef [‡])
		3rd generation	Cefixime [#] · Ceftriaxone [#] · Antipseudomonal (Ceftazidime [#] · Cefoperazone [‡]) · Cefdinir · Cefcapene · Cefdaloxime · Ceftizoxime · Cefmenoxime · Cefotaxime [#] · Cefotiam [‡] · Cefpiramide · Cefpodoxime · Ceftibuten · Cefditoren · Cefetamet [‡] · Cefodizime [‡] · Cefpimizole [‡] · Cefsulodin [‡] · Cefteram [‡] · Ceftioleone [‡] · Oxacephem (Flomoxef [‡] · Latamoxef [‡])
		4th generation	Cefepime · Cefozopran [‡] · Cefpirome [‡] · Cefquinome [‡]
		5th generation	Ceftaroline fosamil · Ceftolozane · Ceftobiprole
Veterinary		Ceftiofur · Cefquinome · Cefovecin	
Monobactams	Aztreonam [#] · Tigemonam [‡] · Carumonam [‡] · Nocardicin A [‡]		
β-lactamase inhibitors	Penam (Sulbactam · Tazobactam) · Clavam (Clavulanic acid) · Avibactam · Relebactam · Sulbactam · Vaborbactam		
Combinations	Amoxicillin/clavulanic acid [#] · Imipenem/cilastatin [#] · Imipenem/cilastatin/relebactam · Ampicillin/flucloxacillin · Ampicillin/sulbactam (Sultamicillin) · Ceftazidime/avibactam · Piperacillin/tazobactam · Ceftolozane/tazobactam · Cefoperazone/sulbactam · Meropenem/vaborbactam		
Other	polymyxins/detergent (Colistin · Polymyxin B) · depolarizing (Daptomycin) · Hydrolyze NAM-NAG (lysozyme) · Tyrothricin (Gramicidin · Tyrocidine) · Isoniazid [#] · Teixobactin		



- Early sign = erythema accentuated in folds.



- Generalized flaccid bullae → denuded areas/superficial desquamation

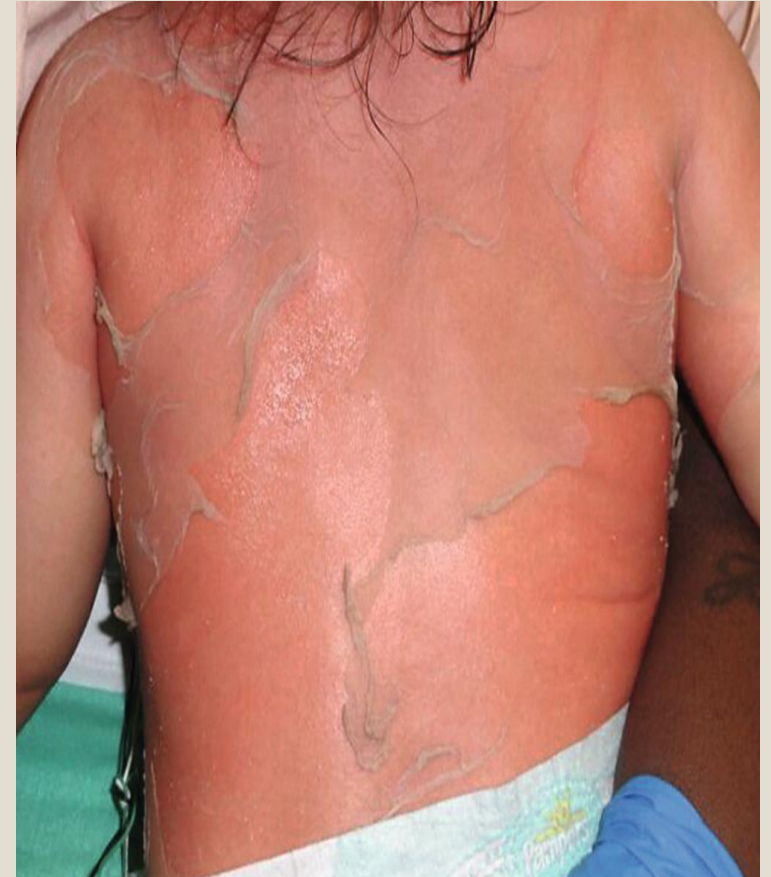Staph Scalded Skin Syndrome (SSSS)

Pathogenesis:

- Infection by *S. aureus* phage **group II (types 55 and 71)** at distant site → produce **exfoliatins A and B** (ETA and ETB) → exfoliatins **disseminate via bloodstream** → widespread cleavage of **desmoglein 1** → diffuse **subcorneal acantholysis**

Clinical features:

- Children esp those with ↓ **renal clearance** (low mortality <5%) > adults with **ESRD** (high mortality >50%)
- Prodrome: fever, skin tenderness, denuded areas on the face lead to characteristic **periorificial radial fissuring** → generalized flaccid bullae + Nikolsky sign → desquamation continues for up to 1 week, **heals without scarring**.



SSSS: Dx

Diagnosis:

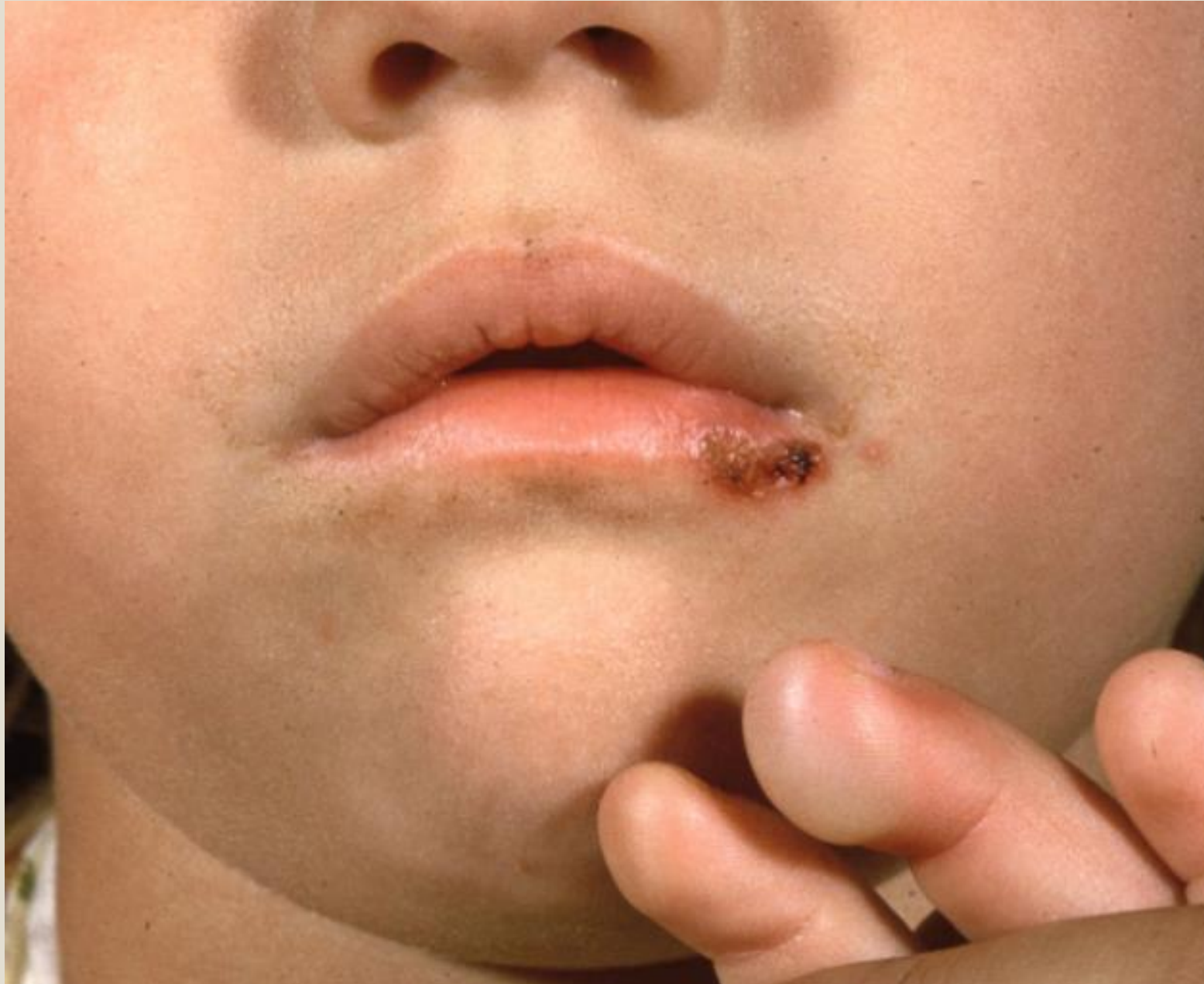- **Clinical presentation is usually diagnostic**
 - Gram staining and cx of blister = **Negative**, because the process is caused by a systemic toxin (contrast to bullous impetigo)
- + Nikolsky sign
- Histology: **subcorneal acantholysis, inflammatory cell poor** blister cavity

What medications known to impair renal function should be avoided in pts with SSSS?

- NSAIDs

HY Facts about SSSS

- SAME exfoliattoxins as bullous impetigo (ETA/ETB) but hematogenously disseminated
- MC site of primary infection
 - Kids = **nasopharynx** or **conjunctivae**
 - Adults = pneumonia or bacteremia



- 5 y/o F
- 1 week history of discoloration of volar fat pad → followed by development of a bullae at that site
- Upon P/E you also note honey colored crusting over a mildly erythematous plaque on the patients lower vermilion lip.

Blistering Distal Dactylitis

- **Pathogenesis**

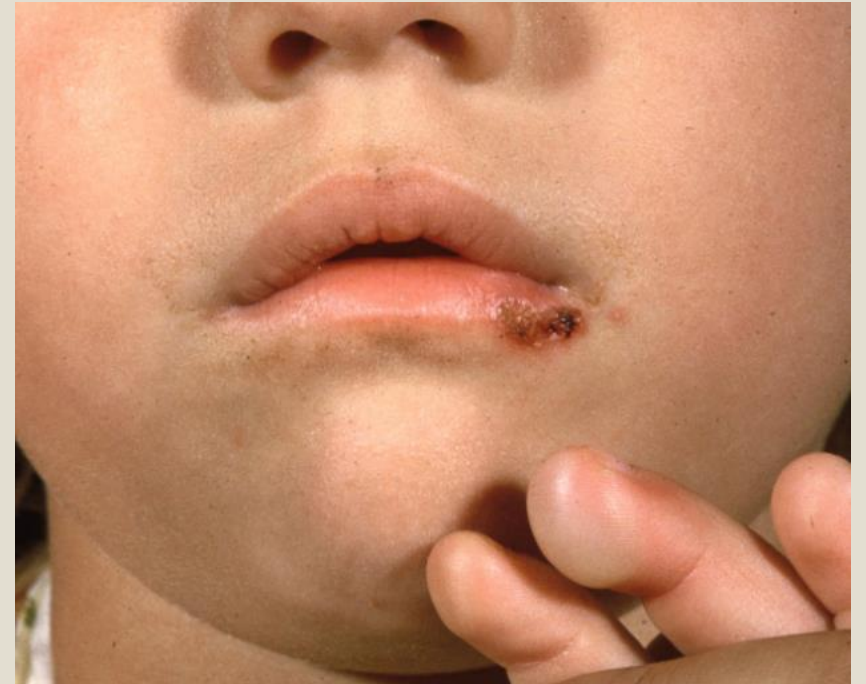- **True or False:** Staph aureus is the mc cause of BDD?
- **False:** *Strep pyogenes* > Staph aureus
- Often, impetigo or other cutaneous infection is present elsewhere.

- **Clinical features**

- Children > adults
- Darkening of the volar fat pad (distal finger > toes) → progresses to vesicle/bullae within one week

- **Diagnosis**

- I&D & obtain gram staining or culture



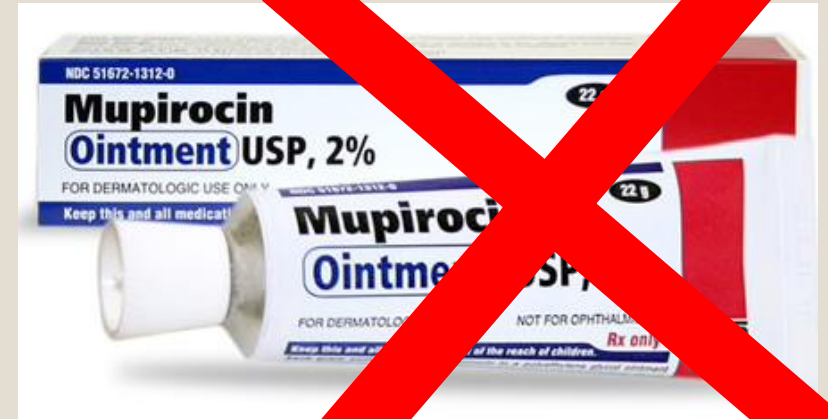Blistering Distal Dactylitis

- **Treatment**

- Aspiration + PO Abx
 - Abx with strep & staph coverage
 - Dicloxacillin 3.125- 6.25 mg/kg for kids <40kg
 - Cephalexin, erythromycin or clindamycin
 - Topical abx, at least as solo therapy, not recommended
- NB: there is no evidence that aspiration/I&D speeds recovery but, it does improve symptomatology

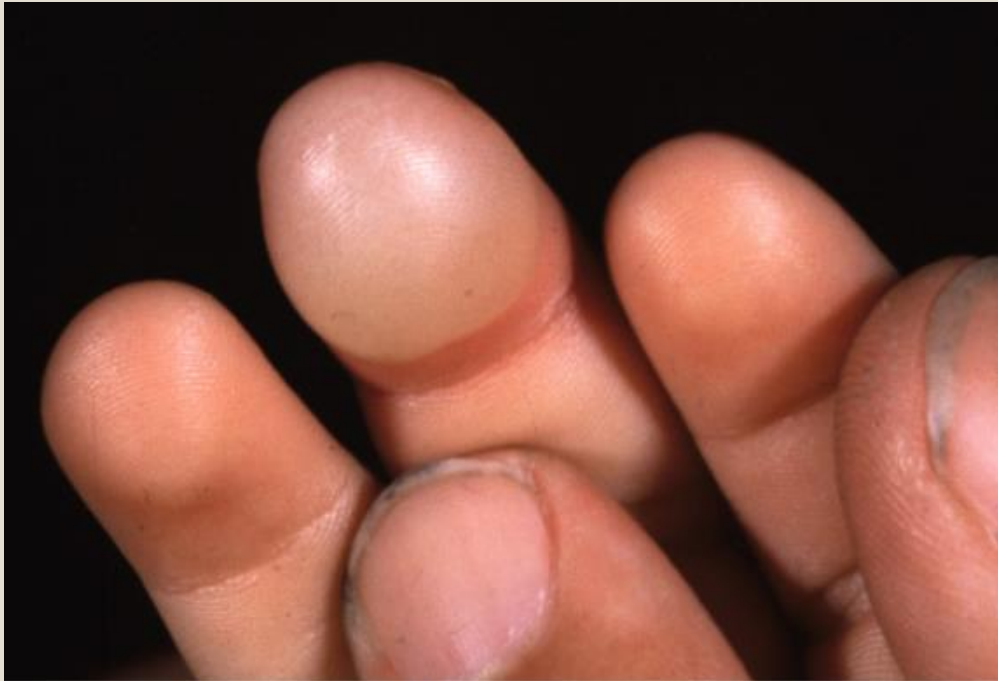- **Clinical Course**

- After treatment patient should demonstrate improvement within 72 hours

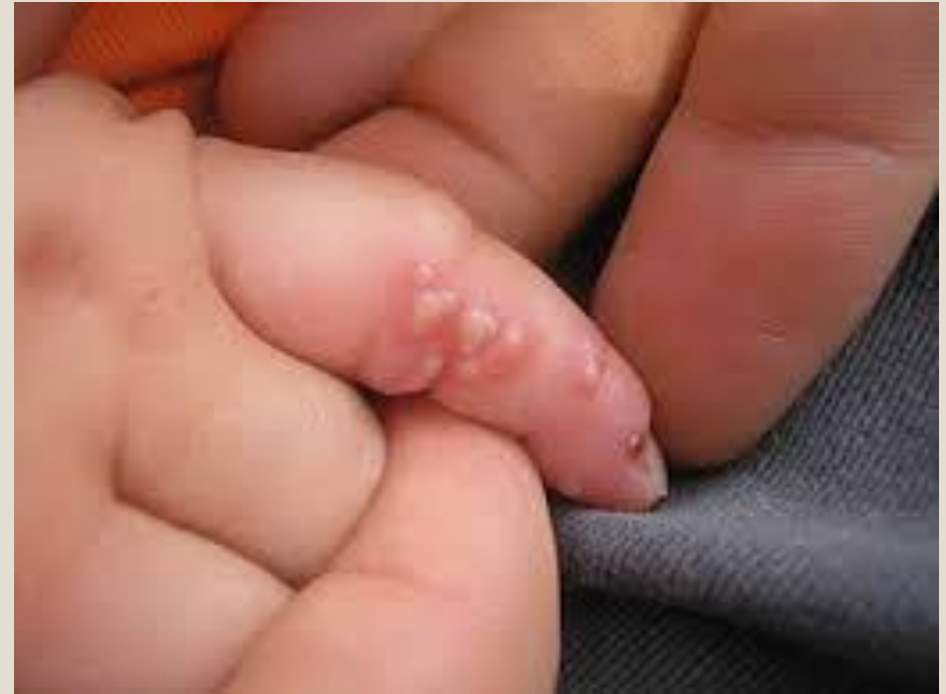

Important diagnostic clue to differentiate blistering distal dactylitis vs herpetic whitlow?

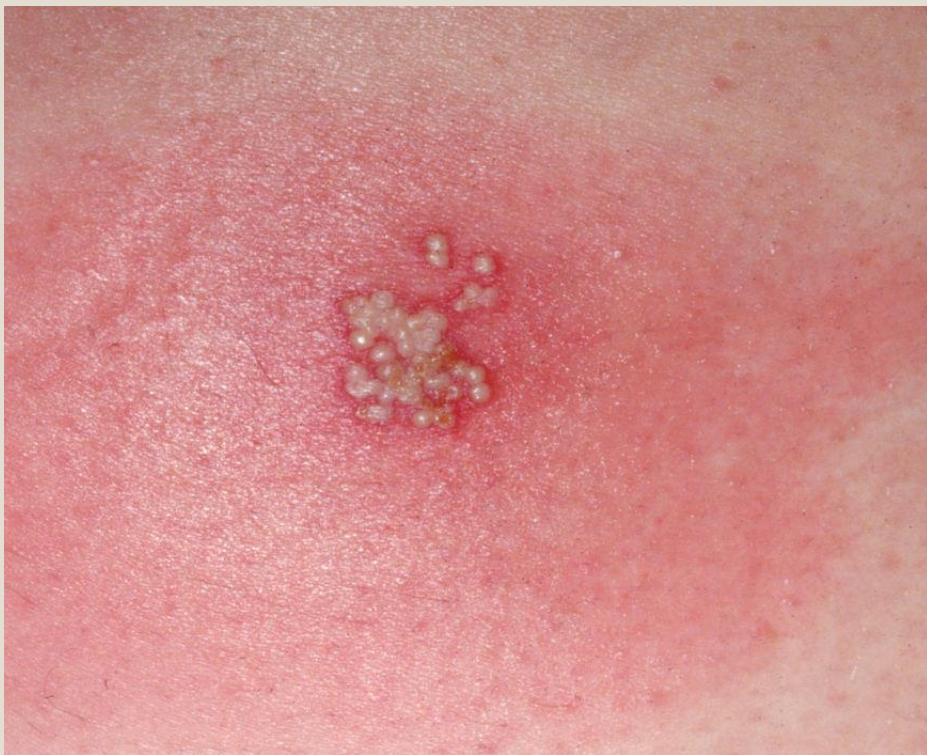Unilocular blister = BDD



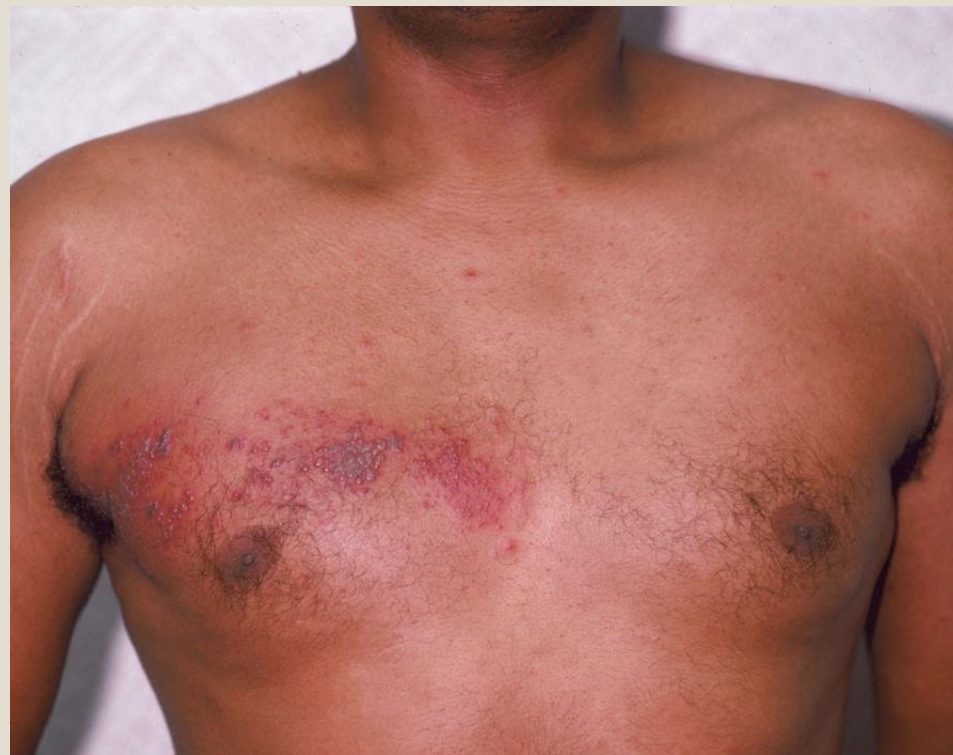Multilocular blister = HW



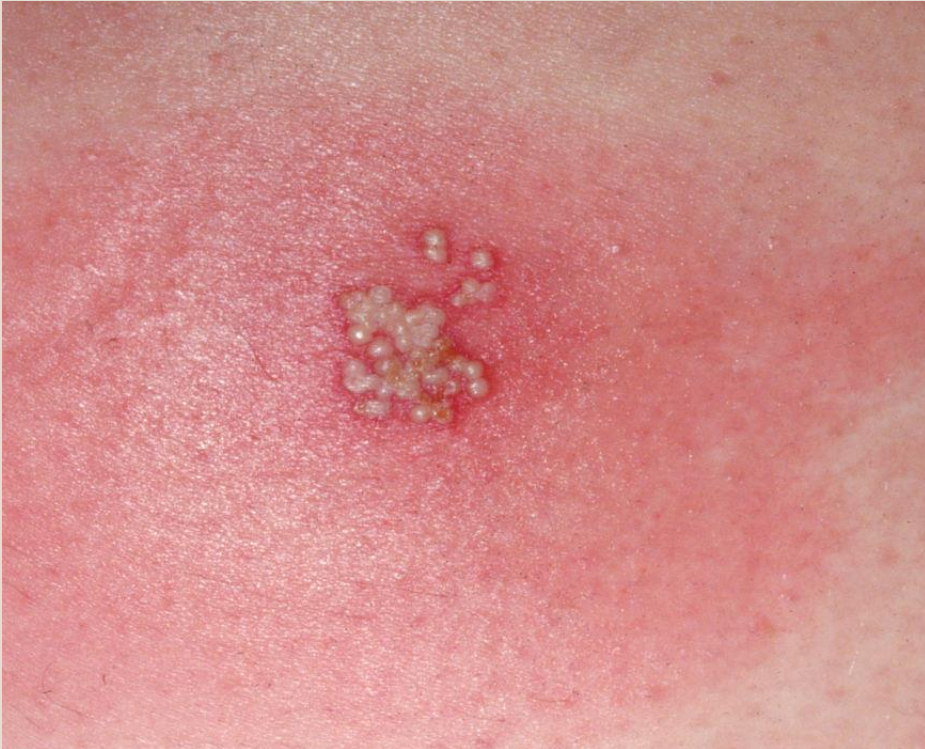Grouped vesicles/pustules on an erythematous base



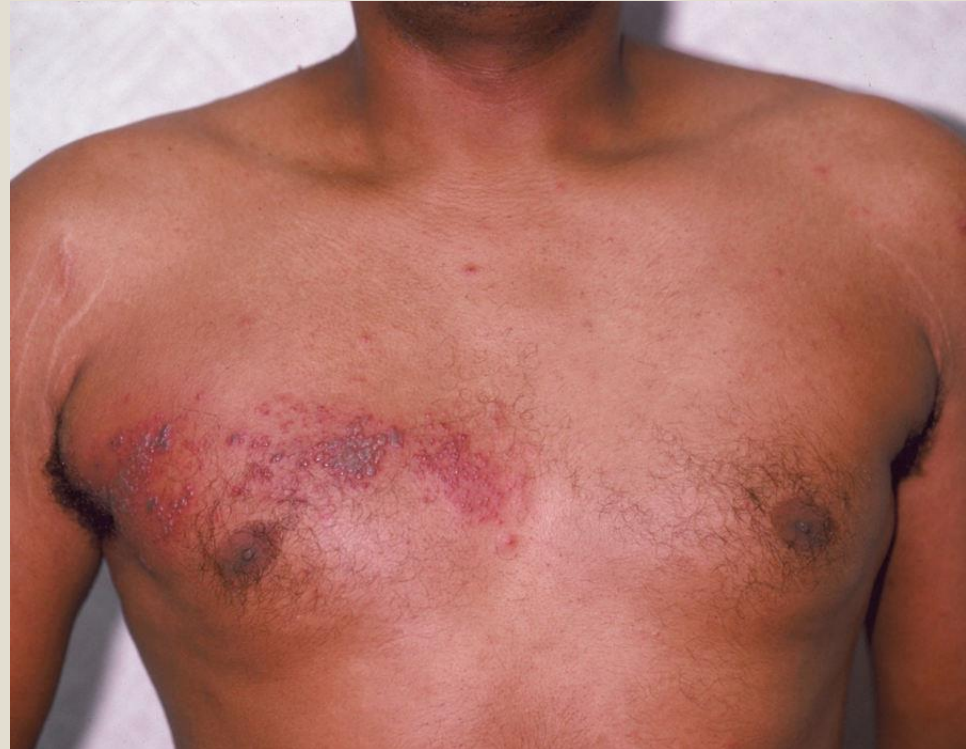Grouped vesicles on an erythematous base in a T3 distribution



HSV



VZV



Human Herpes Viruses: HSV vs VZV

- HHV = 8 distinct human herpesviruses (HHV-1 to HHV-8) all belong to *Herpesviradae* family, all are characterized by **double stranded DNA** and replicate in **host nucleus**.
- **Herpes simplex Virus** = HSV-1 & HSV-2
- **Varicella zoster virus** = HHV-3

Human Herpes Viruses: HSV

- Recurrent vesicular eruptions occurring in **orolabial (classically HSV-1)** and **genital (classically HSV-2)** regions
- Primary infection → Latency = virus **lies dormant in sensory (dorsal root) ganglia**; reactivation/recurrence (may → symptoms)
 - 1° infection: 3 to 7 days post infection → prodromal symptoms (tender lymphadenopathy, malaise, anorexia, and fever) → mucocutaneous lesions +/- pain/tenderness/burning/tingling just before lesions erupt
 - **Recurrent infections: generally milder than 1° infections**, have 24 hour prodrome of tingling/itch/burning

Pathogenesis

- Infection can occur without clinical lesions & virus may still be shed
 - HSV-1 spread by saliva/secretions and HSV-2 spread by sexual contact
- HSV can evade host immune system (e.g., ↓expression of CD1a by APCs, ↓TLR signaling)

Human Herpes Viruses: HSV

Diagnosis

- Viral culture (high specificity, low sensitivity), direct fluorescent antibody assays, serology (Western blot = gold standard), **PCR (most sensitive/specific)**, and **Tzanck smear**

Treatment

- Orolabial: oral valacyclovir, topical penciclovir, or topical acyclovir/hydrocortisone combination
- Genital: oral acyclovir/famciclovir/valacyclovir
- Use meds w/in first 48 hours → ↓pain/healing time/viral shedding
- Suppressive daily doses may be given in patients with >6 outbreaks of orolabial/genital HSV per year (also ↓viral shedding)
- May need **IV acyclovir in eczema herpeticum, neonatal HSV, or severe HSV in immunosuppressed**
- **Foscarnet or cidofovir for acyclovir-resistant HSV** (more common in immunosuppressed patients)

Boards Factoid

- What is the most common cause of **EM minor**?
- **HSV-1**

Human Herpes Viruses: VZV

- * Causes varicella (chickenpox) and herpes zoster (shingles)
- * Primary varicella incidence has decreased because of VZV vaccination

Pathogenesis

- Transmitted via aerosolized droplets and direct contact with lesional fluid
- Contagious from 1 to 2 days before lesion develops in varicella until all lesions crusted over

Primary varicella (chickenpox)

- Cephalocaudal progression of classic lesions “**dew drops on rose petal:**” vesicles on an erythematous base that become pustular, then crust over
- Crops of lesions in **various stages**

Reactivation (herpes zoster)

- **Prodrome** (itch, tingling, hyperesthesia, and pain) → painful grouped vesicles on red base in a **dermatomal pattern**
- **Trunk = most common location** (thoracic)
- Disseminated disease = dermatomal disease + **>20 lesions outside of dermatome**; increased risk of **life-threatening pneumonitis and encephalitis**
- Ramsay-Hunt syndrome: disease of **geniculate ganglion** of facial nerve (CN-VII) → **ipsilateral facial nerve paralysis**, dry mouth/eyes, **anterior 2/3 tongue taste loss**, and auditory (e.g., **deafness and tinnitus**) and equilibrium issues (vestibulocochlear nerve)
- **Hutchinson's sign** (involvement of the side and tip of nose): disease of the **external division of the V1 nasociliary branch**
- **Bell's palsy if CN-VII affected**

Human Herpes Viruses: VZV

Diagnosis

- Tzanck smear
- **PCR (sensitive, fast)**
- Viral culture (specific, not sensitive), serology (four-fold increase in IgG titer can retrospectively confirm prior infection), and skin biopsy

Treatment

Primary varicella

- Systemic acyclovir or valacyclovir **within 3 days of lesion onset** → ↓severity/duration disease
- Primary prevention = varicella vaccination → **Contraindicated in pregnancy and in immunocompromised patients**

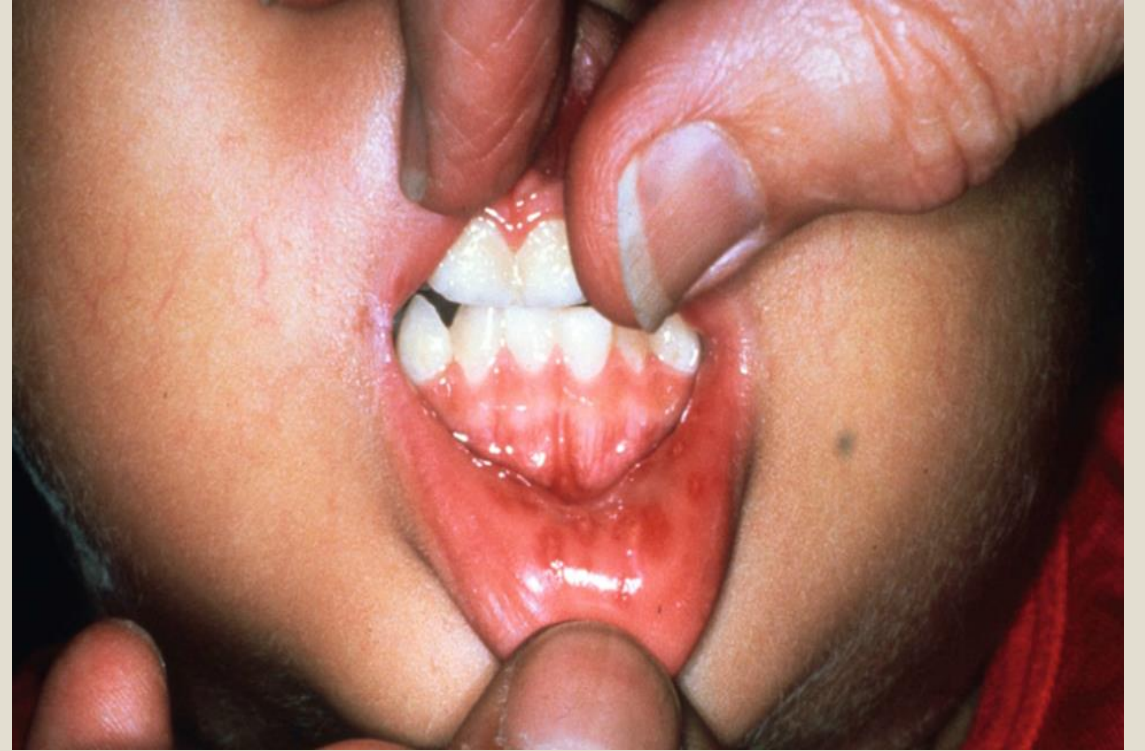
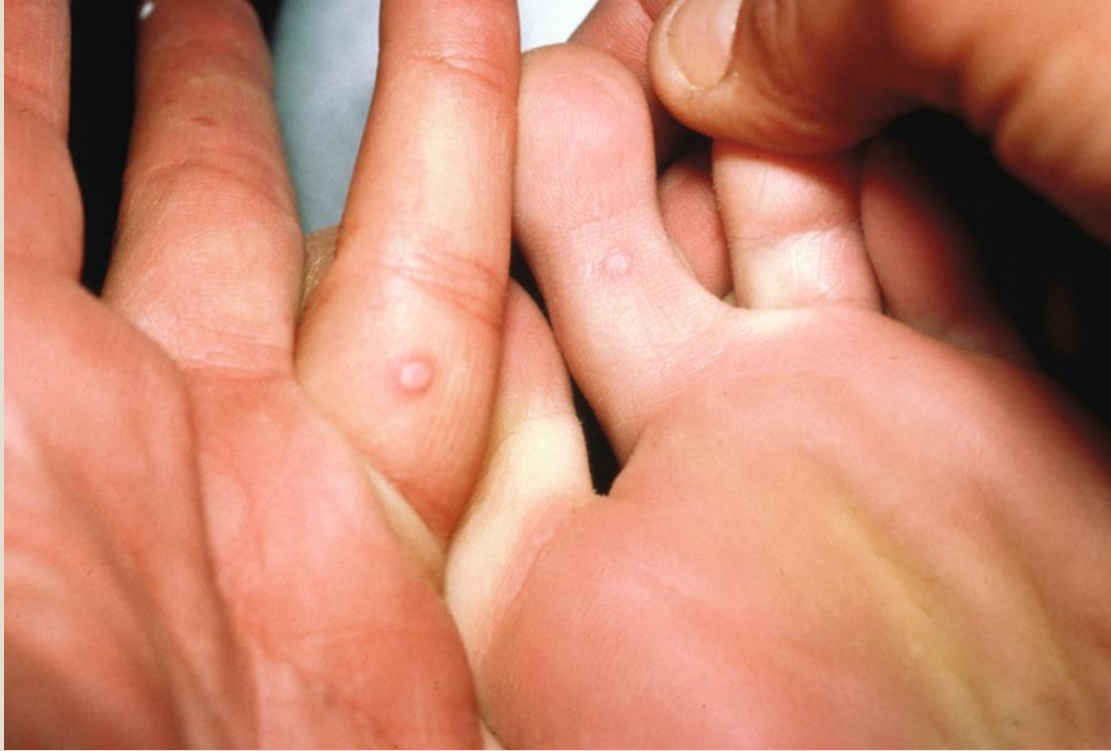Herpes zoster

- **Antiviral treatment** with acyclovir, famciclovir, or valacyclovir is best given **within 72 hours; prednisone** helps with **acute pain** but has no effect on course or development of PHN
 - ↓duration of lesions/pain
 - ↓rate of postherpetic neuralgia (PHN) in patients >50 years old
- PHN: tricyclic antidepressants (e.g., nortriptyline), gabapentin, 8% capsaicin patch, pregabalin, opioid analgesics, and lidocaine patch
- **Live attenuated vaccine** → **≈50%↓ in development of disease and 67%↓ in PHN**; for immunocompetent patients >60 years old

What treatment decreases the risk of postherpetic neuralgia?

Antiviral treatment or prednisone?

- Antiviral tx



Erythematous macules & vesicles with **gray center** distributed on the palms, soles and oral mucosa.

Hand Foot and Mouth Disease (HFMD)

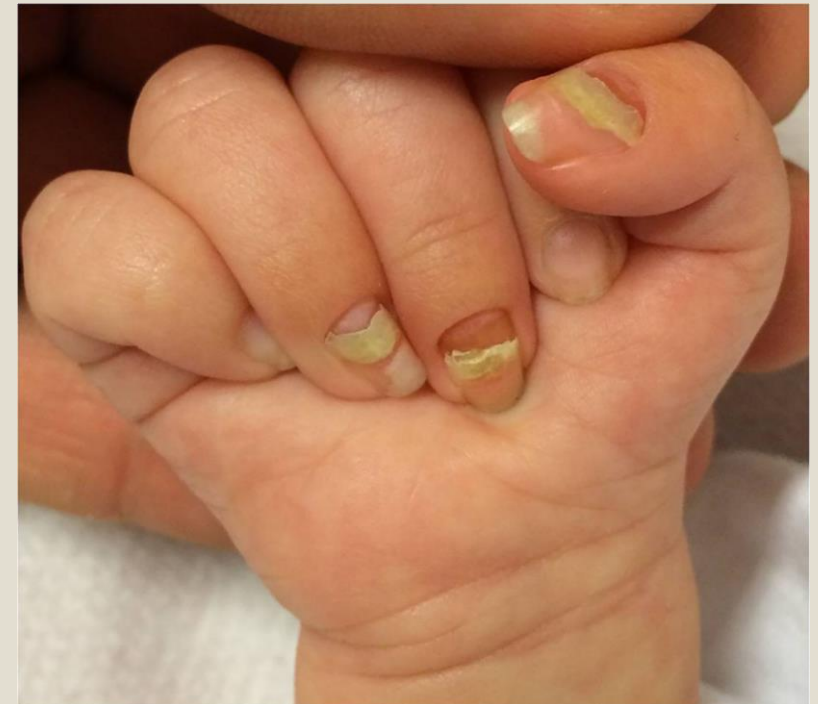- Pathogenesis
 - **Coxsackie A16 virus > Coxsackie A6 > Enterovirus 71**
- Clinical features
 - MC in **Children** >> Adults
 - Outbreaks usually occur from June to October
 - An acute, self-limited viral illness characterized by an oral enanthem with accompanying vesicular eruption
 - Erythematous macules & vesicles and bullae with gray center
 - Typical course starts with **prodrome (fever, abd pain, fussiness, emesis, diarrhea) → 2 days later small oral macules/vesicles → lesions then develop on hands/feet/buttock and can eventually become more widespread**
- Transmission
 - **Fecal-oral & respiratory secretions** → highly contagious and commonly transmitted in day care centers, schools, summer camps, and hospitals
 - The incubation period for the virus is approximately 3-6 days, symptoms last 7-10 days
 - Individuals can shed the virus via GI passage for **4-6 weeks** or via the **upper respiratory tract for 3 weeks**

Hand Foot and Mouth Disease (HFMD)

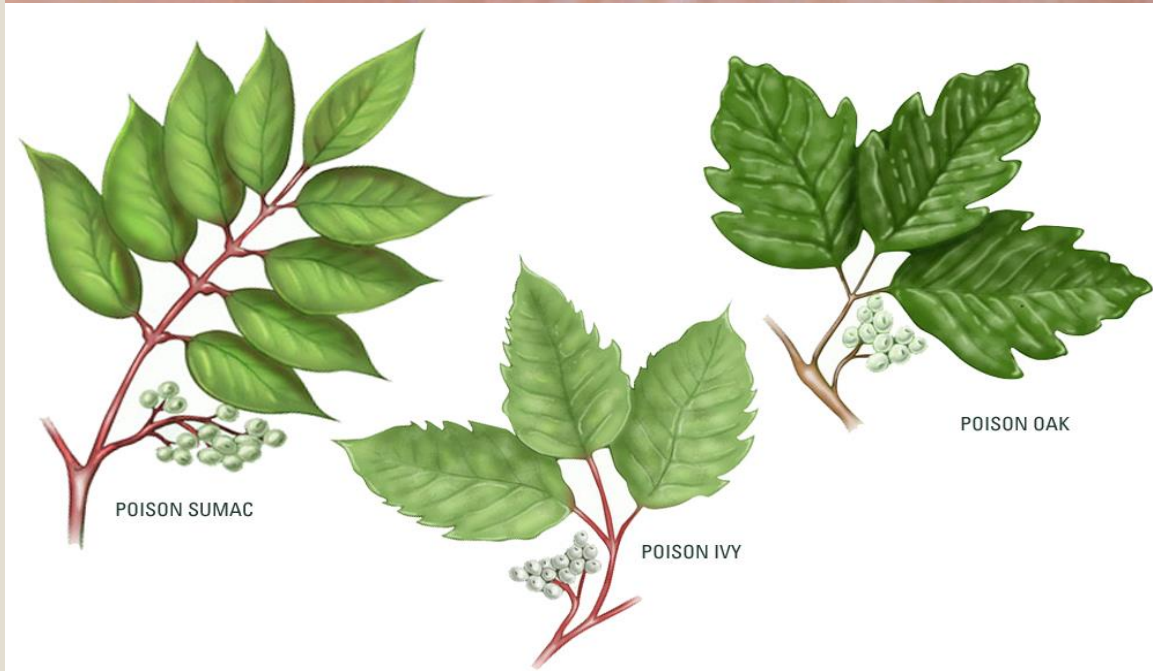
- Diagnosis
 - Usually a **clinical diagnosis**
 - Polymerase chain reaction (**PCR**) can be obtained from vesicular or nasopharyngeal swab
 - Serum antibody testing may also be performed
 - CBC may reveal leukocytosis
- Treatment
 - **Supportive care & Prevention**
 - Hand hygiene
 - **Special consideration should be taken by caregivers changing diapers since CV16 and EV71 can be shed in feces for weeks following infection**
 - Disinfection of surfaces with secretions or feces is necessary to prevent secondary transmission

Hand Foot and Mouth Disease (HFMD)

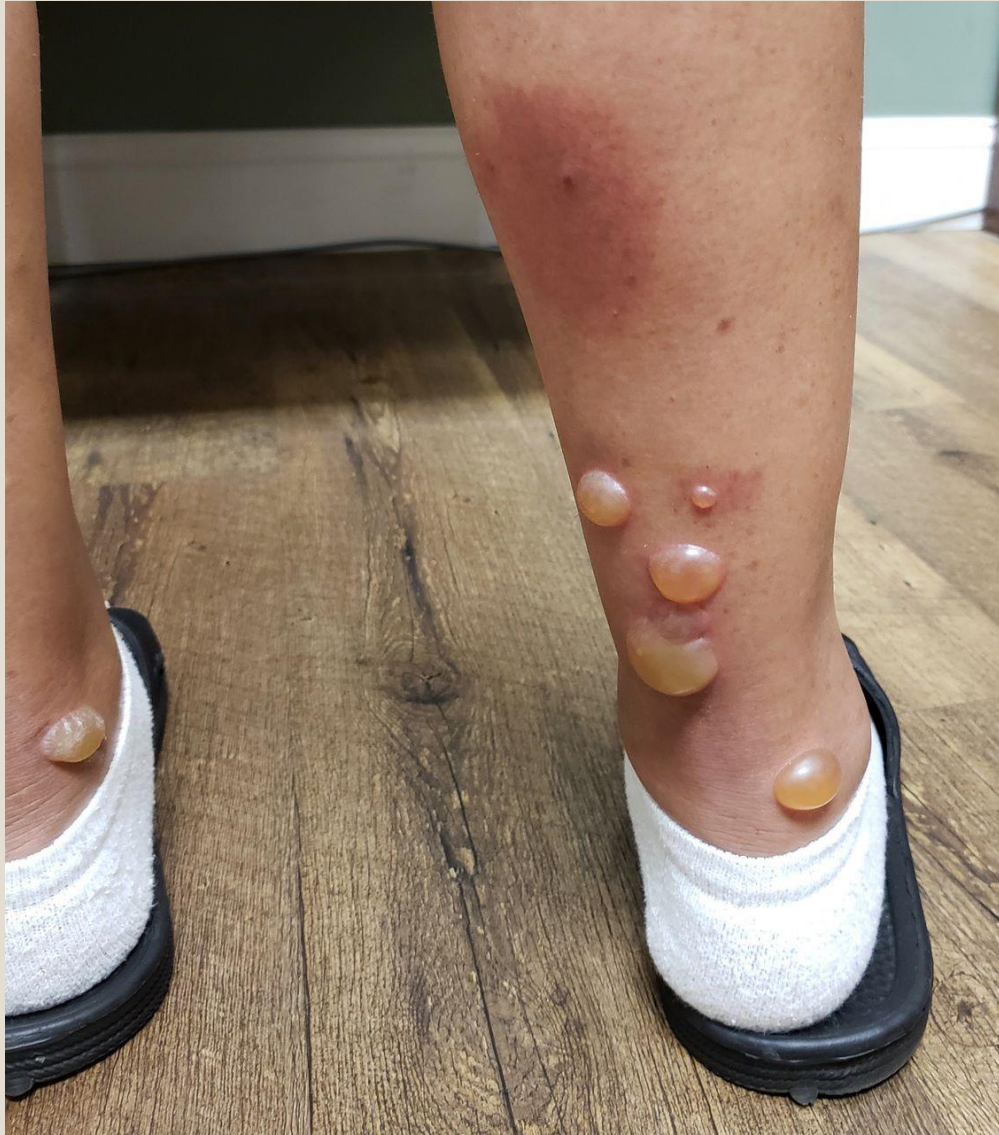- !Boards Factoid!
 - **Coxsackie A6** → causes more widespread & severe vesiculobullous eruptions & is associated with atypical presentations
 - **Enterovirus A71 (EA71)** → can result in uncommon, **severe sequelae**, including encephalitis, interstitial pneumonia, flaccid paralysis, myocarditis, heart failure, meningoencephalitis, pancreatitis, conjunctival ulceration, and spontaneous abortion. Lesions are more likely to present on atypical sites such as the face, scalp, and ankles or diffusely on the whole body
 - **Eczema coxsackium**: diffuse HFMD in atopic patients
 - **Onychomadesis**: common following HFMD due to **nail matrix arrest** at time of infection



Bassi A, Greco A, de Martino M
Neonatal onychomadesis
Archives of Disease in Childhood - Fetal and Neonatal Edition 2016;**101**:F161.



External



Urticarial plaques and tense bullae on the exposed areas of the lower extremities.

Collins P, Sepede J
Bullous arthropod bite reaction
BMJ Case Reports CP 2018;11:e228079.

Bullous Insect/Arthropod reactions

- **Pathogenesis**

- **Hypersensitivity reaction** to allergen i.e. saliva (bedbugs, ticks), feces (scybala of scabies)
- Common causes of **bullous arthropod reactions = bedbugs (Cimex lectularius), fleas and chiggers**

- **Clinical features**

- Exposed areas of the body typically affected → urticarial papules & bullae
- Lesions may be solitary or grouped (breakfast, lunch and dinner arrangement of bedbug insult)
- Consider **leukaemia (CLL)** and other hematological cancers in patients with bullous reactions as these reactions are more common in patients with these disorders

- **FYI**

- According to a major national extermination company, the **Top 10 cites for bedbugs: Detroit, Philadelphia, Cleveland, LA, Dayton, Chicago, Columbus, Cincinnati, Dallas & San Francisco**

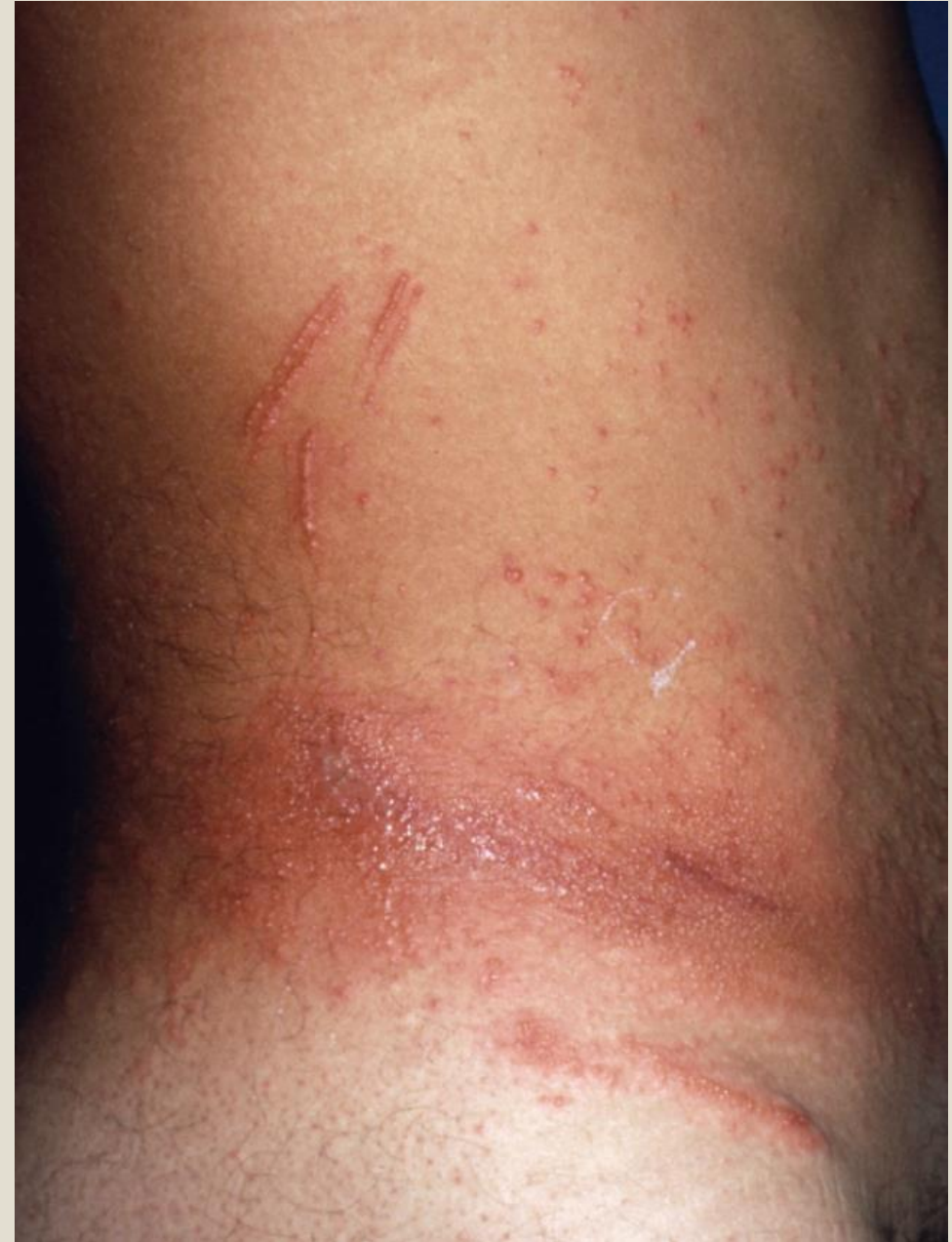- **Treatment**

- Antihistamines, supportive care
- Oral Abx if secondary bacterial infection suspected/identified
- Repellants, extermination, topical or oral antiparasitic treatments

- **Clinical Course**

- Self limiting, as long as source removed

Linear vesicles coalescing into an erythematous plaque in a unilateral distribution.



Bullous Allergic Contact Dermatitis

- **Pathogenesis**

- Uroshiol (poison ivy) or other contactant is introduced to the skin → erythema and blisters 24-72 hours after contact in sensitized patient
- While most ACD is eczematous, severe ACD may present with marked blistering

- **Clinical features**

- **Extreme pruritus**
- **Typically asymmetric configuration. A unilateral linear array of vesicles is a good clue.**

- **Diagnosis**

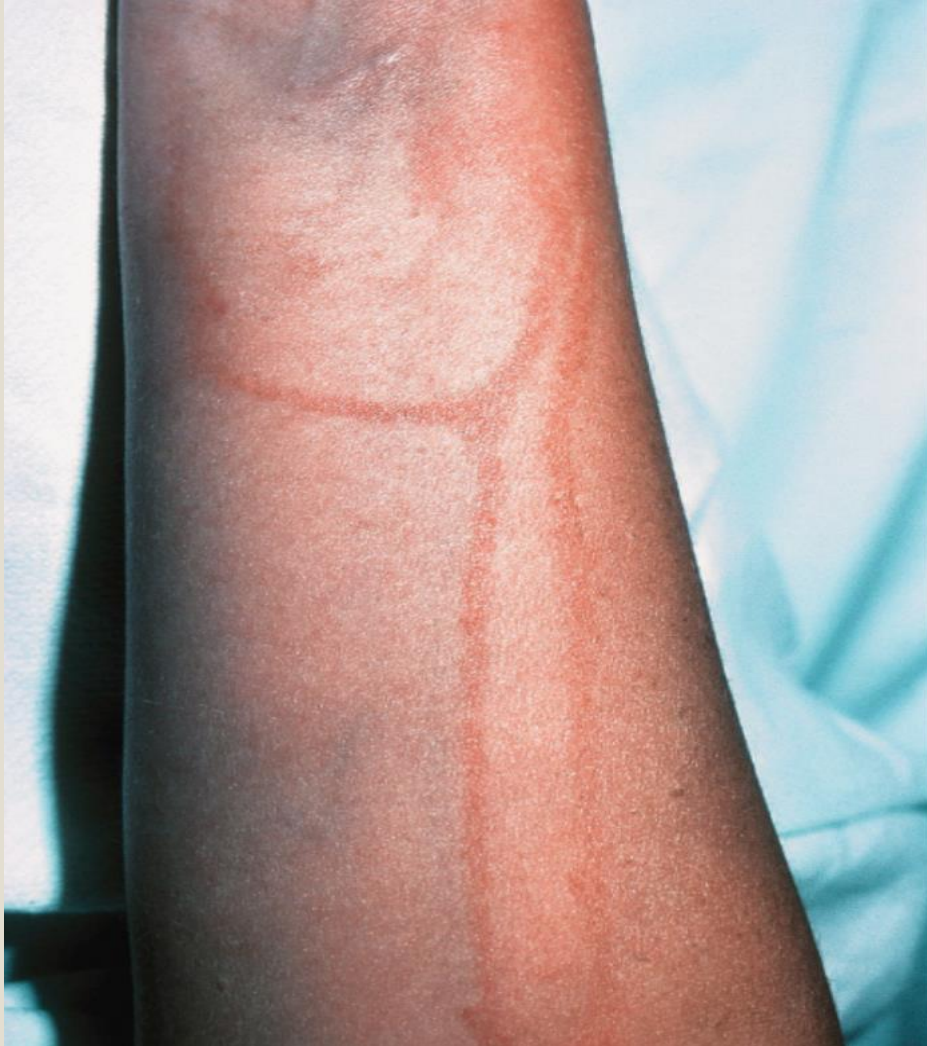- **Careful history & physical**
- Patch testing
- Shave or punch biopsy for H&E
- Occasionally, perilesional DIF to exclude autoimmune bullous entities

- **Treatment**

- Remove/avoid allergen
- Potent topical steroids
- Generalized cases may require PO corticosteroids → **21 day course**
 - Urushiol binds irreversibly to the skin and requires treatment for up to 21 days. A prednisone dose pack (5 days) should be avoided as they patient will likely experience a rebound/flare
- Antihistamines do not shorten disease course but, may provide symptomatic relief

- **Clinical Course**

- New blisters and erythema may develop for up to 3 weeks, without additional exposure



- The patient rinsed her hair with **lime** juice in Mexico and subsequently went in the sun.
- She developed **linear vesicles** followed by **hyperpigmentation**.

Andrews et al. Andrews' Disease of the skin. 11th Ed. Elsevier. 2011.

Phytophotodermatitis

- Caused by **fucocoumarins in plants + UVA light (320–400nm)** → erythema +/- blistering (24–72 hrs post-contact) followed by **hyperpigmentation** (1 to 2 weeks later)
- 4 MC plant families in the USA
 - **Apiaceae/Umbelliferae**
 - **Rutaceae**
 - **Moraceae**
 - **Fabaceae (legumes)**

Phytophotodermatitis

Apiaceae/Umbelliferae

- Flowers easily identified as they are clustered on a stalk and arise from a single point
- **Hogweed** (*Heracleum*), cow parsley, and wild chervil: “**strimmer dermatitis**” after weed whacking
- **Parsley, parsnips, celery**, and carrots: “harvester’s dermatitis” in gardeners
- Mnemonic:
“**A**piaceae/**U**mbelliferae phytophotodermatitis = **Ape** holding an **Umbrella**-looking plant to stay protected from **sun**”



Phytophotodermatitis

Rutaceae

- **Citrus** (lemon, lime, grapefruit), rue
 - Common cause in **bartenders** and spring breakers
- *Citrus bergamia* (bergamot orange): causes **berloque dermatitis**
- *Pelea anisate* (**Hawaiian leis**)
- **Lime beer dermatitis:**
phytophotodermatitis variant that may be widespread rather than linear, due to aerosolization of lime-beer mixture



Phytophotodermatitis

- **Moraceae**

- Fig and fig leaves
- Mulberry

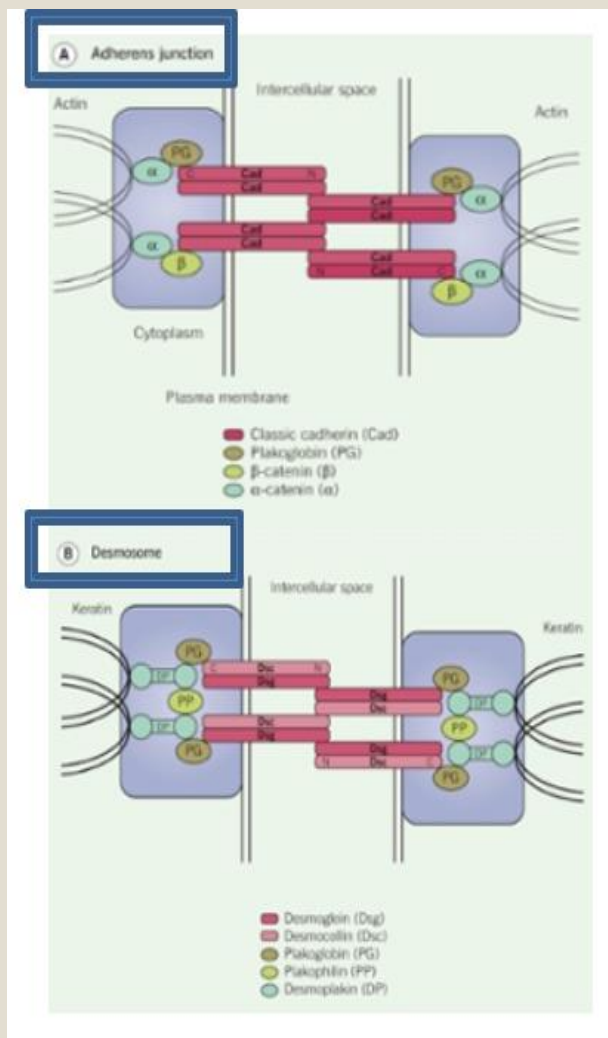
- **Fabaceae (legumes)**

- Bavachee/scurf pea (used as vitiligo treatment)
- **Balsam of Peru** (*Myroxylon balsamum*, *Myroxylon pereirae*)



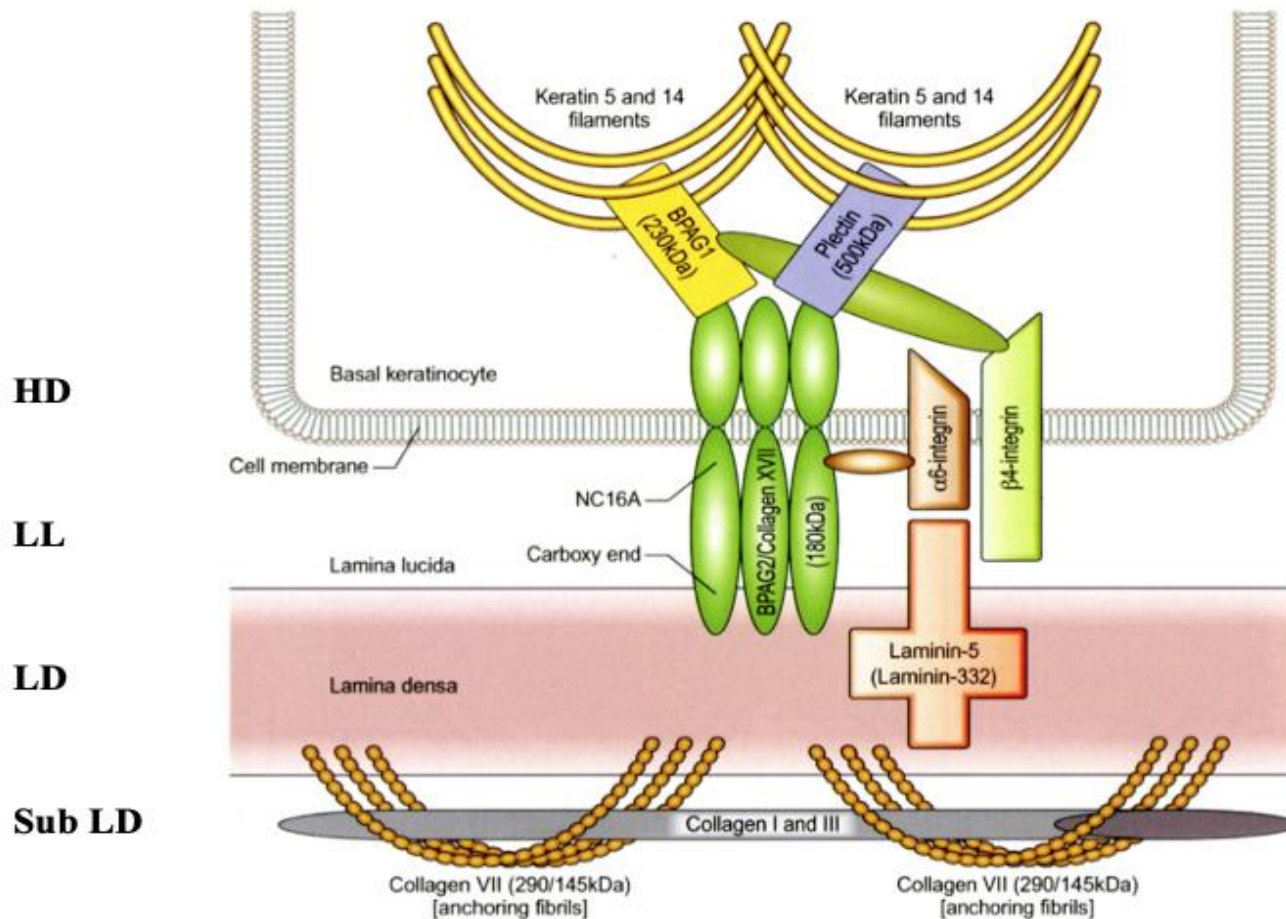
Copywrite: Figs

Pemphigus



Pemphigoid

Basement Membrane Zone



Quick review of Pemphigus: types and subtypes, oversimplification = autoantibodies against desmosomes

Pemphigus Foliaceus

- Pemphigus erythematosus (~~Senechal-Usher~~)
- Fogo ~~schlegelii~~ (endemic)
- Drug-induced pemphigus (Penicillamine, Captopril)
- Pemphigus herpetiformis

IgG4 to DSG-1

IgA Pemphigus

- ~~Subcorneal~~ Pastular Dermatitis
 - o IgA anti-~~desmocollin 1~~
- Intraepidermal neutrophilic type
 - o IgA DSG-1 / DSG-3

SPD (DIF +) vs Sneddon Wilkinson (DIF -), otherwise identical

Pemphigus Vulgaris

- Mucosal dominant
- Mucocutaneous
- ~~Pemphigus vegetans~~
 - Neumann (severe)
 - ~~Hallopeau~~ (mild)

IgG to DSG-1 / DSG-3

Paraneoplastic Pemphigus

Autoantibodies to everything!
NHL > CLL > Castleman's

Quick review of Pemphigoid: types and subtypes, oversimplification = autoantibodies against BMZ

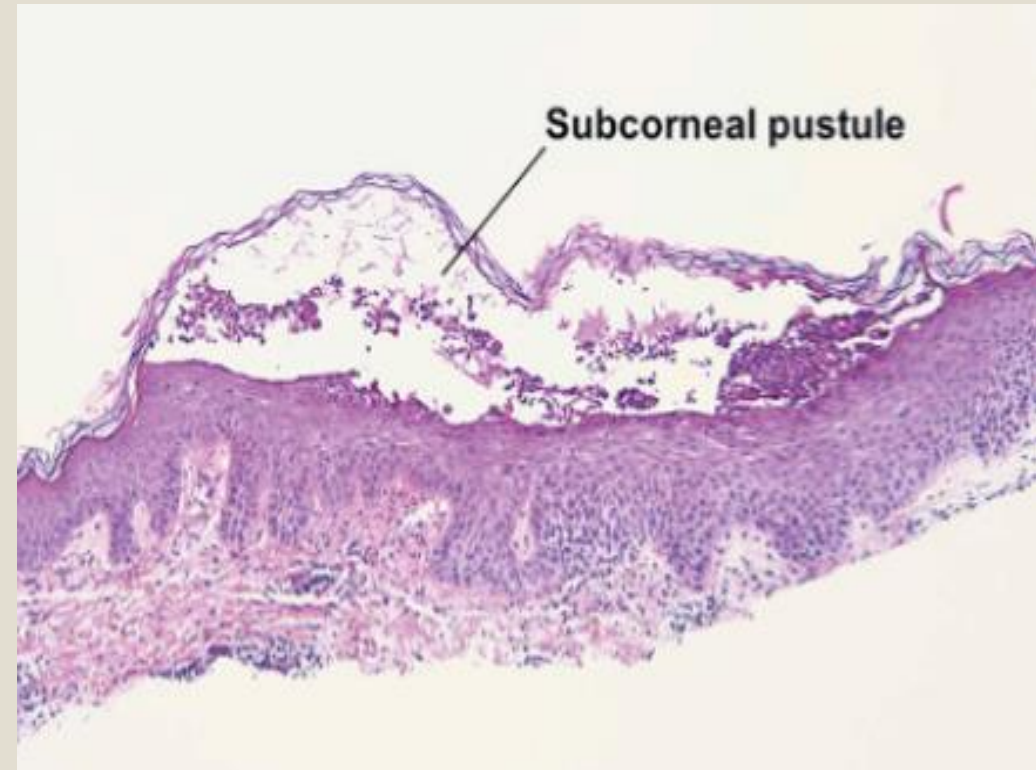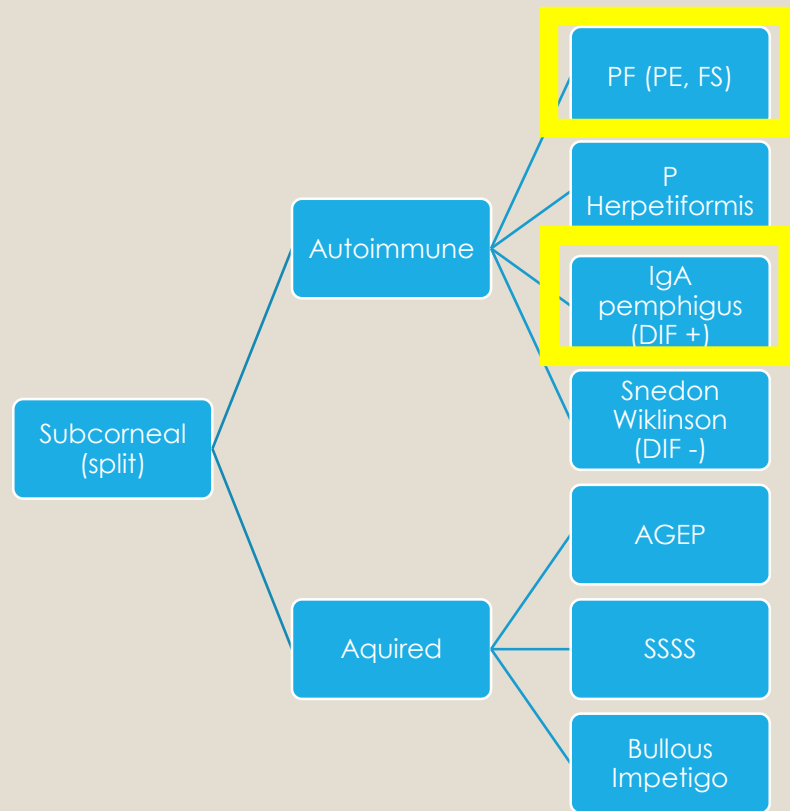
Bullous Pemphigoid

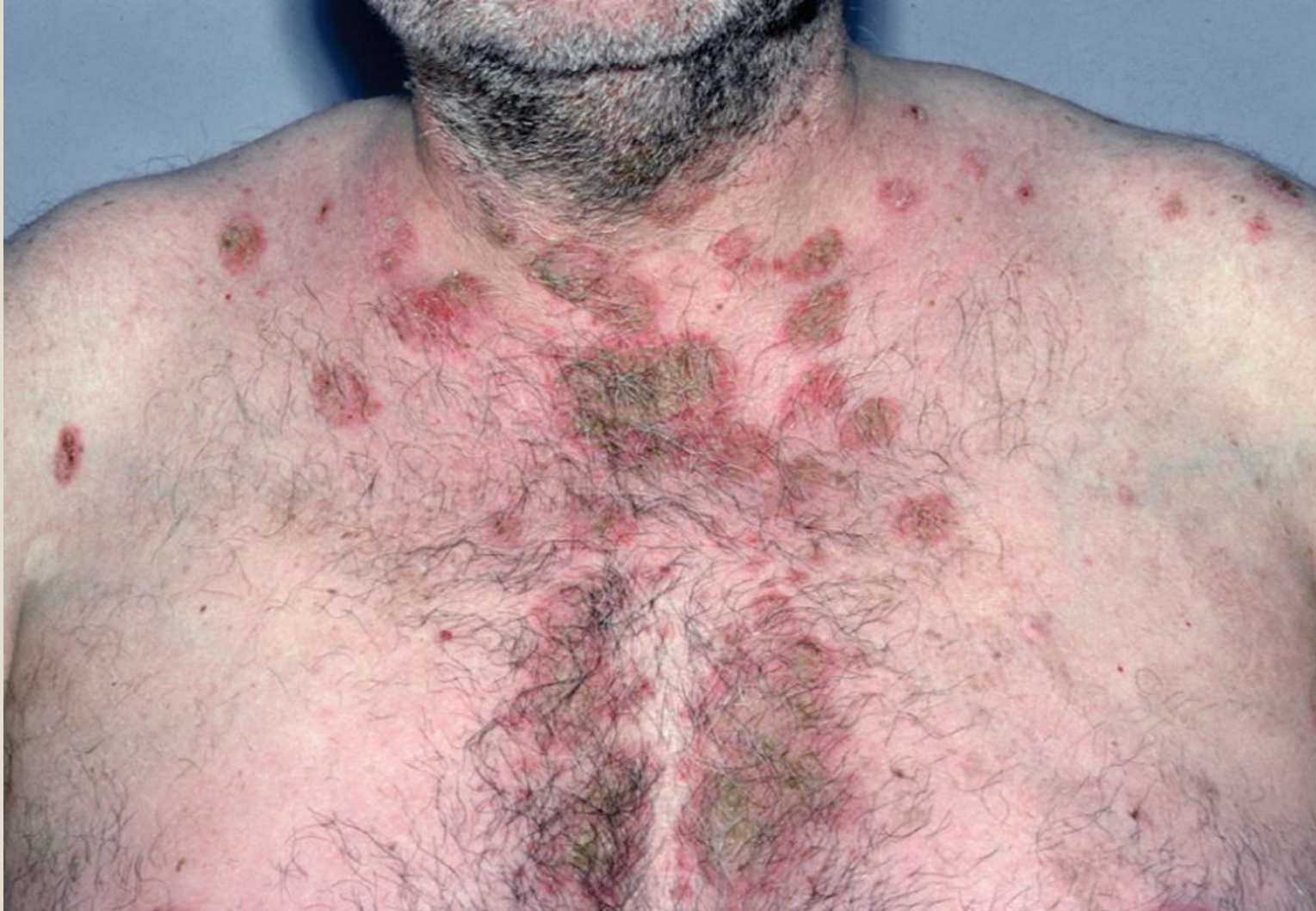- IgG to BPAG2, BPAG1
- Drug induced, ex = furosemide

Mucous Membrane (Cicatricial) Pemphigoid

- Classic MMP: IgG to BPAG2 (c-terminus)
- ~~Antiglomerular~~ MMP: IgG to Laminin 332 (a/b; solid organ malignancy #1 = adenocarcinoma)
- Ocular MMP: IgG to B4 subunit of alpha-6-beta-4 integrin

Subcorneal split





Impetigo-like crusted erosions
on an erythematous base in a
seborrheic distribution →
“cornflakes”

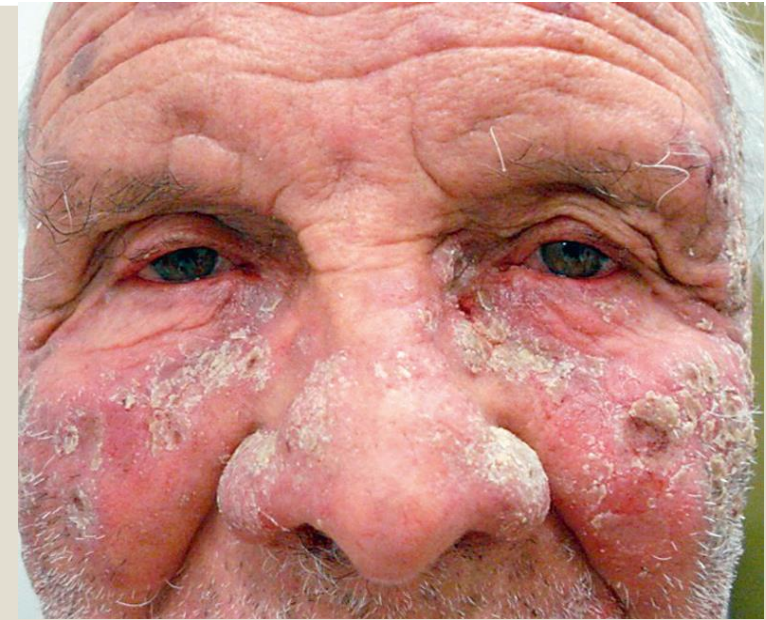Pemphigus Foliaceus

Pathogenesis

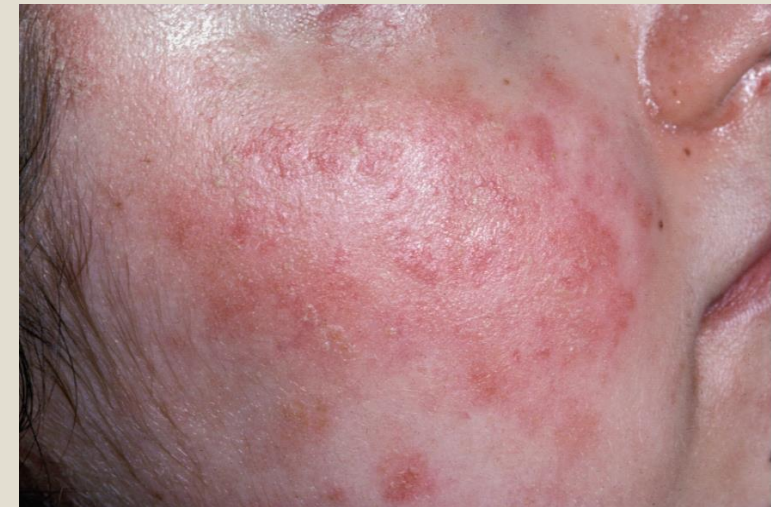- Autoantibody: **IgG4 to Dsg1**

Clinical features

- 2nd mc form of pemphigus
 - Exceptions = Brazil, Tunisia and Finland
- Adults >>> children
- Predilection for Head and neck & lacks mucosal involvement
- Recurrent, superficial, often ruptured blisters with a background of erythema and scaling
- **“Impetigo-like crusted erosions on an erythematous base in a seborrheic distribution” → cornflakes**
- Two important variants
 - **Fogo selvagem**: endemic variant. Highest incidence in areas near rivers rich in **black flies (*Simulium pruinosum*)**; more common in children
 - **Pemphigus erythematosus (Senear-Usher syndrome)**: lupus + PF → malar and seborrheic areas
 - +ANA (30%)
 - DIF: intercellular pemphigus pattern + granular/linear band IgG & C3 along BMZ (lupus band)



Fogo selvagem



Senear-Usher

Pemphigus Foliaceus

◦ Diagnosis

- Culture, r/o secondary infection (may cause flare)
- Shave/punch of AA
- **Perilesional DIF** placed in immunofluorescence transport media or normal saline (for periods of <24-48 hrs)
- **IIF** using **guinea pig esophagus** as substrate
- R/o causes of drug induced PF
 - Thiols: ACE inhibitors (**captopril** >> enalapril, lisinopril), **Penicillamine** = common
 - Non-thiols: B-lactams, CCBs, BBs, gold, sulfasalazine = rare

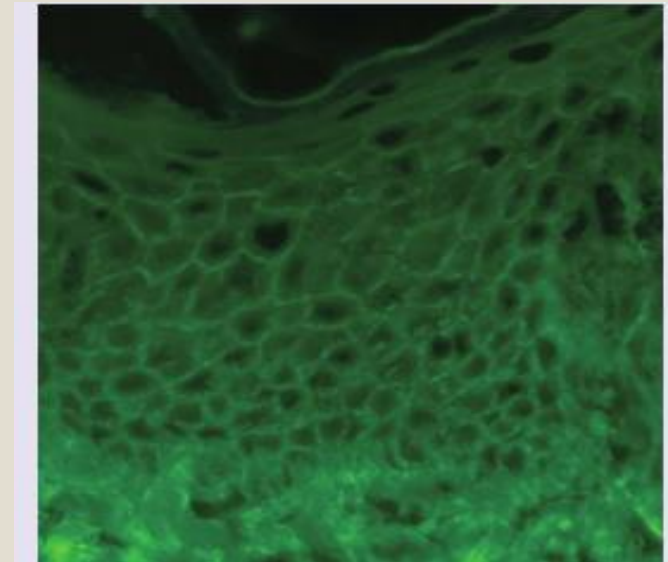
Guinea Pigs eat foliage

◦ Treatment

- **PO prednisone** (0.5 – 1.0 mg/kg per day) with a SLOW taper. **Don't forget Ca and Vit D supplementation**, consider DEXA scan and recommend f/u with PCP for osteoporosis monitoring
- While tapering steroid begin **steroid sparing agent**: mycophenolate mofetil, MTX, azathioprine, dapsone, cyclophosphamide or rituximab

◦ Clinical Course

- Chronic
- In contrast to PV, more benign course but can greatly affect QOL



Intracellular IgG & C3:
PF or PV

Corticosteroid Taper: recommended regimen

The goal of tapering is to use a rate of change that will prevent both recurrent activity of the underlying disease and symptoms of cortisol deficiency due to persistent HPA suppression. We generally aim for a relatively stable decrement of 10 to 20 percent, while accommodating convenience and individual patient response. The dose is tapered by:

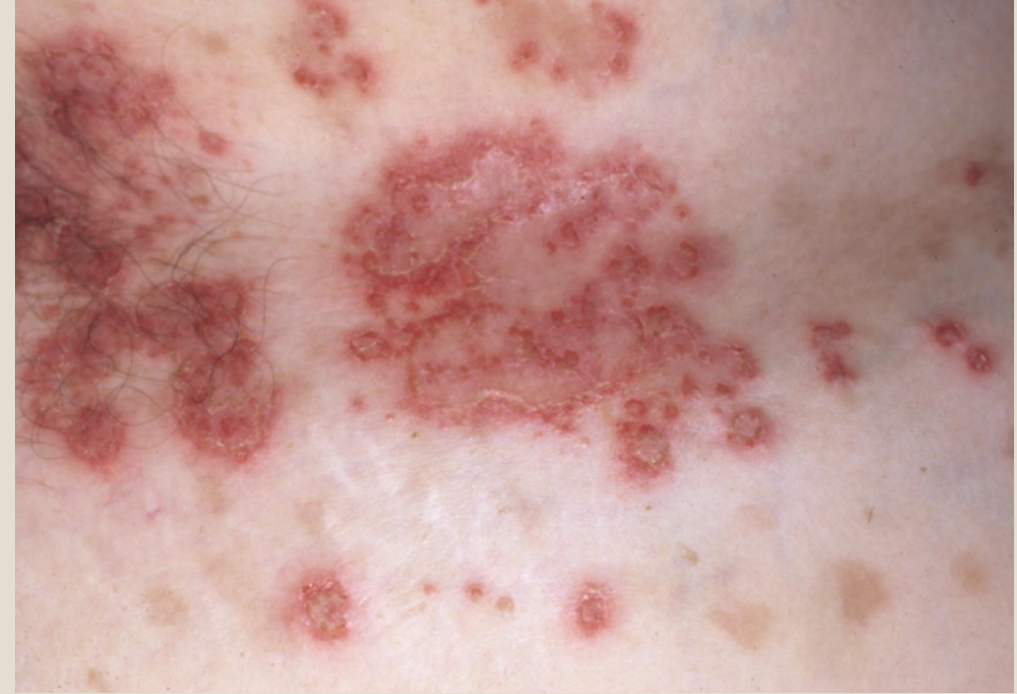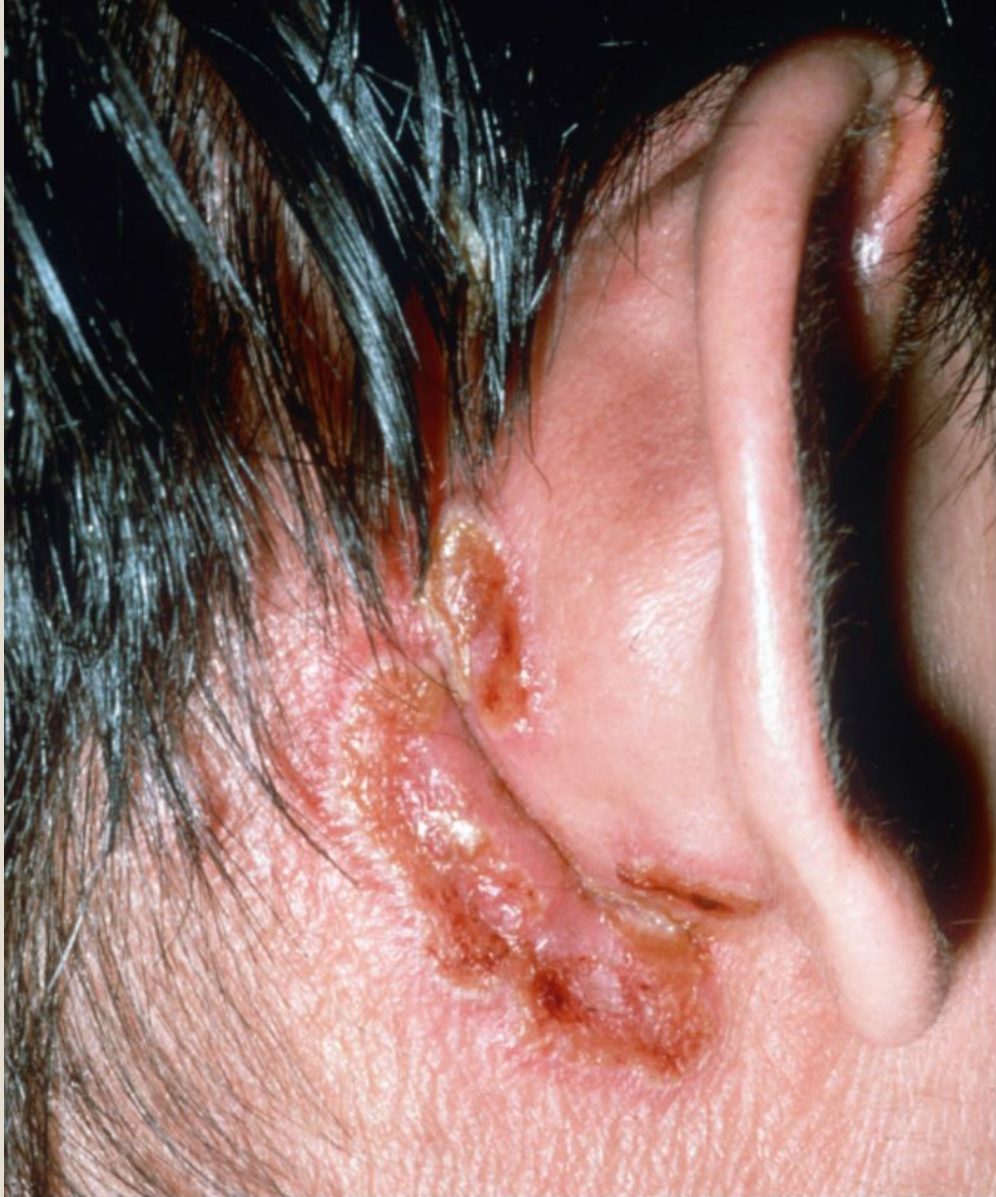- 5 to 10 mg/day every one to two weeks from an initial dose above 40 mg of [prednisone](#) or equivalent per day.
- 5 mg/day every one to two weeks at [prednisone](#) doses between 40 and 20 mg/day.
- 2.5 mg/day every two to three weeks at [prednisone](#) doses between 20 and 10 mg/day.
- 1 mg/day every two to four weeks at [prednisone](#) doses between 10 and 5 mg/day.
- 0.5 mg/day every two to four weeks at [prednisone](#) doses from 5 mg/day down. This can be achieved by alternating daily doses, eg, 5 mg on day one and 4 mg on day two.

Calcium & Vit D supplementation if patient taking glucocorticoids for >3 months

- **Calcium and vitamin D** – We agree with the American College of Rheumatology (ACR) Task Force osteoporosis guidelines, which suggest that all patients taking glucocorticoids (any dose with an anticipated duration of ≥ 3 months) maintain a total calcium intake of 1000 to 1200 mg/day and vitamin D intake of 600 to 800 international units/day through either diet and/or supplements [3]. (See "[Calcium and vitamin D supplementation in osteoporosis](#)".)

Which two entities, previously discussed, have the same target within the epidermis as Pemphigus foliaceus?

- Dsg1 =
 - PF
 - Bullous impetigo
 - Staphylococcal scalded skin syndrome

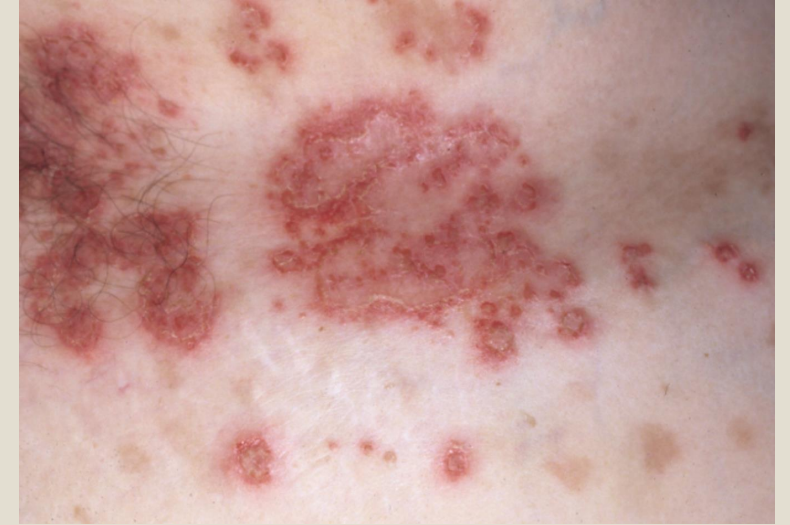

Characteristic **sunflower-like arrangement**
of vesiculopustules

IgA Pemphigus

Pathogenesis

- 2 Subtypes:
 - **Intraepidermal Neutrophilic Type:**
 - **IgA to Desmoglein-1 & 3**
 - Characteristic sunflower-like arrangement of vesiculopustules
 - **+ DIF** intercellular IgA staining throughout entire epidermis
 - **Suprabasilar pustules** → neutrophilic infiltrate confined to the lower epidermis
 - **Subcorneal Pustular Dermatitis Type:**
 - **IgA to Desmocollin-1**
 - Mimics Sneddon-Wilkinson clinically and histologically (need DIF/IIF)
 - **+ DIF** intercellular IgA staining in upper epidermis
 - **Subcorneal pustules** → neutrophilic infiltrate confined to the upper epidermis



IgA Pemphigus

Clinical features

- Pruritic vesicles or pustules in an annular/circinate pattern w/ central crusting; MC on axillae, groin; no mucosal involvement
- A/w IgA gammopathy & possibly multiple myeloma
- **Diagnosis**
 - Shave/punch of AA + perilesional DIF
 - **DIF+** in 100%
 - IIF+ in 50%
- **Treatment**
 - Tx: **Dapsone (TOC)** (resolution w/in 48hrs).
 - Other options: PO corticosteroids & sulfapyridine.

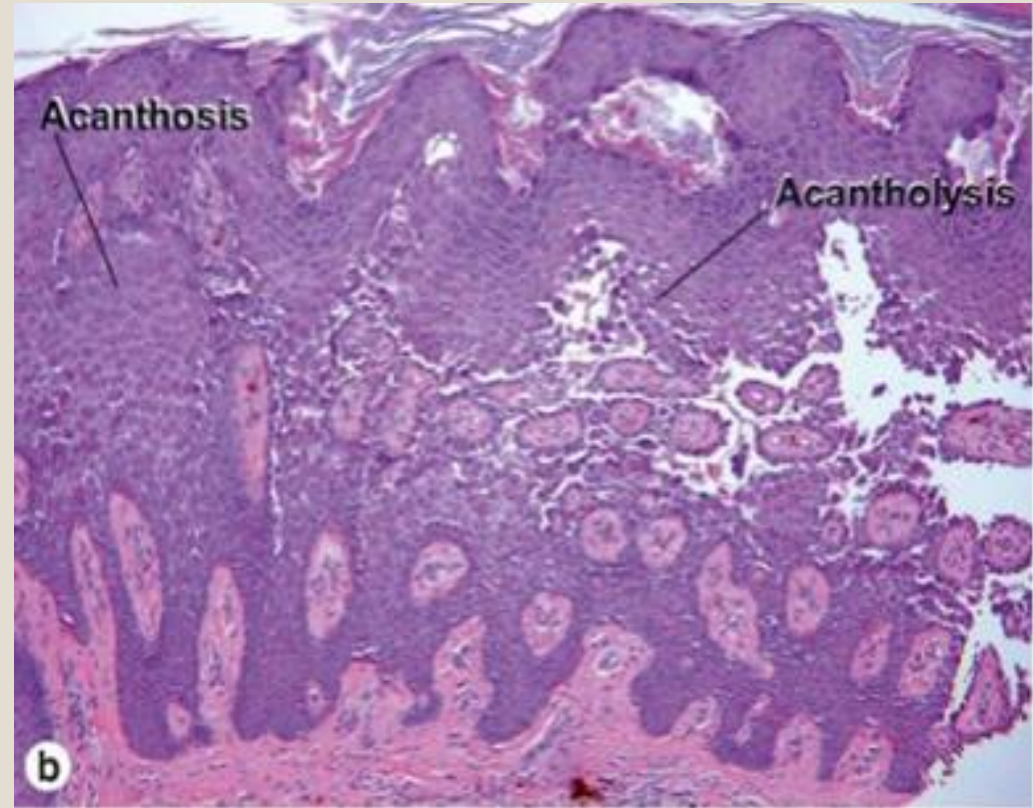
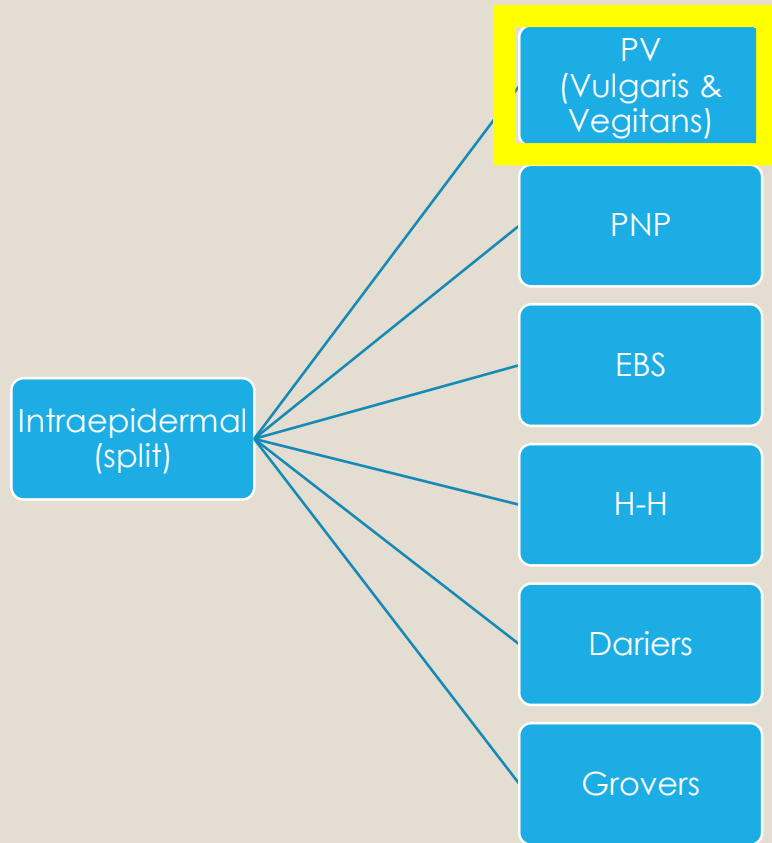
**IgA Monoclonal
Gammopathy
“HI SPEED”
HSP
IgA Pemphigus
Sneddon-Wilkinson
Pyoderma gangrenosum
EED**

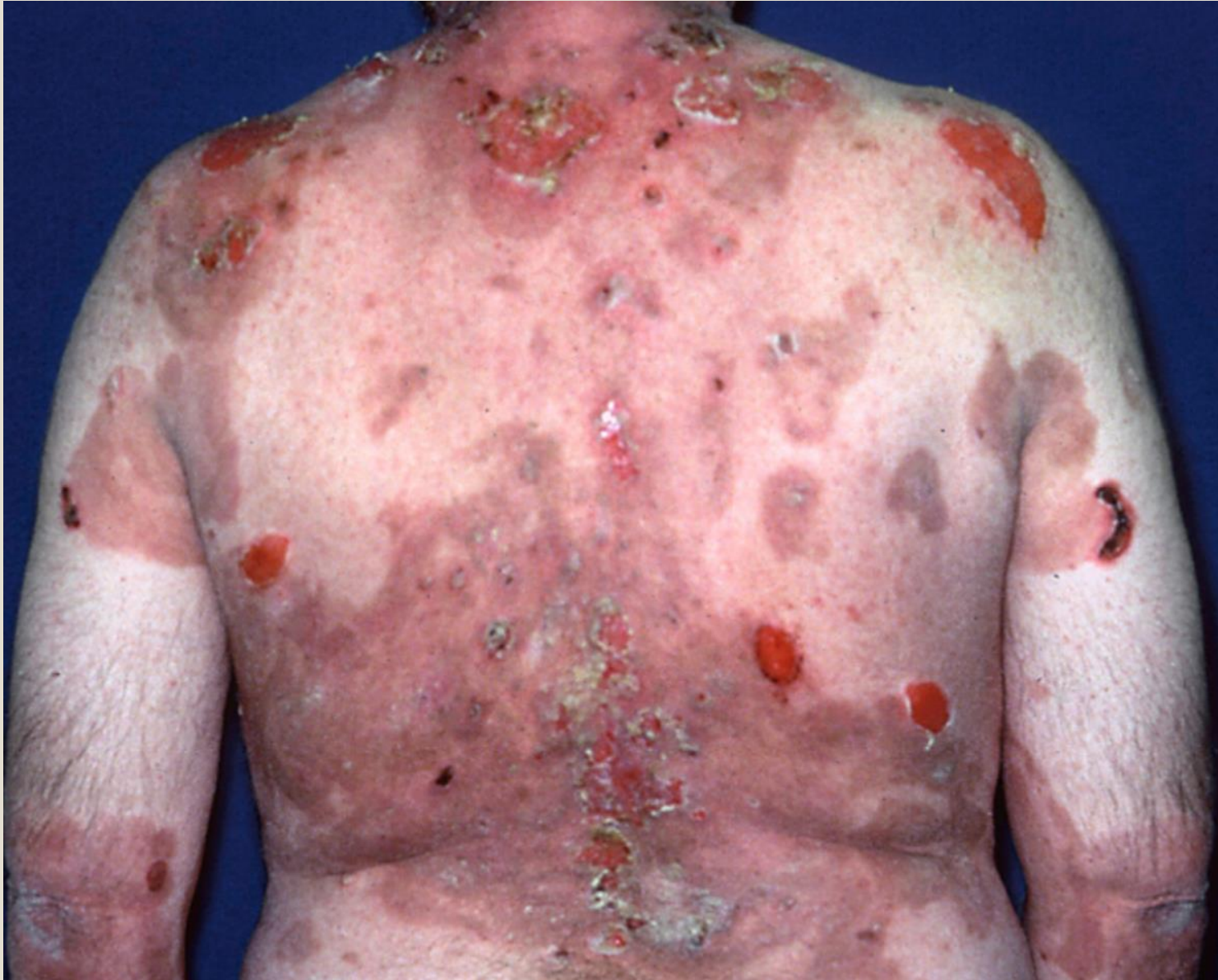Sneddon-Wilkinson:

classic subcorneal pustular dermatosis

- Variant of IgA pemphigus, analogous to the SPD type. Only difference is DIF/IIF.
- **IgA anti-Desmocollin-1**
- SPD = + DIF
- Sneddon Wilkinson = - DIF
- Tx: Dapsone

Intraepidermal split





- **Flaccid vesicles** and bullae, with secondary **erosion**, crusting, and collarettes of scale and PIH.

Pemphigus Vulgaris

Pathogenesis:

- MC form of pemphigus in most of world (PV: PF ~3:1)
- M=F; 50-60yo; Jewish 10x ↑ incidence
- Associated diseases: **myasthenia gravis, thymoma, & AI thyroiditis**
- 2 subtypes:
 - **Mucosal Dominant:** IgG to **Dsg-3** → mucosal dominant pemphigus
 - **Mucocutaneous:** IgG to **Dsg-1 & Dsg-3** (Dsg-1 = 160kDa, Dsg-3 = 130kDa) → mucocutaneous pemphigus

Clinical features

- Oral erosions
- Skin involvement (50%): **flaccid** vesicles/bullae → widespread denudation may result in death from fluid imbalance or secondary infection
- + Nikolsky & Asboe-Hansen signs; **heals without scarring**

Pemphigus Vulgaris

Diagnosis

- **Histo:**

- Eosinophilic spongiosis (early) → intraepidermal acantholysis (tombstoning of basal layer).
- Acantholysis down hair follicles and adnexa (Hailey-Hailey ≠ adnexal involvement)

- **DIF: most reliable test (~100%) perilesional biopsy**

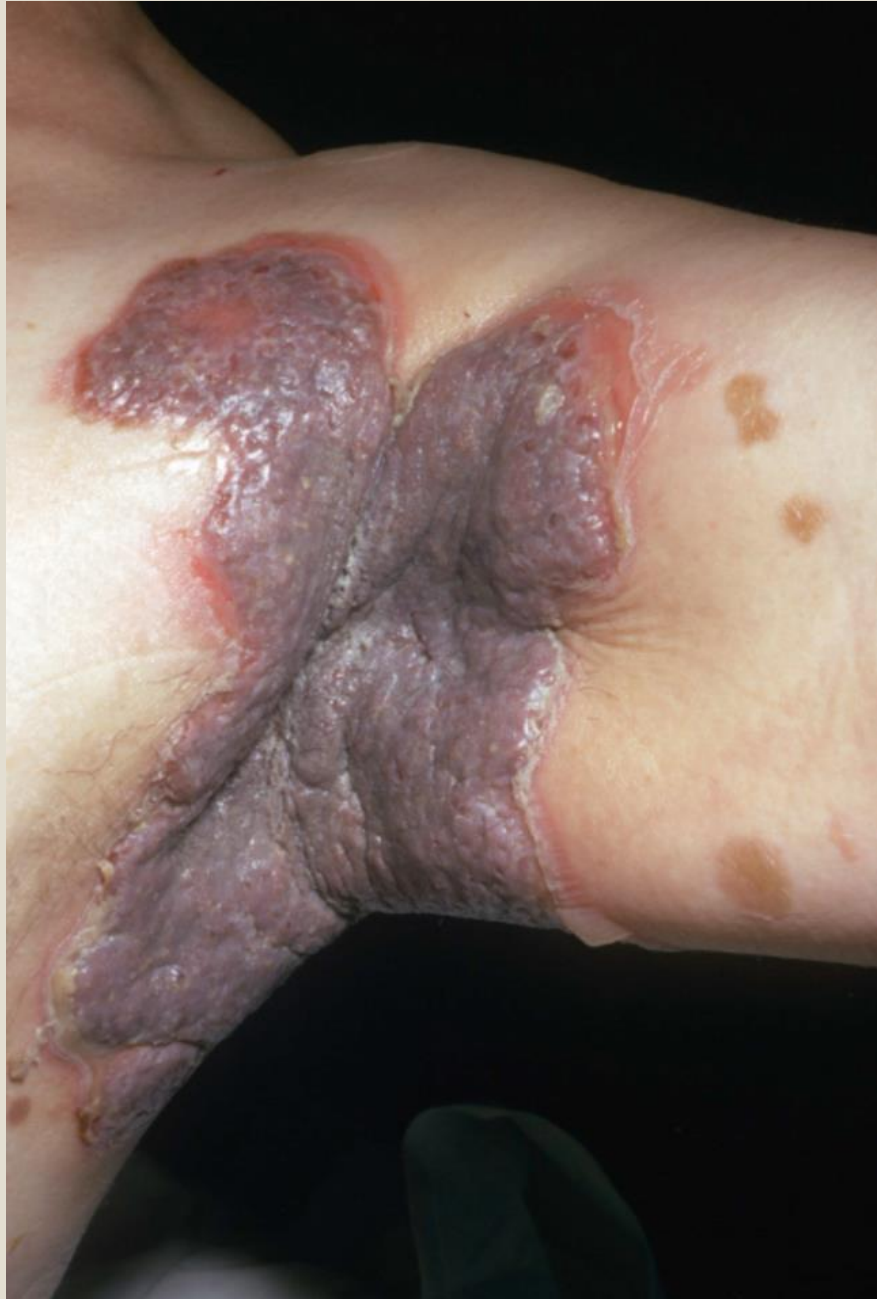- Intercellular “**chicken wire**” IgG (100%) +/- C3, lower epidermis most strongly stained

- **IIF: pt's serum on **Monkey Esophagus tests for patient's anti-IgG DSG3**; levels correlate with dz activity (useful for monitoring)**

- **ELISA: assesses pt's serum for IgG anti-Dsg1 & 3; levels correlate w/ dz activity (useful for monitoring); **can distinguish between pemphigus types****

- **Treatment**

- First line: PO steroids + Azathioprine
- TCNs + nicotinamide if mild
- Tx resistant: IVIG, **rituximab**
- **Monitor tx response with IIF or ELISA**



- A large vegetating plaque in the axilla, and associated outlying smaller, similar plaques.

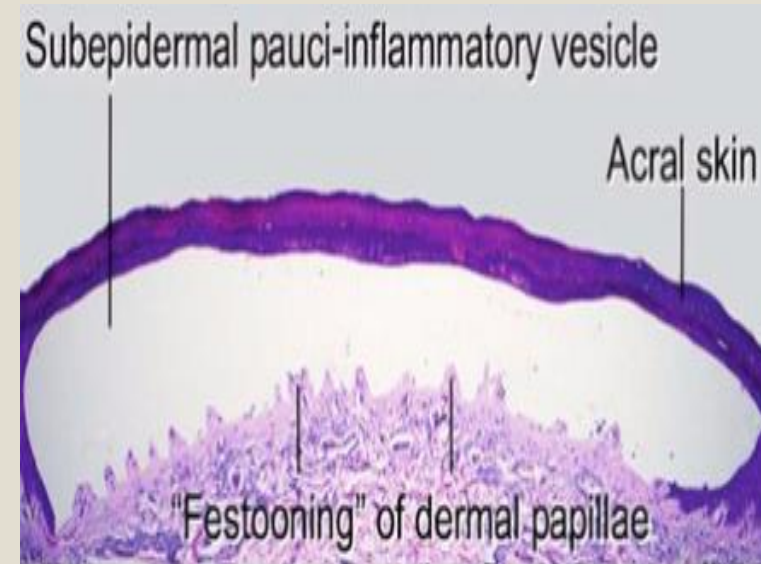
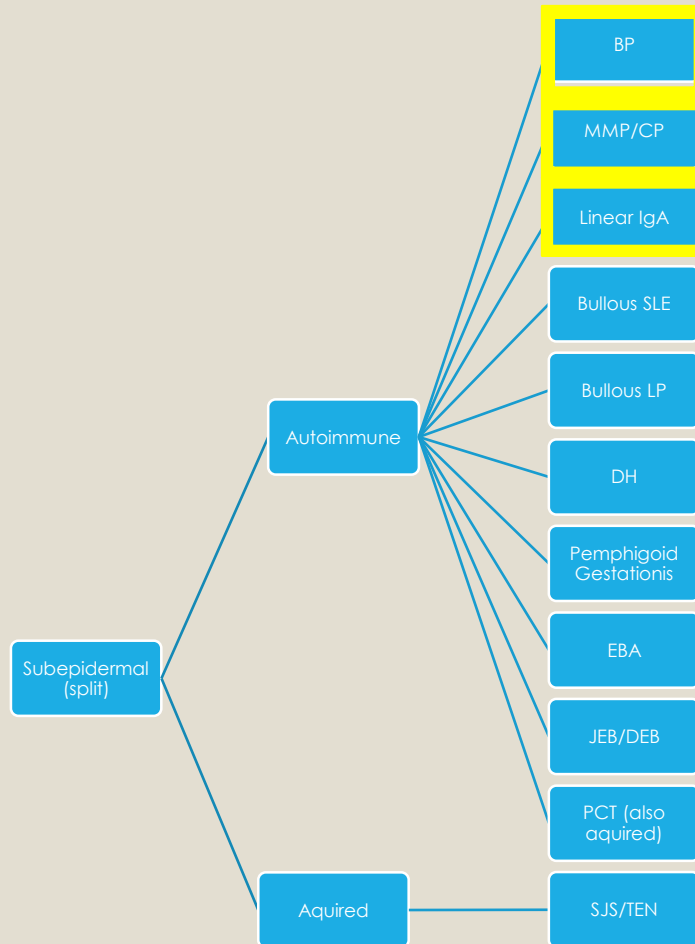
Pemphigus Vegetans

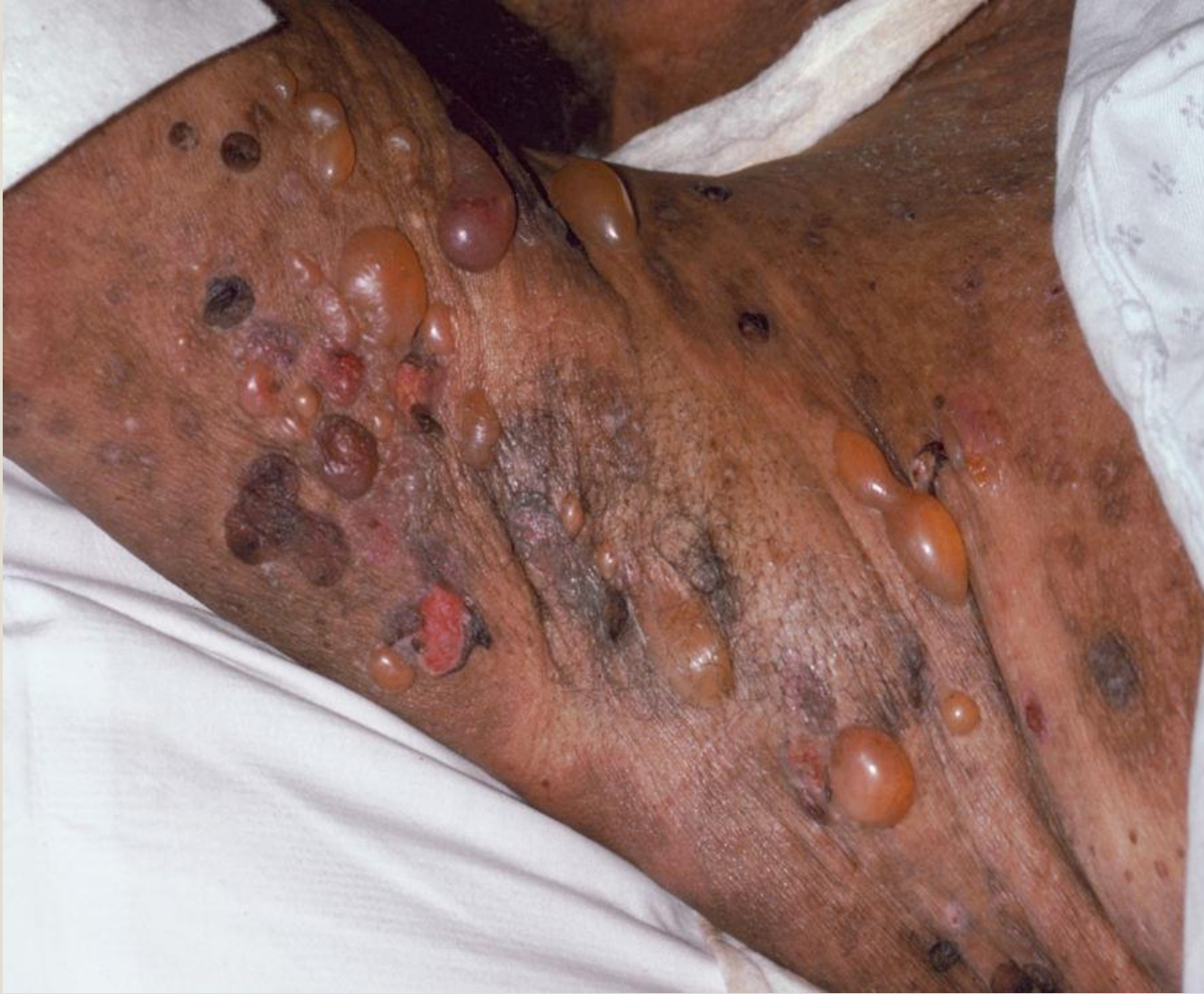- Vegetative variant of PV affecting intertriginous areas (>scalp & face): reactive phenomenon to friction; pustules w/ malodorous plaques
- 2 subtypes:
 - **Neumann: severe, generalized**
 - **Hallopeau: local, less severe**
- Histo: PEH, intraepidermal eosinophilic abscesses, & suprabasilar acantholysis (often subtle)
- DIF/IIF/ELISA/Tx same as pemphigus vulgaris

Drug Induced Pemphigus

- IgG anti-DSG 1 & 3
- PF-like presentation (4:1 PF:PV); most commonly induced by Thiol (sulfhydryl-containing drugs)
- MC = Thiol (sulfhydryl) drugs >> Non-thiols
 - Thiols: **Penicillamine**, ACE inhibitors (**Captopril** > enalapril, lisinopril), ARBs
 - Non-thiols: B-lactams, gold, CCB, BBlockers, piroxicam, rifampin

Subepidermal split





- Multiple **tense vesicles** and bullae with some nearby erosions and crusts in the axilla.

Bullous Pemphigoid

Pathogenesis

- MC autoimmune blistering disorder
- IgG autoantibodies against **BP180 (BPAG2, Type XVII collagen)** a 180kD transmembrane protein, the main pathogenic target is the **NC16A domain** & **BP230 (BPAG1)** a 230kD cytoplasmic protein belonging to the **plakin** family

Clinical features

- MC >60 y/o, M>F
- Non-bullous phase (early): urticarial pruritic plaques
- Bullous phase: tense bullae on the trunk
- Oral involvement 10-30%
- Peripheral eosinophilia (50%)

Clinical Course

- Chronic, may be a/w significant morbidity but usually low mortality
- Elevated ELISA levels or +DIF (linear C3 & IgG) at time of therapy cessation → **higher risk of relapse**

Bullous Pemphigoid

◦ **Diagnosis**

- Biopsy for H&E → **subepidermal split with EOS**
- **DIF = most sensitive → linear C3 (n-serrated pattern) & IgG.** Biopsy from perilesional, uninvolved skin.
- IIF: 80% linear IgG at BMZ, epidermal or roof on SSS → **no correlation with disease activity**
- **ELISA (80-90% sensitivity):** serum test for detecting circulating IgG to BP180 & BP230
 - Levels correlate strongly w BP dz activity → useful for monitoring response
 - High ELISA levels &/or positive DIF at time of tx cessation → high chance of relapse

Treatment

- **First line = 0.5-1mg/kg/d x 1-2 weeks with a 6-9 month taper + steroid sparing agent immunosuppressive (MTX, mycophenolate mofetil, azathioprine or cyclophosphamide)**
- Other options
 - TCN + Nicotinamide 500mg TID (mild disease)
 - Dapsone (mucosal predominate BP)
 - Rituximab (recalcitrant cases)
 - IVIG

BP Variants

- **Pemphigoid vegetans** → plaques in intertriginous areas
- **Childhood pemphigoid** → acral bullae w/ increase facial/genital involvement
- Pemphigoid nodularis
- **Lichen planus pemphigoides** → LP/BP overlap
- **Pemphigoid gestationis** → linear C3 on DIF
- Anti-p200 pemphigoid → often a/w PSO
- Anti-p105 pemphigoid → resembles SJS/TEN
- **Drug induced pemphigoid** → Fat abdomens covered by pemphigoid

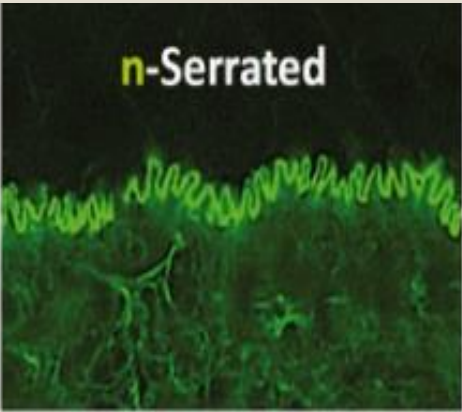

Drug induced BP

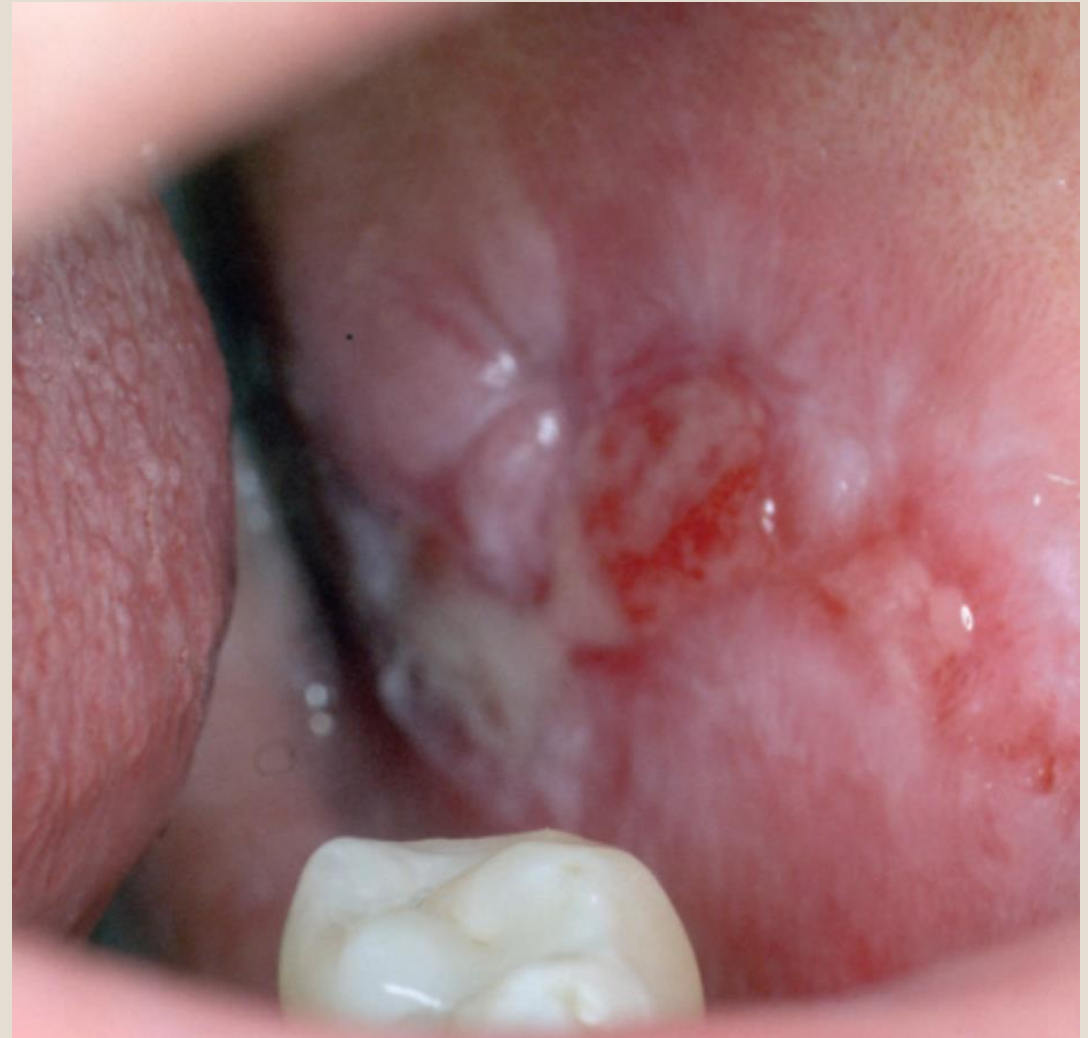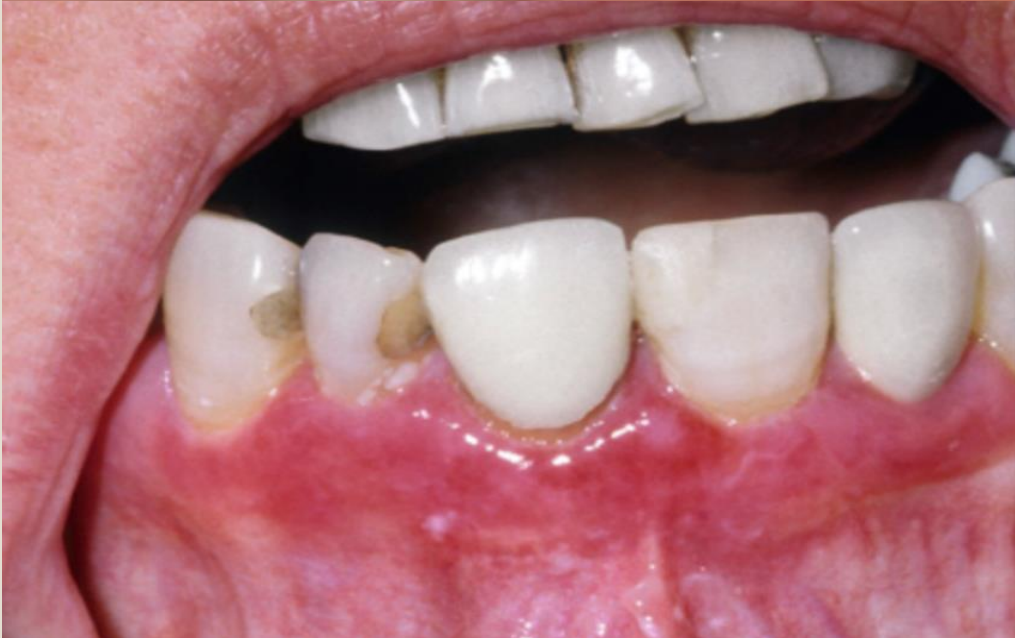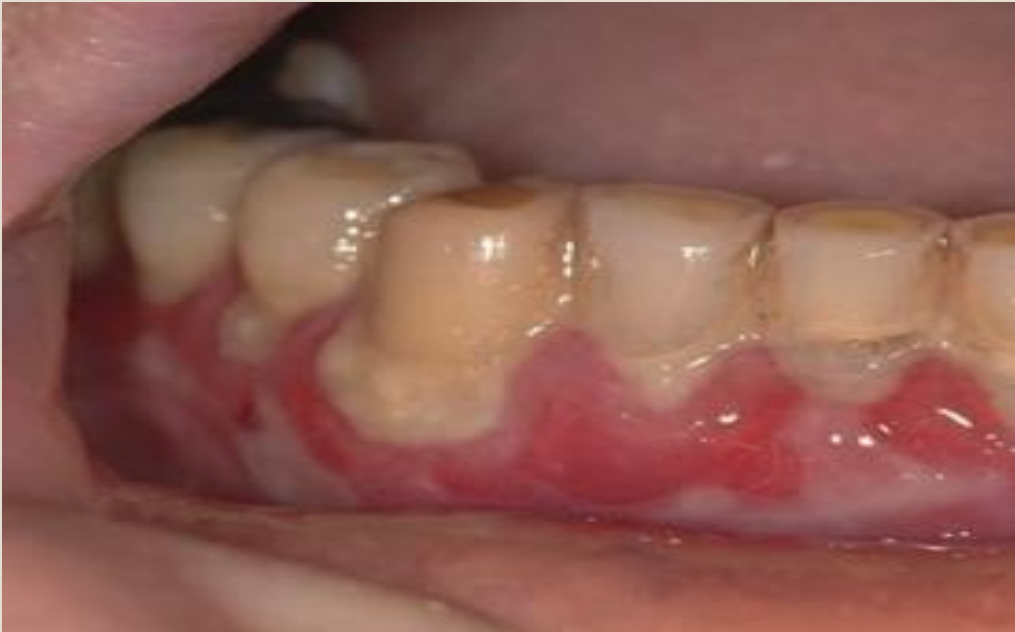- Mnemonic: “Fat Abdomens Covered By Pemphigoid”
 - Furosemide
 - ACE-inhibitors
 - Cephalosporins
 - B-lactams
 - Penicillamine/PD1 inhibitors

- NSAIDs
- Gold
- Sulfa/Spirolactone/Sitagliptin (DPP-4 inhibitor)

Serration Patterns in Subepidermal Blistering Diseases

- **N-serrated linear DIF = BP**
 - Others: MMP, CP, LAD, p200, anti-LN-332
- **U-serrated linear DIF = EBA**
 - Others: BSLE

	n-Serrated		u-Serrated	
DIF BMZ				
IIF salt-split	Epidermal side	Dermal side	Dermal side	
sAIBD	BP MMP CP LAD	p200 anti-LN-332	EBA bSLE	



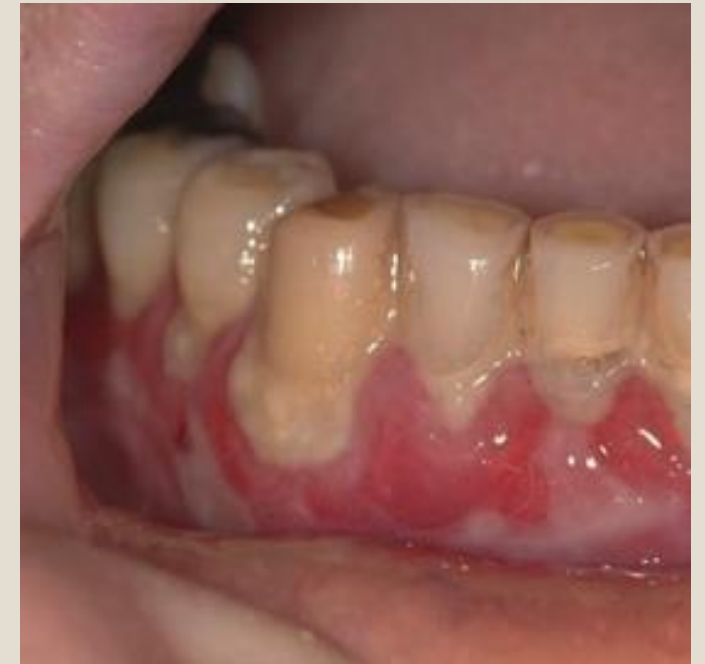Desquamative gingivitis + oral bullae

Cicatricial Pemphigoid

aka mucous membrane pemphigoid (MMP)

Pathogenesis

- Autoreactive IgG abs directed against **anchoring filament zone** (vs hemidesmosomal plaque in BP)
- **4 subgroups:**
 - Ocular MMP = **$\beta 4$ subunit** of $\alpha 6\beta 4$ integrin (transmembrane component of hemidesmosome)
 - Anti-BP MMP: Mucosal + skin dz = **BPAg2 (distal C-terminal)**
 - Anti-epiligrin MMP: strongly a/w underlying solid organ malignancy (#1=adenocarcinoma) → **Laminin 332 (5/epiligrin)**; salt split skin shows **dermal staining**
 - Brunsting-Perry variant: limited to head/neck, scarring alopecia. NO mucosal involvement.
- **Clinical Presentation:** 60-80yo
 - #1 MC site oral (85%); desquamative gingivitis
 - #2 MC Conjunctiva; **symblepharon**, trichiasis → **blindness**
 - **Skin (25%):** MC scalp/face/neck, upper trunk; erythematous plaques, recurrent blisters/erosions heal w atrophic scars (not seen in BP)
- **Associated Dx: Adenocarcinoma** (Laminin 332/5/anti-epiligrin MMP)



Desquamative gingivitis

Cicatricial Pemphigoid

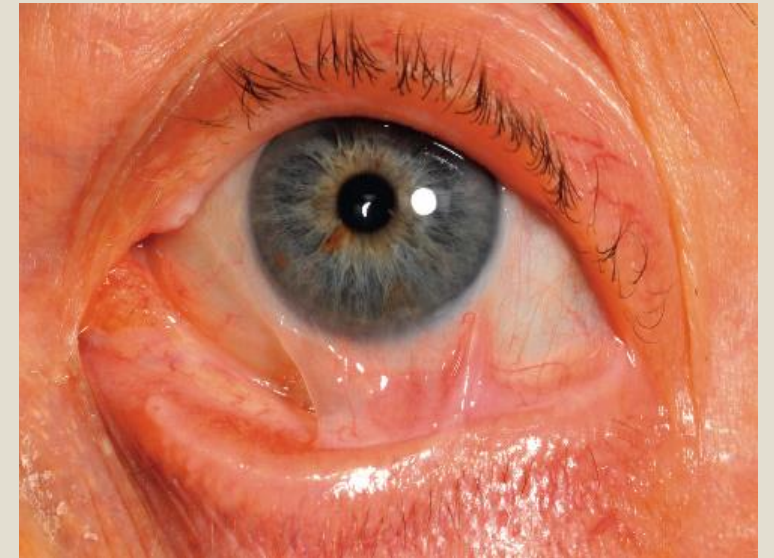aka mucous membrane pemphigoid (MMP)

Diagnosis

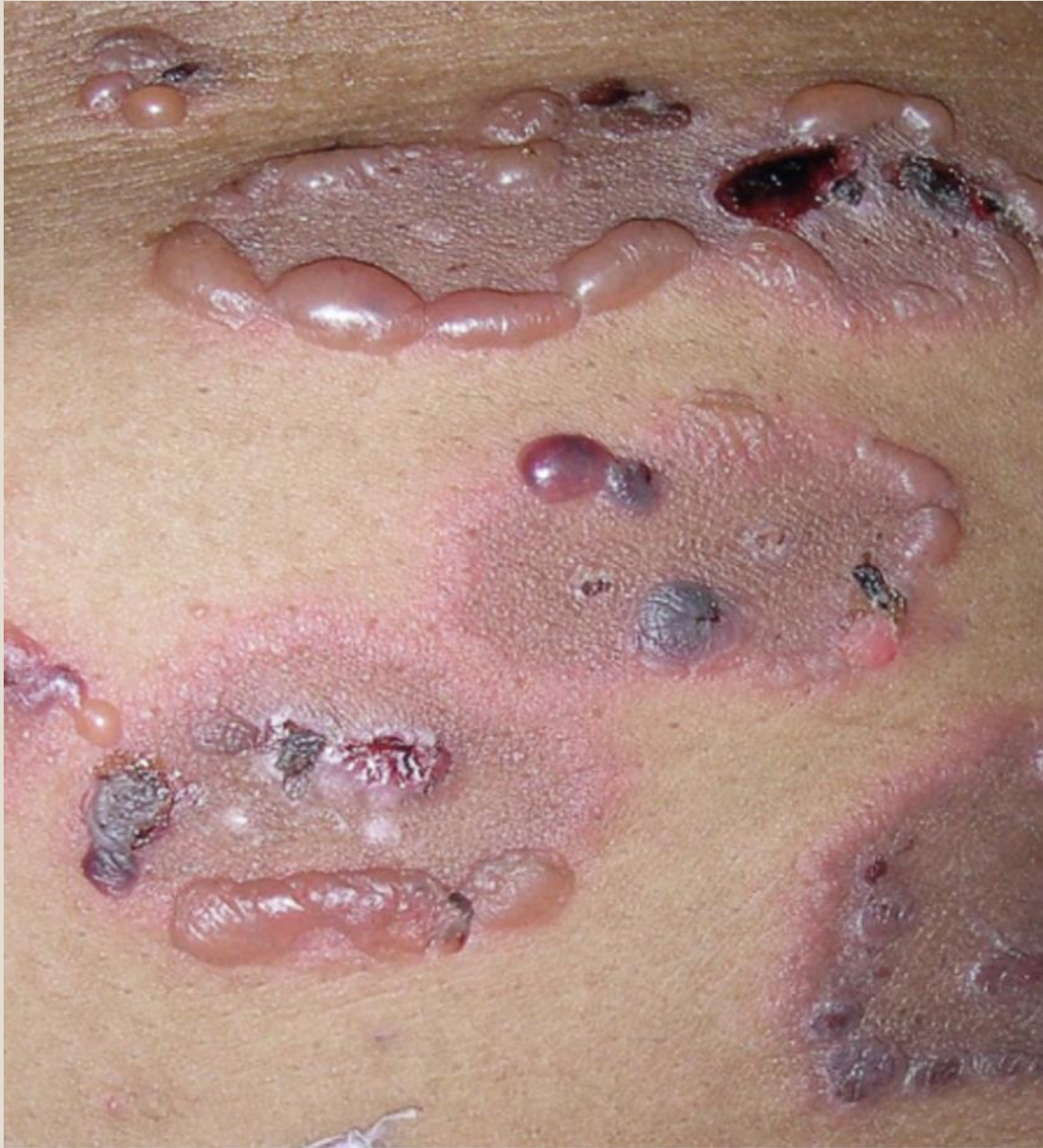- Biopsy for H&E → **subepidermal split with EOS**
- **DIF = most reliable test** → **Linear IgG**, IgA, &/or **C3** along BMZ (perilesional; more frequently + in oral lesions)
- IIF: only 20-30% will have detectable circulating Abs
- S-SS: epidermal (roof) staining in all except Anti-laminin 332 (dermal)

Treatment

- **Dapsone** (1st line for **ORAL + CUTANEOUS** sx) and Steroids
- Severe/progressive ocular dz: **Cyclophosphamide (TOC)** + systemic steroids or steroid sparing **immunosuppressive (MMF, Azathioprine)**
 - “cyclops-phosphamide”
- IVIG & biologic agents for severe dz
- Surgical correction of ocular scarring - only AFTER dz controlled medically!



Synblepharon- adhesion of bulbar & palpebral conjunctivae



- Tense bullae & urticarial plaques in annular (“**crown of jewels**”) arrangement

Linear IgA Bullous Dermatositis (LABD)

Pathogenesis

- **IgA autoabs** against 2 related antigens, both derived from BPAG2:
 - LAD-1 (120kD cleaved portion of BP180 antigen)
 - LABD97 (97kD cleaved portion of LAD-1)

Clinical features

- Tense vesicles/bullae & urticarial plaques in annular, polycyclic, or herpetiform ("**crown of jewels**") arrangement; MC in flexures of lower trunk/thigh/groin/buttocks, & face (kids)
- Childhood Variant (4yo) = **Chronic Bullous Disease of Childhood**
- **Adult onset LABD is usually drug-induced** (ave >60yo): **MC Vancomycin** >PCN/CSN, captopril (>other ACEIs), NSAIDs >phenytoin, sulfonamides >many others (furosemide, lithium)
- **Diagnosis**
 - **Histo:** Early urticarial lesions → neuts diffusely lined up along BMZ w/ basal vacuolar change (represents early separation) +/- neut papillitis; Fully developed bullae → Subepidermal Blister w/ Neuts +/- neutrophilic papillitis. CANNOT distinguish from DH on H&E need DIF.
 - DIF: **Linear IgA** along BMZ +/- C3
 - IIF: + in 65% of cases, Linear IgA, stains epidermal side/roof on SSS

LABD

Treatment

- **Dapsone (TOC)** or Sulfapyridine → **rapid response (<72hrs)**
- Add PO corticosteroids & immunosuppressants in refractory cases (uncommon)

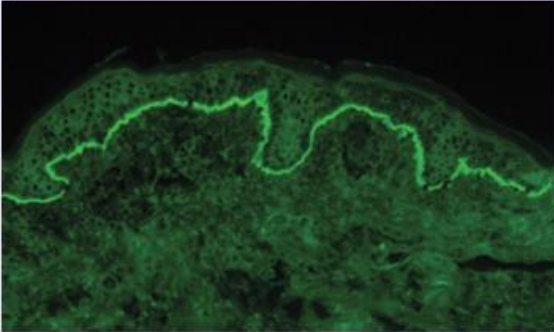
Clinical course

- Usually spontaneous remission in a few years

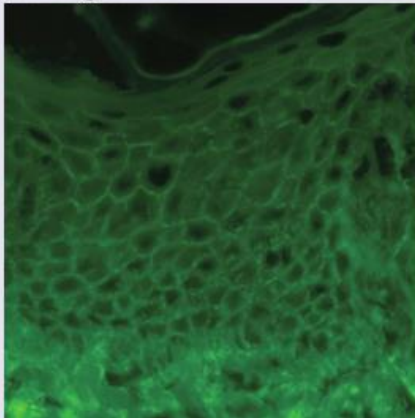
DIF Review

Direct immunofluorescence pattern

Linear C3 and IgG at the dermal-epidermal junction



Intercellular IgG and C3

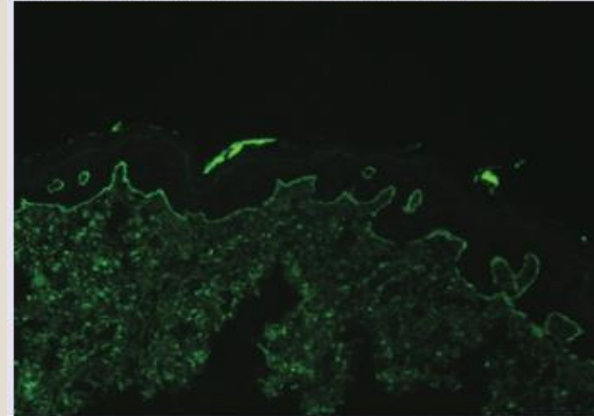


Blistering disorder

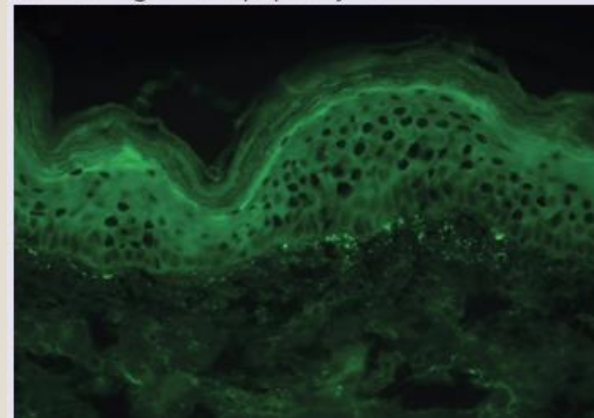
Bullous pemphigoid
Pemphigoid gestationis
Cicatricial pemphigoid
Epidermolysis bullosa
acquisita
Bullous lupus
erythematosus*

Pemphigus vulgaris
Pemphigus foliaceus

Linear IgA at the dermal-epidermal junction



Granular IgA in the papillary dermis



Linear IgA disease
Cicatricial pemphigoid

Dermatitis herpetiformis

Disease	Antigen	Size (kDa)	DIF	Salt-Split Skin
Bullous pemphigoid	BPAG1 (plakin)	230	Linear C3 and IgG along BMZ in "n-serrated" pattern	Epidermal
	BPAG2 (collagen XVII)	180		
Pemphigoid gestationis	BPAG2 (Collagen XVII)	180	Linear C3 > IgG along BMZ	Epidermal
LABD	LAD-1 (120kDcleaved portion of BPAG2) LABD97(97kDcleaved portion of LAD-1)	120→97	Linear IgA +/-C3 along BMZ	Epidermal (IgA)
Mucous membrane pemphigoid (classic form)	BPAG2 (C-terminus)	180	Linear IgG and C3 along BMZ	Epidermal (or both sides with stronger staining on epidermal side)
Ocular-predominant MMP	β_4 integrin	NA	Linear IgG and C3 along BMZ	Epidermal
Anti-epiligrin MMP	Laminin 332	400-440	Linear IgG and C3 along BMZ	Dermal
p200 pemphigoid	Laminin γ 1	200	Linear IgG and C3 along BMZ	Dermal
p105 pemphigoid	NA	105	Linear IgG and C3 along BMZ	Dermal
Bullous SLE	Type VII collagen(anchoring fibrils)	290	Granular to linear staining w/multiple reactants (IgG, IgA, IgM, C3)	Dermal

Etiologies

- **Infectious: bacterial & viral**
- **External**
- **Autoimmune**
- Genetic
 - Porphyria cutanea tarda (PCT)
 - Epidermolysis bullosa (EB)
 - Epidermolysis bullosa acquisita (EBA)
- **Medication**
- Overlap/Multiple etiologies → Hospital consults
 - Bullous Erythema Multiforme
 - Stevens-Johnson syndrome/Toxic Epidermal Necrolysis

Resources

- Fitzpatrick JE, High WA, Kyle WL. Urgent care dermatology: symptom-based diagnosis. Philadelphia: Elsevier, 2018
- Bassi A, Greco A, de Martino M. Neonatal onychomadesis. Archives of Disease in Childhood - Fetal and Neonatal Edition 2016;101:F161.
- Broccolo, Francesco, et al. "Possible long-term sequelae in hand, foot, and mouth disease caused by Coxsackievirus A6." Journal of the American Academy of Dermatology 80.3 (2019): 804-806.
- Bologna, Jean, Joseph L. Jorizzo, and Julie V. Schaffer. 2012. Dermatology. [Philadelphia]: Elsevier Saunders.
- WJames W, Elston D, and McMahon P. Andrews' Diseases of the Skin Clinical Atlas. Hardcover ISBN: 9780323441964. Imprint: Elsevier. 24th February 2017. Page Count: 616
- Alikhan A and Hocker T. 2017. Review of Dermatology. [Philadelphia]: Elsevier Saunders.
- Collins P, Sepede J. Bullous arthropod bite reaction. BMJ Case Reports CP 2018;11:e228079.
- Visual Diagnoses, online.
https://www.visualdx.com/visualdx/diagnosis/hand+foot+and+mouth+disease?moduleId=102&diagnosisId=51665&lang=en_US#view=text



THANK YOU

Kate Braunlich, DO, PGY4