

Original article

Endoscopy and upper gastrointestinal contrast studies are complementary in evaluation of weight regain after bariatric surgery

Stacy A. Brethauer, M.D., Valentine Nfonsam, M.D., Vadim Sherman, M.D.,
Suthep Udomsawaengsup, M.D., Philip R. Schauer, M.D., Bipan Chand, M.D.*

Department of General Surgery, Bariatric and Metabolic Institute, Cleveland Clinic, Cleveland, Ohio

Received May 30, 2006; revised July 22, 2006; accepted July 27, 2006

Abstract

Background: To assess the utility of upper endoscopy (EGD) and upper gastrointestinal (UGI) contrast studies in the evaluation of weight regain after previous bariatric surgery.

Methods: We retrospectively reviewed the findings of EGD and UGI studies for patients referred to our center for weight regain after bariatric surgery. All patients received a dietary assessment concomitant with the anatomic evaluations.

Results: From January 2003 and March 2006, 30 patients qualified for the study (25 women and 5 men, average age 49 years). Of the 30 patients, 16 had undergone gastroplasty and 14 open Roux-en-Y gastric bypass. Of the 30 patients, 27 (90%) had ≥ 1 abnormality detected on UGI study or EGD. Of these abnormalities, 10 were gastrogastic fistulas, 8 of which were detected with both UGI study and EGD; 11 dilated pouches were diagnosed by EGD but only 2 were also diagnosed on the UGI study. An enlarged stoma size was diagnosed in 7 patients (6 by EGD and 1 on the UGI study). Also, the UGI study diagnosed 1 Roux limb and 7 esophageal abnormalities not seen on EGD, and EGD diagnosed 4 esophageal and 3 gastric abnormalities not seen on the UGI study. On the basis of these findings and the dietary evaluation, 23 patients (77%) were offered a revisional procedure.

Conclusion: EGD and UGI contrast studies are complementary in the evaluation of patients with weight regain after bariatric surgery. The combination of the 2 studies detected all the gastrogastic fistulas present. EGD provided more useful pouch and stomal information, and the UGI study detected esophageal or Roux limb abnormalities that frequently require additional evaluation. © 2006 American Society for Bariatric Surgery. All rights reserved.

Keywords:

Weight regain; Evaluation; Endoscopy; Radiographic; Revision; Gastrogastic fistula; Gastroplasty; Gastric bypass

Bariatric surgery is currently the most effective means for morbidly obese patients to achieve weight loss. Roux-en-Y gastric bypass (RYGB) provides durable weight loss for most patients, but 10%–15% of patients undergoing this procedure will fail to lose weight or will have weight re-

cidivism. The reasons for weight regain after gastric bypass can be behavioral or anatomic, or both. Careful evaluation of the psychological and nutritional factors and a detailed anatomic evaluation are required before offering a revisional procedure to these patients.

Many patients who have undergone vertical banded gastroplasty (VBG) have poor long-term outcomes. Only 26%–40% of patients maintain acceptable ($>50\%$) excess weight loss and one third of patients will meet or exceed their preoperative weight 10 years after surgery [1,2]. Weight loss failure in these patients may be secondary to maladaptive eating behaviors related to the fixed or stenotic gastric

Presented at the 23rd Annual Meeting of the American Society for Bariatric Surgery; June 26, 2006, San Francisco, California

*Reprint requests: Bipan Chand, M.D., Division of Surgical Endoscopy, Department of General Surgery, Cleveland Clinic, 9500 Euclid Avenue, M61, Cleveland, OH 44195.

E-mail: chandb@ccf.org

Table 1
Patient characteristics at evaluation

Characteristic	Gastroplasty	RYGB	All	<i>P</i> value
Patients (n)	16	14	30	
Women (%)	88	79	83	.64
Age (yr)				.01
Mean SD	52 ± 5	46 ± 8	49 ± 17	
Range	33–58	45–63	33–63	
BMI (kg/m ²)	48.6 ± 8.3	43.3 ± 10	46.1 ± 9.5	.06
Interval since primary procedure (yr)	18.3 ± 5.6	5.3 ± 2.5	12.6 ± 8.2	<.0001
Weight gain from nadir (kg)*	44.9 ± 36.7	20.8 ± 9.0	34.0 ± 29.9	.04
Severe symptoms† (%)	11/16 (69)	5/14 (36)	16/30 (53)	.15
Co-morbidities (n)	4.7	1.8	3.3	.001

RYGB = Roux-en-Y gastric bypass; BMI = body mass index.

Data presented as mean ± SD, unless otherwise noted.

*Accurate weight nadir available for 9 RYGB and 11 gastroplasty patients.

†Included severe nausea, vomiting, gastroesophageal reflux, limited ambulation secondary to joint pain, symptomatic ventral hernia, and abdominal pain.

outlet [3] or the high failure rate ($\leq 48\%$) of the vertical staple line [4]. Additionally, VBG patients frequently have severe gastroesophageal reflux or intractable nausea and vomiting that necessitates conversion to RYGB [5–7].

The objective of this study was to evaluate the findings of upper gastrointestinal (UGI) contrast study and endoscopy (EGD) in patients referred to our center for weight regain after bariatric surgery. Additionally, the patient characteristics at referral and the outcomes of the patients who underwent revisional surgery were assessed.

Methods

After the institutional review board approved the study, we conducted a retrospective review of our endoscopic and bariatric database to identify patients evaluated for weight regain or failed weight loss after a bariatric procedure. Only patients who had completed both EGD and UGI studies were included in the analysis. At referral, all patients underwent nutritional counseling, and psychiatric referrals were made when indicated by the symptoms.

In our practice, and for the purposes of this study, a pouch is considered enlarged or dilated if >6 cm in length, >5 cm wide, or containing fundus on the UGI study or on retroflexion during EGD. Stomas >2 cm in diameter were classified as enlarged. Currently, no criteria or standardized techniques have been established to measure pouch or stoma size. The criteria we used were based on our clinical experience.

UGI series were performed using dilute barium and standard fluoroscopic techniques. The bariatric surgeon reviewed all UGI images and reports at the patient's evaluation. For this study, the findings from the UGI studies were obtained from the written radiology reports and entered into the database. No UGI video images were archived, but at the chart review, static UGI images were available for 23 patients (77%), and these images were reviewed by the investigators. Pouch and stomal measurements were ob-

tained from the written report based on the initial interpretation. When specific measurements were not stated in the report, subjective statements such as "enlarged gastric pouch" or "enlarged gastric stoma" were confirmed on the UGI study images and considered positive findings.

Of the 30 EGDs, 25 (83%) were performed by 1 surgical endoscopist (B.C.) and 5 by the attending gastroenterologist or surgeon. Endoscopic measurements of pouch length were determined by the distance from the incisors, and the pouch width was determined relative to the diameter of the scope or an endoscopic instrument passed through the working channel. All EGD examinations had images available for review, and the findings from the written report were entered into the database.

Co-morbidities were obtained from the patient records and were determined according to the appropriate biochemical, radiologic, or clinical criteria. The resolution of co-morbidities was determined by the absence of these same diagnostic criteria after surgery or the cessation of treatment for a condition.

Statistical analysis was performed using the chi-square, Fisher exact, McNemar, and Student *t* tests, as appropriate. $P < .05$ was considered statistically significant.

Results

From January 2003 to March 2006, 30 patients referred for weight regain after bariatric surgery had EGD and UGI study results available. Of these 30 patients, 16 had undergone gastroplasty and 14 had undergone open RYGB. Of the gastroplasty procedures, 3 were horizontal gastroplasties and 13 were VBGs. Three of the RYGB patients had received nondivided gastric pouches at their initial surgery. Table 1 shows the patient characteristics at the evaluation; the differences between the gastroplasty and RYGB groups were significant. Although weight regain was the primary reason for the evaluation of the patients in this study, a significant proportion had severe symptoms related to their

Table 2
Co-morbidities present at evaluation

Co-morbidity	Gastroplasty (n = 16)	RYGB (n = 14)	All (n = 30)	P value
Osteoarthritis	11(69)	5(36)	16(53)	.15
Depression	10(63)	5(36)	15(50)	.27
GERD	12(75)	2(14)	14(47)	.003
Diabetes	6(38)	7(50)	13(43)	.75
Hypertension	8(50)	3(21)	11(37)	.21
Sleep apnea	7(44)	0	7(23)	.007
Hyperlipidemia	5(31)	1(7)	6(20)	.18
Asthma	4(25)	1(7)	5(17)	.34
Leg edema	4(25)	0	4(13)	.10
Cardiomyopathy	1(6)	2(14)	3(10)	.59
Migraines	2(13)	0	2(7)	.49
Venous stasis	1(6)	1(7)	2(7)	1.00
Stress urinary incontinence	4(25)	1(7)	5(17)	.34
Pseudotumor cerebri	1(6)	0	1(3)	1.00

RYGB = Roux-en-Y gastric bypass; GERD = gastroesophageal reflux disease.

Data in parentheses are percentages.

primary procedure or weight regain. Of the gastroplasty patients, 11 (69%) had lifestyle-limiting symptoms, including gastroesophageal reflux or regurgitation in 9, joint pain with limited ambulation in 1, and a symptomatic ventral hernia in 1. Also, 5 RYGB patient had severe symptoms related to a symptomatic ventral hernia in 3, nonspecific abdominal pain in 1, and gastroesophageal reflux in 1 with a large gastrogastric fistula.

Overall, the patients had an average of 3.3 co-morbidities per patient at the evaluation for weight regain. Table 2 shows the co-morbidities overall and according to the primary procedure type.

Gastrogastric fistula was diagnosed in 10 patients (33%). Of these patients, 8 had failure of their gastroplasty staple line, and 2 patients with a non-divided RYGB developed a fistula. No undiagnosed gastrogastric fistulas were discovered during revisional surgery. Pouch dilation was detected in 11 patients (37%) and was equally distributed between the gastroplasty and RYGB patients (5 and 6 patients, respectively). Stomal dilation occurred in 2 gastroplasty and 5 RYGB patients (23%). Other findings detected during the preoperative evaluation included hiatal hernias in 5 patients (17%), evidence of esophageal acid exposure (esophagitis, gastroesophageal reflux disease, or Barrett's esophagus) in 6 patients (20%), esophageal dilation or dysmotility in 5 patients (17%), 2 gastric polyps (7%), 1 gastric ulcer (3%), and 1 dilated Roux limb (3%). The incidence of these findings was not significantly different between the gastroplasty and RYGB patients, although fistulas occurred in 50% of the gastroplasty patients and 14% of the RYGB group ($P = .06$).

Only 3 patients (10%) had normal postoperative anatomy with no abnormalities detected on either the UGI study or EGD. In the remaining 27 patients, a total of 22

abnormal findings were identified on UGI study and 36 were detected by EGD. Table 3 shows the distribution of these findings according to the test and abnormality detected. Of the 10 gastrogastric fistulas, 8 were seen on both studies, 1 was seen on the UGI study only, and 1 was seen by EGD only. Gastric abnormalities detected by EGD included 1 prepyloric ulcer in 1 VBG patient and a gastric polyp in 2 RYGB patients. One gastric polyp was located in the gastric pouch and the other was located in the gastric remnant. The presence of a gastrogastric fistula provided endoscopic access to the previously excluded stomach and allowed removal of the polyp. Both polyps were benign on final pathologic examination. Two RYGB patients with large gastrogastric fistulas had no contrast enter the Roux limb during the UGI study because it passed directly through the fistula into the previously excluded stomach (Fig. 1). Both patients subsequently had adequate endoscopic examinations of their gastrojejunal anastomosis and Roux limb.

On the basis of the findings of these tests and the nutritional and behavioral evaluations, 23 patients (77%) were offered a revisional procedure. At last follow-up, 15 patients had undergone a revisional procedure, 4 patients were awaiting revisional surgery, and 4 patients were awaiting endoscopic stomaplasty for a dilated gastrojejunostomy as a part of an investigational trial. The remaining 7 patients were not offered a revisional procedure because of the absence of an anatomic explanation for their weight regain or dietary issues.

Of the 15 patients with completed revisions, 14 underwent revision to a RYGB and 1, with multiple prior small bowel resections, underwent a sleeve gastrectomy. Nine revisions were attempted laparoscopically with 3 conversions to an open procedure; 6 were open. With an average of 11 ± 4 months of follow-up, the body mass

Table 3
Abnormalities detected according to test (all patients)

Abnormality	Detected on UGI	Detected on EGD	Total detected (n)	P value
Pouch dilation	2	11	11(37)	.008
Gastrogastric fistula	9	9	10(33)	1.00
Stomal dilation	1	6	7(23)	.13
Hiatal hernia	2	3	5(17)	1.00
Esophagitis	0	2	2(7)	.50
Barrett's esophagus	0	2	2(7)	.50
Gastric ulcer	0	1	1(3)	1.00
Gastric polyp	0	2	2(7)	.50
GERD	2	0	2(7)	.50
Dilated esophagus	3	0	3(10)	.25
Esophageal dysmotility	2	0	2(7)	.50
Dilated Roux limb	1	0	1(3)	1.00

UGI = upper gastrointestinal; EGD = endoscopy; GERD = gastroesophageal reflux disease.

Data in parentheses are percentages.

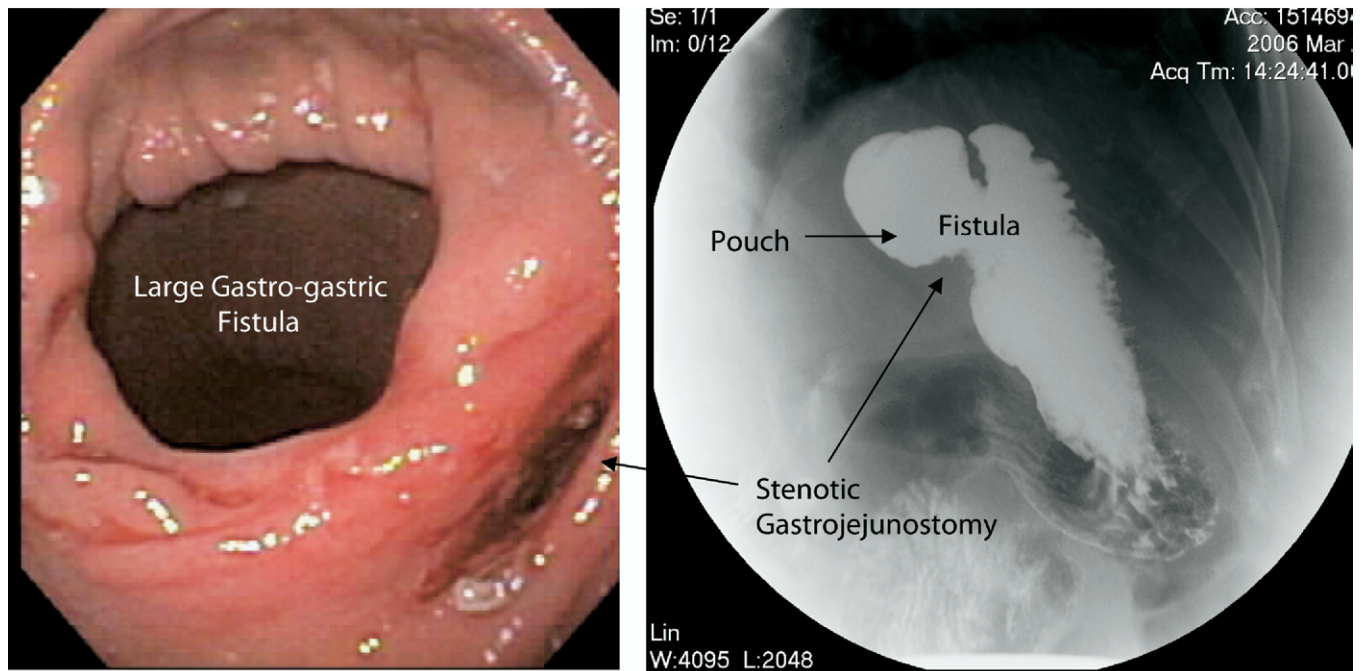


Fig. 1. UGI and EGD images from a patient who underwent gastric bypass surgery two years previously. The UGI shows a large gastro-gastric fistula with no filling of the Roux limb. Pouch size was interpreted as normal on UGI. The EGD revealed an 8 cm pouch containing a large amount of fundus, the large fistula, a stenotic gastrojejunostomy, and a normal Roux limb.

index decreased from 48.3 ± 10.3 to 36.8 ± 8.5 ($P < .001$), and the excess weight loss (from the evaluation for revision) was $52\% \pm 15\%$. Patients who had undergone revision had an average of 4.2 co-morbidities pre-operatively and, for those with >3 months of follow-up, 2.8 co-morbidities at the most recent follow-up visit ($P = .04$).

Discussion

One of the most common indications for repeat bariatric surgery is insufficient weight loss or weight regain [8–11]. Weight regain may be secondary to factors that eliminate the restriction of the procedure such as a gastrogastric fistula, dilated stoma, or a dilated pouch. Behavioral and dietary issues can also play an important role in weight regain, particularly when maladaptive eating behavior occurs in the setting of a fixed, stenotic outlet. Whether weight regain is the operation failing the patient or the patient failing the operation is a matter of much debate. In many cases, however, revisional surgery is appropriate. When an anatomic abnormality has been identified or when behavioral issues such as grazing, sweet eating, bingeing, and poor food choices have been ruled out as the cause, patients often benefit from the change to a different procedure. The most common bariatric salvage operation performed is RYGB [8–10,12–15]. Sugerman et al. [16] clearly demonstrated that revision of a failed gastroplasty to another gastroplasty procedure is inferior to conversion to RYGB and results in

more complications and less weight loss. Laparoscopic adjustable gastric banding has been used by some surgeons as a salvage procedure to replace or augment failed RYGB, with weight loss rates comparable to those after a primary band procedure [11,17,18].

Referrals for weight regain to our institution are primarily because of failed gastric bypass or gastroplasty procedures. We have demonstrated a difference between these two groups of patients in terms of the time to presentation after the primary procedure, with significantly more time elapsing after VBG (18 years) compared with after RYGB (5 years). Consequently, the patients presenting for revision of VBG were older and had more co-morbid conditions than did the patients with a failed RYGB. Although the patients selected for this study had a primary complaint of weight regain, more VBG patients had severe symptoms of gastroesophageal reflux, nausea, vomiting, and abdominal pain than did the patients with a failed RYGB. This is consistent with the well-described failure pattern of VBG in which patients develop severe symptoms with or without concomitant weight regain [1,6].

Limited data are available supporting routine EGD and UGI studies before primary bariatric surgery. Schirmer et al. found *Helicobacter pylori* infections in 30% of patients who were tested and found endoscopic abnormalities that changed or altered the operative procedure in 4.9% of patients [19]. Sharaf et al. [20] also evaluated the use of EGD before primary bariatric procedures in 195 patients and found ≥ 1 lesions in 89% of patients. Of these, 61% were determined to be clini-

cally important findings and included hiatal hernia (40%), gastritis (5%), esophagitis (5%), ulcer (8%), Barrett's esophagus (3%), and esophageal stricture (0.5%).

In a similar study evaluating UGI studies, Sharaf et al. [21] found ≥ 1 lesions in 48% of patients preoperatively, but only 5.3% of these changed or postponed the surgical procedure. The most common findings were gastroesophageal reflux (22%) and hiatal hernia (19%). A small number of patients had esophageal dysmotility, gastritis, or ulcers on the UGI study [20]. Frigg et al. [22] evaluated the use of the UGI study and EGD studies in 148 patients undergoing laparoscopic adjustable gastric banding. UGI studies showed 74 showed hiatal hernias, 2 motility disorders, and 1 incomplete malrotation. EGD showed reflux in 35 patients, gastritis in 53, and 24 *H. pylori* infections. Overall, EGD and the UGI study revealed pathologic findings needing therapy in 42% of patients [22].

No previously published reports have examined the utility of EGD and UGI studies before revisional bariatric surgery. In our retrospective review, both studies had a high rate of abnormal findings. Ninety percent of patients had an abnormal finding on 1 or both of the studies, and only 3 patients had normal postoperative anatomy on both studies. The findings that were the most clinically significant (the most likely causes of weight regain) were gastrogastic fistula, stomal dilation, and pouch dilation. EGD detected 26 (93%) of 28 of these abnormalities and the UGI studies detected 12 (43%) of 28. The combination of the UGI study and EGD found all the gastrogastic fistulas present, although neither test alone detected every fistula. Individually, each of the studies detected 90% of the fistulas present, but EGD detected significantly more pouch dilations and more stomal dilations. Accurate pouch sizing on the UGI study requires complete filling of the pouch with contrast. Rapid pouch emptying through a fistula or an enlarged stoma may inhibit pouch filling during the study and may partially explain why this finding was underreported on the contrast studies. One fistula was detected only by the UGI study in 1 patient who had undergone horizontal gastroplasty, and this was the primary indication for reoperation. Abnormalities detected only on the UGI study (esophageal dilation, dysmotility, gastroesophageal reflux disease) did not alter the course of the operation, but required additional gastroenterology evaluation before surgery. Additionally, the value of the anatomic roadmap provided by the UGI study, particularly for those patients with fistulas, cannot be underestimated. Revisional bariatric procedures have greater complication rates than primary procedures [10,23], and the amount of anatomic information regarding the patient's foregut should be maximized before surgery to optimize patient selection and avoid unexpected findings during these difficult cases.

The main limitation of this study was its retrospective design. The lack of a prospective, standardized method for pouch and stoma measurement on the UGI study and EGD

limits the conclusions that can be drawn from these data. However, the data analyzed for this study reflect the typical information received by the bariatric surgeon when evaluating patients for revision and therefore have some practical application. The order in which the testing is performed may also affect the sensitivity of the tests, and we could not control for this variable in our retrospective study.

The small number of revisions completed and the short follow-up period reported did not allow any conclusions to be drawn regarding the long-term success for these patients.

Conclusion

The evaluation of weight regain after bariatric surgery requires a detailed anatomic, behavioral, and nutritional evaluation to determine the etiology. Patient characteristics (age, weight regain, co-morbidities, interval since primary surgery) differ according to the primary procedure performed. The combination of EGD and UGI contrast studies provides a thorough assessment of the patient's postoperative anatomy. The gastric remnant after RYGB, however, can only be assessed in the presence of a large gastrogastic fistula.

In our retrospective study, EGD provided more detailed information regarding pouch and stoma size and the UGI study provided information regarding esophageal and Roux limb abnormalities that frequently required additional evaluation. The combination of both studies detected all the gastrogastic fistulas present. On the basis of our experience with patients referred for weight regain after bariatric surgery, these studies provide clinically important and complementary information, and we recommend performing both in the evaluation of these patients.

References

- [1] Balsiger BM, Poggio JL, Mai J, et al. Ten and more years after vertical banded gastroplasty as primary operation for morbid obesity. *J Gastrointest Surg* 2000;4:598–605.
- [2] Ramsey-Stewart G. Vertical banded gastroplasty for morbid obesity: weight loss at short and long-term follow up. *Aust N Z J Surg* 1995;65:4–7.
- [3] Salmon PA. Failure of gastroplasty pouch and stoma size to correlate with postoperative weight loss. *Can J Surg* 1986;29:60–3.
- [4] MacLean LD, Rhode BM, Forse RA. Late results of vertical banded gastroplasty for morbid and super obesity. *Surgery* 1990;107:20–7.
- [5] Kim CH, Sarr MG. Severe reflux esophagitis after vertical banded gastroplasty for treatment of morbid obesity. *Mayo Clin Proc* 1992; 67:33–5.
- [6] Nightengale ML, Sarr MG, Kelly KA, et al. Prospective evaluation of vertical banded gastroplasty as the primary operation for morbid obesity. *Mayo Clin Proc* 1991;66:773–82.
- [7] Balsiger BM, Murr MM, Mai J, Sarr MG. Gastroesophageal reflux after intact vertical banded gastroplasty: correction by conversion to Roux-en-Y gastric bypass. *J Gastrointest Surg* 2000;4:276–81.
- [8] Gagner M, Gentileschi P, de Csepe J, et al. Laparoscopic reoperative bariatric surgery: experience from 27 consecutive patients. *Obes Surg* 2002;12:254–60.

- [9] Jones KB Jr. Revisional bariatric surgery—safe and effective. *Obes Surg* 2001;11:183–9.
- [10] Khaitan L, Van Sickle K, Gonzalez R, et al. Laparoscopic revision of bariatric procedures: is it feasible? *Am Surg* 2005;71:6–12.
- [11] O'Brien P, Brown W, Dixon J. Revisional surgery for morbid obesity—conversion to the Lap-Band system. *Obes Surg* 2000;10:557–63.
- [12] Calmes JM, Giusti V, Suter M. Reoperative laparoscopic Roux-en-Y gastric bypass: an experience with 49 cases. *Obes Surg* 2005;15:316–22.
- [13] Sugerman HJ, Kellum JM Jr, DeMaria EJ, Reines HD. Conversion of failed or complicated vertical banded gastroplasty to gastric bypass in morbid obesity. *Am J Surg* 1996;171:263–9.
- [14] van Wageningen B, Berends FJ, Van Ramshorst B, Janssen IF. Revision of failed laparoscopic adjustable gastric banding to Roux-en-Y gastric bypass. *Obes Surg* 2006;16:137–41.
- [15] Westling A, Ohrvall M, Gustavsson S. Roux-en-Y gastric bypass after previous unsuccessful gastric restrictive surgery. *J Gastrointest Surg* 2002;6:206–11.
- [16] Sugerman HJ, Wolper JL. Failed gastroplasty for morbid obesity: revised gastroplasty versus Roux-en-Y gastric bypass. *Am J Surg* 1984;148:331–6.
- [17] Bessler M, Daud A, DiGiorgi MF, et al. Adjustable gastric banding as a revisional bariatric procedure after failed gastric bypass. *Obes Surg* 2005;15:1443–8.
- [18] Kyzer S, Raziell A, Landau O, et al. Use of adjustable silicone gastric banding for revision of failed gastric bariatric operations. *Obes Surg* 2001;11:66–9.
- [19] Schirmer B, Erenoglu C, Miller A. Flexible endoscopy in the management of patients undergoing Roux-en-Y gastric bypass. *Obes Surg* 2002;12:634–8.
- [20] Sharaf RN, Weinshel EH, Bini EJ, Rosenberg J, Sherman A, Ren CJ. Endoscopy plays an important preoperative role in bariatric surgery. *Obes Surg* 2004;14:1367–72.
- [21] Sharaf RN, Weinshel EH, Bini EJ, et al. Radiologic assessment of the upper gastrointestinal tract: does it play an important preoperative role in bariatric surgery? *Obes Surg* 2004;14:313–7.
- [22] Frigg A, Peterli R, Zynamon A, et al. Radiologic and endoscopic evaluation for laparoscopic adjustable gastric banding: preoperative and follow-up. *Obes Surg* 2001;11:594–9.
- [23] Gonzalez R, Gallagher SF, Haines K, Murr MM. Operative technique for converting a failed vertical banded gastroplasty to Roux-en-Y gastric bypass. *J Am Coll Surg* 2005;201:366–74.